

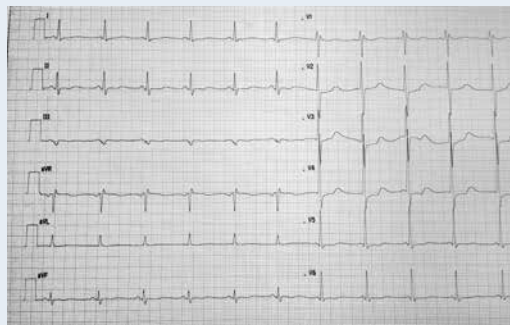
# Myocarditis and pericarditis in the course of colitis ulcerosa

Zapalenie mięśnia sercowego i osierdzia w przebiegu *colitis ulcerosa*

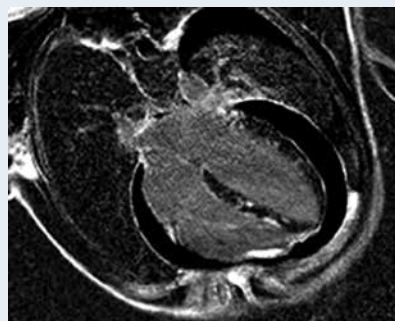
Maciej Mączyński, Magdalena Janus, Tatiana Mularek-Kubzdela, Stefan Grajek

1<sup>st</sup> Department of Cardiology, University of Medical Sciences, Poznan, Poland

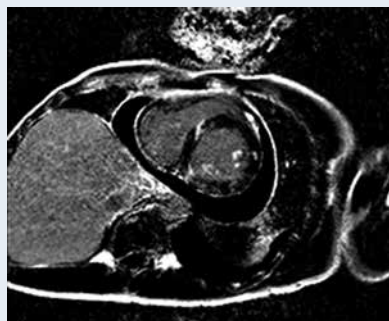
Colitis ulcerosa is a chronic inflammation of the mucous membrane of the colon. There are rare reports of cardiac manifestations of the disease. We present a case of pericarditis and myocarditis due to deterioration of colitis ulcerosa. A 28-year-old male patient was transferred to our clinic from the regional hospital with a diagnosis of myocarditis and pericarditis. Two years previously, he had been diagnosed with colitis ulcerosa and treated with sulfasalazin. One month prior to the current event, he discontinued treatment of sulfasalazin. On admission to our department, the patient was suffering from severe chest and abdominal pain. In physical examination, a pericardial friction rub was heard above the apex. Breathing sounds were diminished above the right base of the lung. Blood pressure was 110/70 mm Hg without the presence of tachycardia (Fig. 1). Jugular veins were normally extended. Laboratory tests disclosed: troponin I 12.051 (ref. 0.00–0.056) ng/mL, hs-C-reactive protein (CRP) 92.8 (ref. 0.0–5.0) mg/L, white blood count (WBC)  $14.81 \times 10^9/L$ , neutrophils 83.1%, red blood count  $3.56 \times 10^{12}/L$ , haemoglobin 6.60 mmol/L, alanine aminotransferase 323 U/L, aspartate aminotransferase 124 U/L, albumin 19.1 g/L; negative tests for: bacteria blood culture, Coxsackie B antibodies, Anti-HIV, Anti-HCV, HBs-Ag, CMV: IgM and IgG antibodies. In echocardiography, there was up to 27 mm fluid in the pericardium and hypokinesis of the infero-lateral wall of the left ventricle, with global left ventricular ejection fraction (LVEF) of 55%. A magnetic resonance imaging (MRI) scan of the heart was performed on the day of admission (Figs. 2, 3). The examination revealed significant pericardial effusion — up to 16 mm fluid with adhesions of its plaques, mostly in the frontal area of the right ventricle, with abnormal pericardial retraction. Patchy intramural areas of late gadolinium enhancement (LGE) in the myocardium were localised subpericardially in the apex and in the infero-lateral wall; transmural in the intraventricular septum and in the basic segment of the inferior wall. Short T1 inversion recovery (STIR) and T2 weighted images showed myocardial oedema of the inferior and lateral wall. Bilateral pleural effusion was present. We did not perform pericardiocentesis because of the patient's stable clinical condition and lack of symptoms of acute tamponade. Symptomatic treatment with intravenous diuretics, glucocorticosteroids, and albumins was introduced. Gradual clinical improvement was obtained. After 24 days of hospitalisation, there were no chest pains and no symptoms of active colitis ulcerosa. A control MRI was performed (Fig. 4). STIR and T2 weighted images revealed a lack of myocardial oedema. There was no significant amount of fluid in the pericardium and pleural cavities. Segmental thickening of the plaques with the proper retraction of the pericardium was present. LGE areas were similar to the previous examination. Global and regional contractivity abnormalities were still observed with a LVEF of 56%. The laboratory results improved: the hs-CRP level was 3.2 mg/L, troponin I 1.6 ng/mL and WBC  $11.68 \times 10^9/L$ . After 25 days, the patient was discharged free of symptoms, with the recommendation of a gradual reduction of doses of oral methylprednisolone. Ramipril and sulfasalazin were prescribed orally. In the presented patient, the infective aetiology of myocarditis and pericarditis were excluded. The symptoms and coincidence with aggravation of colitis ulcerosa suggested an extraintestinal manifestation of the gastroenterological illness. Successful steroid therapy confirmed the diagnosis we made.



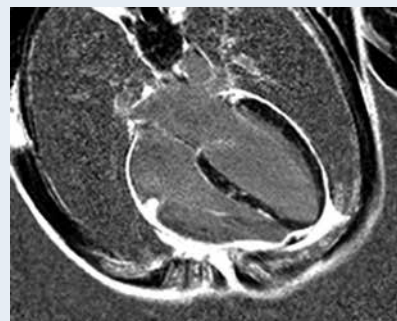
**Figure 1.** Electrocardiogram on admission: regular sinus rhythm 85 bpm, with inverted T waves in leads II, III, aVF, V<sub>4</sub>–V<sub>6</sub>



**Figure 2.** Cardiac MRI on admission: four-chamber LGE image



**Figure 3.** Cardiac MRI on admission: short axis LGE image



**Figure 4.** Cardiac MRI on discharge: four-chamber LGE image

**Address for correspondence:**

Maciej Mączyński, MD, PhD, 1<sup>st</sup> Department of Cardiology, University of Medical Sciences, ul. Długa 1/2, 61–848 Poznań, Poland, e-mail: [maczynski.ma@gmail.com](mailto:maczynski.ma@gmail.com)

**Conflict of interest:** none declared