

# Spaghetti-like leads in the heart — a complication of permanent heart stimulation

Spagetti w sercu jako powikłanie stałej stymulacji serca

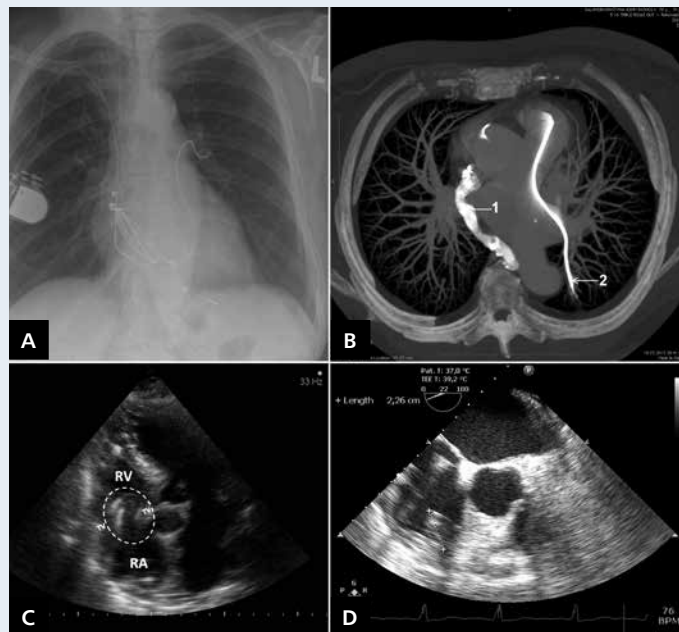
Krzysztof Boczar<sup>1</sup>, Barbara Małecka<sup>1</sup>, Andrzej Ząbek<sup>1</sup>, Andrzej Kutarski<sup>2</sup>, Elżbieta Czekańska-Chehab<sup>3</sup>, Jacek Lelakowski<sup>1</sup>

<sup>1</sup>Department of Electrophysiology, John Paul II Hospital in Krakow, Krakow, Poland

<sup>2</sup>Department of Cardiology, Medical University of Lublin, Lublin, Poland

<sup>3</sup>Department of Medical Radiology with Laboratory for Telemedicine, Medical University of Lublin, Lublin, Poland

A 70-year-old woman had a cardiac pacing system implanted 15 years previously due to third degree atrio-ventricular block. The system consisted of two endocardial leads (atrial and ventricular) and a pacemaker (PM) located in the left subclavian region. Nine years after implantation, a planned PM replacement due to battery depletion was complicated by pocket infection. A decision was made to remove the PM but to leave endocavitary leads, sewing them to the connective tissue which made up the PM pocket wall. After two weeks, a new implantation of atrioventricular, one-lead pacing system was performed in the right subclavian region. Over the course of the six subsequent years, the patient had not reported for follow-up examinations. At present, the patient was admitted to the hospital in a severe condition with lead-dependent infective endocarditis (LDIE). In laboratory tests, the level of procalcitonin was elevated to 18.9 ng/mL and C reactive protein to 145 mg/L. The chest X-ray revealed that inactive leads had been migrated into the heart. One of the leads (atrial) formed several loops that were positioned like spaghetti within the right atrium (RA), right ventricle (RV) and tricuspid valve (TV). The other one (ventricular) was displaced into the left pulmonary artery (Fig. 1A). It was confirmed also that the lead of the right-side active system was located properly. Transthoracic echocardiography (TTE) revealed lead loops responsible for TV regurgitation (Fig. 1C) and numerous vegetations in the RA, RV and TV. In transoesophageal echocardiography (TEE), the size of the largest vegetation was  $22.6 \times 5$  mm (Fig. 1D). Computer tomography (CT) revealed embolisation of the pulmonary artery by a free proximal end of a migrating ventricular lead (Fig. 1B). Antibiotic therapy in accordance with the recommendation of ESC (vancomycin plus gentamycin) and, prophylactically for pulmonary embolism, low-molecular-weight heparin were applied. Inflammatory parameters were reduced but renal failure developed which resulted in the need for dialysis. A procedure of major importance, the successful removal of all leads, was performed transvenously. Reimplantation was delayed for the period necessary to treat infective endocarditis. This case of LDIE is a typical example of a complication that might have been avoided if six years before the patient had undergone the removal of the infected pacing system as a whole. Due to the fact that leads had been left, and their proximal ends were sutured to the infected tissue, the leads became dislocated and migrated to the heart where they formed loops. Abandoned leads live their own lives. Sometimes, as in this case, they form conglomerates in the heart, become abraded, and are anchor points for LDIE.



**Figure 1.** **A.** Chest X-ray — posteroanterior projection; **B.** CT: reconstruction (maximum intensity projection): 1 — leads and the contrast agent in the right heart, 2 — a migrating ventricular lead in the pulmonary artery; **C.** TTE; RA — right atrium; RV — right ventricle; TV — tricuspid valve; **D.** TEE; the largest vegetation was marked

**Address for correspondence:**

Andrzej Ząbek, MD, MSc, Department of Electrophysiology, John Paul II Hospital in Krakow, ul. Piłsudskiego 80, 31-202 Kraków, Poland, e-mail: andrzej\_j\_z@poczta.onet.pl

**Conflict of interest:** none declared