

Combined subvalvular aortic stenosis, subvalvular pulmonary stenosis and membranous ventricular septal defect

Wada złożona obejmująca podzastawkowe zwężenie aorty, podzastawkowe zwężenie tętnicy płucnej i ubytek w części błoniastej przegrody międzykomorowej

James Worms, Lech Paluszkiwicz, Georg Kleikamp, Heinrich Koertke, Jan Gummert

Heart and Diabetes Centre NRW, Ruhr-University of Bochum, Department of Thoracic and Cardiovascular Surgery, Bad Oeynhausen, Germany

We present the case of a male patient with subvalvular aortic stenosis, subvalvular pulmonary stenosis and membranous ventricular septal defect. The patient was admitted to our clinic due to increasing exertional dyspnoea after suffering from mild exertional dyspnoea and easy fatigue for many years. A balloon valvuloplasty of the stenosed pulmonary valve was successfully performed 15 years ago.

On transthoracic echocardiographic examination, mildly hypertrophied left ventricle (LV) with preserved systolic function was found. Aortic valve was literally degenerated with moderate aortic regurgitation. Below the aortic valve, a membrane partially obstructing the LV outflow tract was found (Fig. 1A–C). In the membranous part of the interventricular septum, a left to right shunt was noted with maximum flow velocity of 5 m/s (Fig. 1D–E). The right ventricle was mildly hypertrophied; examination of the pulmonary valve revealed slightly degenerated leaflets with good separation and mild regurgitation although the measured peak pressure gradient was increased to 40 mm Hg. In the short axis view, a membrane in the right ventricular outflow tract below the pulmonary valve was found (Fig. 1D).

The patient was referred for cardiac surgery. The diagnosis was confirmed at surgery. A resection of the subaortic membrane was performed and the aortic valve was replaced by a mechanical prosthesis. The ventricular septal defect was closed. The subpulmonary membrane was resected and epicardial radiofrequency ablation was performed. The postoperative control echocardiography showed a properly functioning aortic prosthesis. There was no significant systolic gradient across the pulmonary valve (PPG = 15 mm Hg). No shunt across the interventricular septum was detected.

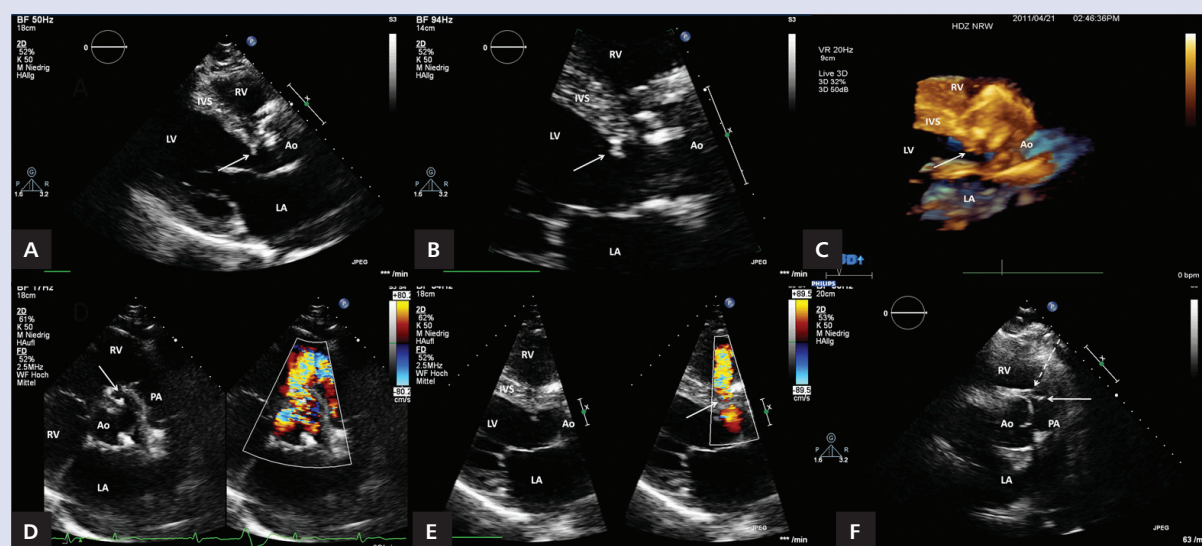


Figure 1. A–F. Transthoracic echocardiography; Ao — aorta; LA — left atrium; LV — left ventricle; RV — right ventricle; PA — pulmonary artery

Address for correspondence:

James Worms, MD, Heart and Cardiovascular Centre Nordrhein-Westfalen, Ruhr University of Bochum, Department of Cardiovascular Surgery, 32545 Bad Oeynhausen, Georgstr. 11, Germany, e-mail: jaworms@yahoo.de

Conflict of interest: none declared