

Maria Wieteska-Milek<sup>1</sup>, Kinga Winiarczyk<sup>2</sup>, Włodzimierz Kupis<sup>3</sup>

<sup>1</sup>Department of Pulmonary Circulation, Thromboembolic Diseases and Cardiology, Centre of Postgraduate Medical Education, European Health Centre Otwock, Poland

<sup>2</sup>Department of Lung Cancer and Chest Tumors, The Maria Skłodowska-Curie Memorial National Oncology Institute, Warsaw, Poland

<sup>3</sup>Department of Surgery, National Research Institute of Tuberculosis and Lung Diseases, Warsaw, Poland

# Treatment of pulmonary artery stump thrombosis after lobectomy: a case report and literature review

## Abstract

**Introduction:** Lung cancer surgery is a well-known risk factor for venous thromboembolism. Thus, standard care involves the use of pharmacological and mechanical prophylaxis until discharge from the hospital. Pulmonary artery stump thrombosis (PAST) is a rare condition which can develop months to years after lung cancer surgery. This report describes a patient diagnosed with PAST and the decisions that were made regarding his treatment.

**Case report:** A 67-year-old male was diagnosed with lung cancer due to shortness of breath, dry cough, hemoptysis, and typical chest computed tomography (CT) findings. He underwent right lower lobectomy and mediastinal lymphadenectomy by video-assisted thoracoscopic surgery. The procedure was complicated by the development of a right pleural empyema. After pleural drainage and an antibiotic regimen, he was discharged from the hospital with further improvement.

A follow-up CT pulmonary angiography performed three months after lobectomy revealed thrombosis in the right lower lobar pulmonary artery stump. The patient had no symptoms.

The attending physician decided to use anticoagulants. Consequently, the patient received low-molecular-weight heparin subcutaneously for one month and a non-vitamin-K antagonist oral anticoagulant (NOAC) for the following 5 months.

A CT scan performed after 3 months of anticoagulation showed complete resolution of stump thrombosis. Subsequent examinations showed no recurrence of either lung cancer or artery stump thrombosis and no anticoagulant-related bleeding.

**Discussion:** Pulmonary artery stump thrombosis can develop after lung cancer surgery. This complication is uncommon and the prognosis is favorable in most treated cases. However, thrombosis may progress, and pulmonary embolism or chronic thromboembolic pulmonary hypertension may develop. Decisions about instituting anticoagulation therapy and its duration are made on an individual basis after considering both the benefits and the potential risks.

**Key words:** stump thrombosis, lung cancer, lobectomy, anticoagulation, pulmonary artery

*Adv Respir Med.* 2021; 89: 311–315

## Introduction

The risk of developing venous thromboembolism (VTE), including pulmonary embolism (PE) and/or deep vein thrombosis, after lung cancer surgery is approximately 2% (0.2–19%) [1], with the highest incidence within the first months after surgery [2]. Most VTE cases are asymptomatic at diagnosis but despite prophylaxis and treatment, the 30-day mortality rate is around 5% [3]. The prevalence of pulmonary artery stump thrombo-

sis (PAST) after all types of lung cancer surgery collectively in retrospective analyses ranged from 1.9–5.7% [4, 5]. The clinical significance of PAST is unclear. The disease can be mild or it can be fatal. Moreover, there is no consensus about the use of anticoagulation therapy in such cases.

## Case report

A 67-year-old male lung cancer patient was admitted to the hospital in January 2017. He re-

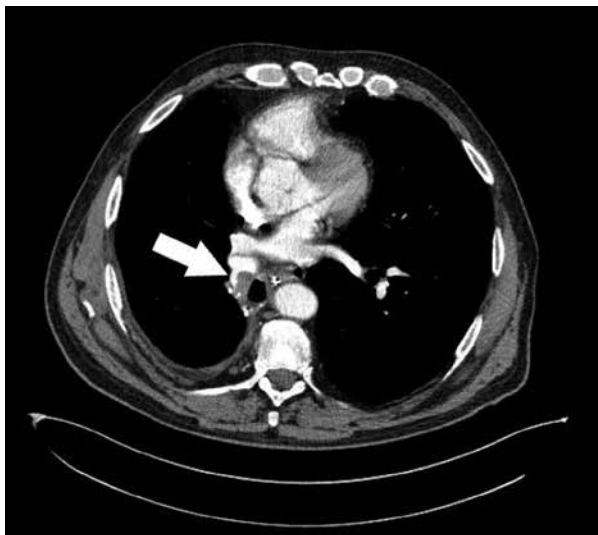**Address for correspondence:** Maria Wieteska-Milek, Department of Pulmonary Circulation, Thromboembolic Diseases and Cardiology, Centre of Postgraduate Medical Education, European Health Centre Otwock; e-mail: mwiet@mp.pl

DOI: 10.5603/ARM.a2021.0010

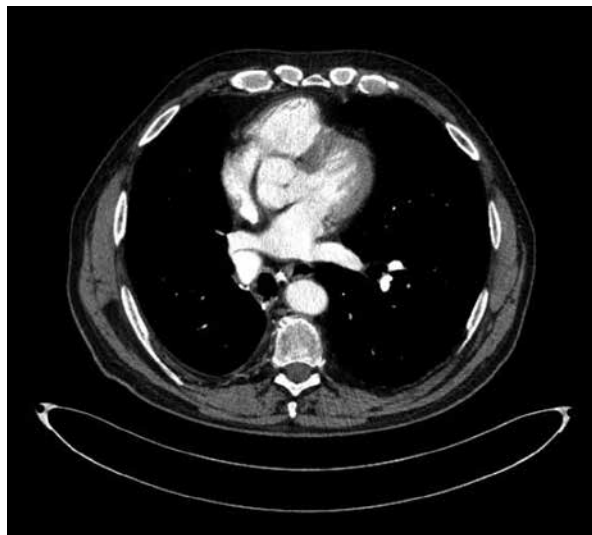
Received: 19.09.2020

Copyright © 2021 PTChP

ISSN 2451–4934



**Figure 1.** Contrast-enhanced computed tomography of the chest showing right lower lobar pulmonary thrombosis (arrow)



**Figure 2.** Contrast-enhanced computed tomography of the chest following anticoagulation treatment

ported shortness of breath, dry cough, and one episode of hemoptysis. The patient had a history of bronchiectasis, emphysema, arterial hypertension, heart failure with preserved ejection fraction, impaired fasting glucose, and abdominal obesity. He was a former smoker with a 25-pack year history. He had a history of bilateral high ligation and stripping of the great saphenous vein. Computed tomography (CT) of the chest revealed an irregular solid tumor measuring  $25 \times 15 \times 11$  mm in the lower right lobe. The patient underwent right lower lobectomy and mediastinal lymphadenectomy by video-assisted thoracoscopic surgery. The final histopathological diagnosis was predominantly papillary adenocarcinoma (G2, pT2aN0M0R0L1V0, clinical stage IB) (IASLC/ITMIG, 8<sup>th</sup> edition). In the perioperative period, the patient received primary anticoagulant prophylaxis (40 mg enoxaparin administered subcutaneously once a day) and used compression stockings. He was readmitted 2 weeks after discharge due to dry cough, fever, and radiological signs of a right pleural empyema. Pleural drainage was performed, and the patient received antibiotics and primary anticoagulant prophylaxis. Pleural fluid culture yielded *Staphylococcus aureus*. The patient showed clinical and biochemical improvement and was discharged after 1 week of treatment. Follow-up chest CT scans and radiographs were recommended with no immediate need for adjunctive therapy. A subsequent CT scan showed no evidence of recurrent or residual disease. Three months later, a CT scan showed sustained complete tumor regression, but

CT pulmonary angiography revealed thrombosis in the right lower lobar pulmonary artery stump (Figure 1). The patient was asymptomatic. Trans-thoracic echocardiography showed no signs of right ventricle overload or pulmonary hypertension. Doppler ultrasound of the lower extremities showed no evidence of venous thrombosis. The decision to introduce anticoagulants was made following a thorough risk-benefit analysis. The patient had PAST and persistent risk factors for venous thromboembolic disease including a history of lung cancer, congestive heart failure, obesity, varicose veins, arterial hypertension, and increased age. His bleeding risk was low. The patient received low-molecular-weight heparin (LMWH) (enoxaparin) at 1.5 mg/kg once daily for 7 days and 1.0 mg/kg once daily for the following month. After 1 month, LMWH was switched to rivaroxaban at 20 mg once daily. After three months of anticoagulation, a follow-up CT pulmonary angiography revealed no pulmonary artery stump thrombosis (Figure 2). There were also no signs of cancer recurrence. Nonetheless, rivaroxaban was continued for 3 more months with no reported side effects and no observable signs of VTE or cancer recurrence in subsequent CT pulmonary angiographies.

## Discussion

Pulmonary artery stump thrombosis is a rare condition and its clinical significance is not fully understood. The risk factors for VTE, called Virchow's triad (stasis of blood flow, endothelial

injury, and hypercoagulability), are present after lung cancer surgeries and can promote pulmonary arterial stump thrombosis formation. After being diagnosed with PAST, patients could ask their doctor about the possible complications and treatment options. For this reason, we conducted a literature review.

In the largest retrospective analysis of 648 surgeries for primary lung cancer, Moon *et al.* [4] demonstrated 25 cases (3.8%) of pulmonary arterial stump thrombosis. Another retrospective analysis of 473 lung cancer surgeries conducted by Lopez-Padilla *et al.* described 9 cases (1.8%) of PAST [5]. All the cases of PAST described by Moon *et al.* [4] and Lopez-Padilla *et al.* [5] were discovered incidentally on follow-up chest CT scans days or months after the surgery (median 28 days, range 20–341 days; or 11.3 months, interquartile range 2.7–42.2 months, respectively). These findings are in concordance with those done by other various authors who reported 5 cases of PAST (only one of them was symptomatic with the patient experiencing chest pain) detected in the period between 3 and 24 months after surgery [6–9]. However, there have also been 6 case reports of late and very late arterial stump thrombosis detected up to 3–10 years after lung cancer surgery [9–14]. Interestingly, the later that the arterial stump thrombosis was discovered, the more frequently clinical symptoms were present. These symptoms included dyspnea, chest pain, and asthenia. The resulting sequelae were also more severe (e.g. acute PE with fatal outcome or chronic thromboembolic pulmonary hypertension with chronic progressive right heart failure) [10, 11, 13, 15].

The larger the surgery is, the greater the risk becomes for developing PAST. Pulmonary artery stump thrombosis is more frequently observed after pneumonectomy than lobectomy. Potential explanations for this include the longer arterial stump and greater activation of the coagulation cascade after major surgery [4, 6]. Different findings were observed about the localization of the PAST. Some authors noticed more frequent right-sided thrombi than left-sided ones [5–11, 13]. Other authors observed the PAST more frequently on the left side [4, 12, 14]. The stump on the left side is longer than the one on the right and can result in turbulent blood flow, but this theory needs to be studied further. It is worthwhile to recommend that oncologic surgeons leave the arterial stumps as short as possible during pulmonary resections in order to decrease risk of the PAST.

There is no consensus on how to treat patients with arterial stump thrombosis and whether they require any treatment at all. Most of the reported cases were discovered incidentally a few months after surgery during routine follow-up chest CT and had a benign outcome with total or partial thrombus regression [4–7, 9, 14]. Nonetheless, it is worth emphasizing that in most of these cases, the patients received anticoagulants or antiplatelet agents [4, 5, 7–9, 11, 14–16]. The available reports do not clearly specify how treatment decisions were made, with some reports containing only a retrospective cohort description. The decision about the treatment of PAST should be individual and based on concomitant diseases and the estimated risk of VTE progression and bleeding.

One of the suggested options is that the treatment of PAST should be the same as that of asymptomatic PE, but further studies are needed. According to the American Society of Clinical Oncology guidelines from 2019, patients with cancer and incidental PE should be managed in the same manner as those with symptomatic PE regardless of the extent of the disease (segmental or more proximal branches, multiple subsegmental vessels, or a single subsegmental vessel with proven concomitant deep vein thrombosis) [17]. Incidental PE has yielded similar clinical outcomes when compared with those of symptomatic PE in cancer patients. Thus, it seems reasonable that regardless of whether it is isolated subsegmental PE or splanchnic or visceral vein thrombi diagnosed incidentally, the treatment should be implemented on a case-by-case basis and should consider the potential benefits and risks of anticoagulation therapy [17]. As a result of clinical trials in recent decades, LMWH has been accepted as optimal anticoagulant therapy for thrombosis in cancer patients. Anticoagulation with LMWH is recommended over anticoagulation with vitamin K antagonists (VKAs) during the first 6 months of treatment [18]. Edoxaban or rivaroxaban should be considered as an alternative to LMWH in non-gastrointestinal cancer patients. Gastrointestinal and genitourinary cancers carry an increased risk of major bleeding with the use of non-vitamin-K antagonist oral anticoagulants (NOACs) [19, 20]. When NOACs are used, the risk of bleeding and drug interactions must be assessed [17]. The most recently published clinical trial on NOACs and VTE in cancer patients showed that apixaban was non-inferior to subcutaneous dalteparin for the treatment of cancer-associated VTE and did not carry an increased risk of major

bleeding. Thus, it can be used as an alternative to NOACs in VTE treatment in cancer patients [16].

The treatment options and regimens presented in the available literature varied from case to case. Some authors administered anticoagulants with treatment modalities including: starting with LMWH followed by VKA [8, 10], starting with unfractionated heparin followed by VKA [11, 12, 14, 15], or using VKA alone [9] for at least 3 months or longer. Others administered no treatment at all [6]. Some used combinations of anticoagulants, antiplatelet drugs, or no treatment [4, 5]. The patients who were left untreated or received an antiplatelet agent alone were closely monitored and if the thrombus increased in size, an anticoagulant was usually initiated [4, 5]. Our patient had a history of lung cancer, pulmonary artery stump thrombosis, persisting risk factors for VTE (congestive heart failure, obesity, varicose veins, arterial hypertension, and increasing age), and a low risk of bleeding. After a discussion with the patient, we implemented anticoagulation with LMWH followed by rivaroxaban. We observed complete thrombus resolution, good treatment tolerance, and no side effects. The patient was closely monitored.

Most of the reported PAST cases had benign outcomes with complete regression or no progression for years [4, 5, 7, 14]. There are only a few reports indicating that arterial stump thrombosis may lead to thrombus size progression (n = 4) [4–6, 11], pulmonary embolism (n = 4) [10–13], or chronic thromboembolic pulmonary hypertension (n = 1) [10] with serious consequences. In conclusion, the presented case showed artery stump thrombosis that was discovered accidentally during lung cancer surgery follow-up. To prevent VTE progression, empirical anticoagulation was administered with a good outcome and no complications. This treatment option was decided based on an individual assessment of concomitant diseases and analysis of the risk of VTE progression and bleeding. Further studies are needed to address the question of whether or not patients with vascular stump thrombosis can benefit from anticoagulation therapy.

### Acknowledgements

The authors would like to thank dr. S. Szmit for reviewing this manuscript.

### Conflict of interest

Non declared.

### References:

- Christensen TD, Vad H, Pedersen S, et al. Venous thromboembolism in patients undergoing operations for lung cancer: a systematic review. *Ann Thorac Surg.* 2014; 97(2): 394–400, doi: [10.1016/j.athoracsur.2013.10.074](https://doi.org/10.1016/j.athoracsur.2013.10.074), indexed in Pubmed: [24365217](https://pubmed.ncbi.nlm.nih.gov/24365217/).
- Yang Yi, Zhou Z, Niu XM, et al. Clinical analysis of postoperative venous thromboembolism risk factors in lung cancer patients. *J Surg Oncol.* 2012; 106(6): 736–741, doi: [10.1002/jso.23190](https://doi.org/10.1002/jso.23190), indexed in Pubmed: [22711667](https://pubmed.ncbi.nlm.nih.gov/22711667/).
- Agzarian J, Hanna WC, Schneider L, et al. Postdischarge venous thromboembolic complications following pulmonary oncologic resection: An underdetected problem. *J Thorac Cardiovasc Surg.* 2016; 151(4): 992–999, doi: [10.1016/j.jtcvs.2015.11.038](https://doi.org/10.1016/j.jtcvs.2015.11.038), indexed in Pubmed: [26707765](https://pubmed.ncbi.nlm.nih.gov/26707765/).
- Moon MiH, Beck KS, Moon YK, et al. Incidence and clinical features of the incidentally found vascular stump thrombus during routine follow up after oncologic lung surgery. *PLoS One.* 2017; 12(9): e0185140, doi: [10.1371/journal.pone.0185140](https://doi.org/10.1371/journal.pone.0185140), indexed in Pubmed: [28953945](https://pubmed.ncbi.nlm.nih.gov/28953945/).
- López-Padilla D, Peghini Gavilanes E, Revilla Ostolaza TY, et al. Arterial stump thrombosis after lung resection surgery: clinical presentation, treatment and progress. *Arch Bronconeumol.* 2016; 52(10): 512–518, doi: [10.1016/j.arbres.2016.02.009](https://doi.org/10.1016/j.arbres.2016.02.009), indexed in Pubmed: [27156986](https://pubmed.ncbi.nlm.nih.gov/27156986/).
- Dury S, Toubas O, Delepine G, et al. Pulmonary artery stump thrombosis following pneumonectomy. *Rev Mal Respir.* 2007; 24(3 Pt 1): 367–370, doi: [10.1016/s0761-8425\(07\)91071-2](https://doi.org/10.1016/s0761-8425(07)91071-2), indexed in Pubmed: [17417177](https://pubmed.ncbi.nlm.nih.gov/17417177/).
- Kotoulas C, Lachanis S. Embolism of the pulmonary artery stump after right pneumonectomy. *Interact Cardiovasc Thorac Surg.* 2009; 8(5): 563–564, doi: [10.1510/ictvs.2008.189415](https://doi.org/10.1510/ictvs.2008.189415), indexed in Pubmed: [19188212](https://pubmed.ncbi.nlm.nih.gov/19188212/).
- Barbetakis N, Asteriou C, Kleontas A. Post-lobectomy pulmonary artery stump thrombosis: how dangerous is it? *Ann Thorac Surg.* 2011; 91(3): e44, doi: [10.1016/j.athoracsur.2010.12.037](https://doi.org/10.1016/j.athoracsur.2010.12.037), indexed in Pubmed: [21352970](https://pubmed.ncbi.nlm.nih.gov/21352970/).
- Sawalha L, Mador MJ. Delayed post-lobectomy pulmonary artery stump thrombosis. *Respir Med Case Rep.* 2015; 15: 36–38, doi: [10.1016/j.rmcr.2015.04.003](https://doi.org/10.1016/j.rmcr.2015.04.003), indexed in Pubmed: [26236597](https://pubmed.ncbi.nlm.nih.gov/26236597/).
- Thomas PA, Doddoli C, Barlési F, et al. Late pulmonary artery stump thrombosis with post embolic pulmonary hypertension after pneumonectomy. *Thorax.* 2006; 61(2): 177–178, doi: [10.1136/thx.2004.028480](https://doi.org/10.1136/thx.2004.028480), indexed in Pubmed: [16443709](https://pubmed.ncbi.nlm.nih.gov/16443709/).
- Joshi M, Farooq U, Mehrook S, et al. Delayed formation of pulmonary artery stump thrombus: a case report and review of the literature. *Thromb J.* 2009; 7: 7, doi: [10.1186/1477-9560-7-7](https://doi.org/10.1186/1477-9560-7-7), indexed in Pubmed: [19515226](https://pubmed.ncbi.nlm.nih.gov/19515226/).
- Sato W, Watanabe H, Sato T, et al. Contralateral pulmonary embolism caused by pulmonary artery stump thrombosis after pneumonectomy. *Ann Thorac Surg.* 2014; 97(5): 1797–1798, doi: [10.1016/j.athoracsur.2013.07.102](https://doi.org/10.1016/j.athoracsur.2013.07.102), indexed in Pubmed: [24792273](https://pubmed.ncbi.nlm.nih.gov/24792273/).
- Lazopoulos A, Asteriou C, Rallis T, et al. Late postpneumonectomy death from stump thrombus. *Ann Thorac Surg.* 2015; 100(1): 330, doi: [10.1016/j.athoracsur.2015.03.048](https://doi.org/10.1016/j.athoracsur.2015.03.048), indexed in Pubmed: [26140787](https://pubmed.ncbi.nlm.nih.gov/26140787/).
- Akcamlı TI, Kaya SO, Samancılar O, et al. Pulmonary artery stump thrombosis developed during the late postoperative period. *Kardiochir Torakochirurgia Pol.* 2016; 13(3): 260–261, doi: [10.5114/kitp.2016.62619](https://doi.org/10.5114/kitp.2016.62619), indexed in Pubmed: [27785144](https://pubmed.ncbi.nlm.nih.gov/27785144/).
- Ohtaka K, Hida Y, Kaga K, et al. Left upper lobectomy can be a risk factor for thrombosis in the pulmonary vein stump. *J Cardiothorac Surg.* 2014; 9(5).
- Agnelli G, Becattini C, Meyer G, et al. Caravaggio Investigators. Apixaban for the treatment of venous thromboembolism associated with cancer. *N Engl J Med.* 2020; 382(17): 1599–1607, doi: [10.1056/NEJMoa1915103](https://doi.org/10.1056/NEJMoa1915103), indexed in Pubmed: [32223112](https://pubmed.ncbi.nlm.nih.gov/32223112/).
- Key NS, Khorana AA, Kuderer NM, et al. Venous thromboembolism prophylaxis and treatment in patients with cancer: ASCO Clinical Practice Guideline Update. *J Clin Oncol.* 2020; 38(5): 496–520, doi: [10.1200/JCO.19.01461](https://doi.org/10.1200/JCO.19.01461), indexed in Pubmed: [31381464](https://pubmed.ncbi.nlm.nih.gov/31381464/).

18. Lee AYY, Kamphuisen PW, Meyer G, et al. CATCH Investigators. Tinzaparin vs warfarin for treatment of acute venous thromboembolism in patients with active cancer: a randomized clinical trial. *JAMA*. 2015; 314(7): 677–686, doi: [10.1001/jama.2015.9243](https://doi.org/10.1001/jama.2015.9243), indexed in Pubmed: [26284719](https://pubmed.ncbi.nlm.nih.gov/26284719/).
19. Raskob GE, van Es N, Verhamme P, et al. Hokusai VTE Cancer Investigators. Edoxaban for the treatment of cancer-associated venous thromboembolism. *N Engl J Med*. 2018; 378(7): 615–624, doi: [10.1056/NEJMoa1711948](https://doi.org/10.1056/NEJMoa1711948), indexed in Pubmed: [29231094](https://pubmed.ncbi.nlm.nih.gov/29231094/).
20. Young AM, Marshall A, Thirlwall J, et al. Comparison of an Oral Factor Xa Inhibitor With Low Molecular Weight Heparin in Patients With Cancer With Venous Thromboembolism: Results of a Randomized Trial (SELECT-D). *J Clin Oncol*. 2018; 36(20): 2017–2023, doi: [10.1200/JCO.2018.78.8034](https://doi.org/10.1200/JCO.2018.78.8034), indexed in Pubmed: [29746227](https://pubmed.ncbi.nlm.nih.gov/29746227/).