

This is a provisional PDF only. Copyedited and fully formatted version will be made available soon.



**ISSN:** 0015-5659

**e-ISSN:** 1644-3284

## **Arterial hypertension and remodeling of the right ventricle**

**Authors:** A. Kosiński, G. M. Piwko, R. Kamiński, E. Nowicka, A. Kaczyńska, M. Zajączkowski, K. Czerwiec, M. Gleinert-Rożek, K. Karnecki, T. Gos

**DOI:** 10.5603/FM.a2021.0038

**Article type:** Original article

**Submitted:** 2020-12-19

**Accepted:** 2021-03-11

**Published online:** 2021-04-13

This article has been peer reviewed and published immediately upon acceptance. It is an open access article, which means that it can be downloaded, printed, and distributed freely, provided the work is properly cited.

Articles in "Folia Morphologica" are listed in PubMed.

## Arterial hypertension and remodeling of the right ventricle

A. Kosiński et al., Arterial hypertension and remodeling of the right ventricle

A. Kosiński<sup>1</sup>, G.M. Piwko<sup>1</sup>, R. Kamiński<sup>1</sup>, E. Nowicka<sup>1</sup>, A. Kaczyńska<sup>1</sup>, M. Zajączkowski<sup>1</sup>,  
K. Czerwec<sup>1</sup>, M. Gleinert-Rożek<sup>1</sup>, K. Karnecki<sup>2</sup>, T. Gos<sup>2</sup>

<sup>1</sup>Department of Clinical Anatomy, Gdansk Medical University, Gdansk, Poland

<sup>2</sup>Department of Forensic Medicine, Gdansk Medical University, Gdansk, Poland

Address for correspondence: Dr. G.M. Piwko, Department of Clinical Anatomy, ul. Dębinki 1, 80-210 Gdańsk, Poland, tel: +48 58 349-14-20, e-mail: grzegorz.piwko@gumed.edu.pl

### Abstract

**Background:** In case of long-term and physiological loads (e.g. during pregnancy or regular athletics training), reversible morphological changes occur in the heart - cardiomyocytes undergo hypertrophy, however, this is not accompanied by impairment of left ventricular function or myocyte metabolism. However, in the course of various pathological processes, as time goes by, gradually permanent morphological changes occur. These changes are referred to as remodeling of the heart muscle, which, regardless of the primary cause, can lead to the development of chronic heart failure.

**Materials and methods:** The study was performed on post-mortem material of 35 human hearts obtained from forensic sections and anatomopathological sections of people who died of non-cardiac causes (mainly traffic accidents, suicide attempts, strokes, acute infections); material was fixed in a 4% formalin solution. The hearts were subjected to macro- and microscopic assessment. During microscopic assessment the features of remodeling were evaluated.

**Results and conclusions:** In vivo and echocardiographic tests, as well as macroscopic evaluation of post-mortem material, suggest the presence of some kind of right ventricular muscle remodeling, however classic microscopic observations, presented in this study do not provide such unambiguous evidence. Thus, the question arises: why and how the right ventricular function is disturbed, sometimes at early stages of arterial hypertension.

**Key words:** heart, human, changes, hypertensive

## INTRODUCTION

Various pathological factors, both external and intracardiac, can negatively affect the effectiveness of the heart. In return, the organ reacts to these factors by changes in its structure and function, which are aimed at ensuring efficient work in other, sometimes adverse conditions. In the time of well-being, the heart has a wide range of compensation mechanisms. In the case of short-term physiological loads, the heart muscle mainly uses the mechanisms of: a) homeometric regulation — an increase in contractility without changing the sarcomere length (Anrep effect) and an increase in contractility with an increase in heart rate (Bowditch effect) [1]; b) heterometric regulation — an increase in contractility associated with an increase in the length of sarcomeres (Frank-Starling law) [2]. In the case of long-term and physiological loads (e.g. during pregnancy or regular athletics training), reversible morphological changes also occur in the heart — cardiomyocytes undergo hypertrophy, however, this is not accompanied by impairment of left ventricular function or myocyte metabolism [3, 4, 5]. In the course of various pathological processes, as time passes, the basic compensatory mechanisms become exhausted, and gradually lead to permanent morphological changes [6, 7, 8]. Within the myocardium, the proportions and correlation between myocytes, fibroblasts and endothelial cells are disturbed. In the literature, the above changes are referred to as remodeling of the left ventricular heart muscle, which, regardless of the primary cause (hypertension, hypertrophic cardiomyopathy, valvular heart disease, ischemic disease, etc.), can lead to the development of chronic heart failure, or right ventricular hypertrophy with all its adverse consequences when appropriate factors affect right ventricle by causing pulmonary hypertension (e.g. chronic obstructive pulmonary disease, idiopathic pulmonary hypertension, chronic thromboembolic pulmonary hypertension, mitral valve insufficiency, etc.).

Due to the increasing prevalence of hypertension in overall population, this group of patients (almost 60% of the population > 59 years of age) is particularly at risk. Additionally if we take into account the fact that only about 26% of treated patients manage to achieve the intended therapeutic effect, it is not surprising that hypertension and its complications, as a basic risk factor for the development of cardiovascular diseases and acute incidents, is — indirectly — the main cause of death in developed countries. Most of the available scientific studies assessing remodeling of the heart are focused on morphological changes within the left ventricle, which is directly affected by the pathological triggers of this remodeling, e.g. hypertension or cardiomyopathy, which apparently lead to asymmetrical hypertrophy of its

walls (interventricular septal wall in comparison to the inferior wall) [9]. Similarly the right ventricle becomes a target of remodeling during pulmonary hypertension of different origins. Right ventricular hypertrophy due to pulmonary hypertension has got higher attention of the scientific since last few years. However little do we know about already observed, but still sparsely described phenomenon of “cross-remodeling”, in this case, within the right ventricle during arterial hypertension [10].

In this study, looking for anatomical exponents of myocardial remodeling within the right ventricular musculature in people with hypertension, we have set ourselves the goal of answering the question whether myocardial remodeling may also involve structures that are not directly affected by the causative agent.

## **MATERIALS AND METHODS**

The material for this study consisted of 35 human hearts from forensic sections and anatomopathological sections of people who died of non-cardiac causes (e.g. traffic accidents, suicide attempts, strokes, acute infections). All hearts were instantly fixed in a solution of formalin and ethanol. The control group (CG) consisted of 13 hearts (6F / 7M; weight (mean  $\pm$  SD):  $317.7 \pm 35.15$  g; age (average  $\pm$  SD):  $50.9 \pm 16.8$  years) from persons in whom in vivo no cardiovascular disease has been diagnosed and in post-mortem assessment no obvious pathological changes were found. The study group (SG) consisted of 22 hearts (10F / 12M; weight (mean  $\pm$  SD):  $533.2 \pm 68.34$  g; age (average  $\pm$  SD):  $51.7 \pm 16.8$  years) from people with a history of arterial hypertension and left ventricular hypertrophy found during anatomopathological examination. The protocol was approved by the Independent Bioethics Commission for Research of the Medical University of Gdansk (consent no. NKBBN/165/2018 dated 12 April 2018).

The material was subjected to macro- and microscopic assessment. The right ventricle (RV) cavity was opened with a long axis cut along the acute margin from the tricuspid ring to the apex of the right ventricle. Similarly, the left ventricle (LV) cavity was opened with a cut along the oblique margin. In addition, the interventricular septum (IVS) was dissected along the long axis, in its frontal plane, in its mid-antero-posterior dimension (Fig. 1). After opening the hearts, the ventricular septum was divided into four equal sections, thus determining three levels: A, B and C. At these levels, halfway between the acute margin and the septum (RV) and between the oblique margin and the septum (LV) incisions of the heart walls were made

and the thickness of both RV walls, LV inferior wall and IVS were measured. The measurements were designated as dimensions A, B and C, respectively (Fig. 2).

The specimens for microscopic assessment were taken from: RV posterior wall (1x1 cm), interventricular septum (covering the entire IVS section) and a fragment from the LV inferior wall (1x1 cm). Seven hearts from each the control and study groups were randomly selected for this stage of the study. In order to reveal various types of tissue within the heart wall, the preparations were subjected to Masson staining with Goldner modification, which allows simultaneous assessment of connective, adipose tissues, and myocardial muscle cells. The preparations were evaluated in the Opta-Tech MN 800 light microscope (Opta-Tech, Poland), with Moticam 2000 2.0M camera (Motic Incorporation Ltd., Hong Kong) and Leica MZ8 / MPS60 (Leica Microsystems Ltd., Switzerland) photographic adapter with the use of Motic Images Plus 2.0 software (version 2.0 2006 Motic China Group CO., LTD.)

During microscopic assessment the following features were evaluated: 1) cardiomyocyte thickness 2) infiltration of the muscular layer of the heart wall by adipose tissue, which penetrates between the muscle fiber strands, thus separating them from each other (Fig. 3), 3) disturbance of the proportion between the amount of muscle tissue and connective tissue, occurring in the form of clusters; its excessive growth is referred to as interstitial myocardial fibrosis (Fig. 4).

## **Statistical analysis**

Statistical analysis was performed using Fisher's test and Student's t-test for mean of small samples. The significance of differences between the results obtained from the qualitative observations of microscopic changes was confirmed using the non-parametric Mann-Whitney U test for two independent groups. P values <0.05 were considered statistically significant. The software used to perform analyses was Statistica 9.0 package from StatSoft.

## **RESULTS**

### **Macroscopic evaluation**

#### **1) Inferior wall of the left ventricle**

Individual dimensions of the inferior wall of the LV, which is the target of systemic hypertension, in SG hearts were significantly larger than those of CG. It is noteworthy that these differences were larger related to dimensions A and B, and to a slightly smaller (but still

statistically significant) for dimension C. At level A, the thickness of the LV inferior wall in CG hearts was on average  $10.28 \pm 1.24$  mm, while in hearts with hypertrophy this average was  $14.26 \pm 2.35$  mm ( $p < 0.000003$ ). Dimension B averaged  $10.01 \pm 0.95$  mm in CG and  $13.27 \pm 2.06$  mm in SG ( $p < 0.00001$ ). Dimension C was  $8.71 \pm 1.20$  mm in CG and  $10.34 \pm 2.40$  mm in SG ( $p < 0.05$ ), respectively.

As the effect of the above changes, also the difference in proportions between individual dimensions of the LV inferior wall was noticeable. While there were no differences between the two groups in the A/B and B/C ratios, in hearts with hypertrophy the A/C ratio was significantly higher ( $p < 0.05$ ) than in CG. This implies a greater disproportion between dimensions A and C in SG (Table 1).

Assessing the shape of the cross-sectional plane along the long axis of the LV inferior wall, some differences in the geometry of this cross-section were observed. Namely, in CG dimensions A and B were similar and dominated over dimension C, which meant that in this group of hearts the cross-section of the LV inferior wall between the levels of the valve attachment (A) and the base of the papillary muscle (B) had a rectangular shape, and below it, in towards the apex of LV, it gradually decreased, giving the last segment a trapezoidal shape. In SG, on the other hand, the highest thickness occurred at level A, and then downwards gradually decreased. Therefore, the whole cross-section of the inferior wall assumed the shape of an inverted trapezoid (Table 2).

## 2) Interventricular septum (IVS)

Same as the LV inferior wall, in terms of individual dimensions A, B and C, the thickness of IVS of hearts from the SG was significantly greater than that of CG hearts. The average dimension A in CG was  $10.6 \pm 1.20$  mm, while in SG it was  $13.4 \pm 2.15$  mm ( $p = 0.0001$ ). Dimension B was  $11.6 \pm 1.18$  mm and  $15.93 \pm 2.52$  mm in groups CG and SG, respectively ( $p < 0.0001$ ). Dimension C averaged  $9.91 \pm 1.52$  mm in CG, and  $12.25 \pm 2.67$  mm in SG ( $p = 0.006$ ).

However, despite such a significant differentiation between individual dimensions in both groups, the comparison of ratios of these dimensions (A/B, B/C, A/C) did not show statistically significant deviations. It seems that hypertrophy of the heart muscle within the septum occurs evenly at all its levels, leading to a proportional increase in all measured IVS dimensions (Table 3).

### 3) Anterior wall of the right ventricle

As in the case of the in LV inferior wall, significant differences in the thickness of the muscle between both groups were also observed within the anterior wall of the right ventricle. The RV anterior wall average thickness at level A was  $4.35 \pm 0.63$  mm in CG, while in SG  $5.35 \pm 1.00$  mm ( $p < 0.001$ ). The average dimension B was  $3.18 \pm 0.72$  mm in CG and  $4.19 \pm 1.16$  mm in SG ( $p < 0.005$ ). Dimension C, measured near the apex of the right ventricle, was on average  $2.37 \pm 0.40$  mm and  $3.20 \pm 1.20$  mm, in CG and SG respectively ( $p < 0.05$ ).

No statistically significant differences were noted between the two groups assessing the proportions between individual dimensions. (Table 4).

The thickness of the anterior wall at individual levels was typical in all hearts with the largest dimension A, intermediate B and the smallest dimension C. Therefore, the longitudinal section through this wall gives the shape of a triangle, with the base pointing towards the base of the heart, and the top pointing towards the apex of the RV. This image was the same for both groups of hearts (Table 2).

### 4) Posterior wall of the right ventricle

Within the RV posterior wall, statistically significant differences were also noted for individual dimensions A, B and C. The average dimension A in CG was  $4.27 \pm 0.89$  mm, while in SG it was  $5.11 \pm 1.28$  mm ( $p < 0.05$ ). Dimension B was  $3.93 \pm 0.69$  mm and  $4.73 \pm 1.17$  mm, in CG and SG respectively ( $p < 0.05$ ). In CG the dimension C averaged  $2.68 \pm 0.81$  mm, and in SG  $3.38 \pm 1.18$  mm ( $p < 0.05$ ).

Again, despite the differences observed, comparing the ratios of these dimensions (A/B, B/C, A/C) in both groups did not reveal any statistically significant deviations. (Table 5).

The posterior wall of the RV in its longitudinal section had, like the RV anterior wall, the shape of an inverted triangle, resulting directly from its dimensions and their proportions (Table 2).

## Microscopic evaluation

In the CG, within the RV and LV free walls, as well as IVS the average thickness of cardiomyocytes was  $10 \mu\text{m}$ . In one case (14.3%), fat infiltration into the muscular layer of the right ventricle wall was observed. This phenomenon did not occur in the remaining, examined walls of this heart, nor in any of the walls of other hearts in this group (Fig. 5). Also in one

case (same heart) (14.3%), interstitial fibrosis was noted, which was present in all its walls (RV, LV and IVS). Other hearts in this group did not show this pathology. In the vast majority of cases, the muscle fiber arrangement was regular. Only in the case of three hearts (2 hearts — RV wall, 1 heart — IVS; 28.6% and 14.3%, respectively), incidents of area-limited disturbance of the cardiomyocytes co-axial arrangement could be observed.

In the study group (SG) with macroscopic hypertrophy of the heart muscle, apart from the assessment of cardiomyocyte thickness, the results of microscopic observations did not differ much from those obtained in the assessment of CG. Within free walls of the RV, in all cases, the average diameter was 10  $\mu\text{m}$ . Within the remaining cardiac walls (IVS and LV), cardiomyocytes most often reached a diameter ranging between 12-15  $\mu\text{m}$ . In one of the examined hearts within SG, the presence of adipose tissue was observed only in the right ventricular musculature (14.3%). The other walls of this, as well as other walls of remaining hearts, did not show the presence of this feature. Interstitial fibrosis was observed in the same heart, also within RV (14.3%), and in the second heart, only in the muscle of the left ventricle (14.3%). The other walls in these two cases, as well as other hearts, also did not show the presence of this feature. Despite the myocardial hypertrophy found at the stage of macroscopic examination, microscopic examination did not show any disturbance of the spatial arrangement of muscle fibers in any of these hearts (Table 6).

## **DISCUSSION**

Remodeling of the heart muscle is a phenomenon quite well known and described. The natural course and final effect of this remodeling, at an organ, tissue and cellular level, may look different depending on the initiating factor. There are many reports focusing on a single heart chamber myocardial remodeling, e.g.: left ventricular muscle under the influence of ischemic disease and myocardial infarction [11, 12], valvular defects of the left arterial and atrioventricular outlet [13], cardiomyopathy [14], arterial hypertension [15]; right ventricular musculature in chronic pulmonary hypertension of various etiologies [16] or chronic obstructive pulmonary disease [17].

However, only recent years have resulted in reports of researchers who drew attention to the fact that in the heart, which is obviously one inseparable whole, there is a possibility of adverse phenomena within the myocardial cavity seemingly unrelated to a given aggravating factor.



Research conducted by Tadic et al. has shown a clear correlation between the occurrence of arterial hypertension and remodeling of the right ventricular muscle, which leads to impairment of its function [18-20]. The above observations were also reflected in the work conducted by Cuspidi et al. [21, 22] and other researchers [23, 24]. Interestingly, changes indicating this remodeling were observed not only in the group of patients with arterial hypertension, but also at earlier stages of the disease [25], and even in the group of patients with arterial blood pressure classified as “normal high” [26, 27]. The above studies were based on in vivo echocardiographic assessment of RV morphology and function. Our study seems to partially confirm these observations on the sectional material.

It may be argued that statistically significant changes in the thickness of the free wall of the right heart ventricle do not go hand in hand with evident cardiomyocyte hypertrophy. However, if we take into account the fact that although the thickness of the RV free walls in SG compared to CG was significantly greater, it still remained within the accepted echocardiographic norms (up to 5mm), exceeding them only at level A.

It can be suspected that in SG the phenomenon occurring in the right ventricular musculature is a result of regulatory and / or compensatory processes occurring in the myocardium as a whole and may be equivalent to physiological hypertrophy observed within the left ventricular muscle in conditions of its increased physiological load (e.g. practicing sports, pregnancy). This thesis is supported by the fact that microscopic examination revealed no evidence of permanent, irreversible remodeling of the right ventricular muscle. As the authors of this study we are aware of its undoubted limitation of the small size of the groups, which limits both the possibility of formulating fully convincing conclusions and the effectiveness of statistical methods. Unfortunately, the selection of material originating from people burdened only with hypertension (in order to eliminate other known factors that can lead to muscle remodeling of any of the walls of the heart) and who died of non-cardiovascular causes is an extremely problematic task. Difficulties associated with obtaining this type of selected material is extremely difficult and time-consuming and affected its limited number.

## **CONCLUSIONS**

Although in vivo echocardiographic tests, as well as our macroscopic evaluation of post-mortem material, suggest such suspicions, based on the results of the study (primarily the

microscopic observations), it was not possible to answer the question of whether the right ventricular muscle remodeling is evident during hypertension. Instead of a simple, unambiguous answer, the question arises: why and how the right ventricular systolic and diastolic function is disturbed, sometimes at a very early stage of the development of arterial hypertensive disease. Confirmation of this requires further research, possibly reaching deeper into the ultrastructure of the cardiomyocyte.

## REFERENCES

1. Anrep GV, Hausler H. The coronary circulation: I. The effect of changes of the blood-pressure and of the output of the heart. *J. Physiol.* 1928; 65(4):357-373.
2. Limbourg P, Wende W, Henrich H, et al. Frequency potentiation and Frank-Starling mechanism in canine ventricle under sinus node rhythm and ventricular pacing. *Pflugers Arch.* 1971; 322(3):250-63.
3. D'Andrea A, Caso P, Scarafile R, et al. Biventricular myocardial adaptation to different training protocols in competitive master athletes. *Int. J. Cardiol.* 2007; 115(3):342-349.
4. Kamiński L, Płońska E, Szyszka A, et al. Echocardiographic examination of cardiac structure and function in male athletes of static and dynamic disciplines. *Pol. Merkurusz Lek.* 2006; 20(117):274-278.
5. Schannwell CM, Zimmermann T, Schneppenheim M, et al. Left ventricular hypertrophy and diastolic dysfunction in healthy pregnant women. *Cardiology.* 2002; 97(2):73-78, doi: 10.1159/000057675.
6. Grajek S. Patofizjologia przebudowy serca. In: Szyszka A (ed.). *Przebudowa serca.* ViaMedica, Gdańsk 2002:1-30.
7. Cohn JN. Structural basis for heart failure. Ventricular remodeling and its pharmacological inhibition. *Circulation* 1995; 91:2504-2507, doi: 10.1161/01.cir.91.10.2504.
8. Weber KT, Sun Y, Guarda E. Structural remodeling in hypertensive heart disease and the role of hormones. *Hypertension* 1994; 23:869-877, doi: 10.1161/01.hyp.23.6.869.
9. Rodrigues JCL, Amadu AM, Dastidar AG, et al. Prevalence and predictors of asymmetric hypertensive heart disease: insights from cardiac and aortic function with cardiovascular magnetic resonance. *Eur Heart J – Cardiovasc Imaging* (2016) 17, 1405–1413, doi:10.1093/ehjci/jev329
10. Franco V. Right Ventricular Remodeling in Pulmonary Hypertension. *Heart Fail Clin.* 2012 Jul;8(3):403-12. doi: 10.1016/j.hfc.2012.04.005
11. Dong L, Mintz G, Witzenbichler B, et al. Coronary Artery Disease: Comparison of Plaque Characteristics in Narrowings With ST-Elevation Myocardial Infarction (STEMI), Non-STEMI/Unstable Angina Pectoris and Stable Coronary Artery Disease (from the ADAPT-DES IVUS Substudy). *Am J Cardiol.* 2015; 115(7):860-866, doi: 10.1016/j.amjcard.2015.01.008.
12. Schuleri KH; Centola M, Evers KS, et al. Cardiovascular magnetic resonance characterization of peri-infarct zone remodeling following myocardial infarction. *J Cardiovasc Magn Reson*; 2012; 14:14-24, doi: 10.1186/1532-429X-14-24.
13. Park JY, Ryu SK, Choi JW, et al. Association of inflammation, myocardial fibrosis and cardiac remodelling in patients with mild aortic stenosis as assessed by biomarkers and echocardiography. *Clin Exp Pharmacol Physiol* 2014; 41(3):185-191, doi: 10.1111/1440-1681.12206.
14. Latus H, Gummel K, Klingel K, et al. Focal myocardial fibrosis assessed by late gadolinium enhancement cardiovascular magnetic resonance in children and adolescents with dilated cardiomyopathy. *J Cardiovasc Magn Reson* 2015; 17(1):1-11, doi: 10.1186/s12968-015-0142-0.
15. Puchades R, Ruiz-Nodar JM, Blanco F, et al. An analysis of cardiac remodeling in the elderly population. EPICARDIAN study. *Rev Esp Cardiol* 2010; 63(8):989-991, doi: 10.1016/s1885-5857(10)70193-6.
16. Harrison A, Hatton N, Ryan J. The right ventricle under pressure: evaluating the adaptive and maladaptive changes in the right ventricle in pulmonary arterial hypertension using echocardiography. *Pulm Circ.* 2015; 5(1):29-47, doi: 10.1086/679699.
17. Biernacki W, Flenley DC, Muir AL, et al. Pulmonary hypertension and right ventricular function in patients with COPD. *Chest* 1988; 94:1169-75, doi: 10.1378/chest.94.6.1169.

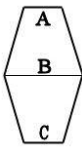
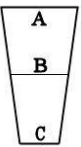
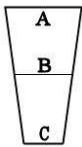
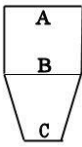
18. Tadic M, Ivanovic B, Celic V, et al. Are the metabolic syndrome, blood pressure pattern, and their interaction responsible for the right ventricular remodeling? *Blood Press Monit* 2013 Aug; 18(4):195-202, doi: 10.1097/MBP.0b013e3283631af4
19. Tadic M, Cuspidi C, Pencic B, et al. Relationship between right ventricular remodeling and heart rate variability in arterial hypertension. *J Hypertens* 2015; 33(5):1090-1097, doi: 10.1097/HJH.0000000000000511.
20. Tadic M, Ivanovic B, Celic V, et al. The impact of metabolic syndrome, recently diagnosed diabetes and hypertension on right ventricular remodeling. Is there difference between risk factors? *Clin Exp Hypertens* 2014; 36:295–301, doi: 10.3109/10641963.2013.810235.
21. Cuspidi C, Valerio C, Sala C, et al. Metabolic syndrome and biventricular hypertrophy in essential hypertension. *J Hum Hypertens* 2009; 23:168-175, doi: 10.1038/jhh.2008.145.
22. Cuspidi C, Sampieri L, Angioni L, et al. Right ventricular wall thickness and function in hypertensive patients with and without left ventricular hypertrophy: echo-Doppler study. *J Hypertens Suppl* 1989; 7:S108–109, doi: 10.1097/00004872-198900076-00050.
23. Cicala S, Galderisi M, Caso P, et al. Right ventricular diastolic dysfunction in arterial systemic hypertension: analysis by pulsed tissue Doppler. *Eur J Echocardiogr* 2002; 3:135–142, doi: 10.1053/euje.2001.0124.
24. Tumuklu MM, Erkorkmaz U, Ocal A. The impact of hypertension and hypertension-related left ventricle hypertrophy on right ventricle function. *Echocardiography* 2007; 24:374–384, doi: 10.1111/j.1540-8175.2007.00419.x.
25. Pedrinelli R, Canale ML, Giannini C, et al. Right ventricular dysfunction in early systemic hypertension: a tissue Doppler imaging study in patients with high-normal and mildly increased arterial blood pressure. *J Hypertens* 2010; 28:615–621, doi: 10.1097/hjh.0b013e328334f181.
26. Tadic M, Cuspidi C, Pencic B, et al. High-normal blood pressure impacts the right heart mechanics: a three-dimensional echocardiography and two-dimensional speckle tracking imaging study. *Blood Press Monit* 2014; 19:145–152, doi: 10.1097/MBP.0000000000000043.
27. Pedrinelli R, Canale ML, Giannini C, et al. Abnormal right ventricular mechanics in early systemic hypertension: a two-dimensional strain imaging study. *Eur J Echocardiogr* 2010; 11:738–742, doi: 10.1093/ejechocard/jeq059.

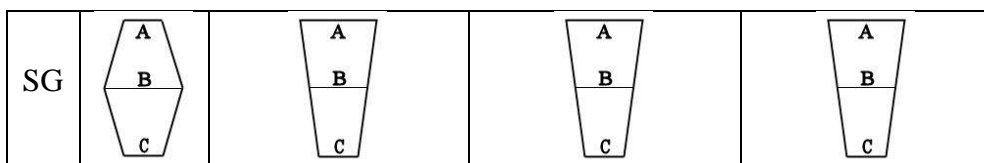
**Table 1.** Comparison of the ratios of the individual dimensions of the inferior wall of the left ventricle in the hearts of CG and SG

	<b>A/B</b>	<b>B/C</b>	<b>A/C</b>
CG	1,031	1,162	1,199
SG	1,044	1,467	1,521
p	0,28	0,11	<b>0,047</b>

CG — control group, SG — studied group, A/B, B/C, A/C — relations of the individual dimensions, p — level of statistical significance

**Table 2.** Schematic representation of the shape of longitudinal section of each of the walls of the heart in CG and SG

	<b>IVS</b>	<b>RV anterior wall</b>	<b>RV posterior wall</b>	<b>LV inferior wall</b>
CG				



IVS — interventricular septum, RV — right ventricle, LV — left ventricle, CG — control group, SG — studied group, A, B, C — levels at which the thickness of the myocardium has been measured

**Table 3.** Comparison of the ratios of the individual dimensions of the interventricular septum in the hearts of CG and SG

	<b>A/B</b>	<b>B/C</b>	<b>A/C</b>
CG	0,917	1,192	1,093
SG	0,843	1,260	1,066
p	0,09	0,07	0,68

CG — control group, SG — studied group, A/B, B/C, A/C — relations of the individual dimensions, p — level of statistical significance

**Table 4.** Comparison of the ratios of the individual dimensions of the anterior wall of the right ventricle in the hearts of CG and SG

	<b>A/B</b>	<b>B/C</b>	<b>A/C</b>
CG	1,406	1,360	1,866
SG	1,274	1,351	1,761
p	0,62	0,97	0,97

CG — control group, SG — studied group, A/B, B/C, A/C — relations of the individual dimensions, p — level of statistical significance

**Table 5.** Comparison of the ratios of the individual dimensions of the posterior wall of the right ventricle in the hearts of CG and SG

	<b>A/B</b>	<b>B/C</b>	<b>A/C</b>
CG	1,097	1,514	1,676
SG	1,142	1,384	1,462
p	0,76	0,94	0,72

CG — control group, SG — studied group, A/B, B/C, A/C — relations of the individual dimensions, p — level of statistical significance

**Table 6.** Table of microscopic observations — frequency [%] of morphological features of remodeling of the heart muscle in studied groups

Group	Adipose tissue infiltrating myocardium [%]			Interstitial fibrosis [%]			Avg. myocytes thickness [ $\mu\text{m}$ ]		
	RV	IVS	LV	RV	IVS	LV	RV	IVS	LV
CG	14,3	0	0	14,3	14,3	14,3	10	10	10
SG	14,3	0	0	14,3	0	14,3	10	13,5	14

CG — control group, no hypertrophy, SG — test group, with myocardial hypertrophy, RV — posterior wall of the right ventricle, IVS — interventricular septum, LV — inferior wall of the left ventricle

**Figure 1.** The scheme of heart opening cut (dashed line) and heart walls cuts for measurements (dashed-dot lines).

**Figure 2.** Opened heart and incisions of the walls to take measurements; LV — left ventricle, RV — right ventricle; IVS — interventricular septum; TVL — tricuspid valve leaflet; A, B, C — measurements of heart walls thickness at appropriate levels.

**Figure 3.** Right ventricle myocardium infiltration by adipose tissue (arrows) ( $\sigma$  1.71; Mason-Goldner staining; 62.5 $\times$ ).

**Figure 4.** Interstitial fibrosis (arrows) of interventricular septum myocardium ( $\sigma$  1.71; Mason-Goldner staining; 62.5 $\times$ ).

**Figure 5.** Microscopic view of a healthy myocardium of interventricular septum ( $\sigma$  1.24; Mason-Goldner staining; 62.5 $\times$ ).

