



The effect of three-dimensional (3D) printing on quantitative and qualitative outcomes in paediatric orthopaedic osteotomies: a systematic review

Mohsen Raza¹
Daniel Murphy¹
Yael Gelfer^{1,2}

- Three-dimensional (3D) printing technology is increasingly being utilized in various surgical specialties. In paediatric orthopaedics it has been applied in the pre-operative and intra-operative stages, allowing complex deformities to be replicated and patient-specific instrumentation to be used. This systematic review analyses the literature on the effect of 3D printing on paediatric orthopaedic osteotomy outcomes.
- A systematic review of several databases was conducted according to PRISMA guidelines. Studies evaluating the use of 3D printing technology in orthopaedic osteotomy procedures in children (aged ≤ 16 years) were included. Spinal and bone tumour surgery were excluded. Data extracted included demographics, disease pathology, target bone, type of technology, imaging modality used, qualitative/quantitative outcomes and follow-up. Articles were further categorized as either 'pre-operative' or 'intra-operative' applications of the technology.
- Twenty-two articles fitting the inclusion criteria were included. The reported studies included 212 patients. There were five articles of level of evidence 3 and 17 level 4.
- A large variety of outcomes were reported with the most commonly used being operating time, fluoroscopic exposure and intra-operative blood loss.
- A significant difference in operative time, fluoroscopic exposure, blood loss and angular correction was found in the 'intra-operative' application group. No significant difference was found in the 'pre-operative' category.
- Despite a relatively low evidence base pool of studies, our aggregate data demonstrate a benefit of 3D printing technology in various deformity correction applications, especially when used in the 'intra-operative' setting. Further research including paediatric-specific core outcomes is required to determine the potential benefit of this novel addition.

Keywords: osteotomy; paediatric orthopaedic; patient-specific instrumentation; surgery; three-dimensional (3D) printing

Cite this article: *EFORT Open Rev* 2021;6:130-138.
DOI: 10.1302/2058-5241.6.200092

Introduction

Three-dimensional (3D) printing technology, also known as 'additive manufacturing' or 'rapid prototyping', is increasingly being utilized in the field of medicine. Its first reported medical use was in 1990 when a 3D model of cranial bony anatomy was created from CT imaging.¹ Since then, it has been increasingly applied especially in surgical specialties such as oral and maxillofacial surgery,^{2,3} cardiothoracic surgery,⁴ plastic surgery,⁵ neurosurgery⁶ and orthopaedic surgery.⁷⁻⁹

3D printing creates a physical model via an 'additive' process rather than the traditional 'subtractive' manufacturing process which removes excess material. It creates a 3D object by adding the material (powder, or liquid-like metal or plastic) layer by layer, based on coordination data using computer-aided design (CAD) software from imaging such as high-resolution computed tomography (CT). This digital representation of an object is then commonly converted to a standard triangulation language (STL) file which allows the 3D printer to print the object layer by layer, producing an accurate 3D printed replica model. Additive technologies used in orthopaedics include stereolithography (SLA), selective laser sintering (SLS) and fused deposition modelling (FDM) for creating custom models, surgical guides and personalized implants.^{7,8} Applying this principle to orthopaedic surgery allows complex deformities of bone to be replicated. To this end, 3D printing has mainly been utilized in pre-operative planning and 3D patient-specific instrumentation (PSI).

One of the key focuses in paediatric orthopaedic practice is corrective limb deformity. With increasing accessibility to 3D printing, this technology is available as a useful

tool in the pre-operative and intra-operative stages of a patient's surgical journey. The benefits of 3D printed models in improving patients' education as well as surgeons' training has already been recognized in the literature.^{10–13} This article will focus on the direct clinical applicability in the pre-operative and intra-operative stages.

The aim of this systematic review is to investigate the effect of 3D printing on paediatric orthopaedic osteotomy surgical outcomes. To our knowledge, this is the first article focusing on this topic.

Methods

Search strategy

We conducted a systematic literature search in accordance with the Preferred Reporting Items for Systematic Reviews and Meta-Analyses (PRISMA) guidelines.¹⁴ The project was prospectively registered on the International Prospective Register of Systematic Reviews (PROSPERO registration: CRD42020189279).

A comprehensive search was undertaken in the PubMed, Embase and Medline databases from their inception until July 2020. A search of the grey literature was also performed with authors contacted for further details where applicable. The following keywords were used in the search and combined to maximize results: “three-dimensional”, “3D”, “print*”, “orthopaedic”, “osteotomy”, “patient specific instrumentation”, “paediatric”, “child”, “teen”, “adolescent”. The search was not limited by year of publication, journal type, language or level of evidence.

Eligibility criteria

The inclusion criteria were: any published original article, use of 3D printing technology, orthopaedic surgery, paediatric primary study population (aged ≤ 16 years). Exclusion criteria were: basic science articles, spinal surgery, bone tumour surgery and review papers. As the aim of the review was assessing the effect on quantitative and qualitative outcomes and taking into consideration the novelty of this intervention, all levels of evidence were considered appropriate for the analysis.

Two authors (MR and DM) reviewed all abstracts and full texts where needed for inclusion according to the above criteria. In cases of disagreement, a senior author (YG) was consulted and disagreement was resolved in consensus.

Data extraction and analysis

The following data were extracted: demographics (year and country of publication, mean age, patient number), disease pathology, target bone, type of 3D printing technology, pre-operative imaging modality, qualitative/

quantitative outcomes and follow up. The articles were then categorized based on either predominantly ‘pre-operative’ or ‘intra-operative’ applications of 3D printing technology.

Data were extracted with use of the Covidence 2019 online platform and a data collection table in Microsoft Excel. All continuous data were pooled, and descriptive data analysis performed. We utilized the ‘Synthesis Without Meta-analysis’ (SWiM) reporting guideline and ‘Enhancing transparency in reporting the synthesis of qualitative research’ (ENTREQ) checklist to aid with data synthesis methodology.^{15,16} As the majority of studies were case reports/series, bias assessment was not deemed appropriate.

Results

A total of 169 published reports were originally identified. Fig. 1 presents the PRISMA flowchart of study selection. A total of 22 articles matched the inclusion criteria with complete agreement between the reviewers. The extracted data are presented in Table 1.

The 22 articles were published between 2011 and 2020 with the large majority (19 out of 22, 86.4%) having been published between 2017 and 2020. The studies were conducted in Belgium, China, Japan, the Netherlands, Poland, Russia, Switzerland, Taiwan, Turkey, the UK and the USA. The majority of studies were from China ($N = 5$, 22.7%) and the USA ($N = 4$, 18.1%). There were nine case series, eight case reports and five comparative cohort studies. The total number of patients across all studies was 212, with the largest individual study patient number equaling 35.¹⁷ The mean age across the studies was 11.2 years (range 3 to 21 years).

The ‘pre-operative’ 3D printing articles printed models for simulation osteotomies and when stated, were made of plastic polymers such as acrylonitrile butadiene styrene (ABS) or polyactide (PLA). All ‘intra-operative’ studies used 3D printing to create plastic patient-specific osteotomy guides with one study additionally creating a patient-specific titanium plate. This is in contrast to the popularity of custom final implants in the adult population as noted by a recent review of 3D printing in orthopaedics as a whole.⁹

Pre-operative surgical planning

Seven studies used 3D printing technology for pre-operative surgical planning: three for proximal femoral deformity correction due to either slipped upper femoral epiphysis (SUFE), Perthes disease, developmental dysplasia of the hip (DDH) or post-osteomyelitis deformity,^{18–20} one study for periacetabular osteotomy (PAO) planning in DDH,²¹ one for cubitus varus deformity in the distal humerus,²² one for complex lower limb deformity

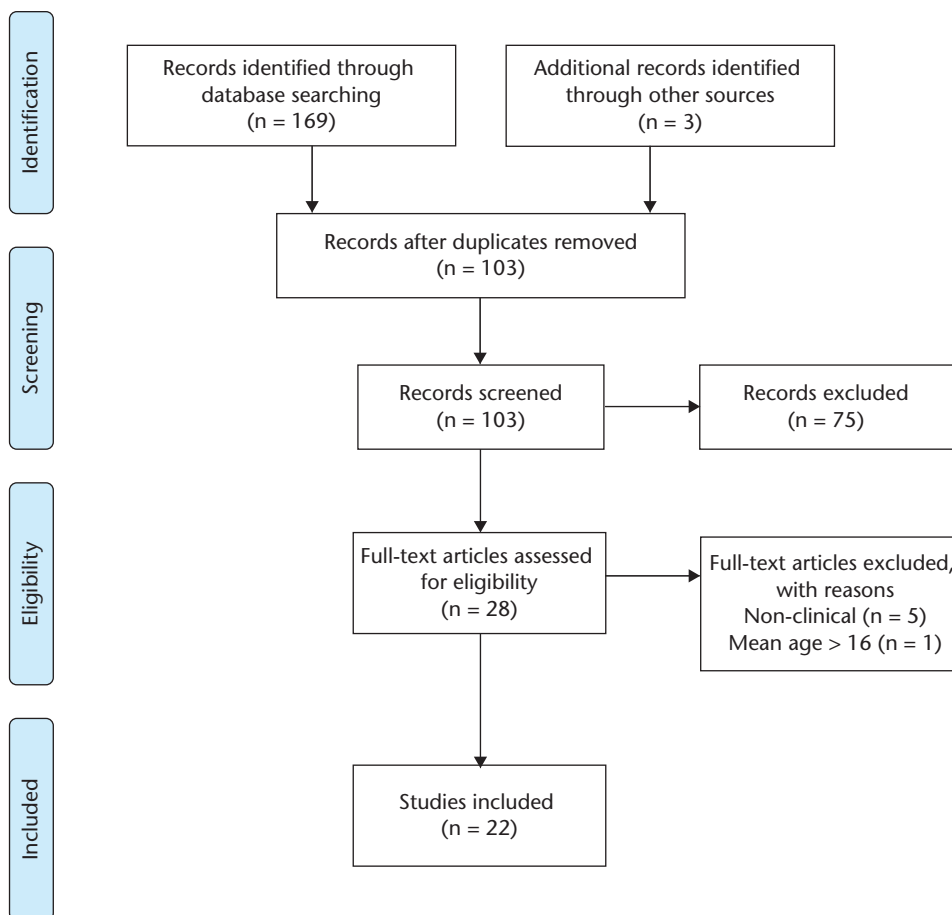


Fig. 1 PRISMA flow diagram.

correction of the tibia and midfoot²³ and one for clavicle malunion.²⁴ All studies printed anatomical 3D models of the relevant deformity to help guide and perform simulated osteotomy techniques.

The reported quantitative outcomes were surgical operating time, fluoroscopy time and radiographic angle measurement.^{18,19} There was no significant difference between the groups in all quantitative outcomes, although a trend towards reduction in operating time and fluoroscopy time was found. Quantitative radiographic measurements were improved to expected values in all groups.^{18,20–22}

The reported qualitative outcomes were development of avascular necrosis (AVN), clinical evaluation (assessing stability, pain, activity levels) and development of post-operative complications. There was an improvement in these outcomes with no reports of AVN^{18,19} and similar satisfactory clinical outcomes and increased activity levels at latest follow up.^{20–22,24} There were no complications reported in the 3D printed patient groups and three minor complications were noted in the control groups.¹⁸

Intra-operative application

Fifteen studies utilized 3D printing for PSI in operations involving the proximal femur (four),^{25–28} forearm (five),^{29–33} foot (one),³⁴ and distal humerus (five).^{17,35–38}

Quantitative outcome measures included surgical operation time, fluoroscopic exposure (number of radiographs), intra-operative blood loss volume, radiographic angular correction measurements and range of motion assessments. There was a statistically significant reduction in operative time,^{17,25,26,37} fluoroscopic exposure^{25,26} and intra-operative blood loss,³⁷ with significant improvements found in angular correction^{27,28} and range of motion.^{29,30}

Qualitative outcomes included clinical examination assessments (e.g. joint stability, activity level and pain), presence of complications and radiographic evaluation (e.g. union). All studies reported satisfactory clinical examination findings at last follow up, such as joint stability^{25,29,37} and improved activity level.^{33–35} Most of the studies report satisfactory radiographic evaluation and either complete resolution of or improved pain

Table 1. Summary of studies

Study / country	Study type / Level of evidence	Mean age (years)	Number of patients	Pathology	Bone	3D Printing primary application	3D Printing material		Pre-op imaging		Qualitative outcomes	Quantitative outcomes	Follow up (months)
							PRE-OP	INTRA-OP	CT	MRI			
1 Cherkasskiy et al, 2017 ¹⁸ USA	Retrospective cohort / 3	13.5	15	SCFE	Femur (proximal)	✓		Acrylonitrile butadiene styrene (ABS)	✓		– Development of avascular necrosis (AVN) – Complications	– Operation time – Fluoroscopy time – Radiographic assessment: epiphyseal shaft angle (ESA), neck shaft angle, articular surface to trochanter distance, medial proximal femoral angle	23
2 Kalenderer et al, 2019 ¹⁹ Turkey	Prospective case series / 4	10.0	2	Perthes, DDH	Femur (proximal)	✓		Not stated	✓		– Development of AVN – Complications	– Operation time – Blood loss	12
3 Wei et al, 2019 ²⁰ Taiwan	Case report / 4	4.0	1	Post-osteomyelitis deformity	Pelvis, Femur	✓		Not stated	✓		– Clinical: gait/squat assessment – Radiographic union – Complications	– Radiographic assessment: lateral centre edge (CE) angle, acetabular index – Clinical: range of motion (ROM)	24
4 Holt et al, 2017 ²¹ USA	Case report / 4	10.0	1	DDH, chronic hip instability (Trisomy 21)	Pelvis	✓		ABS	✓		– Clinical: pain, ambulation, stability – Complications – Radiographic union	– Radiographic assessment: lateral CE angle, anterior CE angle, acetabular index	33
5 Bovid et al, 2019 ²² USA	Case report / 4	3.0	1	Cubitus varus deformity (post-traumatic)	Humerus (distal)	✓		Not stated	✓		– Clinical: pain, activity level – Complications	– Radiographic assessment: carrying angle – Clinical: ROM	28
6 Morasiewicz et al, 2018 ²³ Poland	Case report / 4	6.0	1	Lower limb deformity	Tibia, Midfoot	✓		Poly lactide (PLA)	✓			– Limb lengthening – Correction of valgus angle / axial correction	76
7 Consigliere et al, 2020 ²⁴ UK	Case report / 4	14.0	1	Post-traumatic clavicle deformity	Clavicle	✓		Not stated	✓		– Clinical: pain, activity level – Radiographic union	– Clinical: ROM	12
8 Zheng et al, 2017 ²⁵ China	Prospective cohort / 3	10.9	25	DDH	Femur (proximal)		✓	PLA	✓		– Clinical: McKay criteria, Severin criteria – Proximal femoral epiphyseal growth arrest	– Operation time – X-ray exposures – Radiographic assessment: neck shaft angle, femoral anteversion	18
9 Zheng et al, 2017 ²⁶ China	Retrospective cohort / 3	6.6	11	DDH, Neck of Femur (NOF) fracture	Femur (proximal)		✓	PLA	✓		– Proximal femoral epiphyseal growth arrest	– Operation time – X-ray exposures – Radiographic assessment: neck shaft angle, femoral anteversion	Not stated
10 Baskov et al, 2017 ²⁷ Russia	Retrospective case series / 4	11.5	27	Proximal femoral deformity (congenital/acquired)	Femur (proximal)		✓	Plastic polymer	✓			– Operation time – X-ray exposures – Radiographic assessment: neck shaft angle, epidiaphyseal angle, femoral anteversion	Not stated
11 Furnstahl et al 2020 ²⁸ Switzerland	Retrospective case series / 4	14.0	6	Proximal femoral deformity (Perthes)	Femur (proximal)		✓	Plastic polyamide	✓		– Complications	– Radiographic assessment: diameter index, sphericity index, Stulberg classification, extrusion index, lateral CE angle, Tonnis angle, caput-collum-diaphyseal (CCD) angle – Time: preliminary analysis, simulation, PSI design – Cost: manufacturing, time expense	17.5

(continued)

Table 1. Summary of studies (continued)

Study / country	Study type / Level of evidence	Mean age (years)	Number of patients	Pathology	Bone	3D Printing primary application		3D Printing material		Pre-op imaging		Qualitative outcomes	Quantitative outcomes	Follow up (months)
						PRE-OP	INTRA-OP			CT	MRI			
12 Bauer et al, 2017 ²⁹ USA	Retrospective case series / 4	13.5	19	Forearm deformity (post-traumatic 15, MHE 3, Madelung 1)	Radius, Ulna	✓		Not stated		✓		– Clinical: distal radioulnar joint stability – Complications – Radiographic union	– Radiographic assessment: mean maximum deformity angulation – Clinical: forearm ROM union	Not stated
13 Byrne et al, 2017 ³⁰ Belgium	Prospective case series / 4	13.0	5	Diaphyseal forearm malunions	Radius, Ulna	✓		Polyamide guide Titanium plate		✓		– Complications – Radiographic union	– Radiographic assessment: angular correction of radius/ulna deformity – Clinical: forearm ROM, grip strength – Pain score	42
14 Kataoka et al, 2017 ³¹ Japan	Retrospective case series / 4	13.0	4	Distal diaphyseal radius malunion	Radius	✓		Plastic polymer		✓		– Clinical: pain – Complications – Radiographic union	– Clinical: forearm ROM, grip strength – Radiographic assessment: angular deformity	22
15 Inge et al, 2018 ³² Netherlands	Case report / 4	16.0	1	Distal radius malunion	Radius	✓		Not stated		✓		– Radiographic union	– Clinical: ROM – DASH score	12
16 Jeuken et al, 2017 ³³ Netherlands	Case report / 4	15.0	1	Diaphyseal forearm malunion	Radius, Ulna	✓		Plastic polymer		✓		– Clinical: activity level	– Clinical: forearm ROM – Radiographic: angular correction	6
17 de Wouters et al, 2014 ³⁴ Belgium	Prospective case series / 4	14.2	9	Tarsal coalition	Talus, Calcaneus, Navicular	✓		Acrylic-PMMA + titanium		✓		– Clinical: hindfoot mobility – Complications – Radiographic: completion of resection, recurrence	– AOFAS score	17.9
18 Tricot et al, 2012 ³⁵ Belgium	Prospective Case series / 4	10.3	3	Distal humerus deformity (post-traumatic)	Humerus (distal)	✓		Not stated		✓		– Clinical: pain – Complications	– Clinical: elbow ROM – Radiographic assessment: carrying angle	6
19 Zhang et al, 2011 ³⁶ China	Prospective case series / 4	15.7	18	Cubitus varus deformity (post-traumatic)	Humerus (distal)	✓		Acrylate resin		✓		– Clinical: pain, satisfaction, instability – Complications – Radiographic union	– Clinical: elbow ROM – Radiographic assessment: carrying angle	18
20 Zhang et al, 2019 ³⁷ China	Retrospective case series / 3	9.8	25	Cubitus varus deformity (post-traumatic)	Humerus (distal)	✓		Acrylate resin		✓		– Complications – Radiographic union – Parent satisfaction score	– Operation time – Blood loss – Radiographic assessment: carrying angle – Clinical assessment: elbow ROM, deformity correction (via Bellemore criteria)	18
21 Oka et al, 2017 ³⁸ Japan	Case report / 4	14.0	1	Cubitus varus deformity (post-traumatic)	Humerus (distal)	✓		Plastic polymer		✓		– Radiographic union	– Radiographic assessment: carrying angle – Clinical assessment: elbow ROM	20
22 Hu et al, 2020 ¹⁷ China	Prospective cohort / 3	7.5	35	Cubitus varus deformity (post-traumatic)	Humerus (distal)	✓		PLA		✓		– Complications – Radiographic union	– Operation time – Clinical assessment: elbow ROM, deformity correction (via Bellemore criteria) – Radiographic assessment: carrying angle	6–12

Notes. CT, computed tomography; MRI, magnetic resonance imaging; MHE, multiple hereditary exostoses; DDH, developmental dysplasia of the hip; SCFE, slipped capital femoral epiphysis; PMMA, polymethyl methacrylate; PSI, patient specific instrumentation; DASH, disabilities of the arm, shoulder and hand; AOFAS, American orthopaedic foot and ankle society; ROM, range of motion

on assessment.^{30–35} There were no major complications reported in the PSI patient groups with two minor complications that resolved with treatment.^{35,37}

Discussion

The most significant findings in this review are that 3D printing used during the intra-operative stages is beneficial in reducing surgical operating time, fluoroscopic exposure and blood loss. These findings are in keeping with the data from the adult population.⁹

The primary quantitative outcomes were surgical operating time, fluoroscopic exposure, intra-operative blood loss and radiographic measurements. The qualitative outcomes assessed included clinical examination parameters (such as joint stability, activity level and pain), post-operative complications (such as AVN) and radiographic evaluation (such as union).

In studies looking into pre-operative implementation, comparative studies did not find a significant effect. However, an improvement in qualitative outcomes was reported in terms of clinical assessment and complication rate.¹⁸ The benefits of 3D printing in interpreting complex paediatric deformities and a better understanding of the condition to be treated have been widely reported.^{13,39–46} In the largest of this review's pre-operative studies, the models allowed the surgeon to simulate the procedure and gain a better understanding of the patient's 3D anatomy whilst determining the exact wedge size for a more efficient osteotomy.¹⁸

The implementation of 3D printing for pre-operative planning was the most common application found in a heterogenic systematic review by Levesque et al in 2020 that included a mostly adult population.⁹ This review looked at extensive implementation in orthopaedic surgery that included trauma and oncology. The level I and II evidence consistently found shorter operative time, less blood loss and fluoroscopy use when 3D printing was used. In contrast, our review did not find a significant effect in the pre-operative category for the paediatric population, and a larger randomized controlled trial is needed to be able to answer this question.

The studies that implemented 3D printing as an intra-operative application found a significant effect on the primary outcomes with reductions in operative time,^{18,25,26,37} fluoroscopic exposure^{25,26} and intra-operative blood loss.³⁷ For one of this review's largest prospective cohort studies, operation time (21.08 min vs. 46.92 min) and number of fluoroscopy exposures (3.92 vs. 6.69) were significantly decreased ($p < 0.05$) when comparing patients utilizing 3D printed surgical osteotomy guides to those without.²⁵ In another comparative cohort study, intra-operative blood loss was nearly a third less (35.6 mls in the 3D printed group compared to 52.1 mls in the conventional group)

($p < 0.001$).³⁷ This is consistent with literature in the adult population.^{9,47,48} Improvements in angular correction²⁹ and range of motion were also demonstrated.^{29,30}

Improved qualitative clinical and radiographic outcomes were noted across the studies.^{25,29,33–36} These findings are supported by similar studies in the adult population.⁴⁹

PSI enables the surgical team to pre-determine the osteotomy angle, plane and rotation. It allows more precise surgery and can act to prevent damage to surrounding tissue and epiphyseal cartilage, as shown by the low complication rate and no evidence of growth arrest at follow up.^{25,26} By applying individualized templates which closely correlate to the patient's bony anatomy, there is no requirement to perform repeated adjustments which arguably saves time, blood loss and reduces the requirement for repeated fluoroscopy exposures.^{17,37}

Study limitations

The level of evidence available is low with most studies presenting case reports or series. There is a variability in reported outcomes, anatomical sites as well as a wide range of follow-up time. As this is a novel addition this is to be expected, and although every new report adds value and knowledge, the reported outcomes should be interpreted with caution. The broad inclusion criteria were deemed a strength due to the novelty and relevance of the technology.

3D printing limitations

3D printing technology has its own limitations to recognize, such as cost, time to production and radiation exposure requirements. Cost has been highlighted as a potential obstacle to its widespread application, as 3D printing requires specialist hardware/software, engineering skills, machine maintenance and printing materials.^{7,50} However, a recent systematic review on the use of 3D printing in pre-operative planning in trauma surgery cited reduced operative time and fluoroscopy time as potential financial savings.⁴⁷ This was reiterated by Cherkasskiy et al¹⁸ in 2017 with a reported US\$2700 cost saving per case for a 45 minute reduction in theatre time.

Processing for 3D printing requires pre-operative image acquisition. As bony tissues have a relatively higher contrast than soft tissue on CT, it is the modality of choice. We found that 21 out of 22 studies utilized CT imaging with only one using magnetic resonance imaging (MRI).²² The higher radiation dose of CT is well documented as are the concerns with oncogenic potential which are particularly significant in the paediatric population due to increased radiosensitivity of children to ionizing radiation and increased absorbed organ doses due to their reduced body dimensions.^{51–53} Over the last decade, there has been rapid progress in utilizing MRI imaging sequencing

and expanding its application to better visualize bone and reduce the risk of ionizing radiation in children.⁵² To this end, our review found only one study that utilized MRI to create their custom 3D printed model. The authors highlighted its benefit in visualizing cartilage and non-ossified tissues as well as limiting ionizing radiation exposure in their paediatric patient.²²

Future trends

3D printing technology is continuing to expand and evolve in a number of areas, a few of which can prove attractive to the paediatric orthopaedic patient population. An alternative modality of acquiring images utilizing low ionizing radiation for the purpose of creating a 3D model is the technology of ‘biplanar low-dose X-ray’ technology (EOS_{TM} imaging) that uses low-dose digital stereoradiography to allow for 3D modelling of the skeletal system.^{54–57} The images are taken with significantly lower doses of radiation compared to plain radiographs or CT scans,^{56,57} which is particularly advantageous in the growing child. In the field of developing lightweight custom-made prostheses, 3D printing can prove valuable and affordable.^{57,58} The promising novel technologies of ‘bio-scaffolds’ and ‘bio-printing’ are further implementations which combine gene therapy and tissue engineering for bone or tissue repair.^{7,57,59–62}

Conclusion

3D printing technology is growing in implementation and use in paediatric orthopaedics. Despite a relatively low evidence base pool of studies, our aggregate data demonstrate a benefit of 3D printing technology in various deformity correction applications, especially when used in the ‘intra-operative’ setting. High-quality research including paediatric-specific core outcomes is required to ascertain the potential benefit of this novel addition.

AUTHOR INFORMATION

¹Department of Trauma & Orthopaedics, St George’s University Hospitals NHS Foundation Trust, London, UK.

²St George’s, University of London, London, UK.

Correspondence should be sent to: Mohsen Raza, St George’s University Hospitals NHS Foundation Trust, Blackshaw Road, Tooting, London, SW17 0QT, UK.
Email: mohsen.raza@doctors.org.uk

ICMJE CONFLICT OF INTEREST STATEMENT

The authors declare no conflict of interest relevant to this work.

FUNDING STATEMENT

No benefits in any form have been received or will be received from a commercial party related directly or indirectly to the subject of this article.

OPEN ACCESS

© 2021 The author(s)

This article is distributed under the terms of the Creative Commons Attribution-Non Commercial 4.0 International (CC BY-NC 4.0) licence (<https://creativecommons.org/licenses/by-nc/4.0/>) which permits non-commercial use, reproduction and distribution of the work without further permission provided the original work is attributed.

REFERENCES

- Mankovich NJ, Cheeseman AM, Stoker NG.** The display of three-dimensional anatomy with stereolithographic models. *J Digit Imaging* 1990;3:200–203.
- Choi JW, Kim N.** Clinical application of three-dimensional printing technology in craniofacial plastic surgery. *Arch Plast Surg* 2015;42:267–277.
- Aldaadaa A, Owji N, Knowles J.** Three-dimensional printing in maxillofacial surgery: hype versus reality. *J Tissue Eng* 2018;9:2041731418770909.
- Giannopoulos AA, Steigner ML, George E, Barile M, Hunsaker AR, Rybicki FJ, et al.** Cardiothoracic Applications of 3D Printing. *J Thorac Imaging* 2016;31:253–272.
- Chae MP, Rozen WM, McMenamin PG, Findlay MW, Spychal RT, Hunter-Smith DJ.** Emerging applications of bedside 3D printing in plastic surgery. *Front Surg* 2015;2:25.
- Randazzo M, Pisapia JM, Singh N, Thawani JP.** 3D printing in neurosurgery: a systematic review. *Surg Neurol Int* 2016;7:S801–S809.
- Wong TM, Jin J, Lau TW, et al.** The use of three-dimensional printing technology in orthopaedic surgery. *J Orthop Surg (Hong Kong)* 2017;25:2309499016684077.
- Auricchio F, Marconi S.** 3D printing: clinical applications in orthopaedics and traumatology. *EFORT Open Rev* 2017;1:121–127.
- Levesque JN, Shah A, Ekhtiari S, Yan JR, Thornley P, Williams DS.** Three-dimensional printing in orthopaedic surgery: a scoping review. *EFORT Open Rev* 2020;5:430–441.
- Bockhorn L, Gardner SS, Dong D, et al.** Application of three-dimensional printing for pre-operative planning in hip preservation surgery. *J Hip Preserv Surg* 2019;6:164–169.
- Waran V, Narayanan V, Karupiah R, et al.** Injecting realism in surgical training—initial simulation experience with custom 3D models. *J Surg Educ* 2014;71:193–197.
- Lim PK, Stephenson GS, Keown TW, et al.** Use of 3D printed models in resident education for the classification of acetabulum fractures. *J Surg Educ* 2018;75:1679–1684.
- Wong KC.** 3D-printed patient-specific applications in orthopedics. *Orthop Res Rev* 2016;8:57–66.
- Moher D, Liberati A, Tetzlaff J, Altman DG; PRISMA Group.** Preferred Reporting Items for Systematic Reviews and Meta-Analyses: the PRISMA statement. *BMJ* 2009;339:b2535.
- Campbell M, McKenzie JE, Sowden A, Katikireddi SV, Brennan SE, Ellis S, et al.** Synthesis without meta-analysis (SWiM) in systematic reviews: reporting guideline. *BMJ* 2020;368:l6890.
- Tong A, Fleming K, McInnes E, Oliver S, Craig J.** Enhancing transparency in reporting the synthesis of qualitative research: ENTREQ. *BMC Med Res Methodol* 2012;12:181.
- Hu X, Zhong M, Lou Y, et al.** Clinical application of individualized 3D-printed navigation template to children with cubitus varus deformity. *J Orthop Surg Res* 2020;15:111.

- 18. Cherkasskiy L, Caffrey JP, Szewczyk AF, Cory E, Bomar JD, Farnsworth CL, et al.** Patient-specific 3D models aid planning for triplane proximal femoral osteotomy in slipped capital femoral epiphysis. *J Child Orthop* 2017;11:147–153.
- 19. Kalenderer Ö, Erkuş S, Turgut A, İnan İH.** Preoperative planning of femoral head reduction osteotomy using 3D printing model: a report of two cases. *Acta Orthop Traumatol Turc* 2019;53:226–229.
- 20. Wei Y-P, Lai Y-C, Chang W-N.** Anatomic three-dimensional model-assisted surgical planning for treatment of pediatric hip dislocation due to osteomyelitis. *J Int Med Res* 2020;48:300060519854288.
- 21. Holt AM, Starosolski Z, Kan JH, Rosenfeld SB.** Rapid prototyping 3D model in treatment of pediatric hip dysplasia: a case report. *Iowa Orthop J* 2017;37:157–162.
- 22. Bovid KM, Kohler EJ, Habeck JM, Gustafson PA.** Utilization of a 3D-printed model for preoperative planning and operative osteotomy of a pediatric cubitus varus deformity. *JSES Open Access* 2019;3:219–224.
- 23. Morasiewicz P, Burzyńska K, Orzechowski W, Dragan Sł, Dragan SF, Filipiak J.** Three-dimensional printing as a technology supporting the treatment of lower limb deformity and shortening with the Ilizarov method. *Med Eng Phys* 2018;57:69–74.
- 24. Consigliere P, Tyler J, Tennent D, Pearse E.** Symptomatic malunion after midshaft clavicle fracture in an adolescent patient: a case report of surgical deformity correction using a 3D printed model. *Ann R Coll Surg Engl* 2020;102:e126–e129.
- 25. Zheng P, Xu P, Yao Q, Tang K, Lou Y.** 3D-printed navigation template in proximal femoral osteotomy for older children with developmental dysplasia of the hip. *Sci Rep* 2017;7:44993.
- 26. Zheng P, Yao Q, Xu P, Wang L.** Application of computer-aided design and 3D-printed navigation template in Locking Compression Pediatric Hip Plate™ placement for pediatric hip disease. *Int J Comput Assist Radiol Surg* 2017;12:865–871.
- 27. Baskov VE, Baidurashvili AG, Filippova AV, et al.** Planning corrective osteotomy of the femoral bone using three-dimensional modeling. Part II. *Pediatr Traumatol Orthop Reconstr Surg* 2017;5:74–79.
- 28. FÜRNSTAHL P, CASARI FA, ACKERMANN J, MARCON M, LEUNIG M, GANZ R.** Computer-assisted femoral head reduction osteotomies: an approach for anatomic reconstruction of severely deformed Legg-Calvé-Perthes hips. A pilot study of six patients. *BMC Musculoskelet Disord.* 2020;21(1):1–9.
- 29. Bauer AS, Storelli DAR, Sibbel SE, McCarroll HR, Lattanza LL.** Preoperative computer simulation and patient-specific guides are safe and effective to correct forearm deformity in children. *J Pediatr Orthop* 2017;37:504–510.
- 30. Byrne AM, Impelmans B, Bertrand V, Van Haver A, Verstreken F.** Corrective osteotomy for malunited diaphyseal forearm fractures using preoperative 3-dimensional planning and patient-specific surgical guides and implants. *J Hand Surg Am* 2017;42:836.e1–836.e12.
- 31. Kataoka T, Oka K, Murase T.** Rotational corrective osteotomy for malunited distal diaphyseal radius fractures in children and adolescents. *J Hand Surg Am* 2018;43:286.e1–286.e8.
- 32. Inge S, Brouwers L, van der Heijden F, Bemelman M.** 3D printing for corrective osteotomy of malunited distal radius fractures: a low-cost workflow. *BMJ Case Rep* 2018;2018:1–5.
- 33. Jeuken RM, Hendrickx RPM, Schotanus MGM, Jansen EJ.** Near-anatomical correction using a CT-guided technique of a forearm malunion in a 15-year-old girl: a case report including surgical technique. *Orthop Traumatol Surg Res* 2017;103:783–790.
- 34. de Wouters S, Tran Duy K, Docquier PL.** Patient-specific instruments for surgical resection of painful tarsal coalition in adolescents. *Orthop Traumatol Surg Res* 2014;100:423–427.
- 35. Tricot M, Duy KT, Docquier PL.** 3D-corrective osteotomy using surgical guides for posttraumatic distal humeral deformity. *Acta Orthop Belg* 2012;78:538–542.
- 36. Zhang YZ, Lu S, Chen B, Zhao JM, Liu R, Pei GX.** Application of computer-aided design osteotomy template for treatment of cubitus varus deformity in teenagers: a pilot study. *J Shoulder Elbow Surg* 2011;20:51–56.
- 37. Zhang YW, Xiao X, Gao WC, et al.** Efficacy evaluation of three-dimensional printing assisted osteotomy guide plate in accurate osteotomy of adolescent cubitus varus deformity. *J Orthop Surg Res* 2019;14:1–9.
- 38. Oka K, Murase T, Okada K, Tanaka H, Yoshikawa H.** Single-plane rotational osteotomy for cubitus varus deformity based on preoperative computer simulation. *J Orthop Sci* 2019;24:945–951.
- 39. Starosolski ZA, Kan JH, Rosenfeld SD, Krishnamurthy R, Annapragada A.** Application of 3-D printing (rapid prototyping) for creating physical models of pediatric orthopedic disorders. *Pediatr Radiol* 2014;44:216–221.
- 40. Caffrey JP, Jeffords ME, Farnsworth CL, Bomar JD, Upasani VV.** Comparison of 3 pediatric pelvic osteotomies for acetabular dysplasia using patient-specific 3D-printed models. *J Pediatr Orthop* 2019;39:e159–e164.
- 41. Kim HT, Ahn TY, Jang JH, Kim KH, Lee SJ, Jung DY.** A graphic overlay method for selection of osteotomy site in chronic radial head dislocation: an evaluation of 3D-printed bone models. *J Pediatr Orthop* 2017;37:e88–e95.
- 42. Lee CS, Larsen CG, Marchwiany DA, Chudik SC.** Extra-articular, intraepiphyseal drilling for osteochondritis dissecans of the knee: characterization of a safe and reproducible surgical approach. *Orthop J Sports Med* 2019;7:2325967119830397.
- 43. Ganesan B, Yip J, Al-Jumaily A, et al.** A novel 3D evaluation method for assessing bone to bone relationships in clubfoot. *Eur Rev Med Pharmacol Sci* 2019;23:1882–1890.
- 44. Ballard J, Crawford D.** The use of 3D printing in paediatric orthopaedics for pre-operative planning and bespoke therapeutics. *J Trauma Orthop* 2016;4:26–27.
- 45. Docquier PL, Paul L, TranDuy K.** Surgical navigation in paediatric orthopaedics. *EFORT Open Rev* 2017;1:152–159.
- 46. Ackermann J, Ganz R, Fuernstahl.** A new treatment approach for severe Legg-Calvé-Perthes deformity based on computer simulation and surgical navigation. 2018;6–9. <https://www.zora.uzh.ch/> (date last accessed 11 July 2020).
- 47. Morgan C, Khatri C, Hanna SA, Ashrafian H, Sarraf KM.** Use of three-dimensional printing in preoperative planning in orthopaedic trauma surgery: a systematic review and meta-analysis. *World J Orthop* 2020;11:57–67.
- 48. Tack P, Victor J, Gemmel P, Annemans L.** 3D-printing techniques in a medical setting: a systematic literature review. *Biomed Eng Online* 2016;15:115.
- 49. Miyake J, Murase T, Oka K, Moritomo H, Sugamoto K, Yoshikawa H.** Computer-assisted corrective osteotomy for malunited diaphyseal forearm fractures. *J Bone Joint Surg Am* 2012;94:e150.
- 50. Martelli N, Serrano C, van den Brink H, et al.** Advantages and disadvantages of 3-dimensional printing in surgery: a systematic review. *Surgery* 2016;159:1485–1500.
- 51. Biswas D, Bible JE, Bohan M, Simpson AK, Whang PG, Grauer JN.** Radiation exposure from musculoskeletal computerized tomographic scans. *J Bone Joint Surg Am* 2009;91:1882–1889.

- 52. Parthasarathy J, Krishnamurthy R, Ostendorf A, Shinoka T, Krishnamurthy R.** 3D printing with MRI in pediatric applications. *J Magn Reson Imaging* 2020;51:1641–1658.
- 53. Brenner D, Elliston C, Hall E, Berdon W.** Estimated risks of radiation-induced fatal cancer from pediatric CT. *AJR Am J Roentgenol* 2001;176:289–296.
- 54. Kalifa G, Charpak Y, Maccia C, et al.** Evaluation of a new low-dose digital x-ray device: first dosimetric and clinical results in children. *Pediatr Radiol* 1998;28:557–561.
- 55. Gheno R, Nectoux E, Herbaux B, et al.** Three-dimensional measurements of the lower extremity in children and adolescents using a low-dose biplanar X-ray device. *Eur Radiol* 2012;22:765–771.
- 56. Illés T, Somoskeöy S.** The EOS™ imaging system and its uses in daily orthopaedic practice. *Int Orthop* 2012;36:1325–1331.
- 57. Iobst CA.** New technologies in pediatric deformity correction. *Orthop Clin North Am* 2019;50:77–85.
- 58. Tanaka KS, Lightdale-Miric N.** Advances in 3D-printed pediatric prostheses for upper extremity differences. *J Bone Joint Surg Am* 2016;98:1320–1326.
- 59. Alluri R, Jakus A, Bougioukli S, et al.** 3D printed hyperelastic ‘bone’ scaffolds and regional gene therapy: a novel approach to bone healing. *J Biomed Mater Res A* 2018;106:1104–1110.
- 60. Ozbolat IT, Yu Y.** Bioprinting toward organ fabrication: challenges and future trends. *IEEE Trans Biomed Eng* 2013;60:691–699.
- 61. Binder KW.** In situ bioprinting of the skin. *Wake For Univ Grad Sch Arts Sci* 2011;452. <http://hdl.handle.net/10339/33425> (date last accessed 11 July 2020).
- 62. Popov A, Malferrari S, Kalaskar DM.** 3D bioprinting for musculoskeletal applications. *J 3D Print Med* 2017;1:191–211.