

Henry Ford Health

## Henry Ford Health Scholarly Commons

---

Dermatology Articles

Dermatology

---

3-3-2021

### Cold and COVID: Recurrent Pernio during the COVID-19 Pandemic

E E. Freeman

D E. McMahon

J B. Lipoff

M Rosenbach

S Desai

*See next page for additional authors*

Follow this and additional works at: [https://scholarlycommons.henryford.com/dermatology\\_articles](https://scholarlycommons.henryford.com/dermatology_articles)

---

#### Recommended Citation

Freeman EE, McMahon DE, Lipoff JB, Rosenbach M, Desai SR, Fassett M, French LE, Lim HW, Hruza GJ, and Fox LP. Cold and COVID: Recurrent Pernio during the COVID-19 Pandemic. Br J Dermatol 2021.

This Article is brought to you for free and open access by the Dermatology at Henry Ford Health Scholarly Commons. It has been accepted for inclusion in Dermatology Articles by an authorized administrator of Henry Ford Health Scholarly Commons.

---

**Authors**

E E. Freeman, D E. McMahon, J B. Lipoff, M Rosenbach, S Desai, M Fassett, L E. French, Henry W. Lim, G J. Hruza, and L P. Fox

# Research letter

## Cold and COVID: recurrent pernio during the COVID-19 pandemic

DOI: 10.1111/bjd.19894

DEAR EDITOR, Pernio is a commonly reported cutaneous manifestation of severe acute respiratory syndrome coronavirus 2 (SARS-CoV-2) infection.<sup>1</sup> Our international registry of COVID-

19 dermatological manifestations has collected 1176 total cases of COVID-19 skin manifestations, including 619 cases of pernio in patients with suspected or confirmed COVID-19.<sup>1</sup> Most patients with new-onset pernio were entered into the registry after the first pandemic wave (79% in March to May 2020). Starting in September 2020, the registry received reports of a subset of these patients who developed recurrent pernio in the following months. Herein, we present the cases of the first 18

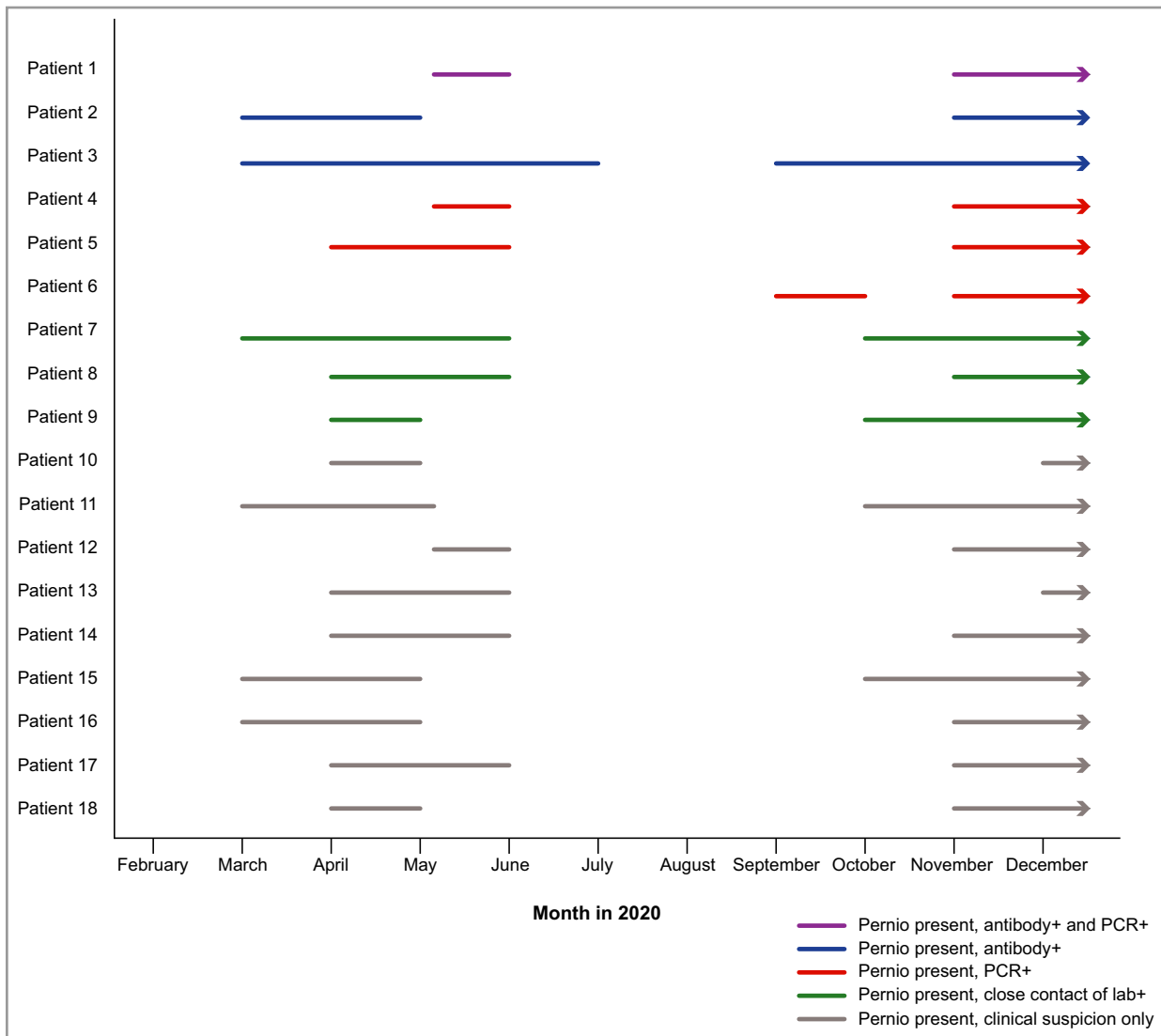


Figure 1 Timeline demonstrating 18 patients who experienced pernio during two discrete timepoints in the setting of laboratory-confirmed or suspected COVID-19 infection during 2020. PCR, polymerase chain reaction; +, positive.

patients with recurrent pernio in the COVID-19 dermatology registry. Patients with a prior pre-pandemic history of pernio were excluded. The registry was reviewed by the Partners Healthcare Institutional Review Board and was determined to not meet the definition of Human Subjects Research.

These patients with recurrent pernio ( $n = 18$ ) had a median age of 22 years [interquartile range (IQR) 16–37], were 72% male, and 83% white. Patients resided in the USA ( $n = 16$ ) [Massachusetts ( $n = 7$ ), California ( $n = 3$ ), Pennsylvania ( $n = 2$ ), New York ( $n = 1$ ), Rhode Island ( $n = 1$ ), Connecticut ( $n = 1$ ) and Michigan ( $n = 1$ )], the Netherlands ( $n = 1$ ) and the UK ( $n = 1$ ). Patients were SARS-CoV-2 polymerase chain reaction (PCR) and antibody positive (6%), antibody-positive only (11%), PCR-positive only (17%), close contacts of a laboratory-confirmed case (17%) or clinically suspected only (50%).

Of note, patient 2 was SARS-CoV-2 antibody-positive 5 weeks after initial pernio lesions started, but tested negative twice for SARS-CoV-2 PCR including a few days after both initial pernio and recurrent pernio symptoms began. Conversely, patient 4 tested PCR positive for SARS-CoV-2 shortly after COVID-19 symptoms of anosmia, dysgeusia and myalgia began, but when antibody testing became available several months later, tested antibody negative. These cases highlight the importance of the timing of testing, and also highlight how patients even with documented prior COVID-19 may test negative on commercial antibody tests.




Overall, 17 of 18 patients initially developed pernio during March to May 2020, the first wave of the COVID-19 pandemic in the USA and Europe (northern hemisphere spring). The pernio resolved in May–July and recurred between September and December 2020 in autumn/winter (Figure 1). The exception (patient 6) was symptomatic with PCR-confirmed COVID-19 in August, developed pernio in September that remitted by October, and then recurred in November 2020.

These cases of recurrent pernio suggest that cold temperatures, combined with a history of SARS-CoV-2 infection, may prompt and perpetuate the inflammatory response.<sup>2</sup> Recent data have demonstrated that patients with pernio/chilblains in the setting of acute SARS-CoV-2 infection have high interferon-alpha responses,<sup>2,3</sup> which may allow rapid control of SARS-CoV-2. Furthermore, not only are there similarities between patients with pernio and type I interferonopathies,<sup>3</sup> but cold exposure has also been noted to cause pernio flares in patients with type I interferonopathies.<sup>4</sup> In cases of recurrent pernio, the mechanism is not yet clear. It remains to be seen whether initial SARS-CoV-2 infection primes patients to be more cold sensitive and therefore prone to recurrent pernio, or whether cold temperature itself is triggering some type of secondary interferon-alpha response without a new SARS-CoV-2 infection.<sup>5</sup>

Limitations to this case series include that only one-third of patients had laboratory confirmation of SARS-CoV-2 infection, an effect heightened by lack of SARS-CoV-2 laboratory testing during the first wave and also noted by prior studies.<sup>1,6,7</sup> In patients without laboratory-confirmed disease,

recurrent pernio/chilblains during the pandemic may also be because of an unrelated cause. However, none of these patients experienced pernio pre-pandemic. This finding also highlights the possibility that other cases of recurrent pernio prior to the COVID-19 pandemic could have been triggered by viral infection.

We do not yet know how frequently, and for how long, patients who developed pernio in the setting of the COVID-19 pandemic will experience recurrent symptoms with subsequent cold exposure. Reports have noted ‘long-hauler’ cutaneous manifestations of COVID-19,<sup>8</sup> and it remains to be seen how persistent and/or recurrent post-COVID pernio will be. Future studies on recurrent pernio may enhance our understanding of the role of temperature and interferon, as well as best practices for patient management.

E.E. Freeman <sup>1,2</sup>, D.E. McMahon,<sup>1</sup> J.B. Lipoff <sup>3</sup>, M. Rosenbach,<sup>3</sup> S.R. Desai <sup>4</sup>, M. Fassett,<sup>5</sup> L.E. French,<sup>6,7</sup> H.W. Lim,<sup>8</sup> G.J. Hruza<sup>9</sup> and L.P. Fox<sup>5</sup>

<sup>1</sup>Massachusetts General Hospital, Harvard Medical School, Boston, MA, USA; <sup>2</sup>Mongan Institute, Massachusetts General Hospital, Boston, MA, USA; <sup>3</sup>University of Pennsylvania, Philadelphia, PA, USA; <sup>4</sup>The University of Texas Southwestern Medical Center, Dallas, TX, USA; <sup>5</sup>University of California San Francisco, San Francisco, CA, USA; <sup>6</sup>University Hospital, Munich University of Ludwig Maximilian, Munich, Germany; <sup>7</sup>University of Miami Miller School of Medicine, Miami, FL, USA; <sup>8</sup>Henry Ford Health System, Detroit, MI, USA; and <sup>9</sup>St. Louis University, St. Louis, MO, USA  
Email: efreeman@mgh.harvard.edu

## References

- Freeman EE, McMahon DE, Lipoff JB et al. Pernio-like skin lesions associated with COVID-19: a case series of 318 patients from 8 countries. *J Am Acad Dermatol* 2020; **83**:486–92.
- Magro CM, Mulvey JJ, Laurence J et al. The differing pathophysiologies that underlie COVID-19-associated pernio and thrombotic retiform purpura: a case series. *Br J Dermatol* 2021; **184**:141–50.
- Hubiche T, Cardot-Leccia N, Le Duff F et al. Clinical, laboratory, and interferon-alpha response characteristics of patients with chilblain-like lesions during the COVID-19 pandemic. *JAMA Dermatol* 2021; **157**:202–6.
- Orcesi S, La Piana R, Fazzi E. Aicardi-Goutieres syndrome. *Br Med Bull* 2009; **89**:183–201.
- Zimmermann N, Wolf C, Schwenke R et al. Assessment of clinical response to Janus kinase inhibition in patients with familial chilblain lupus and TREX1 mutation. *JAMA Dermatol* 2019; **155**:342–6.
- Hubiche T, Le Duff F, Chiaverini C, Giordanengo V, Passeron T. Negative SARS-CoV-2 PCR in patients with chilblain-like lesions. *Lancet Infect Dis* 2021; **21**:315–6.
- Freeman EE, McMahon DE, Fox LP. Emerging evidence of the direct association between COVID-19 and chilblains. *JAMA Dermatol* 2021; **157**:238–9.
- McMahon DE, Gallman AE, Hruza GJ et al. Long COVID in the skin: a registry analysis of COVID-19 dermatological duration. *Lancet Infect Dis* 2021; **21**:313–14.

Funding sources: the International League of Dermatological Societies (ILDS) provided grant support to Massachusetts General Hospital for administration and maintenance of the Dermatology COVID-19 registry.

Conflicts of interest: E.E.F., G.J.H., M.R., J.B.L. and L.P.F. are part of the American Academy of Dermatology (AAD) COVID-19 Ad Hoc Task Force. L.E.F. is the President and H.W.L. is a board member of the ILDS. E.E.F. is an author of COVID-19 dermatology for UpToDate.