

Oncology

First report of a primitive neuroectodermal tumor of the bladder in a newborn

L. Orbegoso-Celis^a, R. Bernuy-Guerrero^b, F. Imán-Izquierdo^c, L. Alfaro-Lujan^d,
L. Barreto Espinoza^{a,b}, W. Silva-Caso^{e,f,*}

^a Urology Service, Edgardo Rebagliati Martins Hospital, Lima, Peru

^b Pediatric Surgery, Edgardo Rebagliati Martins Hospital, Lima, Peru

^c Urology Service, Guillermo Almenara Irigoyen Hospital, Lima, Peru

^d Urology Service, José Alfredo Mendoza Olavarria Hospital, Tumbes, Peru

^e Research and Innovation Centre of the Faculty of Health Sciences, Universidad Peruana de Ciencias Aplicadas, Lima, Peru

^f Faculty of Health Sciences, Universidad Tecnológica Del Perú, Lima, Peru



ARTICLE INFO

Keywords:

Primitive neuroectodermal tumor

Bladder

Partial cystectomy

ABSTRACT

Primitive neuroectodermal tumor (PNET) is part of the Ewing sarcoma family of tumors. The present case reports a primitive neuroectodermal tumor (PNET) of rare location in the bladder in a newborn. It was evaluated with prenatal ultrasound and postnatal tomography that revealed a mass in the posterior wall of the bladder.

The patient underwent partial cystectomy with subsequent analysis of the surgical piece removed, the histopathological study indicated a tumor of mesenchymal origin, and immunohistochemical staining confirmed the diagnosis of PNET of the bladder. Satisfactory result and short-term follow-up.

Introduction

Primitive neuroectodermal tumor (PNET) is part of the Ewing sarcoma family of tumors along with Ewing sarcoma of the bone, extra bone, peripheral neuroepithelioma, Askin's tumor and atypical Ewing sarcoma.¹ PNETs are characterized by being among the high malignancy subtypes of the Ewing family of neoplasms, they are aggressive and tend to compromise bone and soft tissue. They can be classified into: PNET of the central nervous system, neuroblastomas and peripheral PNET. Its morphological aspect describes great cellularity, round cells and of small size with predominance of mitotic figures and diffuse necrosis. Confirmation by immunohistochemical studies (IHC) and search for transcripts by retro transcription polymerase chain reaction (RT-PCR)^{1,2} is required. The presence of a primary PNET in the bladder is considered very rare and invasive, and has generally been described in young patients³

The prognosis of these pathologies is determined by their metastatic or localized form. When the tumor is localized, a survival of more than 70% at 5 years is evident and less than 30% if it is in the metastasis stage. Treatment is based on surgery, chemotherapy and radiotherapy with protocols that define standardized management for each stage of the

disease.¹

We report the case of a primitive neuroectodermal tumor located in the urinary bladder in a newborn (RN) with a prenatal study.

Presentation of the case

Male patient 6 days old, product of first gestation, cesarean delivery, with prenatal history of bladder tumor by obstetric ultrasound 7 days before birth. In the postpartum period, the patient presented macroscopic hematuria of an intermittent course with 24 hours of evolution, which is why he was taken to an emergency at the national referral hospital.

The physical examination did not reveal significant findings, in the differentiated examination by systems directed. The pelvic abdomen region did not reveal palpation of the abdominal mass.

Prenatal ultrasound was reviewed with a report that observed solid tumoration in the pediculated volume 4.87 cc fetal bladder cavity, which appeared to be dependent on the bladder floor and vascularity present in the Doppler study. (Fig. 1). These findings were corroborated with postnatal ultrasound and complemented with renal evaluation, which showed no hydronephrosis.

* Corresponding author. Research and Innovation Centre of the Faculty of Health Sciences, Universidad Peruana de Ciencias Aplicadas, Lima, Peru.

E-mail addresses: pcmewsil@upc.edu.pe, gian_will@hotmail.com (W. Silva-Caso).

<https://doi.org/10.1016/j.eucr.2020.101458>

Received 29 June 2020; Received in revised form 14 October 2020; Accepted 16 October 2020

Available online 16 October 2020

2214-4420/© 2020 The Authors.

Published by Elsevier Inc.

This is an open access article under the CC BY-NC-ND license

(<http://creativecommons.org/licenses/by-nc-nd/4.0/>).

Imaging studies were performed with tomography of the abdomen and chest without contrast, showing a heterogeneous intravesical tumor of 27.6×24.7 mm and absence of distant metastases.

With these examinations the patient is scheduled for Urethrocytostomy under anesthesia where a tumor of approximately 2.5 cm in diameter was observed, with a solid appearance on the posterior wall of the bladder, which does not compromise ureteral meatus or bladder neck (Fig. 2).

He was scheduled for bladder surgical exploration showing a pedicled tumor 2.7×2.5 cm in diameter depending on the posterior wall of the bladder, two mamelon-like tumors 0.5 cm in diameter, and a nodular tumor 1×2 cm in size. A partial cystectomy was performed with placement of the bladder size and urethral foley catheter that remained for 12 days (Fig. 3).

The anatomopathological study of the surgical piece reports the presence of a congenital primitive neuroectodermal tumor with exophytic and endophytic growth, involving up to the bladder lamina itself, necrosis in 60%, evident thrombus embolism and compromised surgical edges. Immunohistochemical study with code I18-962 reports positive CD99. The patient received subsequent medical management by the pediatric oncology unit, where he received adjuvant chemotherapy with a favorable response and absence of recurrence at a 3-month follow-up.

Discussion

Reported cases of primitive neuroectodermal tumor in RN are extremely rare. At the moment, a PNET has not been described in newborns with primary location in the urinary bladder. These are fast-growing tumors, and their extravesical involvement in diagnosis is common.⁴

PNET has a very close relationship with Ewing's sarcoma, both pathologies can describe the t (11; 22) (q24; q12) translocation, which is present in approximately 90% of cases, as well as the variant t translocation (21; 22) (q22; q12). In this context, RT-PCR studies allow better characterization of transcripts and broaden the molecular spectrum of Ewing family tumors. In immunohistochemical studies, PNETs are positive for the anti-CD99 antibody, directed against the MIC2 gene product. This immunophenotype is found in more than 90% of cases, a negative result for this marker leads to consider other diagnoses.¹

Our case is described within the PNETs that are classified as peripheral, with 14% of them involving children under 5 years of age.⁵ In relation to the NB, we have not found descriptions of PNET of primary location in the bladder in the scientific literature, however there are reports of up to 13 newborns (younger than 28 days) with congenital peripheral PNET in other soft tissues. Due to the aggressive phenotype, the treatment of choice is radical surgical resection plus chemotherapy, leaving aside radiotherapy for children under 2 years of age. Treatment that was performed in our patient.^{1,5}

Despite treatment, the disease has a poor prognosis and most diagnosed newborns do not survive more than 2 years.⁵ This can be explained by the fact that at the time of diagnosis 25% of the patients present metastases, which is related to the inadequate response to chemotherapy and mortality. However, in the evaluation of our patient, both tomographic and at the surgical site, the presence of metastasis was not evidenced, so strict monitoring should be carried out for the early identification of recurrences.

Conclusions

Neonate with a primitive primary neuroectodermal tumor of the

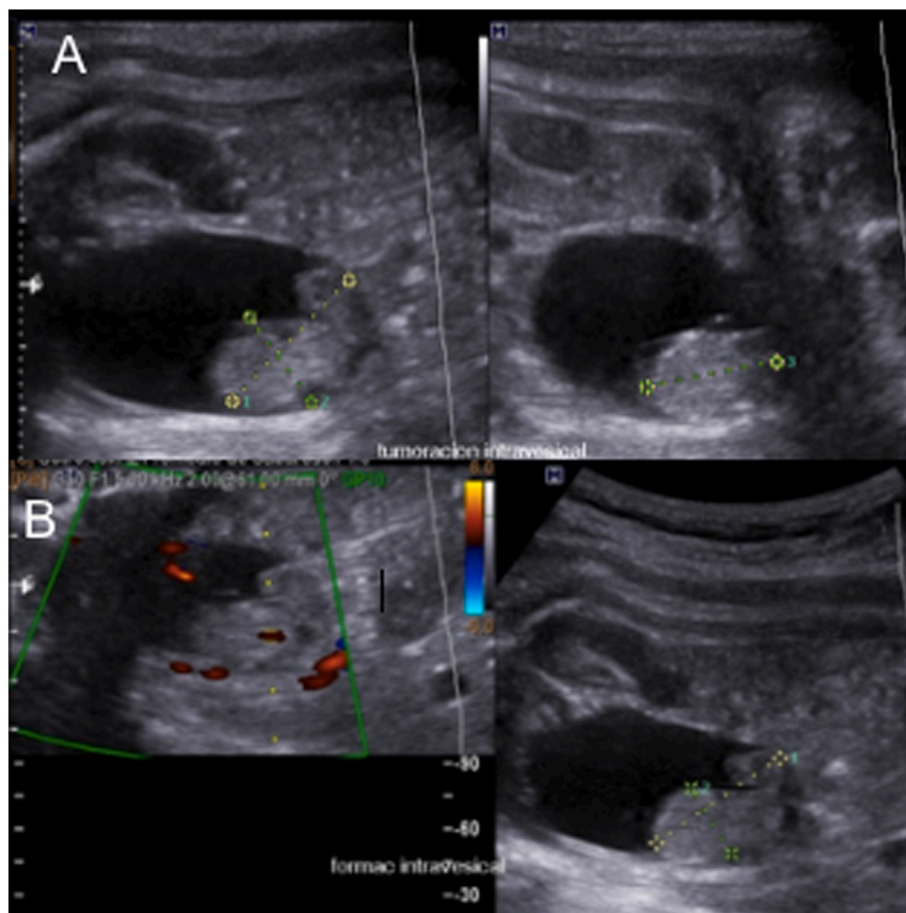


Fig. 1. Pre-natal ultrasound (A) Display a bladder tumor. (B) Vascularized lesion in doppler study.

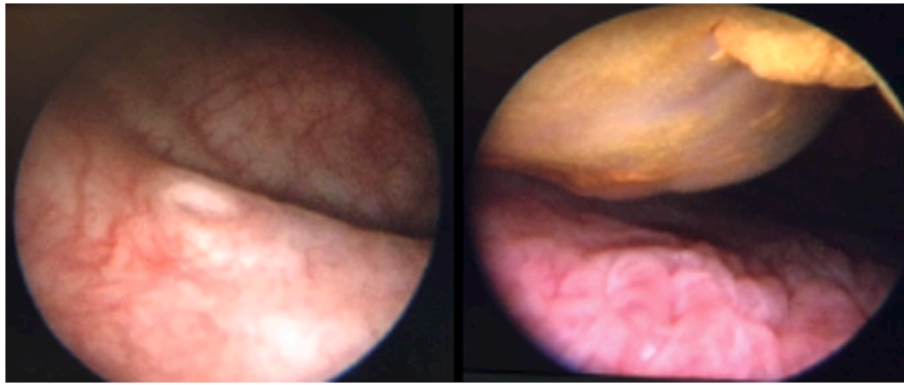


Fig. 2. Urethrocystoscopy evidence solid bladder tumor.

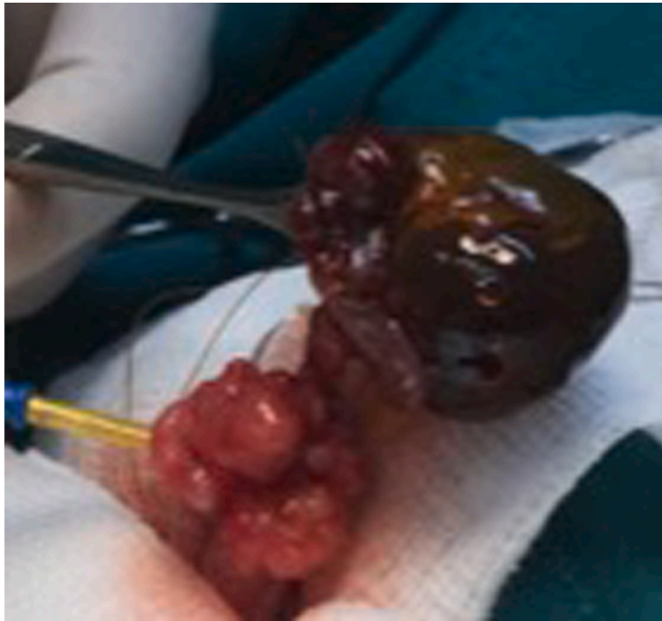

Fig. 3. Multiple mamelonade tumor observed during bladder opening.

urinary bladder with a favorable prognosis due to a 3-month follow-up without recurrences. A longer follow-up time is required to determine a true oncological response.

Consent

Informed consent for publication of clinical details and images was

obtained from the child's parents.

Funding

This research did not receive any specific grant from funding agencies in the public, commercial, or not-for-profit sectors.

CRedit author statement

Orbegoso Luis: Investigation, Conceptualization, Methodology, Writing- Original draft preparation. Bernuy Roxana: Investigation, Investigation, Writing- Original draft preparation. Imán Fernando: Visualization, Investigation, Writing- Original draft preparation. Alfaro Segundo: Investigation, Writing- Original draft preparation. Barreto Luis: Investigation, Writing- Original draft preparation. Silva Wilmer: Investigation, Writing- Reviewing and Editing.

References

1. Renard C, Ranchère-Vince D. Tumeurs de la famille Ewing/PNET : vers un nouveau paradigme ? [Ewing/PNET sarcoma family of tumors: towards a new paradigm?]. *Ann Pathol*. 2015 Jan;35(1):86–97. French.
2. Bernstein M, Kovar H, Paulussen M, et al. Ewing's sarcoma family of tumors: current management. *Oncol*. 2006;11:503–519.
3. Lopez-Beltran A, Pérez-Seoane C, Montironi R, Hernández-Iglesias T, Mackintosh C, de Alava E. Primary primitive neuroectodermal tumour of the urinary bladder: a clinico-pathological study emphasising immunohistochemical, ultrastructural and molecular analyses. *J Clin Pathol*. 2006;59:775–778.
4. Kruger S, Schmidt H, Kausch I, et al. Primitive neuroectodermal tumor (PNET) of the urinary bladder. *Pathol Res Pract*. 2003;199(11):751–754.
5. Jin SG, Jiang XP, Zhong L. Congenital Ewing's sarcoma/peripheral primitive neuroectodermal tumor: a case report and review of the literature. *Pediatr Neonatol*. 2016 Oct;57(5):436–439.