



ELSEVIER

Contents lists available at [ScienceDirect](https://www.sciencedirect.com)

# Trauma Case Reports

journal homepage: [www.elsevier.com/locate/tcr](http://www.elsevier.com/locate/tcr)

## Case Report

# Bilateral neglected posterior dislocation of the shoulder treated by reverse arthroplasty and contralateral osteochondral autograft. A case report

Beatrice Zanini <sup>a,b,\*</sup>, Mattia Rusconi <sup>a,b</sup>, Paolo Fornara <sup>a</sup>, Federico Alberto Grassi <sup>a,b</sup>

<sup>a</sup> Orthopaedic and Trauma Unit, Hospital "Maggiore della Carità", Novara, Italy

<sup>b</sup> Department of Health Sciences, University of East Piedmont, Novara, Italy

## ARTICLE INFO

### Keywords:

Posterior shoulder dislocation  
Neglected dislocation  
Bilateral  
Reverse shoulder arthroplasty  
Osteochondral autograft  
Reverse Hill-Sachs

## ABSTRACT

Bilateral posterior dislocation of the glenohumeral joint is an uncommon event, that can be missed at the initial presentation. We report the case of a 76-year old woman, who suffered a traumatic bilateral posterior dislocation, that was diagnosed three months later. She underwent surgical treatment on both shoulders in a single stage. Since the right shoulder showed a defect of the articular surface >50%, a reverse shoulder arthroplasty was performed on this side. The resected portion of the humeral head was retrieved and used as osteochondral graft to fill the reverse Hill-Sachs lesion of the left shoulder.

At 18-month follow up, the patient was pain-free and had recovered excellent shoulder function on both sides: Constant score was 79 for the right shoulder and 88 for the left one. X-rays showed a grade 1 scapular notch of the right reverse prosthesis and good incorporation of the graft in the left shoulder, with no evidence of degenerative joint changes.

Neglected posterior dislocations of the shoulder can be surgically treated by replacement or reconstruction. In case of bilateral injuries, the surgeon should carefully evaluate the pathoanatomy of both glenohumeral joints in order to choose and plan the most suitable procedure. If shoulder replacement is required on one side, the resected portion of the humeral head can be used as osteochondral autograft for a reconstruction procedure in the opposite side. The choice is influenced by several variables and decision-making might be challenging.

## Introduction

Posterior shoulder dislocation (PSD) is an uncommon injury, accounting for less than 5% of all glenohumeral dislocations [1]. Bilateral PSD is a much rarer event, that mainly occurs for uncontrolled muscular contractions during seizures or electric shocks [2]. It may also occur with major traumas, if an axial force is applied to the shoulders in a flexed, adducted and internally rotated position.

The diagnosis of a PSD is often missed at the initial evaluation due to inadequate clinical and radiographic assessment [3]. The risks posed by delays in diagnosis include irreducibility of the dislocation by closed maneuvers, shoulder stiffness, humeral head avascular necrosis and collapse, post-traumatic arthritis and muscle wasting [4]. In neglected PSDs, pathoanatomy worsens over time and failure to address the injury in a timely manner jeopardizes functional recovery of the shoulder.

\* Corresponding author.

E-mail address: [20027457@studenti.uniupo.it](mailto:20027457@studenti.uniupo.it) (B. Zanini).

<https://doi.org/10.1016/j.tcr.2021.100455>

Accepted 8 March 2021

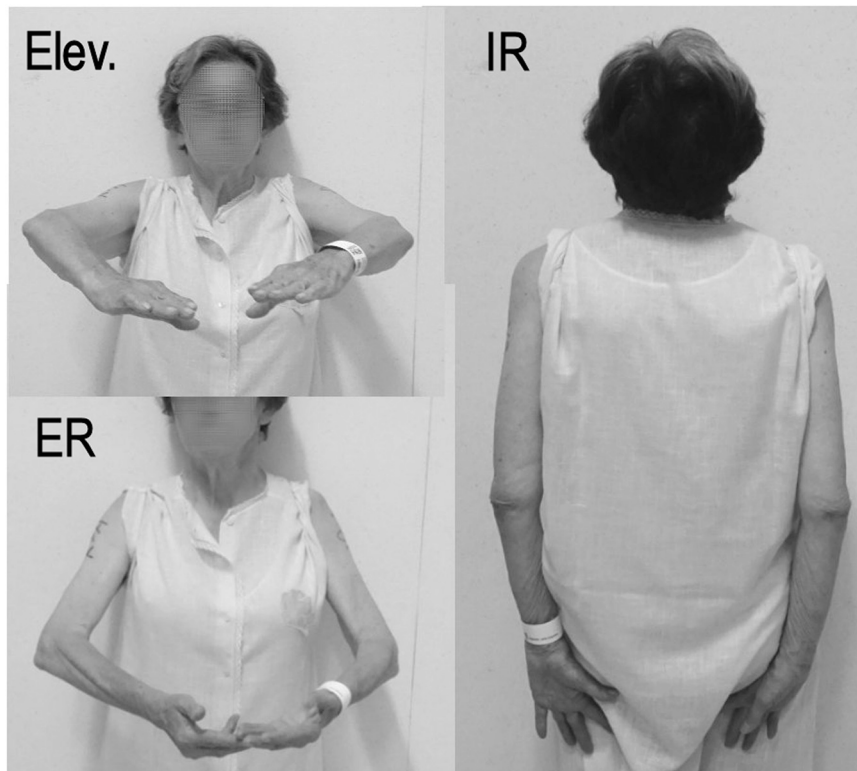
Available online 11 March 2021

2352-6440/© 2021 The Authors. Published by Elsevier Ltd. This is an open access article under the CC BY-NC-ND license

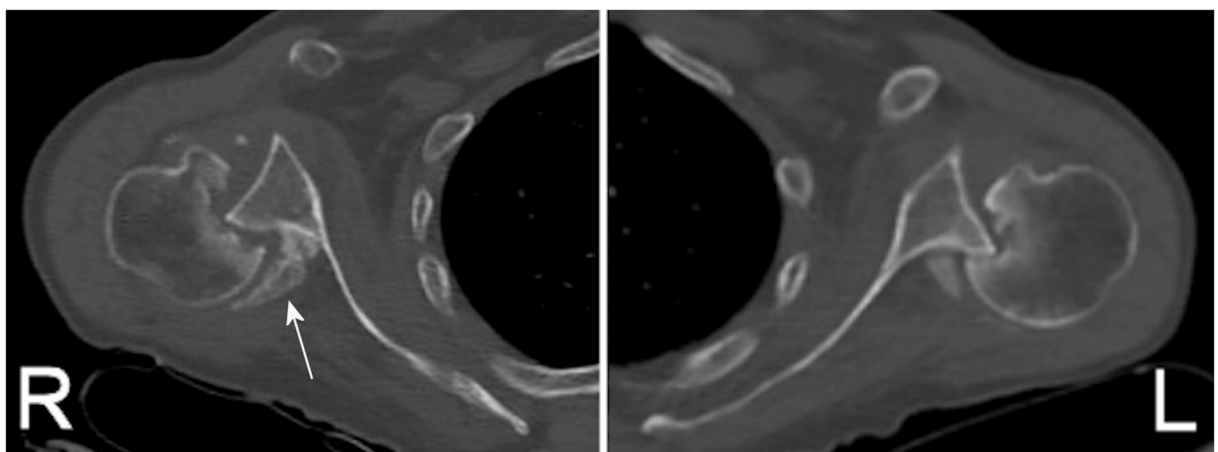
(<http://creativecommons.org/licenses/by-nc-nd/4.0/>).

The treatment of chronic PSDs is influenced by the damage of the articular humeral surface (size of the reverse Hill-Sachs lesion), the duration of the dislocation, the condition of the glenoid and the rotator cuff, the age and general conditions of the patient [3].

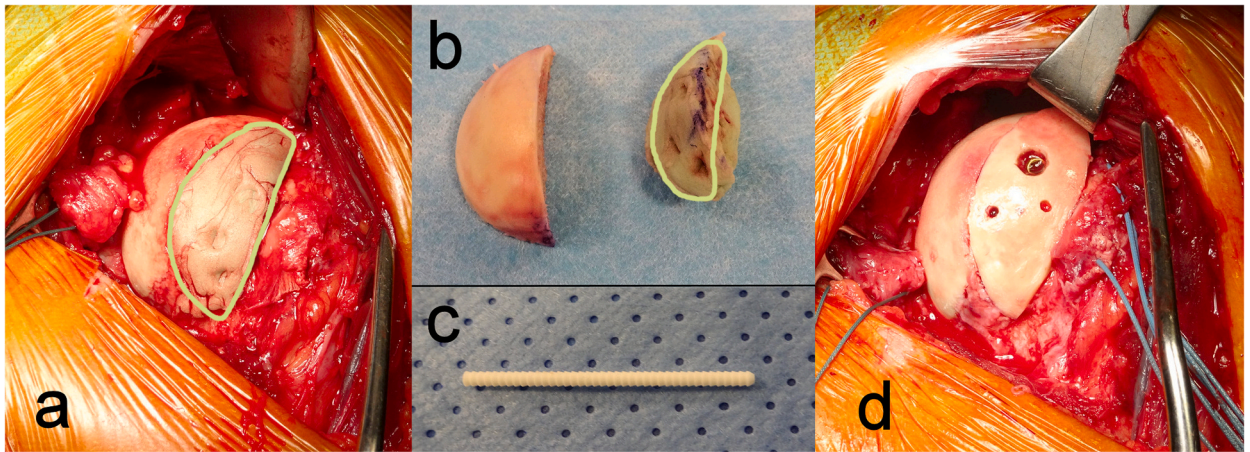
Surgical treatment of neglected PSD ranges from simple open reduction with postoperative immobilization to shoulder replacement. We report the case of a 76-year old woman who sustained a bilateral traumatic PSD, that was diagnosed three months later. Surgical treatment consisted in reverse shoulder arthroplasty for the right shoulder and osteochondral autograft reconstruction of the humeral head for the right shoulder.



**Fig. 1.** Patient's active ROM before treatment: forward elevation (elev.), external rotation (ER) and internal rotation (IR).



**Fig. 2.** Axial CT scans showing the reverse Hill-Sachs lesion in the right (R) and left (L) shoulder (see text for details). The arrow indicates the newly-formed bone shelf (neoglenoid), that appeared on the posterior aspect of the right scapular neck due to the long-standing dislocation. A similar finding is also visible in the left shoulder.

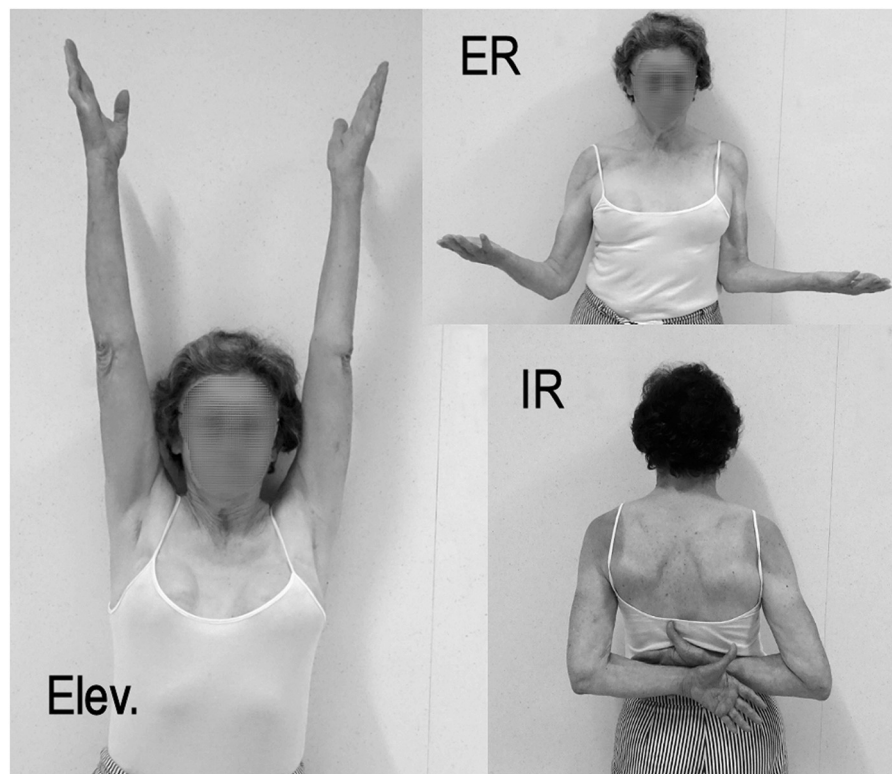


**Fig. 3.** Intraoperative pictures of the reconstruction procedure performed on the left shoulder: a) the mold of the humeral head defect made with bone cement (the edge is marked with the green line); b) comparison between the mold and the osteochondral graft retrieved from the right humeral head; c) the 2-mm resorbable pin used for graft fixation; d) final appearance of the osteochondral graft after implantation: the big hole corresponds to the 4-mm cannulated screw and the two small holes are the entry points of the resorbable pins.

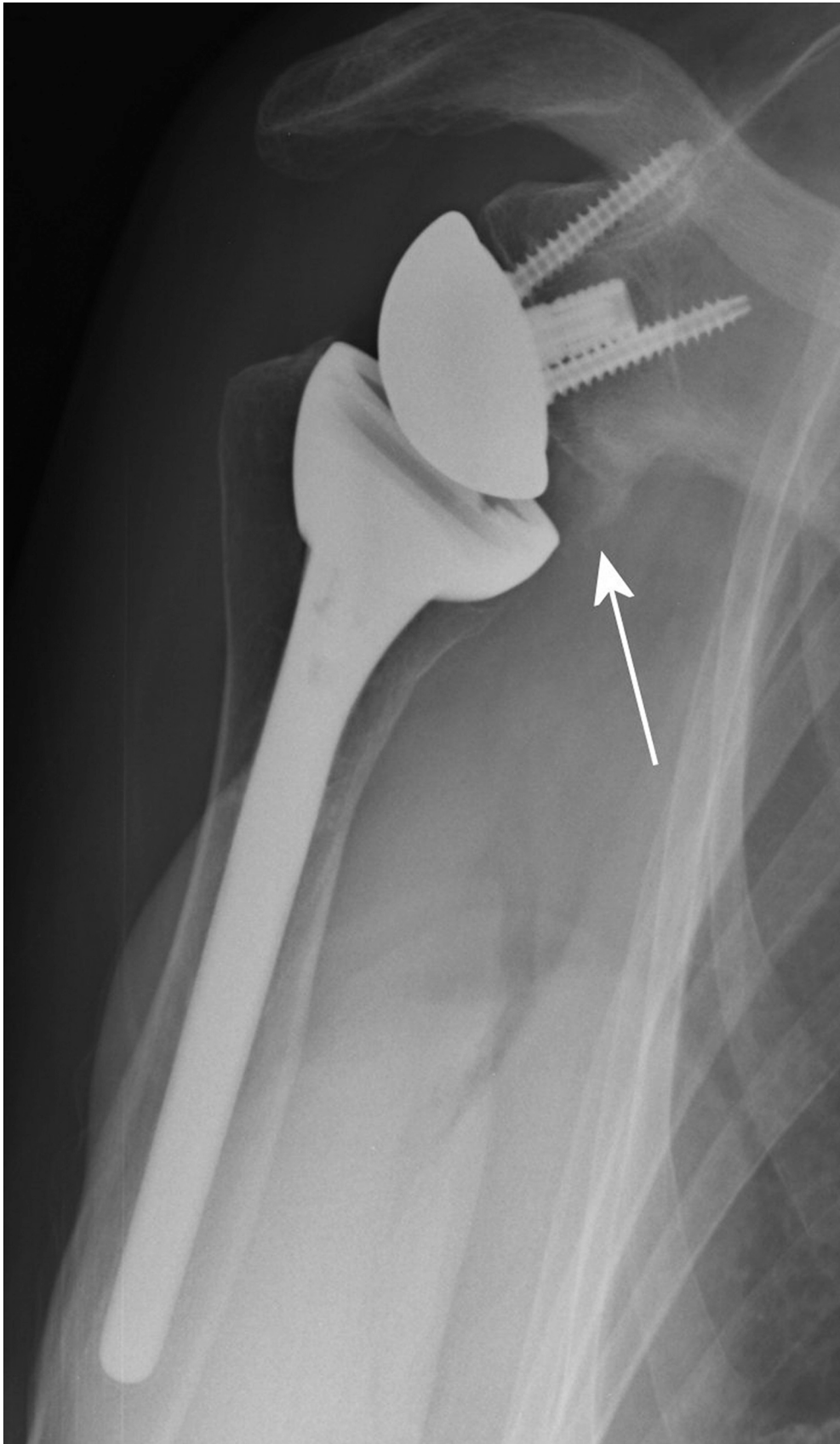
### Case presentation

We present the case of a 76-year old woman in good health status, who sustained a bilateral PSD after a fall from a height of about 2 m. She was admitted to the emergency room, where the injury was not recognized after a single A-P view of both shoulders. Functional rest for few days and gradual shoulder mobilization were recommended.

Since pain and functional impairment did not improve with time, the patient was referred to our hospital for a second evaluation three months after the traumatic event. Clinical examination showed poor active and passive ROM in both shoulders: elevation did not reach 90°, external rotation was  $-45^\circ$  and internal rotation was at the sacrum (Fig. 1). The Constant score was 18 bilaterally. The



**Fig. 4.** Patient's active ROM 18 months after surgery: forward elevation (elev.), external rotation (ER) and internal rotation (IR).



**Fig. 5.** Radiographic examination of the right shoulder at 18 months that shows a grade 1 scapular notching of the RSA and a small inferior osteophyte of the glenoid (arrow).

humeral heads were palpable posteriorly, but no peripheral neurovascular deficit was present.

A true A-P view of the shoulders was strongly suggestive for bilateral PSD. Therefore, a CT scan was performed to better define the pathoanatomy and plan treatment (Fig. 2). The right shoulder showed a reverse Hill-Sachs lesion involving more than 40% of the articular surface; the glenoid was not damaged, but a neoglenoid had appeared on the posterior aspect of the scapular neck due to the long-standing dislocation. A reverse Hill-Sachs lesion was present also in the left shoulder, but involved less than 25% of the articular surface of the humeral head.

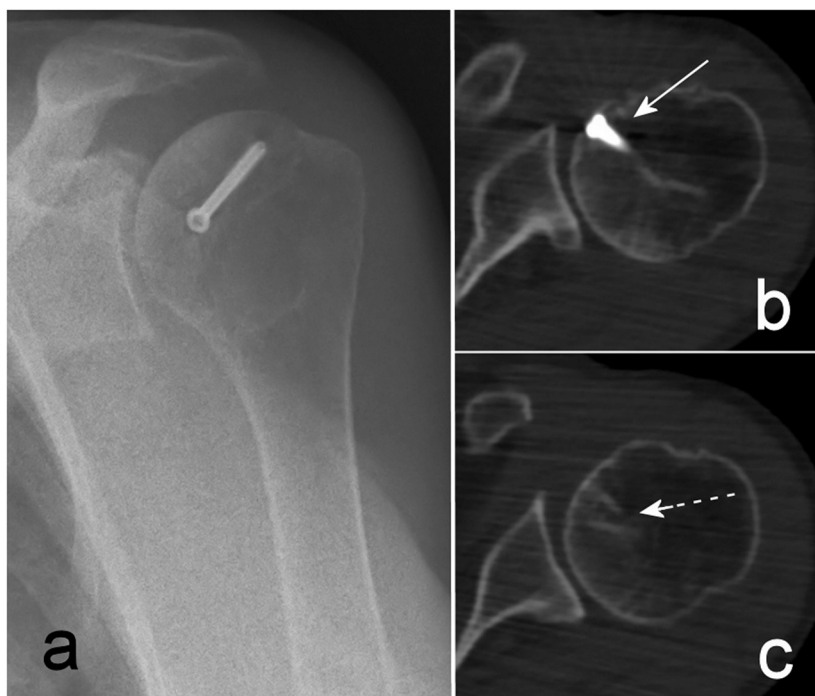Since closed reduction of the chronic PSDs was unlikely, surgical treatment was proposed to the patient in order to treat both shoulder in one stage. Age, general condition, functional requests, duration of dislocation and pathoanatomy were carefully evaluated in planning surgery. A reverse shoulder arthroplasty was considered the best choice for the right shoulder, while a reconstruction procedure seemed practicable for the left shoulder. If a sufficient portion of the right humeral head was preserved, it could be retrieved and used as an osteochondral graft to fill the bone defect of the left humeral head. The potential benefits and risks of treatment were exposed to the patient, who gave her informed consent to the planned procedure.

In the operating room, the patient was placed in the beach-chair position; a traditional delto-pectoral approach was used for both shoulders.

The right shoulder was treated first. The subscapularis was detached from the lesser tuberosity to gain access to the glenohumeral space and reduce the posterior dislocation. After reduction, the joint was highly unstable because of the extensive loss of the articular surface of the humeral head. The residual portion of the humeral head was resected and preserved as potential osteochondral autograft for the left shoulder. Considering the patient's age and the degenerative changes of the rotator cuff, a reverse shoulder prosthesis was eventually implanted.

In the left shoulder, a vertical tenotomy of the subscapularis was performed to expose the glenohumeral space and reduce the dislocation. The reverse Hill-Sachs lesion was debrided in order to outline the cartilaginous edges and expose bleeding cancellous bone on the walls. A mold of the bone defect was made with bone cement to help in shaping the osteochondral graft retrieved from the right humeral head (Fig. 3). Once a perfect match between the defect and the graft was achieved, the graft was fixed with one 4.0 mm cannulated screw and two 2.0 mm resorbable pins. The subscapularis tendon was repaired with an end-to-end suture.

In the postoperative period, the upper limbs were kept in a sling for comfort. Active mobilization of both shoulders for light daily activities was started immediately. After one month, gradual recovery of full ROM and strengthening exercises were allowed. Clinical and radiographic examinations were scheduled every three months: a progressive improvement of shoulder function was observed.



**Fig. 6.** Imaging of the left shoulder at 18 months: a) true A-P view showing the absence of degenerative joint changes; b) axial CT scan at the level of the 4-mm screw (arrow), that does not protrude above the articular surface; the graft is incorporated in the humeral head; c) another CT scan image showing the remnants of the resorbable 2-mm pins (dotted arrow).

At 18-month follow up, the patient was pain-free and had recovered full active ROM in both shoulders (Fig. 4): elevation was 170°, external rotation was 45° in the right and 60° in the left shoulder, internal rotation to T10. The Constant score was 79 for the right shoulder and 88 for the left one. Radiograms showed a grade 1 notching of the reverse prosthesis (Fig. 5) and good incorporation of the graft in the left shoulder, with no evidence of degenerative joint changes of the glenohumeral joint (Fig. 6).

## Discussion

Bilateral PSD is a very rare and frequently misdiagnosed injury. Neglected PSDs can lead to severe anatomic changes of the glenohumeral joint, with loss of shoulder function and pain. Moreover, treatment is more demanding when performed on a shoulder with a long-standing PSD.

Treatment of chronic PSD is influenced by several variables, but the most important one is the size of the reverse Hill-Sachs lesion, particularly when >20% of the articular surface is lost. A reconstruction procedure is generally indicated if the bone defect involves 20–40% of the humeral head, while shoulder replacement is preferred in case of larger defects or in more complex fracture patterns [5,6].

There are different options for both procedures and the surgeon should evaluate carefully every single case in order to choose and plan the best treatment.

Reconstruction procedures include the McLaughlin operation and its modifications, elevation of the bone defect or anatomic reconstruction with autografts or allografts, humeral rotational osteotomy and posterior glenoid bone blocks [7]. In case of bilateral PSD, the surgeon should consider the possibility of combining a shoulder replacement in one shoulder with a reconstruction procedure in the other one. An osteochondral autograft can be harvested from the resected humeral head and used to fill the reverse Hill-Sachs of the contralateral side. The choice between hemiarthroplasty and reverse shoulder arthroplasty is mainly influenced by the patient's age and the condition of the rotator cuff. It might be advisable to have both options available in the operating room when preoperative examinations are not conclusive for a definite decision.

All the studies published in literature on bilateral PSD are case reports or small case series. We could find only five cases of shoulder replacement combined with contralateral osteochondral humeral autograft [8–11]: four patients were treated with hemiarthroplasty and only one patient with a reverse prosthesis. All these patients were male and suffered epileptic seizures, so this is the first report of this procedure for a chronic bilateral PSD due to trauma.

The osteogenic and osteoinductive properties are relevant advantages for using an osteochondral autograft instead of an allograft for the reconstruction of a reverse Hill-Sachs lesion. Bilateral PSD offers this option for reconstruction, when shoulder replacement is indicated in one side. Therefore, graft harvesting should always be considered in planning surgery.

The osteochondral autograft must be carefully shaped before implantation in order to achieve a perfect match to the humeral head defect. A mold of the defect can be made with bone cement or other malleable material, and is effective for this purpose. Graft fixation can be accomplished with different techniques, but it is critical to avoid any hardware protrusion from the articular surface.

The results achieved in our patient are in line with the outcomes reported by other authors: the reconstruction procedure with an osteochondral autograft is more effective than arthroplasty in restoring shoulder function.

This case report shows how a severe injury can be successfully treated when an accurate evaluation of the pathoanatomy is carried out on both shoulders. The clinical and functional outcome was excellent and there are all the prerogatives to predict that it will last over time. However, there are other variables that influence the final outcome, such as patient's compliance with treatment and surgeon's experience, and decision-making might be challenging.

## References

- [1] C.M. Robinson, J. Aderinto, Posterior shoulder dislocations and fracture-dislocations, *J. Bone Joint Surg. Am.* 87 (3) (2005) 639–650.
- [2] M.R.K. Karpinski, K.M. Porter, Bilateral posterior dislocation of the shoulder, *Injury* 15 (4) (1984) 274–276.
- [3] W. Xu, L.X. Huang, J.J. Guo, D.H. Jiang, Y. Zhang, H.L. Yang, Neglected posterior dislocation of the shoulder: a systematic literature review, *J. Orthop. Transl.* 3 (2) (2015) 89–94.
- [4] M.S. Kowalsky, W.N. Levine, Traumatic posterior glenohumeral dislocation: classification, pathoanatomy, diagnosis, and treatment, *Orthop. Clin. North Am.* 39 (4) (2008) 519–533 (viii).
- [5] R.J. Hawkins, C.S. Neer, R.M. Pianta, Mendoza FX (1987) Locked posterior dislocation of the shoulder, *J. Bone Joint Surg. Am.* 69 (1) (1987) 9–18.
- [6] S.L. Checchia, P.D. Santos, A.N. Miyazaki, Surgical treatment of acute and chronic posterior fracture-dislocation of the shoulder, *J. Shoulder Elb. Surg.* 7 (1) (1998) 53–65.
- [7] O. Basal, R. Dincer, B. Turk, Locked posterior dislocation of the shoulder: a systematic review, *EFORT Open Rev.* 3 (1) (2018) 15–23.
- [8] P.M. Connor, J.R. Boatright, D.F. D'Alessandro, Posterior fracture-dislocation of the shoulder: treatment with acute osteochondral grafting, *J. Shoulder Elb. Surg.* 6 (5) (1997) 480–485.
- [9] A. Ivkovic, I. Boric, N. Cicak, One-stage operation for locked bilateral posterior dislocation of the shoulder, *J. Bone Jt. Surg. Br.* 89 (6) (2007) 825–828.
- [10] C. Torrens, F. Santana, E. Melendo, V. Marlet, E. Caceres, Osteochondral autograft and hemiarthroplasty for bilateral locked posterior dislocation of the shoulder, *Am. J. Orthop. (Belle Mead NJ)* 41 (8) (2012) 362–364.
- [11] H.S. Uppal, P.W. Robinson, I. Packham, M. Crowther, The management of bilateral posterior fracture dislocations of the shoulder: a case series illustrating management options, *Shoulder Elbow* 8 (2) (2016) 111–117.