

UNIVERSITY OF BIRMINGHAM

University of Birmingham
Research at Birmingham

Liver function test abnormalities after traumatic brain injury

Sanfilippo, F.; Veenith, T.; Santonocito, C.; Vrettou, C. S.; Matta, B. F.

DOI:

[10.1093/bja/aet305](https://doi.org/10.1093/bja/aet305)

License:

Other (please provide link to licence statement)

Document Version

Publisher's PDF, also known as Version of record

Citation for published version (Harvard):

Sanfilippo, F, Veenith, T, Santonocito, C, Vrettou, CS & Matta, BF 2014, 'Liver function test abnormalities after traumatic brain injury: is hepato-biliary ultrasound a sensitive diagnostic tool?', *British Journal of Anaesthesia*, vol. 112, no. 2, pp. 298-303. <https://doi.org/10.1093/bja/aet305>

[Link to publication on Research at Birmingham portal](#)

General rights

Unless a licence is specified above, all rights (including copyright and moral rights) in this document are retained by the authors and/or the copyright holders. The express permission of the copyright holder must be obtained for any use of this material other than for purposes permitted by law.

- Users may freely distribute the URL that is used to identify this publication.
- Users may download and/or print one copy of the publication from the University of Birmingham research portal for the purpose of private study or non-commercial research.
- User may use extracts from the document in line with the concept of 'fair dealing' under the Copyright, Designs and Patents Act 1988 (?)
- Users may not further distribute the material nor use it for the purposes of commercial gain.

Where a licence is displayed above, please note the terms and conditions of the licence govern your use of this document.

When citing, please reference the published version.

Take down policy

While the University of Birmingham exercises care and attention in making items available there are rare occasions when an item has been uploaded in error or has been deemed to be commercially or otherwise sensitive.

If you believe that this is the case for this document, please contact UBIRA@lists.bham.ac.uk providing details and we will remove access to the work immediately and investigate.

CRITICAL CARE

Liver function test abnormalities after traumatic brain injury: is hepato-biliary ultrasound a sensitive diagnostic tool?

F. Sanfilippo^{1,2*}, T. Veenith¹, C. Santonocito², C. S. Vrettou¹ and B. F. Matta¹

¹ Neuro-Critical Care Unit, Department of Anaesthesia, Addenbrooke's Hospital, Cambridge University Hospitals NHS Foundation Trust, Hills Road, Cambridge CB2 0QQ, UK

² Oxford Heart Centre, John Radcliffe Hospital, Oxford University Hospitals, Oxford OX3 9DU, UK

* Corresponding author: Oxford Heart Centre, John Radcliffe Hospital, Oxford University Hospitals, Oxford OX3 9DU, UK.

E-mail: filipposanfi@yahoo.it

Editor's key points

- Abnormal liver function test results are common among intensive care unit patients with traumatic brain injury.
- This often occurs in the absence of any pre-existing liver dysfunction.
- Hepato-biliary ultrasound scans are frequently requested to exclude treatable causes.
- The authors assessed the diagnostic yield of scans performed for this reason.

Background. This study was to evaluate the usefulness of hepato-biliary ultrasound (HBUS) for the investigation of isolated liver function tests (LFTs) abnormalities.

Methods. We retrospectively reviewed HBUS reports in traumatic brain injury (TBI) patients admitted to our tertiary neuro-critical care unit (NCCU; January 2005–June 2011). We included patients receiving an HBUS for isolated LFTs derangement, excluding pre-existing hepato-biliary diseases or trauma. We assessed the temporal profile of alanine aminotransferase (ALT), bilirubin (Bil), and alkaline phosphatase (ALP).

Results. Of 511 patients, 58 received an HBUS. Of these, 47 were investigated for isolated LFTs derangement; HBUS always failed to identify a cause for these abnormalities. The HBUS was performed on day 18 (range 6–51) with the following mean values: 246 IU litre⁻¹ [ALT, 95% confidence interval (CI) 183–308], 24 µmol litre⁻¹ (Bil, 95% CI 8–40), and 329 IU litre⁻¹ (ALP, 95% CI 267–390); only ALT (72, 95% CI 36–107) and ALP (73, 95% CI 65–81) were deranged from admission values (both $P < 0.01$). At NCCU discharge, both ALT (160, 95% CI 118–202) and ALP (300, 95% CI 240–360) were higher than at admission ($P < 0.01$). Compared with HBUS-day value, only ALT improved by NCCU discharge ($P < 0.05$), while both were recovering by hospital discharge (ALT 83, 95% CI 59–107; ALP 216, 95% CI 181–251; $P < 0.01$). At hospital discharge, ALP remained higher than at admission ($P < 0.01$).

Conclusions. In TBI patients, HBUS did not appear sensitive in detecting causes for isolated LFT abnormalities. Both ALT and ALP worsened and gradually recovered. Their abnormalities did not prevent NCCU discharge. ALP recovered more slowly than ALT. TBI and its complications, critical illness, and pharmacological strategies may explain the LFTs derangement.

Keywords: critical care; imaging techniques; liver function; ultrasonography

Accepted for publication: 23 June 2013

Patients in intensive care unit (ICU) receive daily blood tests and some abnormal results can be challenging to interpret in the context of deranged physiology and critical illness-induced alteration in pharmacodynamics. Derangement of liver function tests (LFTs) are commonly observed in critically ill patients admitted to ICU;¹ its significance in patients admitted with a primary diagnosis of traumatic brain injury (TBI) and without pre-existing risk factors has not been previously investigated.

A recent study² has shown a prevalence of LFT abnormalities on admission to ICU in up to 61% of the patients without pre-existing hepato-biliary disease (HBD). In critically ill patients, these abnormalities can be attributed to multiple factors, such as hepatic ischaemia,^{3,4} sepsis,⁵ drugs,⁶ and artificial nutrition.⁷ Even though Thomson and colleagues² showed an

association of abnormal LFTs with mortality outcomes and clinical events on ICU, this cannot be extrapolated for patients with TBI. In patients with head injury, additional risk factors for LFT abnormalities include hypotension and splanchnic ischaemia, prolonged use of vasopressors–inotropes to sustain cerebral perfusion, and therapeutic agents such as ranitidine,⁸ paracetamol,⁹ antimicrobials,¹⁰ and phenytoin.^{10,11}

The hepato-biliary ultrasound (HBUS) scan is a safe, non-invasive bedside investigation considered as the first-line investigation to detect an obstructive HBD. While the resolution of HBUS is improving over the past decades, the incidence of false positives has not moved forward.¹² Reported sensitivity and specificity ranges of HBUS in detecting acute calculous cholecystitis are 48–100% and 64–100%, respectively.^{13–15}

Even though maintaining high specificity (93–94%), the sensitivity of HBUS for detecting acalculous cholecystitis is reported in lower figures (29–50%) and ICU population is at high risk of developing this condition.^{16–18}

In a recent study of patients admitted to ICU, almost half (47%) had at least one abnormal HBUS finding, but only one-third of the patients with abnormal bilirubin (Bil) and alkaline phosphatase (ALP) values had an abnormal HBUS.¹⁹

The aim of this study is to evaluate the usefulness of performing HBUS in ICU, and to add data to the growing body of literature of LFTs abnormalities in ICU. To the best of our knowledge, there is no reported data addressing the yield of HBUS in isolated abnormalities in LFTs in patients with TBI.

Methods

This study was performed after institutional audit department approval (Cambridge University Hospital NHS Foundation trust).

This retrospective study included patients admitted with diagnosis of TBI to our neuro-critical care unit (NCCU) in a tertiary level hospital, in the period between January 2005 and June 2011. We included in our analysis only those patients receiving an HBUS for isolated LFTs abnormalities (detected on daily routine investigations) during the NCCU stay. To capture patients with hepato-biliary injury due to critical illness, we excluded patients with suspected or proven hepato-biliary trauma and known chronic liver diseases.

At our institution, all the HBUS scans in ICU or NCCU are performed and reported by a radiologist, and reports are available and accessed through electronic records. The decision to investigate isolated LFTs derangement with HBUS scan was decided by the attending NCCU consultant in charge for the day. Over the period of study, there was no protocol for investigating LFTs abnormalities in our NCCU. Three authors (F.S., T.V., C.S.V.) independently screened each report looking for any abnormal finding, regardless of the relationship with the LFTs derangement.

The daily LFTs profile investigated in our unit includes: alanine aminotransferase (ALT, normal range 0–50 IU litre⁻¹), Bil (normal range 0–17 µmol litre⁻¹), and alkaline phosphatase (ALP, normal range 30–135 IU litre⁻¹).

In the population of study who underwent an HBUS, the temporal change of LFTs was investigated at admission, on the day of HBUS, on discharge from NCCU, and on the day of hospital discharge. We also recorded the peak values of each LFT, length of stay on the day of HBUS, and length of stay on the day of peak liver function abnormalities. In patients receiving more than one HBUS, we decided to consider only the length of stay and the LFTs values recorded on the day of the first HBUS.

To address the question of ‘which LFT triggers a request of HBUS investigation’, a subgroup analysis was performed, arbitrarily considering as triggers for requesting HBUS only values of ALT, Bil, or ALP ≥ 1.5 times their normal upper limit.

Statistical analysis

Statistical analyses were performed using IBM® SPSS® Statistics 17 for windows. The Kolmogorov–Smirnov test, histograms, and normal quartile plots were examined to test for

the normality assumption of continuous variables. Continuous variables are presented as the mean and range or 95% confidence interval (95% CI), and categorical variables as number and percentage (%). The non-parametric Friedman test for related samples was performed for the analysis of the course of the LFTs. A Wilcoxon signed-rank test was then used to detect differences among a couple of samples. All tests were two-sided and a result of $P < 0.05$ was considered statistically significant. All P -values are quoted after the Bonferroni corrections (where appropriate), and corrected P -values of < 0.05 were considered significant.

Results

During the 66 months of this retrospective study, 511 patients were admitted with TBI and 58 of them (11.3%) were investigated with an HBUS (Fig. 1). In this cohort, 47 patients (81, 9.2% of all the TBIs) were included in the study as receiving HBUS for isolated LFTs derangement. One of them received three further HBUS investigations, with a total of 50 HBUSs in the population of study. Eleven patients, with a total of 12 HBUS scans, were excluded from the analysis because of traumatic injury to the liver ($n=4$) or for pre-existing liver diseases ($n=7$, one of them receiving a repeated HBUS). In Table 1 is shown the distribution of the HBUS performed over the period of study.

The mean age of the group analysed was 41 (range 20–73) yr, 64% were male, and the mean APACHE score on admission was 12 (range 3–30). The mean lengths of stay in NCCU and in hospital were, respectively, 29 (range 9–98) and 53 (9–230) days. Forty-five patients were discharged from hospital (95.7%).

The mean day for the HBUS investigation was 18 (range 6–51). Of the 50 HBUS scans investigating isolated LFTs derangement, no one revealed obstructive causes or suggested a rationale for the biochemical abnormality. In eight reports (16%), the radiologist reported that a limited vision was

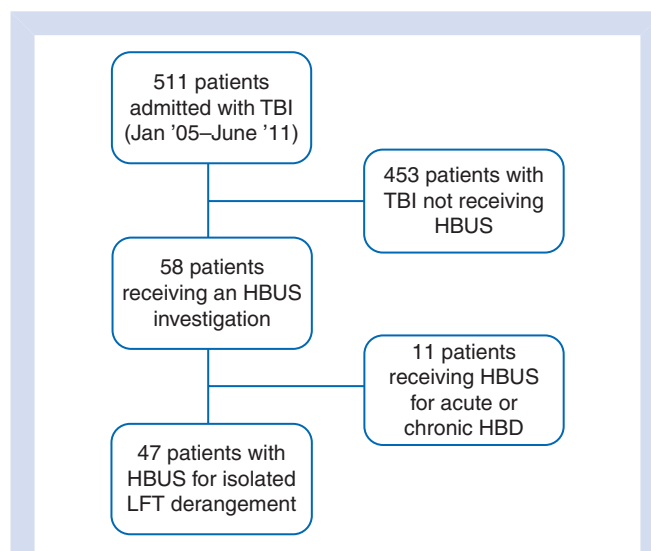


Fig 1 Flowchart of the study. TBI, traumatic brain injury; HBUS, hepato-biliary ultrasound; HBD, hepato-biliary disease.

achieved. This was attributed to ventilation ($n=4$), obesity ($n=3$), or not specified ($n=1$). In total, as positive findings, we found evidence of: 'mild alteration in the liver echo-structure' ($n=5$); 'prominent common biliary duct' ($n=2$); 'mildly thick-wall gallbladder without evidence of stones or sludge' ($n=2$); and 'presence of sludge' ($n=9$). There was one incidental finding of a focal hepatic lesion (a 16 mm haemangioma). The hepato-portal Doppler analysis was reported in 40 of the 50 HBUS scans performed (80%) and there was only one abnormal finding ('mildly hypertrophic hepatic artery').

The course of LFTs values in the study population is shown in Table 2. The mean value of ALT on admission was higher than the normal range (72 IU litre^{-1}), being otherwise normal for Bil and ALP. All the mean LFTs values were deranged on the day of HBUS, but only ALT and ALP maintained abnormal values at NCCU and hospital discharges.

The following mean peak values were recorded: ALT, $400 \text{ IU litre}^{-1}$ (95% CI 301–463); Bil, $32 \mu\text{mol litre}^{-1}$ (95% CI 14–46); ALP, $486 \text{ IU litre}^{-1}$ (95% CI 351–533). On average, the peak results were noted on day 17 (ALT, range 3–35), day 18 (Bil, range 6–29), and day 20 (ALP, range 7–60).

The number of patients with values of ALT, Bil, and ALP ≥ 1.5 the upper normal limit on the HBUS day were $n=39$, $n=5$, and $n=35$, respectively, with a significant predominance of ALT and ALP for requesting HBUS ($P < 0.01$). In only one patient, all three LFTs were above this limit on the day of HBUS. Table 3 shows the details of the different combinations of LFTs derangement on the HBUS day.

The variation of the ALT and ALP profile in the different moments of NCCU or hospital stay is also shown in Figures 2 and 3. The results of the Wilcoxon signed-rank tests for detecting difference among couples are shown in Table 4.

Discussion

To the best of our knowledge, this is the first study looking at usefulness of HBUS for isolated LFTs abnormalities in patients with TBI. These findings are similar to two studies in general intensive care patients that previously have shown a lack of correlation between liver biochemistry and HBUS findings.^{19 20}

In our population of TBI patients, isolated derangement of LFTs was the most common cause for requesting a HBUS and it happened in one out of 11 of the overall population (9.2%). Our analysis suggests that performing an HBUS in this population did not alter management in NCCU and its yield was low in patients with TBI. Moreover, a fair proportion of HBUS achieved only a limited window for visualizing a structural hepato-biliary abnormality (16% in our cohort). This difficulty in achieving a good US view is not surprising, and lower sensitivity and specificity have been previously reported in general ICU populations.^{16 21}

Hepato-biliary US remains a useful non-invasive exam to investigate for an obstructive cause of HBD; we can speculate that its value in our population could have been to exclude the obstructive cause, helping clinician to focus more on other sources of the LFTs derangement, such as drug therapy. However, with the retrospective approach of the present study, it would be hard, if not impossible, to evaluate the impact produced by a negative HBUS on the patient's management.

To investigate the potential trigger for requesting an HBUS, a threshold was arbitrarily set for 1.5 times the upper limit. In our population, ALT and ALP were much more commonly deranged than Bil on the day of HBUS, thus of primary importance in requesting HBUS. Moreover, only ALT and ALP levels on HBUS day were significantly higher than on admission.

Table 1 Distribution of the US scan performed in patients with TBI. HBUS scans over the period of observation are shown in different columns. Only patients with HBUS for isolated LFTs derangement were included in the study. Patients with TBI and traumatic hepato-biliary injury or chronic HBD were excluded and are shown in separate rows

HBUS criteria	Jan–Dec 2006	Jan–Dec 2007	Jan–Dec 2008	Jan–Dec 2009	Jan–Dec 2010	Jan–Jun 2011	Total HBUS
For isolated LFTs derangement	7	5	8	17	9	4	50
TBI with traumatic hepato-biliary injury	1	1	2	0	0	0	4
TBI with chronic hepato-biliary disease	0	1	0	4	1	2	8
Total HBUS	8	7	10	21	10	6	62

Table 2 Values of LFT in different moment of hospital stay. ALT, Bil, and ALP are shown in separate rows. In parentheses are shown the normal range values for all the three markers. The mean values during hospital stay are shown and 95% CI is provided in parentheses within the same box. HBUS, hepato-biliary ultrasound; NCCU, neuro-critical care unit

	Admission	HBUS day	NCCU discharge	Hospital discharge
ALT ($0–50 \text{ IU litre}^{-1}$)	72 (36–107)	246 (183–308)	160 (118–202)	83 (59–107)
Bil ($0–17 \mu\text{mol litre}^{-1}$)	14 (7–22)	24 (8–40)	9 (6–13)	9 (5–12)
ALP ($30–135 \text{ IU litre}^{-1}$)	73 (65–81)	329 (267–390)	300 (240–360)	216 (181–251)

Table 3 Different patterns of abnormality of LFTs on the HBUS day. Only values ≥ 1.5 the upper limit of normal range were considered as abnormal and possible trigger for HBUS investigation. ALT, Bil, and ALP and the possible combinations are shown in the first column with the number of each pattern also shown

Pattern of abnormal LFTs on the HBUS day	n
ALT only	11
Bil only	1
ALP only	4
ALT and ALP	27
ALT and Bil	0
ALP and Bil	3
All the LFTs	1

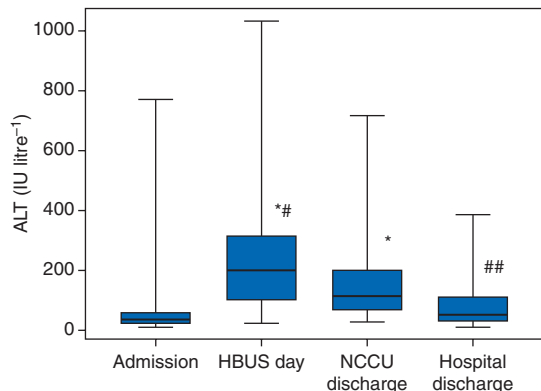


Fig 2 Variation of ALT. Boxplots include median, inter-quartile range, and outliers. Statistically significant differences are shown with asterisks and number sign. HBUS, hepato-biliary ultrasound. * ($P < 0.01$) refers to comparison with admission values; # ($P < 0.05$) and ## ($P < 0.01$) both refer to NCCU discharge.

In our population, the LFTs abnormalities peaked between days 17 (ALT) and 20 (ALP) after admission. Investigations with HBUS were performed on day 18, and no scans were performed before day 6 after admission. The interval in the development of LFTs derangement suggests that this was not associated with the initial trauma and related events, for instance, hepatic ischaemia due to hypotension and organ hypoperfusion at the scene. These results suggest that isolated LFT abnormality in our population of patients with TBI was either due to the critical illness or to the drugs used during the NCCU stay.

The predisposition of critically ill patients in developing acalculous cholecystitis, a gallbladder inflammation without gallstones, which seems caused by an impaired microcirculation in the gallbladder wall, finally leading to inflammation and ischaemia has already been shown.^{22 23} This is a rare but potentially lethal complication occurring in the ICU population.¹⁷ Multiple risk factors have been identified, for instance, trauma^{24 25} and its severity,²⁶ sepsis,²⁵ transfusions at admission,^{26 27} sedation, prolonged mechanical ventilation and

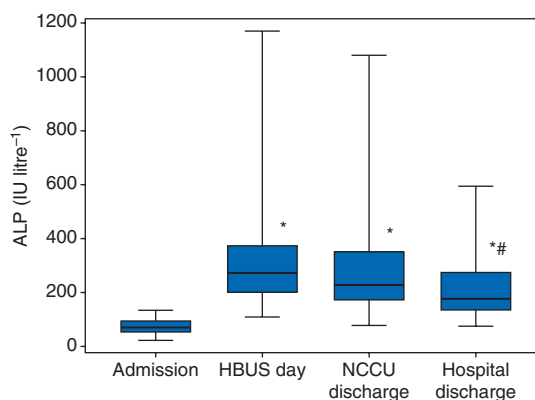


Fig 3 Variation of ALP. Boxplots include median, inter-quartile range, and outliers. Statistically significant differences are shown with asterisks and number sign. HBUS, hepato-biliary ultrasound. * ($P < 0.001$) refers to comparison with admission values; # ($P < 0.001$) refers to NCCU discharge.

Table 4 Analysis of the course of LFTs. ALT, Bil, and ALP in patients with TBI undergoing HBUS for isolated LFTs derangement. The results of Wilcoxon signed-rank test for data with non-normal distribution are shown. Values of $P < 0.05$ were considered as expression of statistically significant difference. NCCU, neuro-critical care unit

	ALT	ALP	Bil
Admission vs HBUS day	$P < 0.01$	$P < 0.01$	$P = 0.74$
HBUS day vs NCCU discharge	$P < 0.05$	$P = 0.50$	$P = 0.08$
Admission vs NCCU discharge	$P < 0.01$	$P < 0.01$	$P = 0.06$
NCCU discharge vs hospital discharge	$P < 0.01$	$P < 0.01$	$P < 0.05$
Admission vs hospital discharge	$P = 0.08$	$P < 0.01$	$P < 0.05$

shock,²⁸ etc. Therefore, patients with TBI seem at very high risk to develop acalculous cholecystitis because of the coexistence of multiple risk factors.

Even though a pharmacological analysis was not performed, TBI patients are highly exposed to drugs such as H₂ antagonists (ranitidine), paracetamol, antimicrobials, well known for causing liver insult.⁸⁻¹⁰ Moreover, we apply the last guidelines of the Brain Trauma Foundation²⁹ starting anti-convulsants therapy with phenytoin, another very well-known cause of drug-induced liver injury.^{10 11}

In addition to these insults, patients with TBI may require inotropic support to maintain cerebral perfusion resulting in vasoconstriction of solid organs including liver, accentuating hepatic dysfunction. Notably, TBI is also associated with ongoing neuro-inflammatory and systemic inflammatory response with elevated serum levels of inflammatory cytokines taking part in the ‘organ crosstalk’ which may result in hepatocellular injury. Yet, in patients with subarachnoid haemorrhage, it has been shown that the severity of extra-cerebral insults

(including the hepatic dysfunction) correlates with poor neurological outcome.³⁰

Another important finding of our study is the progressive improvement of ALT and ALP in the population of TBI investigated with HBUS for isolated LFTs derangement. However, ALT showed a faster recovery, improving at NCCU discharge; however, at this point, its value was still higher than at admission. Conversely, ALP was still deranged at NCCU discharge and did not show improvement after HBUS, remaining significantly higher than on admission. Overall, at the time of NCCU discharge, the mean ALT and ALP values were, respectively, more than three times and more than twice above their upper limits of normal range. We observe that these residual high values did not prevent a discharge from the NCCU.

Considering the period spent in the ward after critical care discharge, both ALT and ALP continued to improve significantly compared with the value on the HBUS day. Interestingly, ALP at hospital discharge remained still significantly higher than on admission, while the value of ALT at hospital discharge was higher but not significantly different than on admission ($P=0.08$).

The improvement of ALT and ALP can be explained by the recovery after critical illness and by a gradual reduction of pharmacological therapy in critical care. However, we think that the meaning of ALT values on admission and at hospital discharge deserves a further consideration. ALT was the only LFT deranged at hospital admission, being otherwise normal both Bil and ALP. The mild abnormal value of ALT on admission should be considered in the context of the traumatic event and the associated muscular–skeletal damage. In this context, ALT on admission could have not been an ideal baseline, and a mildly abnormal ALT value at hospital discharge could be expression of a still ongoing process of recovery from critical illness.

Before firm conclusions can be made from this study, several limitations should be considered. First, the study is conducted at a single tertiary centre and the retrospective design of the study itself makes too difficult to evaluate the impact of HBUS on the management of patients with TBI and isolated LFT derangement.

Secondly, the data presented do not inform us about the correlation between the isolated LFTs derangement and pharmacological therapy. Furthermore, from our results, it is not possible to correlate the LFTs abnormalities with other clinical variables such as the degree of coexistent systemic inflammatory response and sepsis, the haemodynamic deterioration and the use of vasopressors, and generally with the progression of critical illness (i.e. through scoring systems such as SOFA, LOD, MODS).

Even though we investigated more than 500 TBI patients, we detected only a relatively small number of them receiving HBUS investigations (9.2%). Consequently, it is not possible to expand our findings to the general ICU population.

Thirdly, it was not feasible at our institution to detect a well-matched control group of TBI patients, without suspected or proven hepato-biliary trauma and known chronic liver diseases, which developed isolated LFTs derangement not further investigated with HBUS. Therefore, the exact quote of all the TBI patients developing isolated LFTs derangement,

regardless of whether investigated or not with an HBUS, remains not addressed by this study.

For these reasons, further prospective studies on the role of HBUS in patients with isolated LFTs derangement are needed.

Conclusions

TBI patients often result in isolated LFTs abnormalities detected on routine blood sample investigations and requiring further examinations. In this retrospective study, a derangement more commonly happened after the second week in critical care, and the increase in ALT and ALP seems to play a major role in requesting an HBUS scan. However, in the population with head injury, an HBUS did not appear to be a sensitive diagnostic tool to explain the isolated LFT abnormalities. These results are consistent with a non-obstructive cause of LFTs derangement in TBI patients, which we can only assume as related to critical illness or to drug therapy. This hypothesis should be investigated by future prospective data or randomized controlled studies.

Abnormalities of ALT and ALP did not return to baseline normal values before discharging patients from the critical care. Whenever deranged, LFTs continue to improve by hospital discharge, with ALP showing a slower recovery and values significantly higher than at admission.

Authors' contributions

F.S., T.V., and B.F.M.: study design. F.S., T.V. and C.S.V.: data collection and reports screening. F.S. and C.S.: data analysis, tables, and figures. F.S. and T.V.: writing up the first draft of the manuscript. C.S., C.S.V., and B.F.M.: revision of the draft and comments. F.S. and T.V.: editing of the manuscript. All the authors: final approval of the version to be published.

Declaration of interest

None declared.

Funding

T.V. was supported by clinical research training fellowship from National Institute of Academic Anaesthesia and Raymond Beverly Sackler studentship. The funders had no role in study design, data collection and analysis, decision to publish, or preparation of the manuscript.

References

- 1 Lescot T, Karvellas C, Beaussier M, Magder S. Acquired liver injury in the intensive care unit. *Anesthesiology* 2012; **117**: 898–904
- 2 Thomson SJ, Cowan ML, Johnston I, Musa S, Grounds M, Rahman TM. Liver function tests' on the intensive care unit: a prospective, observational study. *Intensive Care Med* 2009; **35**: 1406–11
- 3 Fuhrmann V, Kneidinger N, Herkner H, et al. Impact of hypoxic hepatitis on mortality in the intensive care unit. *Intensive Care Med* 2011; **37**: 1302–10
- 4 Birrer R, Takuda Y, Takara T. Hypoxic hepatopathy: pathophysiology and prognosis. *Intern Med* 2007; **46**: 1063–70
- 5 Chand N, Sanyal AJ. Sepsis induced cholestasis. *Hepatology* 2007; **45**: 230–41

- 6 Lee WM. Drug-induced hepatotoxicity. *N Engl J Med* 2003; **349**: 474–85
- 7 Grau T, Bonet A, Rubio M, et al. Working Group on Nutrition and Metabolism of the Spanish Society of Critical Care. Liver dysfunction associated with artificial nutrition in critically ill patients. *Crit Care* 2007; **11**: R10
- 8 Luyendyk JP, Maddox JF, Cosma GN, Ganey PE, Cockerell GL, Roth RA. Ranitidine treatment during a modest inflammatory response precipitates idiosyncrasy-like liver injury in rats. *J Pharmacol Exp Ther* 2003; **307**: 9–16
- 9 Prescott L. Kinetics and metabolism of paracetamol and phenacetin. *Br J Clin Pharmacol* 1980; **10**: 291–8
- 10 Ghabil M, Fontana R, Rockey D, Jiezhun G, Chalasani N. Drug-induced liver injury caused by intravenously administered medications: the drug-induced liver injury network experience. *J Clin Gastroenterol* 2013; **47**: 553–8
- 11 Björnsson E. Hepatotoxicity associated with antiepileptic drugs. *Acta Neurol Scand* 2008; **118**: 281–90
- 12 Ahmed M, Diggory R. The correlation between ultrasonography and histology in the search for gallstones. *Ann R Coll Surg Engl* 2011; **93**: 81–3
- 13 Shea JA, Berlin JA, Escarce JJ, et al. Revised estimates of diagnostic test sensitivity and specificity in suspected biliary tract disease. *Arch Intern Med* 1994; **154**: 2573–81
- 14 Yusoff IF, Barkun JS, Barkun AN. Diagnosis and management of cholecystitis and cholangitis. *Gastroenterol Clin North Am* 2003; **32**: 1145–68
- 15 Kalimi R, Gecelter GR, Caplin D, et al. Diagnosis of acute cholecystitis: sensitivity of sonography, cholescintigraphy, and combined sonography–cholescintigraphy. *J Am Coll Surg* 2001; **193**: 609–13
- 16 Mariat G, Mahul P, Prevet N, et al. Contribution of ultrasonography and cholescintigraphy to the diagnosis of acute acalculous cholecystitis in intensive care unit patients. *Intensive Care Med* 2000; **26**: 1658–63
- 17 Kalliafas S, Ziegler DW, Flancbaum L, Choban PS. Acute acalculous cholecystitis: incidence, risk factors, diagnosis, and outcome. *Am Surg* 1998; **64**: 471–5
- 18 Puc MM, Tran HS, Wry PW, Ross SE. Ultrasound is not a useful screening tool for acute acalculous cholecystitis in critically ill trauma patients. *Am Surg* 2002; **68**: 65–9
- 19 Myrianthefs P, Evodia E, Vlachou I, et al. Is routine ultrasound examination of the gallbladder justified in critical care patients? *Crit Care Res Pract* 2012; **2012**: 565617
- 20 Boland GW, Slater G, Lu DS, Eisenberg P, Lee MJ, Mueller PR. Prevalence and significance of gallbladder abnormalities seen on sonography in intensive care unit patients. *Am J Roentgenol* 2000; **174**: 973–7
- 21 Crone-Münzebrock W, Wegener C, Nicolas V, Pothmann W. The relevance of sonography in the diagnosis of acute abdomen in the intensive care unit. *Rofa* 1990; **153**: 379–84
- 22 Hinds CJ, Watson JD. Biliary tract emergencies. In: *Intensive Care: A Concise Textbook*, 3rd Edn. Philadelphia, PA: Saunders Ltd, 2008; 466
- 23 Bilhartz L. Acalculous cholecystitis, cholesterolosis, adenomyomatosis and polyps of the gallbladder. In: Feldman M, Friedman L, Sleisenger M, eds. *Sleisenger and Fordtran's Gastrointestinal and Liver Diseases: Pathophysiology, Diagnosis, Management*. Philadelphia, PA: WB Saunders, 2002; 1106–30
- 24 Imhof M, Raunest J, Ohmann C, Röher HD. Acute acalculous cholecystitis complicating trauma: a prospective sonographic study. *World J Surg* 1992; **16**: 1160–5
- 25 Huffman JL, Schenker S. Acute acalculous cholecystitis: a review. *Clin Gastroenterol Hepatol* 2010; **8**: 15–22
- 26 Pelinka LE, Schmidhammer R, Hamid L, Mauritz W, Redl H. Acute acalculous cholecystitis after trauma: a prospective study. *J Trauma* 2003; **55**: 323–9
- 27 Theodorou P, Maurer CA, Spanholtz TA, et al. Acalculous cholecystitis in severely burned patients: incidence and predisposing factors. *Burns* 2009; **35**: 405–11
- 28 Molenat F, Boussuges A, Valantin V, Sainty JM. Gallbladder abnormalities in medical ICU patients: an ultrasonographic study. *Intensive Care Med* 1996; **22**: 356–8
- 29 Brain Trauma Foundation, American Association of Neurological Surgeons, Congress of Neurological Surgeons, Joint Section on Neurotrauma and Critical Care, AANS/CNS, Bratton SL, Chestnut RM, Ghajar J, et al. Guidelines for the management of severe traumatic brain injury. *J Neurotrauma* 2007; **24**: S83–6
- 30 Gruber A, Reinprecht A, Illievich UM, et al. Extracerebral organ dysfunction and neurologic outcome after aneurysmal subarachnoid hemorrhage. *Crit Care Med* 1999; **27**: 505–14

Handling editor: A. R. Absalom