

LONDON  
SCHOOL *of*  
HYGIENE  
& TROPICAL  
MEDICINE



# **Epidemiology and Management of Ocular Surface Squamous Neoplasia in Kenya**

**Stephen Gichuhi**

Thesis submitted in accordance with the requirements for the degree of  
Doctor of Philosophy of the University of London


**2016**

International Centre for Eye Health  
Department of Clinical Research  
Faculty of Infectious and Tropical Diseases  
London School of Hygiene and Tropical Medicine

Funded by: British Council for Prevention of Blindness – Sir John Wilson Fellowship

# Declaration

I, Stephen Gichuhi, confirm that the work presented in this thesis is my own. Where information has been derived from other sources, I confirm that this has been indicated in the thesis.

A handwritten signature in black ink that reads "Stephen Gichuhi". The signature is written in a cursive style and is placed on a light grey rectangular background.

Signature

Date 27<sup>th</sup> February 2016

# Glossary

The following abbreviations have been used throughout this thesis

5FU	5-Fluorouracil
adjOR	Adjusted odds ratio
AgNORs	Argyrophilic nucleolar organizer regions
AJCC	American Joint Committee on Cancer
AMT	Amniotic membrane transplant
ART	Antiretroviral Therapy
ASR	Age-standardised incidence rate
ATRA	All-trans retinoic acid
BCPB	British Council for Prevention of Blindness
BCRP	Breast cancer resistance protein
BD	Twice daily (12 hourly)
CD	Cluster of designation
CI	Confidence interval
CIN	Conjunctival Intraepithelial Neoplasia
CIS	Carcinoma-in-situ
CK	Cytokeratin
CMV	Cytomegalovirus
CONSORT	Consolidated Standards of Reporting Trials
CPD	Cyclobutane pyrimidine dimers
CsA	Cyclosporin A
DFID	Department for International Development
DNA	Deoxyribonucleic acid
DSMB	Data safety and monitoring board
E6	Early protein 6 (of human papilloma virus)
E7	Early protein 7 (of human papilloma virus)
EBV	Epstein Barr Virus
EDTA	Ethylenediaminetetracetic acid (an anticoagulant)
EGF-R	Epidermal growth factor receptor
EQA	External quality assurance
F-	False negative
F+	False positive
FDA	Food and drug administration

FdUMP	Fluorodeoxyuridine monophosphate
FdUTP	Fluorodeoxyuridine triphosphate
FUTP	Fluorouridine triphosphate
G1, G2	Growth phases of the cell cycle
GCLP	Good clinical laboratory practice
GCP	Good clinical practice
GDP	Gross Domestic Product
Gy	Grays (units of radiation)
H&E	Haematoxylin and eosin
HAART	Highly Active Antiretroviral Therapy
HACM	HIV/AIDS Cancer Match study
HC-2	Hybrid Capture 2
HEED	Health education and Early Detection study
HGF	Hepatocyte growth factor
HIV	Human Immunodeficiency Virus
HPLC	High-performance liquid chromatography
HPSG	Heparin sulphate proteoglycan
HPV	Human Papilloma Virus
HR	Hazard ratio
HSV	Herpes Simplex Virus
IAPB	International Agency for Prevention of Blindness
IARC	International Agency for Research in Cancer
ICD	International Classification of Diseases
ICMJE	International Council of Medical Journal Editors
IFN	Interferon
IQR	Interquartile range
ISCO	International Standard Classification of Occupations
IU	International units
IVCM	<i>in vivo</i> confocal microscopy
JAMA	Journal of the American Medical Association
<i>k</i>	Kappa statistic (for inter-observer agreement)
KAIS	Kenya AIDS indicator survey
KAVI	Kenya AIDS Vaccine Institute
KDH	Kitale District Hospital
KDHS	Kenya Demographic and Health Survey

KEU	Kikuyu Eye Unit
KGF-R	Keratinocyte growth factor receptor
KNH	Kenyatta National Hospital
KNOCS	Kenya National Occupation Classification System
KSHV	Kaposi's Sarcoma-associated Herpes Virus
L1, L2	Late proteins (of human papilloma virus)
LESC	Limbal epithelial stem cells
LR	Likelihood ratio
LSHTM	London School of Hygiene & Tropical Medicine
M:F ratio	Male to female ratio
MBASIC	Multilevel Biological And Social Integrative Construct
MMC	Mitomycin C
MMP	Matrix Metalloproteinase
MOH	Ministry of Health
M-phase	Mitotic phase of the cell cycle
MRC	Medical Research Council (UK)
MSVI	Moderately severe visual impairment
MU	Mega Units
Mutp53	Mutated p53 gene
NC ratio	Nuclear to cytoplasm ratio
NGF	Nerve growth factor
NHS	National health service
NSOPS	National specialist ophthalmic pathology service
OA	Ophthalmic assistant
OCO/CS	Ophthalmic clinical officer/Cataract surgeon
OCT	Optical coherence tomography
OD	Once daily
ON	Ophthalmic nurse
OR	Odds ratio
OSSN	Ocular surface squamous neoplasia
PAS	Periodic acid Schiff
PCEA	Presbyterian Church of East Africa
PCNA	Proliferating cell nuclear antigen
PCR	Polymerase Chain Reaction
PEPFAR	President's Emergency Fund for AIDS Relief

PMC	Post-mitotic cells
pRB	Retinoblastoma gene
PV-	Predictive value of a negative test
PV+	Predictive value of a positive test
QID	Four times daily (6 hourly)
qRT-PCR	Quantitative Reverse Transcriptase Polymerase Chain Reaction
RCT	Randomised controlled trial
RNA	Ribonucleic acid
ROC curve	Receiver operator characteristic curve
ROS	Reactive oxygen species
SCC	Squamous Cell Carcinoma
SCCC	Squamous Cell Carcinoma of the Conjunctiva
SD	Standard deviation
SE	Standard error
SEH	Sabatia Eye Hospital
SIR	Standardised Incidence Rate
SOP	Standard operating procedure
S-phase	Synthesis phase of the cell cycle
SSA	Sub-Saharan Africa
STI	Sexually transmitted infections
TAC	Transient amplifying cells
TDRC	Tropical Diseases Research Centre
Th1	T-Helper 1 Lymphocytes
TID	Three times daily (8 hourly)
TIL	Tumour infiltrating lymphocytes
TIMP	Transient Inhibitors of Matrix Metalloproteinase
ToB	Toluidine Blue
UHR-OCT	Ultra-high resolution Optical coherence tomography
UK	United Kingdom
UON	University of Nairobi
USA	United States of America
UV	Ultraviolet
UVR	Ultraviolet radiation
WHO	World Health Organization
XP	Xeroderma pigmentosum

# Abstract

## Introduction

Ocular surface squamous neoplasia (OSSN) is a spectrum of disease that ranges from non-invasive intra-epithelial dysplasia of the conjunctival and cornea (CCIN), through to invasive squamous cell carcinoma (SCC). It often presents with unilateral tumours on the eyeball. The tumours may cause blindness, disfigurement and even death. In East Africa, OSSN is relatively common and aggressive, affecting younger adults and proportionally more women than in other parts of the world. The management of OSSN is challenging for various reasons. Its risk factors are not clearly understood. Studies have implicated HIV, human papilloma virus (HPV) and solar radiation however about 30% of cases are HIV-negative while some studies have implicated HPV and others found no association. The importance of vitamin A for a healthy ocular surface is known, yet its role in OSSN has not been studied. Early diagnosis relies on the clinical impression yet OSSN appears similar to other conjunctival tumours and histopathology services are generally unavailable in Africa. Surgery is the mainstay of treatment but recurrence is an issue. There is no trial evidence for the various treatments used in HIV-infected persons. This project was an integrated set of studies to improve our understanding of the epidemiology and management of OSSN in Kenya.

## Methods

We conducted three systematic reviews on the epidemiology of OSSN in Africa, the pathophysiology of OSSN and updated a Cochrane review on the interventions for OSSN in HIV-infected individuals. Working in four eye care centres in Kenya between July 2012 and July 2015, we conducted the following six studies: (i) clinical assessment of a series of patients with conjunctival lesions to describe OSSN to determine how OSSN may differ clinically from benign lesions, (ii) evaluated vital staining with a special dye called Toluidine Blue (ToB) for making the diagnosis of OSSN, (iii) developed a diagnostic algorithm based on clinical features and vital staining, (iv) conducted a large case-control study to investigate risk factors that may contribute to the development of OSSN, (v) investigated the care-seeking journey of OSSN patients to assess referral pathway and treatment delay, and finally, (vi) conducted a randomised placebo-controlled trial of 5-Fluorouracil (5FU) chemotherapy eyedrops given after surgery to investigate if this can reduce recurrence of the lesions.

## Results

Meta-analysis of data from cancer registries worldwide showed that Africa has the highest incidence of OSSN in the world with a peak at latitude 16° South and males and females are equally affected, unlike other continents where male disease predominates. Here the age-standardized rate in cases/year /100,000 population (95%CI) is 1.38 (1.00–3.75) and 1.18 (1.08–3.43) in males and females, respectively ( $p=0.853$ ). Incidence rises with increasing exposure to direct sunlight (2–4 h, OR = 1.7, 95% CI: 1.2–2.4 and  $\geq 5$  h OR = 1.8, 95% CI: 1.1–3.1) and outdoor occupations (OR = 1.7, 95% CI: 1.1–2.6). Fixed-effect meta-analysis shows a strong association with HIV (6 studies: OR = 6.17, 95% CI: 4.83–7.89) but not cigarette smoking (2 studies: OR = 1.40, 95% CI: 0.94–2.09). HPV shows heterogeneous association (random effects meta-analysis of 7 studies: OR = 2.64, 95% CI: 1.27–5.49).

The pathophysiology review concluded that limbal epithelial stem cells are the likely progenitor cells of OSSN. UV radiation probably causes DNA damage via pyrimidine dimers (involving the p53 tumour suppressor gene), photo-immunosuppression and reactivates latent HPV. HPV E6 inhibits p53 gene allowing DNA-damaged cells past the G1-S checkpoint of the cell cycle. HPV E7 inhibits the retinoblastoma (pRB) gene anti-transcription at G1 so infected cells continue replicating. HIV, photo-immunosuppression and vitamin A deficiency may impair tumour surveillance.

The Cochrane review found no trials for the interventions used in OSSN in HIV-infected populations. There was one trial in Australia that found topical Mitomycin C (MMC) effective. The results from case series reviewed were difficult to compare. They reported a wide variety of combinations of surgery and adjuvant treatment used during surgery or post operatively; varying doses of adjuvant agents used; different inclusion criteria of patients and recurrences reported at varying periods after treatment. Surgery with adjuvant 5FU or MMC was often associated with recurrences of 11% to 67% about 30 months later.

We enrolled 496 adults with any conjunctival lesions requiring excision and 131 controls. OSSN was the most common lesion diagnosed in 187 (38%). Patients with OSSN were slightly older (mean [SD] age, 41 [11.6] vs 38 [10.9] years;  $p=0.002$ ) and tended to have lower levels of education than patients with benign lesions ( $p = 0.001$ ). Females predominated (67% of OSSN vs 64% of benign lesions;  $p = 0.65$ ). HIV infection was common among patients with OSSN (74%). Although some clinical signs were more frequent in OSSN, all OSSN signs were also observed in benign lesions. OSSN and benign conjunctival lesions have overlapping phenotypes and cannot always be reliably distinguished on clinical grounds. The positive



predictive value of clinical appearance in identifying OSSN was 54%. Inter-observer agreement was modest ( $\kappa = 0.1-0.4$ ).

Any blue colour on vital staining with ToB 0.05% had a sensitivity of 92%, specificity of 31%, positive predictive value of 41%, and negative predictive value of 88% for OSSN. Inter-observer agreement was substantial for staining ( $\kappa = 0.8$ ) and moderate for overall diagnosis (OSSN or benign) ( $\kappa = 0.4$ ). Use of ToB caused mild discomfort in 88 (21%) patients; mild superficial punctate keratopathy seen in 7 (1.7%) and no histological evidence of corneal toxicity was observed. ToB had a high rate of false positives (69%).

We developed a simple probability-tree clinical algorithm that shows the probability of OSSN with various combinations of clinical features. A multivariable regression model found 8 features strongly associated with OSSN; prior excision, corneal involvement, feeder vessels, dark blue ToB staining, papillary or gelatinous tumour surface, severe inflammation, anti-retroviral therapy and temporal or circumlimbal tumours. Using a cut-off of any 3 of these features, the sensitivity was 89%, specificity 50%, and 65% of lesions were correctly classified. This specificity was higher than any blue ToB staining (31%) but lower than clinical photo-examination (60%).

A total of 131 cases were frequency-matched to 131 controls by age, sex and eye center. Risk factors for OSSN were HIV infection without antiretroviral therapy (ART) use (OR=48.30; 95%CI 7.53-309.90) and with ART use (OR=19.02; 95%CI 6.55-55.26), longer duration of exposure to the sun in the main occupation (6.9 hrs/day vs. 4.6 hrs/day, OR=1.23; 95%CI 1.08-1.39) and a history of allergic conjunctivitis (OR=80.20; 95%CI 8.62-746.29). Wearing hats was protective (OR=0.21; 95%CI 0.07-0.63).

We studied the care-seeking journey followed by 158 new OSSN patients. About half (88/158, [56%]) presented directly to the study centres while the rest were referred. Indirect presenters sought care earlier than direct presenters (median 2.0 months vs 5.5 months) and travelled a shorter distance to the first health facility (median 20km vs 30km) but had surgery later (median 12.5 months vs 5.5 months). Visits beyond the first health facility for indirect presenters markedly increased delay (median 7.3, 29.0, 37.9, and 32.0 months for 1-4 facilities, respectively). Delay was associated with number of health facilities visited (adjusted ordered OR=9.12; 95%CI 2.83-29.4,  $p < 0.001$ ) and being female (adjusted ordered OR=2.42; 95%CI 1.32-4.44,  $p = 0.004$ ).

In the randomized placebo-controlled trial we randomly allocated 49 participants to 5FU and 49 to placebo. Four participants were lost to follow-up. Treatment with 5FU was associated with fewer OSSN recurrences: there were 5/47 (10.6%) recurrences in the 5FU arm and 17/47 (36.2%) in the placebo arm (odds ratio 0.21; 95%CI 0.07-0.63,  $p=0.01$ ). There was little effect from adjusting for passive smoking and antiretroviral therapy imbalance (adjOR=0.23; 95%CI 0.07-0.75,  $p=0.02$ ). Adverse effects were transient, mild and more frequent with 5FU: ocular discomfort (43 [88%] vs 36 [73%]), epiphora (24 [49%] vs 5 [10%]), and eyelid skin inflammation (7 [14%] vs 0).

## **Conclusions**

The clinical impression alone is unreliable for distinguishing OSSN from benign lesions. Toluidine Blue (ToB) staining is less specific and predictive than clinical examination by an Ophthalmologist. However, ToB may be a useful tool for other health care workers, with less ophthalmic training who might be involved in screening patients for the disease, as when there is no staining the disease is unlikely to be malignant. An algorithm that combines clinical features and ToB staining improves the specificity to 50%, is reasonably accurate (65%) for distinguishing OSSN from non-OSSN and shows the probability of disease with various combinations of clinical features. This algorithm cannot replace histopathology. Measures to prevent and control HIV, prevent sun exposure such as wearing hats, and control allergic conjunctivitis are recommended. Referral introduces significant delay before patients receive definitive treatment for OSSN. Women were more likely to experience delay. Despite regular contact with the health system for those with known HIV infection, delays occurred. Training in recognition and referral of OSSN cases, particularly in the HIV service, might lead to shorter delays before presentation. Post-operative topical 5FU substantially reduced recurrence of OSSN, was well-tolerated, and its use recommended in this context.

## **Format of the thesis**

The thesis for this PhD utilises the “research papers” format, recently introduced by the London School of Hygiene and Tropical Medicine. It therefore includes a number of papers which are either published, accepted or in submittable format for publication in peer-reviewed journals. The chapters listed in italics in the Contents are in this research/review paper format, and each chapter includes publication details in a cover sheet, including acknowledgement of the contributions of other people.

The other chapters of the thesis are composed of “linking material” which includes information/data not covered in the research papers and helps to make the thesis a coherent body.

## Contents

Declaration	2
Glossary	3
Abstract	7
Format of the thesis	11
Acknowledgements	13
List of contributors	14
<b>Introduction</b>	<b>16</b>
Chapter 1. <i>Epidemiology of ocular surface squamous neoplasia in Africa</i>	21
Chapter 2. <i>Pathophysiology of ocular surface squamous neoplasia</i>	44
Chapter 3. <i>Diagnosis of ocular surface squamous neoplasia</i>	58
Chapter 4. <i>Interventions for squamous cell carcinoma of the conjunctiva in HIV-infected individuals (Cochrane Review)</i>	77
Chapter 5. <i>Research setting</i>	133
Chapter 6. <i>Overview of project design</i>	141
<b>Data Chapters</b>	<b>147</b>
Chapter 7. <i>Clinical presentation of ocular surface squamous neoplasia in Kenya</i>	148
Chapter 8. <i>Toluidine Blue 0.05% vital staining for diagnosis of ocular surface squamous neoplasia in Kenya</i>	151
Chapter 9. <i>Clinical algorithm for diagnosis and management of ocular surface squamous neoplasia in East Africa</i>	154
Chapter 10. <i>Risk factors for ocular surface squamous neoplasia in Kenya</i>	175
Chapter 11. <i>Delay along the care-seeking pathway of patients with ocular surface squamous neoplasia in Kenya</i>	195
Chapter 12. <i>Topical 5-Fluorouracil (5FU) following surgery for ocular surface squamous neoplasia (OSSN) in Kenya: a randomised, double-blind, placebo-controlled trial</i>	218
<b>General discussion and future work</b>	<b>242</b>
Chapter 13. <i>Discussion</i>	243
Chapter 14. <i>Future work</i>	248
<b>Appendices</b>	<b>249</b>

# Acknowledgements

I would like to thank the following organisations and individuals for the support they provided:

The British Council for Prevention of Blindness (BCPB) who awarded me £180,000 under the Sir John Wilson Fellowship to conduct this research project.

To my supervisor Matthew Burton, and co-supervisors Helen Weiss and Mandeep Sagoo for their patient guidance and very helpful insights.

To all my Kenya and UK based collaborators who gave a lot towards this work. Various laboratories gave concessionary rates and IVEE Aqua in Kenya manufactured the trial eyedrops at no cost to the study.

To all the study participants who volunteered for the sake of many others suffering from ocular surface squamous neoplasia whose lives I hope will be improved by this work.

To my home institution, the University of Nairobi for giving me study leave.

The London School of Hygiene & Tropical Medicine experience shall remain a memorable chapter in my life story.

To my wife Christine and sons Philip and David, who stood with me throughout and bore the brunt of my 'busyness' with such grace and poise.

## List of contributors

Contributors to the research project in alphabetical order besides the listed authors in manuscripts:

<b>Person</b>	<b>Position</b>	<b>Contribution</b>
David Essex	Laboratory Manager, Eye pathology, Institute of Ophthalmology, Moorfields	Preparation of immunohistochemistry and histopathology slides
Godfrey Nyaga	Consultant Ophthalmologist, Kikuyu Eye Unit	Obtaining control conjunctival tissue
Grace Muthoni	Nurse, Kitale District Hospital	Counselling and coordination of follow up of participants
Heidi Barnes	Laboratory technologist, Institute of Ophthalmology, Moorfield	Preparation of immunohistochemistry and histopathology slides
Hodan Jama	Laboratory technologist, Institute of Ophthalmology, Moorfields	Slide photography
Irene Anne Mwangi	Laboratory technologist, KAVI	HIV and CD4 testing
Jane Nakhumicha	Nurse, Kikuyu Eye Unit	Coordination of sample collection and counselling
John Kamonjo Maina	Research assistant	Data entry and assistance with study coordination. RCT manuscript review.
John Ndiritu	Laboratory technologist, MP Shah Hospital	Tissue preparation for histopathology
John Njogu	Pharmaceutical technician, eyedrop production unit, Kikuyu Eye Unit	Production of toluidine blue eye drops
Justine Chileshe	Scientific officer, Tropical Diseases Research Centre, Zambia	Vitamin A analysis
Leah Mwenda	Nurse, Kikuyu Eye Unit	Coordination of eye clinic reviews of participants
Margaret W. Njoroge	Counsellor, Kikuyu Eye Unit	Participant counselling
Martin Hibberd	Virologist, London School of Hygiene & Tropical Medicine	Viral assays

Merceline Mbayi	Nurse, Sabatia Eye Hospital	Counselling and coordination of participant follow up
Mohammed Farah	Laboratory manager, KAVI	HIV and CD4 testing
Monica K. Ndungu	Counsellor, Kikuyu Eye Unit	Participant counselling
Phil Luthert	Consultant Pathologist, Institute of Ophthalmology, Moorfields	Reporting Immunohistochemistry slides
Ramadhani Athumani	Research degree student, London School of Hygiene & Tropical Medicine & KCMC	DNA extraction from tumour specimens
Ronald Mamboleo	Ophthalmic Clinical Officer, Kitale District Hospital	Participant enrolment
Shadrack Chebet	Ophthalmic Clinical Officer, Kitale District Hospital	Participant enrolment
Shaffiq Jafferjee	Consultant Ophthalmologist, Kikuyu Eye Unit	Obtaining control conjunctival tissue
Stephen Gathiga	Production manager, Ivey Aqua Ltd, Kenya	Production of 5FU eye drops
Sunil Shah	Proprietor, Ivey Aqua Ltd, Kenya	Production of 5FU eye drops
Warda	Laboratory technologist, Institute of Ophthalmology, Moorfields	Preparation of immunohistochemistry and histopathology slides
William Kemei	Ophthalmic Clinical Officer, Kitale District Hospital	Participant enrolment

Abbreviations: KAVI- Kenya Aids Vaccine Institute at University of Nairobi; KCMC – Kilimanjaro Christian Medical Center, Moshi, Tanzania

# Introduction

Ocular surface squamous neoplasia (OSSN) is a spectrum of disease that ranges from non-invasive intra-epithelial dysplasia of the conjunctival and cornea (CCIN), through to invasive squamous cell carcinoma (SCC).<sup>1</sup> In recent decades OSSN has undergone an epidemiological shift. In more temperate countries, it remains a rare, slow growing tumour of elderly males.<sup>2</sup> In contrast, in tropical countries, particularly in Eastern Africa, it is now more common, more aggressive, affects younger people and with a higher incidence in women here than in other parts of the world.<sup>3-6</sup> It seems likely that much of this increased burden of disease is attributable to the HIV/AIDS epidemic.<sup>7</sup> Even though OSSN is not a target condition within Vision 2020, it frequently leads to a poor quality of life, visual disability and death. In September 2010 the “IAPB/Vision2020 Workshop on Research for Global Blindness Prevention” identified specific research priorities.<sup>8</sup> It was recognised that for Africa there was a need for research on HIV-related conditions to better define the epidemiology and determine context-specific management approaches.

## **Prevalence and Incidence**

Reliable prevalence and incidence estimates of the numbers of individuals affected have been difficult to ascertain and vary considerably. At one extreme, in one study from Kenya based in a HIV testing clinic, 7.8% of HIV-infected adults were found to have conjunctival lesions which were found to be OSSN on histopathology.<sup>5</sup> The Kenyan national HIV prevalence is 6% (2.28 million out of 38 million) so it was suggested that over 170,000 Kenyans might have some degree of OSSN. In contrast, a relatively low annual incidence estimate of 2.2/100,000 has been suggested in a study from Tanzania, based on the number of cases being operated in eye units.<sup>6</sup> From the clinical perspective OSSN represents a significant component of the ophthalmic “work-load” in East Africa. About 5% of all ophthalmic surgery in Kenya is for OSSN (Table 1 on page 18) and is associated with a high level of morbidity for the patient, as exenteration is often needed for those with late presentation or recurrent disease. However, OSSN receives little or no attention from either ophthalmic or HIV care programs.

## **Risk factors and Aetiology**

The risk factors and aetiology of OSSN in East Africa are not well understood. There is an association with HIV; however, a significant proportion (~30%) of people with OSSN are not infected with HIV, suggesting that other factors also contribute to the excess burden of disease in this region.<sup>7, 9-11</sup> Despite the association with HIV, a dose-response effect where lower



CD4+ T-lymphocyte levels in HIV+ individuals is associated with more severe OSSN has not been described. The relationship between human papilloma virus (HPV) and OSSN remains unclear; some studies have reported associations and others have not.<sup>12-17</sup> This is probably because of variations in methodology and the specific HPV types that have been looked for. Generally only a very limited sub-set of the many different HPV types have been investigated. It seems plausible that ultraviolet solar radiation also plays a major role; a specific mutation associated with UV radiation has been found more frequently in OSSN tissue.<sup>18</sup> The importance of vitamin A in maintaining the health of the ocular surface is established and its deficiency leads to goblet cell loss, desquamation and keratinization of the ocular surface.<sup>19</sup> Studies in the pre-HAART era found vitamin A deficiency (serum retinol <30 µg/dL or <1.05 µmol/L) common in HIV patients.<sup>20</sup> The potential role of vitamin A deficiency in OSSN has not previously been investigated.

### **Diagnosis**

Histopathology is the gold standard for diagnosing OSSN and determining the stage of the disease. However, generally in sub-Saharan Africa there is very limited access to pathology services, such that most probable OSSN lesions are excised without pathological confirmation of the diagnosis or complete excision of the lesion. A simple and cheap diagnostic aid would be of considerable help to the clinician. Vital stains are used to colour living tissues; various dyes are used extensively in ophthalmic surgery.<sup>21</sup> Toluidine blue (ToB) is a vital dye that stains abnormal tissue. It has been used for many years to help support the clinical diagnosis of oral, oesophageal and cervical dysplasia and carcinoma and to demarcate lesions during surgical excision.<sup>22</sup> There is one case report describing the use of ToB vital staining of OSSN.<sup>23</sup> The dye was reported to clearly demarcate the abnormal tissue, assisting the excision. The authors commented that they also found ToB did not stain other conjunctival lesions such as pterygium (no data presented) and did not cause any toxicity to the ocular surface.

### **Treatment**

A Cochrane systematic review found no randomised controlled clinical trials of any interventions for the treatment of OSSN in HIV-infected people.<sup>24</sup> Most lesions are surgically excised (very large tumours that have spread to the orbit are usually managed by exenteration). However, results in terms of OSSN recurrence rates are very variable. Although one series by a very experienced surgeon reported low recurrence rates (3.2%),<sup>11</sup> under routine operational conditions in Africa and elsewhere the recurrence rates are much higher: reports generally range between 30% and 66%.<sup>5, 25-27</sup> To try to reduce recurrence rates various adjuvant chemotherapy treatments are sometimes used: mitomycin-C, 5-fluorouracil (5-FU) or interferon-2β.<sup>28</sup> A recent case-series study of the long-term efficacy and safety of topical 5-

FU 1% given alone or as adjuvant therapy following surgical excision reported recurrence rates of <10% and no evidence of toxicity.<sup>29</sup> Adjuvant therapy is rarely used in sub-Saharan Africa, although 5-FU is available and affordable. Randomized controlled trials are needed to identify the optimal treatment for this condition to minimise recurrence rates, visual loss and death from conjunctival SCC in the East African setting.

### Research and Thesis Overview

This research project consisted of an integrated set of studies to improve our understanding of the epidemiology and management of OSSN in Kenya. We conducted a systematic review of the epidemiology of OSSN in Africa and updated an earlier conducted Cochrane review of the interventions of OSSN in HIV-infected populations. We also reviewed what is known about the pathophysiology of OSSN. There is a linking chapter on the diagnostic methods used for OSSN. The research setting where the project was conducted is described followed by an overview of the research project design. The data chapters consist of reports on the clinical presentation of OSSN in Africa with an emphasis on the features that may distinguish OSSN from benign lesions; a diagnostic test study of toluidine blue vital staining; a clinical algorithm for diagnosis of OSSN; a case control study of risk factors of OSSN; an evaluation of factors that may contribute to delay in presentation and treatment of patients with OSSN and finally a randomized controlled trial of 5-Fluorouracil adjuvant therapy to try and reduce recurrence rates after surgical excision of OSSN tumours.

**Table 1. The clinical workload attributable to Ocular Surface Squamous Neoplasia (OSSN) in Kenya. This data was obtained from the Ophthalmic Services Unit database in the Ministry of Health**

Year	2008	2009	2010	2011
Total no. of patients seen	376,174	448,923	474,216	454,439
Patients with conjunctival lesions	4,860	7,867	8,198	8,054
Estimated no. with OSSN (38% of lesions)	571	689	740	639
Total no. of eye surgeries	30,701	37,935	36,625	28,897
Total no. of conjunctival excisions	1,428	1,722	1,850	1,597
% of total patients seen estimated to have OSSN	1.3	1.8	1.7	1.8
% of total surgeries estimated due to OSSN	4.7	4.5	5.1	5.5

FOOTNOTE: This data did not include exenterations but shows that the surgical volume attributed to OSSN is increasing over the years. In 2015 Sabatia Eye Hospital, one of our study centers performed 296 conjunctival excisions and 3 exenterations. OSSN was confirmed in 82 patients (29%)

## References

1. Lee GA, Hirst LW. Ocular surface squamous neoplasia. *Survey of ophthalmology* 1995; **39**(6): 429-50.
2. Lee GA, Hirst LW. Retrospective study of ocular surface squamous neoplasia. *Australian and New Zealand journal of ophthalmology* 1997; **25**(4): 269-76.
3. Poole TR. Conjunctival squamous cell carcinoma in Tanzania. *The British journal of ophthalmology* 1999; **83**(2): 177-9.
4. Pola EC, Masanganise R, Rusakaniko S. The trend of ocular surface squamous neoplasia among ocular surface tumour biopsies submitted for histology from Sekuru Kaguvi Eye Unit, Harare between 1996 and 2000. *The Central African journal of medicine* 2003; **49**(1-2): 1-4.
5. Chisi SK, Kollmann MK, Karimurio J. Conjunctival squamous cell carcinoma in patients with human immunodeficiency virus infection seen at two hospitals in Kenya. *East African medical journal* 2006; **83**(5): 267-70.
6. Furahini G, Lewallen S. Epidemiology and management of ocular surface squamous neoplasia in Tanzania. *Ophthalmic epidemiology* 2010; **17**(3): 171-6.
7. Ateenyi-Agaba C. Conjunctival squamous-cell carcinoma associated with HIV infection in Kampala, Uganda. *Lancet* 1995; **345**(8951): 695-6.
8. International Agency for Prevention of Blindness. Workshop Report: A VISION 2020 Workshop on Research for Global Blindness Prevention International Center for Eye Health (ICEH), 2010.
9. Mbulaiteye SM, Katabira ET, Wabinga H, et al. Spectrum of cancers among HIV-infected persons in Africa: the Uganda AIDS-Cancer Registry Match Study. *International journal of cancer Journal international du cancer* 2006; **118**(4): 985-90.
10. Waddell KM, Lewallen S, Lucas SB, Ateenyi-Agaba C, Herrington CS, Liomba G. Carcinoma of the conjunctiva and HIV infection in Uganda and Malawi. *The British journal of ophthalmology* 1996; **80**(6): 503-8.
11. Waddell KM, Downing RG, Lucas SB, Newton R. Corneo-conjunctival carcinoma in Uganda. *Eye (Lond)* 2006; **20**(8): 893-9.
12. Yu JJ, Fu P, Pink JJ, et al. HPV infection and EGFR activation/alteration in HIV-infected East African patients with conjunctival carcinoma. *PloS one* 2010; **5**(5): e10477.
13. Moubayed P, Mwakyoma H, Schneider DT. High frequency of human papillomavirus 6/11, 16, and 18 infections in precancerous lesions and squamous cell carcinoma of the conjunctiva in subtropical Tanzania. *Am J Clin Pathol* 2004; **122**(6): 938-43.
14. Guthoff R, Marx A, Stroebel P. No evidence for a pathogenic role of human papillomavirus infection in ocular surface squamous neoplasia in Germany. *Current eye research* 2009; **34**(8): 666-71.
15. de Koning MN, Waddell K, Magyezi J, et al. Genital and cutaneous human papillomavirus (HPV) types in relation to conjunctival squamous cell neoplasia: a case-control study in Uganda. *Infectious agents and cancer* 2008; **3**: 12.
16. Sen S, Sharma A, Panda A. Immunohistochemical localization of human papilloma virus in conjunctival neoplasias: a retrospective study. *Indian journal of ophthalmology* 2007; **55**(5): 361-3.
17. Simbiri KO, Murakami M, Feldman M, et al. Multiple oncogenic viruses identified in Ocular surface squamous neoplasia in HIV-1 patients. *Infectious agents and cancer* 2010; **5**: 6.
18. Ateenyi-Agaba C, Dai M, Le Calvez F, et al. TP53 mutations in squamous-cell carcinomas of the conjunctiva: evidence for UV-induced mutagenesis. *Mutagenesis* 2004; **19**(5): 399-401.
19. Pfister RR, Renner ME. The corneal and conjunctival surface in vitamin A deficiency: a scanning electron microscopy study. *Investigative ophthalmology & visual science* 1978; **17**(9): 874-83.
20. Baeten JM, McClelland RS, Richardson BA, et al. Vitamin A deficiency and the acute phase response among HIV-1-infected and -uninfected women in Kenya. *Journal of acquired immune deficiency syndromes (1999)* 2002; **31**(2): 243-9.

21. Rodrigues EB, Costa EF, Penha FM, et al. The use of vital dyes in ocular surgery. *Survey of ophthalmology* 2009; **54**(5): 576-617.
22. Lingen MW, Kalmar JR, Karrison T, Speight PM. Critical evaluation of diagnostic aids for the detection of oral cancer. *Oral oncology* 2008; **44**(1): 10-22.
23. Kaji Y, Hiraoka T, Oshika T. Vital staining of squamous cell carcinoma of the conjunctiva using toluidine blue. *Acta ophthalmologica Scandinavica* 2006; **84**(6): 825-6.
24. Gichuhi S, Irlam JJ. Interventions for squamous cell carcinoma of the conjunctiva in HIV-infected individuals. *Cochrane database of systematic reviews (Online)* 2007; (2): CD005643.
25. Tabin G, Levin S, Snibson G, Loughnan M, Taylor H. Late recurrences and the necessity for long-term follow-up in corneal and conjunctival intraepithelial neoplasia. *Ophthalmology* 1997; **104**(3): 485-92.
26. Birkholz ES, Goins KM, Sutphin JE, Kitzmann AS, Wagoner MD. Treatment of Ocular Surface Squamous Cell Intraepithelial Neoplasia With and Without Mitomycin C. *Cornea* 2010.
27. Yeatts RP, Engelbrecht NE, Curry CD, Ford JG, Walter KA. 5-Fluorouracil for the treatment of intraepithelial neoplasia of the conjunctiva and cornea. *Ophthalmology* 2000; **107**(12): 2190-5.
28. Sepulveda R, Pe'er J, Midea E, Seregard S, Dua HS, Singh AD. Topical chemotherapy for ocular surface squamous neoplasia: current status. *The British journal of ophthalmology* 2010; **94**(5): 532-5.
29. Parrozzani R, Lazzarini D, Alemany-Rubio E, Urban F, Midea E. Topical 1% 5-fluorouracil in ocular surface squamous neoplasia: a long-term safety study. *Br J Ophthalmol* 2010.

# Chapter 1. Epidemiology of ocular surface squamous neoplasia in Africa





**Registry**

T: +44(0)20 7299 4646  
F: +44(0)20 7299 4656  
E: registry@lshtm.ac.uk

## RESEARCH PAPER COVER SHEET

**PLEASE NOTE THAT A COVER SHEET MUST BE COMPLETED FOR EACH RESEARCH PAPER INCLUDED IN A THESIS.**

### SECTION A – Student Details

<b>Student</b>	Stephen Gichuhi
<b>Principal Supervisor</b>	Matthew J. Burton
<b>Thesis Title</b>	Epidemiology and management of ocular surface squamous neoplasia

**If the Research Paper has previously been published please complete Section B, if not please move to Section C**

### SECTION B – Paper already published

Where was the work published?	Tropical Medicine and International Health		
When was the work published?	December 2013		
If the work was published prior to registration for your research degree, give a brief rationale for its inclusion			
Have you retained the copyright for the work?*	No	Was the work subject to academic peer review?	Yes

*\*If yes, please attach evidence of retention. If no, or if the work is being included in its published format, please attach evidence of permission from the copyright holder (publisher or other author) to include this work.*

### SECTION C – Prepared for publication, but not yet published

Where is the work intended to be published?	
Please list the paper's authors in the intended authorship order:	
Stage of publication	Choose an item.

### SECTION D – Multi-authored work

For multi-authored work, give full details of your role in the research included in the paper and in the preparation of the paper. (Attach a further sheet if necessary)	I searched the cancer registry databases and extracted the data; conducted the analysis with guidance from H.A. Weiss and M.J Burton; drafted and submitted the manuscript with consideration of comments from all the co-authors
--	---

**Student Signature:** Stephen Gichuhi

**Date:** 4th February 2016

**Supervisor Signature:** M. J. Burton

**Date:** 4th February 2016



# RightsLink®

[Home](#)
[Account Info](#)
[Help](#)


**Title:** Epidemiology of ocular surface squamous neoplasia in Africa

**Author:** Stephen Gichuhi, Mandeep S. Sagoo, Helen A. Weiss, Matthew J. Burton

**Publication:** Tropical Medicine & International Health

**Publisher:** John Wiley and Sons

**Date:** Oct 30, 2013

© 2013 The Authors. Tropical Medicine and International Health published by John Wiley & Sons Ltd.

Logged in as:  
Stephen Gichuhi  
Account #:  
3000472881

[LOGOUT](#)

## Welcome to RightsLink

This article is available under the terms of the Creative Commons Attribution License (CC BY) (which may be updated from time to time) and permits use, distribution and reproduction in any medium, provided that the Contribution is properly cited.

For an understanding of what is meant by the terms of the Creative Commons License, please refer to [Wiley's Open Access Terms and Conditions](#).

Permission is not required for this type of reuse.

Wiley offers a professional reprint service for high quality reproduction of articles from over 1400 scientific and medical journals. Wiley's reprint service offers:

- Peer reviewed research or reviews
- Tailored collections of articles
- A professional high quality finish
- Glossy journal style color covers
- Company or brand customisation
- Language translations
- Prompt turnaround times and delivery directly to your office, warehouse or congress.

Please contact our Reprints department for a quotation. Email [corporatesaleseurope@wiley.com](mailto:corporatesaleseurope@wiley.com) or [corporatesalesusa@wiley.com](mailto:corporatesalesusa@wiley.com) or [corporatesalesDE@wiley.com](mailto:corporatesalesDE@wiley.com).

[CLOSE WINDOW](#)

Copyright © 2016 [Copyright Clearance Center, Inc.](#) All Rights Reserved. [Privacy statement](#). [Terms and Conditions](#).  
Comments? We would like to hear from you. E-mail us at [customercare@copyright.com](mailto:customercare@copyright.com)

## Systematic Review

## Epidemiology of ocular surface squamous neoplasia in Africa

Stephen Gichuhi<sup>1,2</sup>, Mandeep S. Sagoo<sup>3,4</sup>, Helen A. Weiss<sup>2</sup> and Matthew J. Burton<sup>2,3</sup><sup>1</sup> Department of Ophthalmology, University of Nairobi, Nairobi, Kenya<sup>2</sup> London School of Hygiene and Tropical Medicine, London, UK<sup>3</sup> Moorfields Eye Hospital, London, UK<sup>4</sup> UCL Institute of Ophthalmology, University College London, UK**Abstract**

**OBJECTIVES** To describe the epidemiology and an aetiological model of ocular surface squamous neoplasia (OSSN) in Africa.

**METHODS** Systematic and non-systematic review methods were used. Incidence was obtained from the International Agency for Research on Cancer. We searched PubMed, EMBASE, Web of Science and the reference lists of articles retrieved. Meta-analyses were conducted using a fixed-effects model for HIV and cigarette smoking and random effects for human papilloma virus (HPV).

**RESULTS** The incidence of OSSN is highest in the Southern Hemisphere (16° South), with the highest age-standardised rate (ASR) reported from Zimbabwe (3.4 and 3.0 cases/year/100 000 population for males and females, respectively). The mean ASR worldwide is 0.18 and 0.08 cases/year/100 000 among males and females, respectively. The risk increases with exposure to direct daylight (2–4 h, OR = 1.7, 95% CI: 1.2–2.4 and ≥5 h OR = 1.8, 95% CI: 1.1–3.1) and outdoor occupations (OR = 1.7, 95% CI: 1.1–2.6). Meta-analysis also shows a strong association with HIV (6 studies: OR = 6.17, 95% CI: 4.83–7.89) and HPV (7 studies: OR = 2.64, 95% CI: 1.27–5.49) but not cigarette smoking (2 studies: OR = 1.40, 95% CI: 0.94–2.09). The effect of atopy, xeroderma pigmentosa and vitamin A deficiency is unclear.

**CONCLUSIONS** Africa has the highest incidence of OSSN in the world, where males and females are equally affected, unlike other continents where male disease predominates. African women probably have increased risk due to their higher prevalence of HIV and HPV infections. As the survival of HIV-infected people increases, and given no evidence that anti-retroviral therapy (ART) reduces the risk of OSSN, the incidence of OSSN may increase in coming years.

**keywords** ocular surface squamous neoplasia, conjunctival intraepithelial neoplasia, conjunctival intraepithelial dysplasia, ocular surface epithelial dysplasia, conjunctival squamous cell carcinoma, risk factors, incidence

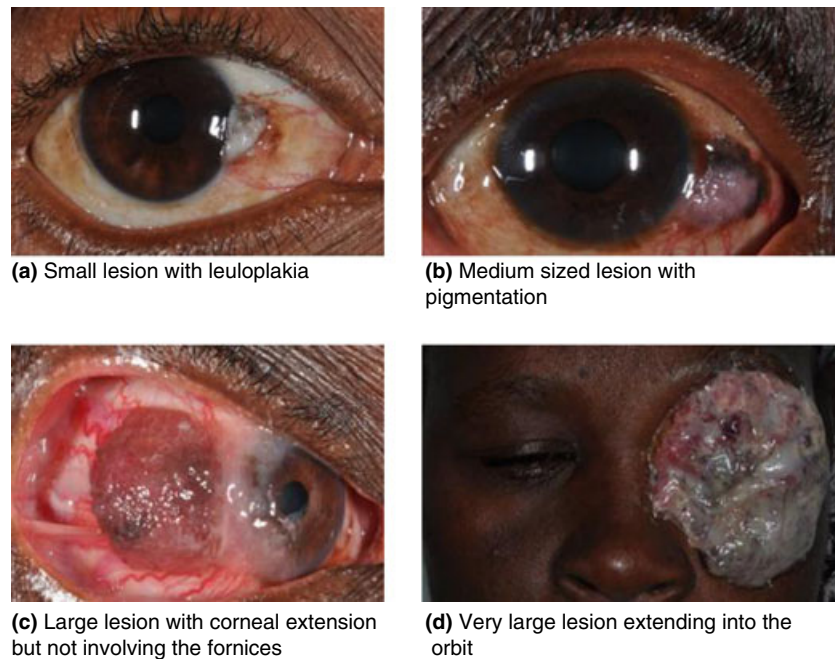
**Introduction**

Ocular surface squamous neoplasia (OSSN) is the most common ocular surface tumour (Grossniklaus *et al.* 1987). Other synonymous terms include ‘conjunctival epithelial neoplasia’, ‘ocular surface epithelial dysplasia’ and ‘conjunctival squamous cell neoplasia’ (Lee & Hirst 1992; McDonnell *et al.* 1992; Tulvatana 2003). OSSN covers a spectrum of disease ranging from non-invasive intra-epithelial dysplasia of the conjunctiva and cornea (CCIN) to invasive squamous cell carcinoma (Lee & Hirst 1995).

**Clinical features**

The disease may present with irritation, red eye, raised gelatinous mass and leucoplakia (Tunc *et al.* 1999). In Africans, it is often pigmented brown (Figure 1). OSSN is usually unilateral (Chisi *et al.* 2006) and arises at the limbus – the junction between the cornea and conjunctiva (Lee & Hirst 1997). Most lesions occur within the exposed part of the eyeball between the lids (Ateenyi-Agaba 1995; McKelvie 2002; Waddell *et al.* 2006). Up to 31.2% of cases seen are recurrent lesions (Chisi *et al.* 2006). Late stages present with a large fungating oculo-orbital mass (Ogun *et al.* 2009). Early lesions resemble



S. Gichuhi *et al.* Ocular surface squamous neoplasia in Africa

**Figure 1** A range of clinical presentations of ocular surface squamous neoplasia (OSSN) in East Africa. (a) Small lesion with leukoplakia; (b) Medium sized lesion with pigmentation; (c) Large lesion with corneal extension but not involving the fornices; (d) Very large lesion extending into the orbit.

**Table 1** Histopathological classification of ocular surface squamous neoplasia (OSSN), Basti & Macsai (2003) and American Joint Committee on Cancer (2010)

Benign
Squamous papilloma
Pseudoepitheliomatous hyperplasia
Benign hereditary intraepithelial dyskeratosis
Pre-invasive
Conjunctival intraepithelial neoplasia (CIN)
CIN I (mild dysplasia) – confined to the basal third of the conjunctival epithelium
CIN II (moderate dysplasia) – extends into the middle third of the conjunctival epithelium
CIN III (severe dysplasia) – extends into the superficial third of the conjunctival epithelium
CIS (carcinoma- <i>in-situ</i> ) – full thickness dysplasia*
Invasive
Squamous cell carcinoma
GX – grade cannot be defined
G1 – Well differentiated
G2 – Moderately differentiated
G3 – Poorly differentiated
G4 – undifferentiated
Mucoepidermoid carcinoma

\*The American Joint Committee on Cancer (AJCC) staging manual 2010 classifies CIS under CIN.

benign growths such as pterygia and pingueculae. OSSN can be the first manifestation of HIV infection in about 50% of cases in HIV-endemic settings (Porges & Groisman 2003; Spitzer *et al.* 2008).

### Histopathology

Histologically, OSSN may be classified into 3 forms: benign, pre-invasive and invasive (Table 1; Basti & Macsai 2003). The term OSSN usually excludes the benign forms. The term ‘invasive’ indicates infiltration through the basement membrane of the conjunctival epithelium into the underlying stroma (Basti & Macsai 2003; Shields & Shields 2004).

### Epidemiology overview

Two disease patterns of OSSN are recognised: older, predominantly male in temperate climates, not associated with HIV or human papilloma virus (HPV); and younger men and women, in tropical climates, associated with HIV and HPV. The latter represents a public health challenge in Africa in relation to the HIV pandemic and late presentation of large tumours (Ukponmwan *et al.* 2002; Chisi *et al.* 2006; Ogun *et al.* 2009), diagnostic difficulties (Furahini & Lewallen 2010), malignant transformation and high recurrence rates after treatment (1-year recurrence of 16.6% reported in Tanzania; Makupa *et al.* 2012). Experienced surgeons report lower recurrences (3.2%) after excision (Waddell *et al.* 2006). Trial data to guide management in this context are lacking (Gichuhi & Irlam 2013). For the temperate pattern of disease, one randomised controlled crossover trial in Australia compared mitomycin-C with placebo in participants

S. Gichuhi *et al.* Ocular surface squamous neoplasia in Africa

whose average age was 67 years (Hirst 2007). There was a significant treatment effect on clinically assessed complete resolution of lesions ( $P = 0.0005$ ), but no effect on histologically assessed complete resolution ( $P = 0.49$ ).

### Incidence rates and geographical variation

Incidence estimates for OSSN are difficult to ascertain and vary regionally (Table 2). The first paper to examine this used cancer registry data from International Agency for Research on Cancer (IARC; Newton *et al.* 1996). A subset of these data were used in a subsequent publication looking at variation in incidence across the USA (Emmanuel *et al.* 2012). However, published results need to be interpreted with caution – firstly, all eye cancers are classified together by the International Classification of Diseases for Oncology (ICD-O-3 C.69) while other databases classify squamous cell carcinoma of the conjunctiva (SCCC) with head and neck cancers (Lee *et al.* 2000; Curado *et al.* 2007; Parkin *et al.* 2010). OSSN is not recognised as a separate entity. Squamous cell carcinomas that are site-coded for the eye (C69) probably include some cancers that originate in the eyelid skin (WHO 2000, 2010; Curado *et al.* 2007). Secondly, the availability of histopathology services to confirm OSSN diagnosis is often limited in low- and middle-income countries (Furahini & Lewallen 2010). Thirdly, health information systems tend to capture invasive squamous cell carcinoma (SCC) but not earlier stages. Countries reporting higher rates of SCC (mostly in Africa) only started sending cancer registry data to IARC in the mid-1980s (Curado *et al.* 2007). Completeness of the current IARC database is hampered in that only data from 80 countries were submitted, of which 75% was of acceptable quality, and not all countries had data on

squamous cell carcinoma in the eye under code C69. Africa had the lowest level of acceptable quality of data (36%). Fourthly, crude incidence rates can be influenced by population structure, a problem often addressed by reporting age-standardised incidence rates. Finally, in areas with limited health facilities for cancer treatment where a large number of patients are treated outside the reference area, incidence may be underestimated. Moreover, in defining incidence from different sources, it may be difficult to distinguish between recurrence or extension of an existing cancer on one hand and the development of a new primary on the other. Analysis of incidence time trends is also difficult if geographical coverage, ICD revisions and disease definitions in a registry change.

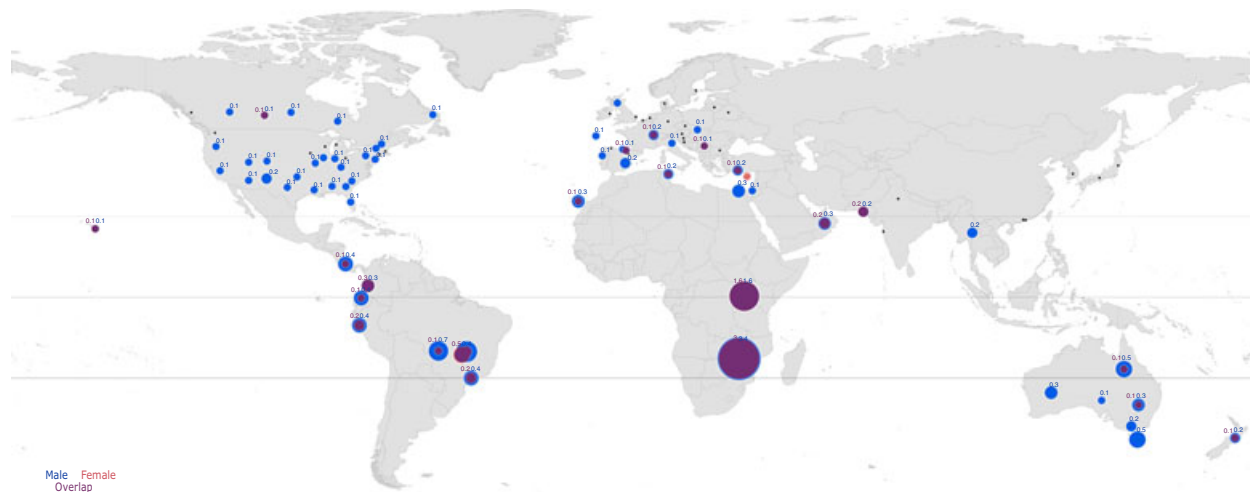
### Methods for this review

Systematic and non-systematic review methods were used. No *a priori* systematic review protocol had been published. Incidence data were obtained from the current IARC report (9th Volume) covering the period 1998–2002. The IARC collates data from cancer registries worldwide. The report uses ICD codes to show the age-standardised incidence per 100 000 population stratified by sex and histological type. Under code C.69 where eye cancers are reported, the four main groups are retinoblastoma, malignant melanoma, carcinomas (11.4% of all eye cancers), sarcoma and other unspecified tumours. Under carcinomas, there are three subgroups – SCC (principally tumours of the conjunctiva and cornea, comprising 70% of the carcinoma subgroup), other specified carcinoma (adenocarcinomas of the lacrimal gland and lacrimal duct) and unspecified carcinomas. We extracted data from the SCC subgroup.

**Table 2** Age-standardized incidence rates of squamous cell carcinoma in the eye (ICD-O-3 C.69) by continent for the period 1998–2002 (Curado *et al.* 2007)

Region	Age-standardized incidence rate (cases/year/100 000 pop)		P-value
	Males mean (95% CI)	Females mean (95% CI)	
Africa	1.38 (–1.00 to 3.75)	1.18 (–1.08 to 3.43)	0.853
Central & South America	0.48 (0.33 to 0.62)	0.21 (0.10 to 0.33)	0.005
Oceania	0.28 (0.14 to 0.41)	0.05 (0.01 to 0.10)	0.002
North America	0.08 (0.06 to 0.10)	0.00 (0.00 to 0.01)	<0.001
Asia	0.08 (0.01 to 0.14)	0.05 (0.00 to 0.09)	0.416
Europe	0.05 (0.02 to 0.08)	0.01 (0.00 to 0.03)	0.033
Southern Hemisphere	0.61 (0.14 to 1.09)	0.33 (–0.12 to 0.78)	0.355
Northern Hemisphere	0.10 (0.06 to 0.14)	0.05 (0.00 to 0.08)	0.045
Worldwide estimate	0.18 (0.09 to 0.26)	0.08 (0.01 to 0.15)	0.091

CI = confidence interval.

S. Gichuhi *et al.* Ocular surface squamous neoplasia in Africa

KEY: Dot size is directly proportional to incidence. Males are shown in blue and females in red. Overlaps between males and females appear purple in colour

**Figure 2** Worldwide mapping of the age-standardized incidence rates (ASR) of squamous cell carcinoma of the eye (ICD-O-3 C.69) for the period 1998–2002 (Curado *et al.* 2007). Key: Dot size is directly proportional to incidence. Males are shown in blue and females in red. Overlaps between males and females appear purple in colour.

The coordinates locating each registry were obtained from <http://itouchmap.com/latlong.html>.

We searched PubMed, EMBASE and Web of Science for systematic reviews, meta-analysis and case-control studies using ‘OSSN’, ‘conjunctival squamous cell carcinoma’, ‘risk factors’ and their synonyms as key words with no language restrictions. Abstracts were assessed and studies were selected if they reported analysis of known or suspected risk factors. The search was conducted on 2 January 2013 and updated on 31 May 2013. Data were extracted from the full texts of articles and additional articles obtained from their reference lists. Meta-analyses were conducted where appropriate. A fixed-effects model was used for HIV and cigarette smoking. A random-effects model was chosen for HPV after investigation of heterogeneity.

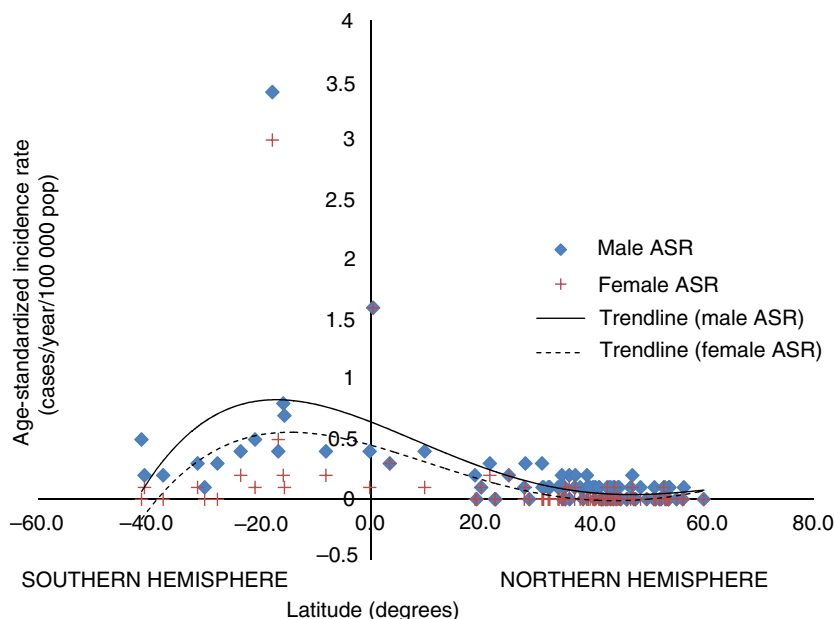
## Results and discussion

Africa has the highest age-standardised incidence rate of ocular SCC followed by Central and South America then Oceania (Australia, New Zealand and Hawaii), respectively (Table 2 and Figure 2). The rate in Africa is about 9–10 times higher than in Europe and North America. The highest incidence rate is 3.4 cases/year/100 000 among males and 3.0 cases/year/100 000 among females in Zimbabwe (Curado *et al.* 2007). Uganda follows with 1.6 cases/year/100 000 for males and females. Australia

comes third with 0.3–0.5 cases/year/100 000 in parts of that country. Other countries have rates between 0 and 0.1 cases/year/100 000. The rates have a right-skewed bell-shaped distribution peaking at latitude 16° South (Figure 3). Incidence rates are higher in the Southern Hemisphere than the Northern Hemisphere, with male ASR = 0.61 cases/year/100 000 (95% CI: 0.14–1.09) and female ASR = 0.33 (95% CI: –0.12 to 0.78) in the Southern Hemisphere, compared with male ASR = 0.10 (95% CI: 0.06–0.14) and female ASR = 0.05 (95% CI: 0.00–0.08) in the Northern Hemisphere.

The high rates in Africa are consistent with other estimates from the region. A Tanzanian study estimated the incidence of suspected OSSN from 2006 to 2008 using operating theatre records across the country. Although there was no histological confirmation in all cases, the incidence was found to be 2.2 cases/year/100 000 (Furahini & Lewallen 2010). Uganda reported a peak incidence of 3.5 cases/year/100 000 in 1992 (Ateanyi-Agaba 1995). More recent data from the Kampala Cancer Registry also show a marked increase, although it is reported as ocular cancer, rather than specifically as OSSN (Wabinga *et al.* 2000).

Cancer registry data in two African countries show that OSSN has become more prevalent with time. In Zimbabwe, the age-adjusted annual incidence rates of SCCC underwent a more than 10-fold increase from 0.17 to 1.8/100 000 between 1990 and 1999 (Masanganise *et al.* 2008) while the prevalence of OSSN among ocular

S. Gichuhi *et al.* Ocular surface squamous neoplasia in Africa

**Figure 3** The age-standardized incidence rates (ASR) of squamous cell carcinoma of the eye (ICD-O-3 C.69) for the period 1998–2002 (Curado *et al.* 2007).

**Table 3** The proportion of orbital exenterations performed due to ocular squamous cell carcinoma in different regions of the world

Year (ref.)	Country	No. of exenterations (N)	No. due to SCCC (n)	Proportion (n/N) (%)
2011 (Ackuaku-Dogbe 2011)	Ghana	25	19	76
2001 (Masanganise & Magava 2001)	Zimbabwe	23	13	57
2007 (Nemet <i>et al.</i> 2007)	Australia	38	12	32
2004 (Pushker <i>et al.</i> 2004)	India	26	3	15
2008 (Croce <i>et al.</i> 2008)	Italy*	6	1	13
2005 (Rahman <i>et al.</i> 2005)	UK†	69	6	9

\*Included children.

†Mainly elderly patients.

surface tumour biopsy specimens increased from 33% in 1996 to 58% by 2000 (Pola *et al.* 2003).

OSSN is the most common indication for orbital exenteration performed in adults in Africa (Table 3; Pola *et al.* 2003). This surgical procedure to excise all the orbital tissue including stripping the periosteum from the orbital walls is performed in cases with advanced disease. More than half ( $\geq 57\%$ ) the exenterations performed in Africa are for OSSN compared with 32% in Australia and 9–15% in Europe and India. Although available data does not clearly distinguish those performed for primary eyelid disease from conjunctival disease, SCC still emerges as an important cause in Africa. Eyelid SCC is uncommon in Africa (Templeton 1967, 1973).

#### Incidence of OSSN by age and sex

In temperate countries, OSSN remains a rare, slow-growing tumour of elderly males (70–80% are males

with a mean age of about 60 years; Lee & Hirst 1997; Tunc *et al.* 1999). In contrast, in tropical countries, particularly in Eastern and Southern Africa, the prevalence is highest among young people in their 30s and among women (50–70%; Table 4; Poole 1999; Pola *et al.* 2003; Chisi *et al.* 2006; Furahini & Lewallen 2010). Within East Africa, the pattern of SCCC in the 1960s differed to that seen today. In 1967, the average age of affected patients was 48 years, and males were four times more frequently affected than females (Templeton 1967).

Worldwide, IARC data show that the overall incidence is higher in males than females but the difference is not statistically significant (Figure 3 and Table 2). The mean male ASR worldwide is 0.18 cases/year/100 000 (95% CI: 0.09–0.26) and 0.08 (95% CI: 0.01–0.15) among females ( $P = 0.09$ ). Incidence is significantly higher in males than females except in Africa and Asia where both

**Table 4** The age and sex of patients affected by ocular surface squamous neoplasia (OSSN)

Year (ref.)	Country	Mean age (years)	Male (%)	Female (%)	Male:Female ratio
1995 (Ateenyi-Agaba 1995)	Uganda	33	52	48	1:2.3
2008 (Spitzer <i>et al.</i> 2008)	Malawi	33	42	58	1:2.1
2010 (Simbiri <i>et al.</i> 2010)	Botswana	39	39	61	1:1.6
2003 (Pola <i>et al.</i> 2003)	Zimbabwe	35	30	70	1:1.4
2002 (Mahomed & Chetty 2002)	S. Africa	37	50	50	1:1.3
2006 (Chisi <i>et al.</i> 2006)	Kenya	38	50	50	1:1
2012 (Makupa <i>et al.</i> 2012)	Tanzania	39	32	68	1:1
2009 (Ogun <i>et al.</i> 2009)	Nigeria	54	43	57	1:0.9
1999 (Tunc <i>et al.</i> 1999)	USA	64	70	30	1:0.4
2002 (McKelvie 2002)	Australia	69	77	23	1:0.3

sexes are equally affected (Table 2). Prevalence in Africa is higher in females than males (Table 4). This may be related to Africa having the highest prevalence of both HIV and HPV, which may increase the risk of OSSN in women and gender differences in mortality of HIV-infected adults. In South Africa, HIV-infected females have a longer life expectancy than HIV-infected males (Cornell *et al.* 2012; Johnson *et al.* 2013; Maskew *et al.* 2013). Men present in later stages of HIV/AIDS for anti-retroviral therapy (ART) and possibly have poorer adherence to ART (Taylor-Smith *et al.* 2010). This has also been observed in Latin America, China and Lao (Dou *et al.* 2011; Gonzalez *et al.* 2011; Bastard *et al.* 2013). In Europe, the response to ART and mortality is similar for both sexes (Perez-Molina *et al.* 2012; Thorsteinsson *et al.* 2012).

#### Variation in disease severity

There may be variation in disease stage at presentation, with more advanced disease present at time of surgery in East Africa, compared with other regions (Table 5; Chisi *et al.* 2006; Waddell *et al.* 2010; Kao *et al.* 2012; Makupa *et al.* 2012). This may reflect delayed presentation to ophthalmic services in this region, leading to more advanced pathology by the time of surgery. Histopathological reporting is also subjective, and pathologists may not always grade tumours the same way (Margo *et al.* 2002). Alternatively, the disease may be intrinsically more aggressive in the East African region or HIV worsens disease progression.

#### Risk factors

Various factors are thought to influence the causation of OSSN, but it is not clear how they interact or which is the most potent. The rising incidence of OSSN in recent decades may be driven by increased prevalence of these

factors. We found no systematic reviews of risk factors for OSSN after the literature search. Of the case-control studies found, two in Uganda and Australia examined the association with solar exposure; six in Africa examined the association with HIV; sixteen examined the association with HPV; seven in Africa, five in Asia, one in Brazil, two in USA and one in Australia. Two studies examined cigarette smoking in Uganda.

**Ultraviolet solar radiation.** Several cutaneous malignancies, including melanoma and SCC, have a strong association with solar radiation. It was first noted in the 1960s that SCCC was relatively common in East Africa, and this apparent excess risk was attributed to higher exposure to sunlight (Templeton 1967). There is a strong relationship between the incidence of SCCC and increasing Ultraviolet (UV) levels (Newton *et al.* 1996). Using IARC data and published measurements of ambient solar ultraviolet light, the incidence of SCCC was found to reduce by 49% for every 10° increase in latitude from 1.2 cases/year/100 000 (Table 7) in Uganda (latitude 0.3°) to <0.02/year/100 000 in the UK (latitude > 50°). More recently, the National Institutes of Health/American Association of Retired Persons (NIH-AARP) Diet and Health Study in the USA found a slightly lower risk of SCCC in those who lived >35° compared with ≤35° from the equator, although this was not statistically significant (adjusted Hazard Ratio = 0.92, 95% CI: 0.49–1.71; Emmanuel *et al.* 2012). The USA has comparatively lower HIV prevalence, solar irradiance and incidence of OSSN than Africa, which is bisected by the equator. The high incidence of ocular SCC near the equator may be related to high solar irradiance (the amount of solar radiant energy incident on a surface per unit area and per unit time) in the world (World Energy Council 2007).

A case-control study in Uganda adjusted for age, sex, residential district, and HIV serostatus demonstrated that the risk of OSSN was higher with increasing time spent

**Table 5** Stages of ocular surface squamous neoplasia (OSSN) seen at presentation in Africa and USA

Country year (ref.)	Stage of OSSN, <i>n</i> (%)						
	Mild dysplasia (CIN I)	Moderate dysplasia (CIN II)	Severe dysplasia (CIN III)	Carcinoma <i>in situ</i> (CIS)	Well differentiated SCC	Moderately differentiated SCC	Poorly differentiated SCC
Kenya 2006 (Chisi <i>et al.</i> 2006)	7 (21.9)				1 (3.1)	9 (28.1)	15 (46.9)
Uganda 2008 (de Koning <i>et al.</i> 2008)	17 (21.0)	18 (22.2)	22 (27.2)	0 (0)	24 (29.6)		
Uganda 2010 (Ateenyi-Agaba <i>et al.</i> 2010)	39 (29.3)				94 (70.7)		
Uganda 2010 (Waddell <i>et al.</i> 2010)	48 (15.1)	66 (20.8)	81 (25.5)	0 (0)	123 (38.7)		
Tanzania 2012 (Makupa <i>et al.</i> 2012)	28 (21.2)		73 (55.3)	0 (0)	31 (23.5)		
Malawi 2013 (Tiong <i>et al.</i> 2013)	1 (2.0)	5 (10.2)	9 (18.4)	17 (34.7)	17 (34.7)		
USA 2012 (Kao <i>et al.</i> 2012)	48 (8.1)	98 (16.4)	59 (9.9)	322 (54.0)	69 (11.6)		

in daylight (Waddell *et al.* 2010). Compared with those who reported spending up to 1 h a day in direct sunlight, the odds ratio (OR) for those who spent 2–4 h was 1.7 (95% CI: 1.2–2.4), and for those who spent 5 or more hours a day, it was 1.8 (95% CI: 1.1–3.1). A case–control study in Australia reported that the strongest risk factor was a past history of skin cancer (OR = 15, 95% CI: 2.0–113.6), although other factors, including outdoor activity, pale skin and irides and propensity to burn, were also important (Lee *et al.* 1994).

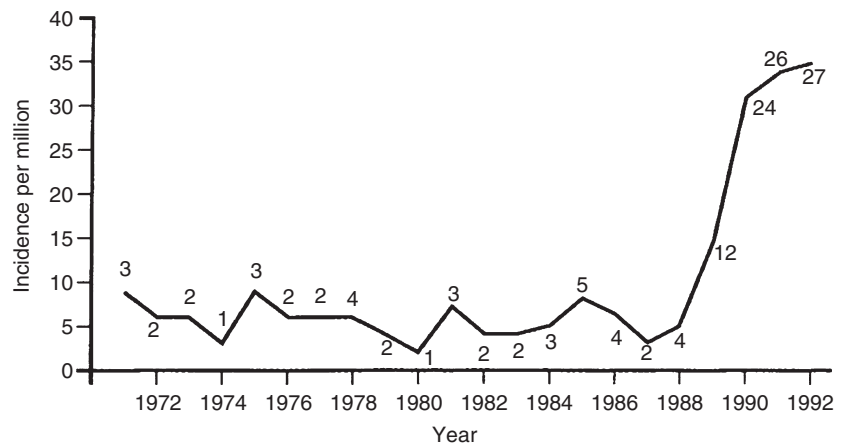
More direct evidence for UV radiation induced damage in the pathophysiology of SCCC was described in another case–control study in Uganda in which 52% of the cases had mutations in the tumour suppressor gene TP53 compared with 14% of controls (Ateenyi-Agaba *et al.* 2004a). The mutations were mainly of the CC TT type, consistent with UV-induced mutagenesis. This gene also downregulates the replication of HPV type 16 via the viral E2 protein, suggesting that its mutation may allow replication of HPV particles (Brown *et al.* 2008). Further, exposure to UV radiation is associated with altered expression of matrix metalloproteinases (MMPs) and the tissue inhibitors of these metalloproteinases (TIMPs), molecules that may be responsible for tissue invasion and metastasis of tumours (Ng *et al.* 2008).

In addition, OSSN lesions occur more often at the limbus. A study in Uganda demonstrated that tumours almost always occur in sun-exposed areas of the eye (Waddell *et al.* 2006). It is thought that the human eye is more exposed laterally, making this a large collecting zone of peripheral sunlight, which, depending on the incident angle and radius of curvature of the cornea, is focused on the limbus, lens and lid margin, which are the main foci of sun-related eye diseases such as pterygium, OSSN, cataract and lid malignancies (Malooof *et al.* 1994). Low doses of ambient sunlight received on every

day exposure inhibit immunity in the skin and internal organs (Halliday *et al.* 2012).

**HIV.** There is strong evidence that HIV is a major risk factor for OSSN. Uganda, which had a cancer registry since 1951, was the first country to report a dramatic increase in the annual incidence of SCCC shortly after the outbreak of HIV/AIDS. There was a sixfold increase from 0.6 cases/year/100 000 between 1970 and 1988 to 3.5/year/100 000 by 1992 (Figure 4; Ateenyi-Agaba 1995). A marked rise was also observed in the USA with the onset of the HIV pandemic (Guech-Ongey *et al.* 2008). At the same time, a US study observed a strong association in an HIV-infected cohort (OR = 13.0, 95% CI: 4–34; Goedert & Cote 1995). In Tanzania, regional incidence rates were significantly correlated with regional HIV prevalence (Pearson's  $r = 0.53$ ,  $P = 0.03$ ; Furahini & Lewallen 2010). The majority of patients (60–77%) with OSSN seen in Africa are HIV-infected (Table 6). A meta-analysis of 6 case–control studies (Table 7) in Uganda, Rwanda and Zimbabwe shows a strong association with HIV infection (pooled OR = 6.17, 95% CI: 4.83–7.89; Figure 5).

The association with HIV suggests that immunosuppression plays a role in OSSN; however, a linear association between the CD4 lymphocyte count and OSSN has not been confirmed. A cross-sectional study conducted in Tanzania found a median CD4 cell count of 71 cells/ $\mu$ l among HIV-infected individuals with OSSN (Makupa *et al.* 2012). HIV-infected cases tended to have larger lesions: 71% had lesions >5 mm in diameter *vs.* 27% among HIV-negative individuals (OR = 3.13, 95% CI: 1.5–6.5). HIV-infected cases were also more likely to develop recurrent tumours within a year of excision (82% *vs.* 18%; OR = 3.54, 95% CI: 1.12–11.2). However, there was no significant trend found between CD4 count and the grade of OSSN ( $P = 0.94$ ). In a Ugandan study,

S. Gichuhi *et al.* Ocular surface squamous neoplasia in Africa

**Figure 4** Sudden rise in the annual incidence rates of conjunctival SCCC in Kampala with the onset of the HIV pandemic – number of cases shown (Ateenyi-Agaba 1995).

**Table 6** Prevalence of HIV infection in cases of squamous cell carcinoma of the conjunctiva in Africa

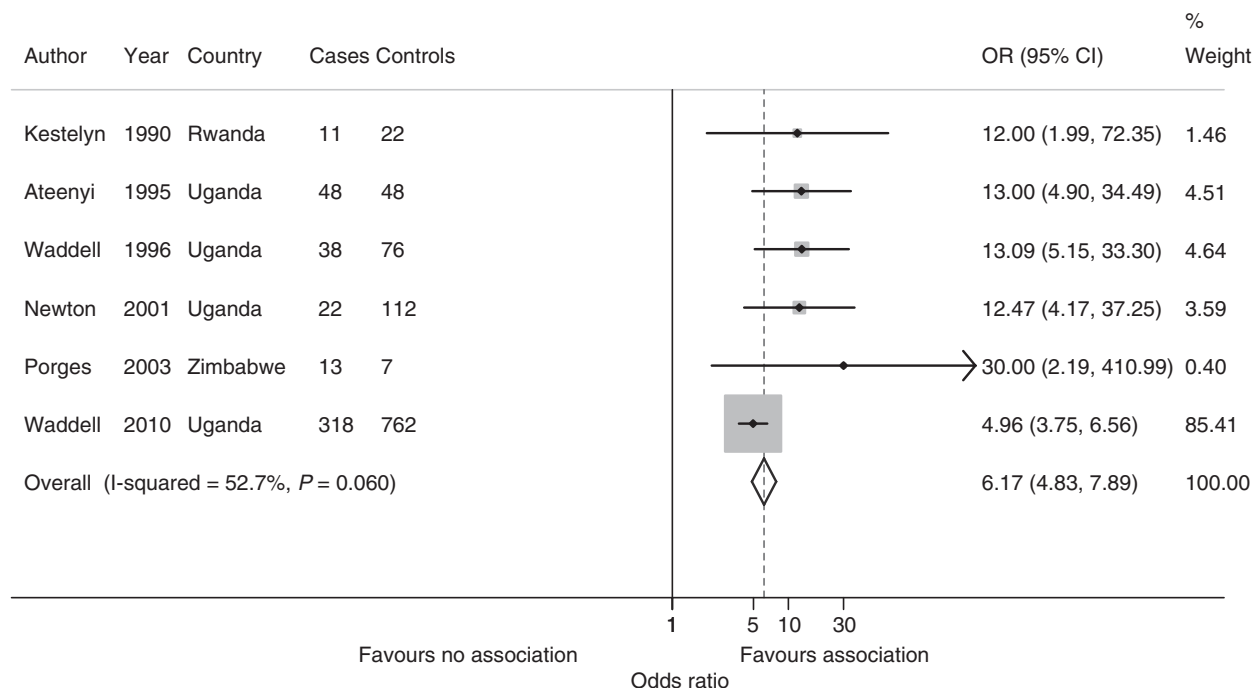
Year (ref.)	Country	Study period	HIV prevalence in SCCC cases (%)
2012 (Makupa <i>et al.</i> 2012)	Tanzania	2005–2008	60
2011 (Osahon <i>et al.</i> 2011)	Nigeria	1999–2009	75
2002 (Mahomed & Chetty 2002)	South Africa	1995–1997	71
1995 (Ateenyi-Agaba 1995)	Uganda	1990–1991	75
1996 (Waddell <i>et al.</i> 1996)	Uganda	1993–1994	71
2003 (Porges & Groisman 2003)	Zimbabwe	1993–1995	91
2001 (Newton <i>et al.</i> 2001)	Uganda	1994–1998	77

among 112 HIV-infected cases of CIN and invasive SCC, the median CD4 count at diagnosis was 111 cells/ $\mu$ L (IQR; 62–221; Waddell *et al.* 2006). Excess risks standardised incidence ratio (SIR = 19.5, 95% CI: 6.3–45.5) have also been observed among a cohort of kidney transplant recipients in Australia suggesting that immune suppression from other causes may play a role (Vajdic *et al.* 2007).

HAART does not reduce the incidence of SCCC according to data from the US HIV/AIDS Cancer Match (HACM) Study (Guech-Ongey *et al.* 2008) which compared SIRs in the pre-HAART and HAART eras among 491 048 adults aged  $\geq 15$  years with HIV/AIDS diagnosed from 1980 to 2004. The SIRs here estimate the excess risk of SCCC attributable to HIV/AIDS compared with a population with negligible HIV/AIDS prevalence and were similar at 12.0 (95% CI: 5.5–22.8) and 12.6 (95% CI: 4.6–27.4) in the pre- and post-HAART eras, respectively ( $P = 0.79$ ). There is, however, a case report of ART causing tumour regression in an otherwise inoperable case (Holkar *et al.* 2005).

**Human papilloma virus.** The relationship between human papilloma virus (HPV) and OSSN is rather controversial with variable results. (Tulvatana 2003;

Moubayed *et al.* 2004; Sen *et al.* 2007; de Koning *et al.* 2008; Guthoff *et al.* 2009; Simbiri *et al.* 2010; Yu *et al.* 2010). A review of 12 case series and 17 case-control studies concluded that there was no causal association between mucosal HPV types and OSSN while the role of cutaneous types was uncertain (de Koning *et al.* 2008). The studies included used different methods for testing of HPV (including PCR and serology), and different HPV types were examined. Conversely, a random-effects meta-analysis of various case-control studies shows that OSSN is associated with HPV infection in sub-Saharan Africa (pooled OR = 2.64, 95% CI: 1.27–5.49) and worldwide (pooled OR = 4.00, 95% CI: 2.11–7.57; Figure 6). The prevalence of HPV in OSSN ranges from 0% to 100% depending on geographical region with subtypes HPV18 and HPV16 being the most common (Table 8; di Girolamo 2012). Most African studies report prevalence of 75–85% (Ateenyi-Agaba *et al.* 2004b; Simbiri *et al.* 2010; Yu *et al.* 2010). HPV is more commonly isolated in OSSN than pterygium – on average, considering studies from different regions of the world, 33.8% of OSSN lesions and 18.6% of pterygia are HPV positive (di Girolamo 2012). There may be a true geographical variation in the prevalence of HPV in OSSN.

S. Gichuhi *et al.* Ocular surface squamous neoplasia in Africa

**Figure 5** Meta-analysis of case-control studies of HIV infection in ocular surface squamous neoplasia (OSSN) in Africa (fixed effect).

Differences in HPV prevalence in OSSN may be influenced by patient selection, sample handling in the operating theatre, preparation, storage, overseas shipping and the detection method. Variations may also be due to different testing methodology and the specific HPV types tested for. Most existing molecular diagnostic tests applied in OSSN testing for HPV were developed for cervical tissue testing. The sensitivity and specificity of various polymerase chain reaction (PCR) tests varies and may be influenced by various factors including the PCR design (nested, broad spectrum or type-specific), size of amplified product and choice of polymerase used (Munoz *et al.* 2012; Meshner *et al.* 2013). Detection of E6/E7 mRNA transcripts by quantitative reverse transcriptase–PCR (qRT-PCR) has been proposed as the gold standard for HPV testing (Smeets *et al.* 2007). However, RNA is unstable limiting this test to fresh frozen tissue (Kim *et al.* 2013). Testing for HPV DNA by PCR from paraffin-embedded archived tumour blocks may be complicated by contamination between samples at the time of initial tissue sectioning for DNA harvest (Boyd *et al.* 1996; Iftner & Villa 2003).

Generally, only a limited subset of HPV types has been investigated among OSSN cases. There are 170 genotypes of HPV described to date, which are broadly subdivided into cutaneous and mucosal types (de Villiers 2013).

There are conflicting reports on which of these two are more commonly associated with OSSN. One study conducted in Uganda reported that among OSSN cases, the prevalence of mucosal types was higher than cutaneous types (38% *vs.* 22%) while from another study in the same population, the prevalence of cutaneous types was higher than mucosal types (43.6% *vs.* 6.8%; Table 8; de Koning *et al.* 2008; Ateenyi-Agaba *et al.* 2010). Multiple HPV types have been found in individual patients with OSSN tumours. One Ugandan study reported multiple HPV types in 57.1% of SCCC and 75% of dysplasia cases by PCR (Ateenyi-Agaba *et al.* 2010). In Botswana, multiple HPV types were identified in all OSSN and all pterygium specimens by DNA sequencing (Simbiri *et al.* 2010). The HPV types found by sequencing ranged from 4 to 21 types per sample. The same study also described co-infection with multiple other viral types per individual in 17 of 18 (94%) histologically proven OSSN specimens by PCR; 83% were positive for Epstein–Barr virus (EBV), 72% were HPV positive, 67% were Kaposi’s sarcoma-associated herpesvirus (KSHV) positive, 67% were herpes simplex virus (HSV-1/2) positive and 56% were cytomegalovirus (CMV) positive. All the pterygium specimens from that study similarly had multiple viruses; 75% were positive for each of EBV, KSHV, CMV and HSV while 50% were



S. Gichuhi *et al.* **Ocular surface squamous neoplasia in Africa****Table 7** Characteristics of case–control studies included in the meta-analysis of HIV as a risk factor of ocular surface squamous neoplasia (OSSN)

Study period (ref.), Country	Cases	Controls
1989–1990 (Kestelyn <i>et al.</i> 1990), Rwanda	11 patients with clinical evidence of conjunctival dysplasia or malignancy seen at Centre Hospitalier de Kigali	22 controls. 2 controls per case from the same area matched for age and sex within 5 years. Referrals from elsewhere were excluded
1990–1991 (Ateenyi-Agaba 1995), Uganda	48 patients with conjunctival growths who presented to the eye clinic at Mulago Hospital, Kampala	48 patients matched for age and sex attending the same eye clinic with other eye diseases
1993–1994 (Waddell <i>et al.</i> 1996), Uganda	38 patients in seven countrywide eye clinics including New Mulago Hospital, Kampala who had suspicious conjunctival lesions had excision biopsy of the lesion	76 controls. 2 controls per case matched for age and sex. 16 Controls were patients in the eye clinic without neoplasia or clinical features of HIV disease; the remainder were general (non-eye clinic) anonymous outpatients at the same health units
1993–1995 (Porges & Groisman 2003), Zimbabwe	13 cases from patients who underwent excisional biopsy for conjunctival lesions at Bindura Provincial Hospital (Mashonaland Central, Zimbabwe)	7 controls. Patients were from the same group as cases but had benign lesions on histology
1994–1998 (Newton <i>et al.</i> 2001), Uganda	22 cases. Patients aged >15 years with a provisional diagnosis of cancer from all wards and out-patient clinics of the 4 main hospitals in Kampala: Mulago, Nsambya, Mengo and Rubaga	112 controls. 93 patients with tumours not suspected to be of infectious aetiology and 19 with non-malignant conditions
2001–2005 (Waddell <i>et al.</i> 2010), Uganda	318 cases recruited from country-wide ophthalmology clinics in Uganda. Anyone with a suspected OSSN was offered surgical treatment and histology, together with enrolment into a case-control study	762 controls were recruited from 2 sources. The first group comprised patients attending the ophthalmology clinics with concerns or conditions other than OSSN. This group also included those individuals who were originally recruited as cases, but where histology subsequently revealed another diagnosis. The second group comprised people who were recruited through the voluntary HIV counselling and testing (VCT) service

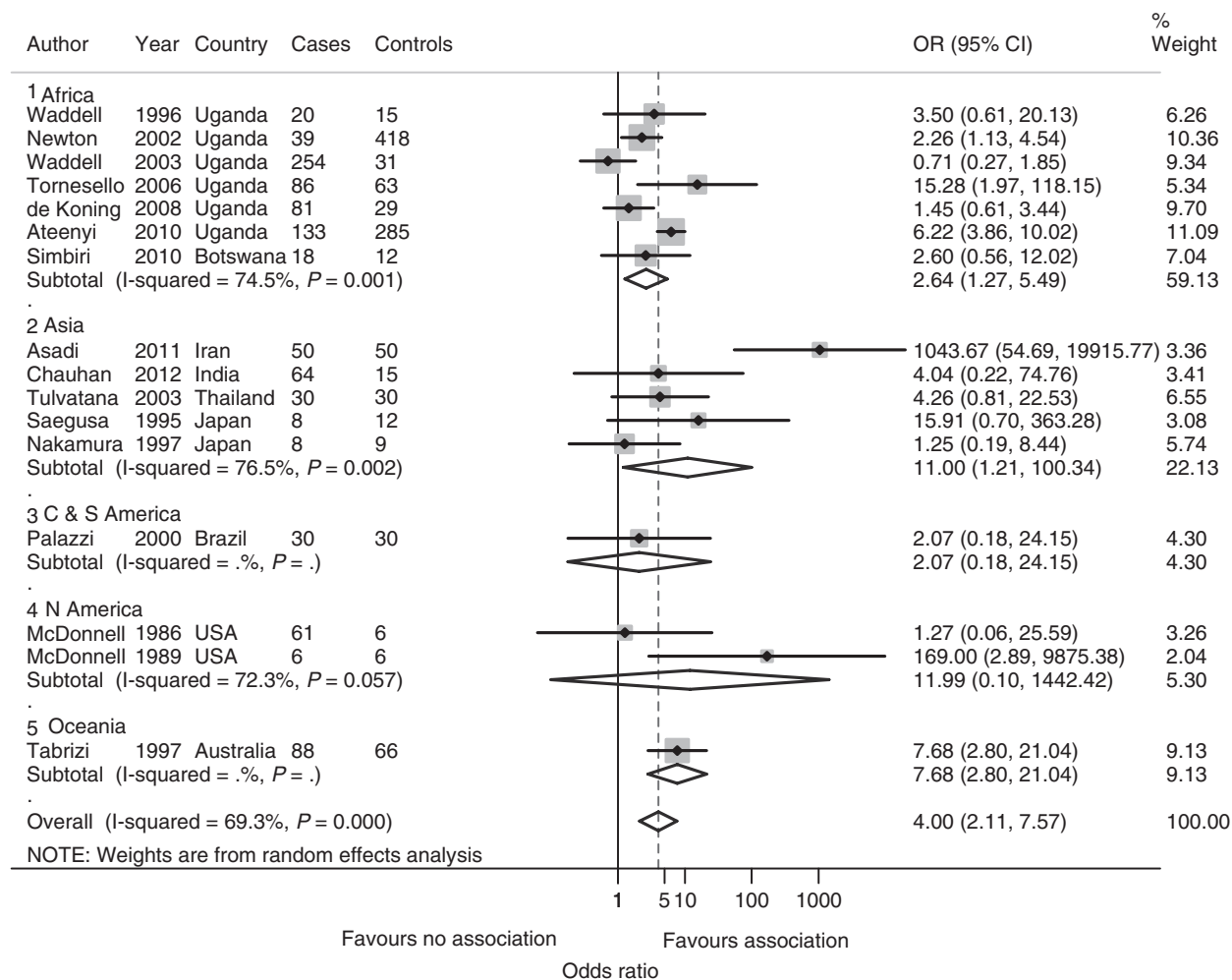
HPV positive. The proportion of HPV infection in this series was much higher than any other studies in the region have reported raising the question whether this could be due to the methodology used.

The mechanism by which HPV is associated with OSSN is unknown. HPV is associated with causation of metaplasia in squamocolumnar epithelial transition zones such as the corneoscleral limbus and eyelid skin of the eye, the cervix and anus where there is active cell turnover and continuous cell division to replace desquamated cells (Chow *et al.* 2010). HPV also promotes degradation of the p53 gene (Scheffner *et al.* 1990).

The epidemiology of OSSN is closely related to that of cervical cancer with respect to high incidence in Africa and the association with HIV and HPV mainly types 18 and 16 (Sun *et al.* 1997; Clifford *et al.* 2003; Stanley 2010). A meta-analysis of HPV prevalence reports worldwide shows that Africa has the highest adjusted prevalence

(22.1%; 95% CI: 20.9–23.4%) among women with cytologically normal cervical pap smears using PCR-based or high-risk Hybrid Capture 2 (HC-2) technology to detect HPV DNA (de Sanjose *et al.* 2007). Whether vaccination against HPV may help to reduce the incidence of OSSN remains to be seen (Hughes *et al.* 2008).

**Occupation.** Outdoor occupations have been associated with OSSN, probably related to UV solar radiation exposure. In Uganda, those with outdoor occupations had an OR of 1.7 (95% CI: 1.1–2.6) compared to those with indoor occupations (Waddell *et al.* 2010). Another in Uganda reported that 74% of 133 patients with SCCC or dysplasia had outdoor occupations (Ateenyi-Agaba *et al.* 2010). In Japan, exposure to petroleum products was also described as a risk factor for conjunctival intraepithelial neoplasia (synonym of OSSN) in a

S. Gichuhi *et al.* Ocular surface squamous neoplasia in Africa

**Figure 6** Meta-analysis of case-control studies of human papilloma virus (HPV) infection in ocular surface squamous neoplasia (OSSN) (random effects).

small age–sex-matched case–control study (Napora *et al.* 1990). Exposure to smoke from burning wood in the kitchen was described as a risk factor for cervical cancer among HPV-infected women in Honduras (Velema *et al.* 2002).

**Cigarette smoking.** Cigarette smoking is implicated in other squamous cell cancers (Haverkos 2004). There is, however, evidence of no effect from smoking on OSSN in Africa. In Uganda, two case–control studies showed that current smokers were not at a significantly higher risk for OSSN than non-smokers (Waddell *et al.* 2010; Ateenyi-Agaba *et al.* 2010; pooled OR = 1.40; 95% CI: 0.94–2.09; Figure 7). In a Nigerian series of 37 SCCC cases, only two patients (5.4%) had a history of cigarette smok-

ing (Ogun *et al.* 2009) while in a series from Australia, 5 of 11 cases of SCCC (45%) were smokers (McKelvie 2002).

**Allergy.** There is little evidence that allergic conjunctivitis is a risk factor. Among 215 SCCC cases in Tanzania, 1.9% had allergic conjunctivitis (Poole 1999). In Rwanda, allergic conjunctivitis was found in 4% of children and was responsible for 3–6% of hospital visits of all ages (de Smedt *et al.* 2013). In a case–control study in Uganda, none of the cases of OSSN had a history of allergic eye disease (Waddell *et al.* 2010). However, a case series of SCCC from Germany reported that 6/10 cases had atopic eczema, so this may be of more importance in temperate climates (Heinz *et al.* 2003).

S. Gichuhi *et al.* Ocular surface squamous neoplasia in Africa**Table 8** Studies on the prevalence and subtypes of human papilloma virus (HPV) in ocular surface squamous neoplasia (OSSN)

Lead author (ref.)	Year	Country	Disease included	Sample size	Diagnostic method	HPV prevalence (%)	HPV subtypes found	Tissue used
<i>Africa</i>								
Ateenyi-Agaba (Ateenyi-Agaba <i>et al.</i> 2004a)	2004	Uganda	SCC	21	PCR	86	14, 27, 37, 38	Fresh frozen tissue shipped to France
Simbiri (Simbiri <i>et al.</i> 2010)	2010	Botswana	OSSN	30	PCR	72	6, 11, 16, 18, 31, 33	Fresh tissue shipped in tissue transport medium to USA
Waddell (Waddell <i>et al.</i> 2003)	2003	Uganda	CIN I–III	254	DNA sequencing	100	21 subtypes*	
Newton (Newton <i>et al.</i> 2002)	2002	Uganda	SCC	39	IHC	72	?	Plasma shipped in dry ice to France
de Koning (de Koning <i>et al.</i> 2008)	2008	Uganda	CIN I–III	17	ISH	61	?	Serum shipped in dry ice to France
Ateenyi-Agaba (Ateenyi-Agaba <i>et al.</i> 2010)	2010	Uganda	SCC	94	anti-HPV antibodies	15	16	Formalin-fixed tissue shipped overseas
Tornesello (Tornesello <i>et al.</i> 2006)	2006	Uganda	CIN I	16	anti-HPV antibodies	36	16, 18, 45	
			CIN II	18	PCR	47	35% gen, 29% cut	
			CIN III	22	PCR	56	50% gen, 28% cut	
			SCC	24	PCR	45	27% gen, 23% cut	
			SCC	94	PCR	22	42% gen, 13% cut	
			Dysplasia	39	PCR	45	6.4% muc, 44.7% cut	Fresh frozen biopsies
			CIN I	16	PCR	41	7.7% muc, 41% cut	shipped to the Netherlands
			CIN II	18	PCR	31	20, CJ198, indeterm ?	
			CIN III	23	PCR	33	18, 38, 100, DL473, PPHLIFR	
			SCC	29	PCR	13	18, 100	
			Dysplasia	10	PCR	3	14, 20, Cj198	
<i>North America</i>								
Scott (Scott <i>et al.</i> 2002)	2002	USA	Dysplasia	10	PCR	100	16, 18	Formalin-fixed paraffin-embedded tissue
Odrich (Odrich <i>et al.</i> 1991)	1991	USA	SCC	3	PCR	100	16	?
McDonnell (McDonnell <i>et al.</i> 1992)	1992	USA	OSSN	42	PCR/DB	88	16	Formalin-fixed paraffin-embedded tissue
Lauer (Lauer <i>et al.</i> 1990)	1990	USA	OSSN	5	PCR	80	16, 18	?
Dushku (Dushku <i>et al.</i> 1999)	1999	USA	OSSN	8	PCR	0	Nil detected	Fresh tissue
<i>Asia</i>								
Kuo (Kuo <i>et al.</i> 2006)	2006	Taiwan	Dysplasia	9	PCR	100	6, 11, 16, 18, 33, 58, 72	Formalin-fixed paraffin-embedded tissue
Karcioglu (Karcioglu & Issa 1997)	1997	Saudi Arabia	CIS/SCC	45	PCR	56	16, 18	Formalin-fixed paraffin-embedded tissue
Nakamura (Nakamura <i>et al.</i> 1997)	1997	Japan	OSSN	8	PCR/IHC	50	16, 18	Formalin-fixed paraffin-embedded tissue

(continued)

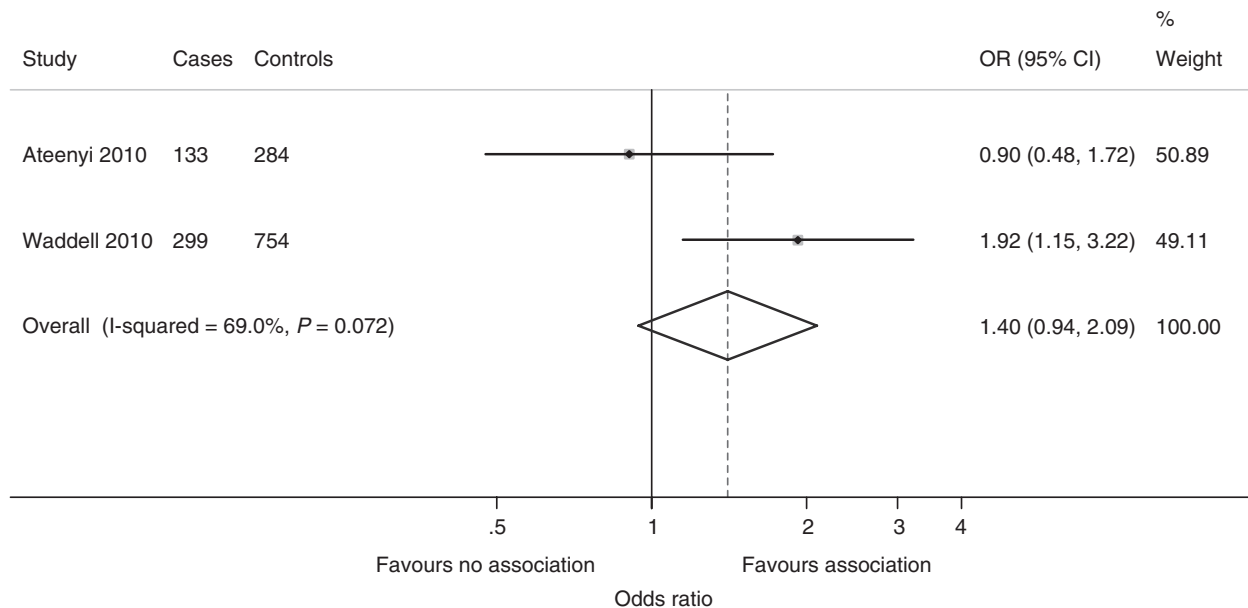
S. Gichuhi *et al.* Ocular surface squamous neoplasia in Africa

Table 8 (Continued)

Lead author (ref.)	Year	Country	Disease included	Sample size	Diagnostic method	HPV prevalence (%)	HPV subtypes found	Tissue used
Saegusa (Saegusa <i>et al.</i> 1995)	1995	Japan	OSSN	8	PCR/ISH	38	16	Formalin-fixed paraffin-embedded tissue
Toth (Toth <i>et al.</i> 2000)	2000	Saudi Arabia	SCC	16	PCR	25	16	Formalin-fixed paraffin-embedded tissue
Manderwad (Manderwad <i>et al.</i> 2009)	2009	India	OSSN	48	PCR/ISH-CARD	0	Nil detected	Formalin-fixed paraffin-embedded tissue supplemented with 7 fresh tissues
Eng (Eng <i>et al.</i> 2002)	2002	Taiwan	OSSN	20	PCR	0	Nil detected	Formalin-fixed paraffin-embedded tissue
Tulvatana (Tulvatana 2003)	2003	Thailand	OSSN	30	PCR/DB	0	Nil detected	Formalin-fixed paraffin-embedded tissue
Sen (Sen <i>et al.</i> 2007)	2007	India	OSSN	30	IHC	0	Nil detected	Formalin-fixed, paraffin-embedded tissue
<i>Oceania</i>								
Tabrizi (Tabrizi <i>et al.</i> 1997)	1997	Australia	OSSN	88	PCR	39	6, 11, 13, 16, 18	Formalin-fixed paraffin-embedded tissue
<i>Europe</i>								
Auw-Haedrich (Auw-Haedrich <i>et al.</i> 2006)	2008	Germany	Dysplasia	12	PCR	17	16	Freshly prepared formalin-fixed paraffin-embedded tissue
Toth (Toth <i>et al.</i> 2000)	2000	Hungary	SCC	7	PCR	14	18	Formalin-fixed paraffin-embedded tissue
Reszec (Reszec & Sulkowski 2005)	2005	Poland	SCC	11		9	16, 18	?
Guthoff (Guthoff <i>et al.</i> 2009)	2009	Germany	OSSN	31	PCR/IHC	0	Nil detected	Formalin-fixed paraffin-embedded tissue
Tuppurainen (Tuppurainen <i>et al.</i> 1992)	1992	Finland	GIS/SCC	4	PCR	0	Nil detected	?

? – means unclear or not mentioned.

\*The 21 subtypes were HPV types 1, 3, 7, 11, 13, 16, 18, 29, 39, 40, 43, 45, 59, 61, 68, 70, 77, 85, 89, 91, 97.

S. Gichuhi *et al.* Ocular surface squamous neoplasia in Africa

**Figure 7** Meta-analysis of case-control studies in Uganda on cigarette smoking and ocular surface squamous neoplasia (OSSN) in Africa (fixed effect).

*Xeroderma pigmentosum.* Xeroderma pigmentosum (XP), a rare, inherited skin disease characterised by high sensitivity to UV damage is associated with a high prevalence (40%) of specific mutations of the TP53 tumour suppressor gene (Dumaz *et al.* 1993). Over a 25-year period in Zimbabwe, in a series of 12 cases, 2 had SCCC while the rest had SCC of the skin, lip or tongue (Chidzonga *et al.* 2009). From a series of 7 XP cases in India, 6 of the 14 eyes (42.9%) had invasive SCC and eight eyes (57.1%) had CIN (Gupta *et al.* 2011). A larger series of 32 cases in France found that 59% of them had ocular and periocular malignancies (Touzri *et al.* 2008).

*Vitamin A deficiency.* The importance of vitamin A in maintaining the health of the ocular surface is well known, but the role of vitamin A deficiency in OSSN has not been established. Deficiency of vitamin A induces keratinisation of the ocular surface (Beitch 1970; Pfister & Renner 1978). Keratinisation is commonly observed as leucoplakia in OSSN lesions (Figure 1). There is a synergistic interaction between vitamin A and zinc in maintenance of the corneal and conjunctival epithelium (Kanazawa *et al.* 2002). In South Africa, it was shown that 54% of HIV-infected adults are deficient in vitamin A (plasma retinol  $<1.05 \mu\text{M}$ ) and 33% deficient in zinc ( $<10.7 \mu\text{M}$ ; Visser *et al.* 2003). In Ethiopia, 53% of HIV-infected adults were deficient in vitamin A (Fufa

*et al.* 2009). As most patients with OSSN are also HIV-infected, it is plausible that vitamin A deficiency contributes to the aetiology.

*Other risk factors.* There is limited evidence of a role for exposure to dust, ocular trauma and pre-existing benign conjunctival lesions such as pterygia and pingueculae (Templeton 1967; Margo & Groden 1986; Waddell *et al.* 2010).

*Protective factors.* One of the Ugandan case-control studies found that some factors are associated with a lower risk for SCCC such as higher personal income (adjusted OR = 0.4, 95% CI: 0.3–0.7) and decreasing age at leaving home ( $P = 0.05$ ), perhaps reflecting less exposure to sunlight consequent to rural-to-urban migration (Newton *et al.* 2002).

#### Aetiological model of OSSN

Various models have been proposed to simultaneously address the role of two or more risk factors in cancer causation within hierarchical levels (Victoria *et al.* 1997). Most such models focus on social and environmental hypothesis but do not incorporate biological factors. A recently proposed framework called Multi-level Biological And Social Integrative Construct (MBASIC) includes

S. Gichuhi *et al.* **Ocular surface squamous neoplasia in Africa**

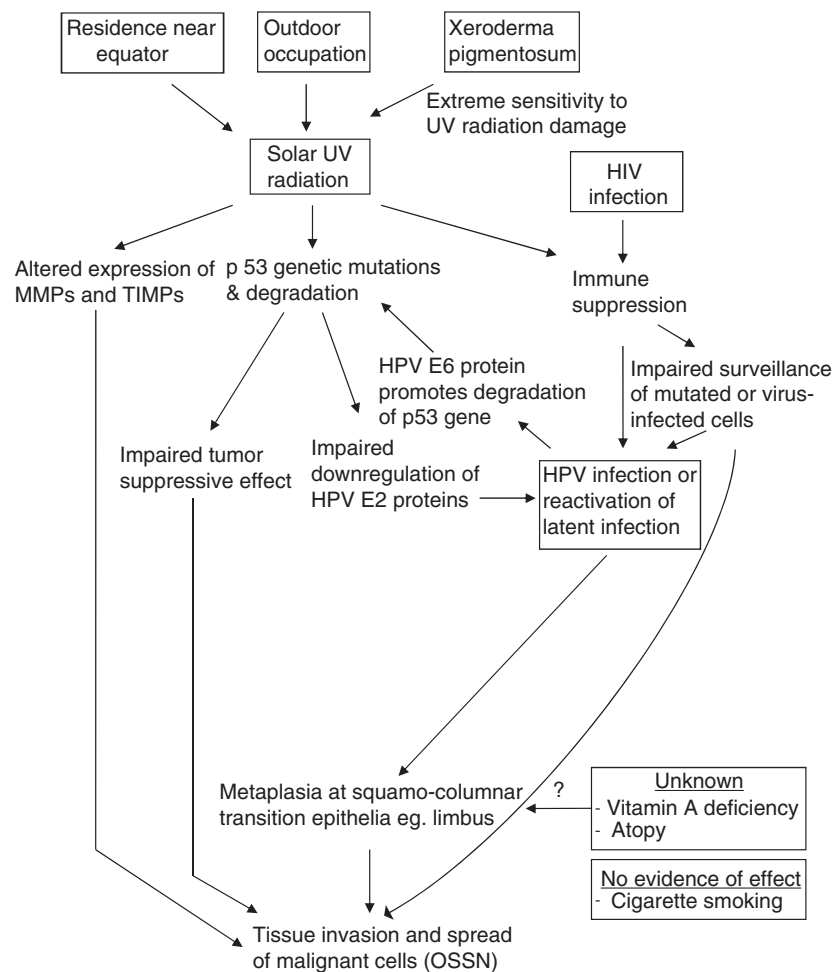
biological factors together with macro-environmental and individual level factors (Lynch & Rebbeck 2013). Using the existing evidence reviewed in this article, we propose an aetiological model that might explain how the risk factors discussed may be involved development of OSSN (Figure 8).

**Conclusions**

OSSN is a disease of increasing importance in Africa. A triad of ultraviolet solar radiation, HIV and HPV form the major risk factors and this may explain the high incidence rates in Africa. There is evidence from case-control studies that exposure to UV radiation, outdoor occupations – perhaps due to exposure to sunlight, HIV and

HPV infection are associated with a higher risk for OSSN. These studies also show no evidence of effect of cigarette smoking. Dust, ocular trauma and pre-existing benign conjunctival tumours may play a role. Although mentioned in the literature, the effect of atopy and xeroderma pigmentosa is unclear. The effect of vitamin A deficiency has not been examined in case-control studies.

The highest incidence of OSSN is found in Africa, where males and females are equally affected, unlike other continents where male disease predominates. This probably reflects that African women have increased risk due to their higher prevalence of HIV and HPV infections. As people with HIV are living longer, and given no evidence that ART reduces risk of OSSN, one could expect incidence of OSSN to increase in Africa in coming years.



MMPs - matrix metalloproteinases  
 TIMPs - tissue inhibitors of metalloproteinases

**Figure 8** An aetiological model illustrating how ocular surface squamous neoplasia (OSSN) might develop. MMPs, matrix metalloproteinases; TIMPs, tissue inhibitors of metalloproteinases.

S. Gichuhi *et al.* **Ocular surface squamous neoplasia in Africa**

Currently, the best available options for OSSN control remain early detection and effective treatment. However, there are no early non-invasive diagnostic methods in use and no trial evidence to guide treatment. OSSN is currently largely neglected by both eye and HIV care programmes. Eye care programmes prioritise preventable blindness while OSSN often in early stages does not affect vision. OSSN may, however, lead to facial disfigurement and death in late stages. In Africa, a key research question is whether scale-up of ART and HPV vaccination will impact on OSSN.

**Acknowledgements**

SG received funding from the British Council for Prevention of Blindness (BCPB) to conduct this study. MJB is supported by The Wellcome Trust (Grant Number 098481/Z/12/Z). We acknowledge Benjamin D. Hennig from the University of Oxford (<http://www.viewsoftheworld.net>) for help with preparing the incidence map (Figure 2).

**References**

- Ackuaku-Dogbe E (2011) Review of orbital exenterations in Korle-Bu teaching hospital. *Ghana Medical Journal* **45**, 45–49.
- American Joint Committee on Cancer 2010. Carcinoma of the conjunctiva. In: *Cancer Staging Handbook*, 7th edn (eds SB Edge, DR Byrd, CC Compton, AG Fritz, FL Greene & A Trotti) Springer, New York, 597.
- Ateenyi-Agaba C (1995) Conjunctival squamous-cell carcinoma associated with HIV infection in Kampala, Uganda. *Lancet* **345**, 695–696.
- Ateenyi-Agaba C, Dai M, le Calvez F *et al.* (2004a) TP53 mutations in squamous-cell carcinomas of the conjunctiva: evidence for UV-induced mutagenesis. *Mutagenesis* **19**, 399–401.
- Ateenyi-Agaba C, Weiderpass E, Smet A *et al.* (2004b) Epidermodysplasia verruciformis human papillomavirus types and carcinoma of the conjunctiva: a pilot study. *British Journal of Cancer* **90**, 1777–1779.
- Ateenyi-Agaba C, Franceschi S, Wabwire-Mangen F *et al.* (2010) Human papillomavirus infection and squamous cell carcinoma of the conjunctiva. *British Journal of Cancer*, **102**, 262–267.
- Auw-Haedrich C, Sundmacher R, Freudenberg N *et al.* (2006) Expression of p63 in conjunctival intraepithelial neoplasia and squamous cell carcinoma. *Graefes Archive for Clinical and Experimental Ophthalmology* **244**, 96–103.
- Bastard M, Soulinphumy K, Phimmason P *et al.* (2013) Women experience a better long-term immune recovery and a better survival on HAART in Lao People's Democratic Republic. *BMC Infectious Diseases* **13**, 27.
- Basti S & Macsai MS (2003) Ocular surface squamous neoplasia: a review. *Cornea* **22**, 687–704.
- Beitch I (1970) The induction of keratinization in the corneal epithelium. A comparison of the “dry” and vitamin A-deficient eyes. *Investigative Ophthalmology* **9**, 827–843.
- Boyd AS, Annarella M, Rapini RP, Adler-Storhthz K & Ducic M (1996) False-positive polymerase chain reaction results for human papillomavirus in lichen planus. Potential laboratory pitfalls of this procedure. *Journal of the American Academy of Dermatology* **35**, 42–46.
- Brown C, Kowalczyk AM, Taylor ER, Morgan IM & Gaston K (2008) P53 represses human papillomavirus type 16 DNA replication via the viral E2 protein. *Virology Journal* **5**, 5.
- Chidzonga MM, Mahomva L, Makunike-Mutasa R & Masanganise R (2009) Xeroderma pigmentosum: a retrospective case series in Zimbabwe. *Journal of Oral and Maxillofacial Surgery* **67**, 22–31.
- Chisi SK, Kollmann MK & Karimurio J (2006) Conjunctival squamous cell carcinoma in patients with human immunodeficiency virus infection seen at two hospitals in Kenya. *East African Medical Journal* **83**, 267–270.
- Chow LT, Broker TR & Steinberg BM (2010) The natural history of human papillomavirus infections of the mucosal epithelia. *APMIS: Acta Pathologica, Microbiologica, et Immunologica Scandinavica* **118**, 422–449.
- Clifford GM, Smith JS, Plummer M, Munoz N & Franceschi S (2003) Human papillomavirus types in invasive cervical cancer worldwide: a meta-analysis. *British Journal of Cancer* **88**, 63–73.
- Cornell M, Schomaker M, Garone DB *et al.* (2012) Gender differences in survival among adult patients starting antiretroviral therapy in South Africa: a multicentre cohort study. *PLoS Medicine* **9**, e1001304.
- Croce A, Moretti A, D'agostino L & Zingariello P (2008) Orbital exenteration in elderly patients: personal experience. *Acta Otorhinolaryngologica Italica* **28**, 193–199.
- Curado MP, Edwards B, Shin HR *et al.* (eds.) (2007). *Cancer incidence in Five Continents*. International Agency for Research on Cancer, Lyon, France.
- de Koning MN, Waddell K, Magyezi J *et al.* (2008) Genital and cutaneous human papillomavirus (HPV) types in relation to conjunctival squamous cell neoplasia: a case-control study in Uganda. *Infectious Agents and Cancer* **3**, 12.
- de Sanjose S, Diaz M, Castellsague X *et al.* (2007) Worldwide prevalence and genotype distribution of cervical human papillomavirus DNA in women with normal cytology: a meta-analysis. *The Lancet Infectious Diseases* **7**, 453–459.
- de Smedt S, Wildner G & Kestelyn P (2013) Vernal keratoconjunctivitis: an update. *British Journal of Ophthalmology* **97**, 9–14.
- de Villiers EM (2013). *Cross-roads in the classification of papillomaviruses*. Virology.
- di Girolamo N (2012) Association of human papilloma virus with pterygia and ocular-surface squamous neoplasia. *Eye (London, England)* **26**, 202–211.
- Dou Z, Xu J, Jiao JH *et al.* (2011) Gender difference in 2-year mortality and immunological response to ART in an HIV-infected Chinese population 2006–2008. *PLoS One* **6**, e22707.
- Dumaz N, Drougard C, Sarasin A & Daya-Grosjean L (1993) Specific UV-induced mutation spectrum in the p53 gene of

S. Gichuhi *et al.* Ocular surface squamous neoplasia in Africa

- skin tumors from DNA-repair-deficient xeroderma pigmentosum patients. *Proceedings of the National Academy of Sciences, USA* 90, 10529–10533.
- Dushku N, Hatcher SL, Albert DM & Reid TW (1999) p53 expression and relation to human papillomavirus infection in pingueculae, pterygia, and limbal tumors. *Archives of Ophthalmology* 117, 1593–1599.
- Emmanuel B, Ruder E, Lin SW, Abnet C, Hollenbeck A & Mbulaitaye S (2012) Incidence of squamous-cell carcinoma of the conjunctiva and other eye cancers in the NIH-AARP Diet and Health Study. *Eccancermedicalsience* 6, 254.
- Eng HL, Lin TM, Chen SY, Wu SM & Chen WJ (2002) Failure to detect human papillomavirus DNA in malignant epithelial neoplasms of conjunctiva by polymerase chain reaction. *American Journal of Clinical Pathology* 117, 429–436.
- Fufa H, Umata M, Taffesse S, Mokhtar N & Aguenauou H (2009) Nutritional and immunological status and their associations among HIV-infected adults in Addis Ababa, Ethiopia. *Food and Nutrition Bulletin* 30, 227–232.
- Furahini G & Lewallen S (2010) Epidemiology and management of ocular surface squamous neoplasia in Tanzania. *Ophthalmic Epidemiology* 17, 171–176.
- Gichuhi S & Irlam JH (2013) Interventions for squamous cell carcinoma of the conjunctiva in HIV-infected individuals. *Cochrane Database Systematic Review*, 2, CD005643.
- Goedert JJ & Cote TR (1995) Conjunctival malignant disease with AIDS in USA. *Lancet* 346, 257–258.
- Gonzalez MA, Martin L, Munoz S & Jacobson JO (2011) Patterns, trends and sex differences in HIV/AIDS reported mortality in Latin American countries: 1996–2007. *BMC Public Health* 11, 605.
- Grossniklaus HE, Green WR, Luckenbach M & Chan CC (1987) Conjunctival lesions in adults. A clinical and histopathologic review. *Cornea* 6, 78–116.
- Guech-Ongey M, Engels EA, Goedert JJ, Biggar RJ & Mbulait-eye SM (2008) Elevated risk for squamous cell carcinoma of the conjunctiva among adults with AIDS in the United States. *International Journal of Cancer* 122, 2590–2593.
- Gupta N, Sachdev R & Tandon R (2011) Ocular surface squamous neoplasia in xeroderma pigmentosum: clinical spectrum and outcome. *Graefes Archive for Clinical and Experimental Ophthalmology* 249, 1217–1221.
- Guthoff R, Marx A & Stroebel P (2009) No evidence for a pathogenic role of human papillomavirus infection in ocular surface squamous neoplasia in Germany. *Current Eye Research* 34, 666–671.
- Halliday GM, Damian DL, Rana S & Byrne SN (2012) The suppressive effects of ultraviolet radiation on immunity in the skin and internal organs: implications for autoimmunity. *Journal of Dermatological Science* 66, 176–182.
- Haverkos HW (2004) Viruses, chemicals and co-carcinogenesis. *Oncogene* 23, 6492–6499.
- Heinz C, Fanihagh F & Steuhl KP (2003) Squamous cell carcinoma of the conjunctiva in patients with atopic eczema. *Cornea* 22, 135–137.
- Hirst LW (2007) Randomized controlled trial of topical mitomycin C for ocular surface squamous neoplasia: early resolution. *Ophthalmology* 114, 976–982.
- Holkar S, Mudhar HS, Jain A *et al.* (2005) Regression of invasive conjunctival squamous carcinoma in an HIV-positive patient on antiretroviral therapy. *International Journal of STD and AIDS* 16, 782–783.
- Hughes DS, Powell N & Fiander AN (2008) Will vaccination against human papillomavirus prevent eye disease? A review of the evidence. *British Journal of Ophthalmology* 92, 460–465.
- Iftner T & Villa LL (2003) Chapter 12: Human papillomavirus technologies. *Journal of the National Cancer Institute, Monographs* 31, 80–88.
- Johnson LF, Mossong J, Dorrington RE *et al.* (2013) Life expectancies of South African adults starting antiretroviral treatment: collaborative analysis of cohort studies. *PLoS Medicine* 10, e1001418.
- Kanazawa S, Kitaoka T, Ueda Y, Gong H & Amemiya T (2002) Interaction of zinc and vitamin A on the ocular surface. *Graefes Archive for Clinical and Experimental Ophthalmology* 240, 1011–1021.
- Kao AA, Galor A, Karp CL, Abdelaziz A, Feuer WJ & Dubovy SR (2012) Clinicopathologic correlation of ocular surface squamous neoplasms at bascom palmer eye institute: 2001 to 2010. *Ophthalmology* 119, 1773–1776.
- Karcioglu ZA & Issa TM (1997) Human papilloma virus in neoplastic and non-neoplastic conditions of the external eye. *British Journal of Ophthalmology* 81, 595–598.
- Kestelyn P, Stevens AM, Ndayambaje A, Hanssens M & van de Perre P (1990) HIV and conjunctival malignancies. *Lancet* 336, 51–52.
- Kim Y, Choi KR, Chae MJ *et al.* (2013) Stability of DNA, RNA, cytomorphology, and immunoantigenicity in Residual ThinPrep Specimens. *APMIS: Acta Pathologica, Microbiologica, et Immunologica Scandinavica* doi: 10.1111/apm.12082 [Epub ahead of print].
- Kuo KT, Chang HC, Hsiao CH & Lin MC (2006) Increased Ki-67 proliferative index and absence of P16INK4 in CIN-HPV related pathogenic pathways different from cervical squamous intraepithelial lesion. *British Journal of Ophthalmology* 90, 894–899.
- Lauer SA, Malter JS & Meier JR (1990) Human papillomavirus type 18 in conjunctival intraepithelial neoplasia. *American Journal of Ophthalmology* 110, 23–27.
- Lee GA & Hirst LW (1992) Incidence of ocular surface epithelial dysplasia in metropolitan Brisbane. A 10-year survey. *Archives of Ophthalmology* 110, 525–527.
- Lee GA & Hirst LW (1995) Ocular surface squamous neoplasia. *Survey of Ophthalmology* 39, 429–450.
- Lee GA & Hirst LW (1997) Retrospective study of ocular surface squamous neoplasia. *Australian and New Zealand Journal of Ophthalmology* 25, 269–276.
- Lee GA, Williams G, Hirst LW & Green AC (1994) Risk factors in the development of ocular surface epithelial dysplasia. *Ophthalmology* 101, 360–364.



S. Gichuhi *et al.* **Ocular surface squamous neoplasia in Africa**

- Lee SB, Au Eong KG, Saw SM, Chan TK & Lee HP (2000) Eye cancer incidence in Singapore. *British Journal of Ophthalmology*, **84**, 767–770.
- Lynch SM & Rebbeck TR (2013) Bridging the gap between biologic, individual, and macroenvironmental factors in cancer: a multilevel approach. *Cancer Epidemiology Biomarkers & Prevention* **22**, 485–495.
- Mahomed A & Chetty R (2002) Human immunodeficiency virus infection, Bcl-2, p53 protein, and Ki-67 analysis in ocular surface squamous neoplasia. *Archives of Ophthalmology* **120**, 554–558.
- Makupa II, Swai B, Makupa WU, White VA & Lewallen S (2012) Clinical factors associated with malignancy and HIV status in patients with ocular surface squamous neoplasia at Kilimanjaro Christian Medical Centre, Tanzania. *British Journal of Ophthalmology*, **96**, 482–484.
- Maloo AJ, Ho A & Coroneo MT (1994) Influence of corneal shape on limbal light focusing. *Investigative Ophthalmology & Visual Science* **35**, 2592–2598.
- Manderwad GP, Kannabiran C, Honavar SG & Vemuganti GK (2009) Lack of association of high-risk human papillomavirus in ocular surface squamous neoplasia in India. *Archives of Pathology and Laboratory Medicine* **133**, 1246–1250.
- Margo CE & Groden LR (1986) Squamous cell carcinoma of the cornea and conjunctiva following a thermal burn of the eye. *Cornea* **5**, 185–188.
- Margo CE, Harman LE & Mulla ZD (2002) The reliability of clinical methods in ophthalmology. *Survey of Ophthalmology* **47**, 375–386.
- Masanganise R & Magava A (2001) Orbital exenterations and squamous cell carcinoma of the conjunctiva at Sekuru Kaguvi Eye Unit, Zimbabwe. *Central African Journal of Medicine* **47**, 196–199.
- Masanganise R, Rusakaniko S, Makunike R *et al.* (2008) A historical perspective of registered cases of malignant ocular tumors in Zimbabwe (1990 to 1999). Is HIV infection a factor? *Central African Journal of Medicine* **54**, 28–32.
- Maskew M, Brennan AT, Westreich D, McNamara L, Macphail AP & Fox MP (2013) Gender differences in mortality and CD4 count response among virally suppressed HIV-positive patients. *Journal of Women's Health (2002)* **22**, 113–120.
- McDonnell JM, McDonnell PJ & Sun YY (1992) Human papillomavirus DNA in tissues and ocular surface swabs of patients with conjunctival epithelial neoplasia. *Investigative Ophthalmology & Visual Science* **33**, 184–189.
- McKelvie PA (2002) Squamous cell carcinoma of the conjunctiva: a series of 26 cases. *British Journal of Ophthalmology* **86**, 168–173.
- Mesher D, Szarewski A, Cadman L *et al.* (2013) Comparison of human papillomavirus testing strategies for triage of women referred with low-grade cytological abnormalities. *European Journal of Cancer* **49**, 2179–2186.
- Moubayed P, Mwakyoma H & Schneider DT (2004) High Frequency of Human Papillomavirus 6/11, 16, and 18 Infections in Precancerous Lesions and Squamous Cell Carcinoma of the Conjunctiva in Subtropical Tanzania. *American Journal of Clinical Pathology* **122**, 938–943.
- Munoz M, Camargo M, Soto-De Leon SC *et al.* (2012) The diagnostic performance of classical molecular tests used for detecting human papillomavirus. *Journal of Virological Methods*, **185**, 32–38.
- Nakamura Y, Mashima Y, Kameyama K, Mukai M & Oguchi Y (1997) Detection of human papillomavirus infection in squamous tumours of the conjunctiva and lacrimal sac by immunohistochemistry, *in situ* hybridisation, and polymerase chain reaction. *British Journal of Ophthalmology* **81**, 308–313.
- Napora C, Cohen EJ, Genvert GI *et al.* (1990) Factors associated with conjunctival intraepithelial neoplasia: a case control study. *Ophthalmic Surgery* **21**, 27–30.
- Nemet AY, Martin P, Bengler R *et al.* (2007) Orbital exenteration: a 15-year study of 38 cases. *Ophthalmic Plastic and Reconstructive Surgery* **23**, 468–472.
- Newton R, Ferlay J, Reeves G, Beral V & Parkin DM (1996) Effect of ambient solar ultraviolet radiation on incidence of squamous-cell carcinoma of the eye. *Lancet* **347**, 1450–1451.
- Newton R, Ziegler J, Beral V *et al.* (2001) A case-control study of human immunodeficiency virus infection and cancer in adults and children residing in Kampala, Uganda. *International Journal of Cancer* **92**, 622–627.
- Newton R, Ziegler J, Ateenyi-Agaba C *et al.* (2002) The epidemiology of conjunctival squamous cell carcinoma in Uganda. *British Journal of Cancer* **87**, 301–308.
- Ng J, Coroneo MT, Wakefield D & di Girolamo N (2008) Ultraviolet radiation and the role of matrix metalloproteinases in the pathogenesis of ocular surface squamous neoplasia. *Investigative Ophthalmology & Visual Science* **49**, 5295–5306.
- Odrich MG, Jakobiec FA, Lancaster WD *et al.* (1991) A spectrum of bilateral squamous conjunctival tumors associated with human papillomavirus type 16. *Ophthalmology*, **98**, 628–635.
- Ogun GO, Ogun OA, Bekibele CO & Akang EE (2009) Intraepithelial and invasive squamous neoplasms of the conjunctiva in Ibadan, Nigeria: a clinicopathological study of 46 cases. *International Ophthalmology* **29**, 401–409.
- Osahon AI, Ukponmwan CU & Uhumwangho OM (2011) Prevalence of HIV seropositivity among patients with squamous cell carcinoma of the conjunctiva. *Asian Pacific Journal of Tropical Biomedicine* **1**, 150–153.
- Parkin DM, Namboozee S, Wabwire-Mangen F & Wabinga HR (2010) Changing cancer incidence in Kampala, Uganda 1991–2006. *International Journal of Cancer* **126**, 1187–1195.
- Perez-Molina JA, Mora Rillo M, Suarez-Lozano I *et al.* (2012) Response to combined antiretroviral therapy according to gender and origin in a cohort of naive HIV-infected patients: GESIDA- 5808 study. *HIV Clinical Trials*, **13**, 131–141.
- Pfister RR & Renner ME (1978) The corneal and conjunctival surface in vitamin A deficiency: a scanning electron microscopy study. *Investigative Ophthalmology & Visual Science* **17**, 874–883.
- Pola EC, Masanganise R & Rusakaniko S (2003) The trend of ocular surface squamous neoplasia among ocular surface tumour biopsies submitted for histology from Sekuru Kaguvi Eye Unit, Harare between 1996 and 2000. *Central African Journal of Medicine* **49**, 1–4.

S. Gichuhi *et al.* Ocular surface squamous neoplasia in Africa


- Poole TR (1999) Conjunctival squamous cell carcinoma in Tanzania. *British Journal of Ophthalmology* **83**, 177–179.
- Porges Y & Groisman GM (2003) Prevalence of HIV with conjunctival squamous cell neoplasia in an African provincial hospital. *Cornea* **22**, 1–4.
- Pushker N, Kashyap S, Balasubramanya R *et al.* (2004) Pattern of orbital exenteration in a tertiary eye care centre in India. *Clinical & Experimental Ophthalmology* **32**, 51–54.
- Rahman I, Cook AE & Leatherbarrow B (2005) Orbital exenteration: a 13 year Manchester experience. *British Journal of Ophthalmology* **89**, 1335–1340.
- Reszcz J & Sulkowski S (2005) The expression of P53 protein and infection of human papilloma virus in conjunctival and eyelid neoplasms. *International Journal of Molecular Medicine* **16**, 559–564.
- Saegusa M, Takano Y, Hashimura M, Okayasu I & Shiga J (1995) HPV type 16 in conjunctival and junctional papilloma, dysplasia, and squamous cell carcinoma. *Journal of Clinical Pathology* **48**, 1106–1110.
- Scheffner M, Werness BA, Huibregtse JM, Levine AJ & Howley PM (1990) The E6 oncoprotein encoded by human papillomavirus types 16 and 18 promotes the degradation of p53. *Cell* **63**, 1129–1136.
- Scott IU, Karp CL & Nuovo GJ (2002) Human papillomavirus 16 and 18 expression in conjunctival intraepithelial neoplasia. *Ophthalmology* **109**(542–7), 39.
- Sen S, Sharma A & Panda A (2007) Immunohistochemical localization of human papilloma virus in conjunctival neoplasias: a retrospective study. *Indian Journal of Ophthalmology* **55**, 361–363.
- Shields CL & Shields JA (2004) Tumors of the conjunctiva and cornea. *Survey of Ophthalmology* **49**, 3–24.
- Simbiri KO, Murakami M, Feldman M *et al.* (2010) Multiple oncogenic viruses identified in Ocular surface squamous neoplasia in HIV-1 patients. *Infectious Agents and Cancer* **5**, 6.
- Smeets SJ, Hesselink AT, Speel EJ *et al.* (2007) A novel algorithm for reliable detection of human papillomavirus in paraffin embedded head and neck cancer specimen. *International Journal of Cancer* **121**, 2465–2472.
- Spitzer MS, Batumba NH, Chirambo T *et al.* (2008) Ocular surface squamous neoplasia as the first apparent manifestation of HIV infection in Malawi. *Clinical & Experimental Ophthalmology* **36**, 422–425.
- Stanley M (2010) Pathology and epidemiology of HPV infection in females. *Gynecologic Oncology* **117**, S5–10.
- Sun EC, Fears TR & Goedert JJ (1997) Epidemiology of squamous cell conjunctival cancer. *Cancer Epidemiology Biomarkers & Prevention* **6**, 73–77.
- Tabrizi SN, McCurrach FE, Drewe RH, Borg AJ, Garland SM & Taylor HR (1997) Human papillomavirus in corneal and conjunctival carcinoma. *Australian and New Zealand Journal of Ophthalmology* **25**, 211–215.
- Taylor-Smith K, Tweya H, Harries A, Schoutene E & Jahn A (2010) Gender differences in retention and survival on antiretroviral therapy of HIV-1 infected adults in Malawi. *Malawi Medical Journal* **22**, 49–56.
- Templeton AC (1967) Tumors of the eye and adnexa in Africans of Uganda. *Cancer* **20**, 1689–1698.
- Templeton AC (1973) Tumours of the eye and adnexa. *Recent Results in Cancer Research*, **41**(20), 3–14.
- Thorsteinnsson K, Ladelund S, Jensen-Fangel S *et al.* (2012) Impact of gender on the risk of AIDS-defining illnesses and mortality in Danish HIV-1-infected patients: a nationwide cohort study. *Scandinavian Journal of Infectious Diseases* **44**, 766–775.
- Tiong T, Borooah S, Msosa J *et al.* (2013) Clinicopathological review of ocular surface squamous neoplasia in Malawi. *British Journal of Ophthalmology* **97**, 961–964.
- Tornesello ML, Duraturo ML, Waddell KM *et al.* (2006) Evaluating the role of human papillomaviruses in conjunctival neoplasia. *British Journal of Cancer* **94**, 446–449.
- Toth J, Karcioğlu ZA, Moshfeghi AA, Issa TM, Al-Ma'ani JR & Patel KV (2000) The relationship between human papillomavirus and p53 gene in conjunctival squamous cell carcinoma. *Cornea* **19**, 159–162.
- Touzri RA, Mohamed Z, Khalil E *et al.* (2008) Ocular malignancies of xeroderma pigmentosum: clinical and therapeutic features. *Annales de Dermatologie et de Venereologie* **135**, 99–104.
- Tulvatana W (2003) Risk factors for conjunctival squamous cell neoplasia: a matched case-control study. *British Journal of Ophthalmology* **87**, 396–398.
- Tunc M, Char DH, Crawford B & Miller T (1999) Intraepithelial and invasive squamous cell carcinoma of the conjunctiva: analysis of 60 cases. *British Journal of Ophthalmology* **83**, 98–103.
- Tuppurainen K, Raninen A, Kosunen O *et al.* (1992) Squamous cell carcinoma of the conjunctiva. Failure to demonstrate HPV DNA by *in situ* hybridization and polymerase chain reaction. *Acta Ophthalmologica* **70**, 248–254.
- Ukponmwan CU, Igbokwe UO & Aligbe JU (2002) Squamous cell carcinoma of the conjunctiva in Benin City Nigeria. *Nigerian Journal of Medical Practice* **5**, 143–147.
- Vajdic CM, van Leeuwen MT, McDonald SP *et al.* (2007) Increased incidence of squamous cell carcinoma of eye after kidney transplantation. *Journal of the National Cancer Institute* **99**, 1340–1342.
- Velema JP, Ferrera A, Figueroa M *et al.* (2002) Burning wood in the kitchen increases the risk of cervical neoplasia in HPV-infected women in Honduras. *International Journal of Cancer* **97**, 536–541.
- Victoria CG, Huttly SR, Fuchs SC & Olinto MT (1997) The role of conceptual frameworks in epidemiological analysis: a hierarchical approach. *International Journal of Epidemiology* **26**, 224–227.
- Visser ME, Maartens G, Kossew G & Hussey GD (2003) Plasma vitamin A and zinc levels in HIV-infected adults in Cape Town, South Africa. *British Journal of Nutrition* **89**, 475–482.
- Wabinga HR, Parkin DM, Wabwire-Mangen F & Nambooze S (2000) Trends in cancer incidence in Kyadondo County, Uganda 1960–1997. *British Journal of Cancer* **82**, 1585–1592.

S. Gichuhi *et al.* **Ocular surface squamous neoplasia in Africa**

- Waddell KM, Lewallen S, Lucas SB, Atenyi-Agaba C, Herrington CS & Liomba G (1996) Carcinoma of the conjunctiva and HIV infection in Uganda and Malawi. *British Journal of Ophthalmology* 80, 503–508.
- Waddell K, Magyezi J, Bousarghin L *et al.* (2003) Antibodies against human papillomavirus type 16 (HPV-16) and conjunctival squamous cell neoplasia in Uganda. *British Journal of Cancer* 88, 2002–2003.
- Waddell KM, Downing RG, Lucas SB & Newton R (2006) Corneo-conjunctival carcinoma in Uganda. *Eye (London, England)* 20, 893–899.
- Waddell K, Kwehangana J, Johnston WT, Lucas S & Newton R (2010) A case-control study of ocular surface squamous neoplasia (OSSN) in Uganda. *International Journal of Cancer* 127, 427–432.
- WHO (2000) *International Classification of Diseases for Oncology (ICD-O-3)* [Online]. Available: <http://www.who.int/classifications/icd/adaptations/oncology/en/index.html> [Accessed 14th March 2013].
- WHO (2010) *International Statistical Classification of Diseases and Related Health Problems 10th Revision (ICD-10)* [Online]. Available: <http://apps.who.int/classifications/icd10/browse/2010/en> [Accessed 4th January 2013].
- World Energy Council (2007) *Survey of Energy Resources* [Online]. Available: [http://www.worldenergy.org/documents/fig\\_solar\\_10\\_2.gif](http://www.worldenergy.org/documents/fig_solar_10_2.gif) [Accessed 4th March 2013].
- Yu JJ, Fu P, Pink JJ *et al.* (2010) HPV infection and EGFR activation/alteration in HIV-infected East African patients with conjunctival carcinoma. *PLoS One* 5, e10477.

**Corresponding Author** Stephen Gichuhi, Department of Ophthalmology, University of Nairobi, Nairobi, Kenya.  
E-mail: [sgichuhi@uonbi.ac.ke](mailto:sgichuhi@uonbi.ac.ke)

## Chapter 2. Pathophysiology of ocular surface squamous neoplasia





**Registry**

T: +44(0)20 7299 4646  
F: +44(0)20 7299 4656  
E: registry@lshtm.ac.uk

## RESEARCH PAPER COVER SHEET

**PLEASE NOTE THAT A COVER SHEET MUST BE COMPLETED FOR EACH RESEARCH PAPER INCLUDED IN A THESIS.**

### SECTION A – Student Details

<b>Student</b>	Stephen Gichuhi
<b>Principal Supervisor</b>	Matthew J. Burton
<b>Thesis Title</b>	Epidemiology and management of ocular surface squamous neoplasia in Kenya

**If the Research Paper has previously been published please complete Section B, if not please move to Section C**

### SECTION B – Paper already published

Where was the work published?	Experimental Eye Research		
When was the work published?	December 2014		
If the work was published prior to registration for your research degree, give a brief rationale for its inclusion			
Have you retained the copyright for the work?*	No	Was the work subject to academic peer review?	Yes

*\*If yes, please attach evidence of retention. If no, or if the work is being included in its published format, please attach evidence of permission from the copyright holder (publisher or other author) to include this work.*

### SECTION C – Prepared for publication, but not yet published

Where is the work intended to be published?	
Please list the paper's authors in the intended authorship order:	
Stage of publication	Choose an item.

### SECTION D – Multi-authored work

For multi-authored work, give full details of your role in the research included in the paper and in the preparation of the paper. (Attach a further sheet if necessary)	I conducted the literature searches, extracted the data, conducted the analysis with guidance from H.Weiss and MJ Burton, drafted and submitted the manuscript with consideration of comments from all the co-authors
--	---

**Student Signature:** Stephen Gichuhi

**Date:** 4th February 2016

**Supervisor Signature:** M. J. Burton

**Date:** 4th February 2016



# RightsLink®

## [Creative Commons Attribution License \(CC BY\)](#)

This article is available under the terms of the [Creative Commons Attribution License \(CC BY\)](#). You may distribute and copy the article, create extracts, abstracts, and other revised versions, adaptations or derivative works of or from an article (such as a translation), to include in a collective work (such as an anthology), to text or data mine the article, including for commercial purposes without permission from Elsevier. The original work must always be appropriately credited.

Permission is not required for this type of reuse.

**CLOSE WINDOW**

Copyright © 2016 [Copyright Clearance Center, Inc.](#) All Rights Reserved.

Comments? We would like to hear from you. E-mail us at [customercare@copyright.com](mailto:customercare@copyright.com)



## Review

## Pathophysiology of ocular surface squamous neoplasia

Stephen Gichuhi<sup>a, b, \*</sup>, Shin-ichi Ohnuma<sup>c</sup>, Mandeep S. Sagoo<sup>c, d, e</sup>, Matthew J. Burton<sup>a, d</sup><sup>a</sup> London School of Hygiene and Tropical Medicine, Keppel Street, London WC1E 7HT, UK<sup>b</sup> Department of Ophthalmology, University of Nairobi, P.O. Box 19676-00202, Nairobi, Kenya<sup>c</sup> UCL Institute of Ophthalmology, 11-43 Bath Street, London EC1V 9EL, UK<sup>d</sup> Moorfields Eye Hospital, 162 City Road, London EC1V 2PD, UK<sup>e</sup> St. Bartholomew's Hospital, W Smithfield, London EC1A 7BE, UK

## ARTICLE INFO

## Article history:

Received 29 August 2014

Accepted in revised form 17 October 2014

Available online 18 October 2014

## Keywords:

Pathophysiology

Ocular surface squamous neoplasia (OSSN)

Limbal stem cells

Cancer stem cells

Ultraviolet radiation

p53

HPV

HIV

## ABSTRACT

The incidence of ocular surface squamous neoplasia (OSSN) is strongly associated with solar ultraviolet (UV) radiation, HIV and human papilloma virus (HPV). Africa has the highest incidence rates in the world. Most lesions occur at the limbus within the interpalpebral fissure particularly the nasal sector. The nasal limbus receives the highest intensity of sunlight. Limbal epithelial crypts are concentrated nasally and contain niches of limbal epithelial stem cells in the basal layer. It is possible that these are the progenitor cells in OSSN. OSSN arises in the basal epithelial cells spreading towards the surface which resembles the movement of corneo-limbal stem cell progeny before it later invades through the basement membrane below. UV radiation damages DNA producing pyrimidine dimers in the DNA chain. Specific CC → TT base pair dimer transformations of the p53 tumour-suppressor gene occur in OSSN allowing cells with damaged DNA past the G1-S cell cycle checkpoint. UV radiation also causes local and systemic photo-immunosuppression and reactivates latent viruses such as HPV. The E7 proteins of HPV promote proliferation of infected epithelial cells via the retinoblastoma gene while E6 proteins prevent the p53 tumour suppressor gene from effecting cell-cycle arrest of DNA-damaged and infected cells. Immunosuppression from UV radiation, HIV and vitamin A deficiency impairs tumour immune surveillance allowing survival of aberrant cells. Tumour growth and metastases are enhanced by; telomerase reactivation which increases the number of cell divisions a cell can undergo; vascular endothelial growth factor for angiogenesis and matrix metalloproteinases (MMPs) that destroy the intercellular matrix between cells. Despite these potential triggers, the disease is usually unilateral. It is unclear how HPV reaches the conjunctiva.

© 2015 The Authors. Published by Elsevier Ltd. This is an open access article under the CC BY license (<http://creativecommons.org/licenses/by/4.0/>).

## 1. Introduction

Ocular surface squamous neoplasia (OSSN) comprises of a spectrum of tumours that affect the ocular surface ranging histologically from intraepithelial neoplasia to different grades of invasive squamous cell carcinoma (Lee and Hirst, 1995). Early lesions of varying size usually occur at the limbus, the area of transition between the cornea and conjunctiva (Lee and Hirst, 1997; Waddell et al., 2006). Advanced stages may involve the eyelids and may

invade the orbit. Curiously OSSN usually affects only one eye (Chisi et al., 2006).

OSSN occurs worldwide but the peak incidence is found at a latitude of 16° South (Gichuhi et al., 2013). The mean age-standardised incidence rate worldwide is 0.18 and 0.08 cases/year/100,000 among males and females, respectively and the highest incidence rate is found in Africa (1.38 and 1.18 cases/year/100,000 in males and females) (Gichuhi et al., 2013). In temperate countries OSSN predominantly affects males while in Africa both sexes are affected equally. Systematic reviews and meta-analysis show that the main risk factors are solar ultraviolet (UV) radiation, HIV and human papilloma virus (HPV); while vitamin A deficiency is a potential risk factor but has not been investigated (Gichuhi et al., 2013; Carreira et al., 2013). This paper reviews the pathophysiological mechanisms underlying the development of OSSN.

\* Corresponding author. International Center for Eye Health (ICEH), London School of Hygiene & Tropical Medicine, Keppel Street, WC1E 7HT London, UK.

E-mail addresses: [stephen.gichuhi@lshtm.ac.uk](mailto:stephen.gichuhi@lshtm.ac.uk) (S. Gichuhi), [s.ohnuma@ucl.ac.uk](mailto:s.ohnuma@ucl.ac.uk) (S.-i. Ohnuma), [m.sagoo@ucl.ac.uk](mailto:m.sagoo@ucl.ac.uk) (M.S. Sagoo), [matthew.burton@lshtm.ac.uk](mailto:matthew.burton@lshtm.ac.uk) (M.J. Burton).

## 2. Ocular surface anatomy

The ocular surface consists of the cornea, limbus and conjunctiva but in a wider anatomical and embryological sense the mucosa of the ocular adnexa (lacrimal gland and lacrimal drainage system) is included. The epithelia of the cornea, conjunctiva and eyelid are formed from differentiation of the surface ectoderm during embryonic development. The corneal endothelium and the corneal stroma, conjunctiva and eyelids are formed when periocular mesenchymal cells of neural crest origin migrate and differentiate (Cvekl and Tamm, 2004; Kao et al., 2008).

The cornea has a stratified squamous non-keratinizing epithelium with five to seven cell layers. It is immunologically privileged due to its lack of blood vessels and lymphatics, with dendritic cells present usually only in the peripheral cornea (Akpek and Gottsch, 2003).

The limbal epithelium is 8–10 cells thick and is constantly being replenished from stem cells in the basal layer (Schermer et al., 1986). The limbal basement membrane has undulating peg-like inter-digitations into the underlying stroma called the palisades of Vogt, which increase the surface area and protect against shearing forces (Fig. 1). The palisades are unique for individuals (like fingerprints) and have distinct radial vascular loops that leak fluorescein in the late phase of angiography suggesting a protective function for stem cells (Goldberg and Bron, 1982). The basal cells are protected from UV light by melanin within deep limbal crypts, where melanocytes contain melanin granules oriented towards the apex of each cell, acting as a pigmented cap facing the ocular surface (Higa et al., 2005). Among darker pigmented races the limbus is heavily pigmented, perhaps offering greater protection from UV radiation.

The conjunctiva consists of an epithelium on a basement membrane and underlying loose connective tissue called the lamina propria. The lamina propria is loosely anchored to the episclera and sclera making the conjunctiva easily mobile. The epithelium varies between 2–3 and 10–12 cell layers, depending on whether it is the bulbar, fornix or tarsal portion. Lymphocytes and plasma cells are abundant in the conjunctiva (Hingorani et al., 1997). They form the conjunctiva-associated lymphoid tissue (CALT) in the lamina propria (Knop and Knop, 2007).

## 3. Limbal stem cell biology

Stem cell biology is a rapidly progressing field. A stem cell is a special undifferentiated progenitor cell capable of giving rise to many more cells of the same type, and from which other kinds of cells arise by differentiation. There are three types of stem cells. Embryonic stem cells originate from pre-implantation embryos and can develop into tissues that belong to one of the three germ layers (Martin, 1981). Non-embryonic adult stem cells (termed somatic) are undifferentiated cells found in special niches of various organs where they divide and differentiate to replace damaged tissue while some may transdifferentiate to other tissues (Gonzalez and Bernad, 2012). Their origin remains unclear. Limbal epithelial cells would fall in this category. Lastly, induced pluripotent stem cells are created in the lab by genetically reprogramming somatic cells to an embryonic stem cell-like state (Takahashi et al., 2007; Obokata et al., 2014).

Corneo-limbal lineage is distinct from conjunctival lineage (Wei et al., 1996). Evidence suggests the existence of corresponding stem cell reservoirs. Corneo-limbal epithelial stem cells are located in the limbal basal layer while conjunctival stem cells are distributed throughout the bulbar and forniceal conjunctiva, but some propose that they are concentrated in the fornix (Nagasaki and Zhao, 2005;

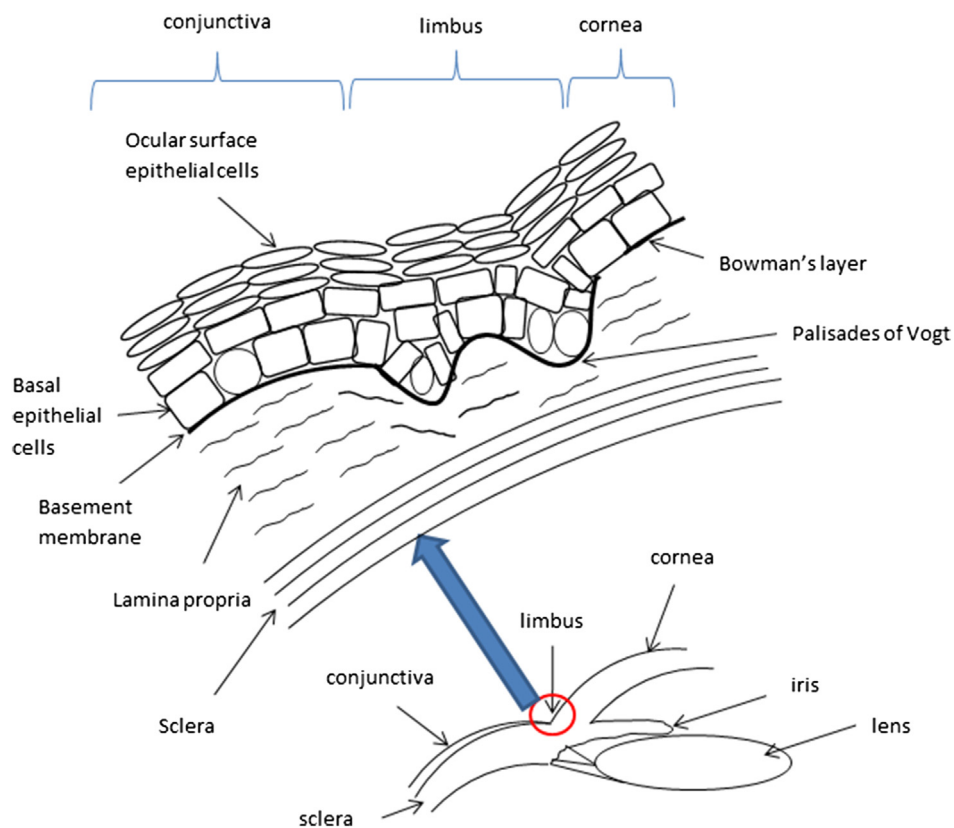


Fig. 1. Anatomy of the limbus.



Sun et al., 2010; Pellegrini et al., 1999; Wei et al., 1995). Stem cells are also found in the corneal stroma and mucocutaneous junction of the lid margin (Du et al., 2005; Wirtschafter et al., 1997). The molecular structure of the basement membrane and extracellular matrix at the cornea, limbus and conjunctiva differ from each other and this is thought to play a role in regulation of epithelial differentiation (Kolega et al., 1989; Schlotzer-Schrehardt et al., 2007). Various markers have been studied in the ocular surface to determine which are more concentrated at the limbus (Table 1) (Schlotzer-Schrehardt and Kruse, 2005). There are no specific limbal stem cell markers or any that distinguishes stem cells from their early progeny (Chee et al., 2006).

Limbal stem cells are found in special niches in the basal region called limbal epithelial crypts which are cords of epithelial cells extending from the palisades of Vogt into the underlying stroma

(Dua et al., 2005). The crypts are most abundant nasally in the mid- or distal limbus (Shanmuganathan et al., 2007). Stem cells within the crypts have the following marker profile; CK3–/CK19+/CD34–/Vimentin+/p63+/Connexin43+/Ki67– (Shanmuganathan et al., 2007). Stem cells represent less than 10% of the limbal basal cell population (Lavker et al., 1991). They are characterised by; low level of differentiation, slow cell-cycle, long life-span, high proliferative potential and self-renewal (ability to produce more stem cells) (Schlotzer-Schrehardt and Kruse, 2005; Dua and Azuara-Blanco, 2000). The limbus creates a barrier to prevent extension of conjunctival epithelium and blood vessels into the cornea (Osei-Bempong et al., 2013). Clinical features of limbal stem cell deficiency disorders thus include corneal epithelial defects, conjunctival epithelial migration onto the cornea and corneal neovascularization (Sejpal et al., 2013).

**Table 1**  
Molecular markers for limbal stem cells (Schlotzer-Schrehardt and Kruse, 2005).

Characterization	Examples
Cytoskeletal proteins - proteins that form intermediate filaments in epithelial cells	i) Cytokeratins <sup>a</sup> (CK3, CK12, CK5, CK14, CK19) – CK3/CK12 pair is lacking in the limbus. It is a marker of corneal phenotype ii) Vimentin fastens limbal stem cells to their local environment. It is localised in limbal basal cells
Cytosolic proteins - associated with cellular metabolic functions	a) enzymes i) cytochrome oxidase – Na/K-ATPase ii) carbonic anhydrase iii) $\alpha$ -enolase (initially thought to be a glycolytic enzyme it acts as a plasminogen binding receptor) iv) protein kinase C (PKC), a key enzyme controlling signal transduction pathways in growth and differentiation. v) aldehyde dehydrogenase (ALDH) vi) transketolase (TKT) b) Cell-cycle associated proteins i) Cyclins ii) Ki67 acts as a marker for actively cycling cells c) Metallothioneins, which are cysteine-rich metal-binding intracellular proteins d) Involucrin, a structural protein found in the cytosol of differentiated human keratinocytes e) calcium-linked protein (CLED), that is associated with early epithelial differentiation f) protein S100A12, which is involved in Ca <sup>2+</sup> -dependent signal transduction processes in differentiated cells
Nuclear proteins	p63 is a transcription factor that regulates epithelial development and differentiation. Although concentrated at the limbus in stem cells, it is not exclusively expressed by stem cells.
Cell surface proteins a) Cell–cell and cell–matrix interaction molecules b) Growth factor receptors c) Transporter molecules d) Cell surface glycoconjugates	i) Connexins are transmembrane proteins in gap junctions that allow diffusion of ions, low molecular weight metabolites, and second messengers thus determining the extent of metabolic cooperation between cells ii) Cadherins are a family of Ca <sup>2+</sup> -dependent transmembrane receptors that mediate cell–cell adhesion iii) Integrins are a large family of heterodimeric transmembrane glycoproteins consisting of $\alpha$ and $\beta$ subunits, that play a role in attachment of cells to the basement membrane, extracellular matrix proteins or to ligands on other cells iv) epidermal growth factor receptor (EGF-R) v) keratinocyte growth factor receptor (KGF-R) vi) TrkA, the high affinity receptor for nerve growth factor (NGF). vii) hepatocyte growth factor (HGF) viii) Transferrin receptor CD71 ix) transforming growth factor-beta (TGF- $\beta$ ) type I and II x) ABCG2, a member of the ATP binding cassette transporters. ABCG2 has been proposed as a universal and conserved marker for stem cells from a wide variety of tissues. ABCG2 protein is also known as breast cancer resistant protein 1 (BCRP1), which causes resistance to certain chemotherapeutic drugs. It is a multi-resistance drug protein that pumps drugs out of cells. This is protective to the cell. It is localized to the cell membrane and cytoplasm of some human limbal basal epithelial cells, but not in most limbal suprabasal cells and corneal epithelial cells. xi) $\alpha$ -2,3-sialyltransferase
Neuronal markers - human corneal and limbal cells may exhibit neuronal properties characteristic of their neuroectodermal origin	i) Nestin is a neural stem cell marker. It is not normally expressed in limbal basal cells except when they are in an environment with mitogens ii) transcription factor Pax-6
Hematopoietic stem cell markers	i) CD34 a sialomucin cell surface antigen ii) CD133 a transmembrane glycoprotein

<sup>a</sup> In the original article cytokeratins were abbreviated as K. We have modified that to CK in keeping with more recent terminology.

The ocular surface is self-renewing. Superficial cells are constantly lost and are replaced by basal cells entering the differentiation pathway. To replenish the corneal epithelium, corneal epithelial stem cells undergo mitosis producing a progeny of fast-dividing transient amplifying cells (TAC) that make up the majority of the proliferating cell population in the epithelium (Castro-Munozledo, 2013). TAC migrate superficially to the suprabasal limbus and centripetally towards the centre of the cornea to form the basal layer of the corneal epithelium (Lehrer et al., 1998). They undergo a limited number of divisions then differentiate into post-mitotic cells (PMC) and further into terminally differentiated cells (TDC) that migrate superficially to the corneal surface (Lehrer et al., 1998). It takes 14–21 days for complete renewal of the rabbit corneal epithelium (Haddad, 2000). In humans it takes 5–7 days (Hanna and O'Brien, 1960). For conjunctival renewal, cells stream centrifugally (instead of centripetally as occurs in the cornea) at  $10.5 \pm 2.4 \mu\text{m}/\text{day}$  then superficially at  $9.3 \pm 5.4 \mu\text{m}/\text{day}$  with a cell-cycle time of 8.3 days in rats (Zajicek et al., 1995). Stem cells have a slower passage through the cell cycle than the other basal cells of the cornea and conjunctiva (Lavker et al., 1991). In mice they take 4–8 weeks and are preferentially stimulated by wounding and tumour promoting compounds (Cotsarelis et al., 1989). Intact innervation of the ocular surface is needed to maintain the stem cell niche (Ueno et al., 2012).

#### 4. Cancer stem cells

The term cancer stem cell is a relatively new one in cancer biology, though this is a concept known for many years (Wicha et al., 2006). In malignant tumours there is frequently a subpopulation of cells that responds poorly to treatment such as chemotherapy and radiotherapy, divides at a slower rate than other cancer cells, and is less affected by hypoxia (Moore and Lyle, 2011; Lin and Yun, 2010). This subpopulation is thought to drive tumour growth and is the subject of much debate and much investigation for different tumour types. The origin of these cells is controversial and their interaction with non-stem cancer cells has been variously studied using mathematical models (Wang et al., 2014).

Cancer stem cells comprise less than 5% of the cell population in most tumours (Yang and Chang, 2008). They are found in various cancers including breast, brain, gastric, pancreatic and liver (Al-Hajj et al., 2003; Yuan et al., 2004; Takaishi et al., 2008; Lee et al., 2008; Sell and Leffert, 2008). In high-grade cervical intraepithelial neoplasia (CIN) associated with carcinogenic HPV types they are found at the squamo-columnar junction but rarely in ectocervical/

transformation zone CINs or those associated with non-carcinogenic HPVs (Herfs et al., 2012).

Their existence could help to explain the clinical observation of the inaction of conventional cancer chemotherapy and radiotherapy in some instances since these treatments target rapidly dividing cells yet stem cells by nature are slow-cycling. For example, treatment with fluorouracil (5-FU) selects and enriches the cancer stem cell population since the rapidly dividing cells would be killed while slow-cycling ones incorporate the drug at a lower rate (Shi et al., 2013; Wang et al., 2006). Potentially, therapies targeting cancer stem cells could be more effective (Duggal et al., 2014).

#### 5. Patterns of ocular surface dysplastic and neoplastic disease

The clinical presentation of ocular surface dysplastic and neoplastic diseases provides clues to the pathophysiology of OSSN. Firstly, OSSN, pterygium, pingueculae, climatic droplet keratopathy and actinic keratosis are usually located within the interpalpebral fissure, the space between the open upper and lower eyelid that is exposed to UV radiation (Waddell et al., 2006; Sudhalkar, 2012; Shields et al., 2004; Gray et al., 1992). Secondly, most OSSN lesions arise from the limbus particularly the nasal quadrant (Fig. 2) (Waddell et al., 2006). A similar observation was made of pterygia in India where all the lesions in a study of 427 participants were nasal (Sudhalkar, 2012). This is the area with the highest concentration of limbal epithelial crypts (Shanmuganathan et al., 2007). Thirdly, the disease may involve the circumferential limbus with relatively little involvement of the cornea or fornix (Fig. 3). Lastly, intraepithelial neoplasia begins in the basal cells and spreads upwards, a pattern reflected in the histological grading (Basti and Macsai, 2003; American Joint Committee on Cancer, 2010). This resembles the spreading waves of limbal stem cells and their progeny described in biology above suggesting that the disease may be of stem cell origin. It remains unclear why OSSN is often unilateral since exposure to UV radiation, HIV and HPV has no laterality.

#### 6. Vulnerability of the limbus

The limbus receives direct sunlight temporally which is focused nasally (Fig. 4). As the human eye is more exposed laterally, the large temporal visual field becomes a collecting zone of peripheral light, which, depending on the angle of incidence ( $\theta$ ) and the corneal central radius of curvature ( $r_0$ ), is intensely focused onto the nasal limbus, lid margin or lens with up to a 20-fold increase in

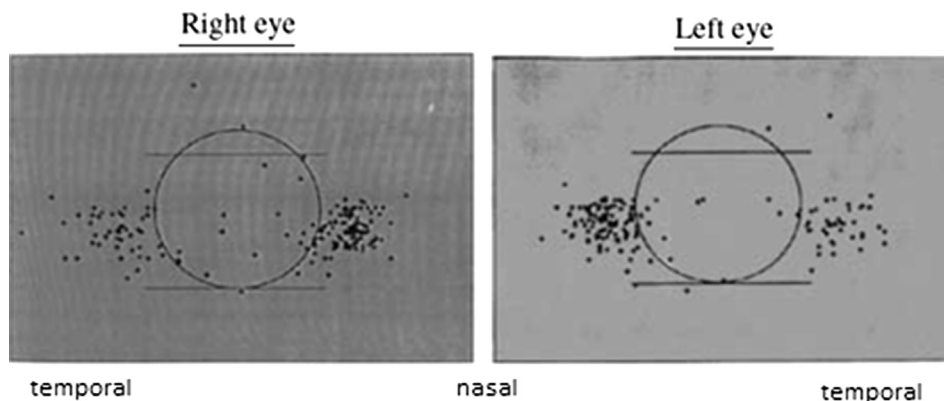
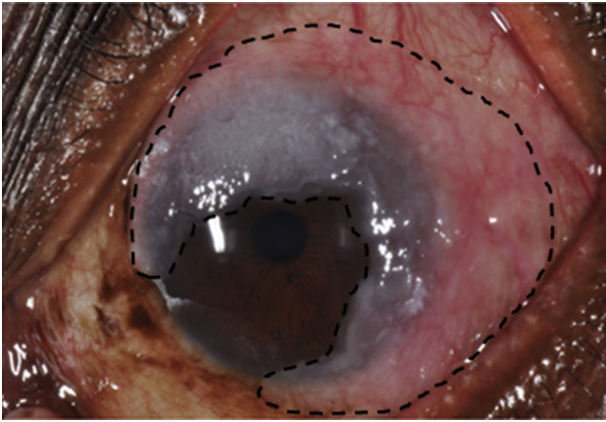


Fig. 2. Location of 352 OSSN tumours in Uganda showing most lesions occurred within the interpalpebral fissure with a higher concentration in the nasal sector. Reprinted by permission from Macmillan Publishers Ltd: Eye 20 (8):893–899 copyright 2006



**Fig. 3.** A lesion of OSSN lesion in Kenya showing a circum-limbal growth pattern involving almost the entire circumference of the limbus. The margins are drawn in a black dotted line to show extension into the cornea and bulbar conjunctiva.

peak intensity (Malooof et al., 1994). Temporal light that traverses the anterior chamber strikes the nasal limbal cells basally where there is less melanin. These foci coincide with the usual site for pterygium, OSSN, lid malignancy and cataract.

Limbal basal cells remain quiescent but proceed more rapidly through the cell cycle when there is an insult to the ocular surface such as a wound or tumour promoter (Cotsarelis et al., 1989). Quiescent adult stem cells accumulate DNA damage making them vulnerable to neoplastic transformation (Mohrin et al., 2010). Others however suggest that slow-cycling protects them from cancer (Wodarz, 2007). Quiescence may create a reservoir of latent virus infection, which can persist for long periods before reactivation following immunosuppression (Maglennon et al., 2011). In skin hair follicle stem cells the papilloma virus oncogenes, E6 and E7, can compromise stem cell quiescence by promoting their aberrant mobilization (Michael et al., 2013).

## 7. Key events in the aetiology of OSSN

### 7.1. DNA damage: genetic and epigenetic changes

At the heart of carcinogenesis is non-lethal DNA damage. DNA damage can be genetic (mutations of the DNA nucleotide sequence) or epigenetic (variations in gene expression that do not involve changing the nucleotide sequence). DNA damage



**Fig. 4.** Light from a torch shining on the temporal side of the eye to illustrate that the limbus receives direct sunlight temporally which is focused nasally. Notice the glow in the nasal limbus.

affects genome stability and stem cell function leading to cancer (Xu and Taylor, 2014). Mutations may affect oncogenes (genes that facilitate cell division) or tumour suppressor genes (that slow down or stop cell division). Epigenetic modifications can take three different forms (Walters, 2013). Firstly, DNA methylation where cytosine nucleotides (C) are found adjacent to guanine nucleotides (G) called CpG sites, which shuts down RNA transcription. Secondly, modifying histones (e.g. acetylation and methylation) around which DNA is wrapped allowing uncontrolled access to DNA by transcription factors. Thirdly, silencing micro RNA (miRNA) genes which regulate cell processes such as proliferation, differentiation, and apoptosis by binding the 3' untranslated region of target mRNA. Epigenetic changes are often reversible (Delcuve et al., 2009). Although distinct from each other, epigenetic changes and mutations are related because epigenetic changes may lead to mutations and cancer (Feinberg et al., 2006). Ocular surface DNA damage is probably mainly caused by solar UV radiation (UVR), although HPV may also play a role.

#### 7.1.1. Effects of solar ultraviolet radiation

**7.1.1.1. Genetic and epigenetic changes.** Ambient UVR can be broadly divided into UVA (320–400 nm, approximately 90%) and UVB (290–320 nm, approximately 5%) wavebands (Diffey, 2002). UVC (200–290 nm) is largely prevented from reaching the earth's surface by the ozone layer in the atmosphere.

UVB radiation causes direct DNA damage by crosslinking adjacent bases to form cyclobutane pyrimidine dimers (CPDs) and 6–4 photoproducts (6–4 PPs) (Pfeifer et al., 2005). The most commonly seen are CPDs and are considered the hallmarks of UV damage (Besaratina et al., 2011). Pyrimidine dimers are formed when adjacent bases (thymine-T or cytosine-C) on the same DNA strand absorb energy from UV light and form crosslinks via carbon-to-carbon covalent bonds (Rastogi et al., 2010). CPDs and 6–4PPs distort DNA's structure and block DNA synthesis by preventing the replicative DNA polymerases from moving along a template strand (Ikehata and Ono, 2011). CPDs are also resistant to hydrolysis (Yamamoto et al., 2014). Specific CC → TT dimer transitions of the p53 tumour-suppressor gene have been observed in OSSN lesions in Uganda (Ateenyi-Agaba et al., 2004). p53 mutations occur in different phases of the multistep malignant transformation and can be found in precancerous lesions such as actinic keratosis (Rivlin et al., 2011). The effects of p53 mutation are discussed later in this article.

UVA causes indirect DNA damage via reactive oxygen species (ROS), like  $\cdot\text{OH}$  (hydroxyl radical),  $\text{O}_2^-$  (superoxide radical anion) or  $\text{H}_2\text{O}_2$  (hydrogen peroxide) leading to DNA strand breaks (Cortat et al., 2013; Greinert et al., 2012; Cadet et al., 2009). No studies have demonstrated DNA strand breaks in OSSN. Cells have greater ability to repair UVA effects than UVB (Besaratina et al., 2008).

**7.1.1.2. Reactivation of latent HPV infection.** Exposure to UVB reactivates latent HPV (Zhang et al., 1999), HIV (Breuer-Mcham et al., 2001), varicella-zoster (shingles) (Zak-Prelich et al., 2002; Rice, 2011) and herpes simplex (cold sores) (Blatt et al., 1993; Miller et al., 1993). HPV is a small DNA virus. Asymptomatic HPV infection is widespread with an estimated global prevalence of 11.7% in women and 1.3%–72.9% in men (Bruni et al., 2010; Dunne et al., 2006). HPV is epitheliotropic for squamous epithelia especially transitional mucosae and is implicated in the aetiology of various squamous cell carcinomas including cervical (summary OR = 70.0, 95% CI; 57.0–88.0), colorectal (summary OR = 10.0, 95% CI; 3.7–27.5), laryngeal (summary OR = 5.4, 95% CI; 3.3–8.9), OSSN (summary OR = 4.0, 95% CI; 2.1–7.6), oesophageal (summary OR = 3.3, 95% CI; 2.3–4.9) and bladder (summary OR = 2.8, 95% CI;

1.4–5.8) (Munoz, 2000; Damin et al., 2013; Li et al., 2013b, 2014, 2011; Gichuhi et al., 2013; Li et al., 2014, Li et al., 2011).

Much of what is known about the pathophysiology of HPV in cancer is derived from cervical studies. HPV invades the basement membrane through micro abrasions where it initially binds to heparin sulphate proteoglycan (HSPG) (Johnson et al., 2009; Sapp and Bienkowska-Haba, 2009). It does not bind intact epithelia (Johnson et al., 2009). The basement membrane is not merely a passive reservoir of virus but is involved in viral processing. Here the viral capsids undergo a conformational change where the L2 epitope is cleaved by a protease and exposure of its N-terminal leads to the transfer of capsids to the epithelial cell surface (Kines et al., 2009). After internalization, the virus is disassembled and the DNA enters the nucleus by a mechanism that is still not well understood where it replicates producing extra-chromosomal copies of viral DNA (Sapp and Bienkowska-Haba, 2009). However the genome of high-risk HPV has been found incorporated into specific preferential sites of the host DNA in cervical lesions (Li et al., 2013a). During differentiation of epithelial cells, virions mature and are carried towards the surface (Doorbar, 2005). In normal uninfected epithelia, as cells leave the basal layer, they exit the cell cycle but infected cells remain active due to E7 (Longworth and Laimins, 2004). E7 inactivates the retinoblastoma gene (pRB) which usually acts in the G1 phase of the cell cycle where it binds transcription factors, thus infected cells remain in a proliferative state while E6 binds the p53 protein preventing it from suppressing replication of such DNA-defective cells (Lehoux et al., 2009). In high-risk HPV types, E6 and E7 also cause genomic instability; E7 causes centriole over-duplication and disturbs mitotic fidelity while E6 causes structural chromosomal alterations and DNA breakage (Korzeniewski et al., 2011). The effects on p53 and pRB are considered the molecular signatures of HPV-induced carcinogenesis (Buitrago-Perez et al., 2009). Regression of HPV-induced lesions is mediated by a T-helper 1 lymphocyte (Th1) cell mediated immune response (Stanley, 2012). HPV latency may arise in two ways; (i) low titre infection that is too low to complete the life cycle or (ii) clearance of lesions by the adaptive immune system followed by persistence of low-level viral gene expression, which is reactivated by immunosuppression (Doorbar, 2013).

How HPV initially reaches the conjunctiva is not clear. The prevalence of HPV in OSSN tissue is heterogeneous, varying widely from zero to 100% (Gichuhi et al., 2013).

HPV infection is associated with an increased incidence of HIV acquisition (summary OR = 1.96; 95% CI: 1.55–2.49) (Lissouba et al., 2013).

## 7.2. Failure of DNA repair mechanisms

Several mechanisms prevent UV-induced DNA mutations from being incorporated into the genome and UV-damaged cells from establishing themselves. Cells can correct carcinogen-induced DNA damage; severely damaged cells are eliminated from healthy tissues by processes that trigger apoptosis; and abnormal cells are recognized, targeted and destroyed by immune surveillance (Di Girolamo, 2010).

The cell-division cycle involves duplication of the genome and intracellular organelles (Imoto et al., 2011). The stages of the cycle can be visualised directly by high-resolution imaging (Hesse et al., 2012). Nuclear DNA is synthesized during a stage of interphase called the S phase which is followed by a gap (G2), then mitosis (M phase) in which nuclear and cell division occur and another gap (G1) before the next S phase (Fig. 5).

DNA damage activates checkpoint pathways that regulate specific DNA repair mechanisms in the different phases of the cell cycle (Branzei and Foiani, 2008). There are three important cell-cycle

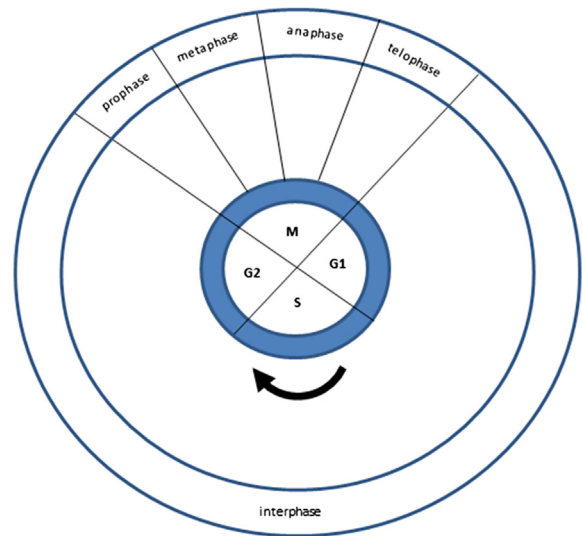


Fig. 5. The cell division cycle.

checkpoints (Sancar et al., 2004). The G1-S checkpoint prevents cells with damaged DNA from entering the S phase by inhibiting the initiation of replication. The intra-S-phase checkpoint deals with DNA damage that may occur during S-phase or unrepaired damage that escaped the G1-S checkpoint. The G2-M checkpoint prevents cells with damaged DNA from undergoing mitosis.

The molecular mechanisms that repair UVR-induced DNA damage include excision repair, mismatch repair, strand break repair, and cross-link repair (Rastogi et al., 2010). During excision repair sections of damaged DNA are replaced by a nucleotide or base (Sinha and Hader, 2002). The nucleotide excision repair (NER) pathway is primarily responsible for repairing CPDs in humans (Sancar et al., 2004). There are two types of NER; general excision repair which removes lesions from the whole genome and transcription-coupled repair which works on damage in transcribed DNA strands. The latter is not clearly understood but the former is performed through a series of special proteins and proceeds through four discrete steps; recognition of the damage; excision of the section of DNA that includes and surrounds the error; filling in of the resulting gap by DNA polymerase; and sealing of the nick between the newly synthesized and older DNA by DNA ligase (Hu et al., 2013; Reardon and Sancar, 2005).

Base excision repair (BER) is the predominant pathway against lesions caused by ROS, ionizing radiation and strong alkylating agents (Svilar et al., 2011). It proceeds through 5 steps as follows; DNA glycosylases remove damaged or modified bases; the apurinic/apyrimidinic site is removed by an endonuclease or lyase; the remaining phosphate residue is removed by a phosphodiesterase; the gap is filled by a DNA polymerase and the strand sealed by a DNA ligase (Hegde et al., 2008).

### 7.2.1. The p53 tumour-suppressor system

The p53 tumour-suppressor gene is found on the short arm of chromosome 17 (17p13.1) (Mcbride et al., 1986). P53 is a phosphoprotein found in the nucleus which regulates the cell cycle to protect cells from the effects of DNA damage (Ford, 2005; Jin and Robertson, 2013; Borrás et al., 2011). It is thus described as the 'guardian of the genome' (Lane, 1992). Once p53 is activated by a stress signal it binds to specific DNA elements in the genome with various primary and secondary response effects (Levine et al., 2006). The primary responses include; cell cycle arrest at the G1-S checkpoint; irreversible withdrawal of cells from the cycle into a terminal state of senescence or programmed cell death

(apoptosis) if the damage is irreparable. The secondary responses come from p53-regulated gene products that prevent DNA damage (sestrins) or aid in DNA repair; mediate communication between the cell and its neighbours, the extracellular matrix or more distant cells; or create intracellular or extracellular p53 feedback loops that modulate p53 activity. In addition, deacetylation of p53 facilitates autophagy (autophagocytosis by controlled lysosomal degradation) (Contreras et al., 2013). Mutated p53 (Mutp53) leads to further genomic instability (Meek, 2009).

### 7.3. Reduced immunity

Tumour immunology presumes that tumour cells express antigens such as mutp53 and HPV proteins that distinguish them from non-transformed cells. The immune system prevents tumour formation in 3 ways (i) elimination or suppression of viral infection (ii) preventing establishment of a pro-inflammatory environment and (iii) specifically identifying and eliminating cells that express tumour-specific antigens or molecular signals of cellular stress before they cause harm (Schreiber et al., 2011). The latter is part of a more general process called tumour immuno-editing. Immuno-editing is a dual process in which the immune system may either suppress tumour growth by destroying or inhibiting growth of cancer cells or inadvertently promote tumour progression by selecting tumour cells that are more likely to survive. It has 3 phases: elimination, equilibrium and escape (Schreiber et al., 2011). In the elimination phase the immune system recognizes tumour cells and initiates cell death eliminating them completely before they become clinically apparent. If not fully eliminated the remaining tumour cells enter a state of temporary equilibrium between the immune system and the developing tumour in which the tumour cells remain dormant or continue to accumulate further genetic and epigenetic changes. Finally if the immune system fails to contain the tumour at this phase, surviving tumour cell variants escape causing uncontrolled tumour expansion. The quantity, quality and distribution of tumour infiltrating lymphocytes (TILs) such as CD8+ cytotoxic T lymphocytes (CTL), CD4+ T helper lymphocytes (Th), CD4+ regulatory T lymphocytes (Treg) and CD3+ lymphocytes influence prognosis. A meta-analysis showed that improved survival, measured by the death Hazard ratio (HR), was associated with CD3+ TIL infiltration (HR = 0.58, 95% CI; 0.43–0.78) and CD8+ TIL (HR = 0.71, 95% CI; 0.62–0.82) (Gooden et al., 2011). However TIL counts alone may overestimate this effect and ratios between TIL subsets CD8+/FoxP3+ (effector:regulatory ratio) and CD8+/CD4+ (effector:helper ratio) may be more informative. Natural killer cells are another important component of cancer immunosurveillance and immuno-editing (Gross et al., 2013).

#### 7.3.1. Photoimmunosuppression

Ambient UV radiation suppresses cell-mediated immunity (Clydesdale et al., 2001). UVB is a more potent immunosuppressor than UVA (Poon et al., 2005). This phenomenon referred to as photoimmunosuppression is not limited to exposed cutaneous tissues but is also systemic, affecting internal organs (Gibbs and Norval, 2013). The immunosuppressive effect of UVB is used in phototherapy of skin conditions such as psoriasis (Chen et al., 2013). In the skin, UVB stimulates migration of epidermal Langerhans cells, which present antigens to lymphocytes in the draining lymph nodes promoting a Th2 and regulatory T cells (Treg) dominated response that suppresses local immune responses (Taguchi et al., 2013; Schwarz and Schwarz, 2011; Norval et al., 2008).

#### 7.3.2. HIV

HIV preferentially infects helper T cells (CD4+), inducing their apoptosis (Lundin et al., 1987; Cloyd et al., 2001; Alimonti et al.,

2003). The virus establishes latency in resting memory T cells, which explains why combination antiretroviral therapy (ART) is not curative; interruption of treatment inevitably results in rebound viraemia (Van Lint et al., 2013) (van Der Sluis et al., 2013). HIV may weaken tumour immunosurveillance (Mbulaiteye et al., 2003). A meta-analysis found an increased incidence of cancers among both HIV/AIDS patients and immunosuppressed transplant recipients, however, there was no significant difference in the risk between the two groups suggesting that it is primarily the immunosuppression, rather than another action of HIV that is responsible for the increased risk of cancer (Grulich et al., 2007).

HIV potentiates the oncogenic action of other viruses such as HPV, Kaposi sarcoma-associated herpes virus (KSHV) and Epstein–Barr virus (EBV) by enhancing their transmission to target cells (Aoki and Tosato, 2004). A report from Botswana reported multiple oncogenic viruses (EBV, HPV, KSHV, HSV1/2 and CMV) in cases of OSSN and pterygium (Simbiri et al., 2010). In rabbits immunosuppression induced by T-cell depletion facilitated reactivation of latent HPV infection leading to a 3 to 5 log increase in the number of viral copies to levels associated with productive infection (Maglennon et al., 2014).

Lastly, HIV induces a state of persistent inflammation (Hunt, 2012). Markers of inflammation such as C-reactive protein and interleukin-6 are elevated in HIV patients particularly those on ART even when viral loads are undetectable (Neuhaus et al., 2010). Inflammatory microenvironments have tumour-promoting effects (Mantovani et al., 2008). One proposed mechanism is via over-expression of microRNA-155 (MiR155), which increases spontaneous mutation rates (Tili et al., 2011; Valeri et al., 2010).

#### 7.3.3. Vitamin A deficiency

Vitamin A helps to maintain the integrity of the ocular surface (Kanazawa et al., 2002). Its deficiency is associated with squamous metaplasia of the conjunctiva (Mckelvie, 2003). Vitamin A also acts as a mucosal and systemic immune enhancer through immunohomeostasis of CD4+ helper T cells and Treg cells (Hall et al., 2011; Pino-Lagos et al., 2011; Ross, 2012). These cells are part of tumour immuno-surveillance. Retinoids are reported to prevent various cancers in the skin and liver (Alizadeh et al., 2014). They promote stem cell differentiation through epigenetic modifications of histones or by altering chromatin structure to remove the stem cell from the self-renewing pluripotential state to a differentiated one (Gudas, 2013). Loss of the differentiated phenotype can lead to generation of cancer stem cells (Gudas, 2013). Retinoids activate DNA transcription in stem cells via retinoic acid receptors (RAR  $\alpha, \beta, \gamma$ ), retinoid X receptors (RXR  $\alpha, \beta, \gamma$ ) and other transcription factor regulatory proteins (Gudas and Wagner, 2011).

A study in Kenya found that HIV-positive women had a higher prevalence of vitamin A deficiency (<30  $\mu\text{g/dL}$ ) than HIV-negative women (59% vs 29%,  $p < 0.001$ ) (Baeten et al., 2002).

We hypothesize that vitamin A deficiency has three effects; it compromises the integrity of the surface epithelium creating micro-abrasions for HPV entry, it leads to cell-mediated immunodeficiency, and dysregulation of stem cell differentiation.

## 8. Downstream events after initiation of neoplasia

### 8.1. Uncontrolled cell replication

Human somatic cells can only undergo a limited number of cell divisions (50–70) then arrest, an event related to shortening of telomeres (Gomez et al., 2012). In comparison, epidermal stem cells can divide for more than 150 generations in vitro (Mathor et al., 1996). Telomeres are a repetitive sequence of nucleotides rich in guanine, synthesized by the enzyme telomerase, that cap the

ends of chromosomes to prevent chromosomes from deterioration (Blackburn and Gall, 1978). Usually telomeres shorten during each round of DNA replication but in advanced cancers telomerase is reactivated to maintain telomere length allowing many more cell divisions (Artandi and DePinho, 2010; Prescott et al., 2012). Downregulation of 14-3-3 $\sigma$  protein in keratinocytes maintains telomerase activity allowing them to escape replicative senescence (Dellambra et al., 2000).

### 8.2. Angiogenesis

Neovascularization occurs to meet the increased tumour metabolic demand. Tumours overproduce vascular growth factors such as vascular endothelial growth factor (VEGF) (Aonuma et al., 1999). In conjunctival tumours this manifests clinically as feeder vessels, enlarged blood vessels in the conjunctiva that perfuse the growth. In a Tanzanian study 88% of OSSN lesions and 61% of benign tumours had feeder vessels (Nguena et al., 2014).

### 8.3. Metastasis

Metastasis is considered a hallmark of malignancy. Cells loose adherence with each other and secrete proteolytic enzymes such as matrix metalloproteinases (MMPs) that degrade the extracellular matrix (Chiang and Massague, 2008). UVB radiation alters the balance between MMPs and tissue inhibitors of matrix metalloproteinases (TIMPs) (Ng et al., 2008). When exposed to UVB, cultured human dysplastic conjunctival epithelial cells show increased expression of MMP-1 and MMP-3 with little change in TIMP-1 unlike normal conjunctival cells (Ng et al., 2008). Increased MMP activity upsets cell-to-cell adhesion and promotes carcinogenesis and tumour invasion into surrounding tissues (Johansson et al., 2000). In lesions of squamous cell carcinoma of the conjunctiva MMPs and TIMP are overexpressed compared to normal conjunctiva and cornea (Di Girolamo et al., 2013).

## 9. Are cancer stem cells central to OSSN?

The short lifespan of ocular surface cells means that epithelial cells with DNA mutations do not last long enough to have an effect, as they are constantly being shed from the surface. The longevity of stem cells however gives them enough time to accumulate mutagenic insults. Why tumours are heterogeneous yet originating from the same stem cells could partly be explained by ongoing mutagenesis (Pardal et al., 2003).

The location of stem cells on the ocular surface coincides with the position of OSSN tumours while the growth pattern of lesions (from base upwards) is consistent with the stem cell theory. A study in Australia described concurrent existence of features of OSSN and primary acquired melanosis and stem cells arranged in micro-clusters in the basal epithelium in 12% of pterygia (Chui et al., 2011). Focus would necessarily have to shift to ocular surface limbal epithelial stem cells (LESCs) as the potential progenitors of OSSN to consider new explanations for tumour formation, new diagnostic methods to detect the LESCs and new treatments that target LESCs.

## 10. Conclusion

The known risk factors of OSSN – solar UV radiation, HIV and HPV are implicated in the aetiology. The pattern of distribution of OSSN lesions within the interpalpebral fissure of the ocular surface at the limbus, particularly the nasal side provides further clues. The site is highly vulnerable to solar UVR and has a high concentration of stem cells in the basal epithelium. Stem cells in the limbal

epithelial crypts are the likely originators of this disease, and may take on cancer stem cell properties.

Neoplasia is probably initiated when background solar UV radiation causes various forms of genetic and epigenetic DNA damage. UVB mainly creates pyrimidine dimers. Specific dimer CC  $\rightarrow$  TT transformation, a signature UV mutation, occurs at the p53 gene, a tumour suppressor that maintains cell-cycle arrest at the G1-S checkpoint. UV radiation also reactivates latent viruses such as HPV. HPV's E7 protein keeps infected cells in a proliferative state while E6 inhibits cell cycle arrest of DNA-damaged cells. Immunosuppression caused by UV radiation, HIV and vitamin A deficiency weakens the tumour surveillance system and allows DNA-damaged cells to proliferate into tumours. Vitamin A deficiency interferes with ocular surface integrity creating micro-abrasions through which HPV may invade the conjunctival basement membrane and epithelial cells. Cancer cells reactivate telomerase which maintains long telomeres increasing the number of cell divisions a cell can undergo. Further tumour expansion and metastasis is enhanced by angiogenesis and increased matrix metalloproteinases (MMPs) which destroy the intercellular matrix.

Despite these advances in our understanding there remain gaps, which are areas for further research. For example, there is no explanation why the disease is mostly unilateral despite both eyes receiving equal sunlight exposure. Equally the route of transmission of HPV to the conjunctiva is unknown. The drivers on a molecular level which convert intraepithelial neoplasia to squamous cell cancer are also out with our current understanding of the disease.

## Acknowledgements

SG received funding from the British Council for Prevention of Blindness (BCPB) fellowship programme. MJB is supported by The Wellcome Trust (Grant Number 098481/Z/12/Z).

## References

- Akpek, E.K., Gottsch, J.D., 2003. Immune defense at the ocular surface. *Eye (Lond.)* 17, 949–956.
- Al-Hajj, M., Wicha, M.S., Benito-Hernandez, A., Morrison, S.J., Clarke, M.F., 2003. Prospective identification of tumorigenic breast cancer cells. *Proc. Natl. Acad. Sci. U. S. A.* 100, 3983–3988.
- Alimonti, J.B., Ball, T.B., Fowke, K.R., 2003. Mechanisms of CD4+ T lymphocyte cell death in human immunodeficiency virus infection and AIDS. *J. Gen. Virol.* 84, 1649–1661.
- Alizadeh, F., Bolhassani, A., Khavari, A., Bathaie, S.Z., Naji, T., Bidgoli, S.A., 2014. Retinoids and their biological effects against cancer. *Int. Immunopharmacol.* 18, 43–49.
- American Joint Committee On Cancer, 2010. Carcinoma of the conjunctiva. In: Edge, S.B., Byrd, D.R., Compton, C.C., Fritz, A.G., Greene, F.L., Trotti, A. (Eds.), *Cancer Staging Handbook*, seventh ed. Springer, New York.
- Aoki, Y., Tosato, G., 2004. Neoplastic conditions in the context of HIV-1 infection. *Curr. HIV Res.* 2, 343–349.
- Aonuma, M., Saeki, Y., Akimoto, T., Nakayama, Y., Hattori, C., Yoshitake, Y., Nishikawa, K., Shibuya, M., Tanaka, N.G., 1999. Vascular endothelial growth factor overproduced by tumour cells acts predominantly as a potent angiogenic factor contributing to malignant progression. *Int. J. Exp. Pathol.* 80, 271–281.
- Artandi, S.E., DePinho, R.A., 2010. Telomeres and telomerase in cancer. *Carcinogenesis* 31, 9–18.
- Ateenyi-Agaba, C., Dai, M., Le Calvez, F., Katongole-Mbidde, E., Smet, A., Tommasino, M., Franceschi, S., Hainaut, P., Weiderpass, E., 2004. TP53 mutations in squamous-cell carcinomas of the conjunctiva: evidence for UV-induced mutagenesis. *Mutagenesis* 19, 399–401.
- Baeten, J.M., McClelland, R.S., Richardson, B.A., Bankson, D.D., Lavreys, L., Wener, M.H., Overbaugh, J., Mandaliya, K., Ndinya-Achola, J.O., Bwayo, J.J., Kreiss, J.K., 2002. Vitamin A deficiency and the acute phase response among HIV-1-infected and -uninfected women in Kenya. *J. Acquir. Immune Defic. Syndr.* 31, 243–249.
- Basti, S., Macsai, M.S., 2003. Ocular surface squamous neoplasia: a review. *Cornea* 22, 687–704.
- Besaratinia, A., Kim, S.I., Pfeifer, G.P., 2008. Rapid repair of UVA-induced oxidized purines and persistence of UVB-induced dipyrimidine lesions determine the mutagenicity of sunlight in mouse cells. *FASEB J.* 22, 2379–2392.

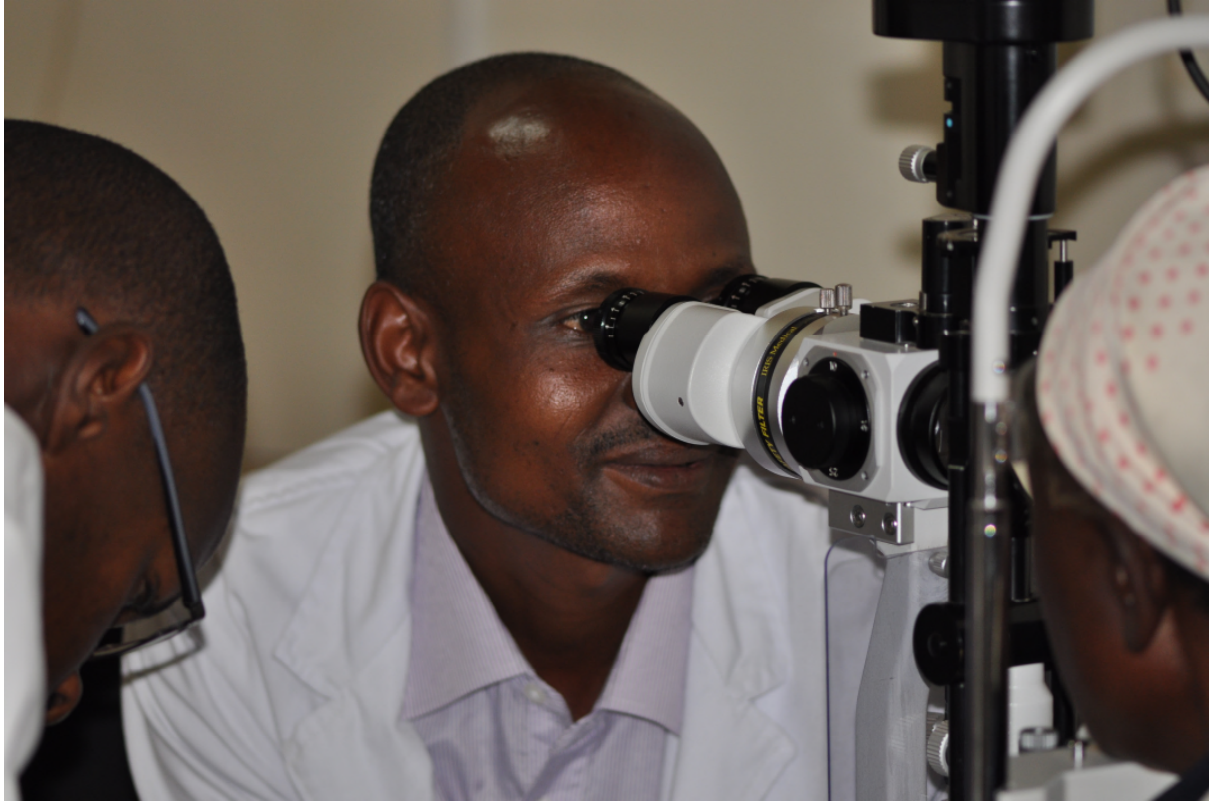- Besaratinia, A., Yoon, J.I., Schroeder, C., Bradforth, S.E., Cockburn, M., Pfeifer, G.P., 2011. Wavelength dependence of ultraviolet radiation-induced DNA damage as determined by laser irradiation suggests that cyclobutane pyrimidine dimers are the principal DNA lesions produced by terrestrial sunlight. *FASEB J.* 25, 3079–3091.
- Blackburn, E.H., Gall, J.G., 1978. A tandemly repeated sequence at the termini of the extrachromosomal ribosomal RNA genes in *Tetrahymena*. *J. Mol. Biol.* 120, 33–53.
- Blatt, A.N., Laycock, K.A., Brady, R.H., Traynor, P., Krogstad, D.J., Pepose, J.S., 1993. Prophylactic acyclovir effectively reduces herpes simplex virus type 1 reactivation after exposure of latently infected mice to ultraviolet B. *Investig. Ophthalmol. Vis. Sci.* 34, 3459–3465.
- Borras, C., Gomez-Cabrera, M.C., Vina, J., 2011. The dual role of p53: DNA protection and antioxidant. *Free Radic. Res.* 45, 643–652.
- Branzei, D., Foiani, M., 2008. Regulation of DNA repair throughout the cell cycle. *Nat. Rev. Mol. Cell Biol.* 9, 297–308.
- Breuer-Mcham, J., Simpson, E., Dougherty, I., Bonkobara, M., Ariizumi, K., Lewis, D.E., Dawson, D.B., Duvic, M., Cruz Jr., P.D., 2001. Activation of HIV in human skin by ultraviolet B radiation and its inhibition by NFkappaB blocking agents. *Photochem. Photobiol.* 74, 805–810.
- Bruni, L., Diaz, M., Castellsague, X., Ferrer, E., Bosch, F.X., De sanjose, S., 2010. Cervical human papillomavirus prevalence in 5 continents: meta-analysis of 1 million women with normal cytological findings. *J. Infect. Dis.* 202, 1789–1799.
- Buitrago-Perez, A., Garaulet, G., Vazquez-Carballo, A., Paramio, J.M., Garcia-Escudero, R., 2009. Molecular signature of HPV-induced carcinogenesis: pRb, p53 and gene expression profiling. *Curr. Genomics* 10, 26–34.
- Cadet, J., Douki, T., Ravanat, J.L., Di Mascio, P., 2009. Sensitized formation of oxidatively generated damage to cellular DNA by UVA radiation. *Photochem. Photobiol. Sci.* 8, 903–911.
- Carreira, H., Coutinho, F., Carrilho, C., Lunet, N., 2013. HIV and HPV infections and ocular surface squamous neoplasia: systematic review and meta-analysis. *Br. J. Cancer* 109, 1981–1988.
- Castro-Munozledo, F., 2013. Review: corneal epithelial stem cells, their niche and wound healing. *Mol. Vis.* 19, 1600–1613.
- Chee, K.Y., Kicic, A., Wiffen, S.J., 2006. Limbal stem cells: the search for a marker. *Clin. Exp. Ophthalmol.* 34, 64–73.
- Chen, X., Yang, M., Cheng, Y., Liu, G.J., Zhang, M., 2013. Narrow-band ultraviolet B phototherapy versus broad-band ultraviolet B or psoralen-ultraviolet A photochemotherapy for psoriasis. *Cochrane Database Syst. Rev.* 10, CD009481.
- Chiang, A.C., Massague, J., 2008. Molecular basis of metastasis. *N. Engl. J. Med.* 359, 2814–2823.
- Chisi, S.K., Kollmann, M.K., Karimurjo, J., 2006. Conjunctival squamous cell carcinoma in patients with human immunodeficiency virus infection seen at two hospitals in Kenya. *East Afr. Med. J.* 83, 267–270.
- Chui, J., Coroneo, M.T., Tat, L.T., Crouch, R., Wakefield, D., Di Girolamo, N., 2011. Ophthalmic pterygium: a stem cell disorder with premalignant features. *Am. J. Pathol.* 178, 817–827.
- Cloyd, M.W., Chen, J.J., Adeqboyege, P., Wang, L., 2001. How does HIV cause depletion of CD4 lymphocytes? A mechanism involving virus signaling through its cellular receptors. *Curr. Mol. Med.* 1, 545–550.
- Clydesdale, G.J., Dandie, G.W., Muller, H.K., 2001. Ultraviolet light induced injury: immunological and inflammatory effects. *Immunol. Cell Biol.* 79, 547–568.
- Contreras, A.U., Mebratu, Y., Delgado, M., Montano, G., Hu, C.A., Ryter, S.W., Choi, A.M., Lin, Y., Xiang, J., Chand, H., Tesfaygi, Y., 2013. Deacetylation of p53 induces autophagy by suppressing Bmf expression. *J. Cell Biol.* 201, 427–437.
- Cortat, B., Garcia, C.C., Quinet, A., Schuch, A.P., De Lima-Bessa, K.M., Menck, C.F., 2013. The relative roles of DNA damage induced by UVA irradiation in human cells. *Photochem. Photobiol. Sci.* 12, 1483–1495.
- Cotsarelis, G., Cheng, S.Z., Dong, C., Sun, T.T., Lavker, R.M., 1989. Existence of slow-cycling limbal epithelial basal cells that can be preferentially stimulated to proliferate: implications on epithelial stem cells. *Cell* 57, 201–209.
- Cvekl, A., Tamm, E.R., 2004. Anterior eye development and ocular mesenchyme: new insights from mouse models and human diseases. *Bioessays* 26, 374–386.
- Damin, D.C., Ziegelmann, P.K., Damin, A.P., 2013. Human papillomavirus infection and colorectal cancer risk: a meta-analysis. *Colorectal Dis.* 15, e420–e428.
- Delcuve, G.P., Rastegar, M., Davie, J.R., 2009. Epigenetic control. *J. Cell. Physiol.* 219, 243–250.
- Dellambra, E., Golisano, O., Bondanza, S., Siviero, E., Lacal, P., Molinari, M., D'atri, S., De Luca, M., 2000. Downregulation of 14-3-3sigma prevents clonal evolution and leads to immortalization of primary human keratinocytes. *J. Cell Biol.* 149, 1117–1130.
- Di Girolamo, N., 2010. Signalling pathways activated by ultraviolet radiation: role in ocular and cutaneous health. *Curr. Pharm. Des.* 16, 1358–1375.
- Di Girolamo, N., Atik, A., McCluskey, P.J., Wakefield, D., 2013. Matrix metalloproteinases and their inhibitors in squamous cell carcinoma of the conjunctiva. *Ocul. Surf.* 11, 193–205.
- Diffey, B.L., 2002. Sources and measurement of ultraviolet radiation. *Methods* 28, 4–13.
- Doorbar, J., 2005. The papillomavirus life cycle. *J. Clin. Virol.* 32 (Suppl. 1), S7–S15.
- Doorbar, J., 2013. Latent papillomavirus infections and their regulation. *Curr. Opin. Virol.* 3, 416–421.
- Du, Y., Funderburgh, M.L., Mann, M.M., Sundarraj, N., Funderburgh, J.L., 2005. Multipotent stem cells in human corneal stroma. *Stem Cells* 23, 1266–1275.
- Dua, H.S., Azuara-Blanco, A., 2000. Limbal stem cells of the corneal epithelium. *Surv. Ophthalmol.* 44, 415–425.
- Dua, H.S., Shanmuganathan, V.A., Powell-Richards, A.O., Tighe, P.J., Joseph, A., 2005. Limbal epithelial crypts: a novel anatomical structure and a putative limbal stem cell niche. *Br. J. Ophthalmol.* 89, 529–532.
- Duggal, R., Mineev, B., Geissinger, U., Wang, H., Chen, N.G., Koka, P.S., Szalay, A.A., 2014. Biotherapeutic approaches to target cancer stem cells. *J. Stem Cells* 8, 135–149.
- Dunne, E.F., Nielson, C.M., Stone, K.M., Markowitz, L.E., Giuliano, A.R., 2006. Prevalence of HPV infection among men: a systematic review of the literature. *J. Infect. Dis.* 194, 1044–1057.
- Feinberg, A.P., Ohlsson, R., Henikoff, S., 2006. The epigenetic progenitor origin of human cancer. *Nat. Rev. Genet.* 7, 21–33.
- Ford, J.M., 2005. Regulation of DNA damage recognition and nucleotide excision repair: another role for p53. *Mutat. Res.* 577, 195–202.
- Gibbs, N.K., Norval, M., 2013. Photoimmunosuppression: a brief overview. *Photochem. Photobiol.* 89, 57–64.
- Gichuhi, S., Sagoo, M.S., Weiss, H.A., Burton, M.J., 2013. Epidemiology of ocular surface squamous neoplasia in Africa. *Trop. Med. Int. Health* 18, 1424–1443.
- Goldberg, M.F., Bron, A.J., 1982. Limbal palisades of Vogt. *Trans. Am. Ophthalmol. Soc.* 80, 155–171.
- Gomez, D.E., Armando, R.G., Farina, H.G., Menna, P.L., Cerrudo, C.S., Ghiringhelli, P.D., Alonso, D.F., 2012. Telomere structure and telomerase in health and disease (review). *Int. J. Oncol.* 41, 1561–1569.
- Gonzalez, M.A., Bernad, A., 2012. Characteristics of adult stem cells. *Adv. Exp. Med. Biol.* 741, 103–120.
- Gooden, M.J., De Bock, G.H., Leffers, N., Daemen, T., Nijman, H.W., 2011. The prognostic influence of tumour-infiltrating lymphocytes in cancer: a systematic review with meta-analysis. *Br. J. Cancer* 105, 93–103.
- Gray, R.H., Johnson, G.J., Freedman, A., 1992. Climatic droplet keratopathy. *Surv. Ophthalmol.* 36, 241–253.
- Greiner, R., Volkmer, B., Henning, S., Breitbart, E.W., Greulich, K.O., Cardoso, M.C., Rapp, A., 2012. UVA-induced DNA double-strand breaks result from the repair of clustered oxidative DNA damages. *Nucleic Acids Res.* 40, 10263–10273.
- Gross, E., Sunwoo, J.B., Bui, J.D., 2013. Cancer immunosurveillance and immunoevasion by natural killer cells. *Cancer J.* 19, 483–489.
- Grulich, A.E., Van Leeuwen, M.T., Falster, M.O., Vajdic, C.M., 2007. Incidence of cancers in people with HIV/AIDS compared with immunosuppressed transplant recipients: a meta-analysis. *Lancet* 370, 59–67.
- Gudas, L.J., 2013. Retinoids induce stem cell differentiation via epigenetic changes. *Semin. Cell Dev. Biol.* 24, 701–705.
- Gudas, L.J., Wagner, J.A., 2011. Retinoids regulate stem cell differentiation. *J. Cell. Physiol.* 226, 322–330.
- Haddad, A., 2000. Renewal of the rabbit corneal epithelium as investigated by autoradiography after intravitreal injection of 3H-thymidine. *Cornea* 19, 378–383.
- Hall, J.A., Cannons, J.L., Grainger, J.R., Dos Santos, L.M., Hand, T.W., Naik, S., Wohlfert, E.A., Chou, D.B., Oldenhove, G., Robinson, M., Grigg, M.E., Kastenmayer, R., Schwartzberg, P.L., Belkaid, Y., 2011. Essential role for retinoic acid in the promotion of CD4(+) T cell effector responses via retinoic acid receptor alpha. *Immunity* 34, 435–447.
- Hanna, C., O'Brien, J.E., 1960. Cell production and migration in the epithelial layer of the cornea. *Arch. Ophthalmol.* 64, 536–539.
- Hegde, M.L., Hazra, T.K., Mitra, S., 2008. Early steps in the DNA base excision/single-strand interruption repair pathway in mammalian cells. *Cell. Res.* 18, 27–47.
- Herfs, M., Yamamoto, Y., Laury, A., Wang, X., Nucci, M.R., McLaughlin-Drubin, M.E., Munger, K., Feldman, S., Mckeon, F.D., Xian, W., Crum, C.P., 2012. A discrete population of squamocolumnar junction cells implicated in the pathogenesis of cervical cancer. *Proc. Natl. Acad. Sci. U. S. A.* 109, 10516–10521.
- Hesse, M., Raulf, A., Pilz, G.A., Haberlandt, C., Klein, A.M., Jabs, R., Zaehres, H., Fugemann, C.J., Zimmermann, K., Trebicka, J., Welz, A., Pfeifer, A., Roll, W., Kotlikoff, M.I., Steinhäuser, C., Gotz, M., Scholer, H.R., Fleischmann, B.K., 2012. Direct visualization of cell division using high-resolution imaging of M-phase of the cell cycle. *Nat. Commun.* 3, 1076.
- Higa, K., Shimmura, S., Miyashita, H., Shimazaki, J., Tsubota, K., 2005. Melanocytes in the corneal limbus interact with K19-positive basal epithelial cells. *Exp. Eye Res.* 81, 218–223.
- Hingorani, M., Metz, D., Lightman, S.L., 1997. Characterisation of the normal conjunctival leukocyte population. *Exp. Eye Res.* 64, 905–912.
- Hu, J., Choi, J.H., Gaddameedhi, S., Kemp, M.G., Reardon, J.T., Sancar, A., 2013. Nucleotide excision repair in human cells: fate of the excised oligonucleotide carrying DNA damage in vivo. *J. Biol. Chem.* 288, 20918–20926.
- Hunt, P.W., 2012. HIV and inflammation: mechanisms and consequences. *Curr. HIV/AIDS Rep.* 9, 139–147.
- Ikehata, H., Ono, T., 2011. The mechanisms of UV mutagenesis. *J. Radiat. Res.* 52, 115–125.
- Imoto, Y., Yoshida, Y., Yagisawa, F., Kuroiwa, H., Kuroiwa, T., 2011. The cell cycle, including the mitotic cycle and organelle division cycles, as revealed by cytological observations. *J. Electron Microsc. (Tokyo)* 60 (Suppl. 1), S117–S136.
- Jin, B., Robertson, K.D., 2013. DNA methyltransferases, DNA damage repair, and cancer. *Adv. Exp. Med. Biol.* 754, 3–29.
- Johansson, N., Ahonen, M., Kahari, V.M., 2000. Matrix metalloproteinases in tumor invasion. *Cell. Mol. Life Sci.* 57, 5–15.
- Johnson, K.M., Kines, R.C., Roberts, J.N., Lowy, D.R., Schiller, J.T., Day, P.M., 2009. Role of heparan sulfate in attachment to and infection of the murine female genital tract by human papillomavirus. *J. Virol.* 83, 2067–2074.

- Kanazawa, S., Kitaoka, T., Ueda, Y., Gong, H., Amemiya, T., 2002. Interaction of zinc and vitamin A on the ocular surface. *Graefes Arch. Clin. Exp. Ophthalmol.* 240, 1011–1021.
- Kao, W.W., Xia, Y., Liu, C.Y., Saika, S., 2008. Signaling pathways in morphogenesis of cornea and eyelid. *Ocul. Surf.* 6, 9–23.
- Kines, R.C., Thompson, C.D., Lowy, D.R., Schiller, J.T., Day, P.M., 2009. The initial steps leading to papillomavirus infection occur on the basement membrane prior to cell surface binding. *Proc. Natl. Acad. Sci. U. S. A.* 106, 20458–20463.
- Knop, E., Knop, N., 2007. Anatomy and immunology of the ocular surface. *Chem. Immunol. Allergy* 92, 36–49.
- Kolega, J., Manabe, M., Sun, T.T., 1989. Basement membrane heterogeneity and variation in corneal epithelial differentiation. *Differentiation* 42, 54–63.
- Korzeniewski, N., Spardy, N., Duensing, A., Duensing, S., 2011. Genomic instability and cancer: lessons learned from human papillomaviruses. *Cancer Lett.* 305, 113–122.
- Lane, D.P., 1992. Cancer. p53, guardian of the genome. *Nature* 358, 15–16.
- Lavker, R.M., Dong, G., Cheng, S.Z., Kudoh, K., Cotsarelis, G., Sun, T.T., 1991. Relative proliferative rates of limbal and corneal epithelia. Implications of corneal epithelial migration, circadian rhythm, and suprabasally located DNA-synthesizing keratinocytes. *Investig. Ophthalmol. Vis. Sci.* 32, 1864–1875.
- Lee, C.J., Dosch, J., Simeone, D.M., 2008. Pancreatic cancer stem cells. *J. Clin. Oncol.* 26, 2806–2812.
- Lee, G.A., Hirst, L.W., 1995. Ocular surface squamous neoplasia. *Surv. Ophthalmol.* 39, 429–450.
- Lee, G.A., Hirst, L.W., 1997. Retrospective study of ocular surface squamous neoplasia. *Aust. N. Z. J. Ophthalmol.* 25, 269–276.
- Lehoux, M., D'abramo, C.M., Archambault, J., 2009. Molecular mechanisms of human papillomavirus-induced carcinogenesis. *Public Health Genomics* 12, 268–280.
- Lehrer, M.S., Sun, T.T., Lavker, R.M., 1998. Strategies of epithelial repair: modulation of stem cell and transit amplifying cell proliferation. *J. Cell Sci.* 111 (Pt 19), 2867–2875.
- Levine, A.J., Hu, W., Feng, Z., 2006. The P53 pathway: what questions remain to be explored? *Cell Death Differ.* 13, 1027–1036.
- Li, H., Yang, Y., Zhang, R., Cai, Y., Yang, X., Wang, Z., Li, Y., Cheng, X., Ye, X., Xiang, Y., Zhu, B., 2013a. Preferential sites for the integration and disruption of human papillomavirus 16 in cervical lesions. *J. Clin. Virol.* 56, 342–347.
- Li, N., Yang, L., Zhang, Y., Zhao, P., Zheng, T., Dai, M., 2011. Human papillomavirus infection and bladder cancer risk: a meta-analysis. *J. Infect. Dis.* 204, 217–223.
- Li, X., Gao, C., Yang, Y., Zhou, F., Li, M., Jin, Q., Gao, L., 2014. Systematic review with meta-analysis: the association between human papillomavirus infection and oesophageal cancer. *Aliment. Pharmacol. Ther.* 39 (3), 270–281.
- Li, X., Gao, L., Li, H., Gao, J., Yang, Y., Zhou, F., Gao, C., Li, M., Jin, Q., 2013b. Human papillomavirus infection and laryngeal cancer risk: a systematic review and meta-analysis. *J. Infect. Dis.* 207, 479–488.
- Lin, Q., Yun, Z., 2010. Impact of the hypoxic tumor microenvironment on the regulation of cancer stem cell characteristics. *Cancer Biol. Ther.* 9, 949–956.
- Lissouba, P., Van De Perre, P., Auvert, B., 2013. Association of genital human papillomavirus infection with HIV acquisition: a systematic review and meta-analysis. *Sex. Transm. Infect.* 89, 350–356.
- longworth, M.S., Laimins, L.A., 2004. Pathogenesis of human papillomaviruses in differentiating epithelia. *Microbiol. Mol. Biol. Rev.* 68, 362–372.
- Lundin, K., Nygren, A., Arthur, L.O., Robey, W.G., Morein, B., Ramstedt, U., Gidlund, M., Wigzell, H., 1987. A specific assay measuring binding of 125I-Gp 120 from HIV to T4+/CD4+ cells. *J. Immunol. Methods* 97, 93–100.
- Maglennon, G.A., McIntosh, P., Doorbar, J., 2011. Persistence of viral DNA in the epithelial basal layer suggests a model for papillomavirus latency following immune regression. *Virology* 414, 153–163.
- Maglennon, G.A., McIntosh, P.B., Doorbar, J., 2014. Immunosuppression facilitates the reactivation of latent papillomavirus infections. *J. Virol.* 88 (1), 710–716.
- Maloof, A.J., Ho, A., Coroneo, M.T., 1994. Influence of corneal shape on limbal light focusing. *Investig. Ophthalmol. Vis. Sci.* 35, 2592–2598.
- Mantovani, A., Allavena, P., Sica, A., Balkwill, F., 2008. Cancer-related inflammation. *Nature* 454, 436–444.
- Martin, G.R., 1981. Isolation of a pluripotent cell line from early mouse embryos cultured in medium conditioned by teratocarcinoma stem cells. *Proc. Natl. Acad. Sci. U. S. A.* 78, 7634–7638.
- Mathor, M.B., Ferrari, G., Dellambra, E., Cilli, M., Mavilio, F., Cancedda, R., De Luca, M., 1996. Clonal analysis of stably transduced human epidermal stem cells in culture. *Proc. Natl. Acad. Sci. U. S. A.* 93, 10371–10376.
- Mbulaitye, S.M., Biggar, R.J., Goedert, J.J., Engels, E.A., 2003. Immune deficiency and risk for malignancy among persons with AIDS. *J. Acquir. Immune Defic. Syndr.* 32, 527–533.
- Mcbride, O.W., Merry, D., Givol, D., 1986. The gene for human p53 cellular tumor antigen is located on chromosome 17 short arm (17p13). *Proc. Natl. Acad. Sci. U. S. A.* 83, 130–134.
- Mckelvie, P., 2003. Ocular surface impression cytology. *Adv. Anat. Pathol.* 10, 328–337.
- Meek, D.W., 2009. Tumour suppression by p53: a role for the DNA damage response? *Nat. Rev. Cancer* 9, 714–723.
- Michael, S., Lambert, P.F., Strati, K., 2013. The HPV16 oncogenes cause aberrant stem cell mobilization. *Virology* 443, 218–225.
- Miller, J.K., Laycock, K.A., Nash, M.M., Pepose, J.S., 1993. Corneal Langerhans cell dynamics after herpes simplex virus reactivation. *Investig. Ophthalmol. Vis. Sci.* 34, 2282–2290.
- Mohr, M., Bourke, E., Alexander, D., Warr, M.R., Barry-Holson, K., Le Beau, M.M., Morrison, C.G., Passegue, E., 2010. Hematopoietic stem cell quiescence promotes error-prone DNA repair and mutagenesis. *Cell Stem Cell* 7, 174–185.
- Moore, N., Lyle, S., 2011. Quiescent, slow-cycling stem cell populations in cancer: a review of the evidence and discussion of significance. *J. Oncol.* 2011.
- Munoz, N., 2000. Human papillomavirus and cancer: the epidemiological evidence. *J. Clin. Virol.* 19, 1–5.
- Nagasaki, T., Zhao, J., 2005. Uniform distribution of epithelial stem cells in the bulbar conjunctiva. *Investig. Ophthalmol. Vis. Sci.* 46, 126–132.
- Neuhaus, J., Jacobs Jr., D.R., Baker, J.V., Calmy, A., Duprez, D., La Rosa, A., Kuller, L.H., Pett, S.L., Ristola, M., Ross, M.J., Shlipak, M.G., Tracy, R., Neaton, J.D., 2010. Markers of inflammation, coagulation, and renal function are elevated in adults with HIV infection. *J. Infect. Dis.* 201, 1788–1795.
- Ng, J., Coroneo, M.T., Wakefield, D., Di Girolamo, N., 2008. Ultraviolet radiation and the role of matrix metalloproteinases in the pathogenesis of ocular surface squamous neoplasia. *Investig. Ophthalmol. Vis. Sci.* 49, 5295–5306.
- Nguena, M.B., Van Den Tweel, J.G., Makupa, W., Hu, V.H., Weiss, H.A., Gichuhi, S., Burton, M.J., 2014. Diagnosing ocular surface squamous neoplasia in East Africa: case-control study of clinical and in vivo confocal microscopy assessment. *Ophthalmology* 121 (2), 484–491.
- Norval, M., Mcloone, P., Lesiak, A., Narbutt, J., 2008. The effect of chronic ultraviolet radiation on the human immune system. *Photochem. Photobiol.* 84, 19–28.
- Obokata, H., Wakayama, T., Sasai, Y., Kojima, K., Vacanti, M.P., Niwa, H., Yamato, M., Vacanti, C.A., 2014. Stimulus-triggered fate conversion of somatic cells into pluripotency. *Nature* 505, 641–647.
- Osei-Bempong, C., Figueiredo, F.C., Lako, M., 2013. The limbal epithelium of the eye – a review of limbal stem cell biology, disease and treatment. *Bioessays* 35, 211–219.
- Pardal, R., Clarke, M.F., Morrison, S.J., 2003. Applying the principles of stem-cell biology to cancer. *Nat. Rev. Cancer* 3, 895–902.
- Pellegrini, G., Golisano, O., Paterna, P., Lambiase, A., Bonini, S., Rama, P., De Luca, M., 1999. Location and clonal analysis of stem cells and their differentiated progeny in the human ocular surface. *J. Cell Biol.* 145, 769–782.
- Pfeifer, G.P., You, Y.H., Besaratinia, A., 2005. Mutations induced by ultraviolet light. *Mutat. Res.* 571, 19–31.
- Pino-Lagos, K., Guo, Y., Brown, C., Alexander, M.P., Elgueta, R., Bennett, K.A., De Vries, V., Nowak, E., Blomhoff, R., Sockanathan, S., Chandraratna, R.A., Dmitrovsky, E., Noelle, R.J., 2011. A retinoic acid-dependent checkpoint in the development of CD4+ T cell-mediated immunity. *J. Exp. Med.* 208, 1767–1775.
- Poon, T.S., Barnetson, R.S., Halliday, G.M., 2005. Sunlight-induced immunosuppression in humans is initially because of UVB, then UVA, followed by interactive effects. *J. Invest. Dermatol.* 125, 840–846.
- Prescott, J., Wentzensen, I.M., Savage, S.A., De Vivo, I., 2012. Epidemiologic evidence for a role of telomere dysfunction in cancer etiology. *Mutat. Res.* 730, 75–84.
- Rastogi, R.P., Richa, Kumar, A., Tyagi, M.B., Sinha, R.P., 2010. Molecular mechanisms of ultraviolet radiation-induced DNA damage and repair. *J. Nucleic Acids* 2010, 592980.
- Reardon, J.T., Sancar, A., 2005. Nucleotide excision repair. *Prog. Nucleic Acid Res. Mol. Biol.* 79, 183–235.
- Rice, P.S., 2011. Ultra-violet radiation is responsible for the differences in global epidemiology of chickenpox and the evolution of varicella-zoster virus as man migrated out of Africa. *Virol. J.* 8, 189.
- Rivlin, N., Brosh, R., Oren, M., Rotter, V., 2011. Mutations in the p53 tumor suppressor gene: important milestones at the various steps of tumorigenesis. *Genes Cancer* 2, 466–474.
- Ross, A.C., 2012. Vitamin A and retinoic acid in T cell-related immunity. *Am. J. Clin. Nutr.* 96, 1166S–1172S.
- Sancar, A., Lindsey-Boltz, L.A., Unsal-Kacmaz, K., Linn, S., 2004. Molecular mechanisms of mammalian DNA repair and the DNA damage checkpoints. *Annu. Rev. Biochem.* 73, 39–85.
- Sapp, M., Bienkowska-Haba, M., 2009. Viral entry mechanisms: human papillomavirus and a long journey from extracellular matrix to the nucleus. *FEBS J.* 276, 7206–7216.
- Schermer, A., Galvin, S., Sun, T.T., 1986. Differentiation-related expression of a major 64K corneal keratin in vivo and in culture suggests limbal location of corneal epithelial stem cells. *J. Cell Biol.* 103, 49–62.
- Schlotzer-Schrehardt, U., Dietrich, T., Saito, K., Sorokin, L., Sasaki, T., Paulsson, M., Kruse, F.E., 2007. Characterization of extracellular matrix components in the limbal epithelial stem cell compartment. *Exp. Eye Res.* 85, 845–860.
- Schlotzer-Schrehardt, U., Kruse, F.E., 2005. Identification and characterization of limbal stem cells. *Exp. Eye Res.* 81, 247–264.
- Schreiber, R.D., Old, L.J., Smyth, M.J., 2011. Cancer immunotherapy: integrating immunity's roles in cancer suppression and promotion. *Science* 331, 1565–1570.
- Schwarz, T., Schwarz, A., 2011. Molecular mechanisms of ultraviolet radiation-induced immunosuppression. *Eur. J. Cell Biol.* 90, 560–564.
- Sejpal, K., Bakhtiar, P., Deng, S.X., 2013. Presentation, diagnosis and management of limbal stem cell deficiency. *Middle East Afr. J. Ophthalmol.* 20, 5–10.
- Sell, S., Leffert, H.L., 2008. Liver cancer stem cells. *J. Clin. Oncol.* 26, 2800–2805.
- Shanmuganathan, V.A., Foster, T., Kulkarni, B.B., Hopkinson, A., Gray, T., Powe, D.G., Lowe, J., Dua, H.S., 2007. Morphological characteristics of the limbal epithelial crypt. *Br. J. Ophthalmol.* 91, 514–519.
- Shi, M.M., Xiong, Y.L., Jia, X.S., Li, X., Zhang, L., Li, X.L., Wang, E.H., 2013. Fluorouracil selectively enriches stem-like cells in the lung adenocarcinoma cell line SPC. *Tumour Biol.* 34, 1503–1510.



- Shields, C.L., Demirci, H., Karatza, E., Shields, J.A., 2004. Clinical survey of 1643 melanocytic and nonmelanocytic conjunctival tumors. *Ophthalmology* 111, 1747–1754.
- Simbiri, K.O., Murakami, M., Feldman, M., Steenhoff, A.P., Nkomazana, O., Bisson, G., Robertson, E.S., 2010. Multiple oncogenic viruses identified in ocular surface squamous neoplasia in HIV-1 patients. *Infect. Agent Cancer* 5, 6.
- Sinha, R.P., Hader, D.P., 2002. UV-induced DNA damage and repair: a review. *Photochem. Photobiol. Sci.* 1, 225–236.
- Stanley, M.A., 2012. Epithelial cell responses to infection with human papillomavirus. *Clin. Microbiol. Rev.* 25, 215–222.
- Sudhalkar, A., 2012. Fixation and its role in the causation, laterality and location of pterygium: a study in amblyopes and non-amblyopes. *Eye (Lond.)* 26, 438–443.
- Sun, T.T., Tseng, S.C., Lavker, R.M., 2010. Location of corneal epithelial stem cells. *Nature* 463, E10–E11 (discussion E11).
- Svilar, D., Goellner, E.M., Almeida, K.H., Sobol, R.W., 2011. Base excision repair and lesion-dependent subpathways for repair of oxidative DNA damage. *Antioxid. Redox Signal* 14, 2491–2507.
- Taguchi, K., Fukunaga, A., Ogura, K., Nishigori, C., 2013. The role of epidermal Langerhans cells in NB-UVB-induced immunosuppression. *Kobe J. Med. Sci.* 59, E1–E9.
- Takahashi, K., Tanabe, K., Ohnuki, M., Narita, M., Ichisaka, T., Tomoda, K., Yamanaka, S., 2007. Induction of pluripotent stem cells from adult human fibroblasts by defined factors. *Cell* 131, 861–872.
- Takaishi, S., Okumura, T., Wang, T.C., 2008. Gastric cancer stem cells. *J. Clin. Oncol.* 26, 2876–2882.
- Tili, E., Michaille, J.J., Wernicke, D., Alder, H., Costinean, S., Volinia, S., Croce, C.M., 2011. Mutator activity induced by microRNA-155 (miR-155) links inflammation and cancer. *Proc. Natl. Acad. Sci. U. S. A.* 108, 4908–4913.
- Ueno, H., Ferrari, G., Hattori, T., Saban, D.R., Katikireddy, K.R., Chauhan, S.K., Dana, R., 2012. Dependence of corneal stem/progenitor cells on ocular surface innervation. *Investig. Ophthalmol. Vis. Sci.* 53, 867–872.
- Valeri, N., Gasparini, P., Fabbri, M., Braconi, C., Veronese, A., Lovat, F., Adair, B., Vannini, I., Fanini, F., Bottoni, A., Costinean, S., Sandhu, S.K., Nuovo, G.J., Alder, H., Gafa, R., Calore, F., Ferracin, M., Lanza, G., Volinia, S., Negrini, M., McIlhatton, M.A., Amadori, D., Fishel, R., Croce, C.M., 2010. Modulation of mismatch repair and genomic stability by miR-155. *Proc. Natl. Acad. Sci. U. S. A.* 107, 6982–6987.
- Van Der Sluis, R.M., Jeeninga, R.E., Berkhout, B., 2013. Establishment and molecular mechanisms of HIV-1 latency in T cells. *Curr. Opin. Virol.* 3 (6), 700–706.
- Van Lint, C., Bouchat, S., Marcello, A., 2013. HIV-1 transcription and latency: an update. *Retrovirology* 10, 67.
- Waddell, K.M., Downing, R.G., Lucas, S.B., Newton, R., 2006. Corneo-conjunctival carcinoma in Uganda. *Eye (Lond.)* 20, 893–899.
- Walters, D.M., 2013. Epigenetic considerations in medicine. *N. C. Med. J.* 74, 534–536.
- Wang, W., Quan, Y., Fu, Q., Liu, Y., Liang, Y., Wu, J., Yang, G., Luo, C., Ouyang, Q., Wang, Y., 2014. Dynamics between cancer cell subpopulations reveals a model coordinating with both hierarchical and stochastic concepts. *PLoS One* 9, e84654.
- Wang, Z., Song, J., Taichman, R.S., Krebsbach, P.H., 2006. Ablation of proliferating marrow with 5-fluorouracil allows partial purification of mesenchymal stem cells. *Stem Cells* 24, 1573–1582.
- Wei, Z.G., Cotsarelis, G., Sun, T.T., Lavker, R.M., 1995. Label-retaining cells are preferentially located in fornical epithelium: implications on conjunctival epithelial homeostasis. *Investig. Ophthalmol. Vis. Sci.* 36, 236–246.
- Wei, Z.G., Sun, T.T., Lavker, R.M., 1996. Rabbit conjunctival and corneal epithelial cells belong to two separate lineages. *Investig. Ophthalmol. Vis. Sci.* 37, 523–533.
- Wicha, M.S., Liu, S., Dontu, G., 2006. Cancer stem cells: an old idea—a paradigm shift. *Cancer Res.* 66, 1883–1890 (discussion 1895–1896).
- Wirtschafter, J.D., Mcloon, L.K., Ketcham, J.M., Weinstock, R.J., Cheung, J.C., 1997. Palpebral conjunctival transient amplifying cells originate at the mucocutaneous junction and their progeny migrate toward the fornix. *Trans. Am. Ophthalmol. Soc.* 95, 417–429 (discussion 429–432).
- Wodarz, D., 2007. Effect of stem cell turnover rates on protection against cancer and aging. *J. Theor. Biol.* 245, 449–458.
- Xu, Z., Taylor, J.A., 2014. Genome-wide age-related DNA methylation changes in blood and other tissues relate to histone modification, expression, and cancer. *Carcinogenesis* 35 (2), 356–364.
- Yamamoto, J., Oyama, T., Kunishi, T., Masutani, C., Hanaoka, F., Iwai, S., 2014. A cyclobutane thymine-N4-methylcytosine dimer is resistant to hydrolysis but strongly blocks DNA synthesis. *Nucleic Acids Res.* 42 (3), 2075–2084.
- Yang, Y.M., Chang, J.W., 2008. Current status and issues in cancer stem cell study. *Cancer Investig.* 26, 741–755.
- Yuan, X., Curtin, J., Xiong, Y., Liu, G., Waschmann-Hogiu, S., Farkas, D.L., Black, K.L., Yu, J.S., 2004. Isolation of cancer stem cells from adult glioblastoma multiforme. *Oncogene* 23, 9392–9400.
- Zajicek, G., Perry, A., Pe'er, J., 1995. Streaming of labelled cells in the conjunctival epithelium. *Cell. Prolif.* 28, 235–243.
- Zak-Prelich, M., Borkowski, J.L., Alexander, F., Norval, M., 2002. The role of solar ultraviolet irradiation in zoster. *Epidemiol. Infect.* 129, 593–597.
- Zhang, P., Nouri, M., Brandsma, J.L., Iftner, T., Steinberg, B.M., 1999. Induction of E6/E7 expression in cottontail rabbit papillomavirus latency following UV activation. *Virology* 263, 388–394.

## Chapter 3. Diagnosis of ocular surface squamous neoplasia



The following is a review of current diagnostic methods for OSSN and the related challenges.

## 1. Clinical diagnosis

Many clinicians rely on their clinical impression to make a diagnosis of OSSN. A standard of care survey in the USA found that only about half the ophthalmologists always perform a biopsy before instituting topical therapy for suspected OSSN lesions.<sup>1</sup>

Red eye, photophobia, irritation, foreign body sensation and a whitish painless progressive growth are common presenting symptoms.<sup>2-4</sup> Various clinical features may be seen in OSSN. Most lesions occur in the interpalpebral fissure especially on the nasal side.<sup>5</sup> They involve the conjunctiva and may extend onto the peripheral cornea so visual acuity is often normal in the early lesions. For reasons that are unclear, most lesions are unilateral.<sup>6</sup> Bilateral cases are rare.<sup>7</sup> Perhaps an immune response to the first tumour prevents further tumour establishment in the fellow eye, however, this remains to be proven. The surface may be gelatinous, papillomatous or fibrovascular.<sup>8</sup> There may be accompanying inflammation of the ocular surface, leukoplakia and markedly dilated blood vessels referred to as feeder vessels.<sup>9</sup> The lesions may be flat or raised and of variable size. Late lesions present as large fungating orbital masses. At this stage a diagnosis of OSSN seems obvious as few other diseases present that way.

A study in Tanzania evaluated various symptoms and signs that may distinguish OSSN from benign lesions and found that OSSN tumours were more likely to have a shorter mean duration than benign lesions (3.7 months vs 8.8 months,  $p=0.029$ ), show feeder vessels ( $p=0.034$ ) and have a gelatinous surface ( $p=0.055$ ) than benign lesions (Table 3.1).<sup>10</sup> Studies have also evaluated features that may distinguish different grades of OSSN. A study in USA found that male gender, temporal and superior locations, lack of corneal involvement, papillomatous and nodular appearance were associated with higher-grade OSSN lesions.<sup>11</sup> A second study in Tanzania found that the patients' age, size of lesion and lesion pigmentation were associated with the degree of malignancy defined by histological grade of OSSN (Table 3.2).<sup>12</sup>

**Table 3.1 Clinical features of OSSN and other benign conjunctival tumours are similar in a Tanzania study.<sup>10</sup>**

	OSSN (N=34)	Benign Lesions* (N=18)	P-value
<b>Symptom</b>			
Irritated red eye	21 (61.7%)	8 (44.4%)	0.26
Discharge	20 (58.8%)	11 (61.1%)	1.00
Foreign body sensation	14 (41.1%)	10 (55.5%)	0.39
Decreased vision	8 (23.5%)	3 (16.6%)	0.73
Pain	5 (14.7%)	5 (27.7%)	0.29
Proptosis	5 (14.7%)	1 (5.5%)	0.65
Itchy	2 (5.8%)	1 (5.5%)	1.00
Mean duration in months, (95%CI)	3.7 (2.4-5.8)	8.8 (3.9-19)	0.029 <sup>a</sup>
<b>Sign</b>			
Feeder vessel	30 (88.2%)	11 (61.1%)	0.034
Limbal involvement	26 (76.4%)	9 (50.0%)	0.07
Leukoplakia	15 (44.1%)	3 (16.6%)	0.07
Gelatinous	13 (38.2%)	2 (11.1%)	0.055
Pedunculated	4 (11.7%)	2 (11.1%)	1.00
Papilliform	2 (5.8%)	1 (5.5%)	1.00
Orbital invasion	2 (5.8%)	0 (0.0%)	0.54
Fibrovascular tissue	1 (2.9%)	7 (44.4%)	0.001

\* Including one lymphoma case

<sup>a</sup> p-values calculated using Fisher exact test for variables except duration, which was calculated by Wilcoxon rank-sum test.

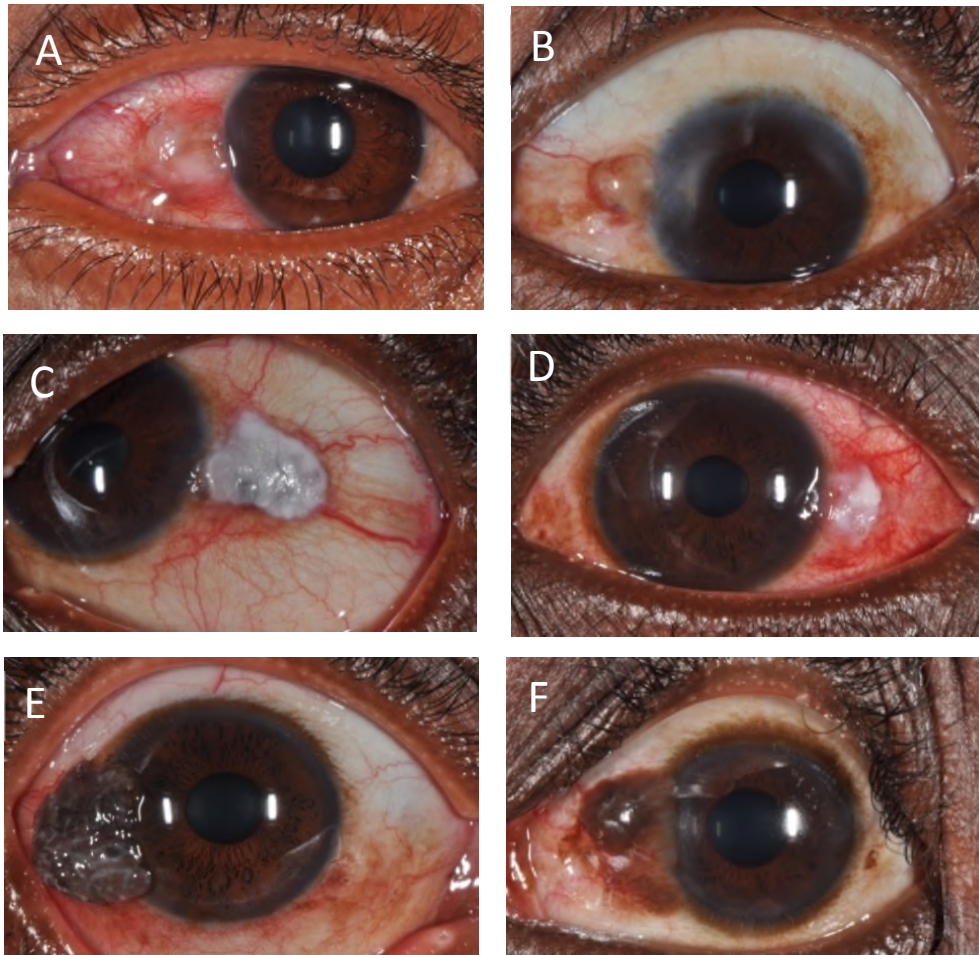
**Table 3.2. Clinical features that distinguish various grades of OSSN<sup>12</sup>**

Feature	Histological grade of OSSN			p-value <sup>a</sup>
	Mild-moderate dysplasia n(%) or mean(SD)	Severe dysplasia n(%) or mean(SD)	Squamous cell carcinoma n(%) or mean(SD)	
Mean age, (SD),y	34.8 (8.6)	38.1 (11.4)	43.6 (14.9)	0.016
Lesion size (mm)				
≤5	17 (30.9%)	33 (60.0%)	5 (9.1%)	0.002
>5	11 (14.3%)	40 (52.0%)	26 (33.7%)	
Lesion pigmentation	4 (10%)	22 (55%)	14 (35%)	0.036

<sup>a</sup> the paper did not report how p-values were calculated

However the predictive value of the clinical features has not been formally assessed. Clinically it is difficult to distinguish dysplasias from invasive squamous cell carcinomas. Also the appearance of OSSN overlaps with several other lesions of the conjunctiva including benign changes such as pterygium and pinguecula, or premalignant lesions such as actinic keratosis (Table 3.1 and Figure 3.1).<sup>13</sup> In addition, OSSN lesions especially in Africans are often pigmented and the conjunctival nevi seen can be fleshy with leukoplakia, which makes distinction between OSSN and nevi difficult. In a study of 287 cases of conjunctival squamous carcinoma in Mexico, clinical diagnosis was correct in only 41% of them.<sup>14</sup>

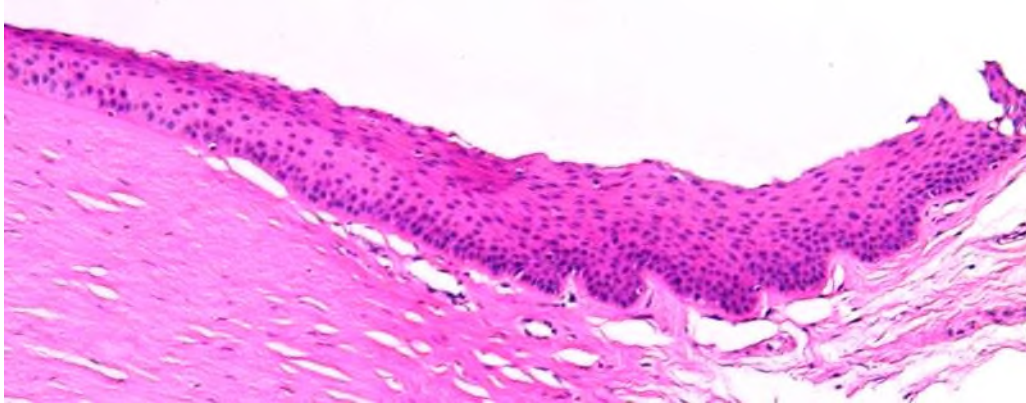
**Figure 3.1** This montage shows lesions that may mimic OSSN. All the lesions in the left column (A, C, E) are moderately differentiated squamous cell carcinoma (SCC), while the lesions in the right column are not OSSN, but appear similar. (A) SCC with a gelatinous surface, (B) pterygium, (C) SCC with leukoplakia, (D) actinic keratosis with leukoplakia, (E) SCC with pigmentation and (F) a nevus.



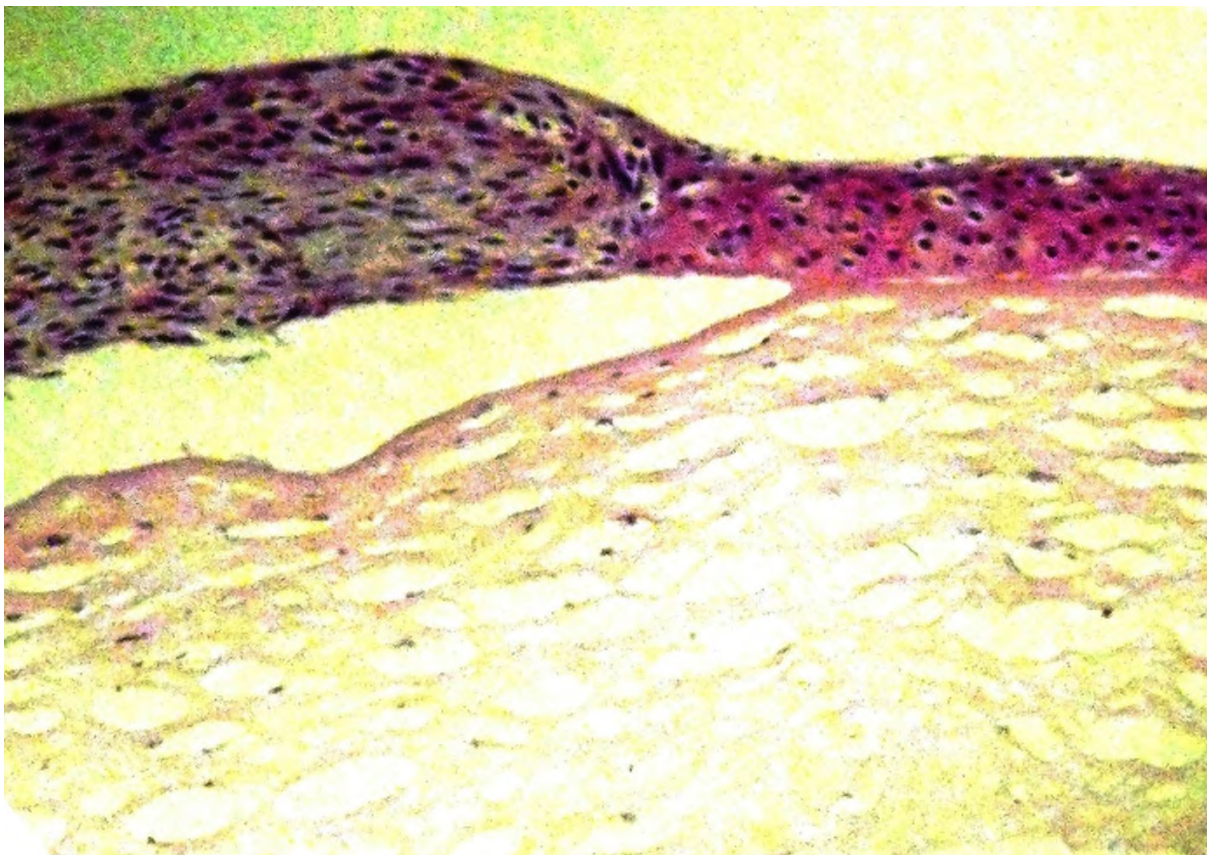## 2. Histopathology

The normal conjunctiva is divided into 3 regions: (1) the palpebral (tarsal) conjunctiva on the inner aspect of the upper lid has stratified columnar epithelial cells with little substantia propria, (2) the fornix has abundant goblet cells, loose stroma, lymphatics and accessory lacrimal glands of Krause, and (3) the bulbar conjunctiva on the eyeball, in which the epithelium changes from stratified columnar to stratified squamous near the limbus and has few goblet cells and melanocytes (Figure 3.2a). Where the lesion is excised with a 2-4 mm margin of normal tissue, an abrupt transition can be seen between the tumour and adjoining normal tissue (Figure 3.2b).<sup>9</sup>

**Figure 3.2a. Histology of the conjunctiva showing the normal limbus. The cornea is to the left and conjunctiva and sclera to the right of the picture. Cells at the base of the conjunctiva appear more columnar but get more rounded as you move towards the surface where they appear flattened. (H&E x10)**



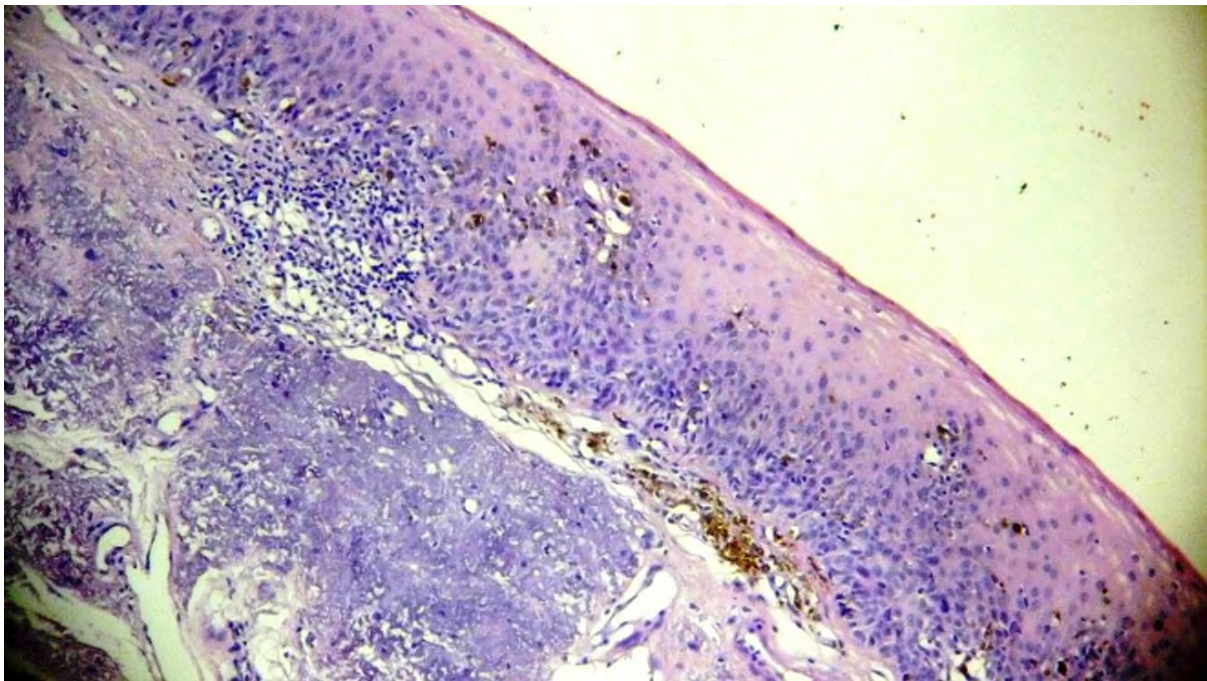
**Figure 3.2b. This picture shows conjunctival intraepithelial neoplasia on the left hand side where the conjunctiva appears thickened. Notice the loss of normal cell orientation in the lesion with some rounded cells seen in superficial areas. The lesion involves the full thickness of the epithelium but does not erode through the basement membrane into the underlying stroma. The space between the epithelium and the stroma is an artefact created during slide preparation. (H& E x20)**



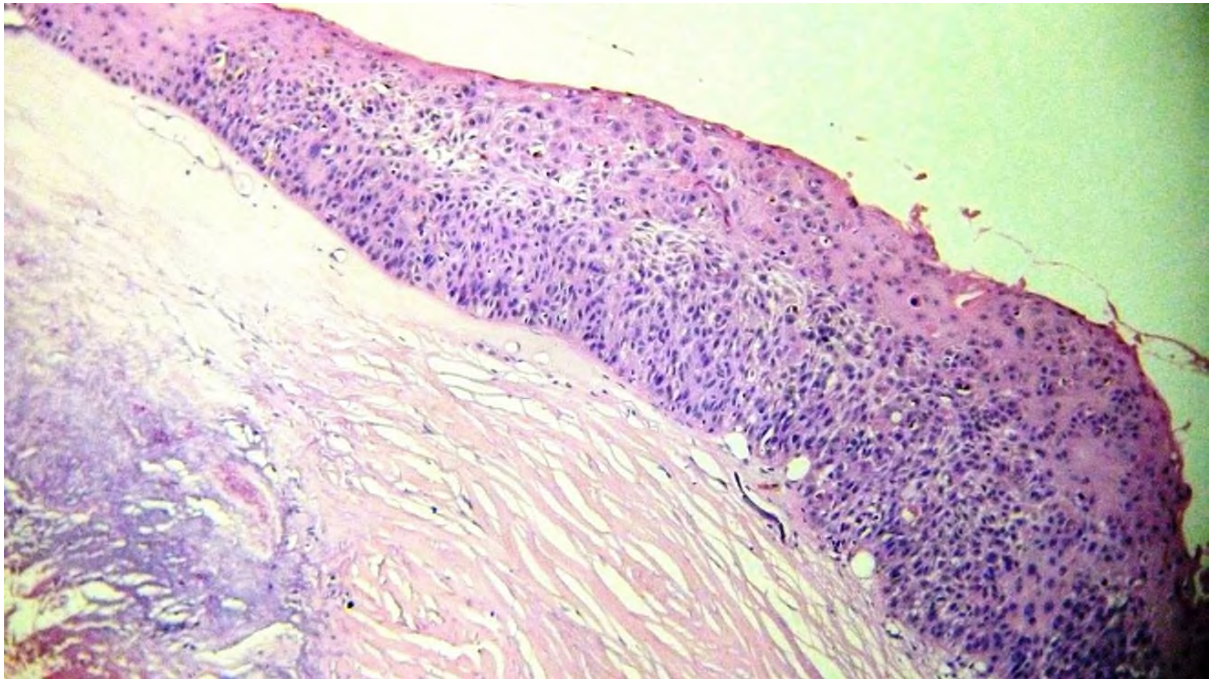
The histological features of OSSN depend on the stage of disease and include:

- Dysplasia – disorderly maturation of epithelium with loss of polarity, cytological atypia (increased nuclear/cytoplasmic ratio, hyperchromatic pleomorphic nuclei and mitotic figures) as the cells rise from the basement membrane towards the epithelial surface. The degree of dysplasia depends on the level and thickness of epithelial involvement. Thus the lesion may be classified as conjunctival intraepithelial neoplasia (CIN) I, II or III (Figure 3.2c-e). When this invades the underlying basal epithelium into the substantia propria this is called invasive squamous cell carcinoma (Figure 3.2f).
- Epithelial hyperkeratosis – thickening of the keratin layer, clinically this is seen as leukoplakia
- Dyskeratosis – keratin formation within the basal cell layer or deeper
- Penetration through the basement membrane by malignant cells seen in invasive squamous cell carcinoma (SCC)

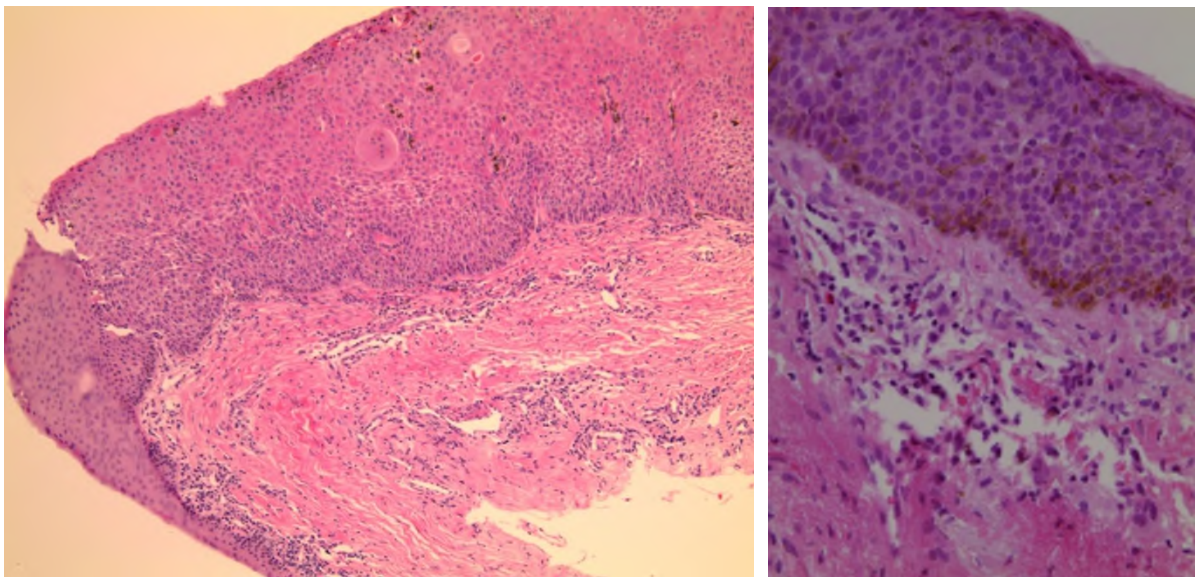
**Figure 3.2c. CIN 1 showing dysplastic cells in the deep 1/3 of the conjunctival epithelium. (H&E x10)**



**Figure 3.2d. CIN 2 showing dysplasia in the deep 2/3 closer to the epithelial surface. (H&E x10)**

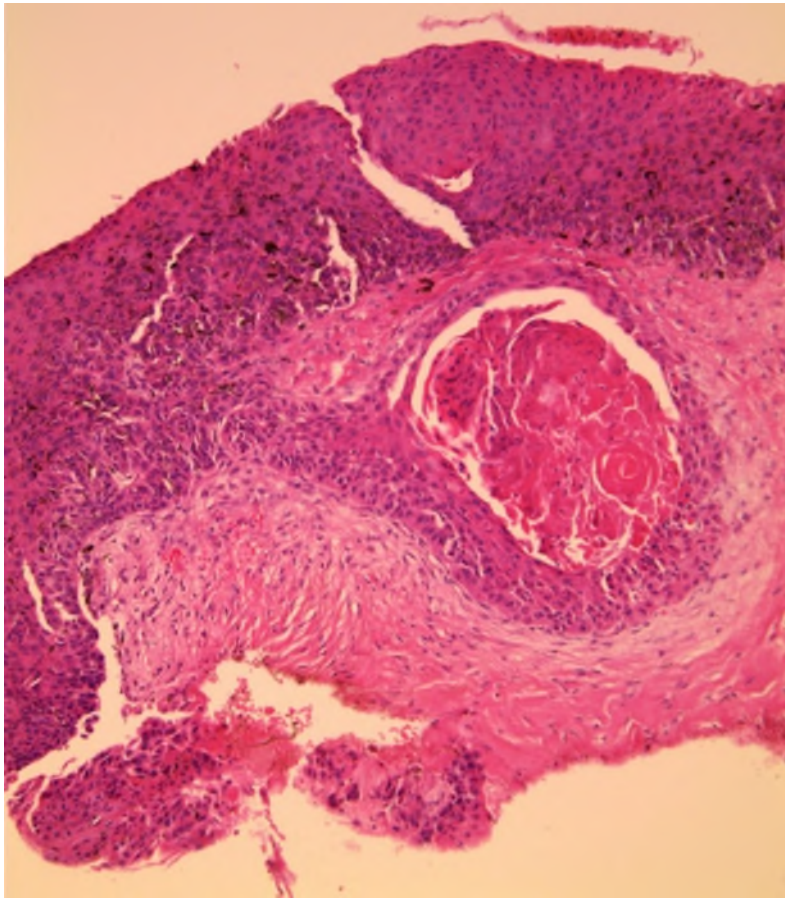


**Figure 3.2e. CIN 3 showing dysplasia involving the whole thickness of the conjunctiva. (H&E10)**





**Figure 3.2f. Invasive well differentiated squamous cell carcinoma. (H&E x10)**



Basti originally suggested a classification for OSSN into benign, pre-invasive and invasive stages (Table 3.3).<sup>15</sup> The American Joint Committee on Cancer (AJCC) has suggested both a clinical and pathological staging (Table 3.4).<sup>16</sup>

**Table 3.3 Classification of OSSN after Basti & Macsai.<sup>15</sup>**

<b>Benign</b>
Papilloma
Pseudoepitheliomatous hyperplasia
Benign hereditary intraepithelial dyskeratosis

---

<b>Pre-invasive</b>
Conjunctival/corneal intraepithelial neoplasia (CIN) grades I-III
CIN I (mild dysplasia) - confined to the lower third of the conjunctival epithelium
CIN II (moderate dysplasia) - extends into the middle third of the conjunctival epithelium
CIN III (severe dysplasia) – full thickness of the conjunctival epithelium also referred to as CIS (carcinoma-in-situ)

---

<b>Invasive</b>
Squamous cell carcinoma
Mucoepidermoid carcinoma

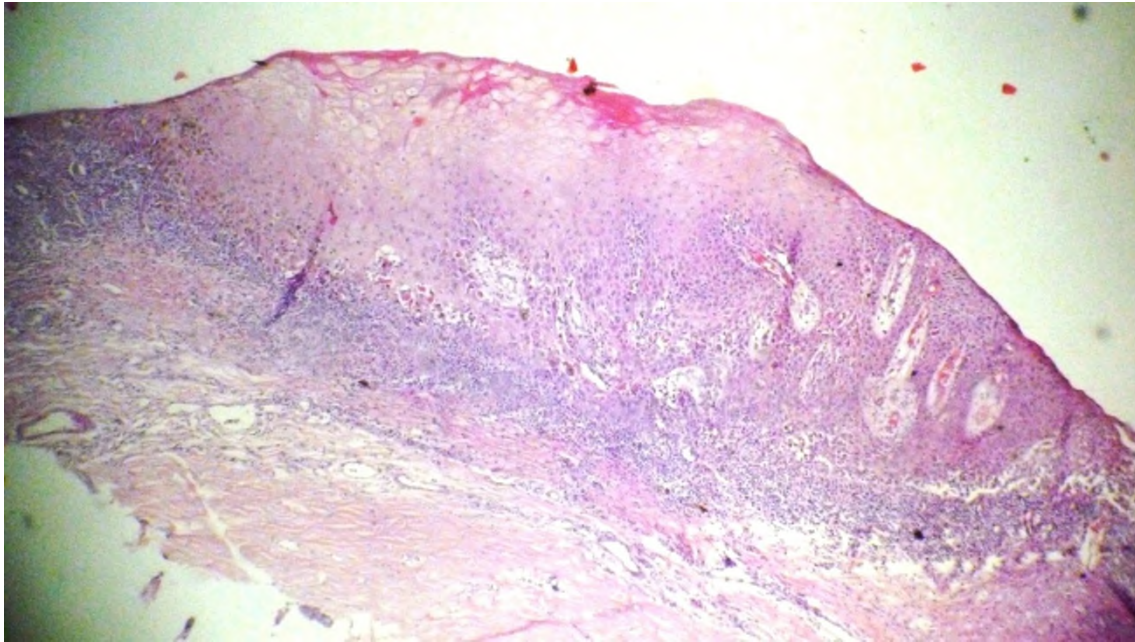
**Table 3.4 American Joint Committee on Cancer (AJCC) staging of carcinoma of the conjunctiva.<sup>16</sup>**

<b>Tumour (T) size</b>	
TX	primary tumour cannot be assessed
T0	no evidence of primary tumour
Ti	carcinoma in situ
T1	tumour ≤5mm in greatest dimension
T2	tumour >5mm in greatest dimension without invading adjacent structures <sup>a</sup>
T3	tumour invades adjacent structures (excluding the orbit)
T4	tumour invades the orbit ±further extension
<b>Regional lymph nodes (N)</b>	
NX	regional lymph nodes cannot be assessed
N0	no regional lymph node metastasis
N1	regional lymph node metastasis
<b>Distant metastasis (M)</b>	
MX	distant metastasis cannot be assessed
M0	no distant metastasis
M1	distant metastasis
<b>Histopathologic type</b>	
CIN including carcinoma in situ	
Squamous cell carcinoma	
Mucoepidermoid carcinoma	
Spindle cell carcinoma	
Sebaceous gland carcinoma including pagetoid (conjunctival) spread	
Basal cell carcinoma	
<b>Histologic grade (G)</b>	
GX	grade cannot be defined
G1	Well differentiated
G2	Moderately differentiated
G3	Poorly differentiated
G4	undifferentiated
<b>Biomarker (Ki-67 growth fraction)</b>	
	Is Ki-67 growth fraction <5%?
	Is Ki-67 growth fraction between 5% and <10%?
	Is Ki-67 growth fraction between 10% <20%?
	Is Ki-67 growth fraction between 20% and 50%?
	Is Ki-67 growth fraction >50%?

<sup>a</sup> Adjacent structures include the cornea (3,6,9 or 12 o'clock hours), intraocular compartments, forniceal conjunctiva, palpebral conjunctiva, tarsal conjunctiva, lacrimal punctum and canaliculi, plica, caruncle, posterior eyelid lamellar, anterior eyelid lamellar, and/or eyelid margin

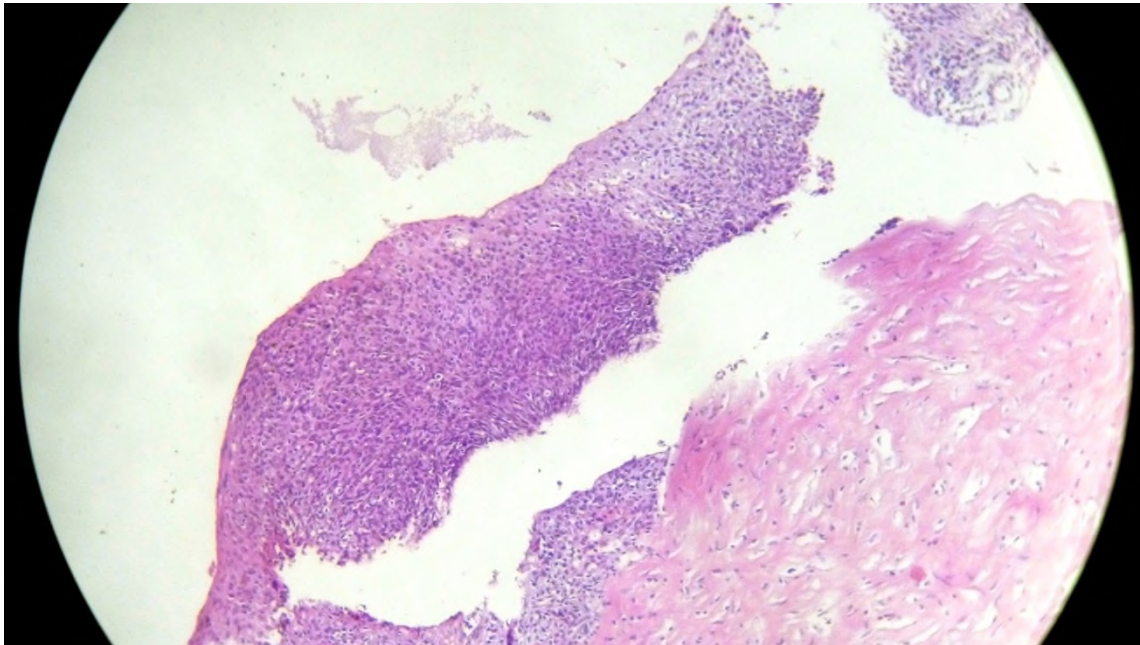
The term actinic keratosis is not used much nowadays. Some pathologists classify these lesions with CIN however the diagnosis of actinic keratosis is based on the presence of elastotic stromal degeneration, acanthosis, hyperkeratosis and parakeratosis in the presence of normal cellular polarity. By the accepted criteria for dysplasia, such lesions are classified as CIN only if there is loss of polarity. An example of the histology of actinic keratosis is shown in Figure 3.2g.

**Figure 3.2g. Actinic keratosis showing hyperkeratosis on the surface. (H&E x10)**



Histopathology is considered the gold-standard for cancer diagnosis but has a number of shortcomings. It requires surgical intervention. The service is also in short supply in high-incidence areas. In 2012 Kenya had 40 pathologists (1 pathologist to 1 Million population).<sup>17</sup> In most of Sub-Saharan Africa there were 1 million to 5 million people per pathologist. Histopathology is also subject to individual interpretation and discordance may arise at two levels (i) between pathologists and (ii) between pathologists and clinical observations.<sup>18</sup> In addition immediately after excision, the specimen often rolls up if put in formalin immediately. This is often counteracted by first placing the tissue on a sterile piece of flat paper or suture packing for a few minutes before putting it in formalin containers.<sup>9</sup> Labelling and orientation need to be indicated to the pathologist to aid interpretation. Fragmentation of small tumour specimens may also occur. During section preparation not all conjunctival layers may be represented on the slide mounts. Some of the tissue may shear off making assessment of the depth of involvement difficult (Figure 3.2b and 3.2h). Lastly, an adequate margin may not be included at the time of surgical excision. Further, the term OSSN is not used in the AJCC manual which raises questions of consistent comparisons and clinical interpretation.<sup>19</sup>

**Figure 3.2h. This lesion is graded as CIN 3 but the shearing off during section preparation may make it difficult to grade the depth of involvement. (H&E x5)**



Histopathology may be augmented with immunocytochemistry. A study in Japan found that proliferating cell nuclear antigen (PCNA) immunostaining, p53 immunostaining, and argyrophilic nucleolar organizer regions (AgNORs) staining in formalin-fixed and paraffin-embedded tissues could be used as markers of proliferative potency and cell differentiation. The PCNA-positive staining proportion was highest in SCC, followed by severe dysplasia and mild dysplasia. P53-positive staining was highest in severe dysplasia, followed by mild dysplasia, and was negative in SCC. AgNORs-count increased with advancing histological grade of malignancy.<sup>20</sup>

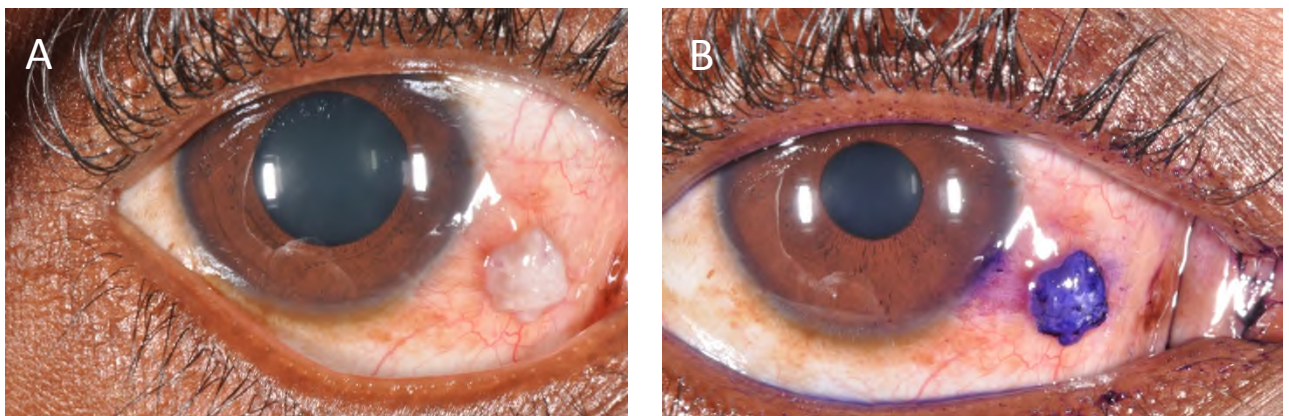
### **3. Vital staining**

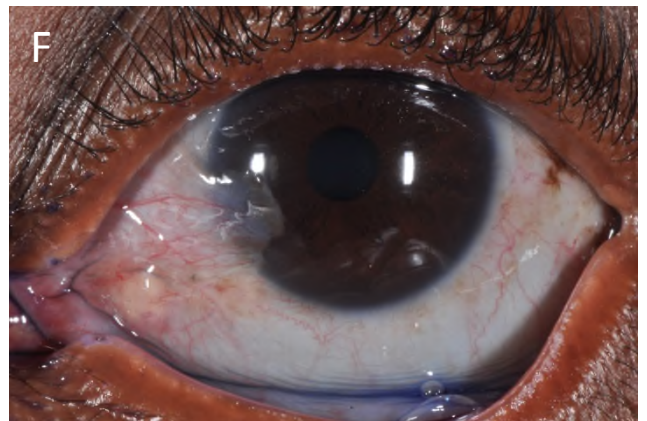
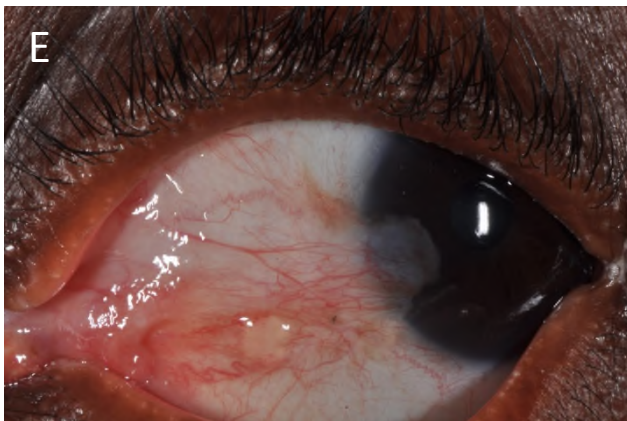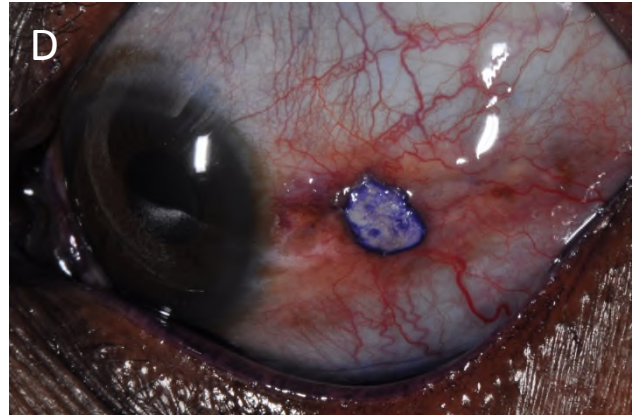
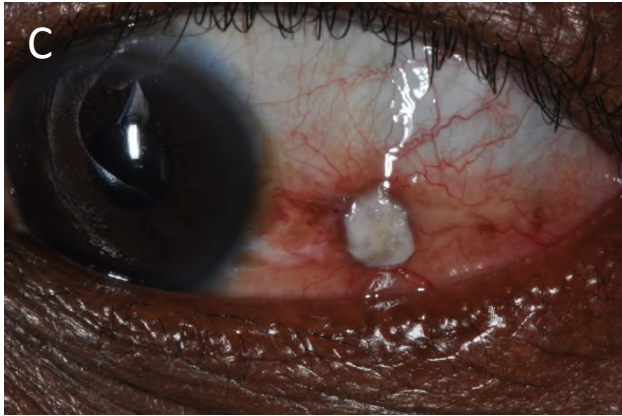
Vital stains are used to colour living tissues; various dyes are used extensively in ophthalmology including rose Bengal, fluorescein, methylene blue and toluidine blue.<sup>21,22</sup> Toluidine blue (ToB) is a vital dye that stains abnormal tissue dark royal blue by penetrating into cancerous tissue where it has a selective affinity for nucleic acids (Figure 3.3).<sup>23</sup> ToB has been used safely for many years to help support the clinical diagnosis of oral, oesophageal and cervical carcinoma and to demarcate tumours during surgical excision.<sup>24-28</sup> Animal safety studies found that intraocular injection (as opposed to topical use) of 1% and 2% ToB caused irreversible damage to all the corneal layers; 0.5% damaged the stromal keratocytes and corneal endothelium but 0.25% stained the lens capsule and did not damage the cornea layer or trabecular meshwork.<sup>29</sup> Wander et al conducted animal safety studies in rabbits and guinea pigs applying eye drops of 0.01%, 0.1%, 0.25%, 0.5%, and 1.0% toluidine blue applied to stain

corneal epithelial cells. The cells picked up the vital dye within 5 minutes. Wash out time was rapid and no toxic effects were observed.<sup>30</sup> There is one case report describing the use of topical / extraocular 0.05% ToB vital staining of OSSN.<sup>31</sup> The dye was reported to clearly demarcate the abnormal tissue, assisting the excision. The authors commented that they also found ToB did not stain other conjunctival lesions such as pterygium (no data presented) and it did not cause any toxicity to the ocular surface at a concentration of 0.05%.

A recent study in Brazil evaluated 1% topical Toluidine Blue eyedrops in diagnosis of OSSN and found that all OSSN lesions stained blue while 90% of pterygia did not and there were no adverse events reported.<sup>32</sup> The sensitivity was 100%, specificity 90%, predictive value positive 96.4% and predictive value negative 96%. However the performance of diagnostic tests vary with disease prevalence so in East Africa it may be different. Further, we do not know the effect of lesion pigmentation on staining - lesions in Africans tend to have more brown pigmentation. A similar study in South Africa evaluated 1% methylene blue vital staining for diagnosis of OSSN and found a sensitivity of 97% but a low specificity of 50%, a predictive value positive of 50% and predictive value negative of 96%.<sup>33</sup> However, the classification of OSSN in the two studies was different.

**Figure 3.3 Conjunctival lesions before and after vital staining with 0.05% Toluidine blue. The pictures in the left column are before staining and those on the right after staining. (A and B) Moderately differentiated squamous cell carcinoma, showing deep royal blue staining. (C and D) Actinic keratosis, showing mixed staining (margin and parts of the lesion). (E and F) Pterygium, showing no staining.**





#### 4. Cytology

Superficial cellular tissue from the ocular surface may be obtained by conjunctival impression cytology or exfoliative cytology. Impression cytology has been used for the diagnosis of ocular lesions for a number of decades.<sup>34,35</sup> There are minor variations in the techniques for impression cytology of the ocular surface.<sup>36</sup> Cellulose acetate filter paper strips or special biopore membranes are used to obtain superficial cells.<sup>37</sup> The technique involves gently pressing the paper or membrane on the surface of the eyeball and collecting the cells that stick to it. The paper is fixed in acetic acid, formaldehyde, and ethyl alcohol in a 1:1:20 volume ratio, rehydrated with 70% ethyl alcohol, then taken through cycles of washing in periodic acid Schiff reagent, sodium metarsulfite, Gill's haematoxylin, and Scott's tap water substitute for 2 minutes each, before rinsing in tap water and staining the cell surface of the filter paper.<sup>36</sup> Xylene is used in the final step to make the filter paper transparent to allow examination of the morphology of these cells under a microscope. For exfoliative cytology a brush is used to obtain the tissue.<sup>38</sup> The most commonly used staining methods are Papanicolaou<sup>39</sup>, periodic acid Schiff (PAS) with haematoxylin and eosin (H&E)<sup>40</sup> or Giemsa<sup>41</sup>.

An Australian study identified a number of cytomorphological features associated with OSSN.<sup>42</sup> About 50% of CIN cases had keratinized dysplastic cells often accompanied by hyperkeratosis, large syncytial-like groups in about 35% and individual non-keratinized dysplastic cells in 10%, while 70% of invasive SCC had significant keratinization. In alcohol-fixed Papanicolaou stained smears, squamous dysplasia or malignancy was indicated by nuclear hyperchromasia, high nuclear/cytoplasmic ratio and pleomorphism.<sup>43</sup> Conjunctival impression cytology has been reported to have a sensitivity of 85% and specificity of 90% in Thailand and USA.<sup>44 45</sup> Recently a scoring system was proposed that identifies cytomorphological features, which may help to reliably differentiate invasive conjunctival squamous cell carcinoma from pre-invasive lesions.<sup>46</sup> In that study the following seven cytological parameters were found to be predictive of malignancy:

- i) nuclear size enlargement >x3
- ii) hyperchromasia (dark staining nuclei which is usually due to increased DNA content)
- iii) prominent nucleoli
- iv) syncytial-like groupings
- v) increased nuclear-to-cytoplasm (NC) ratio - it is considered a slightly increased NC ratio when the cell has an NC ratio of 2:1 or a marked increase in NC ratio when the cell has an NC ratio up to 2:1
- vi) eosinophilic cytoplasmic stain
- vii) absence of distinct cytoplasmic borders

Each feature was given a score based on a logistic regression model. A score of 4.25 was the best cut-off for malignancy.

The following 4 parameters were not predictive:

- i) cell disposition - single or individual cells, cells within sheets or cells inside keratin plaques
- ii) cell size - very small or very large
- iii) the presence of a regular or irregular nuclear contour
- iv) cytoplasmic area - significant reduction in mean cytoplasmic area when the nucleus fills at least two-thirds of the cell or increased cytoplasmic area when the nucleus occupies less than half the total area of the cytoplasm

Cytology has also been applied in diagnosis of other diseases of the ocular surface such as limbal stem-cell deficiency, viral keratoconjunctivitis, allergic/inflammatory keratoconjunctivitis, vitamin A deficiency and melanocytic lesions.<sup>36,37</sup>

Impression cytology has a number of shortcomings. It is constrained by the need for specialised equipment and personnel and this may not be easily available in peripheral care

centres. Inter- and intra-observer variation may occur. It is also likely to miss CIN as the abnormal cells are deeper down. In one Australia study it was difficult to distinguish between carcinoma-in-situ and minimally invasive disease.<sup>47</sup>

## **5. Confocal microscopy**

Unlike conventional light microscopes whose image is degraded by reflections and light scattering by objects outside of the focal plane, in *in vivo* confocal microscopy, light from a point source is focused on a tissue and the light reflected from this focal point is collected by a parallel objective lens and focused onto a duplicate pinhole aperture. Light that passes this second aperture is collected by a detector. Both the illuminating point source and the observation aperture of the detector are conjugate with the same point in the tissue, and are said to be confocal.<sup>48</sup> Initially it was used for corneal examination but later extended to conjunctival studies such as trachoma.<sup>49</sup> Confocal microscopy is non-invasive and may allow serial visualization of the same living tissue down to the cellular level (hence the term *in vivo* confocal microscopy – IVCM) over time unlike histology.

Several studies have evaluated the use of IVCM for the diagnosis of OSSN with differing results. A study of 10 cases from Italy found that the main pathological features include: cytonuclear atypias, epithelial folds into an inflammatory and vascularised conjunctival stroma, fine vessels perpendicular to the surface, clear limit with normal epithelium, papillomatous organization, and abnormal keratinisation.<sup>50</sup> A study of 5 cases in China found cellular anisocytosis (variation in cell size) and enlarged nuclei with high nuclear to cytoplasmic ratio in 3 cases of CIN and nests partially formed by isolated keratinized, binucleated, and actively mitotic dysmorphic epithelial cells in the other 2 cases diagnosed as carcinoma in situ (CIS).<sup>51</sup> However, more recently we looked at a larger series of 52 cases of conjunctival lesions in Tanzania and found that IVCM features such as hyper-reflective cells, anisocytosis and starry night appearance of basal cells could not reliably distinguish OSSN from benign conjunctival pathology because of an overlap in the features (see appendix 1).<sup>10</sup>

## **6. Anterior segment Optical Coherence Tomography (OCT)**

OCT is a computer assisted optical instrument that produces cross-sectional images (tomograms) similar to B-mode ultrasound only that it uses light instead of sound. A low coherence infra-red light (820nm) is directed at a target tissue and the amount and position of backscattered light displayed according to the optical properties of the structure in question. It has the advantages of fast image acquisition speed and non-contact and is non-invasive with some referring to it as a non-excisional 'optical biopsy'.<sup>52</sup> It has been suggested that ultra-high resolution anterior segment optical coherence tomography (UHR OCT) may be used in



diagnosis and follow up of OSSN however the studies in this area are small. One study showed that UHR OCT images of the lesions showed a thickened hyper-reflective epithelium and abrupt transition from normal to hyper-reflective epithelium in all 7 cases.<sup>53</sup> In a study to distinguish OSSN from pterygium, there was a statistically significant difference in the epithelial thickness with an average 346µm (standard deviation [SD], 167) in 17 OSSN patients and 101 µm (SD, 22) in 17 pterygium patients ( $p < 0.001$ ). By receiver operating characteristic curve, the sensitivity and specificity of UHR OCT for differentiating between OSSN and pterygia was found to be 94% and 100%, respectively, using a cut-off value of 142 µm.<sup>54</sup>

One of the major shortcomings of ultrasound and OCT is the cost of equipment and the effect of rapidly changing technology that may render it obsolete in a few years. In practice the reliability of this technique is yet to be proven.

## **Conclusions**

OSSN has serious consequences associated with recurrence and local metastasis that may lead to death. Early diagnosis may reduce this. There seems to be a mismatch between availability of diagnostic facilities and where OSSN is most frequently found. Highly affected areas have short supply of diagnostic capability.

Some clinicians make management decisions without a tissue diagnosis but clinical signs are not very reliable for diagnosis due to the overlap between the features of OSSN and other conjunctival lesions. There is a risk of misclassification and inappropriate treatment with this practice. Patients with benign disease would inappropriately be subjected to chemotherapy and live with a diagnosis of 'cancer' and fear of recurrence.

Histology is the gold standard but is subjective and prone to inter-observer variability. Tissue samples are small and may roll up if put in formalin immediately after excision making orientation and interpretation of slides difficult. During tissue section preparation the surface epithelium may be sheared off making classification by depth of involvement difficult.

Vital staining with toluidine blue is promising as a non-invasive diagnostic tool. Formal evaluation in areas of differing prevalence is needed as the performance of diagnostic tests is affected by disease prevalence. Toluidine blue vital staining may be useful for marking the extent of tumour to aid surgical excision. Brown pigmentation of lesions however obscures the dye. In addition, this will not replace a tissue diagnosis.

Cytology is a less invasive tissue diagnostic method. Scoring systems using cytology are reliable. However cytology may miss CIN as it would not pick the deeper epithelial cells. There are also relatively few trained cytologists.

In-vivo confocal microscopy, ultrasound and anterior segment optical coherence tomography (OCT) are modern technologies that promise to circumvent surgical excision and facilitate primary topical treatment. However there is overlap in the appearance of OSSN and other conjunctival lesions so IVCM cannot reliably distinguish between the two. The technology is very expensive and prone to short lifespans due to rapid new developments that may render existing equipment obsolete. They are currently not a suitable option in Africa where OSSN mainly occurs.

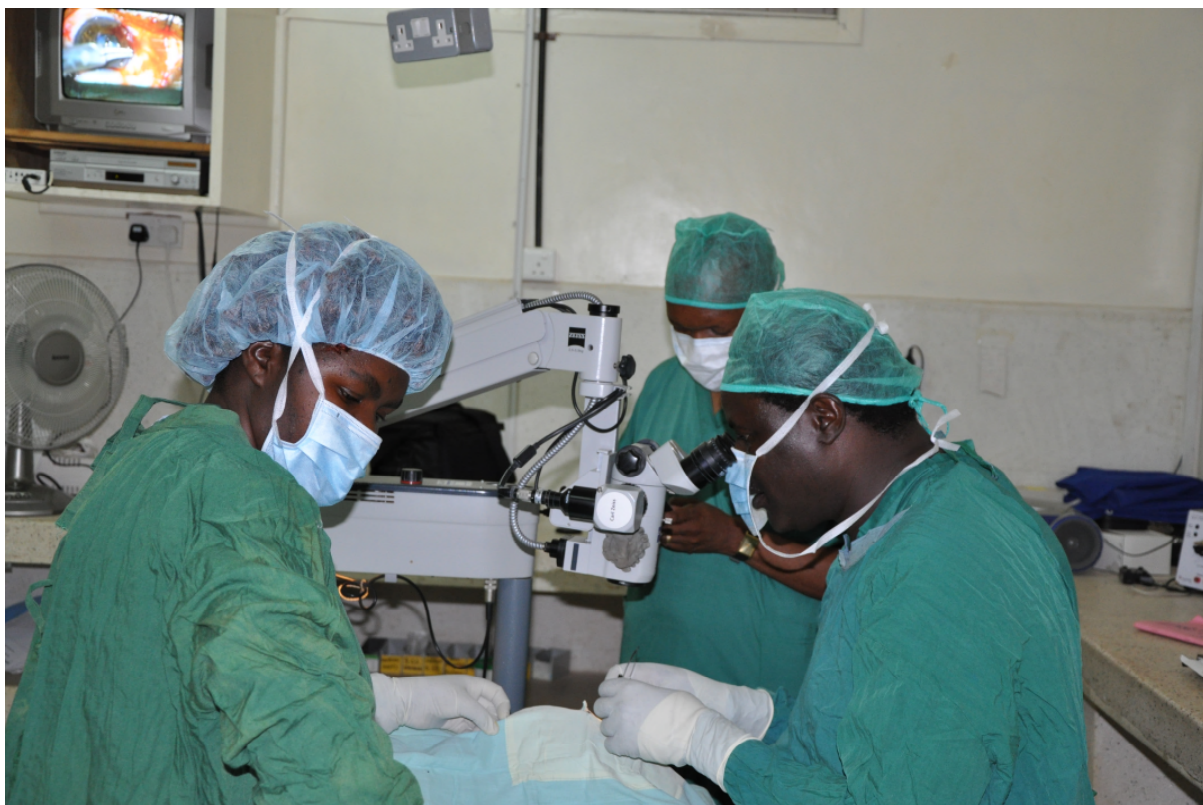## References

1. Stone DU, Butt AL, Chodosh J. Ocular surface squamous neoplasia: a standard of care survey. *Cornea* 2005; **24**(3): 297-300.
2. Lee GA, Hirst LW. Retrospective study of ocular surface squamous neoplasia. *Australian and New Zealand journal of ophthalmology* 1997; **25**(4): 269-76.
3. Nelson KD, McSoley JJ. Clinical findings and management of conjunctival intraepithelial neoplasia. *Optometry (St Louis, Mo)* 2011; **82**(1): 15-21.
4. Tunc M, Char DH, Crawford B, Miller T. Intraepithelial and invasive squamous cell carcinoma of the conjunctiva: analysis of 60 cases. *British Journal of Ophthalmology* 1999; **83**(1): 98-103.
5. Waddell KM, Downing RG, Lucas SB, Newton R. Corneo-conjunctival carcinoma in Uganda. *Eye (Lond)* 2006; **20**(8): 893-9.
6. Kamal S, Kaliki S, Mishra DK, Batra J, Naik MN. Ocular Surface Squamous Neoplasia in 200 Patients. *Ophthalmology*.
7. Usui Y, Waring GO, See RF, Rao NA, Marrone AC. Bilateral ocular surface squamous neoplasia: a clinicopathological case report. *The British journal of ophthalmology* 2004; **88**(4): 595-6.
8. Kim BH, Kim MK, Wee WR, Oh JY. Clinical and pathological characteristics of ocular surface squamous neoplasia in an Asian population. *Graefe's archive for clinical and experimental ophthalmology = Albrecht von Graefes Archiv fur klinische und experimentelle Ophthalmologie* 2013; **251**(11): 2569-73.
9. Mittal R, Rath S, Vemuganti GK. Ocular surface squamous neoplasia - Review of etio-pathogenesis and an update on clinico-pathological diagnosis. *Saudi journal of ophthalmology : official journal of the Saudi Ophthalmological Society* 2013; **27**(3): 177-86.
10. Nguena MB, van den Tweel JG, Makupa W, et al. Diagnosing ocular surface squamous neoplasia in East Africa: case-control study of clinical and in vivo confocal microscopy assessment. *Ophthalmology* 2014; **121**(2): 484-91.
11. Kao AA, Galor A, Karp CL, Abdelaziz A, Feuer WJ, Dubovy SR. Clinicopathologic correlation of ocular surface squamous neoplasms at bascom palmer eye institute: 2001 to 2010. *Ophthalmology* 2012; **119**(9): 1773-6.
12. Makupa, II, Swai B, Makupa WU, White VA, Lewallen S. Clinical factors associated with malignancy and HIV status in patients with ocular surface squamous neoplasia at Kilimanjaro Christian Medical Centre, Tanzania. *The British journal of ophthalmology* 2012; **96**(4): 482-4.
13. Clear AS, Chirambo MC, Hutt MS. Solar keratosis, pterygium, and squamous cell carcinoma of the conjunctiva in Malawi. *The British journal of ophthalmology* 1979; **63**(2): 102-9.

14. Cervantes G, Rodriguez AA, Jr., Leal AG. Squamous cell carcinoma of the conjunctiva: clinicopathological features in 287 cases. *Canadian journal of ophthalmology Journal canadien d'ophtalmologie* 2002; **37**(1): 14-9; discussion 9-20.
15. Basti S, Macsai MS. Ocular surface squamous neoplasia: a review. *Cornea* 2003; **22**(7): 687-704.
16. American Joint Committee on Cancer. Carcinoma of the conjunctiva. In: Edge SB, Byrd DR, Compton CC, Fritz AG, Greene FL, Trotti A, eds. *Cancer staging handbook*. 7 ed. New York: Springer; 2010: 600-2.
17. Adesina A, Chumba D, Nelson AM, et al. Improvement of pathology in sub-Saharan Africa. *The lancet oncology* 2013; **14**(4): e152-7.
18. Margo CE, Harman LE, Mulla ZD. The reliability of clinical methods in ophthalmology. *Survey of ophthalmology* 2002; **47**(4): 375-86.
19. Margo CE, White AA. Ocular surface squamous neoplasia: terminology that is conceptually friendly but clinically perilous. *Eye (Lond)* 2014; **28**(5): 507-9.
20. Aoki S, Kubo E, Nakamura S, et al. Possible prognostic markers in conjunctival dysplasia and squamous cell carcinoma. *Japanese journal of ophthalmology* 1998; **42**(4): 256-61.
21. Rodrigues EB, Costa EF, Penha FM, et al. The use of vital dyes in ocular surgery. *Survey of ophthalmology* 2009; **54**(5): 576-617.
22. Norn MS. Vital staining of cornea and conjunctiva. *Acta ophthalmologica* 1962; **40**: 389-401.
23. Herlin P, Marnay J, Jacob JH, Ollivier JM, Mandard AM. A study of the mechanism of the toluidine blue dye test. *Endoscopy* 1983; **15**(1): 4-7.
24. Lingen MW, Kalmar JR, Karrison T, Speight PM. Critical evaluation of diagnostic aids for the detection of oral cancer. *Oral oncology* 2008; **44**(1): 10-22.
25. Martin IC, Kerawala CJ, Reed M. The application of toluidine blue as a diagnostic adjunct in the detection of epithelial dysplasia. *Oral surgery, oral medicine, oral pathology, oral radiology, and endodontics* 1998; **85**(4): 444-6.
26. Onofre MA, Sposto MR, Navarro CM. Reliability of toluidine blue application in the detection of oral epithelial dysplasia and in situ and invasive squamous cell carcinomas. *Oral surgery, oral medicine, oral pathology, oral radiology, and endodontics* 2001; **91**(5): 535-40.
27. Allegra E, Lombardo N, Puzzo L, Garozzo A. The usefulness of toluidine staining as a diagnostic tool for precancerous and cancerous oropharyngeal and oral cavity lesions. *Acta otorhinolaryngologica Italica : organo ufficiale della Societa italiana di otorinolaringologia e chirurgia cervico-facciale* 2009; **29**(4): 187-90.
28. Nishimura S, Ishiko O, Honda K, Hyun Y, Ogita S. New cervicoscopy with toluidine blue staining for superficial cervical invasion by endometrial carcinoma. *Gynecologic and obstetric investigation* 2000; **50**(2): 133-5.
29. Gamal Eldin SA, el Mehelmy EM, el Shazli EM, Mostafa YM. Experimental staining of the anterior lens capsule in albino rabbits. *Journal of cataract and refractive surgery* 1999; **25**(9): 1289-94.
30. Wander AH, Neumeister RD, Tschismadia I, Choromokos EA, Masukawa T. In vivo corneal and conjunctival epithelial nuclear stain. *Cornea* 1985; **4**(1): 8-13.
31. Kaji Y, Hiraoka T, Oshika T. Vital staining of squamous cell carcinoma of the conjunctiva using toluidine blue. *Acta ophthalmologica Scandinavica* 2006; **84**(6): 825-6.
32. Romero IL, Barros JD, Martins MC, Ballalai PL. The Use of 1% Toluidine Blue Eye Drops in the Diagnosis of Ocular Surface Squamous Neoplasia. *Cornea* 2012.
33. Steffen J, Rice J, Lecuona K, Carrara H. Identification of ocular surface squamous neoplasia by in vivo staining with methylene blue. *The British journal of ophthalmology* 2014; **98**(1): 13-5.
34. Dykstra PC, Dykstra BA. The cytologic diagnosis of carcinoma and related lesions of the ocular conjunctiva and cornea. *Transactions - American Academy of Ophthalmology and Otolaryngology American Academy of Ophthalmology and Otolaryngology* 1969; **73**(5): 979-95.
35. Naib ZM. Cytology of ocular lesions. *Acta cytologica* 1972; **16**(2): 178-85.
36. Singh R, Joseph A, Umapathy T, Tint NL, Dua HS. Impression cytology of the ocular surface. *The British journal of ophthalmology* 2005; **89**(12): 1655-9.

37. McKelvie P. Ocular surface impression cytology. *Advances in anatomic pathology* 2003; **10**(6): 328-37.
38. Ersoz C, Yagmur M, Ersoz TR, Yalaz M. Preoperative brush and impression cytology in ocular surface squamous neoplasms. *Acta cytologica* 2003; **47**(1): 13-5.
39. Gelender H, Forster RK. Papanicolaou cytology in the diagnosis and management of external ocular tumors. *Archives of ophthalmology* 1980; **98**(5): 909-12.
40. Egbert PR, Lauber S, Maurice DM. A simple conjunctival biopsy. *American journal of ophthalmology* 1977; **84**(6): 798-801.
41. Doughty MJ. Reliability of nucleus-to-cell and nucleus-to-cytoplasm calculations for conjunctival impression cytology specimens. *Current eye research* 2012; **37**(7): 583-91.
42. Nolan GR, Hirst LW, Bancroft BJ. The cytomorphology of ocular surface squamous neoplasia by using impression cytology. *Cancer* 2001; **93**(1): 60-7.
43. Doughty MJ. Objective assessment of conjunctival squamous metaplasia by measures of cell and nucleus dimensions. *Diagnostic cytopathology* 2011; **39**(6): 409-23.
44. Tananuvat N, Lertprasertsuk N, Mahanupap P, Noppanakeepong P. Role of impression cytology in diagnosis of ocular surface neoplasia. *Cornea* 2008; **27**(3): 269-74.
45. Semenova EA, Milman T, Finger PT, et al. The diagnostic value of exfoliative cytology vs histopathology for ocular surface squamous neoplasia. *American journal of ophthalmology* 2009; **148**(5): 772-8 e1.
46. Barros JN, Lowen MS, Ballalai PL, Mascaro VL, Gomes JA, Martins MC. Predictive index to differentiate invasive squamous cell carcinoma from preinvasive ocular surface lesions by impression cytology. *The British journal of ophthalmology* 2009; **93**(2): 209-14.
47. McKelvie PA. Squamous cell carcinoma of the conjunctiva: a series of 26 cases. *British Journal of Ophthalmology* 2002; **86**(2): 168-73.
48. Erie JC, McLaren JW, Patel SV. Confocal microscopy in ophthalmology. *American journal of ophthalmology* 2009; **148**(5): 639-46.
49. Hu VH, Weiss HA, Massae P, et al. In vivo confocal microscopy in scarring trachoma. *Ophthalmology* 2011; **118**(11): 2138-46.
50. Parrozzani R, Lazzarini D, Dario A, Midenia E. In vivo confocal microscopy of ocular surface squamous neoplasia. *Eye (Lond)* 2011; **25**(4): 455-60.
51. Xu Y, Zhou Z, Xu Y, et al. The clinical value of in vivo confocal microscopy for diagnosis of ocular surface squamous neoplasia. *Eye (Lond)* 2012; **26**(6): 781-7.
52. Chen J, Lee L. Clinical applications and new developments of optical coherence tomography: an evidence-based review. *Clinical & experimental optometry : journal of the Australian Optometrical Association* 2007; **90**(5): 317-35.
53. Shousha MA, Karp CL, Perez VL, et al. Diagnosis and management of conjunctival and corneal intraepithelial neoplasia using ultra high-resolution optical coherence tomography. *Ophthalmology* 2011; **118**(8): 1531-7.
54. Kieval JZ, Karp CL, Abou Shousha M, et al. Ultra-high resolution optical coherence tomography for differentiation of ocular surface squamous neoplasia and pterygia. *Ophthalmology* 2012; **119**(3): 481-6.

## **Chapter 4. Interventions for squamous cell carcinoma of the conjunctiva in HIV-infected individuals (Cochrane Review)**





**Registry**

T: +44(0)20 7299 4646  
F: +44(0)20 7299 4656  
E: registry@lshtm.ac.uk

## RESEARCH PAPER COVER SHEET

**PLEASE NOTE THAT A COVER SHEET MUST BE COMPLETED FOR EACH RESEARCH PAPER INCLUDED IN A THESIS.**

### SECTION A – Student Details

<b>Student</b>	Stephen Gichuhi
<b>Principal Supervisor</b>	Matthew J. Burton
<b>Thesis Title</b>	Epidemiology and management of ocular surface squamous neoplasia in Kenya

**If the Research Paper has previously been published please complete Section B, if not please move to Section C**

### SECTION B – Paper already published

Where was the work published?	The Cochrane Library		
When was the work published?	2013		
If the work was published prior to registration for your research degree, give a brief rationale for its inclusion			
Have you retained the copyright for the work?*	No	Was the work subject to academic peer review?	Yes

*\*If yes, please attach evidence of retention. If no, or if the work is being included in its published format, please attach evidence of permission from the copyright holder (publisher or other author) to include this work.*

### SECTION C – Prepared for publication, but not yet published

Where is the work intended to be published?	
Please list the paper's authors in the intended authorship order:	
Stage of publication	Choose an item.

### SECTION D – Multi-authored work

For multi-authored work, give full details of your role in the research included in the paper and in the preparation of the paper. (Attach a further sheet if necessary)

I reviewed the search output from the Trial Search Coordinator, extracted the data from the papers, conducted the analysis with guidance from a statistician from the South African Cochrane Center, drafted and James Irlam and submitted the manuscript with consideration of comments from James Irlam. For the supplementary review of case series, I did the searches, data extraction and analysis with input from Matthew Burton.

**Student Signature:** Stephen Gichuhi

**Date:** 4th February 2016

**Supervisor Signature:** M. J. Burton

**Date:** 4th February 2016

JOHN WILEY AND SONS LICENSE  
TERMS AND CONDITIONS

Feb 27, 2016

This Agreement between Stephen Gichuhi ("You") and John Wiley and Sons ("John Wiley and Sons") consists of your license details and the terms and conditions provided by John Wiley and Sons and Copyright Clearance Center.

License Number	3817130105825
License date	Feb 27, 2016
Licensed Content Publisher	John Wiley and Sons
Licensed Content Publication	Cochrane Database of Systematic Reviews
Licensed Content Title	Interventions for squamous cell carcinoma of the conjunctiva in HIV-infected individuals
Licensed Content Author	Stephen Gichuhi, James H Irlam
Licensed Content Date	Feb 28, 2013
Pages	22
Type of use	Dissertation/Thesis
Requestor type	Author of this Wiley article
Format	Print and electronic
Portion	Full article
Will you be translating?	No
Title of your thesis / dissertation	Epidemiology and management of ocular surface squamous neoplasia in Kenya
Expected completion date	May 2016
Expected size (number of pages)	22
Requestor Location	Stephen Gichuhi P.O Box 347  Nairobi, Kenya 00202 Attn: Stephen Gichuhi
Billing Type	Invoice
Billing Address	Stephen Gichuhi P.O Box 347  Nairobi, Kenya 00202 Attn: Stephen Gichuhi
Total	0.00 USD

Terms and Conditions

**TERMS AND CONDITIONS**

This copyrighted material is owned by or exclusively licensed to John Wiley & Sons, Inc. or one of its group companies (each a "Wiley Company") or handled on behalf of a society with which a Wiley Company has exclusive publishing rights in relation to a particular work (collectively "WILEY"). By clicking "accept" in connection with completing this licensing

transaction, you agree that the following terms and conditions apply to this transaction (along with the billing and payment terms and conditions established by the Copyright Clearance Center Inc., ("CCC's Billing and Payment terms and conditions"), at the time that you opened your RightsLink account (these are available at any time at <http://myaccount.copyright.com>).

## Terms and Conditions

- The materials you have requested permission to reproduce or reuse (the "Wiley Materials") are protected by copyright.
- You are hereby granted a personal, non-exclusive, non-sub licensable (on a stand-alone basis), non-transferable, worldwide, limited license to reproduce the Wiley Materials for the purpose specified in the licensing process. This license, **and any CONTENT (PDF or image file) purchased as part of your order**, is for a one-time use only and limited to any maximum distribution number specified in the license. The first instance of republication or reuse granted by this license must be completed within two years of the date of the grant of this license (although copies prepared before the end date may be distributed thereafter). The Wiley Materials shall not be used in any other manner or for any other purpose, beyond what is granted in the license. Permission is granted subject to an appropriate acknowledgement given to the author, title of the material/book/journal and the publisher. You shall also duplicate the copyright notice that appears in the Wiley publication in your use of the Wiley Material. Permission is also granted on the understanding that nowhere in the text is a previously published source acknowledged for all or part of this Wiley Material. Any third party content is expressly excluded from this permission.
- With respect to the Wiley Materials, all rights are reserved. Except as expressly granted by the terms of the license, no part of the Wiley Materials may be copied, modified, adapted (except for minor reformatting required by the new Publication), translated, reproduced, transferred or distributed, in any form or by any means, and no derivative works may be made based on the Wiley Materials without the prior permission of the respective copyright owner. **For STM Signatory Publishers clearing permission under the terms of the [STM Permissions Guidelines](#) only, the terms of the license are extended to include subsequent editions and for editions in other languages, provided such editions are for the work as a whole in situ and does not involve the separate exploitation of the permitted figures or extracts**, You may not alter, remove or suppress in any manner any copyright, trademark or other notices displayed by the Wiley Materials. You may not license, rent, sell, loan, lease, pledge, offer as security, transfer or assign the Wiley Materials on a stand-alone basis, or any of the rights granted to you hereunder to any other person.
- The Wiley Materials and all of the intellectual property rights therein shall at all times remain the exclusive property of John Wiley & Sons Inc, the Wiley Companies, or their respective licensors, and your interest therein is only that of having possession of and the right to reproduce the Wiley Materials pursuant to Section 2 herein during the continuance of this Agreement. You agree that you own no right, title or interest in or to the Wiley Materials or any of the intellectual property rights therein. You shall have no rights hereunder other than the license as provided for above in Section 2. No right, license or interest to any trademark, trade name, service mark or other branding ("Marks") of WILEY or its licensors is granted hereunder, and you agree that you



shall not assert any such right, license or interest with respect thereto

- NEITHER WILEY NOR ITS LICENSORS MAKES ANY WARRANTY OR REPRESENTATION OF ANY KIND TO YOU OR ANY THIRD PARTY, EXPRESS, IMPLIED OR STATUTORY, WITH RESPECT TO THE MATERIALS OR THE ACCURACY OF ANY INFORMATION CONTAINED IN THE MATERIALS, INCLUDING, WITHOUT LIMITATION, ANY IMPLIED WARRANTY OF MERCHANTABILITY, ACCURACY, SATISFACTORY QUALITY, FITNESS FOR A PARTICULAR PURPOSE, USABILITY, INTEGRATION OR NON-INFRINGEMENT AND ALL SUCH WARRANTIES ARE HEREBY EXCLUDED BY WILEY AND ITS LICENSORS AND WAIVED BY YOU.
- WILEY shall have the right to terminate this Agreement immediately upon breach of this Agreement by you.
- You shall indemnify, defend and hold harmless WILEY, its Licensors and their respective directors, officers, agents and employees, from and against any actual or threatened claims, demands, causes of action or proceedings arising from any breach of this Agreement by you.
- IN NO EVENT SHALL WILEY OR ITS LICENSORS BE LIABLE TO YOU OR ANY OTHER PARTY OR ANY OTHER PERSON OR ENTITY FOR ANY SPECIAL, CONSEQUENTIAL, INCIDENTAL, INDIRECT, EXEMPLARY OR PUNITIVE DAMAGES, HOWEVER CAUSED, ARISING OUT OF OR IN CONNECTION WITH THE DOWNLOADING, PROVISIONING, VIEWING OR USE OF THE MATERIALS REGARDLESS OF THE FORM OF ACTION, WHETHER FOR BREACH OF CONTRACT, BREACH OF WARRANTY, TORT, NEGLIGENCE, INFRINGEMENT OR OTHERWISE (INCLUDING, WITHOUT LIMITATION, DAMAGES BASED ON LOSS OF PROFITS, DATA, FILES, USE, BUSINESS OPPORTUNITY OR CLAIMS OF THIRD PARTIES), AND WHETHER OR NOT THE PARTY HAS BEEN ADVISED OF THE POSSIBILITY OF SUCH DAMAGES. THIS LIMITATION SHALL APPLY NOTWITHSTANDING ANY FAILURE OF ESSENTIAL PURPOSE OF ANY LIMITED REMEDY PROVIDED HEREIN.
- Should any provision of this Agreement be held by a court of competent jurisdiction to be illegal, invalid, or unenforceable, that provision shall be deemed amended to achieve as nearly as possible the same economic effect as the original provision, and the legality, validity and enforceability of the remaining provisions of this Agreement shall not be affected or impaired thereby.
- The failure of either party to enforce any term or condition of this Agreement shall not constitute a waiver of either party's right to enforce each and every term and condition of this Agreement. No breach under this agreement shall be deemed waived or excused by either party unless such waiver or consent is in writing signed by the party granting such waiver or consent. The waiver by or consent of a party to a breach of any provision of this Agreement shall not operate or be construed as a waiver of or consent to any other or subsequent breach by such other party.

- This Agreement may not be assigned (including by operation of law or otherwise) by you without WILEY's prior written consent.
- Any fee required for this permission shall be non-refundable after thirty (30) days from receipt by the CCC.
- These terms and conditions together with CCC's Billing and Payment terms and conditions (which are incorporated herein) form the entire agreement between you and WILEY concerning this licensing transaction and (in the absence of fraud) supersedes all prior agreements and representations of the parties, oral or written. This Agreement may not be amended except in writing signed by both parties. This Agreement shall be binding upon and inure to the benefit of the parties' successors, legal representatives, and authorized assigns.
- In the event of any conflict between your obligations established by these terms and conditions and those established by CCC's Billing and Payment terms and conditions, these terms and conditions shall prevail.
- WILEY expressly reserves all rights not specifically granted in the combination of (i) the license details provided by you and accepted in the course of this licensing transaction, (ii) these terms and conditions and (iii) CCC's Billing and Payment terms and conditions.
- This Agreement will be void if the Type of Use, Format, Circulation, or Requestor Type was misrepresented during the licensing process.
- This Agreement shall be governed by and construed in accordance with the laws of the State of New York, USA, without regards to such state's conflict of law rules. Any legal action, suit or proceeding arising out of or relating to these Terms and Conditions or the breach thereof shall be instituted in a court of competent jurisdiction in New York County in the State of New York in the United States of America and each party hereby consents and submits to the personal jurisdiction of such court, waives any objection to venue in such court and consents to service of process by registered or certified mail, return receipt requested, at the last known address of such party.

## **WILEY OPEN ACCESS TERMS AND CONDITIONS**

Wiley Publishes Open Access Articles in fully Open Access Journals and in Subscription journals offering Online Open. Although most of the fully Open Access journals publish open access articles under the terms of the Creative Commons Attribution (CC BY) License only, the subscription journals and a few of the Open Access Journals offer a choice of Creative Commons Licenses. The license type is clearly identified on the article.

### **The Creative Commons Attribution License**

The [Creative Commons Attribution License \(CC-BY\)](#) allows users to copy, distribute and transmit an article, adapt the article and make commercial use of the article. The CC-BY license permits commercial and non-

### **Creative Commons Attribution Non-Commercial License**

The [Creative Commons Attribution Non-Commercial \(CC-BY-NC\) License](#) permits use, distribution and reproduction in any medium, provided the original work is properly cited and is not used for commercial purposes.(see below)

**Creative Commons Attribution-Non-Commercial-NoDerivs License**

The [Creative Commons Attribution Non-Commercial-NoDerivs License](#) (CC-BY-NC-ND) permits use, distribution and reproduction in any medium, provided the original work is properly cited, is not used for commercial purposes and no modifications or adaptations are made. (see below)

**Use by commercial "for-profit" organizations**

Use of Wiley Open Access articles for commercial, promotional, or marketing purposes requires further explicit permission from Wiley and will be subject to a fee.

Further details can be found on Wiley Online Library <http://olabout.wiley.com/WileyCDA/Section/id-410895.html>

**Other Terms and Conditions:****v1.10 Last updated September 2015**

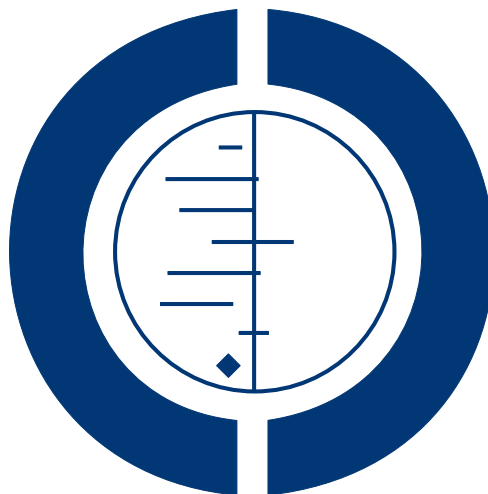Questions? [customercare@copyright.com](mailto:customercare@copyright.com) or +1-855-239-3415 (toll free in the US) or +1-978-646-2777.

---

---

# Interventions for squamous cell carcinoma of the conjunctiva in HIV-infected individuals (Review)

Gichuhi S, Irlam JH



**THE COCHRANE  
COLLABORATION®**

This is a reprint of a Cochrane review, prepared and maintained by The Cochrane Collaboration and published in *The Cochrane Library* 2013, Issue 2

<http://www.thecochranelibrary.com>



---

Interventions for squamous cell carcinoma of the conjunctiva in HIV-infected individuals (Review)  
Copyright © 2013 The Cochrane Collaboration. Published by John Wiley & Sons, Ltd.

## TABLE OF CONTENTS

HEADER . . . . .	1
ABSTRACT . . . . .	1
PLAIN LANGUAGE SUMMARY . . . . .	2
BACKGROUND . . . . .	2
Figure 1. . . . .	5
OBJECTIVES . . . . .	5
METHODS . . . . .	5
RESULTS . . . . .	6
Figure 2. . . . .	7
DISCUSSION . . . . .	7
AUTHORS' CONCLUSIONS . . . . .	8
ACKNOWLEDGEMENTS . . . . .	8
REFERENCES . . . . .	8
CHARACTERISTICS OF STUDIES . . . . .	11
DATA AND ANALYSES . . . . .	13
ADDITIONAL TABLES . . . . .	13
APPENDICES . . . . .	15
WHAT'S NEW . . . . .	19
HISTORY . . . . .	19
CONTRIBUTIONS OF AUTHORS . . . . .	20
DECLARATIONS OF INTEREST . . . . .	20
SOURCES OF SUPPORT . . . . .	20
INDEX TERMS . . . . .	20

[Intervention Review]

# Interventions for squamous cell carcinoma of the conjunctiva in HIV-infected individuals

Stephen Gichuhi<sup>1</sup>, James H Irlam<sup>2</sup>

<sup>1</sup>Department of Ophthalmology, University of Nairobi, Nairobi, Kenya. <sup>2</sup>Primary Health Care Directorate, University of Cape Town, Cape Town, South Africa

Contact address: Stephen Gichuhi, Department of Ophthalmology, University of Nairobi, P.O Box 347, KNH, Nairobi, 00202, Kenya. [sgichuhi@wananchi.com](mailto:sgichuhi@wananchi.com). [sgichuhi@uonbi.ac.ke](mailto:sgichuhi@uonbi.ac.ke).

**Editorial group:** Cochrane HIV/AIDS Group.

**Publication status and date:** New search for studies and content updated (no change to conclusions), published in Issue 2, 2013.

**Review content assessed as up-to-date:** 19 February 2007.

**Citation:** Gichuhi S, Irlam JH. Interventions for squamous cell carcinoma of the conjunctiva in HIV-infected individuals. *Cochrane Database of Systematic Reviews* 2013, Issue 2. Art. No.: CD005643. DOI: 10.1002/14651858.CD005643.pub3.

Copyright © 2013 The Cochrane Collaboration. Published by John Wiley & Sons, Ltd.

## ABSTRACT

### Background

Squamous cell carcinoma of the conjunctiva is described in the ophthalmic literature as a rare, slow-growing tumour of the eye, normally affecting elderly men around 70 years of age. In Africa, however, the disease is different. The incidence is rising rapidly, affecting young persons (around 35 years of age), and usually affecting women. It is more aggressive, with a mean history of three months at presentation. This pattern is related to the co-existence of the HIV/AIDS pandemic, high HPV exposure, and solar radiation in the region. Various interventions exist, but despite therapy, there is a high recurrence rate (up to 43%) and poor cosmetic results in late disease. This review was conducted to evaluate the interventions for treatment of conjunctival squamous cell carcinoma in HIV-infected individuals.

### Objectives

To evaluate the effect of interventions for treating squamous cell carcinoma of the conjunctiva in HIV-infected individuals on local control, recurrence, death, time to recurrence, and adverse events.

### Search methods

Using a sensitive search strategy, we attempted to identify all relevant trials, regardless of language or publication status, from the following electronic databases; PubMedPubMed, EMBASE and The Cochrane Library. We also searched clinical trial registries; WHO International Clinical Trials Registry Platform (ICTRP) and the US National Institutes of Health Clinicaltrials.gov. We searched the international conference proceedings of HIV/AIDS and AIDS-related cancers from the AIDS Education Global Education System (AEGIS). Searches were conducted between January and February 2012.

### Selection criteria

Randomised controlled trials (RCTs) involving HIV-infected individuals with ocular surface squamous neoplasia.

### Data collection and analysis

We independently screened the results of the search to select potentially relevant studies and to retrieve the full articles. We independently applied the inclusion criteria to the potentially relevant studies. No studies were identified that fulfilled the selection criteria.

---

Interventions for squamous cell carcinoma of the conjunctiva in HIV-infected individuals (Review)

Copyright © 2013 The Cochrane Collaboration. Published by John Wiley & Sons, Ltd.

1

## Main results

No RCTs of interventions currently used against conjunctival squamous cell carcinoma in HIV-infected individuals were identified. There is one ongoing RCT in Kenya that was registered in July 2012.

## Authors' conclusions

### Implications for practice:

Current clinical practice in treatment of squamous cell carcinoma of the conjunctiva rests on a weak evidence base of case series and case reports.

### Implications for research:

Randomised controlled trials for treatment of this disease are needed in settings where it occurs most frequently. Preventive interventions also need to be identified. HIV/AIDS research has not focused on treatment of this tumour.

## PLAIN LANGUAGE SUMMARY

### Interventions for squamous cell carcinoma of the conjunctiva in HIV-infected individuals

Conjunctival squamous cell carcinoma, a tumour of the thin membrane that covers the white of the eye, is becoming more common, more aggressive, and affecting more young people, especially women. This pattern is associated with the HIV/AIDS pandemic, exposure to solar radiation, and infection with human papilloma virus (HPV). Various treatment modalities exist, but the recurrence rate is high and the cosmetic outcome of late disease unsightly (Figure 1). Death may occur when the disease spreads to the surrounding structures and the brain. This review was conducted to evaluate the effects of the current interventions. No randomised controlled trials of any interventions for this cancer were found. Current clinical practice appears to be based on case series and case reports. These are weak sources of evidence for the effectiveness of a treatment. Randomised controlled clinical trials are needed.

## BACKGROUND

### Definition

Squamous cell carcinoma of the conjunctiva (SCC) is the end stage of a spectrum of conditions called ocular surface squamous neoplasia (OSSN). Histologically, OSSN varies from a benign form that includes papilloma, pseudoepitheliomatous hyperplasia and benign hereditary intraepithelial dyskeratosis, through a pre-invasive form called conjunctival intraepithelial neoplasia (CIN) graded as I, II or III depending on depth of involvement and finally the invasive form that includes squamous cell carcinoma and mucoepidermoid carcinoma (Basti 2003). When the dysplastic changes are confined to the basal one third of the epithelium, this is termed CIN I or mild dysplasia, when they extend into the middle third of the epithelium this is termed CIN II or moderate dysplasia and when they extend into the superficial third of the epithelium this is termed CIN III or severe dysplasia. Full thickness dysplasia is also referred to as carcinoma-in-situ (CIS). Invasive squamous cell carcinoma of the conjunctiva refers to the infiltration through the basement membrane to involve the underlying stroma (Basti

2003; Shields 2004). Clinically, these stages may be indistinguishable except by histology.

### Clinical features

The tumour may be asymptomatic or present with redness, irritation, severe pain, and visual loss (Tunc 1999). It commonly affects the visible area between the upper and lower eyelids (interpalpebral conjunctiva), usually on the nasal side at the margin of the conjunctiva and the cornea (limbus). This slow-growing tumour can present as a solitary or diffuse growth. Solitary tumours can be nodular or gelatinous and may have a whitish plaque (leukoplakia). The lesion mimics benign conjunctival degenerations such as pterygium and pinguecula. Most cases are unilateral (Cervantes 2002; Chisi 2006).

The morbidity from squamous cell carcinoma of the conjunctiva relates to the effects of the disease and its treatment. It may extend into the eyeball, orbit, regional lymph nodes, surrounding

paranasal sinuses and the brain. Death may result from regional or distant metastases, as well as intracranial spread.

### Aetiology

The aetiology of SCC has been associated with HIV infection (Ateenyi-Agaba 1995; Waddell 1996), human papilloma virus (HPV) infection (Waddell 1996; Nakamura 1997; Newton 2002), immunosuppression in organ transplant recipients (Macarez 1999), and exposure to ultraviolet B rays of the sun (Ateenyi-Agaba 2004; Ng 2008; ). Chronic conjunctival diseases, such as allergic conjunctivitis and trachoma, have also been implicated (Poole 1999).

The majority of affected persons in Africa are HIV-positive; 71% in Uganda, 86% in Malawi (Waddell 1996), 70.6% in South Africa (Mahomed 2002) and 75% in Nigeria (Osahon 2011). In a smaller study in Zimbabwe, 12 out of 13 persons with SCC or CIS (92.3%) were HIV-positive (Porges 2003). Many ophthalmologists in Africa now consider SCC in young adults to be a marker for HIV infection. The relationship between SCC and HPV is less clear. Some case-control studies have found an association (Moubayed 2004; de Koning 2008) while some have not (Sen 2007; Guthoff 2009). Among HIV-infected people with SCC, cutaneous types of HPV are detected more frequently than the mucosal types (de Koning 2008; Ateenyi-Agaba 2010). In another Ugandan study, HPV was detected more frequently in the low-grade conjunctival neoplasias than in more advanced disease (Tornesello 2006). Ultraviolet solar radiation causes tissue damage mediated through mutation of the tp53 tumour-suppressor gene and tissue matrix metalloproteinases (Ateenyi-Agaba 2004; Ng 2008).

It is plausible that the aetiology involves an interaction of these factors in a yet to be determined model.

### Epidemiology

The epidemiology of SCC has transformed in the last few decades. It used to be an uncommon slow-growing tumour found in elderly males (Lee 1997; McKelvie 2002), but in Africa it is becoming more common, more aggressive, and more likely to affect young persons, especially females (Ateenyi-Agaba 1995). This pattern is related to the co-existence of the HIV/AIDS pandemic, high HPV exposure, and solar radiation in the region. The HIV pandemic is mainly centered in Africa. In 2009 22.5 million of the 33.3 million infected people worldwide were living in Africa (UNAIDS 2010). Africa also has the highest prevalence of HPV infection in the world, with an age-adjusted prevalence of 25.6% in women of age 15 to 74 years, followed by South America (14.3%), Asia (8.7%) and Europe (5.2%). (Clifford 2005). The equator bisects the continent and over 75% of the continent is within the tropics with consequent high ambient solar exposure all year round.

The Kampala Cancer Registry in Uganda recorded a six-fold increase in the incidence of conjunctival squamous cell carcinoma,

from an average of six per million per year between 1970 and 1988, to 35 per million per year in 1992 (Ateenyi-Agaba 1995).

A study in Australia found that 78.5% of affected persons were elderly males with a mean age of 60 years (Lee 1997). Similarly, in Britain, 77% were males and 69% of them were more than 60 years old (McKelvie 2002). In contrast, a study in Zimbabwe found that 70% of patients were young females with a median age of 35 years (Pola 2003), while in South Africa the mean age was 37 years (Mahomed 2002). In Tanzania the tumour has been observed to be more aggressive than it was previously. The mean length of history on presentation is three months (Poole 1999).

SCC is a common tumour of the ocular surface among adults in Africa. Pola 2003 In Tanzania 45.8% of 168 conjunctival biopsies seen between 1996 and 1997 were squamous cell carcinomas, while 35% were pingueculum or pterygium (Poole 1999).

The prevalence of SCC in a hospital-based HIV-positive population in Kenya was 7.8% (Chisi 2006).

### Diagnosis

Most cases are diagnosed on clinical impression after a person presents with a growth on the eyeball, which is then excised and sent for histology to get a definitive diagnosis (Shields 1997). Histopathology is the commonest mode of diagnosis in practice. Although regarded as the gold standard, histopathological diagnoses are subject to discordant interpretation (Margo 2002). Cytology has also been used, especially for the follow-up of people treated using chemotherapy or immune therapy to monitor recurrence, since malignant cells are poorly adherent to each other (McKelvie 2001).

Other methods include the use of DNA cytometry to identify tumour-cell regression (Nadjari 1999); immunostaining for certain molecular genetic markers, such as proliferating cells nuclear antigens (PCNA), Ki67 expression, tp53 gene mutations, and argyrophilic nucleolar organiser regions (AgNORs) (Aoki 1998); and toluidine blue staining to mark tumour margins for surgical excision (Kaji 2006).

### Treatment options

The treatment of this condition since the pre-HIV era has been simple: surgical excision alone or with additional adjunctive therapy. The main objective of surgical excision is complete removal of the tumour to minimise recurrence (Shields 1997). The resulting surface defect may need reconstruction using amniotic membrane transplantation (España 2002; Gunduz 2005) or limbal autografts (Copeland 1990). Adjunctive therapies augment surgical excision. These include cryotherapy, chemotherapy, radiotherapy, immune therapy, and amniotic membrane transplants. They work



by killing residual malignant cells at the excision margins or any that may be seeded during excision, although there are also reports of their use as primary therapy (Cerezo 1990; Karp 2001; Barbazetto 2004). Cidofovir, an antiviral active against human papilloma virus, has been described as a primary therapy, and was reported to cause tumour regression (Sherman 2002). It undergoes phosphorylation to active diphosphates independent of viral enzymes, which act as both inhibitors and alternative substrates of viral DNA polymerase, thus inhibiting DNA synthesis (Safrin 2004). A list of these interventions is shown in Table 1.

Cryotherapy kills malignant cells by repeated cycles of freezing and thawing (Peksayar 1989). Chemotherapy involves using a class of drugs called antimetabolites. They act by interfering with the enzymes involved in the intermediary metabolism of replicating cancer cells. An example is 5-Fluorouracil (5-FU) and mitomycin C. The former (5-FU), is a prodrug, which means it is converted to active molecules. One of them, 5-fluoro-2'-deoxyuridine-5'-monophosphate (FdUMP), binds to the enzyme thymidylate synthetase critical for the synthesis of thymidylate, which results in the inhibition of DNA synthesis. Another one, 5-fluorouridine-5'-triphosphate (FUTP) interferes with RNA synthesis (Chu 2004). It is cell-cycle specific and acts in the S phase of the cell cycle. In one study, 1% 5-FU eyedrops were used alone without concurrent surgery or radiotherapy to treat a recurrent tumour (Midena 2000). Mitomycin C is an antibiotic which acts by interfering with the DNA of tumour cells. It undergoes metabolic activation, which generates an alkylating agent that cross-links DNA, making the cell unable to replicate (Chu 2004). It is a cycle-non-specific agent that is most effective in the G1 and S phases. Radiotherapy destroys the DNA and RNA of dividing cells (Goldberg 1963). The source of beta radiation is strontium 90 (Cerezo 1990). Photodynamic therapy combines a drug (called a photosensitizer or photosensitizing agent) with light of a specific wavelength to produce activated oxygen species that promote tumour destruction (Castano 2005). Another treatment option is amniotic membrane transplantation. It is one of the layers of the placenta and is obtained after elective Caesarean section. It has anti-angiogenic, anti-scarring, and anti-inflammatory properties (Hao 2000). Immune therapy for this condition involves the use of interferon alpha. Interferon alpha is part of a group of proteins called cytokines. It has three-pronged action with antiviral and oncostatic effects and also activates natural killer cells, which are cells of the immune system that are able to recognise and destroy tumour cells (Lake 2004). The exact mechanism of action is not known. Cidofovir, an antiviral that is active against human papilloma virus, has been reported to cause regression of this tumour (Sherman 2002). It undergoes phosphorylation to active diphosphates independent of viral enzymes, which act as both inhibitors and alternative substrates of viral DNA polymerase, thus inhibiting DNA synthesis (Safrin 2004).

Advanced disease where the tumour has spread requires removal of the eyeball (modified enucleation) or the entire orbital contents (exenteration) in an attempt to save life (Shields 1991).

Despite therapy, up to 43% of treated patients experience recurrence at variable times (but usually within two years) (Peksayar 1989; Tabin 1997; Yeatts 2000). Simple excision has a higher rate of recurrence. A study in Australia reported 23% (Lee 1997). In the USA, it was 28.5%, but was 7.7% when combined with cryotherapy (Sudesh 2000). In one series of 17 cases treated with mitomycin C eye drops, 15 of them had undergone one to four surgical procedures before the mitomycin C treatment and six (35%) recurred within six months (Frucht-Pery 1997). The efficacies of treatment reported in the literature need to be interpreted cautiously, since some of the treated cases have recurrences from prior surgical excision (Frucht-Pery 1997; Midena 2000). The recurrence rate may be higher in Africa due to late presentation, exposure to solar radiation, and lack of many of the adjunctive therapies. Only cryotherapy and chemotherapy are likely to be found in advanced centres.

It is not clear whether the efficacy of these interventions is different in people with HIV infection. The effect, if any, of highly active antiretroviral therapy (HAART) on this condition is also not clearly known.

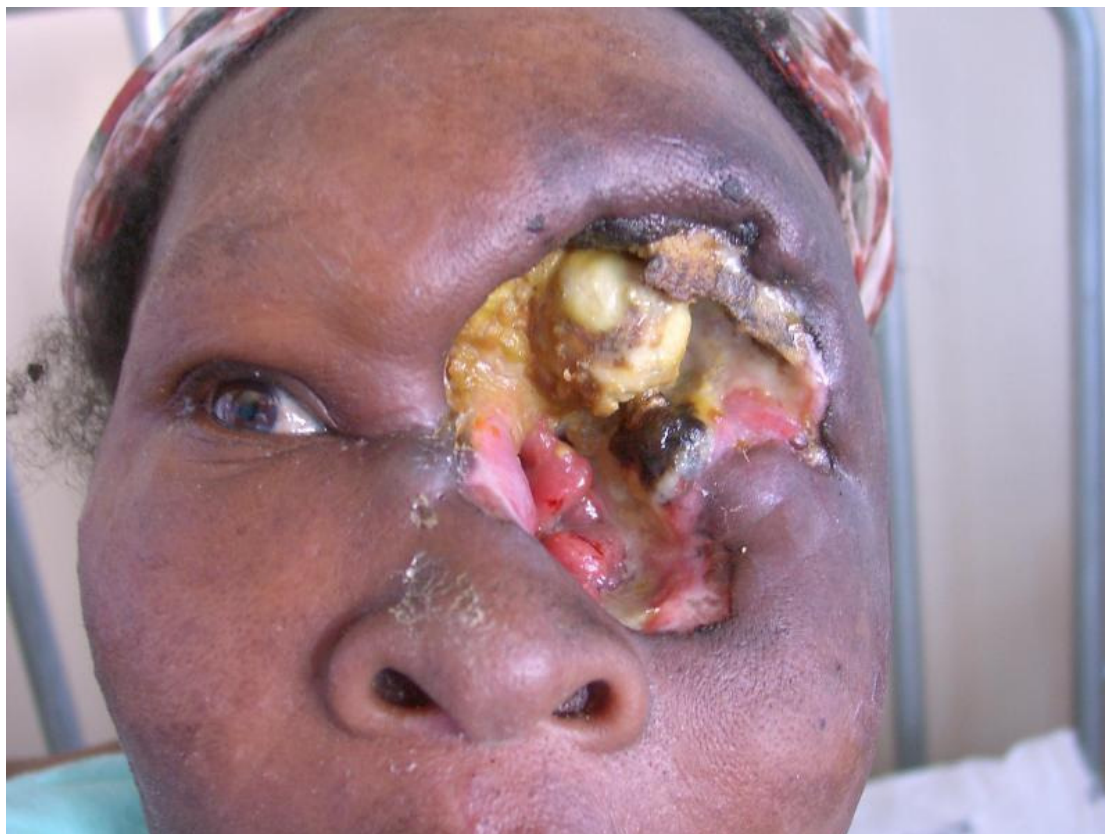
#### Clinical and public health importance of this review

Although the number of people living with HIV infection worldwide seems to have stabilized Africa remains the global epicentre of the AIDS pandemic (UNAIDS 2010). The region also has the highest prevalence of HPV in the world and high solar ultraviolet exposure year-round (Clifford 2005). If this triad of risk factors remains, the number of cases of conjunctival squamous cell carcinoma is expected to remain high. The effect of HPV vaccination in children on OSSN if any will take a long time to determine.

Recurrences still occur after surgical excision. Most of the current adjunctive therapies described are not readily available in low-income countries. They are expensive and inconvenient to use. Cryotherapy requires special probes and canisters of liquid nitrogen gas that need refilling. Amniotic membrane transplantation requires tissue banks to process and preserve the transplant material. Medications for chemotherapy are not widely available, but are probably the easiest to obtain and use in such settings, since they are packed in small vials and do not require stringent storage conditions.

The cosmetic outcome of advanced disease and its treatment is very poor and leaves patients with an empty socket (Figure 1). Patients who undergo orbital exenteration often experience social problems because of their facial disfigurement leading to limited social interaction (Bonanno 2010). Facilities for cosmetic surgery and orbital implants in low-income countries are often unavailable.

Figure 1.



With antiretroviral therapy, HIV-infected people can now enjoy an improved physical appearance and quality of life, but unsightly lesions on the face such as those caused by conjunctival squamous cell carcinoma unmask what would otherwise be a 'hidden' HIV infection. This potentially exposes the affected persons to the stigma and discrimination associated with HIV infection. Effective evidence-based interventions that allow early diagnosis and treatment are therefore needed.

## OBJECTIVES

To evaluate interventions for treating squamous cell carcinoma of the conjunctiva in HIV-infected individuals (see [Table 1](#) for list of interventions).

## METHODS

### Criteria for considering studies for this review

### Types of studies

Randomised controlled trials (RCT).

### Types of participants

HIV-positive people with ocular surface squamous neoplasia (OSSN), whose diagnosis of HIV infection is based on either antibody or antigen tests, and whose OSSN is determined by histology, conjunctival impression cytology, or immunostaining.

### Types of interventions

Any intervention used for treating OSSN, including the following:

- surgical excision, modified enucleation, and exenteration
- adjunctive therapies such as cryotherapy, chemotherapy, radiotherapy, amniotic membrane transplants, and immune therapies, such as interferon therapy
- cidofovir
- different regimens of HAART
- combinations of the above

We were interested in trials that compared any of the interventions with another intervention or a placebo, or trials comparing different dosages or regimens of the same intervention.

## Types of outcome measures

### Primary outcomes

- local control, defined as a tumour-free period of two years
- recurrence at six months, then at six-month intervals thereafter until two years after treatment, diagnosed by histopathology, conjunctival impression cytology, or immunostaining
- death

### Secondary outcomes

- time to recurrence
- adverse events

## Search methods for identification of studies

The HIV/AIDS review group search methods were used. We searched electronic databases and abstracts of conference proceedings. There were no language restrictions. The key words used in the search included:

ocular surface squamous neoplasia, squamous cell carcinoma, conjunctiva, carcinoma in situ, conjunctival intraepithelial neoplasia, HIV, AIDS, excision, enucleation, exenteration, chemotherapy, cryotherapy, interferon, immunotherapy, radiotherapy, A search had been conducted in December 2009 using search terms from the first edition of this review and found no trials. We conducted an updated search beginning January 2010.

### • Electronic databases

The following electronic databases were searched.

1. PubMed - from January 2010 to 27th January 2012
2. EMBASE - from January 2010 to 10th February 2012
3. The Cochrane Library - from January 2010 to 3rd February 2012

### • Clinical trial registers

We searched the WHO International Clinical Trials Registry Platform (ICTRP) on 10th February 2012 ([WHO ICTRP 2012](#)). We also searched the clinical trial register of the US National Institutes of Health (NIH) [www.clinicaltrials.gov](http://www.clinicaltrials.gov) website ([NIH 2012](#)) on 12th February 2012. This database includes trials registered with the US National Eye Institute (NEI) and US National Cancer Institute (NCI).

### • Conference proceedings

We searched abstracts of the proceedings of the HIV/AIDS conferences covered in the AIDS Education Global Education System (AEGIS) database (<http://www.aegis.com/search>).

This search covered all the following conferences which also shows the latest conference abstracts available in the AEGIS database:

1. International AIDS conference by the the International AIDS Society (IAS) upto the conference held from 18th-23rd August 2010
2. International AIDS Society (IAS) HIV Pathogenesis and Treatment upto the 5th conference held from 19th-22nd July 2009
3. International Congress on Drug Therapy in HIV infection upto the 9th meeting on 9th-13th November 2008
4. International Workshops on Adverse Drug Reactions and Lipodystrophy in HIV upto the 11th workshop on 26th-28th October 2009
5. Conference on Retroviruses and Opportunistic Infections (CROI) upto the 15th conference on 3rd-6th February 2008
6. Centers for Disease Control and Prevention (CDC) National HIV Prevention conference upto the meeting on 12th-15th June 2005
7. The International Workshops on HIV Drug Resistance and Treatment Strategies upto the 5th workshop on 4th-8th June 2001
8. British HIV Association (BHIVA) upto the 17th conference held on 6th to 8th April 2011
9. European AIDS Clinical Society upto the 11th conference held on 24th-27th October 2007
10. National HIV/AIDS Update Conference upto the 17th conference on 10th-13th April 2005

### • Reference lists

We checked the reference lists of all studies identified by the above methods for additional relevant records.

## Data collection and analysis

We independently screened the results of the search to select potentially relevant studies and to retrieve the full articles ([Table 2](#)). Where there was any uncertainty we obtained the full article. We independently applied the inclusion criteria using a specially designed eligibility form to the potentially relevant studies. No randomised controlled trials met the inclusion criteria.

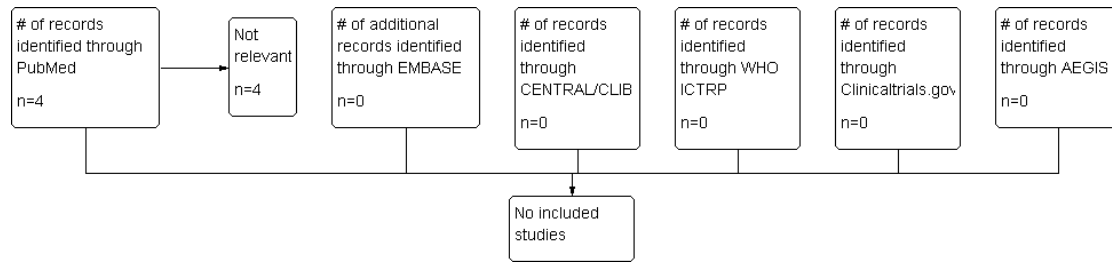
## RESULTS

### Description of studies

See: [Characteristics of ongoing studies](#).

No studies were identified that fulfilled the selection criteria. The PRISMA flowchart in [Figure 2](#) summarizes the results ([Figure 2](#)). There is an ongoing study in Kenya that was registered in the PanAfrican Clinical Trials Register on 19th July 2012. This register feeds into the WHO International Clinical Trials Registry Platform (ICTRP).

**Figure 2. PRISMA study flow diagram.**



### Risk of bias in included studies

No studies were identified that fulfilled the selection criteria.

### Effects of interventions

No studies were identified that fulfilled the selection criteria. The search strategy yielded 12 records, which were all excluded (see table of excluded studies).

## DISCUSSION

In this review no randomised controlled trials on the effectiveness of interventions against conjunctival squamous cell carcinoma in HIV-infected individuals were identified. No randomised controlled trials were found, even in the HIV-uninfected populations. Current practice is based on the results of interventional case series and case reports (Table 1). The quality of evidence from these study designs ranks low by various systems for grading evidence. It is graded level four by the Oxford Centre for Evidence-Based Medicine (OECBM) recommendations (Phillips 2001) and low-grade by the Grading of Recommendations Assessment, Development and Evaluation (GRADE) Working Group (Atkins 2004). According to GRADE, low means that further research is very likely to have an important impact on our confidence in the estimate of effect and is likely to change the estimate. These studies are also mainly from western countries, where the participants are usually elderly males, who have a different disease profile from participants in developing countries. They have a less aggressive form of the disease and few are HIV-infected (Ateenyi-Agaba 1995; Waddell 1996; Lee 1997; Poole 1999; Mahomed 2002; McKelvie 2002). We could not explain why there are no trials, but postulate that perhaps it reflects differences in research priorities, since the prevalence of this tumour is low among HIV-infected individuals living in the western world.

There is a need to conduct randomised controlled trials to provide unbiased evidence for the effectiveness of currently used interventions for treating conjunctival squamous cell carcinoma. Ideally,

the disease would be studied in its early stages, before it has spread, since in the later stages the treatment is more costly, can only be provided in tertiary care centres, and would tend to be individually tailored depending on the extent of spread. Studies are needed in the setting where the greatest burden of disease is found. The typical setting involves young HIV-infected individuals, mostly females with aggressive disease and HIV co-infections, in the context of high HIV prevalence, high solar exposure, and limited resources.

Investigating the effectiveness of simple surgical excision versus wide excision with or without adjunctive antimetabolite eye drops would be relevant as these are relatively simple interventions that can be easily translated in developing countries. The effect of new health technologies used in the developed world, such as cryotherapy, amniotic membrane transplants, and photodynamic therapy, should also be assessed in RCTs.

Preventive interventions directed against the mutagenic effects of solar ultraviolet B radiation and the oncogenic viruses associated with this disease also need to be identified.

There is also an important implication for diagnostic tests for early disease. Ethical issues that may arise include, for instance, whether participants should be subjected to the application of potentially dangerous cytotoxic antimetabolites as an adjunct to excision biopsy before there is histological confirmation of tumour. Treatment of conjunctival squamous cell carcinomas with topical mitomycin C and/or radiation has been associated with induction of atypical cell changes, such as conjunctival DNA-polyploidy afterward (Cartsburg 2001). More sensitive diagnostic tests, such as cytology or immunostaining, may thus need to be used pre-operatively.

Treatment of opportunistic tumours in HIV/AIDS, such as squamous cell carcinoma of the conjunctiva, is part and parcel of HIV care. Untreated squamous cell carcinoma of the conjunctiva threatens survival. Not paying attention to this disease may compromise the gains from other care availed to affected individuals.

## AUTHORS' CONCLUSIONS

### Implications for practice

Current clinical practice in treatment of squamous cell carcinoma of the conjunctiva is based on case series and case reports. This is a weak evidence base.

### Implications for research

RCTs for treatment of this disease are needed in the settings where it occurs most frequently. Preventive interventions, such as HPV vaccination, also need to be identified once scientific knowledge

of the serotypes involved is established. HIV/AIDS research has not focused on treatment of this tumour.

## ACKNOWLEDGEMENTS

Dr S Gichuhi was awarded a Reviews for Africa Programme Fellowship ([www.mrc.ac.za/cochrane/rap.htm](http://www.mrc.ac.za/cochrane/rap.htm)), funded from the Nuffield Commonwealth Programme, through The Nuffield Foundation. We would like to acknowledge the support provided by the staff at the South African Cochrane Centre and the Cochrane HIV/AIDS Review Group mentoring programme.

## REFERENCES

### References to ongoing studies

#### Gichuhi 2012 {unpublished data only}

Adjuvant topical 5fluorouracil (5FU) for ocular surface squamous neoplasia. Ongoing study 23/8/2012.

### Additional references

#### Aoki 1998

Aoki S, Kubo E, Nakamura S, Tsuzuki A, Tsuzuki S, Takahashi Y, et al. Possible prognostic markers in conjunctival dysplasia and squamous cell carcinoma. *Japanese Journal of Ophthalmology* 1998;**42**(4):256–61.

#### Ateenyi-Agaba 1995

Ateenyi-Agaba C. Conjunctival squamous cell carcinoma associated with HIV infection in Kampala, Uganda. *Lancet* 1995;**345**(8951):695–6.

#### Ateenyi-Agaba 2004

Ateenyi-Agaba C, Dai M, Le Calvez F, Katongole-Mbidde E, Smet A, Tommasino M, et al. TP53 mutations in squamous cell carcinomas of the conjunctiva: evidence for UV-induced mutagenesis. *Mutagenesis* 2004;**19**(5):399–401.

#### Ateenyi-Agaba 2010

Ateenyi-Agaba C, Franceschi S, Wabwire-Mangen F, Arisian A, Othieno E, Binta-Kahwa J, van Doorn LJ, Kleter B, Weiderpass E. Human papillomavirus infection and squamous cell carcinoma of the conjunctiva. *British Journal of Cancer* 2010;**102**:262–7.

#### Atkins 2004

Atkins D, Best D, Briss PA, Eccles M, Falck-Ytter Y, Flottorp S, et al. Grading quality of evidence and strengths of recommendations. *BMJ* 2004;**328**(7454):1490–7.

#### Barbazetto 2004

Barbazetto IA, Lee TC, Abramson DH. Treatment of conjunctival squamous cell carcinoma with photodynamic therapy. *American Journal of Ophthalmology* 2004;**138**(2):183–9.

#### Basti 2003

Basti S, Macsai MS. Ocular surface squamous neoplasia: a review. *Cornea* 2003;**22**(7):687–704.

#### Bonanno 2010

Bonanno A, Esmaeli B, Fingere MC, Nelson DV, Randal S, Weber RS. Social challenges of cancer patients with orbitofacial disfigurement. *Ophthalmic Plastic and Reconstructive Surgery* 2010;**26**:18–22.

#### Cartsburg 2001

Cartsburg O, Kallen C, Hillenkamp J, Sundmacher R, Pomjanski N, Bocking A. Topical mitomycin C and radiation induce conjunctival DNA-polyploidy. *Analytical Cellular Pathology* 2001;**23**(2):65–74.

#### Castano 2005

Castano AP, Demidova TN, Hamblin MR. Mechanisms in photodynamic therapy: Part three - photosensitizer pharmacokinetics, biodistribution, tumor localization and modes of tumor destruction. *Photodiagnosis and Photodynamic Therapy* 2005;**2**(2):91–106.

#### Cerezo 1990

Cerezo L, Otero J, Aragon G, Polo E, de la Torre A, Valcarcel F, et al. Conjunctival intraepithelial and invasive squamous cell carcinomas treated with strontium-90. *Radiotherapy and oncology Journal of the European Society for Therapeutic Radiology and Oncology* 1990;**17**(3):191–7.

#### Cervantes 2002

Cervantes G, Rodriguez AA Jr, Leal AG. Squamous cell carcinoma of the conjunctiva: clinicopathological features in 287 cases. *Canadian Journal of Ophthalmology* 2002;**37**(1):14–9.

#### Chisi 2006

Chisi SK, Kollmann MKH, Karimurio J. Conjunctival squamous cell carcinoma in patients with Human Immunodeficiency Virus infection seen at two hospitals in Kenya. *East African Medical Journal* 2006;**83**(5):267–70.

**Chu 2004**

Chu T, Sartorelli AC. Cancer chemotherapy. In: Katzung BG editor(s). *Basic and clinical pharmacology*. 9th Edition. Boston: McGraw Hill, 2004:898–930.

**Clifford 2005**

Clifford GM, Gallus S, Herrero R, Munoz N, Snijders PJF, Vaccarella S, et al. Worldwide distribution of human papillomavirus types in cytologically normal women in the International Agency for Research on Cancer HPV prevalence surveys: a pooled analysis. *Lancet* 2005;**366**(9490):991–8.

**Copeland 1990**

Copeland RA. Limbal autograft for reconstruction after conjunctival squamous cell carcinoma. *American Journal of Ophthalmology* 1990;**4**(110):412–5.

**de Koning 2008**

de Koning MN, Waddell K, Magyezi J, Purdie K, Proby C, Harwood C, Lucas S, Downing R, Quint WG, Newton R. Genital and cutaneous human papillomavirus (HPV) types in relation to conjunctival squamous cell neoplasia: a case-control study in Uganda. *Infectious agents and cancer* 2008;**3**:12.

**Espana 2002**

Espana EM, Prabhasawat P, Grueterich M, Solomon A, Tseng SCG. Amniotic membrane transplantation for reconstruction after excision of large ocular surface neoplasias. *British Journal of Ophthalmology* 2002;**86**(6):640–5.

**Frucht-Pery 1997**

Frucht-Pery J, Sugar J, Baum J, Sutphin JE, Pe'er J, Savir H, et al. Mitomycin C treatment for conjunctival-corneal intraepithelial neoplasia: a multicenter experience. *Ophthalmology* 1997;**104**(12):2085–93.

**Goldberg 1963**

Goldberg JR, Becker SC, Rosenbaum HD. Gamma radiation in the treatment of squamous cell carcinoma of the limbus. *American Journal of Ophthalmology* 1963;**55**:811–5.

**Gunduz 2005**

Gunduz K, Ucakhan OO, Kanpolat A, Gunalp I. Non-preserved human amniotic membrane transplantation for conjunctival reconstruction after excision of extensive ocular surface neoplasia. *Eye* 2005;**20**(3):351–7.

**Guthoff 2009**

Guthoff R, Marx A, Stroebel P. No evidence for a pathogenic role of human papillomavirus infection in ocular surface squamous neoplasia in Germany. *Current Eye Research* 2009;**34**:666–71.

**Hao 2000**

Hao Y, Ma DH, Hwang DG, Kim WS, Zhang F. Identification of antiangiogenic and antiinflammatory proteins in human amniotic membrane. *Cornea* 2000;**19**(3):348–52.

**Kaji 2006**

Kaji Y, Hiraoka T, Oshika T. Vital staining of squamous cell carcinoma of the conjunctiva using toluidine blue. *Acta Ophthalmologica Scandinavica* 2006;**84**(6):825–6.

**Karp 2001**

Karp CL, Moore JK, Rosa RH Jr. Treatment of conjunctival and corneal intraepithelial neoplasia with topical interferon alpha-2b. *Ophthalmology* 2001;**108**(6):1093–8.

**Lake 2004**

Lake DF, Briggs AD, Akporiaye ET. Immunopharmacology. In: Katzung BG editor(s). *Basic and clinical pharmacology*. 9th Edition. Boston: McGraw Hill, 2004:931–57.

**Lee 1997**

Lee GA, Hirst LW. Retrospective study of ocular surface squamous neoplasia. *Australian and New Zealand Journal of Ophthalmology* 1997;**25**(4):269–76.

**Macarez 1999**

Macarez R, Bossis S, Robinet A, Le Callonnec A, Charlin JF, Colin J. Conjunctival epithelial neoplasias in organ transplant patients receiving cyclosporine therapy. *Cornea* 1999;**18**(4):495–7.

**Mahomed 2002**

Mahomed A, Chetty R. Human immunodeficiency virus infection, Bcl-2, p53 protein, and Ki-67 analysis in ocular surface squamous neoplasia. *Archives of Ophthalmology* 2002;**120**(5):554–8.

**Margo 2002**

Margo CE, Harman LE, Mulla ZD. The reliability of clinical methods in ophthalmology. *Survey of Ophthalmology* 2002;**47**(4):375–86.

**McKelvie 2001**

McKelvie PA, Daniell M. Impression cytology following mitomycin C therapy for ocular surface squamous neoplasia. *British Journal of Ophthalmology* 2001;**85**(9):1115–9.

**McKelvie 2002**

McKelvie PA, Daniell M, McNab A, Loughnan M, Santamaria JD. Squamous cell carcinoma of the conjunctiva: a series of 26 cases. *British Journal of Ophthalmology* 2002;**86**(2):168–73.

**Midena 2000**

Midena E, Angeli CD, Valenti M, de Belvis V, Boccato P. Treatment of conjunctival squamous cell carcinoma with topical 5-fluorouracil. *British Journal of Ophthalmology* 2000;**84**(3):268–72.

**Moubayed 2004**

Moubayed P, Mwakyoma H, Schneider DT. High frequency of Human Papillomavirus 6/11, 16, and 18 infections in precancerous lesions and squamous cell carcinoma of the conjunctiva in subtropical Tanzania. *American Journal of Clinical Pathology* 2004;**122**:938–43.

**Nadjari 1999**

Nadjari B, Kersten A, Ross B, Motherby H, Krallmann R, Sundmacher R, et al. Cytologic and DNA cytometric diagnosis and therapy monitoring of squamous cell carcinoma in situ and malignant melanoma of the cornea and conjunctiva. *Analytical and Quantitative Cytology and Histology* 1999;**21**(5):387–96.

**Nakamura 1997**

Nakamura Y, Mashima Y, Kameyama K, Mukai M, Oguchi Y. Detection of human papillomavirus infection in squamous tumours of the conjunctiva and lacrimal sac by immunohistochemistry, in situ hybridisation and polymerase chain reaction. *British Journal of Ophthalmology* 1997;**81**(4):308–13.

**Newton 2002**

Newton R, Ziegler J, Ateenyi-Agaba C, Bousarghin L, Casabonne D, Beral V, et al. The epidemiology of conjunctival squamous cell carcinoma in Uganda. *British Journal of Cancer* 2002;**87**(3):301–8.

**Ng 2008**

Ng J, Coroneo MT, Wakefield D, Di Girolamo N. Ultraviolet radiation and the role of matrix metalloproteinases in the pathogenesis of ocular surface squamous neoplasia. *Investigative Ophthalmology & Visual Science* 2008;**49**:5295–5306.

**NIH 2012**

U.S. National Institutes of Health. Information on clinical trials and human research studies. [www.clinicaltrials.gov](http://www.clinicaltrials.gov) (accessed 10 February 2012).

**Osahon 2011**

Osahon AI, Ukponmwan CU, Uhumwangho OM. Prevalence of HIV seropositivity among patients with squamous cell carcinoma of the conjunctiva. *Asian Pacific Journal of Tropical Biomedicine* 2011;**1**(2):150–53.

**Peksayar 1989**

Peksayar G, Soyuturk MK, Demiryont M. Long-term results of cryotherapy on malignant epithelial tumours of the conjunctiva. *American Journal of Ophthalmology* 1989;**107**(4):337–49.

**Phillips 2001**

Phillips B, Ball C, Sackett D, Badenoch D, Straus S, Haynes B, et al. Levels of evidence and grades of recommendation. [www.cebm.net/levels\\_of\\_evidence.asp](http://www.cebm.net/levels_of_evidence.asp) (accessed 14 June 2006).

**Pola 2003**

Pola EC, Masanganise R, Rusakaniko S. The trend of ocular surface squamous neoplasia among ocular surface tumour biopsies submitted for histology from Sekuru Kaguvi Eye Unit, Harare between 1996 and 2000. *Central African Journal of Medicine* 2003;**49**:1–4.

**Poole 1999**

Poole TR. Conjunctival squamous cell carcinoma in Tanzania. *British Journal of Ophthalmology* 1999;**83**(2):177–9.

**Porges 2003**

Porges Y, Groisman GM. Prevalence of HIV with conjunctival squamous cell neoplasia in an African provincial hospital. *Cornea* 2003;**22**(1):1–4.

**Safrin 2004**

Safrin S. Antiviral agents. In: Katzung BG editor(s). *Basic and clinical pharmacology*. 9th Edition. Boston: McGraw Hill, 2004:801–27.

**Sen 2007**

Sen S, Sharma A, Panda A. Immunohistochemical localization of human papilloma virus in conjunctival neoplasias: a retrospective study. *Indian Journal of Ophthalmology* 2007;**55**:361–3.

**Sherman 2002**

Sherman MD, Feldman KA, Farahmand SM, Margolis TP. Treatment of conjunctival squamous cell carcinoma with topical cidofovir. *American Journal of Ophthalmology* 2002;**134**(3):432–3.

**Shields 1991**

Shields JA, Shields CL, Suvanamani C, Tantisira M, Shah P. Orbital exenteration with eyelid sparing: indications, technique and results. *Ophthalmic surgery* 1991;**22**(5):292–7.

**Shields 1997**

Shields JA, Shields CL, De Potter P. Surgical management of conjunctival tumours: The 1994 Lynn B. McMahan Lecture. *Archives of Ophthalmology* 1997;**115**(6):808–15.

**Shields 2004**

Shields JA, Shields CL. Tumors of the conjunctiva and cornea. In: McLeod SD editor In: Tasman W, Jaeger EA editor(s). *Duane's clinical ophthalmology CD-ROM*. Revised 2004. Vol. 4, Philadelphia: Lippincott William and Wilkins, 2004:Chapter 10.

**Sudesh 2000**

Sudesh S, Rapuano CJ, Cohen EJ, Eagle RC Jr, Laibson PR. Surgical management of ocular surface squamous neoplasms: the experience from a cornea center. *Cornea* 2000;**19**(3):278–83.

**Tabin 1997**

Tabin G, Levin S, Snibson G, Loughnan M, Taylor H. Late recurrences and the necessity for long-term follow-up in corneal and conjunctival neoplasia. *Ophthalmology* 1997;**104**(3):485–92.

**Tornesello 2006**

Tornesello ML, Duraturo ML, Waddell KM, Biryahwaho B, Downing R, Balinandi S, et al. Evaluating the role of human papillomaviruses in conjunctival neoplasia. *British Journal of Cancer* 2006;**94**(3):446–9.

**Tunc 1999**

Tunc M, Char DH, Crawford B, Miller T. Intraepithelial and invasive squamous cell carcinoma of the conjunctiva: analysis of 60 cases. *British Journal of Ophthalmology* 1999;**83**(1):98–103.

**UNAIDS 2010**

Joint United Nations Programme on HIV/AIDS (UNAIDS). Global report: UNAIDS report on the global AIDS epidemic 2010. [http://www.unaids.org/globalreport/global\\_report.htm](http://www.unaids.org/globalreport/global_report.htm) 2010.

**Waddell 1996**

Waddell KM, Lewallen S, Lucas SB, Ateenyi-Agaba C, Herrington CS, Liomba G. Carcinoma of the conjunctiva and HIV infection in Uganda and Malawi. *British Journal of Ophthalmology* 1996;**80**(6):503–8.

**WHO ICTRP 2012**

WHO ICTRP. WHO International Clinical Trials Registry Platform. [www.who.int/ictip/](http://www.who.int/ictip/) (accessed on 10 February 2012).

**Yeatts 2000**

Yeatts RP, Engelbrecht NE, Curry CD, Ford JG, Walker KA. 5-Fluorouracil for the treatment of intraepithelial neoplasia of the conjunctiva and cornea. *Ophthalmology* 2000;**107**(12):2190–5.

\* *Indicates the major publication for the study*



## CHARACTERISTICS OF STUDIES

### Characteristics of ongoing studies *[ordered by study ID]*

#### Gichuhi 2012

Trial name or title	Adjuvant topical 5fluorouracil (5FU) for ocular surface squamous neoplasia
Methods	In this randomized controlled trial tumours involving less than 2 quadrants of the conjunctiva that are suspected to be OSSN will be surgically excised
Participants	Adults with histologically proven OSSN whose tumour excision site has healed
Interventions	Topical 1% 5-Fluorouracil in artificial tears vs artificial tears applied 6 hourly for one month
Outcomes	Primary: Development of histopathologically confirmed recurrent OSSN anytime during the first year after the primary surgery Secondary: Adverse effects of using topical 5-FU 1% four times daily for one month
Starting date	23/8/2012
Contact information	sgichuhi@uonbi.ac.ke
Notes	

## DATA AND ANALYSES

This review has no analyses.

## ADDITIONAL TABLES

Table 1. 2 Interventions used in treatment of conjunctival squamous cell carcinoma

Intervention	Description	Reference
Surgical excision	Alcohol epitheliectomy for the corneal component and partial lamellar scleroconjunctivectomy with 3 to 4mm margins for the conjunctival component. Frozen sections may be used to ensure tumour-free margins. Modified enucleation involves removing the affected conjunctiva with a 4mm margin together with the eyeball. Exenteration involves complete removal of orbital tissue including the periosteum of the bony walls. The eyelids may or may not be spared	<a href="#">Shields 1997</a> <a href="#">Shields 2004</a>
Cryotherapy	Freeze-thaw-freeze-thaw (double freeze-thaw) applying probe to the excised conjunctival margin	<a href="#">Peksayar 1989</a>
Chemotherapy - 5 Fluorouracil (5FU) 1% solution - Mitomycin C 0.02% or 0.04%	As topical solutions to soak operated site for 2-5 minutes, as subconjunctival injection intra- or post operatively or as eyedrops to be applied post-operatively as follows  4 times daily for 1-2 weeks or as pulsed therapy giving 4 applications for 4 days repeated every month for 4-6 cycles  4 times daily for 2 weeks then repeat at 4-6 weeks intervals depending on response	<a href="#">Yeatts 2000</a> <a href="#">Midena 2000</a> <a href="#">Frucht-Pery 1997</a>
Radiotherapy	- beta irradiation - gamma irradiation - photodynamic therapy	<a href="#">Cerezo 1990</a> <a href="#">Goldberg 1963</a> <a href="#">Barbazetto 2004</a>
Amniotic membrane transplants (AMT)	Excise tumour with a 3-4 mm tumour-free margin (so frozen sections needed), apply cryotherapy to the margin then to close the defect suture amniotic membrane with 8/0 vicryl sutures to adjacent conjunctiva and to adjacent cornea using 10/0 nylon sutures with epithelial side facing up	<a href="#">Gunduz 2005</a>

**Table 1. 2 Interventions used in treatment of conjunctival squamous cell carcinoma (Continued)**

Interferon alpha 2b	Topical drops or intralesion injection	Karp 2001
Cidofovir eyedrops 2mg/ml	Applied every 2 hours for 2 weeks then 4 times daily for 2 weeks then 3 times daily for 2 weeks	Sherman 2002

**Table 2. 1 Review methods**

Study selection	The titles and abstracts of search results are scanned and compared to predetermined selection criteria for studies. Articles written in foreign languages are translated to English. Two authors working independently select trials. The authors are blinded to the trial authors and institutions by asking the trial search co-ordinator to block this out when sending abstracts. Where there is uncertainty about inclusion, the full text of the article is obtained and read. If additional information is needed about the trial in question, it is categorized as awaiting assessment until this is obtained. If differences arise regarding trial inclusion, they are discussed and if still unresolved, Dr Taryn Young at the South African Cochrane Centre is asked to take a decision
Data extraction	Data are collected and recorded in similar data extraction forms. The following information is extracted; citation details, study eligibility, study quality and study characteristics. The study characteristics include methods, participants, interventions and outcomes
Assessment of methodological quality of included studies	The methodological quality of the included studies is assessed to determine validity. Selection bias is checked by assessing whether the generation of a random allocation sequence and allocation concealment were performed. Randomization is considered adequate if the allocation sequence is generated from a table of random numbers or by computer. Allocation concealment is deemed adequate if undertaken by means of sequentially prenumbered sealed opaque envelopes, a centralised system or prenumbered coded identical containers. In addition, assessment of blinding, losses to follow-up and whether the analysis was by intention-to-treat (ITT) is undertaken. The definition of ITT is the requirement that participants be analyzed in the groups to which they were randomized, regardless of which intervention they actually received
Data analysis	Measures of treatment effect: The effect measures of choice here are relative risk (RR) for dichotomous data and hazard ratio (HR) for time-to-event data with a 95% confidence interval
	Dichotomous data include: - number of people who experience local control in each comparison group - number of people who experience recurrence during the specified time periods in each comparison group

**Table 2. 1 Review methods** (Continued)

	<ul style="list-style-type: none"> <li>- number of deaths in each comparison group</li> <li>- number of people who experience adverse events in each comparison group</li> <li>- number of people who experience local control in each comparison group</li> <li>- number of people who experience recurrence during the specified time periods in each comparison group</li> <li>- number of deaths in each comparison group</li> <li>- number of people who experience adverse events in each comparison group</li> </ul>
	Time-to-event data include: - time to recurrence
	Dealing with missing data: Participants lost to follow up are censored in the survival analysis
	Assessment of heterogeneity: To identify statistical heterogeneity we look at the forest plot for overlapping confidence intervals and test it using the Cochrane Q test with a p-value of 0.10. The impact of heterogeneity on the meta-analysis is measured using the I-squared test. If I-squared is greater than 70% we will investigate by checking the trials for data entry errors and looking for existence of subgroups. Subgroup analysis by age, sex, geographical location and diagnostic method will be done. These factors have been shown to influence the occurrence of OSSN and we anticipate that they may also influence treatment effects. If no explanation for heterogeneity is found or its correction is not possible, meta-analysis will not be done
	Meta-analysis: A fixed-effect model is used for meta-analysis but when there is heterogeneity that cannot be readily explained, a random-effects model is incorporated
	Sensitivity analysis: We examine how the magnitude of effect differs according to study quality or trial size and also the results of per-protocol analysis with those of intention-to-treat analysis
	Assessment of reporting bias: Publication bias is assessed by using a funnel plot to look for asymmetry

## APPENDICES

### Appendix I. PubMed search strategy and results

Title: Interventions for squamous cell carcinoma of the conjunctiva in HIV-infected individuals  
 Database: PubMed (2010 - 2012)  
 Date: 27 January 2012

Search	Query	Items found
#13	Search #1 AND #2 AND #11 AND ("2010/10/01"[Date - Publication] : "2012/01/27"[Date - Publication])	4
#12	Search #1 AND #2 AND #11	23
#11	Search #9 OR #10	2290
#10	Search conjunctival neoplasms[mh]	1729
#9	Search #5 AND #8	1099
#8	Search #6 OR #7	546016
#7	Search carcinoma[tiab] OR carcinomas[tiab] OR neoplasia[tiab] OR neoplasm[tiab] OR neoplasms[tiab]	514787
#6	Search carcinoma, squamous cell[mh]	92643
#5	Search #3 OR #4	23573
#4	Search conjunctiva[tiab] OR conjunctivas[tiab] OR conjunctival[tiab]	18906
#3	Search conjunctiva[MeSH Terms]	11829
#2	Search (randomized controlled trial [pt] OR controlled clinical trial [pt] OR randomized [tiab] OR placebo [tiab] OR drug therapy [sh] OR randomly [tiab] OR trial [tiab] OR groups [tiab]) NOT (animals [mh] NOT humans [mh])	2499392
#1	Search HIV Infections[MeSH] OR HIV[MeSH] OR hiv[tw] OR hiv-1*[tw] OR hiv-2*[tw] OR hiv1[tw] OR hiv2[tw] OR hiv infect*[tw] OR human immunodeficiency virus[tw] OR human immunodeficiency virus[tw] OR human immunodeficiency virus[tw] OR human immunodeficiency virus[tw] OR ((human immun*) AND (deficiency virus[tw])) OR acquired immunodeficiency syndrome[tw] OR acquired immunodeficiency syndrome[tw] OR acquired immunodeficiency syndrome[tw] OR ((acquired immun*) AND (deficiency syndrome[tw])) OR "sexually transmitted diseases, vi-	282439

(Continued)

ral"[MH:noexp]

## Appendix 2. EMBASE search strategy and results

Title: Interventions for squamous cell carcinoma of the conjunctiva in HIV-infected individuals

Database: PubMed (2010 - 2012)

Date: 10 February 2012

No.	Query	Results
#13	#1 AND #2 AND #11 AND [humans]/lim AND [embase]/lim AND [1-2-2012]/sd NOT [10-2-2012]/sd	0
#12	#1 AND #2 AND #11	4
#11	#9 OR #10	2964
#10	'conjunctiva tumor'/syn	1802
#9	#5 AND #8	1796
#8	#6 OR #7	646277
#7	carcinoma:ab,ti OR carcinomas:ab,ti OR neoplasia:ab,ti OR neoplasm:ab,ti OR neoplasms:ab,ti	617186
#6	'carcinoma, squamous cell'/syn	110025
#5	#3 OR #4	56567
#4	conjunctiva:ab,ti OR conjunctivas:ab,ti OR conjunctival:ab,ti	22041
#3	'conjunctiva'/syn	51682
#2	random*:ti OR random*:ab OR factorial*:ti OR factorial*:ab OR cross?over*:ti OR cross?over*:ab OR crossover*:ti OR crossover*:ab OR placebo*:ti OR placebo*:ab OR (doubl*:ti AND blind*:ti) OR (doubl*:ab AND blind*:ab) OR (singl*:ti AND blind*:ti) OR (singl*:ab AND blind*:ab) OR assign*:ti OR assign*:ab OR volunteer*:ti OR volunteer*:ab OR 'crossover procedure'/de OR 'crossover procedure' OR 'double-blind procedure'/de OR 'double-blind procedure' OR 'single-blind procedure'/de OR 'single-blind procedure' OR 'randomized controlled trial'/de OR 'randomized controlled trial' OR allocat*:ti OR allocat*:ab	1186635

(Continued)

#1	'human immunodeficiency virus infection'/exp OR 'human immunodeficiency virus infection' OR 'human immunodeficiency virus'/exp OR 'human immunodeficiency virus' OR hiv:ti OR hiv:ab OR 'hiv-1':ti OR 'hiv-1':ab OR 'hiv-2':ti OR 'hiv-2':ab OR 'human immunodeficiency virus':ti OR 'human immunodeficiency virus':ab OR 'human immunodeficiency virus':ti OR 'human immunodeficiency virus':ab OR 'human immunodeficiency virus':ti OR 'human immunodeficiency virus':ab OR 'human immunodeficiency virus':ti OR 'human immunodeficiency virus':ab OR 'human immunodeficiency virus':ti OR 'human immunodeficiency virus':ab OR 'acquired immunodeficiency syndrome':ti OR 'acquired immunodeficiency syndrome':ab OR 'acquired immunodeficiency syndrome':ti OR 'acquired immunodeficiency syndrome':ab OR 'acquired immunodeficiency syndrome':ti OR 'acquired immunodeficiency syndrome':ab OR 'acquired immunodeficiency syndrome':ti OR 'acquired immunodeficiency syndrome':ab OR 'acquired immunodeficiency syndrome':ti OR 'acquired immunodeficiency syndrome':ab	371108
----	--	--------

### Appendix 3. The Cochrane Library search strategy and results

Title: Interventions for squamous cell carcinoma of the conjunctiva in HIV-infected individuals  
Database: CLIB (2010 - 2012)  
Date: 3 February 2012

ID	Search	Hits
#1	<a href="#">MeSH descriptor HIV Infections explode all trees</a>	6499
#2	<a href="#">MeSH descriptor HIV explode all trees</a>	2172
#3	<a href="#">hiv</a> OR <a href="#">hiv-1*</a> OR <a href="#">hiv-2*</a> OR <a href="#">hiv1</a> OR <a href="#">hiv2</a> OR <a href="#">HIV INFECT*</a> OR <a href="#">HUMAN IMMUNODEFICIENCY VIRUS</a> OR <a href="#">HUMAN IMMUNODEFICIENCY VIRUS</a> OR <a href="#">HUMAN IMMUNE-DEFICIENCY VIRUS</a> OR <a href="#">HUMAN IMMUNO-DEFICIENCY VIRUS</a> OR <a href="#">HUMAN IMMUN* DEFICIENCY VIRUS</a> OR <a href="#">ACQUIRED IMMUNODEFICIENCY SYNDROME</a> OR <a href="#">ACQUIRED IMMUNODEFICIENCY SYNDROME</a> OR <a href="#">ACQUIRED IMMUNO-DEFICIENCY SYNDROME</a> OR <a href="#">ACQUIRED IMMUNE-DEFICIENCY SYNDROME</a> OR <a href="#">ACQUIRED IMMUN* DEFICIENCY SYNDROME</a>	10597
#4	<a href="#">MeSH descriptor Lymphoma, AIDS-Related, this term only</a>	21
#5	<a href="#">MeSH descriptor Sexually Transmitted Diseases, Viral, this term only</a>	22

(Continued)

#6	(#1 OR #2 OR #3 OR #4 OR #5)	10671
#7	MeSH descriptor Conjunctiva, this term only	473
#8	conjunctiva*:ti,ab,kw	1906
#9	(#7 OR #8)	1906
#10	MeSH descriptor Carcinoma, Squamous Cell, this term only	1818
#11	carcinoma*:ti,ab,kw OR neoplasia:ti,ab,kw OR neoplasm*:ti,ab,kw	42921
#12	(#10 OR #11)	42921
#13	(#6 AND #9 AND #12)	2
#14	(#6 AND #9 AND #12), from 2010 to 2012	0

#### Appendix 4. WHO International Clinical Trials Registry Platform (ICTRP) search terms and results

Title: Interventions for squamous cell carcinoma of the conjunctiva in HIV-infected individuals  
Database: WHO International Clinical Trials Registry Platform (ICTRP) 2010 - 2012  
Date: 10 February 2012  
No results were found for: hiv AND carcinoma AND conjunctiva

#### Appendix 5. National Institutes for Health (NIH) Clinical Trials registry search terms and results

Title: Interventions for squamous cell carcinoma of the conjunctiva in HIV-infected individuals  
Database: Clinicaltrials.gov  
Date: 10 February 2012  
Found no studies with search of: "squamous cell carcinoma" AND conjunctiva AND hiv

### WHAT'S NEW

Last assessed as up-to-date: 19 February 2007.

Date	Event	Description
11 December 2012	New citation required but conclusions have not changed	New comprehensive searches, review updated.
11 December 2012	New search has been performed	Updated



## HISTORY

Protocol first published: Issue 1, 2006

Review first published: Issue 2, 2007

Date	Event	Description
29 October 2008	Amended	Converted to new review format.
19 February 2007	New citation required and conclusions have changed	Substantive amendment

## CONTRIBUTIONS OF AUTHORS

SG developed the review topic idea. JJ looked through search outputs, provided input, guidance and mentoring.

## DECLARATIONS OF INTEREST

Stephen Gichuhi has received funding to conduct a trial in this field ([Gichuhi 2012](#)).

## SOURCES OF SUPPORT

### Internal sources

- University of Nairobi, Department of Ophthalmology, Kenya.

### External sources

- South African Cochrane Centre HIV/AIDS Mentoring Programme, South Africa.

## INDEX TERMS

### Medical Subject Headings (MeSH)

Carcinoma, Squamous Cell [\*therapy]; Conjunctival Neoplasms [\*therapy]; HIV Infections [\*complications]

### MeSH check words

Humans

# Review of case-series and case-reports of interventions for ocular surface squamous neoplasia (OSSN)

## Rationale

A Cochrane systematic review of interventions found no randomized controlled trials except one in Australia. Numerous case reports and case-series formed the evidence base for treatment of OSSN which is low down in the hierarchy of evidence. We reviewed these case series to see what could be learned from them.

## Methods

In August 2015 using a sensitive search strategy we tried to identify all relevant trials, regardless of language or publication status using the following search terms; “randomized controlled trial”, “controlled clinical trial”, “randomized”, “placebo”, “drug therapy”, “randomly”, “trial”, “conjunctiva\*”, “ocular surface”, “carcinoma”, “cancer”, “neoplasia”, “neoplasm”, “neoplastic”, “dysplasia”, “dysplastic”, “squamous”, “squamous cell”.

We searched electronic databases (PubMed, EMBASE, The Cochrane Library), clinical trial registries (WHO International Clinical Trials Registry Platform and the US National Institutes of Health Clinicaltrials.gov), and international conference proceedings of HIV/AIDS and AIDS-related cancers from the AIDS Education Global Education System (AEGIS). Only series that reported recurrence as an outcome were included.

## Results

The interventions reported in various cases series are summarised in tables 1-10. There is only one published trial on topical Mitomycin-C (MMC) in a patient group without HIV infection in Australia. Some case series reported tumour resolution as an outcome and are not included here. Only five studies involved African patients (Tunisia, Egypt, Uganda, and South Africa). Sample sizes were variable. With all treatment regimens reported, there were varying doses, inclusion criteria and follow up times.

### *Surgery ± Cryotherapy (Table 1)*

Surgical excision was the most commonly employed treatment. Small tumours were excised while more advanced orbital disease needed exenteration to clear all the orbital contents down to the periosteum of the bone. The margins of the excision varied from 2m to 4mm. Some surgeons used alcohol epitheliectomy (absolute alcohol) to aid removal of tumour extending

to the cornea. Some used the bare sclera technique where the tumour was dissected off down to the sclera leaving the wound uncovered while some closed the resulting defect by mobilising the surrounding conjunctiva (primary closure) or transplanted either amniotic membrane or autologous conjunctiva from the same or other eye. Amniotic membranes are obtained from tissue banks and there are no such facilities in Africa.

Surgical excision may be augmented by cryotherapy where 2-4 freeze-thaw cycles were used to obliterate residual tumour at the bed and margins. Cryotherapy requires the use of liquefied gas, either carbon dioxide or nitrous oxide, which is not easily available in most centres in sub-Saharan Africa. Cryotherapy was the most commonly used adjuvant treatment with surgical excision. Some articles mentioned local excision without qualifying whether cryotherapy was used or not. A series consisting of advanced squamous cell carcinoma from Germany worse than grade 3 using the American Joint Committee on Cancer (AJCC) system reported that 52% of excisions and 20% of exenterations recurred after a median of 24 months.

Surgical excision alone is associated with recurrences of 3.2% to 66.7% 32 months later. The former involved surgical excision with the corneal extension removed using blade dissection then wiped with alcohol and using primary closure without cryotherapy. This was a very experienced surgeon in Uganda. With cryotherapy surgical excision was associated with recurrences varying from zero at 6.5 years to 52% at 24 months (the latter being the advanced tumour series aforementioned).

#### *Surgery ± amniotic membrane transplant (Table 2)*

Series involving surgery with amniotic membrane transplants reported recurrences ranging from zero after a mean of 31 months to 12.5% after a mean 17.8 months of follow up. Those who used the bare sclera technique sometimes applied Weck-cel sponges soaked with cytotoxic agents such as 5FU or MMC to the tumour bed intraoperatively for periods varying from 2 minutes to 5 minutes while others would employ this only when complete excision of the tumour was not deemed possible. Surgical excision with adjuvant chemotherapy was associated with recurrences varied between zero and 67% but most often in the 30% to 67% range. In older series local resection would be supplemented by radiation therapy.

#### *Interferon alpha 2b (IFNα2b) (Table 3)*

IFN is an immune modulator used on its own or combined with surgical excision and cryotherapy while in one series IFN was combined with retinoic acid eye drops. Preparations available include eye drops or an injection. Some used it as primary treatment of presumed

OSSN or for residual OSSN unresponsive to excision, cryotherapy and MMC. Two formulations of IFN eyedrops were reported, 1million IU/ml and 3 million IU/ml, used four times daily for four weeks. Some continued the drops till a month beyond complete clinical resolution. The injection preparations vary from 6-16 million IU/ml. Some infiltrated it around the lesion (peri-lesion) while some injected it under the lesion (sub-lesion). Injections were given every three days for seven doses or three times weekly. Recurrences varied from none to 33.3% at one year. IFN $\alpha$ 2b needs refrigeration and is continued long after clinical resolution. It has local and systemic side effects such as conjunctival hyperemia, superficial punctate keratitis and flu-like symptoms. The cost of the 3 million IU/ml dose of eyedrops was \$260 for a 5 ml bottle and the 1 million IU/ml dose is \$120 in 2010 in Bascolm Palmer, Florida, USA. Treatment for 1 month with IFN 1 million IU/ml drops four times daily for a month cost \$179 in 2012 in Wills Eye Hospital, Philadelphia, USA. In Africa this would be too expensive besides being unavailable.

#### *Cyclosporin A (CsA) (Table 4)*

CSA is an immunosuppressant that interferes with the activity of T-lymphocytes. It is prepared as a 0.05% ophthalmic emulsion and used topically. In one series it was combined with surgical excision and MMC while in another it was combined only with MMC. Its use allows a lower concentration of MMC (0.01%) to be used. There were no recurrences reported after two years of follow up. The ocular surface toxicity observed (punctate keratopathy, conjunctival hyperemia) and eyelid toxicity were attributed to MMC but it was not clear how this distinction was made.

#### *Mitomycin C (MMC) (Table 5)*

MMC is an antibiotic classified as an alkylating agent causing cross linking of DNA thus inhibiting DNA synthesis. It is usually used topically as a 0.02% or 0.04% solution applied four times daily for a week or two followed by one to three weeks off then the cycle is repeated to make a total of 4 cycles. Most pharmacies compound it for themselves due to a short shelf life and typically patients have to return after a few weeks to get the next bottle. It is often combined with surgical excision although some use it on its own. Recurrences range from zero to 29.4% when used alone; zero to 14% with surgical excision; and zero with IFN. A caveat here is that the severity of disease treated and surgical margin involvement in these three groups differs. The most common adverse effect is allergy and conjunctival hyperemia usually in the second cycle while perhaps the most grievous is persistent epithelial defects due to presumed limbal stem cell deficiency and corneal or scleral melting.

### *5-Fluorouracil (5FU) (Table 6)*

5FU belongs to the family of antimetabolites meaning it is a chemical that interferes with cell metabolism by inhibiting the use of a metabolite which is another chemical needed for normal metabolism of the cell (typically an enzyme). It is a pyrimidine analogue which works through inhibition of thymidylate synthetase, an enzyme used to produce one of the intermediate products along the process of producing thymine, one of the nucleic acids in DNA. Like MMC it is often used in combination with surgical excision and cryotherapy and is applied intraoperatively to soak the excision bed or post operatively as eye drops or subconjunctival injections at the end of surgery. Eyedrops are usually a 1% solution often prepared by diluting the injection in normal saline or methylcellulose. A treatment course often involves using the drops four times daily for 2 or 4 weeks. Some have used it in 2-3 week cycles lasting a week followed by a 1-week drug holiday while others have used it for 4 weeks continuously. Reported recurrences vary from 2% to 43% when used alone, none with MMC, and zero to 31% with surgery. 5FU is cheap. The cost of 5FU 1% eyedrops four times daily for 4 weeks in 2016 February was 320 Kenyan shillings (US\$ 3.2 or Sterling £ 2.1). A long-term safety study in Italy reported that there was no difference between the treated eye and the fellow eye with respect to endothelial cell count, pleomorphism and polymegathism, anterior stromal keratocyte density, sub-basal nerve plexus fibre number, density, and beadings and central cornea epithelium thickness. It has been used off-label for a long time so there is widespread clinical experience and acceptability for it is used in OSSN and other areas of ophthalmology such as trabeculectomy. Case series report its effectiveness; and regimes with some of the other interventions are rather complicated. This makes it a feasible alternative for East Africa.

### *All Trans Retinoic acid (ATRA) (Table 7)*

ATRA is a metabolite of vitamin A which mediates development of a healthy ocular surface. A 0.01% topical preparation was reported to be useful in one case that had not responded to two IFN injections two months apart followed by IFN 1 Million IU/ml four time daily topical use for a further three months. After a combined approach of IFN four times daily and ATRA applied every second day for a month the tumour resolved without recurrence.

### *Anti-vascular endothelial growth factor (anti-VEGF) (Table 8)*

Anti-VEGF agents interfere with growth of blood vessels into tumours hence cutting off their blood supply and nutrition. They may be used alone before surgical excision topically or as injections. Used alone recurrences were zero to 20% and with surgery zero to 25%.

### *Radiotherapy (Table 9)*

Brachytherapy plaques are used to deliver radiation to the tumours. This is often used after surgical excision. In Kenya's Kenyatta National Hospital, radiotherapy is used after exenteration but no results have been reported. The source of radiation may be Strontium-90 or Ruthenium-105. Recurrences vary from zero at one year to 13.2% after 39 months.

### *Others (Table 10)*

Thermotherapy, Aloe vera, photodynamic therapy and Urea have been used but these were usually single case reports. Urea was associated with a 22% recurrence after use by nine patients.

## **Discussion**

A wide variety of treatments are used for OSSN. Some adjuvant treatments are combined with surgery and some are not. Some adjuvants are used intraoperatively and others post operatively. Varying doses of adjuvant agents used for varying durations. Inclusion criteria of patients differ and potentially different disease phenotypes may be present in different regions. Recurrences are reported at varying periods after treatment. A number of series reported recurrences as a whole group despite various combinations of intervention being used.

There was a trend where radiotherapy was used in earlier years then surgery was introduced and afterwards non-invasive topical treatments became popular, initially with cytotoxic agents and later with biological agents such as immune modulators and retinoic acid. 5FU was often used initially then MMC was introduced with no clear rationale why 5FU somehow fell out of favour. It is unclear whether this was because it is not registered by the FDA as a topical medication.

Surgery with adjuvant 5FU or MMC was often associated with recurrences of 11% to 67% about 30 months later. Few series reported the adverse effects of surgery. Series that used topical agents primarily without surgery did not have histopathology while one used impression cytology before starting treatment. Treating OSSN without a histopathology report is a problem because the true diagnosis is not established and factors that may influence recurrence such as surgical margin involvement during excision are not known.

The cost of interferon is prohibitive and would not be an option for East Africa. Availability of cryotherapy and agents like mitomycin C is uncommon. 5FU is the most readily available of the adjuvant agents used in OSSN treatment. 5FU does not have stringent storage conditions

such as refrigeration and cytotoxics have a low risk of contamination. 5FU is on the WHO essential medicines list, and is a widely available and low cost option particularly in sub-Saharan Africa where the highest incidence of OSSN in the world is found.

In conclusion, the results from case series are difficult to compare. As most modes of treatment such as cryotherapy, amniotic membrane transplants and MMC are unavailable in most centres in East Africa, we believe that a randomized controlled trial using 5FU is warranted. Availability of 5FU would make translation of these trial results into clinical practice feasible.

**Tabulated summary of the review of interventions used in ocular surface squamous neoplasia (OSSN). This will be a published supplement to the randomized controlled trial reported in Chapter 12.**

**Table 1: Surgery ± Cryotherapy**

Year	Country	Study size	Average age (years)	M:F ratio	Intervention	Recurrence
2015	Tunisia <sup>1</sup>	79	61.1	2.56:1	excision 89.8%; margin excision + cryotherapy 46.6%; enucleation 2.5%; exenteration 6.4%	33.3% after 9 months
2015	USA <sup>2</sup>	43	68.4	7:3	excision + cryotherapy. Alcohol epitheliectomy for corneal extension. At surgeon's discretion AMT with sutures or glue	7.1% after 1year
2014	Germany <sup>3</sup>	38	70.6	1.4:1	excision (n=25). If complete excision was not feasible adjuvant IFN was used (n=14) applied one drop 5 times daily for 6 weeks. If the tumour invaded deep orbital structures exenteration was done (n=10)	52% of excisions and 20% of exenterations. Average time to recurrence 24 months
2014	USA <sup>4</sup>	98	64.0	1:1	excision alone (n=49) ; excision + cryotherapy (n=41) or intraoperative MMC (n=1) or sclerectomy (n=8) + AMT (n=14) or conjunctival autograft (n=1) or primary closure (n=10) or bare sclera (n=24) vs IFN drops (n=40)or subconj/perilesion IFN injection (n=1) or combined drops+injection (n=8). The dose was 3 million IU (in 0.5 ml) in all cases treated with subconjunctival injections. For topical therapy, the dose was 1 million IU/ml in 35 patients and 3 million IU/ml in 13 patients.	1% in the surgery group and 3% in the IFN group after 1yr
2013	Argentina <sup>5</sup>	4	53.2	1:1	excision + cryotherapy and primary closure	None after 6.5 years
2012	Iran <sup>6</sup>	17	70.7	7.5:1	excision + cryotherapy then Chloramphenicol/Betamethasone drops QID x 1wk; then MMC 0.04% x7-10 days;	5.9% after 9 months
2006	Uganda <sup>7</sup>	476	32.0	1:1.2	401 had eye-conserving excision, lamellar sclerectomy if deeply fixed, corneal dissection with a blade then wiped with alcohol, primary closure. No cryotherapy.	13 of the 401 (3.2%) after median follow up of 32 months
2003	Turkey <sup>8</sup>	57	55.0	1.9:1	excision + cryotherapy before and after the excision	12.3% after 31.7 months median follow up
2002	Mexico <sup>9</sup>	287	60.4	1.2:1	Local resection in 258 cases (90%), exenteration in 18 (6%), enucleation in 7 (2%) and radiation therapy in 2 (1%). One patient was treated with	5.2% after 7.7 months median follow up



					local resection and gamma irradiation, and another with local resection and application of cryotherapy at the surgical margins	
2002	India <sup>10</sup>	5	?	?	Excision + cryotherapy + MMC	None at 1 year
2002	Australia <sup>11</sup>	26	65.1	3.3:1	Excision± cryotherapy (n=19), exenteration (n=6)	27% within 4-15 months
2000	USA <sup>12</sup>	28	66.6	4:1	19 had Excision alone (E) and 9 had excision+cryotherapy (E+C)	overall 5 (17.9%) recurred. 2 in the E+C and 3 in the E group. Mean follow up was 13months for primary lesions and 28months for recurrent lesions
1999	USA <sup>13</sup>	60	64.0	2.3:1	27excision+cryotherapy ; 14 excision+cryotherapy+sclerectomy; 8 excision+cryotherapy+mucosal graft; 1 exenteration; 1 enucleation	5% after a median of 56 months follow up
1997	Australia <sup>14</sup>	79	64.1	5:1	Excision	39% (31 eyes) overall recurred after a mean 4.6 years follow up
1989	Turkey <sup>15</sup>	22	?		Excision + cryotherapy before and after excision	9% (time point unclear)
1983	USA <sup>16</sup>	9	71.0	2:1	Excision + cryotherapy	22% after 9 months

**Table 2. Surgery with amniotic membrane transplant (AMT)**

Year	Country	Study size	age (years)	M:F ratio	Intervention	Recurrence
2014	Turkey <sup>17</sup>	21	62.4	1:2	AMT. no touch excision with 2mm margin + double freeze-thaw cryotherapy for 3 sec ± Alcohol epitheliectomy for corneal extension. The conjunctival defects were reconstructed up to the limbus with one sheet of Cryotherapy-preserved single layer AMT—the stromal side facing down—secured side to side with 8/0 vicryl sutures	None after 31 months follow up
2011	Lithuania <sup>18</sup>	2			AMT	None after 38 months follow up

2008	Brazil <sup>19</sup>	8			AMT	1 (12.5%)recurred after 17.8 months mean follow up
2003	Taiwan <sup>20</sup>	5	64.6	3:2	excised with 3mm margin + AMT with basement membrane facing up.	None after mean 27 months follow up
2002	USA <sup>21</sup>	10	58.6		excised with a 3–4 mm lesion free margin and a superficial keratectomy was performed if there was corneal infiltration. AMT was placed over the surgical defect with the basement membrane side facing up and secured to the adjacent conjunctiva and episclera by interrupted or continuous 10-0 Vicryl sutures, making sure that its borders were placed under the conjunctival margin.	1 case (10%) with follow up period unclear

**Table 3. Immune-therapy with Interferon  $\alpha$  2b (IFN $\alpha$ 2b)**

Year	Country	Study size	age (years)	M:F ratio	intervention	Recurrence at median/mean follow up	Adverse effects
2014	Iran <sup>22</sup>	5	60.2	4:1	IFN $\alpha$ 2b 3 million IU/ml QID x 4wks	None after median follow up 10.2 months	No patient developed persistent epithelial defect, symblepharon, limbal stem deficiency or systemic adverse effects related to IFN $\alpha$ 2b therapy such as malaise, flu like symptoms, bone pain and fatigue.
2013	USA <sup>23</sup>	81	?	?	IFN $\alpha$ 2b alone (n = 22, 27%) or combined with surgery (n = 59, 73%)	5% (4/81) of cases over a median follow-up of 1 year	Conjunctival hyperaemia (n = 4, 5%), ocular irritation (n = 3, 4%), superficial punctate keratitis (n = 3, 4%), conjunctival follicles (n = 1, 1%). Systemic side effects included post injection flu-like syndrome for 1 day (n = 7, 9%).
2012	Australia <sup>24</sup>	116	?	?	27 had IFN $\alpha$ 2b alone and 89 had combined IFN $\alpha$ 2b + retinoic acid 0.01%. Patients were prescribed	3.7% in the IFN alone 2.25% with combined treatment.	Four patients with complete response developed a mild allergic papillary conjunctivitis that settled

					IFN $\alpha$ 2b drops 1 MIU/ml 4 times daily and retinoic acid 0.01% once every second day.		on halving the interferon dose to 0.5 million IU drops and reducing the frequency to 3 times daily. Side effects were limited to 1 case of epithelial microcysts and 1 case of marginal keratitis.
2012	USA <sup>25</sup>	18	68.0	1.3:1	1 drop of 1 MIU/ml IFN $\alpha$ 2b QID or subconjunctival 10 MIU/ml of recombinant IFN injected till the lesion ballooned	None after mean 11 months follow up	Transient flu-like symptoms after IFN $\alpha$ 2b injection (n=3). Corneal epithelial defect after 4 months of using topical IFN $\alpha$ 2b (n=2) and Conjunctival hyperaemia (n=1). All symptoms resolved with conservative measures (e.g., acetaminophen, artificial tears, and ointments)
2012	USA <sup>26</sup>	20	63.0	2.3:1	Topical IFN $\alpha$ 2b 1 million IU/mL QID continued at least 1 month beyond complete clinical resolution	5% (1 case) at 3 months follow up	Conjunctival hyperaemia (2 [10%]), follicular hypertrophy (2 [10%]), giant papillary conjunctivitis (1 [5%]), irritation (1 [5%]), corneal epithelial defect (1 [5%]), and flu-like symptoms (1 [5%]); all resolved within 1 month of medication discontinuation.
2011	USA <sup>27</sup>	3	41.0	2:1	IFN $\alpha$ 2b drops (1 million units/cc) QID and IFN $\alpha$ 2b sublesional injection (5 million units/0.5cc to 8 million units/0.8 cc)	None at 3,6, 69 months respectively	nausea and chills were minor, lasting 1 day
2010	USA <sup>28</sup>	15	64.0	2:1	Thrice weekly perilesional /subconjunctival 3 MIU of recombinant IFN $\alpha$ 2b in 0.5 ml of solution. Ten eyes received concomitant topical interferon therapy 4 times daily in addition to the injections. Later the injection regime was changed to	6.7% (1 eye of 15) recurred 4 months after clinical resolution	Patients were given 1000 mg acetaminophen after the injection and every 4 hours as needed to help ameliorate flulike symptoms associated with interferon injections.

					received weekly until clinical disease resolution		
2010	USA <sup>29</sup>	3	63.7	All males	pegylated IFN $\alpha$ 2 $\beta$ subconjunctival/perilesion injection of 1 $\mu$ g/kg in the area of the lesion	1 (33.3%) recurrence after 7 months follow up	No adverse effects. Acetaminophen 1000mg was given to prevent flu-like symptoms.
2010	USA <sup>30</sup>	33	64.4	1:2	IFN $\alpha$ 2b drops (1 million international units (IU)/ml vs 3 million IU/ml) for 1 month after excision	9% (3 eyes) 20,21 & 28 months later	discomfort and photophobia
2008	USA <sup>31</sup>	29	66.7	13:1	IFN $\alpha$ 2b drops vs no touch excision + cryotherapy and 8 had AMT too. 10 received IFN $\alpha$ 2b 1 million IU/ml and 4 received 2 million U/ml, all 4 times per day, and 1 received 3 million IU/ml thrice daily. Those whose lesion failed to regress within 2 months of therapy crossed over to surgery. IFN $\alpha$ 2b was continued until 4 months after clinical resolution	None at 35.6 months	Not described
2006	Australia <sup>32</sup>	10	73.4	2:1	topical IFN- $\alpha$ 2b (1 million IU/ml) four times a day until clinical resolution of the lesion or until the lesion appeared nonresponsive	None at 55 weeks follow up	Not described
2006	Australia <sup>33</sup>	3	69.3	1:2	IFN $\alpha$ 2b 3Mill IU/ml every 3 days for 7 doses	None after 22.7 months follow up	Not described
2005	USA <sup>34</sup>	2	69.0	All males	IFN $\alpha$ 2b drops 1 million units/ml) QID	None after 3 and 6 months follow up respectively	Not described
2004	USA <sup>35</sup>	7	68.7	6:1	recombinant topical IFN $\alpha$ 2b drops (1 million IU/ml) 4 times daily until lesion resolution noted	2 (33.3%) patients had another recurrence of	Not described

						noted at 1 year and 2 months, respectively.	
2002	Japan <sup>36</sup>	1	73.0	Female	subconj IFN $\alpha$ 2b x2 then drops for 12wks (cryotherapy had been done twice before and failed)		Not described
1999	USA <sup>37</sup>	6	64.3	2:1	single subconjunctival/perilesional injection of 3 MIU/ml recombinant IFN $\alpha$ 2b in 0.5 ml and then IFN $\alpha$ 2b drops (1 MIU/ml) four times a day	None after 7.2 months follow up	Not described
1976	USA <sup>38</sup>	1	24	Male	dinitrochlorobenzene (DNCB). Initial sensitization with topical DNCB 2000 $\mu$ g on volar aspect of forearm. Then 30-50 $\mu$ L of DNCB 2mg/ml solution in acetone applied to the tumour surface. Repeated topical treatment a week later for 5 cycles	None after 3 years follow up	Not described

**Table 4. Immune-therapy with cyclosporin A (CSA)**

Year	Country	Study size	age (years)	M:F ratio	intervention	Recurrence	Adverse effects
2009	Egypt <sup>39</sup>	10	65.0	2:1	wide surgical excision + topical cyclosporine A (0.05%) and topical mitomycin C (0.01%) QID x 12 weeks after surgery	None after a mean 2 years follow up	Epithelial toxicity (punctate keratopathy) occurred in 3 eyes, ocular irritation and mild conjunctival hyperemia in 5 eyes, and lid toxicity in 2 cases during the treatment with mitomycin C
2006	Turkey <sup>40</sup>	2	65.0	All male	Combined CSA and MMC. CSA (0.05%) ophthalmic emulsion QID	None after 18 months follow up	In this study they lowered the concentration of MMC to 0.01%

					for 12 weeks, and topical MMC (0.01%) QID was combined with CSA at the second, fourth, and sixth weeks		and combined it with CSA to prevent potential ocular surface side effects
--	--	--	--	--	--	--	---

**Table 5. Chemotherapy with mitomycin C (MMC)**

Year	Country	Study size	age (years)	M:F ratio	intervention	Recurrence	Adverse effects
2014	Australia <sup>41</sup>	135	69.0	3.5:1	MMC 0.04% 4 times daily for 1 week, followed by 3 weeks off treatment. IFN $\alpha$ 2b 1 MIU/mL 4 times daily if previous treatment with MMC had failed or unable to tolerate MMC due to side effects. Again, this treatment was continued until an end point was reached. Endpoint was resolution or failure.	Overall 19 (14.1%) recurred. The mean time to recurrence was 17.2 months (range, 4 to 61 months). 14 recurrences (15.1%) were in patients treated only with MMC (n = 93), 4 recurrences (20.0%) were in patients treated with both MMC and IFN $\alpha$ 2b (n=20), and only 1 recurrence (4.6%) was in patients treated only with IFN $\alpha$ 2b (n= 22).	Adverse effects occurred in 76 (58.9%) patients using MMC and in 14 (30.4%) patients using IFN $\alpha$ 2b. The most common were conjunctival hyperemia or irritation (MMC, n=63 [48.8%]; IFN, n=13 28.2%), localized allergic or toxic reactions (defined as papillary conjunctivitis, lid swelling, or both; MMC, n = 12 [9.3%]) and punctal stenosis (MMC, n = 7 [5.4%]). There was one case of corneal erosion in each of the MMC and IFN groups. Patients occasionally had more than 1 adverse effect. There were no cases of limbal stem cell deficiency identified. Most side effects were mild and were tolerated by patients. Side effects significant enough to result in cessation of treatment before clinical resolution occurred in 12 (8.4%) of 143 eyes; all

							were with MMC.
2012	Turkey <sup>42</sup>	28	64.5	7:3	combined excision, cryotherapy, and intraoperative mitomycin-C (EXCRIM) using adjuvant 0.02 % mitomycin-C (MMC)	0% over mean 49months	7 (21 %) had delayed epithelial healing. Two of eight patients (25 %) with squamous cell carcinoma (SCC) had positive lateral margins.
2011	USA <sup>43</sup>	32	70.3	4:1	Excision vs Excision + MMC. intraoperative MMC use involved applying a Weck cel sponge soaked with either 0.02% or 0.04% MMC to the subconjunctival surface at the edge of the surgical excision for 1–3 minutes. Postoperatively, 1 drop of topical MMC 0.02% was given TID for 2 weeks. In most cases, 3 cycles of 2 weeks on and 2 weeks off were used with a punctal plug inserted before treatment	66.7% for excision alone, 7.7% for excision + MMC after a mean of 31.7 months follow up	Discomfort during the 2 <sup>nd</sup> or 3 <sup>rd</sup> treatment cycle occurred in all patients
2010	Australia <sup>44</sup>	91	66.0	3:1	Excision + cryotherapy then MMC 0.04% (0.4 mg/ml) four times a day was used on a week-on week-off basis for two to three cycles (one cycle of treatment=1 week on+one week off)	12.5% after a mean 56.8 months follow up	A localised allergic reaction was seen in 23% of patients during the second or third cycle of treatment but settled rapidly on cessation of treatment in all. Of these patients, one developed a secondary levator disinsertion ptosis requiring surgical correction. 15% of patients developed epiphora, most of which settled following simple syringing of the involved nasolacrimal system. Two patients with diffuse disease developed a corneal epithelial defect but no stromal melt. There were no incidences of severe complications

							such as hypotony, corneo-scleral melt or limbal stem cell failure.
2010	UK <sup>45</sup>	24	63.0	?	MMC as primary treatment or surgical adjuvant. 0.04% MMC four times a day for 3 weeks on, 3 weeks off, 3 weeks on, with topical steroid and lubricants throughout	67% after a mean 50 months of follow up	hyperemia, allergy, epiphora, discharge, mild keratoconjunctivitis, uveitis, corneal abrasion, corneal oedema, pyogenic granuloma, nose bleed. The most common short term complication was allergy, 64% of which occurred in the second 3-week cycle. The most common long term complication was continuing mild keratoconjunctivitis
2009	Iran <sup>46</sup>	17	58.7	2.4:1	2-3 alternate 7-day courses of 0.04% mitomycin-C in artificial tears. 14 patients (82.4%) received 2 courses of MMC one week apart, and only 3 patients (17.6%) received 3 MMC courses	5 (29.4%) recurrences over a mean follow up of 30.8 months	All patients reported some degrees of mild to moderate eye redness and irritation that were controlled by artificial tear, mild corticosteroid drops, and warm compress. There were no cases of scleral melting or any systemic complications
2006	Spain <sup>47</sup>	1	82.0	Female	Short term MMC 0.02% (2 cycles) followed by long term interferon 1 MIU/ml QID until tumour disappearance (took 75 days to disappear)	None after 1 year	no clinical evidence of limbal stem cell deficiency
2004	USA <sup>48</sup>	1	52.0	Female	0.02% MMC for 14 days in the first cycle, 12 days in the second cycle, and 3 days in the third cycle followed by topical interferon alfa-2b 1 x 10 <sup>6</sup> U/mL for 11 days due to intolerance to MMC.	Resolution lasted 10 months. Recurrence not explicitly mentioned in	Not described
2004	Australia <sup>49</sup>	27	64.0	2.7:1	excised with 2mm margin + cryotherapy (where available) +	None after 27 months mean follow up	5 patients developed granuloma following excision of OSSN, all of



					Chloramphenicol and Prednefrine Forte eye drops four times daily until wound healing + at least two 1 week courses of topical MMC 0.04% four times a day, after complete epithelial healing. Each course was followed by 1 week free of MMC		which resolved rapidly with continued topical steroid treatment. Eight patients received two courses because of allergy to MMC with redness, swelling, and significant itching, which developed late in the second course. All MMC allergy symptoms resolved rapidly following discontinuation of treatment.
2002	USA <sup>50</sup>	10	66.0	2:3:1	Mitomycin C 0.04% four times daily was applied for a median of three cycles	None after a median 15 months follow up	temporary local irritation, erythema, chemosis
2002	Israel <sup>51</sup>	5	58.4	2:3	MMC, 0.02% or 0.04%, four times daily for 14 days. Second and third identical cycles of MMC were applied at 3- to 4-week intervals. Wide excision of the conjunctiva was done 4 to 6 weeks after the final cycle of MMC	None after a mean 23.8 months follow up	1 case of conjunctival hyperaemia seen from day 8
2002	Greece <sup>52</sup>	7	73.8	3:4	During excision of the lesion, mitomycin-C 0.02% was applied intraoperatively for 5 minutes. In two cases, excision was combined with conjunctival limbal autograft	14% ( n=1) after a mean of 16 months follow up	Not described
2002	UK <sup>53</sup>	11	66.7	2:9	Preoperative topical and intraoperative local mitomycin C. MMC 0.04% eye drops QID in two weekly courses preoperatively and/or a single intraoperative application of 0.4 mg/ml. 7 patients had additional limited local excision of the residual	None after a mean of 9.5 months follow up	1 developed a reaction to the drops during the second fortnightly course of MMC drops but treatment was continued under steroid cover. 1 persistent epithelial defect following both courses of topical mitomycin C drops

					tumour mass and 1 had cryotherapy.		
2001	Germany <sup>54</sup>	9	?	?	mitomycin C eye drops 0.02% (MMC) after excision	11% (1 patient) 14 months after surgery and after 2 MMC-cycles.	self-limited conjunctivitis
1999	USA <sup>55</sup>	4	?	?	MMC 0.02% TID x2wk	None after a mean of 20 months follow up	mild discomfort, redness, photophobia, and punctate epithelial keratopathy that subsided on discontinuation of the medication
1997	UK <sup>56</sup>	7	?	?	one drop of MMC 0.04% QID for 7 days in alternate weeks	None after 9 months follow up	transitory ocular discomfort, conjunctival injection, tearing, photophobia, and punctate epithelial keratopathy

**Table 6. Chemotherapy with 5-Fluorouracil (5FU)**

Year	Country	Study size	age (years)	M:F ratio	intervention	Recurrence	Adverse effects
2015	Australia <sup>57</sup>	38	70.0	6:1	1% 5FU in N/saline QIDx 2wks or 0.04% MMC in N/saline x2-3 cycles each cycle lasting 1 wk followed by 1 wk drug holiday. Some pts had excision with a 2mm margin + cryotherapy	31% (10 patients) required further treatment for disease persistence or recurrence; 7 on MMC and 3 on 5FU	5-FU 1% resulted in drug-related complications in seven of 12 cases (58.3%), and included a single case of focal paracentral corneal stromal melt. MMC 0.04% resulted in transient drug related complications in 23 of 39 (59%) cases
2014	Australia <sup>58</sup>	153	65.5	7:3	89 on 5FU 1% QID x 2 wks and 64 on MMC 0.04% QID for 2-3 1-week cycles.	2% (n=) 2 on 5FU; 0 on MMC. Mean follow up 33.6months on 5FU and 57.9months on MMC	Not described

2011	Australia <sup>59</sup>	65	66.3	3:1	a single cycle of 5FU 1% in N/saline QID x 2wk	1.5% (1 case) after a median follow up 23 months	37 (57%) patients had short-term complications. Lid toxicity 32 (49.2%); epiphora 5 (7.7%); superficial keratitis 6 (9.2%); corneal epithelial defect 1 (1.5%); ectropion 1 (1.5%). Four patients were unable to complete the course of 5-FU 1% because of local toxicity
2011	Italy <sup>60</sup>	41	65.5	1.7:1	1% 5-FU QID x4 weeks (one course). 22 patients (53.7%) had 5-FU as a sole treatment, and 19 patients (46.3%) as adjuvant and/or debulking therapy	7.3% (3 tumours) treated with 5-FU alone recurred during a follow-up of 89.7 months	Clinical confocal microscopy showed no long-term difference between the treated eye and fellow (control) eye in: endothelial cells count, pleomorphism and polymegathism, anterior stromal keratocyte density, sub-basal nerve plexus fibre number, density, and beadings and central cornea epithelium thickness
2010	Yemen <sup>61</sup>	15	50.8	1:4	subconjunctival 5FU (5mg) at the end of surgery + 1% 5-FU eye drops QID x 4days then repeated at 30 day intervals x6 cycles. All had 6 months therapy	1/15 (6.7%) recurred	mild temporary local irritation
2000	USA <sup>62</sup>	7	74.0	All male	1% 5-FU in methylcellulose was administered four times daily for 2 to 4 days for each cycle. The number of initial treatment cycles was two to six, with the time between cycles being 30 to 45 days.	3 recurrences (43%)	No adverse effects noted
2000	Italy <sup>63</sup>	8	70.0	3:1	1% 5FU drops alone QID x4wks without surgery or radiotherapy	1 patient (12.5%) with a mean 27 months follow up	Acute transient toxic keratoconjunctivitis was observed in all treated cases; it was controlled with topical therapy.

1995	USA <sup>64</sup>	6	61·0	2:1	excision +5FU or 5FU alone	1 recurred (16·6%) after 30 months	Punctate epithelial keratopathy, epithelial defect
------	-------------------	---	------	-----	----------------------------	------------------------------------	--

**Table 7. Retinoic acid**

Year	Country	Study size	age (years)	M:F ratio	intervention	Recurrence	Adverse effects
2010	Australia <sup>65</sup>	1	64·0	Female	topical all-trans retinoic acid (ATRA), 0·01%, 1 eyedrop applied every second day x9mo. After there was no response from 2 intralesional injections of 3 Mill IU of recombinant IFN in 0·5 mL, 2 months apart, followed by topical interferon alfa-2b (1 Mill IU/mL) 4 times a day.	No recurrence	Not described

**Table 8. Anti-vascular endothelial growth factor (VEGF)**

Year	Country	Study size	age (years)	M:F ratio	intervention	Recurrence	Adverse effects
2015	Turkey <sup>66</sup>	6	66	2:1	topical 5mg/mL bevacizumab QID x 8 weeks	None after 6 months follow up	Not described
2014	Turkey <sup>67</sup>	10	60·5		bevacizumab (Avastin) 25mg/ml x 7·8wks (range 5-14) then excision biopsy+cryo+AMT	None after 6 months follow up	Not described
2009	Egypt <sup>68</sup>	10	45·0	2:1	subconj Avastin (bevacizumab)	20% after 12 months follow up	Not described
2009	USA <sup>69</sup>	4	51·5	?	Subconjunctival injections of ranibizumab 0·5 mg were given every 2 or 4 weeks if the tumour regressed or remained stable.	1 recurred (25%) and 1 did not regress (25%)	No adverse ranibizumab-related ocular or systemic side effects. Specifically, there were no local or systemic allergies and no corneal

							epitheliopathy, perforation, conjunctival hyperaemia, scleral thinning, uveitis or cataract formation.
--	--	--	--	--	--	--	--

**Table 9. Radiotherapy, Thermotherapy**

Year	Country	Study size	age (years)	M:F ratio	intervention	Recurrence	Adverse effects
2015	S. Africa <sup>70</sup>	69	42.0	1:1	60 Gray Sr-90 brachytherapy in four divided doses after resection with a 2 mm margin. No cryotherapy or alcohol debridement	8 (11.6%) after a median 27 months follow up	Five patients developed a dry eye, which was treated with ocular lubricants
2011	Spain <sup>71</sup>	1	61.0	Male	Orthovoltage was administered with direct field radiation focused on the tumor. The patient received 500 cGy in 2 sessions/week for 2 weeks (2000 cGy) and then 7 sessions 300 cGy daily (2100 cGy).	No recurrence after 1 year follow up	Not described
2009	France <sup>72</sup>	15	63.7	4:1	proton beam therapy and surgery	2 patients (13.2%). Mean follow-up was 39.1 months	Not described
2009	Australia <sup>73</sup>	11	60.8	1:3.7	Plaque brachytherapy. A 10- 15-mm-diameter circular Iodine-125 plaque was applied under assisted local or general anaesthesia during surgery (excised with histological confirmation using a technique involving minimal lateral clearance and avoidance of deep scleral dissection)	None after 23.4 months mean follow up	Not described

1995	Germany <sup>74</sup>	2	58-5	All male	Brachytherapy with Ruthenium 105-applicator for radiation (after prior surgery). The applicator was fixed to the sclera adjacent to the corneal limbus. A 100 Gy radiation dose was delivered with 2mm tissue penetration.	None after 2 years follow up	Not described
1993	Austria <sup>75</sup>	1			local excision and brachytherapy with ruthenium-106. A total dose of 320 Gy was delivered to the tumour bed	None after 22 months	Not described
1990	Spain <sup>76</sup>	12			strontium-90 source on cup-shaped applicators of different sizes according to the extension of the tumor. Surface dose ranged from 60 Gy in a single treatment to 140 Gy in 7 fractions, depending on the thickness of the lesion.	1 (8.3%) recurred in a follow up period ranging from 2-15 years	Cataracts
1988	Australia <sup>77</sup>	146			123 were treated with a strontium-90 source, 10 with a radon "ring," and 7 with superficial X ray therapy. of the 123, 107 received 30 Gy, 14 received 40 Gy (pre 1960) and one patient each received 20 and 25 Gy incident dose	3 (2.3%) developed local recurrence	complications were very uncommon. 3 patients developed unsightly conjunctival telangiectasia, 2 patients developed a persistent scleral ulcer and 2 patients developed clinically significant cataracts.

**Table 10. Others**

Year	Country	Study size	age (years)	M:F ratio	intervention	Recurrence	Adverse effects
------	---------	------------	-------------	-----------	--------------	------------	-----------------

2015	USA <sup>78</sup>	1	64·0	Female	<i>Aloe vera</i> drops TID	None	Not described
2004	USA <sup>79</sup>	3	70·7	2:1	<i>Photodynamic therapy</i> 1-3 treatments of verteporfin (6 mg/m <sup>2</sup> body surface area, intravenously). All tumours irradiated 1 min after injection using a diode laser with an emission wavelength of 695 nm, applying a light dose of 50 J/cm <sup>2</sup> .	None after 8·6 months follow up	minimal temporary local irritation in two patients, and small conjunctival haemorrhages and mild transient chemosis in the three eyes directly after treatment. One patient had infusion-related back pain.
2002	USA <sup>80</sup>	1	52·0	Female	<i>Cidofovir drops</i> 6-week course of cidofovir eyedrops (2·5 mg/ml) one drop q2h x2wk then QIDx2wk then TID x2wk	None after 24 months follow up	Not described
1979	Greece <sup>81</sup>	9			<i>Urea</i> local application	22%	Not described

We included studies that reported recurrence as an outcome.

MIU- million international units

? means unreported or unclear

## References

1. Chebbi A, Bouguila H, Boukari M, et al. [Prognosis of primary malignant tumors of the conjunctiva]. *Journal francais d'ophtalmologie* 2015; **38**(6): 477-85.
2. Li AS, Shih CY, Rosen L, Steiner A, Milman T, Udell IJ. Recurrence of Ocular Surface Squamous Neoplasia Treated With Excisional Biopsy and Cryotherapy. *American journal of ophthalmology* 2015; **160**(2): 213-9 e1.
3. Miller CV, Wolf A, Klingenstein A, et al. Clinical outcome of advanced squamous cell carcinoma of the conjunctiva. *Eye (Lond)* 2014; **28**(8): 962-7.
4. Nanji AA, Moon CS, Galor A, Sein J, Oellers P, Karp CL. Surgical versus medical treatment of ocular surface squamous neoplasia: a comparison of recurrences and complications. *Ophthalmology* 2014; **121**(5): 994-1000.
5. Crim N, Fornies-Paz ME, Monti R, Esposito E, Maccio JP, Urrets-Zavalía JA. In situ carcinoma of the conjunctiva: surgical excision associated with cryotherapy. *Clinical ophthalmology (Auckland, NZ)* 2013; **7**: 1889-93.
6. Kashkouli MB, Heirati A, Pakdel F, Kiavash V, Naseripour M, Aghamohammadi F. Long-term follow-up of invasive ocular surface squamous cell carcinoma treated with excision, cryotherapy, and topical mitomycin C. *Graefes archive for clinical and experimental ophthalmology = Albrecht von Graefes Archiv fur klinische und experimentelle Ophthalmologie* 2012.
7. Waddell KM, Downing RG, Lucas SB, Newton R. Corneo-conjunctival carcinoma in Uganda. *Eye (Lond)* 2006; **20**(8): 893-9.
8. Peksayar G, Altan-Yaycioglu R, Onal S. Excision and cryosurgery in the treatment of conjunctival malignant epithelial tumours. *Eye (Lond)* 2003; **17**(2): 228-32.
9. Cervantes G, Rodriguez AA, Jr., Leal AG. Squamous cell carcinoma of the conjunctiva: clinicopathological features in 287 cases. *Canadian journal of ophthalmology Journal canadien d'ophtalmologie* 2002; **37**(1): 14-9; discussion 9-20.
10. Khokhar S, Soni A, SinghSethi H, Sudan R, Sony P, Pangtey MS. Combined surgery, cryotherapy, and mitomycin-C for recurrent ocular surface squamous neoplasia. *Cornea* 2002; **21**(2): 189-91.
11. McKelvie PA. Squamous cell carcinoma of the conjunctiva: a series of 26 cases. *British Journal of Ophthalmology* 2002; **86**(2): 168-73.
12. Sudesh S, Rapuano CJ, Cohen EJ, Eagle RC, Jr., Laibson PR. Surgical management of ocular surface squamous neoplasms: the experience from a cornea center. *Cornea* 2000; **19**(3): 278-83.
13. Tunc M, Char DH, Crawford B, Miller T. Intraepithelial and invasive squamous cell carcinoma of the conjunctiva: analysis of 60 cases. *British Journal of Ophthalmology* 1999; **83**(1): 98-103.
14. Tabin G, Levin S, Snibson G, Loughnan M, Taylor H. Late recurrences and the necessity for long-term follow-up in corneal and conjunctival intraepithelial neoplasia. *Ophthalmology* 1997; **104**(3): 485-92.
15. Peksayar G, Soy Turk MK, Demiryont M. Long-term results of cryotherapy on malignant epithelial tumors of the conjunctiva. *American journal of ophthalmology* 1989; **107**(4): 337-40.
16. Divine RD, Anderson RL. Nitrous oxide cryotherapy for intraepithelial epithelioma of the conjunctiva. *Archives of ophthalmology* 1983; **101**(5): 782-6.
17. Palamar M, Kaya E, Egrilmez S, Akalin T, Yagci A. Amniotic membrane transplantation in surgical management of ocular surface squamous neoplasias: long-term results. *Eye (Lond)* 2014; **28**(9): 1131-5.
18. Asoklis RS, Damijonaityte A, Butkiene L, et al. Ocular surface reconstruction using amniotic membrane following excision of conjunctival and limbal tumors. *European journal of ophthalmology* 2011; **21**(5): 552-8.
19. Carvalho-Rego PR, Gomes JA, Ballalai PL, Cunha MC, Sousa LB, Erwenne CM. [Amniotic membrane for ocular surface reconstruction after conjunctival squamous cell carcinoma resection]. *Arquivos brasileiros de oftalmologia* 2008; **71**(1): 22-7.



20. Yeh LK, Lin HC, Ma DH. Amniotic membrane grafts following excision of corneal and conjunctival intraepithelial neoplasia. *Chang Gung medical journal* 2003; **26**(10): 737-44.
21. Espana EM. Amniotic membrane transplantation for reconstruction after excision of large ocular surface neoplasias. *British Journal of Ophthalmology* 2002; **86**(6): 640-5.
22. Zarei-Ghanavati S, Alizadeh R, Deng SX. Topical interferon alpha-2b for treatment of noninvasive ocular surface squamous neoplasia with 360 degrees limbal involvement. *J Ophthalmic Vis Res* 2014; **9**(4): 423-6.
23. Shields CL, Kaliki S, Kim HJ, et al. Interferon for ocular surface squamous neoplasia in 81 cases: outcomes based on the American Joint Committee on Cancer classification. *Cornea* 2013; **32**(3): 248-56.
24. Krilis M, Tsang H, Coroneo M. Treatment of conjunctival and corneal epithelial neoplasia with retinoic acid and topical interferon alfa-2b: long-term follow-up. *Ophthalmology* 2012; **119**(10): 1969-73.
25. Kim HJ, Shields CL, Shah SU, Kaliki S, Lally SE. Giant ocular surface squamous neoplasia managed with interferon alpha-2b as immunotherapy or immunoreduction. *Ophthalmology* 2012; **119**(5): 938-44.
26. Shah SU, Kaliki S, Kim HJ, Lally SE, Shields JA, Shields CL. Topical interferon alfa-2b for management of ocular surface squamous neoplasia in 23 cases: outcomes based on american joint committee on cancer classification. *Archives of ophthalmology* 2012; **130**(2): 159-64.
27. Shields CL, Kancherla S, Bianciotto CG, Lally SE, Shields JA. Ocular surface squamous neoplasia (squamous cell carcinoma) of the socket: management of extensive tumors with interferon. *Ophthalmic plastic and reconstructive surgery* 2011; **27**(4): 247-50.
28. Karp CL, Galor A, Chhabra S, Barnes SD, Alfonso EC. Subconjunctival/perilesional recombinant interferon alpha2b for ocular surface squamous neoplasia: a 10-year review. *Ophthalmology* 2010; **117**(12): 2241-6.
29. Karp CL, Galor A, Lee Y, Yoo SH. Pegylated interferon alpha 2b for treatment of ocular surface squamous neoplasia: a pilot study. *Ocular immunology and inflammation* 2010; **18**(4): 254-60.
30. Galor A, Karp CL, Chhabra S, Barnes S, Alfonso EC. Topical interferon alpha 2b eye-drops for treatment of ocular surface squamous neoplasia: a dose comparison study. *The British journal of ophthalmology* 2010; **94**(5): 551-4.
31. Sturges A, Butt AL, Lai JE, Chodosh J. Topical interferon or surgical excision for the management of primary ocular surface squamous neoplasia. *Ophthalmology* 2008; **115**(8): 1297-302, 302 e1.
32. Holcombe DJ, Lee GA. Topical Interferon Alfa-2b for the Treatment of Recalcitrant Ocular Surface Squamous Neoplasia. *American journal of ophthalmology* 2006; **142**(4): 568-71.e3.
33. Nemet AY, Sharma V, Benger R. Interferon alpha 2b treatment for residual ocular surface squamous neoplasia unresponsive to excision, cryotherapy and mitomycin-C. *Clin Experiment Ophthalmol* 2006; **34**(4): 375-7.
34. Esquenazi S, Fry CL, Holley E. Treatment of biopsy proved conjunctival intraepithelial neoplasia with topical interferon alfa-2b. *The British journal of ophthalmology* 2005; **89**(9): 1221.
35. Boehm MD, Huang AJ. Treatment of recurrent corneal and conjunctival intraepithelial neoplasia with topical interferon alfa 2b. *Ophthalmology* 2004; **111**(9): 1755-61.
36. Kobayashi A, Yoshita T, Uchiyama K, et al. Successful management of conjunctival intraepithelial neoplasia by interferon alpha-2b. *Japanese journal of ophthalmology* 2002; **46**(2): 215-7.
37. Vann RR, Karp CL. Perilesional and topical interferon alfa-2b for conjunctival and corneal neoplasia1. *Ophthalmology* 1999; **106**(1): 91-7.
38. Ferry AP, Meltzer MA, Taub RN. Immunotherapy with dinitrochlorobenzene (DNCB) for recurrent squamous cell tumor of conjunctiva. *Transactions of the American Ophthalmological Society* 1976; **74**: 154-71.
39. Zaki AA, Farid SF. Management of intraepithelial and invasive neoplasia of the cornea and conjunctiva: a long-term follow up. *Cornea* 2009; **28**(9): 986-8.

40. Tunc M, Erbilgen E. Topical cyclosporine-a combined with mitomycin C for conjunctival and corneal squamous cell carcinoma. *American journal of ophthalmology* 2006; **142**(4): 673-5.
41. Besley J, Pappalardo J, Lee GA, Hirst LW, Vincent SJ. Risk factors for ocular surface squamous neoplasia recurrence after treatment with topical mitomycin C and interferon alpha-2b. *American journal of ophthalmology* 2014; **157**(2): 287-93 e2.
42. Sarici AM, Arvas S, Pazarli H. Combined excision, cryotherapy, and intraoperative mitomycin C (EXCRIM) for localized intraepithelial and squamous cell carcinoma of the conjunctiva. *Graefes archive for clinical and experimental ophthalmology = Albrecht von Graefes Archiv fur klinische und experimentelle Ophthalmologie* 2013; **251**(9): 2201-4.
43. Birkholz ES, Goins KM, Sutphin JE, Kitzmann AS, Wagoner MD. Treatment of ocular surface squamous cell intraepithelial neoplasia with and without mitomycin C. *Cornea* 2011; **30**(1): 37-41.
44. Gupta A, Muecke J. Treatment of ocular surface squamous neoplasia with Mitomycin C. *The British journal of ophthalmology* 2010; **94**(5): 555-8.
45. Russell HC, Chadha V, Lockington D, Kemp EG. Topical mitomycin C chemotherapy in the management of ocular surface neoplasia: a 10-year review of treatment outcomes and complications. *The British journal of ophthalmology* 2010; **94**(10): 1316-21.
46. Rahimi F, Alipour F, Ghazizadeh Hashemi H, Hashemian MN, Mehrdad R. Topical mitomycin-C for treatment of partially-excised ocular surface squamous neoplasia. *Archives of Iranian medicine* 2009; **12**(1): 55-9.
47. Huerva V, Mateo AJ, Mangues I, Jurjo C. Short-term mitomycin C followed by long-term interferon alpha2beta for conjunctiva-cornea intraepithelial neoplasia. *Cornea* 2006; **25**(10): 1220-3.
48. Di Pascuale MA, Espana EM, Tseng SC. A case of conjunctiva-cornea intraepithelial neoplasia successfully treated with topical mitomycin C and interferon alfa-2b in cycles. *Cornea* 2004; **23**(1): 89-92.
49. Chen C, Louis D, Dodd T, Muecke J. Mitomycin C as an adjunct in the treatment of localised ocular surface squamous neoplasia. *The British journal of ophthalmology* 2004; **88**(1): 17-8.
50. Shields CL, Naseripour M, Shields JA. Topical mitomycin C for extensive, recurrent conjunctival-corneal squamous cell carcinoma. *American journal of ophthalmology* 2002; **133**(5): 601-6.
51. Frucht-Pery J, Rozenman Y, Pe'er J. Topical mitomycin-C for partially excised conjunctival squamous cell carcinoma. *Ophthalmology* 2002; **109**(3): 548-52.
52. Siganos CS, Kozobolis VP, Christodoulakis EV. The intraoperative use of mitomycin-C in excision of ocular surface neoplasia with or without limbal autograft transplantation. *Cornea* 2002; **21**(1): 12-6.
53. Kemp EG, Harnett AN, Chatterjee S. Preoperative topical and intraoperative local mitomycin C adjuvant therapy in the management of ocular surface neoplasias. *The British journal of ophthalmology* 2002; **86**(1): 31-4.
54. Carlsburg O, Kersten A, Sundmacher R, Nadjari B, Pomjanski N, Bocking A. [Treatment of 9 squamous epithelial carcinoma in situ lesions of the conjunctiva (CIN) with mitomycin C eyedrops in cytological and DNA image cytometric control]. *Klinische Monatsblätter für Augenheilkunde* 2001; **218**(6): 429-34.
55. Akpek EK, Ertoy D, Kalayci D, Hasiripi H. Postoperative topical mitomycin C in conjunctival squamous cell neoplasia. *Cornea* 1999; **18**(1): 59-62.
56. Wilson MW, Hungerford JL, George SM, Madreperla SA. Topical mitomycin C for the treatment of conjunctival and corneal epithelial dysplasia and neoplasia. *American journal of ophthalmology* 1997; **124**(3): 303-11.
57. Rudkin AK, Dempster L, Muecke JS. Management of diffuse ocular surface squamous neoplasia: efficacy and complications of topical chemotherapy. *Clinical & Experimental Ophthalmology* 2015; **43**(1): 20-5.

58. Bahrami B, Greenwell T, Muecke JS. Long-term outcomes after adjunctive topical 5-fluorouracil or mitomycin C for the treatment of surgically excised, localized ocular surface squamous neoplasia. *Clin Experiment Ophthalmol* 2014; **42**(4): 317-22.
59. Rudkin AK, Muecke JS. Adjuvant 5-fluorouracil in the treatment of localised ocular surface squamous neoplasia. *The British journal of ophthalmology* 2011; **95**(7): 947-50.
60. Parrozzani R, Lazzarini D, Alemany-Rubio E, Urban F, Midea E. Topical 1% 5-fluorouracil in ocular surface squamous neoplasia: a long-term safety study. *The British journal of ophthalmology* 2011; **95**(3): 355-9.
61. Al-Barrag A, Al-Shaer M, Al-Matary N, Al-Hamdani M. 5-Fluorouracil for the treatment of intraepithelial neoplasia and squamous cell carcinoma of the conjunctiva, and cornea. *Clinical ophthalmology (Auckland, NZ)* 2010; **4**: 801-8.
62. Yeatts RP, Engelbrecht NE, Curry CD, Ford JG, Walter KA. 5-Fluorouracil for the treatment of intraepithelial neoplasia of the conjunctiva and cornea. *Ophthalmology* 2000; **107**(12): 2190-5.
63. Midea E. Treatment of conjunctival squamous cell carcinoma with topical 5-fluorouracil. *British Journal of Ophthalmology* 2000; **84**(3): 268-72.
64. Yeatts RP, Ford JG, Stanton CA, Reed JW. Topical 5-fluorouracil in treating epithelial neoplasia of the conjunctiva and cornea. *Ophthalmology* 1995; **102**(9): 1338-44.
65. Skippen B, Tsang HH, Assaad NN, Coroneo MT. Rapid response of refractory ocular surface dysplasia to combination treatment with topical all-trans retinoic acid and interferon alfa-2b. *Archives of ophthalmology* 2010; **128**(10): 1368-9.
66. Asena L, Dursun Altinors D. Topical Bevacizumab for the Treatment of Ocular Surface Squamous Neoplasia. *Journal of ocular pharmacology and therapeutics : the official journal of the Association for Ocular Pharmacology and Therapeutics* 2015.
67. Ozcan AA, Ciloglu E, Esen E, Simdivar GH. Use of topical bevacizumab for conjunctival intraepithelial neoplasia. *Cornea* 2014; **33**(11): 1205-9.
68. Zaki AA, Fouad H, Emera S, Labibi H. Subconjunctival Anti VEGF for Conjunctival Intraepithelial and Invasive Neoplasia. *Australian Journal of Basic and Applied Sciences*, 2009; **3**(4): 3186-9.
69. Teng CC, Chin KJ, Finger PT. Subconjunctival ranibizumab for squamous cell carcinoma of the conjunctiva with corneal extension. *The British journal of ophthalmology* 2009; **93**(6): 837-8.
70. Lecuona K, Stannard C, Hart G, et al. The treatment of carcinoma in situ and squamous cell carcinoma of the conjunctiva with fractionated strontium-90 radiation in a population with a high prevalence of HIV. *The British journal of ophthalmology* 2015; **99**(9): 1158-61.
71. Sanchez-Perez JL, Fuentes-Sanchez C, Acosta-Acosta B. Conjunctival-corneal intraepithelial neoplasia (Bowen disease) treated with orthovoltage. *Cornea* 2011; **30**(4): 474-6.
72. Caujolle JP, Maschi C, Chauvel P, Herault J, Gastaud P. [Surgery and additional protontherapy for treatment of invasive and recurrent squamous cell carcinomas: technique and preliminary results]. *Journal francais d'ophtalmologie* 2009; **32**(10): 707-14.
73. Walsh-Conway N, Conway RM. Plaque brachytherapy for the management of ocular surface malignancies with corneoscleral invasion. *Clin Experiment Ophthalmol* 2009; **37**(6): 577-83.
74. Haberle H, Pham DT, Scholman HJ, Wollensak J. [Ruthenium 105-applicator for radiation treatment of carcinoma in situ of the cornea and conjunctiva]. *Der Ophthalmologe : Zeitschrift der Deutschen Ophthalmologischen Gesellschaft* 1995; **92**(6): 866-9.
75. Zehetmayer M, Menapace R, Kulnig W. Combined local excision and brachytherapy with ruthenium-106 in the treatment of epibulbar malignancies. *Ophthalmologica Journal international d'ophtalmologie International journal of ophthalmology Zeitschrift fur Augenheilkunde* 1993; **207**(3): 133-9.
76. Cerezo L, Otero J, Aragon G, et al. Conjunctival intraepithelial and invasive squamous cell carcinomas treated with strontium-90. *Radiotherapy and oncology : journal of the European Society for Therapeutic Radiology and Oncology* 1990; **17**(3): 191-7.

77. Kearsley JH, Fitchew RS, Taylor RG. Adjunctive radiotherapy with strontium-90 in the treatment of conjunctival squamous cell carcinoma. *International journal of radiation oncology, biology, physics* 1988; **14**(3): 435-43.
78. Damani MR, Shah AR, Karp CL, Orlin SE. Treatment of ocular surface squamous neoplasia with topical Aloe vera drops. *Cornea* 2015; **34**(1): 87-9.
79. Barbazetto IA, Lee TC, Abramson DH. Treatment of conjunctival squamous cell carcinoma with photodynamic therapy. *American journal of ophthalmology* 2004; **138**(2): 183-9.
80. Sherman MD, Feldman KA, Farahmand SM, Margolis TP. Treatment of conjunctival squamous cell carcinoma with topical cidofovir. *American journal of ophthalmology* 2002; **134**(3): 432-3.
81. Danopoulos ED, Danopoulou IE, Liarikos SB, Merkuris KM. Effects of urea treatment in malignancies of the conjunctiva and cornea. *Ophthalmologica Journal international d'ophthalmologie International journal of ophthalmology Zeitschrift fur Augenheilkunde* 1979; **178**(4): 198-203.

# Chapter 5. Research setting

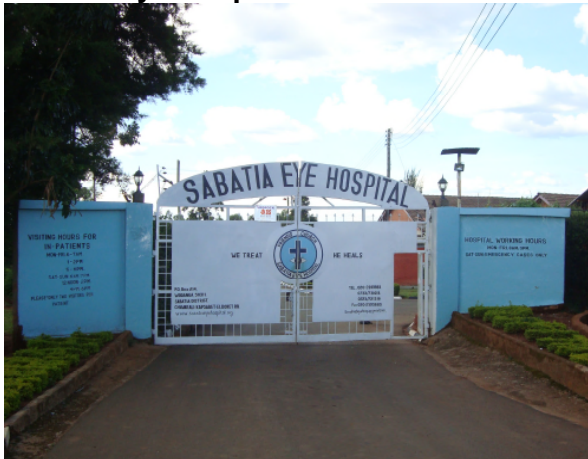**Kenyatta National Hospital**



**Kikuyu Eye Unit**



**Sabatia Eye Hospital**



**Kitale District Hospital**

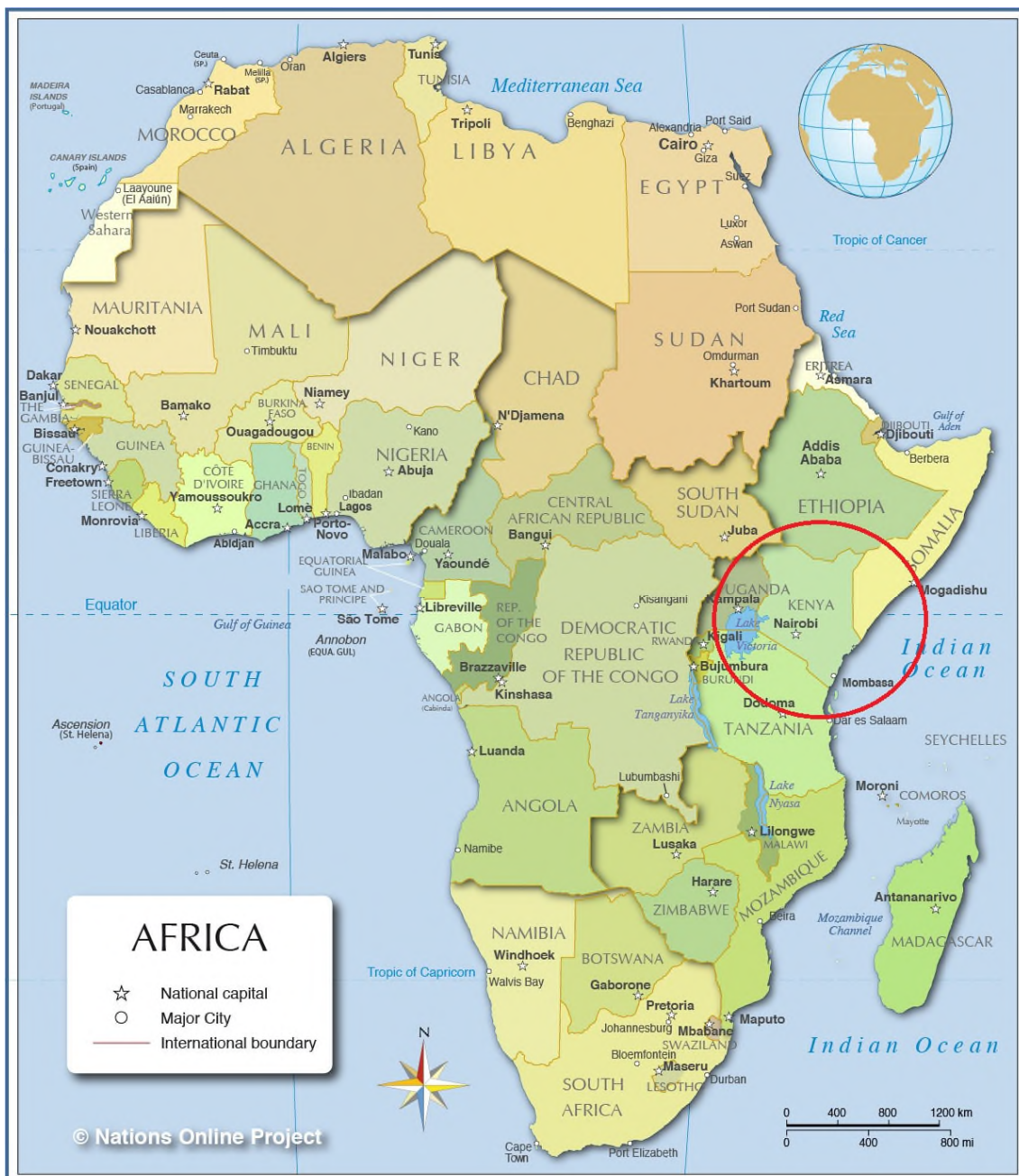

## Kenya – an introduction to the research setting

### 5.1 Geography of Kenya

Kenya sits astride the equator in East Africa (Figure 5.1). The climate is tropical; hot and humid at the Indian ocean coast and Lake Victoria basin, temperate in the highlands and very hot and dry in the north and eastern parts of the country. The long rains occur from March to May and a short rains from October to December. June and July are the coldest months of the year while January and February are the hottest.

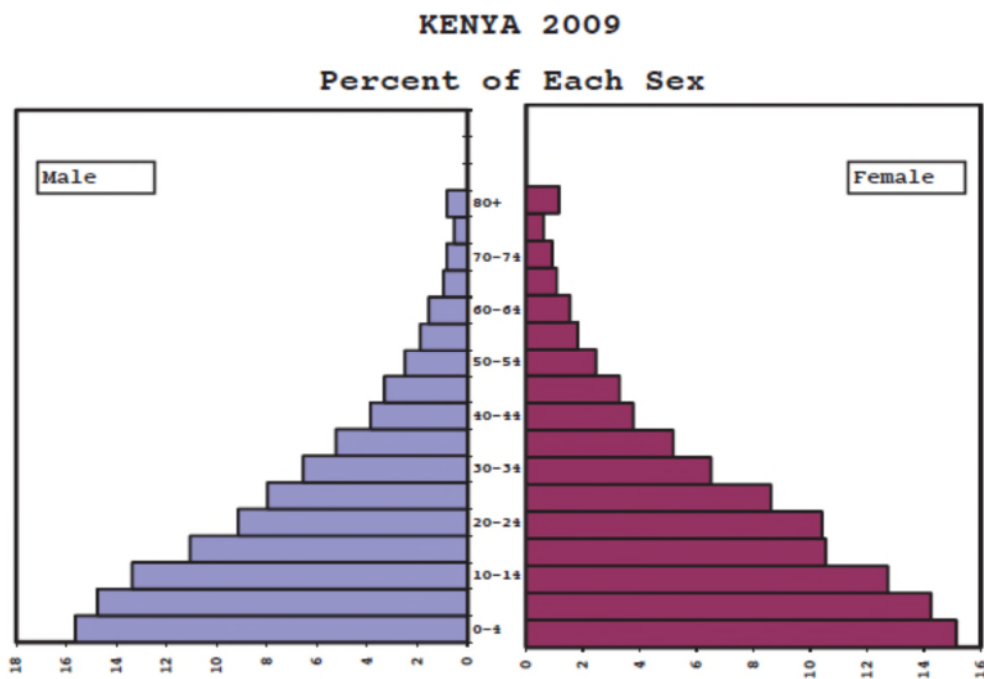
Figure 5.1 Map of Africa showing Kenya highlighted in a red circle in East Africa.



## 5.2 Demography

The population in 2014 was estimated at 43.0 Million.<sup>1</sup> From the last Kenya Population and Housing Census in 2009, the total population was 38.6 Million representing a 35% increase from the previous census in 1999.<sup>2</sup> There were 19.2 Million males and 19.4 Million females (male: female ratio of 1:1). The majority (26.1 Million, 68%) of the population was rural while about one third (12.5 Million, 32%) lived in urban areas. The population pyramid shows that Kenya's population is mainly youthful (Figure 5.2).

**Figure 5.2 Kenya population pyramid in 2009.**



Based on the 2009 census about 65% of the population had only primary or incomplete secondary education, and another 10% had never attended school.

## 5.3 HIV

HIV/AIDS is a huge burden in Kenya. In 2013 the prevalence of HIV in the 15-49 years age group was estimated at 6.0% and approximately 1.6 Million people were living with HIV.<sup>3</sup> The peak age affected is 35-39 years among women and 45-49 years among men. (Figure 5.3) The prevalence was higher among women (7.6%) compared to men (5.6%). The top 4 counties with the highest HIV prevalence among adults in Kenya are found around Lake Victoria. (Table 5.1). Two of our study centers (Sabatia and Kikuyu) were located in these

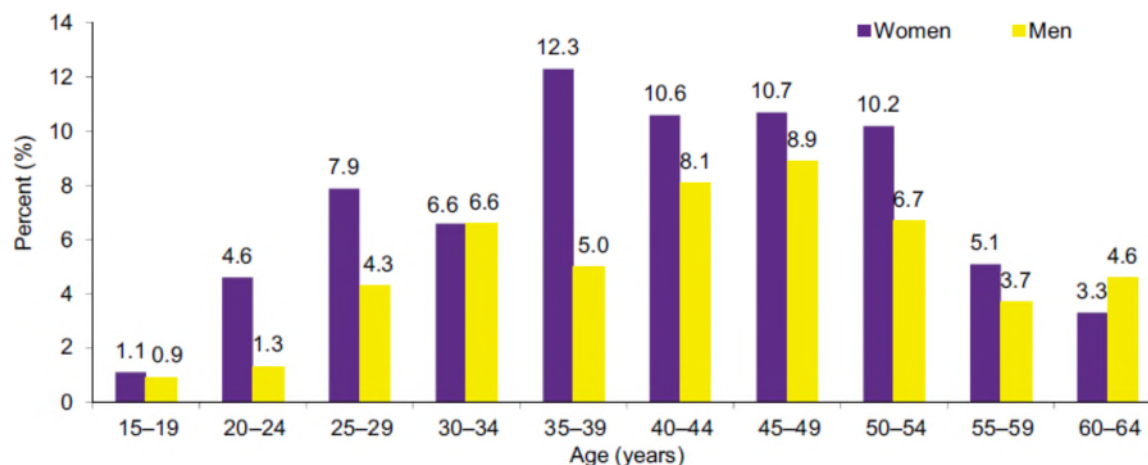
areas. (Figure 5.4) The areas with the highest prevalence include western Kenya and the Lake Victoria region, Nairobi and pockets along the Indian Ocean coast (Figure 5.5)

**Table 5.1 Counties in Kenya with the highest HIV prevalence among adults in 2013.<sup>3</sup>**

County	HIV prevalence in adults (%)
Homa Bay	25.7
Siaya	23.7
Kisumu	19.3
Migori	14.7
Kisii	8.0
Nairobi	7.6
Mombasa	7.4

These figures were generated by the National Aids Control Council (NACC) in Kenya using the Estimation and Projection Package (EPP) and Spectrum software recommended by the UNAIDS reference group with data from antenatal clinic surveillance, population based surveys such as the Kenya AIDS Indicator Survey II (KAIS 2012) and other program data.

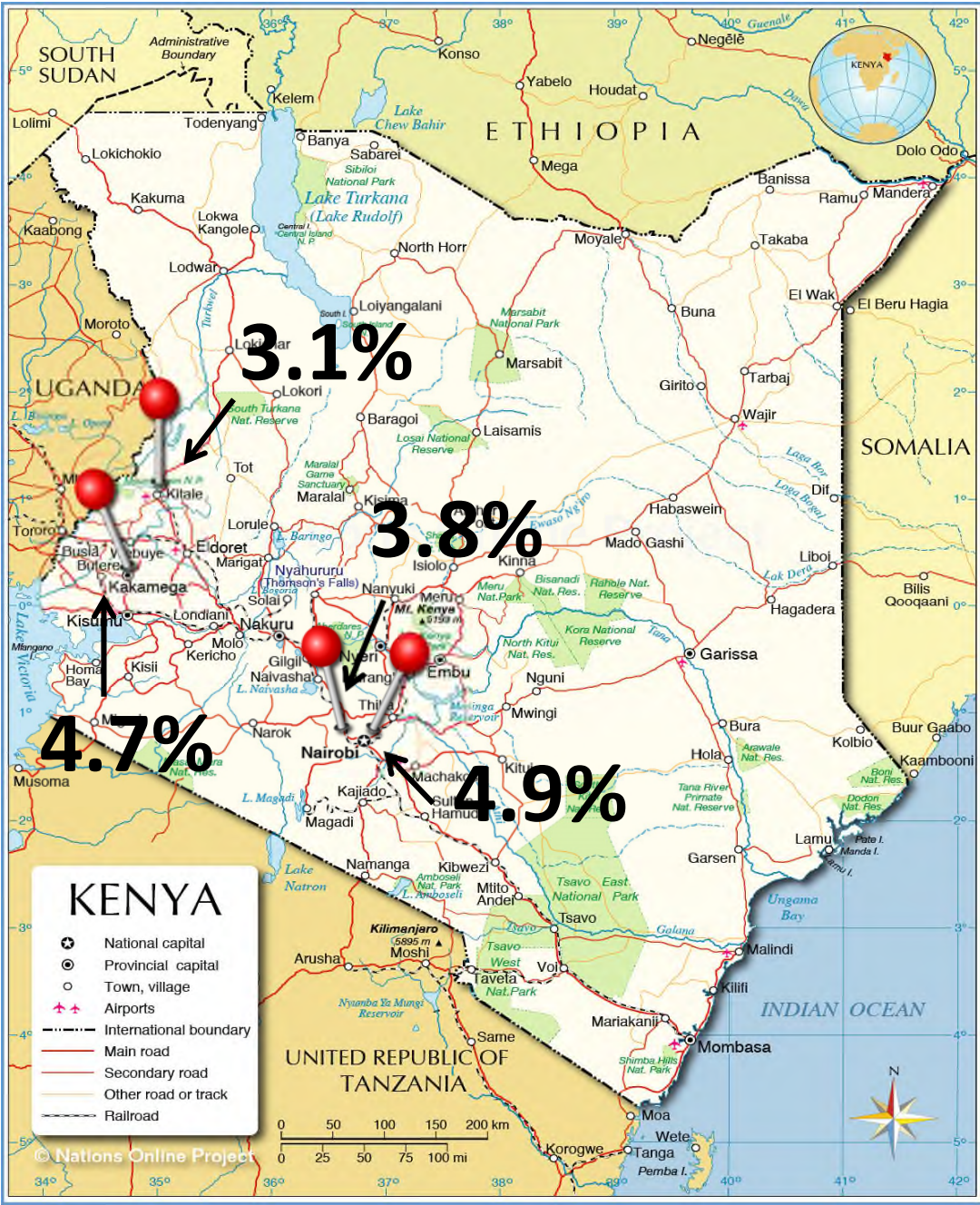
**Figure 5.3 HIV prevalence by age and sex in the KAIS 2012 survey.<sup>4</sup>**



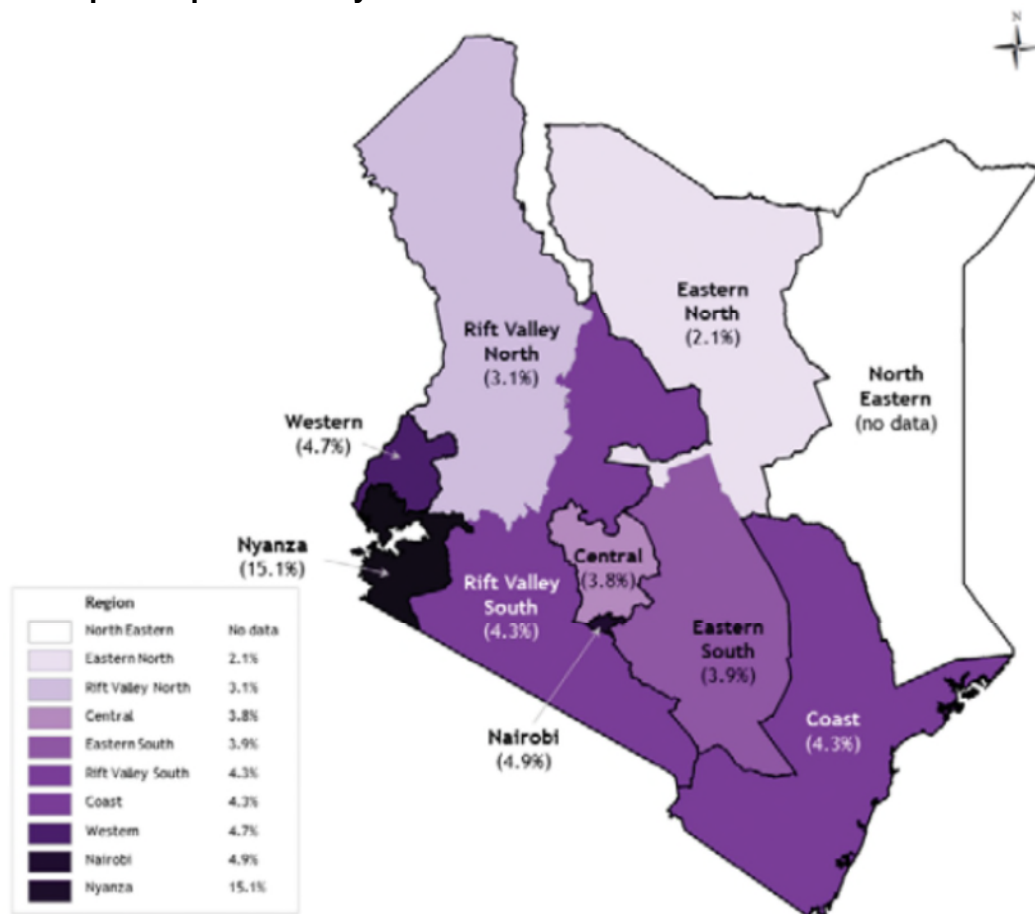
NOTE: HIV prevalence is highest in the 35-39 years and 45-49 years age groups in women and men respectively  
Abbreviation: KAIS – Kenya AIDS Indicator Survey



**Figure 5.4 Map of Kenya showing study sites and the HIV prevalence in those counties in 2012.**



**Figure 5.5. Map showing HIV prevalence in Kenya (2012) in different provinces under the now-replaced provincial system.<sup>4</sup>**



NOTE: Nyanza region and Nairobi have the highest prevalence. Two of our study centers (Kenyatta National Hospital and PCEA Kikuyu Eye Unit) serve Nairobi and its environs. Sabatia Eye Unit serves Western and Nyanza regions.

#### 5.4 Kenya eye health system

The Kenya eye care program started as a small project of the Royal Commonwealth Society in 1956. In 1966 the first National Prevention of Blindness Committee was formed. Later as it grew it was absorbed into the Ministry of Health and in 2001 it was upgraded to a full Division of the Ministry of Health and Sanitation after the launch of VISION 2020. The eye health delivery system now comprises of: Government, non-governmental, Mission and private facilities at various levels. There is an electronic eye health information system which is part of the health management information system (HMIS) of the Ministry of Health that collates data from all eye clinics except the private practices.

In 2012 there were 87 ophthalmologists, 92 Ophthalmic Clinical Officers specialised as Cataract Surgeons (OCO/CS), 43 OCO, 67 Ophthalmic Nurses (ON) and 34 Ophthalmic

Assistants (OA).<sup>5</sup> Eye care workers are unevenly distributed with the highest numbers being in urban and non-arid areas. The University of Nairobi (UON) trains ophthalmologists while the Kenya Medical Training Centre (KMTC) in Nairobi trains OCO/CS and OCO and nurses. Training of OCOs started in 1959, Ophthalmologists in 1978 and ON in 2003. A number of Mission hospitals and NGO clinics train OA. UON has the capacity to train 10 ophthalmologists per year of which about 5 are from other African countries while KMTC can train 10 OCO/CS and 16 ON per year.

The prevalence of blindness in people aged 50 years and older from a rapid assessment of blindness study in Nakuru district of Kenya, a predominantly rural area, was 2.0% (95%CI; 1.5%-2.4%), while that of visual impairment was 5.8% (95%CI; 4.8%-6.8%).<sup>6</sup> Cataract is the leading cause of blindness and refractive error for MSVI. The cataract surgery rate in 2010 was 589 operations/million population/year far below the Vision 2020 goal of 3000.<sup>5</sup> This is attributed to lack of resources, lack of awareness by blind persons, high cost of treatment and limited access to services.

## **5.5 Research Partners**

### **5.5.1 Study centres**

The study centres for this project were selected by obtaining data from the Kenya Ophthalmic Services electronic eye health information system to show the centres that reported the highest number of conjunctival excision between 2008 and 2011. The top 4 were:-

- Sabatia Eye Unit (219 cases/year) in the western highlands bordering Lake Victoria 300km from Nairobi and 20km from Kisumu
  - PCEA Kikuyu Eye Unit (118 cases/year) about 25 kilometres (km) from Nairobi in Central Kenya
  - Homa Bay District Hospital (94 cases/year) in Nyanza on the shores of Lake Victoria
  - Kitale District Hospital (83 cases/year) in the north Rift Valley 490km from Nairobi
- Kenyatta National Hospital (KNH) Eye Clinic in Nairobi which did not submit data in that period but is the national referral hospital was also chosen.

The location of the centres is shown in Figure 5.4.

Initially data collection started in PCEA Kikuyu Eye Unit and KNH in July 2012 but by October 2012 the recruitment at KNH had been rather slow due to a sudden increase in user fees in KNH from KSh. 1500 for a conjunctival excision to KSh. 5000 earlier that year. We wrote to the ethics committees in Nairobi and London School of Hygiene & Tropical Medicine to request for a protocol amendment to include the other 3 centres above. We thus added Sabatia and

Kitale hospitals but for logistical reasons (difficult to transport pathology specimens to Nairobi) Homa Bay district hospital was not activated.

From the foregoing description of Kenya, it is seen that the centres are located in the areas with the largest ethnic groups and highest HIV prevalence in the country.

### 5.5.2 Laboratories

- i) MP Shah Hospital in Nairobi - histopathology
- ii) The Kenya Aids Vaccine Institute (KAVI) Institute for Clinical Research laboratory at the University of Nairobi - HIV and CD4 testing and frozen tissue storage (serum for vitamin A and fresh frozen tumour samples).
- iii) The Tropical Diseases Research Centre's (TDRC) Nutrition Unit in Ndola Hospital, Zambia - vitamin A analysis.
- iv) The University College London (UCL) Institute of Ophthalmology, Department of Eye Pathology at the Moorfields Eye Hospital in London - Immunohistochemistry
- v) The London School of Hygiene & Tropical Medicine - DNA extraction from tumour specimens
- vi) Genome Institute of Singapore – HPV genotyping

### References

1. Kenya National Bureau of Statistics. Economic survey 2015., 2015.
2. Kenya National Bureau of Statistics. The 2009 Kenya Population and Housing Census., 2010.
3. National AIDS and STI Control Programme (NASCOP) Kenya. Kenya HIV estimates, 2014.
4. National AIDS and STI Control Programme (NASCOP) Kenya. Kenya AIDS Indicator Survey 2012: Final Report. Nairobi: NASCOP, 2014.
5. Ministry of Health. National Strategic Plan For Eye Health and Blindness Prevention 2012-2018. In: Ophthalmic Services Unit, editor.; 2012.
6. Mathenge W, Kuper H, Limburg H, et al. Rapid assessment of avoidable blindness in Nakuru district, Kenya. *Ophthalmology* 2007; **114**(3): 599-605.

# Chapter 6. Overview of project design

## 6.1 Research Questions

- i) Are HIV infection, low CD4 lymphocyte count, HPV infection, vitamin A deficiency, ultraviolet light exposure, cigarette smoking and occupation risk factors for OSSN?
- ii) Is CD4 T lymphocyte count (in HIV positive individuals) associated with the severity of OSSN?
- iii) In patients with conjunctival tumours, what is the safety, sensitivity and specificity of Toluidine blue dye 0.05% as a point-of-care diagnostic test for OSSN?
- iv) Why do patients with OSSN present late and from their perspective what can be done to reduce the delay?
- v) Does adjuvant chemotherapy with topical 1% 5FU applied four times daily for one month reduce the recurrence rate over a period of one year more than surgical excision alone?

## 6.2 Objectives

### 6.2.1 Broad Objectives

- i) To improve the understanding of the epidemiology, aetiology and pathophysiology of OSSN in East Africa.
- ii) To develop a diagnostic algorithm based on clinical signs and vital staining of the conjunctiva.
- iii) To understand why patients with OSSN present late with advanced disease.
- iv) To determine whether the recurrence of OSSN can be reduced through the use of adjuvant topical chemotherapy.

### 6.2.2 Specific objectives

- i) To determine if HIV infection, low CD4 lymphocyte count, HPV infection, vitamin A deficiency, ultraviolet light exposure, cigarette smoking and occupation are risk factors for OSSN in Kenya and describe the expression patterns of the SLRP family members.
- ii) To determine the sensitivity and specificity of Toluidine blue dye 0.05% vital staining in patients with conjunctival tumour for diagnosis of OSSN with histology as the gold standard.
- iii) To develop a diagnostic algorithm based on clinical signs and vital staining of the conjunctiva to guide the management of possible OSSN in resource-limited settings.

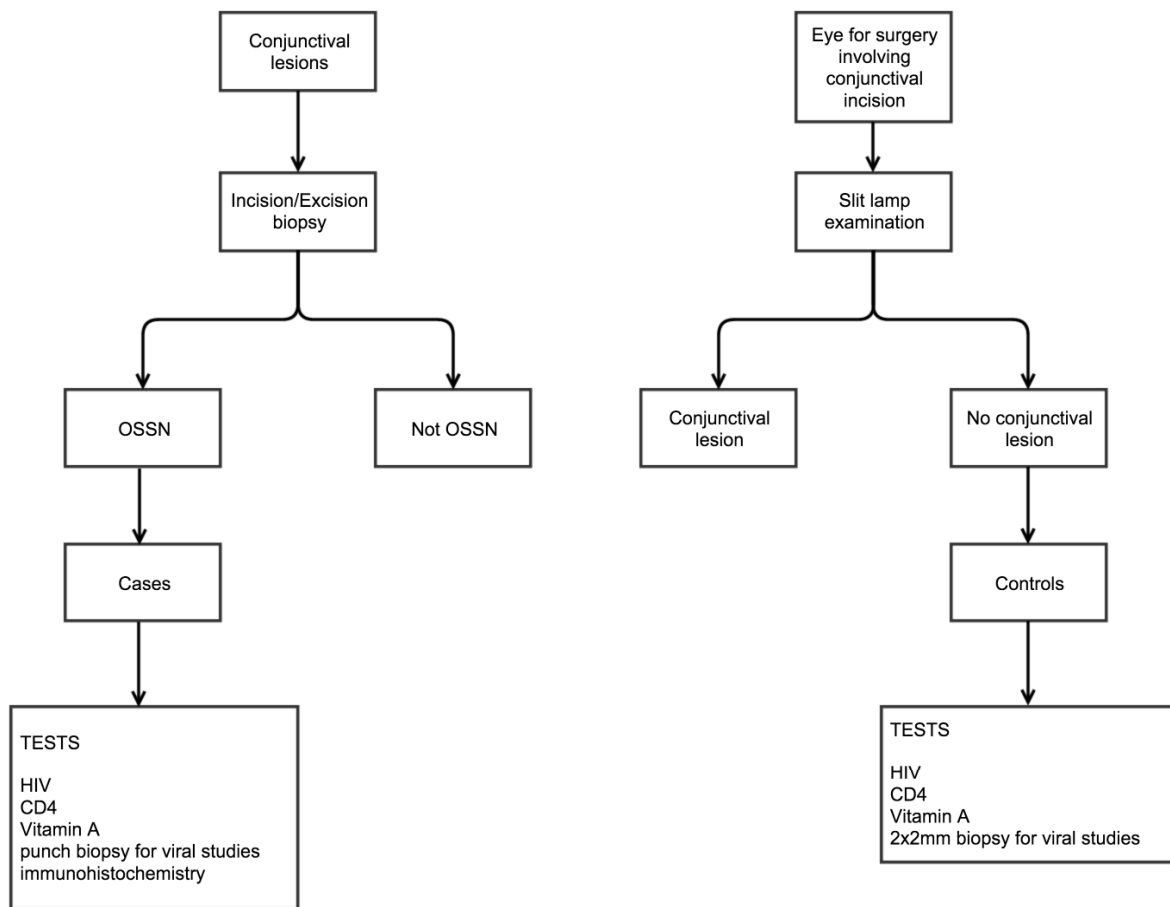
- iv) To describe the barriers to care, the care-seeking pathway of patients with OSSN and possible solutions from the patients' perspective.
- v) To conduct a randomised controlled trial to determine the efficacy and safety of adjuvant topical 5FU 1% eye drops applied 4 times daily for one month after surgical excision of OSSN tumours which involve less than 2 quadrants of the conjunctiva by evaluating the one-year recurrence rate and mean time-to-recurrence of OSSN; and both immediate and delayed adverse effects of this therapy.

### **6.3 Methods/design**

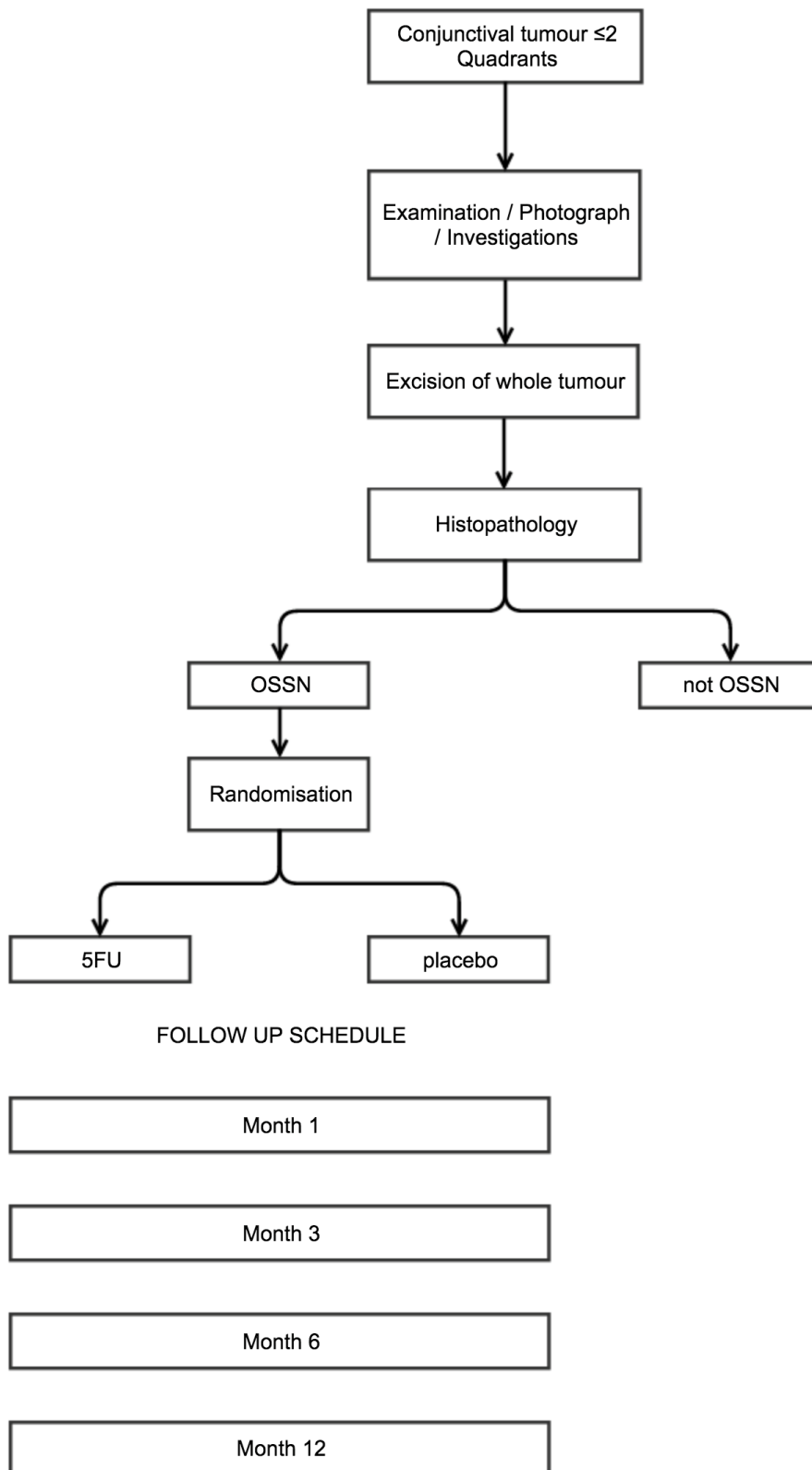
Participants passed through the following study sequence:

- i) Case-Control Study: confirmed cases of OSSN were compared with controls. Clinical features were recorded and various risk factors evaluated: HIV, CD4, vitamin A, HPV types, ultraviolet exposure and occupational history. (Figure 6.1)
- ii) Evaluation of Toluidine Blue (ToB) vital staining of conjunctival tumours as a point-of-care test in the diagnosis of OSSN compared to histopathology as the gold standard.
- iii) A narrative of the care-seeking pathway OSSN cases took.
- iv) A randomised controlled trial to determine whether OSSN recurrence can be reduced by adjuvant topical 5FU chemotherapy following excision. (Figure 6.2)

**Figure 6.1 Case-control study outline.**



**Figure 6.2 Randomised controlled trial outline.**





## 6.4 Project timeline

Figure 6.3 Project timeline

Activity	2011				2012				2013				2014				2015				2016
	Q1	Q2	Q3	Q4	Q1	Q2	Q3	Q4	Q1	Q2	Q3	Q4	Q1	Q2	Q3	Q4	Q1	Q2	Q3	Q4	Q1
Fellowship result	■																				
Finalize full protocol		■	■																		
1 <sup>st</sup> term courses in London (LSHTM)				■																	
Ethics committee submission				■																	
Ethics committee feedback received					■																
Protocol review and resubmission to ethics						■															
Write SOPs				■																	
Equipment procurement				■																	
Staff recruitment						■															
Protocol training						■															
Pilot phase					■																
Modify SOPs						■															
Participant recruitment							■	■	■	■	■	■	■	■	■	■					
Participant follow up								■	■	■	■	■	■	■	■	■	■	■	■	■	■
PhD Upgrade Report & seminar								■													
Laboratory testing									■	■	■	■	■	■	■	■	■	■	■	■	■
Data analysis										■	■	■	■	■	■	■	■	■	■	■	■
Write up (review papers were published first)											■	■	■	■	■	■	■	■	■	■	■

During the project period certain untoward events occurred in Kenya that affected the timeline:

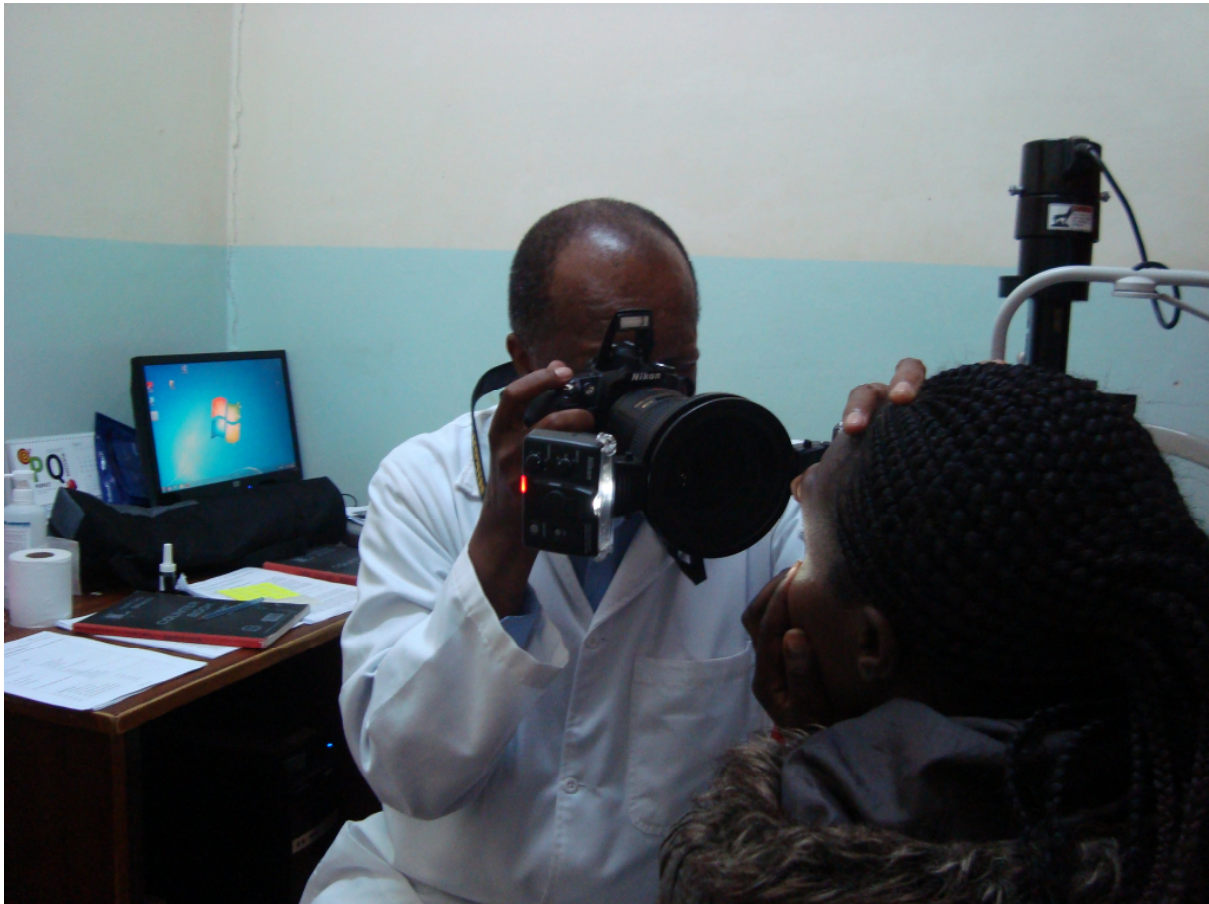- a) There were national elections held in March 2013 and by six months before that tension was already rising high nationwide during campaigns. There was a lot of anxiety in the populace at large related to major inter-ethnic violence that took place after the previous elections in December 2007. People residing in areas where they were considered 'outsiders' migrated back to their rural homes where they felt safer. From December 2012, about 50 or so participants who had surgical excisions and were enrolled in the study did not return for their results and we lost the opportunity to enrol them in the case-control study and trial. Some of the participants who had been enrolled also missed their visits or were lost to follow up completely.
- b) In the year 2011, for example, a total of 21 industrial strikes were reported involving 13,499 employees with up to 175,329 man-days lost mainly affecting health workers, school teachers and university academic staff.<sup>1</sup> Nationwide industrial action by health workers from August 2011 to December 2011 and another in September 2012 paralysed services in the health facilities from where we were receiving referrals to the study centres. There were additional strikes by health workers and teachers in 2012 and 2013. In March 2014 teaching and non-teaching staff in public universities went on strike. In one case, blood samples for 20 study participants that were stored in the freezers of a district hospital laboratory neighbouring Sabatia Eye Unit went missing and were never found again. We resorted to direct courier of subsequent samples to Nairobi which considerably raised costs.
- c) There was a sudden increase in user fees at KNH that slowed down recruitment. Time was lost as we had to get the necessary ethical approval for additional study centres. We thus started recruitment in Sabatia in January 2013 and in Kitale in February 2013. Recruitment in the other centres had started about 8 months before (KNH in June 2012 and Kikuyu in July 2012).
- d) The first batch of 16 tumour specimens from one centre (Kitale) arrived at the pathology laboratory autolysed. It was suspected to be related to poorly constituted formalin which was subsequently replaced.

## References

1. Odhong E, Were S, Omolo J. Re-thinking industrial relations for enhanced organizational performance in Kenya. International Conference on Sustainable Research and Innovation; 2014; 2014. p. 158-61.

# Data Chapters

## Chapter 7. Clinical presentation of ocular surface squamous neoplasia in Kenya





**Registry**

T: +44(0)20 7299 4646  
F: +44(0)20 7299 4656  
E: registry@lshtm.ac.uk

## RESEARCH PAPER COVER SHEET

**PLEASE NOTE THAT A COVER SHEET MUST BE COMPLETED FOR EACH RESEARCH PAPER INCLUDED IN A THESIS.**

### SECTION A – Student Details

<b>Student</b>	Stephen Gichuhi
<b>Principal Supervisor</b>	Matthew J. Burton
<b>Thesis Title</b>	Epidemiology and management of ocular surface squamous neoplasia in Kenya

**If the Research Paper has previously been published please complete Section B, if not please move to Section C**

### SECTION B – Paper already published

Where was the work published?	JAMA Ophthalmology		
When was the work published?	November 2015		
If the work was published prior to registration for your research degree, give a brief rationale for its inclusion			
Have you retained the copyright for the work?*	No	Was the work subject to academic peer review?	Yes

*\*If yes, please attach evidence of retention. If no, or if the work is being included in its published format, please attach evidence of permission from the copyright holder (publisher or other author) to include this work.*

### SECTION C – Prepared for publication, but not yet published

Where is the work intended to be published?	
Please list the paper's authors in the intended authorship order:	
Stage of publication	Choose an item.

### SECTION D – Multi-authored work

For multi-authored work, give full details of your role in the research included in the paper and in the preparation of the paper. (Attach a further sheet if necessary)

I coordinated and actively led the field work for this paper. I identified the participants, carried out the clinical examinations and photo assessments. Field supervision was provided by Matthew Burton throughout. I also performed the statistical analysis, with some guidance from Helen Weiss. I wrote and submitted the paper with consideration of comments from co-authors.

**Student Signature:** Stephen Gichuhi

**Date:** 4th February 2016

**Supervisor Signature:** M. J. Burton

**Date:** 4th February 2016

## Permissions

### **Clinical Presentation of Ocular Surface Squamous Neoplasia in Kenya**

Stephen Gichuhi, Ephantus Macharia, Joy Kabiru, Alain M'bongo Zindamoyen, Hilary Rono, Ernest Ollando, Leonard Wanyonyi, Joseph Wachira, Rhoda Munene, Timothy Onyuma, Mandeep S. Sagoo, Helen A. Weiss, and Matthew J. Burton

**JAMA Ophthalmology. 2015; 133(11): 1305-1313.**

To access the paper, press the CTRL button and at the same time click on the link below.

<http://archophth.jamanetwork.com/article.aspx?articleId=2442775&questAccessKey=7ee32d94-5c35-463f-8f09-c864be6c6ab6>

There was an invited commentary on this paper whose reference is shown below.

### **Ocular Surface Squamous Neoplasia: From Blue Skies to Blue Dyes-We Still Need Our Ophthalmic Pathologists.**

Shields CL, Shields JA.

**JAMA Ophthalmology. 2015 Nov;133(11):1321-2.**

Comment on

JAMA Ophthalmol. 2015 Nov;133(11):1305-13.

JAMA Ophthalmol. 2015 Nov;133(11):1314-21.

## **Chapter 8. Toluidine Blue 0.05% vital staining for diagnosis of ocular surface squamous neoplasia in Kenya**





**Registry**

T: +44(0)20 7299 4646  
F: +44(0)20 7299 4656  
E: registry@lshtm.ac.uk

## RESEARCH PAPER COVER SHEET

**PLEASE NOTE THAT A COVER SHEET MUST BE COMPLETED FOR EACH RESEARCH PAPER INCLUDED IN A THESIS.**

### SECTION A – Student Details

<b>Student</b>	Stephen Gichuhi
<b>Principal Supervisor</b>	Matthew J. Burton
<b>Thesis Title</b>	Epidemiology and management of ocular surface squamous neoplasia in Kenya

**If the Research Paper has previously been published please complete Section B, if not please move to Section C**

### SECTION B – Paper already published

Where was the work published?	JAMA Ophthalmology		
When was the work published?	November 2015		
If the work was published prior to registration for your research degree, give a brief rationale for its inclusion			
Have you retained the copyright for the work?*	No	Was the work subject to academic peer review?	Yes

*\*If yes, please attach evidence of retention. If no, or if the work is being included in its published format, please attach evidence of permission from the copyright holder (publisher or other author) to include this work.*

### SECTION C – Prepared for publication, but not yet published

Where is the work intended to be published?	
Please list the paper's authors in the intended authorship order:	
Stage of publication	Choose an item.

### SECTION D – Multi-authored work

For multi-authored work, give full details of your role in the research included in the paper and in the preparation of the paper. (Attach a further sheet if necessary)

I coordinated and actively led the field work for this paper. I identified the participants, carried out the clinical examinations and photo assessments. Field supervision was provided by Matthew Burton throughout. I also performed the statistical analysis, with some guidance from Helen Weiss. I wrote and submitted the paper with consideration of comments from co-authors.

**Student Signature:** Stephen Gichuhi

**Date:** 4th February 2016

**Supervisor Signature:** M. J. Burton

**Date:** 4th February 2016



## Permissions

### **Toluidine blue 0.05% vital staining for diagnosis of ocular surface squamous neoplasia in Kenya.**

Stephen Gichuhi, Ephantus Macharia, Joy Kabiru, Alain M'bongo Zindamoyen, Hilary Rono, Ernest Ollando, Leonard Wanyonyi, Joseph Wachira, Rhoda Munene, Timothy Onyuma, Walter Jaoko, Mandeep S. Sagoo, Helen A. Weiss, and Matthew J. Burton

**JAMA Ophthalmology. 2015; 133(11): 1314-1321.**

To access the paper, press the CTRL button and at the same time click on the link below.

<http://archophth.jamanetwork.com/article.aspx?articleId=2442776&questAccessKey=f9c382af-d52a-401f-9478-b1dc32d80045>

There was an invited commentary on this paper whose reference is shown below.

### **Ocular Surface Squamous Neoplasia: From Blue Skies to Blue Dyes--We Still Need Our Ophthalmic Pathologists.**

Shields CL, Shields JA.

**JAMA Ophthalmology. 2015 Nov;133(11):1321-2.**

Comment on

JAMA Ophthalmol. 2015 Nov;133(11):1305-13.

JAMA Ophthalmol. 2015 Nov;133(11):1314-21.

## **Chapter 9. Clinical algorithm for diagnosis and management of ocular surface squamous neoplasia in East Africa**





**Registry**

T: +44(0)20 7299 4646  
F: +44(0)20 7299 4656  
E: registry@lshtm.ac.uk

## RESEARCH PAPER COVER SHEET

**PLEASE NOTE THAT A COVER SHEET MUST BE COMPLETED FOR EACH RESEARCH PAPER INCLUDED IN A THESIS.**

### SECTION A – Student Details

<b>Student</b>	Stephen Gichuhi
<b>Principal Supervisor</b>	Matthew J. Burton
<b>Thesis Title</b>	Epidemiology and management of ocular surface squamous neoplasia in Kenya

**If the Research Paper has previously been published please complete Section B, if not please move to Section C**

### SECTION B – Paper already published

Where was the work published?			
When was the work published?			
If the work was published prior to registration for your research degree, give a brief rationale for its inclusion			
Have you retained the copyright for the work?*	Choose an item.	Was the work subject to academic peer review?	Choose an item.

*\*If yes, please attach evidence of retention. If no, or if the work is being included in its published format, please attach evidence of permission from the copyright holder (publisher or other author) to include this work.*

### SECTION C – Prepared for publication, but not yet published

Where is the work intended to be published?	British Journal of Ophthalmology
Please list the paper's authors in the intended authorship order:	Stephen Gichuhi, Ephantus Macharia, Joy Kabiru, Alain Mbongo Zindamoyen, Hilary Rono, Ernest Ollando, Joseph Wachira, Rhoda Munene, Timothy Onyuma, Mandeep S. Sagoo, David Macleod, Helen A. Weiss, and Matthew J. Burton
Stage of publication	<b>Not yet submitted</b>

### SECTION D – Multi-authored work

For multi-authored work, give full details of your role in the research included in the paper and in the preparation of the paper. (Attach a further sheet if necessary)	I coordinated and actively led the field work for this paper. Supervision was provided by Matthew Burton throughout. I also performed the statistical analysis, with some guidance from Helen Weiss and David Macleod. I wrote the paper with consideration of comments from co-authors.
--	--

**Student Signature:** Stephen Gichuhi

**Date:** 4th February 2016

**Supervisor Signature:** M. J. Burton

**Date:** 4th February 2016

# Clinical algorithm for diagnosis of Ocular Surface Squamous Neoplasia (OSSN) in East Africa

## Corresponding Author:

Stephen Gichuhi  
International Center for Eye Health  
London School of Hygiene & Tropical Medicine  
Keppel Street, London WC1E 7HT  
United Kingdom  
Tel. +44 (20) 7636 8636 ext. 8257  
[stephen.gichuhi@lshtm.ac.uk](mailto:stephen.gichuhi@lshtm.ac.uk)

## Authors:

Stephen Gichuhi MBChB, M.Med<sup>1,2</sup>, Joy Kabiru MBChB, M.Med<sup>3</sup>, Alain M'bongo Zindamoyen MBChB, M.Med<sup>3</sup>, Hilary Rono MBChB, M.Med<sup>4</sup>, Ernest Ollando MBChB, M.Med<sup>5</sup>, Joseph Wachira MBChB, M.Med<sup>6</sup>, Rhoda Munene MBChB, M.Med<sup>6</sup>, Timothy Onyuma MBChB, M.Med<sup>7</sup>, Mandeep S. Sagoo PhD, FRCOphth<sup>8,9,10</sup>, David Macleod MSc<sup>1</sup>, Helen A. Weiss MSc, PhD<sup>1,11</sup> and Matthew J. Burton PhD, FRCOphth<sup>1,9</sup>

## Email contacts

Stephen Gichuhi, [Stephen.Gichuhi@lshtm.ac.uk](mailto:Stephen.Gichuhi@lshtm.ac.uk)  
Joy Kabiru, [joykabiru@yahoo.com](mailto:joykabiru@yahoo.com)  
Alain M'bongo Zindamoyen, [zindamoyen@yahoo.com](mailto:zindamoyen@yahoo.com)  
Hilary Rono, [hkrono@yahoo.com](mailto:hkrono@yahoo.com)  
Ernest Ollando, [eollando@yahoo.com](mailto:eollando@yahoo.com)  
Joseph Wachira, [drjwachira@gmail.com](mailto:drjwachira@gmail.com)  
Rhoda Munene, [drmmunene@gmail.com](mailto:drmmunene@gmail.com)  
Timothy Onyuma, [tonyuma@mpshahhosp.org](mailto:tonyuma@mpshahhosp.org)  
Mandeep S. Sagoo, [mandeep.sagoo@moorfields.nhs.uk](mailto:mandeep.sagoo@moorfields.nhs.uk)  
David Macleod [david.macleod@lshtm.ac.uk](mailto:david.macleod@lshtm.ac.uk)  
Helen A. Weiss, [helen.weiss@lshtm.ac.uk](mailto:helen.weiss@lshtm.ac.uk)  
Matthew J. Burton, [matthew.burton@lshtm.ac.uk](mailto:matthew.burton@lshtm.ac.uk)

## Affiliations:

<sup>1</sup>International Centre for Eye Health, London School of Hygiene and Tropical Medicine, Keppel Street, London, WC1E 7HT, UK  
<sup>2</sup>Department of Ophthalmology, University of Nairobi, P.O Box 19676-00202, Nairobi, Kenya  
<sup>3</sup>PCEA Kikuyu Eye Unit, PO Box 45, Kikuyu, Kenya  
<sup>4</sup>Kitale District Hospital, PO Box 98-30200, Kitale, Kenya  
<sup>5</sup>Sabatia Eye Hospital, PO Box 214-50311, Wodanga, Kenya  
<sup>6</sup>Kenyatta National Hospital, PO Box 20723-00202, Nairobi, Kenya  
<sup>7</sup>MP Shah Hospital, Department of Pathology, PO Box 14497-00800, Nairobi, Kenya  
<sup>8</sup>UCL Institute of Ophthalmology, 11-43 Bath Street, London EC1V 9EL, UK  
<sup>9</sup>Moorfields Eye Hospital, 162 City Road, London, EC1V 2PD, UK  
<sup>10</sup>St. Bartholomew's Hospital, W Smithfield, London EC1A 7BE, London, UK  
<sup>11</sup>MRC Tropical Epidemiology Group, London School of Hygiene and Tropical Medicine, Keppel Street, London, WC1E 7HT,

## Subtitle:

Diagnostic algorithm for OSSN

## Key words:

Algorithm;  
Diagnosis  
Ocular surface squamous neoplasia  
East Africa

**Word count: text 2534; abstract 250**

## **Abstract**

### *Background*

Clinical features of Ocular Surface Squamous Neoplasia (OSSN) and benign conjunctival lesions overlap. Toluidine blue (ToB) 0.05% vital staining of OSSN has a high sensitivity (92%) but low specificity (31%). This study was conducted to determine whether an algorithm combining clinical features and vital staining increased the specificity.

### *Methods*

Clinical features of participants presenting with conjunctival lesions in Kenya were evaluated and lesions excised for histopathology to confirm the diagnosis. Participants were randomly divided into two sets: “development” and “validation” sets. Using the development set, clinical criteria that had the strongest association with OSSN were analysed using logistic regression, a specificity-based and sensitivity-based model. Using the best combination of features in the three models, receiver operator characteristic curves were plotted, cut-off determined, best model chosen and repeated in the validation set. An algorithm showing the probability of OSSN with features at the cut-off was developed.

### *Results*

Out of 496 participants OSSN was confirmed in 187 (38%). The regression-based model had the highest area under the curve (79.8%). The best cut-off was using 3 out of 8 features; prior excision, corneal involvement, feeder vessels, dark blue ToB staining, papillary or gelatinous tumour surface, severe inflammation, anti-retroviral therapy and temporal or circumlimbal tumours. At this cut-off sensitivity was 89%, specificity 50%, and 65% of lesions were correctly classified. This specificity was higher than any blue ToB staining (31%) but lower than clinical photo-examination (60%).

### *Conclusion*

This algorithm may assist clinicians decide about the need for surgery but cannot replace histopathology.

## Introduction

Ocular surface squamous neoplasia (OSSN) is a relatively common, aggressive disease in Africa. Compared to other parts of the world, it more frequently affects younger adults, particularly those living with HIV, and has a higher incidence in women.<sup>1</sup> Late presentation with large tumours is not infrequent and the outlook of treatment limited by high recurrence rates.<sup>2-4</sup> The gold standard for diagnosis of OSSN remains histopathology.<sup>5</sup> However most practitioners in Africa depend on their clinical impression and lesions are often excised without histopathology due to a shortage of pathologists, logistical problems of sending the specimens to distant histopathology service centres and the added cost thereof.<sup>6,7</sup> This means that it is difficult to know what the lesion was exactly and whether the margins were involved or not. In some countries without such resource constraints, treatment decisions are also being made without an excision biopsy for histopathology being performed.<sup>8</sup> Studies from East Africa have found an overlap in the clinical features of OSSN and benign lesions, making it difficult to distinguish between them.<sup>9,10</sup> In addition, different histological grades of OSSN show overlapping phenotypes.<sup>9,10</sup> Clinical examination of a series of conjunctival lesions from photographs had a positive predictive value of 54%.<sup>9</sup>

We have previously reported the use of Toluidine blue (ToB) 0.05% vital staining in Kenya to assist in the diagnosis of OSSN and found that although any blue staining was sensitive for OSSN (92%) it lacked specificity (31%).<sup>11</sup> The test was however easily interpreted by different examiners ( $\kappa=0.76$ ). Dark royal blue staining had a sensitivity of 64% and specificity of 67%. Other studies have reported that vital staining for OSSN has high sensitivity and relatively low specificity. In Brazil, toluidine blue 1% had high sensitivity of 100% and a specificity of 50% while in South Africa methylene blue 1% had a sensitivity of 92% and a specificity of 50%.<sup>12,13</sup> Therefore, vital staining alone cannot currently be relied upon to guide treatment decisions.

In the African setting a clinical diagnostic algorithm may help support the clinician's impression of OSSN to distinguish lesions that should be excised from those that can be followed up. We conducted this study to develop an algorithm that combined ToB staining with other clinical features. The key qualities sought were: simplicity, for clinicians to use easily; specificity, as we have a test with high sensitivity already (any blue ToB stain) but it has an unacceptably low specificity (31%); sensitivity (using dark blue ToB stain has a higher specificity of 67% but the sensitivity is only 64%).<sup>11</sup>

## Methods

### *Ethical Approval*

This study was approved by the Kenyatta National Hospital – University of Nairobi Ethics and Research Committee and the London School of Hygiene & Tropical Medicine Ethics Committee. It

adhered to the tenets of the Declaration of Helsinki. All participants gave informed written consent to take part.

### *Study population*

The participants were part of an integrated set of studies on the epidemiology and management of OSSN in Kenya. They were recruited between July 2012 and July 2014 in four eye care centres: Kenyatta National Hospital in Nairobi, PCEA Kikuyu Eye Unit about 25 kilometres (km) from Nairobi in Central Kenya, Kitale district hospital in the north Rift Valley 490km from Nairobi and Sabatia Eye Hospital 300km from Nairobi in western Kenya near Lake Victoria. Adult patients ( $\geq 18$  years) presenting to these clinics with any conjunctival lesion (first presentation or a recurrence) and scheduled for surgery were recruited.

Participant examination methods have been published elsewhere.<sup>9</sup> Briefly, a comprehensive history was taken, clinical examination at the slit lamp was performed to record features of the lesions, vital staining done with ToB 0.05% and digital photographs of the lesions taken before and after staining.<sup>11</sup> Lesions were excised and sent for histopathology. One pathologist examined all the histology slides. OSSN was defined as any lesion with mild, moderate or severe conjunctival intraepithelial neoplasia (CIN I, II, III respectively); any who had carcinoma-in-situ (CIS); or invasive squamous cell carcinoma. Benign lesions included pterygium, actinic keratosis, papillomas, pyogenic granulomas, nevi and rhinosporidiosis. During the post-operative visit about 3-4 weeks later, participants found to have OSSN were offered HIV testing and a CD4 count if positive.

### *Generation of development and validation datasets*

The original dataset, consisting of observations of both OSSN and benign lesions, was split into two datasets, one for the purposes of developing the diagnostic test and the other for validating it. This was done by setting a "seed" (in order to make the random allocation reproducible). Each individual was allocated a random number between 0 and 1. They were then sorted by this random number and split into a development set (consisting of 75% of the participants) and a validation set (consisting of the remaining 25%). This, and all other statistical analysis, was performed using Stata version 12.1 (StataCorp, College Station, Texas, USA).

### *Model construction and validation*

Using the development dataset, univariable analysis was conducted to find which features were associated with OSSN. Multivariable logistic regression analysis was used to estimate odds ratios (ORs) and 95% confidence intervals (CIs). The likelihood ratio test was used to assess statistical significance of associations. Variables that were associated with OSSN in the univariable analyses at a level of  $p < 0.05$  were included in the multivariable analysis and then those with  $p < 0.2$  were retained in the model. We took the features selected by the logistic regression model and for each

patient created a “diagnostic score” which was the number of features observed. We then plotted a ROC curve to identify the most appropriate “cut-off” to classify a lesion as OSSN or not.

In addition to the regression-based model, specificity-based and sensitivity-based models were also developed. The specificity-based model which aimed to reduce the proportion of false positives was developed using a similar method to a Zimbabwe study that created an algorithm for verbal autopsy of HIV.<sup>14</sup> The positive likelihood ratio (LR) for a range of features from the history and clinical examination findings was calculated in the development dataset to examine their strength of association with OSSN. Features with a  $LR \geq 1.92$  (corresponding to a significant chi-squared test on 1 degree of freedom at  $p < 0.05$ ) were retained for further analysis. The selected features were then ordered from the highest specificity to lowest and the following steps followed:

- 1) Take the feature with the highest specificity
- 2) Classify all observations where this feature is present as OSSN+
- 3) Calculate sensitivity and specificity of diagnostic test using this feature
- 4) Recalculate the specificity of all remaining features using only the observations not classified as OSSN+
- 5) Take the feature with the highest specificity in the remaining list of variables
- 6) Classify all observations where this feature is present as OSSN+
- 7) Calculate sensitivity and specificity of diagnostic test

This iterative process was repeated until all the variables had been incorporated. For the sensitivity-based model, the same method was used except that the selection of features to be included was based on the highest sensitivity. These features from the specificity-based and sensitivity-based models were then applied to the development dataset and used to plot a modified receiver operator characteristic (ROC) curve to visualise the effect that adding each feature had on the sensitivity and specificity and to choose a cut-off point which optimised the two. We modified the typical ROC curve, which shows different cut-offs for the same parameter, usually a continuous variable, by creating an ordered categorical variable in which different categories consisted of various combinations of features. For example, category 1=feature A, 2= feature A + feature B, 3= feature A + feature B + feature C and so on.

The results of the models from the development set were then applied to the validation set and ROC curves plotted. To choose the best model among the three, the ROC that was closest to the upper left hand corner of the plot was used. The cut-off value from the ROC curve was also selected by choosing the point closest to the upper left hand-corner of the plot and specificity above 50%.



### *Algorithm development*

Finally, an algorithm was built from the development dataset as a probability tree using identified features from the best model, in the case of the regression model starting with the ones with the highest odds ratios.

## **Results**

There were 496 participants with conjunctival lesions. The development dataset included 372 participants and validation dataset 124. Histologically confirmed OSSN was present in 187 (38%) participants: 139/372 (37%) of the development dataset and 48/124 (39%) of the validation dataset.

### *Model Development*

The features from the history, clinical examination and laboratory testing that were evaluated are listed in the Supplementary Table. Those that were associated with OSSN at the 5% significance level on univariate analysis are shown in Table 9.1. In the multivariable logistic regression model eight variables were considered significant predictors of OSSN (Table 9.2).

The three ROC curves (regression, sensitivity and specificity models) generated from the development dataset are shown in Figure 9.1. The best cut-off for the specificity-based model was the presence of any one of the following features; symblepharon, fornix involvement, history of prior excision, anti-retroviral therapy (ART) use, severe inflammation or dark ToB vital stain. The best cut-off for the sensitivity-based model was the presence of a papillary-gelatinous surface. For the regression-based model, the best cut-off was the presence of any 3 of the 8 features listed in Table 9.2. With this cut-off in the regression model the sensitivity was 89% and specificity 50%. The curve from the regression-based model had the highest area under the curve (79.8% vs 77.9% for the specificity-based and 58.0% for the sensitivity-based).

### *Model Validation*

The ROC curves from application of the three models to the validation dataset are shown in the Supplementary Figure. The curve from the regression-based model had the highest area under the curve (73% vs specificity 57% and sensitivity 58%). The cut-off giving the point closest to the top left of the plot was 3, which means those individuals with 3 or more of the 8 selected features are classified as OSSN. Using 2 features as a cut-off had a high sensitivity (94%) but low specificity (26%) while 4 features, though with a higher specificity (74%), had a low sensitivity (56%), making 3 the best compromise. With 3 features the sensitivity was 83% and specificity 54%. The odds ratios for many of the variables in Table 9.2 were not statistically significant in the validation dataset because of sample size limitations.

A comparison of the performance, using the validation dataset, of the three models with ToB staining and clinical assessment from photographs is shown in Table 9.3. The regression-based model was more accurate (65%) than the specificity (57%) or sensitivity (50%) models. It offered the best compromise with false positives at 46% (instead of 69% with any blue staining) and false negatives at 17% (twice those of any blue staining but dark blue staining had four times as many false negatives at 36%). Clinical photograph examination had a higher sensitivity (86% vs 83%), specificity (60% vs 50%) and accuracy (70% vs 65%) than the regression model.

### *Diagnostic Algorithm*

Applying this to the four clinical features with the highest odds ratios from the multivariable regression model we constructed the diagnostic probability tree shown in Figure 9.2 to show the probability of OSSN in an individual patient with specific combinations of features in this dataset.

## **Discussion**

Earlier studies from the East African region have found that the diagnosis of OSSN on clinical grounds can be unreliable, due to an overlap in clinical features of OSSN with other ocular surface lesions.<sup>9</sup> In addition, we have previously reported the use of toluidine blue vital staining, which we found to have a high sensitivity but low specificity.<sup>11</sup> In this study we developed and evaluated several models to try to identify a combination of variables that most reliably distinguishes OSSN from other pathology.

We found that a simple logistic regression model, with a classifier threshold of 3 or more out of 8 features associated with OSSN from history, clinical examination and ToB vital staining provided the best balance (of the options tested) between reasonable sensitivity (89%) and improved specificity (50%) over using ToB alone.<sup>11</sup> The sensitivity and specificity in the regression model compares well with the quoted values in the clinical features we previously reported (86% sensitivity and 60% specificity) although we do not know which specific features the examiners were using or how they interpreted them when looking at the photographs.<sup>9</sup> A high sensitivity is a critical requirement when dealing with a serious disease like OSSN. However, the moderate specificity remains problematic, as this is likely to result in more patients having surgery for suspected OSSN who turn out not to have this disease.

The probability tree algorithm is a simple tool that clinicians may also find helpful in assessing patients with ocular surface lesions. Tracing the presence or absence of certain features leads to a probability score for the diagnosis of OSSN. However, it should be emphasised that this algorithm pertains to this specific dataset. It is not a substitute for careful clinical assessment and judgment,

which should continue to form the basis for decisions around the need for surgical excision or other treatment.

Formal diagnostic algorithms have not previously been evaluated in the management of OSSN, although it seems likely that most clinicians implicitly go through a similar process when forming a clinical impression. The results of our previous study in Kenya found that individual clinical features were not specific for OSSN, being found in variable proportions in malignant and benign lesions.<sup>9</sup> However, when clinicians were asked to provide an overall categorisation of OSSN or not OSSN their sensitivity and specificity were similar to the performance of the model we describe here. This suggests that clinicians who are experienced in examining such patients are integrating the information provided by the combination of clinical features to draw similar conclusions about the nature of the pathology.

This study had several limitations. Firstly, as with many diagnostic tests, there is a trade-off between sensitivity and specificity. Secondly, it can be difficult to standardize the assessment of some clinical features such as the degree of inflammation. Although histopathology is the gold standard for diagnosis it is still open to individual interpretation. Some non-OSSN lesions such as pterygia and actinic keratosis have been shown in several studies to share some histological and etiological features with OSSN.<sup>15-17</sup> Extrapolation of these results or direct comparison with other populations of OSSN patients requires caution as the pattern of disease in this population appears quite distinct from that seen in more temperate regions.

In conclusion, ToB staining is less specific and predictive than clinical examination by an Ophthalmologist but it may be useful for other health care workers screening patients for the disease, and when there is no ToB staining, to reassure that the disease is unlikely to be malignant. We developed a simple model with various combinations of clinical features that could identify a high proportion of OSSN cases and give an indication of the probability of disease. This could be used to estimate the risk of OSSN. However, it is context-specific and given the clinical overlap between OSSN and non-OSSN lesion, this should not be regarded as a substitute for histological assessment.

**Table 9.1. Univariate analysis of the development dataset, showing variables that were associated with OSSN with a p-value <0.05. Ranked in descending order of odds ratios.**

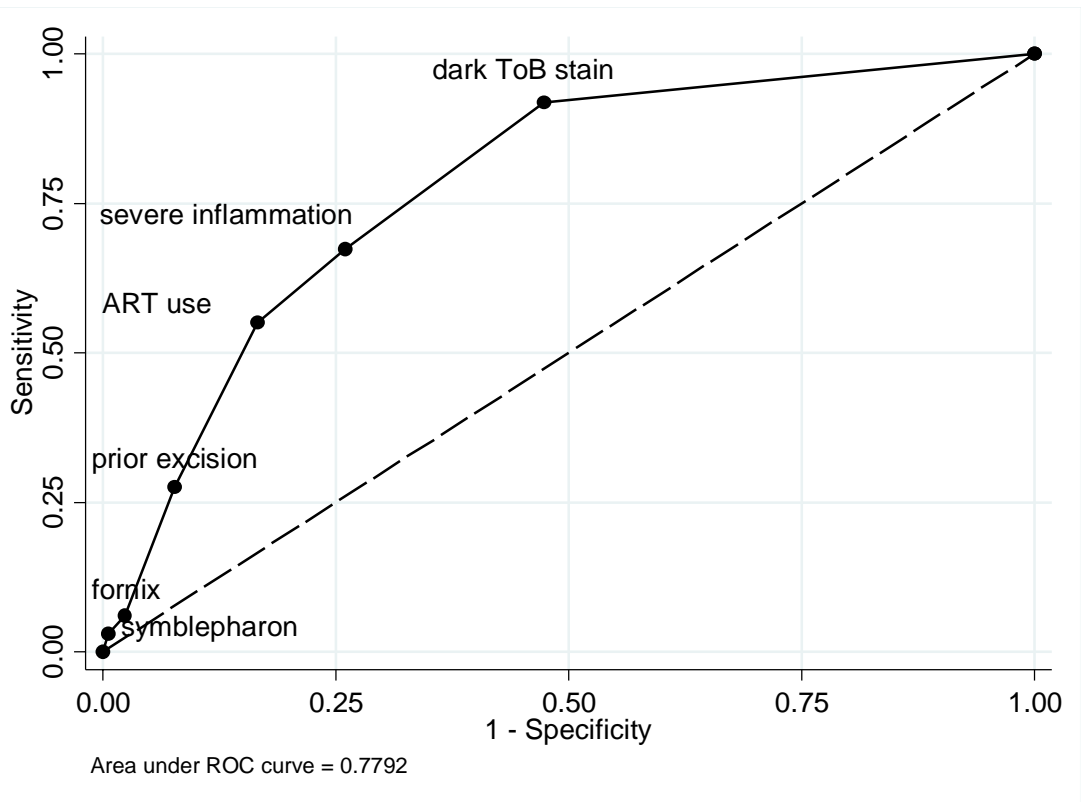
<b>Variable</b>	<b>OSSN N=139</b>		<b>Benign N=233</b>		<b>Crude OR</b>	<b>(95%CI)</b>	<b>p-value</b>
	<b>n</b>	<b>(%)</b>	<b>n</b>	<b>(%)</b>			
Feeder vessels	124	(91.2)	148	(64.1)	5.80	(3.02-11.11)	<0.001
Prior excision of present lesion	28	(20.1)	12	(5.2)	4.65	(2.28-9.48)	<0.001
ART use	53	(41.4)	26	(13.4)	4.57	(2.65-7.86)	<0.001
Any toluidine blue staining	99	(90.8)	144	(69.2)	4.40	(2.15-8.98)	<0.001
No formal education	14	(10.1)	6	(2.6)	4.24	(1.59-11.30)	0.004
Fornix involvement	9	(6.5)	4	(1.7)	3.95	(1.19-12.07)	0.03
Papillary or gelatinous surface	126	(92.0)	173	(74.9)	3.84	(1.94-7.61)	<0.001
Dark royal blue Toluidine staining	72	(66.1)	71	(34.1)	3.75	(2.30-6.12)	<0.001
Severe inflammation	50	(36.5)	36	(15.5)	3.14	(1.91-5.17)	<0.001
Corneal involvement	92	(67.2)	96	(41.4)	2.90	(1.86-4.51)	<0.001
Temporal or circumlimbal tumour	48	(34.5)	41	(17.6)	2.47	(1.52-4.01)	<0.001
Any inflammation	122	(89.1)	179	(76.8)	2.45	(1.32-4.55)	0.004
Leukoplakia	95	(69.9)	116	(50.0)	2.32	(1.48-3.63)	<0.001
Age group, n(%) y							
18-29	15	(10.8)	42	(18.0)	1.00	(REF)	0.01
30-39	49	(35.3)	103	(44.2)	1.33	(0.67-2.63)	
40-49	47	(33.8)	52	(22.3)	2.53	(1.25-5.14)	
50-59	19	(13.7)	23	(9.9)	2.31	(0.99-5.39)	
60-69	3	(2.2)	10	(4.3)	0.84	(0.20-3.47)	
70-79	6	(4.3)	3	(1.3)	5.60	(1.24-25.25)	

**Table 2. Multivariable logistic regression analysis of predictors of OSSN identified using the development dataset and applied to the validation dataset.**

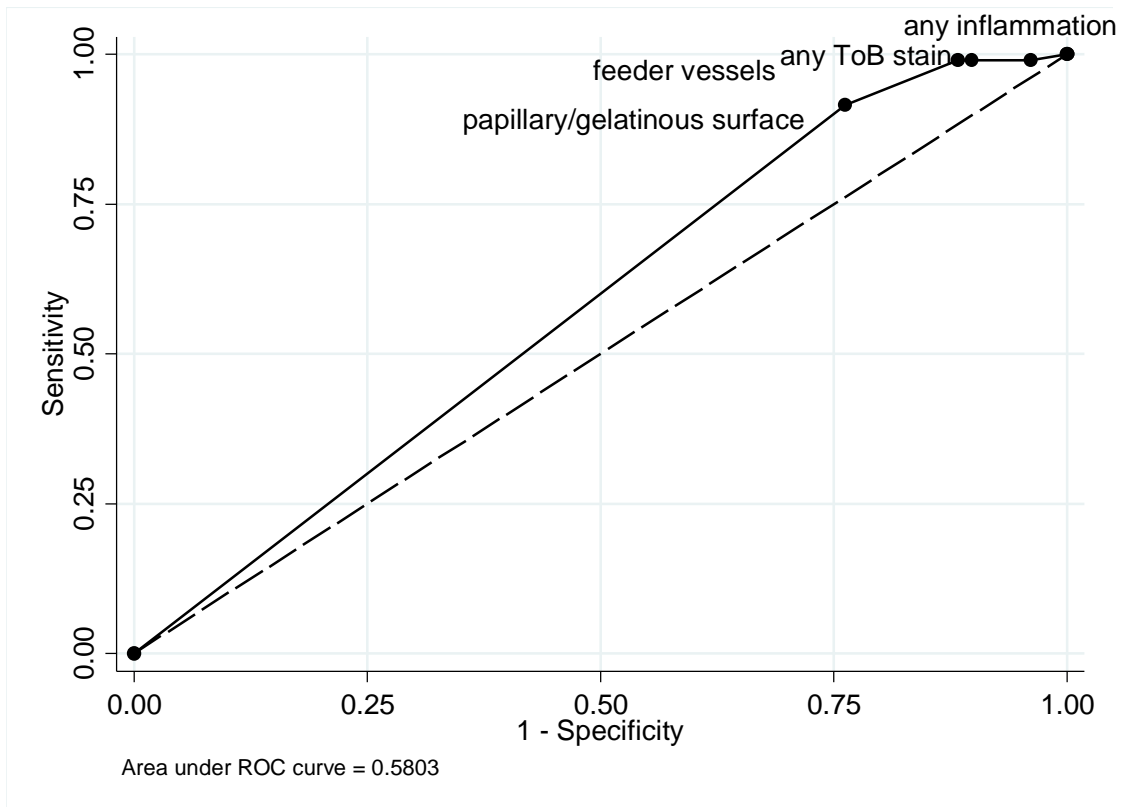
Variable	Development set (N=372)			Validation set (N=124)		
	Adjusted OR	(95%CI)	p-value	Adjusted OR	(95%CI)	p-value
Prior excision of the present lesion	4.51	(1.64-12.42)	0.004	0.55	(0.09-3.23)	0.51
Corneal involvement	3.66	(1.93-6.95)	<0.001	3.28	(1.13-9.55)	0.03
Feeder vessels	3.38	(1.32-8.62)	0.01	2.57	(0.75-8.79)	0.13
Dark royal blue Toluidine staining	3.08	(1.61-5.88)	0.001	2.56	(0.92-7.14)	0.07
Papillary or gelatinous tumour surface	2.98	(1.09-8.09)	0.03	1.57	(0.46-5.39)	0.47
Severe inflammation	2.91	(1.39-6.10)	0.005	1.20	(0.40-3.63)	0.74
ART use	2.32	(1.10-4.89)	0.03	1.27	(0.41-3.91)	0.67
Temporal or circumlimbal tumour	2.21	(1.09-4.45)	0.03	1.84	(0.55-6.13)	0.32

**Figure 9.1. Receiver operator characteristic (ROC) curves plotted from the three models using the development dataset: (A) Specificity-based model; (B) Sensitivity-based model; (C) Regression-based model.** The area under the curve is shown under each plot eg 0.7792=77.92%. The cut-off point is the point at which we make the OSSN vs non-OSSN distinction. Read the curves from the origin of the x and y axis. For instance in (A) the options are using symblepharon alone, then the next is using symblepharon or fornix, then symblepharon or fornix or prior excision and so on such that the last point refers to a cut-off point where we use any one of symblepharon or fornix involvement or prior excision or ART use or severe inflammation or dark ToB staining. For (B) the cut-off point was papillary/gelatinous surface. For (C) similarly we read it from the origin and use either all 8 features listed in Table 9.2, or 7 features or 6 features and so forth with the last option being the use of only 1 feature. The cut off was any 3 of the 8 features listed in Table 9.2.

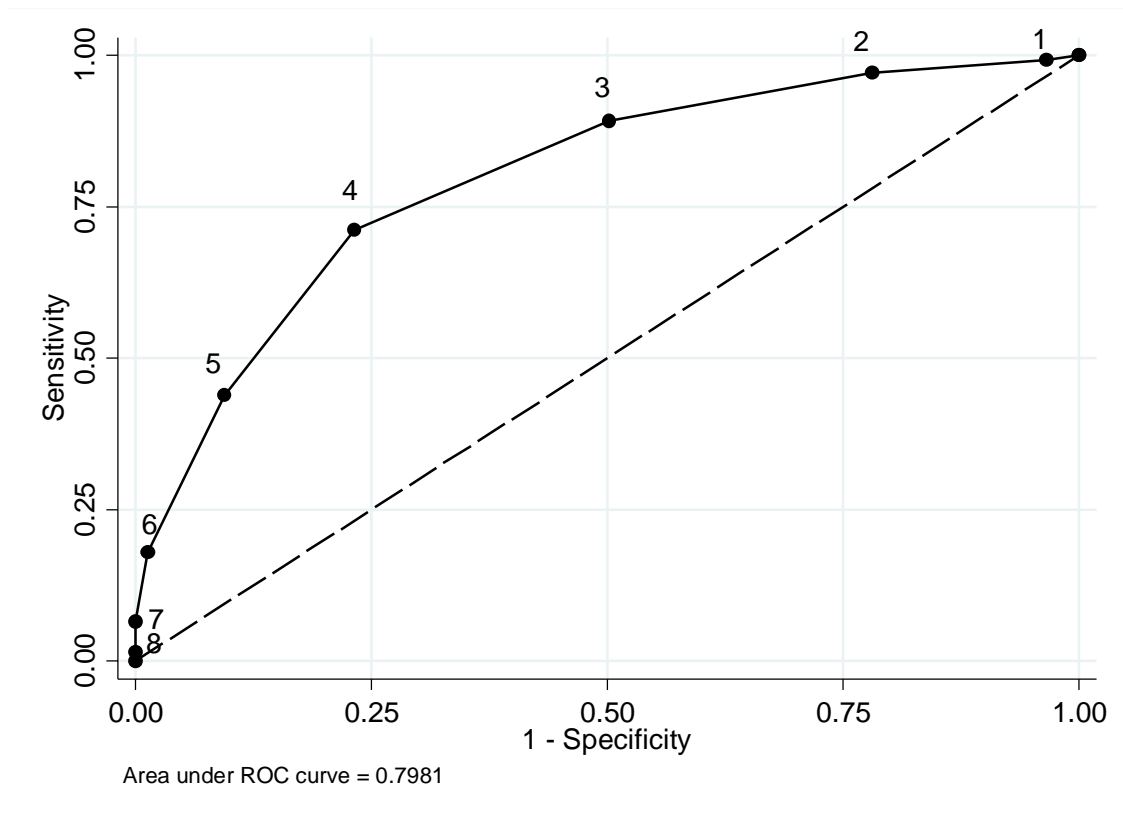
**(A) Specificity-based model**



**(B) Sensitivity-based model**



**(C) Regression-based model**



**Table 9.3. Performance of different diagnostic tools for diagnosing OSSN in the validation dataset and Toluidine blue data and photograph examination from a previous study.<sup>9,11</sup>**

<b>Diagnostic tool</b>	<b>Sensitivity</b>	<b>Specificity</b>	<b>PV+</b>	<b>PV-</b>	<b>Correctly classified</b>	<b>F+ rate</b>	<b>F- rate</b>	<b>LR+</b>	<b>LR-</b>
Toluidine blue (any blue)	92%	31%	41%	88%	52%	69%	8%	1.33	0.26
Toluidine blue (dark royal blue)	64%	67%	50%	78%	66%	33%	36%	1.95	0.53
Clinical examination of photographs <sup>a</sup>	86%	60%	54%	88%	70%	40%	14%	2.15	0.23
Regression based model <sup>b</sup>	83%	54%	53%	84%	65%	46%	17%	1.81	0.31
Specificity based model <sup>b</sup>	75%	45%	47%	73%	57%	55%	25%	1.38	0.55
Sensitivity based model <sup>b</sup>	85%	31%	44%	77%	50%	69%	15%	1.22	0.50

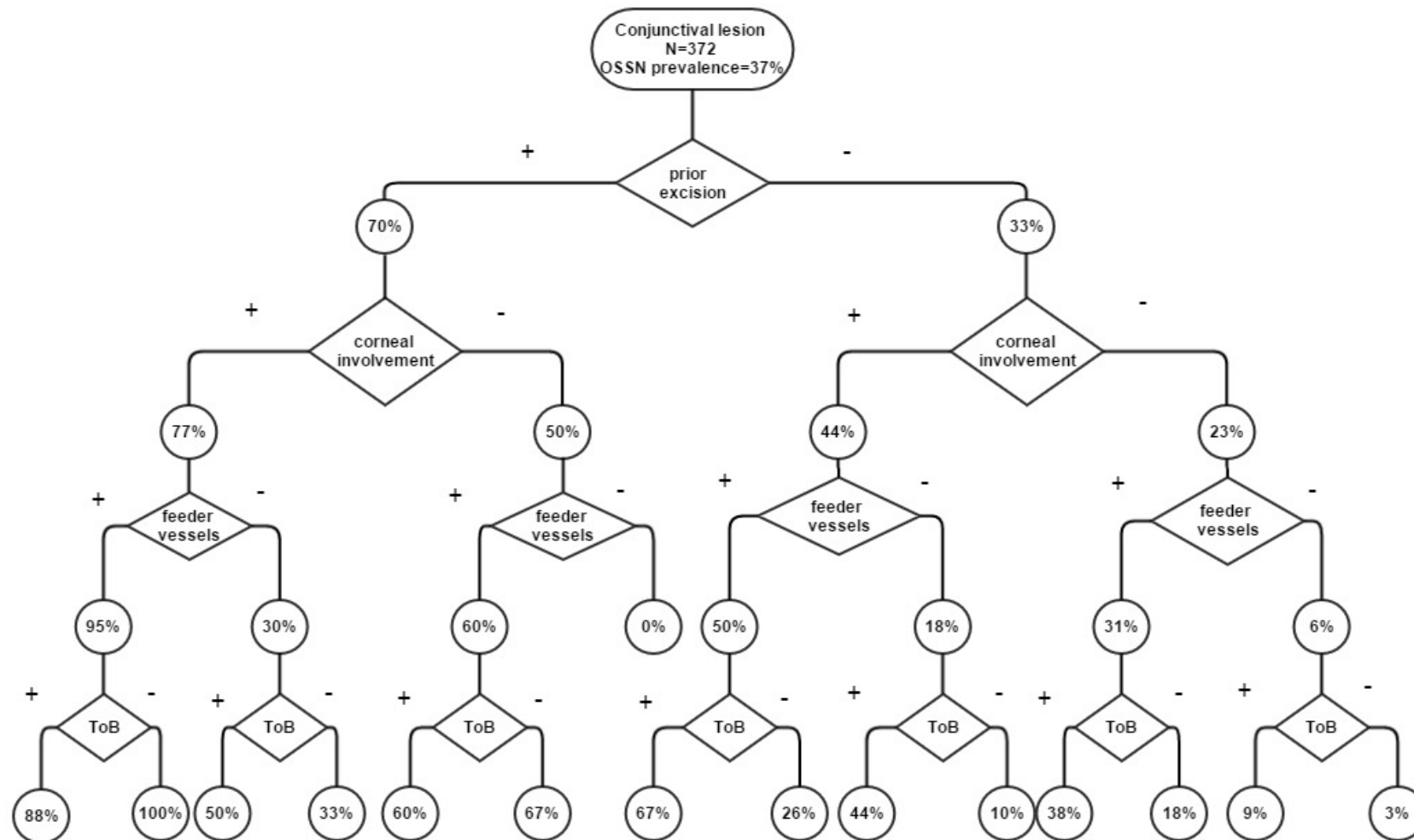
NOTE: Abbreviations; PV means predictive value, F+ means false positive, F- means false negative, LR means likelihood ratio

<sup>a</sup> This was the median score of 6 examiners looking at lesion photos without vital staining

<sup>b</sup> This is at the best cut-offs shown in the ROC curves we plotted.



**Figure 9.2. Probability-tree algorithm for determining the probability of OSSN in the specific data set presented in this study. This uses the features most strongly associated with OSSN added in the order shown in table 9.2. The probability of OSSN at each level is shown in the circles.**



NOTE: + means present and - means absent. To illustrate the use this algorithm, we first ask whether there is history of prior excision of the present lesion or not. If present, the probability of OSSN is 70% and if not it is 30%. Next we determine the presence of corneal involvement. If the patient had prior excision and the cornea is involved the risk of OSSN is 77%. We can further determine the presence of feeder vessels in this patient. If present, the risk of OSSN increases to 95%.

**Supplementary Table: All the features evaluated for inclusion in the algorithm.**

<b>Clinical feature</b>	<b>Sensitivity</b>	<b>Specificity</b>	<b>LR(+)</b>
<b>History</b>			
Age group	4.3%	98.7%	3.35
Female gender	66.2%	33.5%	1.00
Any formal education	89.9%	2.6%	0.92
Outdoor occupation	65.0%	43.0%	1.14
History of any smoking	30.2%	74.0%	1.16
Current smoking	14.5%	90.4%	1.52
Ocular pain	10.8%	86.7%	0.81
Ocular redness	5.8%	94.4%	1.03
Prior lesion excision	20.1%	94.8%	3.91
Allergic conjunctivitis history	0.7%	97.9%	0.34
HIV infection	80.2%	7.4%	0.87
ART	41.4%	86.6%	3.09
<b>Clinical Examination</b>			
Inflammation (any)	89.1%	23.2%	1.16
Inflammation (mod/severe)	36.5%	84.5%	2.36
Leukoplakia	69.9%	50.0%	1.40
Erythroplakia	15.3%	84.1%	0.97
Pigment	51.8%	57.8%	1.23
Papilliform/ gelatinous surface	92.0%	25.1%	1.23
Feeder vessels	91.2%	35.9%	1.42
Corneal involvement	67.2%	58.6%	1.62
Symblepharon	2.9%	99.1%	3.38
Fornix involvement	6.5%	98.3%	3.76
ToB stain (any blue)	90.8%	30.8%	1.31
ToB stain (dark royal blue)	66.1%	65.9%	1.94

NOTE: Abbreviations; LR(+) likelihood ratio of a positive test; ToB- toluidine blue; ART- antiretroviral therapy

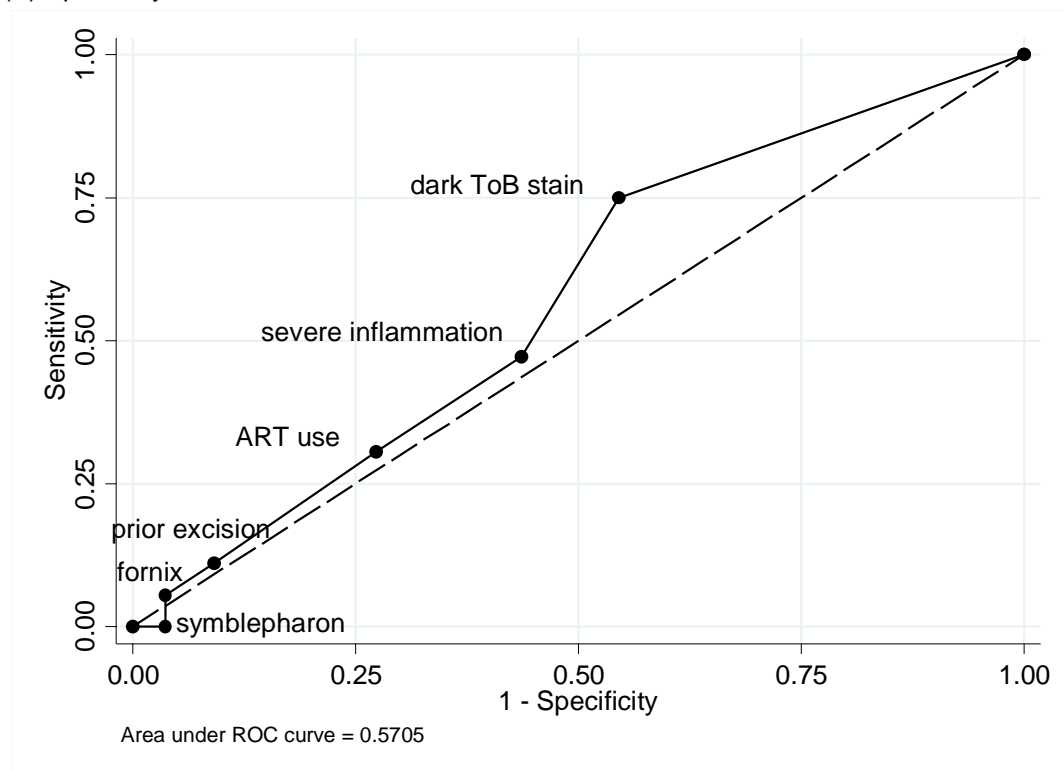
**Supplementary Figure: Receiver operator characteristic (ROC) curves plotted from the three models using the validation dataset: (A) Specificity-based model; (B) Sensitivity-based model; (C) Regression-based model.**

LEGEND: The area under the curve is shown under each plot eg 0.7792=77.92%. The cut-off point is the point at which we make the OSSN vs non-OSSN distinction. Read the curves from the origin of the x and y axis. For instance in A) the options are using symblepharon alone, then the next is using symblepharon or fornix, then symblepharon or fornix or prior excision and so on such that the last point refers to a cut-off point where we use any one of symblepharon or fornix involvement or prior excision or ART use or severe inflammation or dark ToB staining.

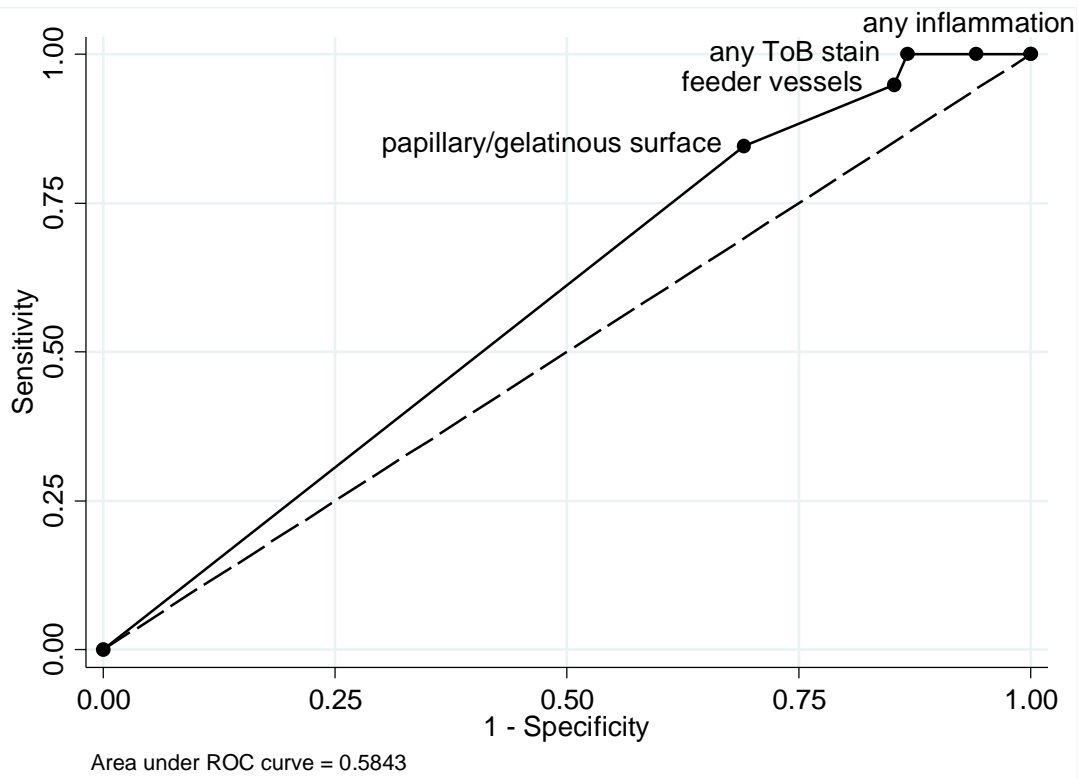
For (B) the cut-off point was papillary/gelatinous surface

For (C) similarly we read it from the origin and use either all 8 features listed in table 9.2 or 7 or 5 and so forth with the last option being the use of only 1 feature. it was any 3 of the 8 features listed in table 9.2.

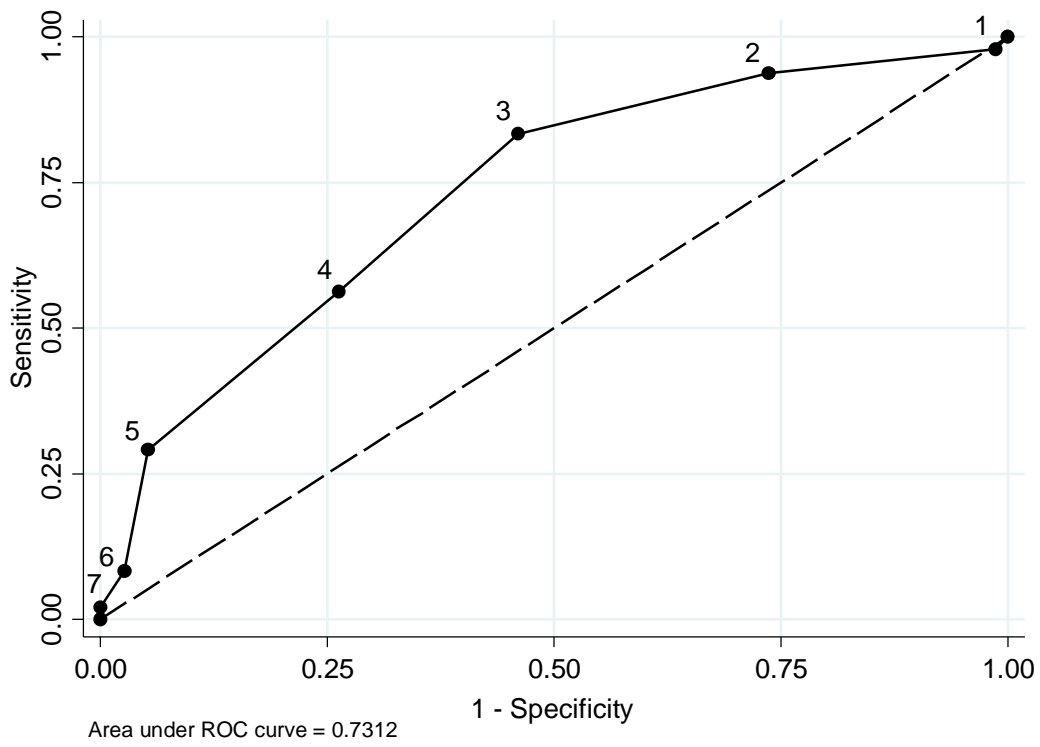
(A) Specificity-based model



(B) Sensitivity-based model



(C) Regression-based model



**Competing interests**

The authors have no conflict of interest disclosures. All authors have completed and submitted the ICMJE Form for Disclosure of Potential Conflicts of Interest and none were reported.

**Financial support**

SG received funding from the British Council for Prevention of Blindness (BCPB) fellowship programme. MJB is supported by The Wellcome Trust (Grant Number 098481/Z/12/Z). HAW and DM are supported by the MRC and DFID (Grant Number G0700837). The funding organizations had no role in the design or conduct of this research.

## References

1. Gichuhi S, Sagoo MS, Weiss HA, et al. Epidemiology of ocular surface squamous neoplasia in Africa. *Tropical medicine & international health : TM & IH* 2013;**18**(12):1424-43.
2. Chebbi A, Bouguila H, Boukari M, et al. [Prognosis of primary malignant tumors of the conjunctiva]. *Journal francais d'ophtalmologie* 2015;**38**(6):477-85.
3. Bonanno A, Esmaeli B, Fingeret MC, et al. Social challenges of cancer patients with orbitofacial disfigurement. *Ophthalmic plastic and reconstructive surgery* 2010;**26**(1):18-22.
4. Birkholz ES, Goins KM, Sutphin JE, et al. Treatment of ocular surface squamous cell intraepithelial neoplasia with and without mitomycin C. *Cornea* 2011;**30**(1):37-41.
5. Shields CL, Shields JA. Ocular Surface Squamous Neoplasia: From Blue Skies to Blue Dyes-We Still Need Our Ophthalmic Pathologists. *JAMA ophthalmology* 2015:1-2.
6. Adesina A, Chumba D, Nelson AM, et al. Improvement of pathology in sub-Saharan Africa. *The lancet oncology* 2013;**14**(4):e152-7.
7. Rambau PF. Pathology practice in a resource-poor setting: Mwanza, Tanzania. *Archives of pathology & laboratory medicine* 2011;**135**(2):191-3.
8. Adler E, Turner JR, Stone DU. Ocular surface squamous neoplasia: a survey of changes in the standard of care from 2003 to 2012. *Cornea* 2013;**32**(12):1558-61.
9. Gichuhi S, Macharia E, Kabiru J, et al. Clinical Presentation of Ocular Surface Squamous Neoplasia in Kenya. *JAMA ophthalmology* 2015;**133**(11):1305-13.
10. Nguena MB, van den Tweel JG, Makupa W, et al. Diagnosing ocular surface squamous neoplasia in East Africa: case-control study of clinical and in vivo confocal microscopy assessment. *Ophthalmology* 2014;**121**(2):484-91.
11. Gichuhi S, Macharia E, Kabiru J, et al. Toluidine Blue 0.05% Vital Staining for the Diagnosis of Ocular Surface Squamous Neoplasia in Kenya. *JAMA ophthalmology* 2015;**133**(11):1314-21.
12. Romero IL, Barros Jde N, Martins MC, et al. The use of 1% toluidine blue eye drops in the diagnosis of ocular surface squamous neoplasia. *Cornea* 2013;**32**(1):36-9.
13. Steffen J, Rice J, Lecuona K, et al. Identification of ocular surface squamous neoplasia by in vivo staining with methylene blue. *The British journal of ophthalmology* 2014;**98**(1):13-5.
14. Lopman BA, Barnabas RV, Boerma JT, et al. Creating and validating an algorithm to measure AIDS mortality in the adult population using verbal autopsy. *PLoS Med* 2006;**3**(8):e312.
15. Di Girolamo N. Association of human papilloma virus with pterygia and ocular-surface squamous neoplasia. *Eye (Lond)* 2012;**26**(2):202-11.
16. Dushku N, Hatcher SL, Albert DM, et al. p53 expression and relation to human papillomavirus infection in pingueculae, pterygia, and limbal tumors. *Archives of ophthalmology* 1999;**117**(12):1593-9.
17. Hirst LW, Axelsen RA, Schwab I. Pterygium and associated ocular surface squamous neoplasia. *Archives of ophthalmology* 2009;**127**(1):31-2.

## Chapter 10. Risk factors for ocular surface squamous neoplasia in Kenya





**Registry**

T: +44(0)20 7299 4646  
F: +44(0)20 7299 4656  
E: registry@lshtm.ac.uk

## RESEARCH PAPER COVER SHEET

**PLEASE NOTE THAT A COVER SHEET MUST BE COMPLETED FOR EACH RESEARCH PAPER INCLUDED IN A THESIS.**

### SECTION A – Student Details

<b>Student</b>	Stephen Gichuhi
<b>Principal Supervisor</b>	Matthew J. Burton
<b>Thesis Title</b>	Epidemiology and management of ocular surface squamous neoplasia in Kenya

**If the Research Paper has previously been published please complete Section B, if not please move to Section C**

### SECTION B – Paper already published

Where was the work published?			
When was the work published?			
If the work was published prior to registration for your research degree, give a brief rationale for its inclusion			
Have you retained the copyright for the work?*	Choose an item.	Was the work subject to academic peer review?	Choose an item.

*\*If yes, please attach evidence of retention. If no, or if the work is being included in its published format, please attach evidence of permission from the copyright holder (publisher or other author) to include this work.*

### SECTION C – Prepared for publication, but not yet published

Where is the work intended to be published?	Tropical Medicine & International Health
Please list the paper's authors in the intended authorship order:	Stephen Gichuhi, Ephantus Macharia, Joy Kabiru, Alain Mbongo Zindamoyen, Hilary Rono, Ernest Ollando, Joseph Wachira, Rhoda Munene, Timothy Onyuma, Walter G. Jaoko, Mandeep S. Sagoo, Helen A. Weiss, and Matthew J. Burton
Stage of publication	<b>Not yet submitted</b>

### SECTION D – Multi-authored work

For multi-authored work, give full details of your role in the research included in the paper and in the preparation of the paper. (Attach a further sheet if necessary)	I coordinated and actively led the field work for this paper. Supervision was provided by Matthew Burton throughout. I also performed the statistical analysis, with some guidance from Helen Weiss. I wrote the paper with consideration of comments from co-authors.
--	--

Student Signature: Stephen Gichuhi

Date: 4th February 2016

Supervisor Signature: M. J. Burton

Date: 4th February 2016



# Risk factors for Ocular Surface Squamous Neoplasia in Kenya; a case-control study

## Authors:

Stephen Gichuhi MBChB, M.Med<sup>1,2</sup>, Ephantus Macharia HND<sup>3</sup>, Joy Kabiru MBChB, M.Med<sup>3</sup>, Alain M'bongo Zindamoyen MBChB, M.Med<sup>3</sup>, Hilary Rono MBChB, M.Med<sup>4</sup>, Ernest Ollando MBChB, M.Med<sup>5</sup>, Joseph Wachira MBChB, M.Med<sup>6</sup>, Rhoda Munene MBChB, M.Med<sup>6</sup>, Timothy Onyuma MBChB, M.Med<sup>7</sup>, Walter G. Jaoko MBChB, PhD<sup>8</sup>, Mandeep S. Sagoo PhD, FRCOphth<sup>9,10,11</sup>, Helen A. Weiss MSc, PhD<sup>1,12</sup> and Matthew J. Burton PhD, FRCOphth<sup>1,10</sup>

## Email contacts

Stephen Gichuhi, [stephen.gichuhi@lshtm.ac.uk](mailto:stephen.gichuhi@lshtm.ac.uk)  
Ephantus Macharia, [machariaew@yahoo.co.uk](mailto:machariaew@yahoo.co.uk)  
Joy Kabiru, [joykabiru@yahoo.com](mailto:joykabiru@yahoo.com)  
Alain M'bongo Zindamoyen, [zindamoyen@yahoo.com](mailto:zindamoyen@yahoo.com)  
Hilary Rono, [hkrono@yahoo.com](mailto:hkrono@yahoo.com)  
Ernest Ollando, [eollando@yahoo.com](mailto:eollando@yahoo.com)  
Joseph Wachira, [drjwachira@gmail.com](mailto:drjwachira@gmail.com)  
Rhoda Munene, [drmunene@nairobioplasty.co.ke](mailto:drmunene@nairobioplasty.co.ke)  
Timothy Onyuma, [tonyuma@mpshahhosp.org](mailto:tonyuma@mpshahhosp.org)  
Walter G. Jaoko, [wjaoko@kaviuon.org](mailto:wjaoko@kaviuon.org)  
Mandeep S. Sagoo, [mandeep.sagoo@moorfields.nhs.uk](mailto:mandeep.sagoo@moorfields.nhs.uk)  
Helen A. Weiss, [helen.weiss@lshtm.ac.uk](mailto:helen.weiss@lshtm.ac.uk)  
Matthew J. Burton, [matthew.burton@lshtm.ac.uk](mailto:matthew.burton@lshtm.ac.uk)

## Corresponding Author:

Stephen Gichuhi  
International Centre for Eye Health  
London School of Hygiene & Tropical Medicine  
Keppel Street, London WC1E 7HT  
United Kingdom  
Tel. +44 (20) 7636 8636 ext. 8257  
[stephen.gichuhi@lshtm.ac.uk](mailto:stephen.gichuhi@lshtm.ac.uk)

## Financial support

SG received funding from the British Council for Prevention of Blindness (BCPB) fellowship programme. HAW is supported by the MRC and DFID (Grant Number G0700837). MJB is supported by The Wellcome Trust (Grant Number 098481/Z/12/Z). The funding organizations had no role in the design or conduct of this research.

## Running head

Risk factors for OSSN in Kenya

## Affiliations:

<sup>1</sup>International Centre for Eye Health, London School of Hygiene and Tropical Medicine, Keppel Street, London, WC1E 7HT, UK

<sup>2</sup>Department of Ophthalmology, University of Nairobi, P.O Box 19676-00202, Nairobi, Kenya

<sup>3</sup>PCEA Kikuyu Eye Unit, PO Box 45, Kikuyu, Kenya

<sup>4</sup>Kitale District Hospital, PO Box 98-30200, Kitale, Kenya

<sup>5</sup>Sabatia Eye Hospital, PO Box 214-50311, Wodanga, Kenya

<sup>6</sup>Kenyatta National Hospital, PO Box 20723-00202, Nairobi, Kenya

<sup>7</sup>MP Shah Hospital, Department of Pathology, PO Box 14497-00800, Nairobi, Kenya

<sup>8</sup>KAVI Institute of Clinical Research, University of Nairobi, P.O Box 19676-00202, Nairobi, Kenya

<sup>9</sup>UCL Institute of Ophthalmology, 11-43 Bath Street, London EC1V 9EL, UK

<sup>10</sup>Moorfields Eye Hospital, 162 City Road, London, EC1V 2PD, UK

<sup>11</sup>St. Bartholomew's Hospital, W Smithfield, London EC1A 7BE, London, UK

<sup>12</sup> MRC Tropical Epidemiology Group, London School of Hygiene and Tropical Medicine, Keppel Street, London, WC1E 7HT,

**Author contributions:**

Dr Gichuhi had full access to all the data in the study and takes responsibility for the integrity of the data and the accuracy of the data analysis.

*Study concept and design:* Gichuhi, Jaoko, Sagoo, Weiss, Burton

*Acquisition, analysis, or interpretation of data:* All authors

*Drafting of the manuscript:* Gichuhi, Sagoo, Weiss, Burton

*Critical revision of the manuscript for important intellectual content:* All authors

*Statistical analysis:* Gichuhi, Weiss, Burton

*Obtained funding:* Gichuhi, Burton

*Administrative, technical, or material support:* Zindamoyen, Rono, Ollando, Jaoko, Sagoo, Burton

*Study supervision:* Burton, Weiss

**Conflict of interest disclosures:**

All authors have completed and submitted the ICMJE Form for Disclosure of Potential Conflicts of Interest and none were reported.

Word count:

Text - 2992

Abstract - 255

## **ABSTRACT**

### **Introduction**

In East Africa, ocular surface squamous neoplasia (OSSN) is a relatively common aggressive disease affecting younger adults and more women than in other parts of the world. Studies have implicated HIV, human papilloma virus (HPV) and solar radiation as risk factors. The aim of this study was to determine modifiable risk factors of OSSN in Kenya using disease-free controls.

### **Methods**

Adults with conjunctival lesions were recruited at four eye care centres in Kenya and excision biopsy performed. An equal number of controls having surgery for conditions not affecting the conjunctiva and unrelated to ultraviolet light were group-matched to cases by age group, sex and eye care centre. Associations of risk factors with OSSN were evaluated using multivariable logistic regression to estimate odds ratios (ORs) and 95% confidence intervals (95%CI). Continuous variables were compared using the t-test or the Wilcoxon-Mann-Whitney U test depending on their distribution.

### **Results**

A total of 131 cases and 131 controls were recruited. About two-thirds of participants were female and the mean age of cases and controls was 42.1 years and 43.3 years respectively. Risk factors for OSSN were HIV infection without antiretroviral therapy (ART) use (OR=48.30; 95%CI 7.53-309.90) and with ART use (OR=19.02; 95%CI 6.55-55.26), longer duration of exposure to the sun in the main occupation (6.9 hrs/day vs 4.6 hrs/day, OR=1.23; 95%CI 1.08-1.39) and a history of allergic conjunctivitis (OR=80.20; 95%CI 8.62-746.29). Wearing hats was protective (OR=0.21; 95%CI 0.07-0.63).

### **Discussion**

Measures to prevent and control HIV, prevent sun exposure such as wearing hats, and control allergic conjunctivitis are recommended.

## Background

Ocular surface squamous neoplasia (OSSN) is a spectrum of disease in the conjunctiva and cornea that ranges from intraepithelial neoplasia to invasive squamous cell carcinoma. It usually presents as a unilateral tumour on the eye, centred around the corneal limbus (the junction between the cornea and conjunctiva).<sup>1</sup>

The epidemiology, aetiology and pathophysiology of OSSN are not well understood. There appears to be two disease patterns: a milder form in temperate climates and a more aggressive one in sub-Saharan Africa (SSA). In SSA both males and females have equal incidence rates, although in prevalence series females constitute 60-70%, in contrast to other regions where males predominate.<sup>2,3</sup> It is unclear why the prevalence is not 1:1 in African series. The presentation of OSSN in SSA also is relatively more aggressive, with a short history of 3 to 8 months compared to one year in temperate climates<sup>4-7</sup>, and younger age of onset (30-40 years in SSA compared with 60-70 years in temperate climates).<sup>2,3,8</sup> Current evidence suggests that multiple factors may combine to drive the disease process. Case-control studies and cancer registry data implicate ambient solar ultraviolet radiation (UVR) among other factors. The risk of OSSN is higher in those who spend more time outdoors and the incidence worldwide varies with latitude peaking at 16° South, particularly in the sunny areas of Eastern and Southern Africa, and also Australia.<sup>2,9-11</sup> This may be related to the Earth's 23° tilt and elliptical orbit which brings it closer to the sun during the southern summers (perihelion) than during the northern summer (aphelion).<sup>12</sup> The *TP-53* gene mutation, which is associated with UV radiation, has been found more frequently in OSSN tissue.<sup>11,13</sup>

There is a strong association between OSSN and HIV in SSA, and incidence rose sharply with the onset of the HIV pandemic.<sup>14</sup> However, about 30% of people with OSSN in SSA are not infected with HIV, suggesting that other factors also contribute.<sup>2</sup> The association between human papilloma virus (HPV) and OSSN is inconclusive.<sup>15-20</sup> This is probably because of variations in methodology and the specific HPV types that have been looked for.<sup>2</sup>

The importance of vitamin A in maintaining the health of the ocular surface is established and its deficiency leads to goblet cell loss, desquamation and keratinization of the ocular surface.<sup>21</sup> Vitamin A deficiency (serum retinol <30 µg/dL or <1.05 µmol/L) is common in HIV patients.<sup>22</sup> The potential role of vitamin A deficiency in OSSN has not previously been investigated. Cigarette smoking although associated with many cancers has not been conclusively shown to be associated with OSSN.<sup>2</sup>

To date, case-control studies investigating risk factors for OSSN have enrolled individuals with conjunctival lesions suspected to be OSSN, which were excised and sent for histopathology. Individuals with OSSN were classified as “cases” and those with benign lesions as “controls”.<sup>6,11,13,23</sup> However, these are probably not appropriate controls, as benign conjunctival lesions may have some risk factors in common with OSSN. For example, pterygia, actinic keratosis and papillomas, the most common benign lesions, may also be associated with solar UV radiation, p53 gene mutation, and human papillomavirus infection.<sup>24-27</sup>

The aim of this study was to investigate the role of multiple risk factors (HIV infection, vitamin A, cigarette smoking, ultraviolet light exposure and occupation), which are preventable or modifiable, by comparing OSSN cases to disease-free controls presenting at four eye care centres in Kenya.

## **Methods**

### *Ethical Approval*

This study was approved by the Kenyatta National Hospital – University of Nairobi Ethics and Research Committee and the London School of Hygiene & Tropical Medicine Ethics Committee. All participants gave informed written consent to take part. It adhered to the tenets of the Declaration of Helsinki.

### *Study design*

A frequency matched case-control study design was used, with a 1:1 case to control ratio. Matching was by age (10-year age groups) and sex, as both are strong constitutional factors associated with OSSN. Cases of OSSN (subsequently confirmed by histology to have OSSN) were compared with controls who had no conjunctival lesion, attending for routine ophthalmic surgery that involved incision of the conjunctiva. Controls were recruited at the same ophthalmic clinics after cases were enrolled.

### *Study setting*

Cases were recruited between July 2012 and July 2014 while controls were enrolled between January 2014 and May 2015 in four eye care centres in Kenya namely; Kenyatta National Hospital (KNH) Eye Clinic, Nairobi; PCEA Kikuyu Eye Unit (KEU), Kikuyu near Nairobi; Sabatia Eye Hospital (SEH), Vihiga about 350 kilometres north-west of Nairobi near Lake Victoria; and Kitale District Hospital (KDH) in the North Rift Valley. These are busy eye units that receive referrals from surrounding areas (Table 10.1).

### *Study population, inclusion & exclusion criteria*

Both cases and controls were recruited from people attending the eye clinic. Adult patients (aged  $\geq 18$  years) with any histologically confirmed OSSN tumour (first presentation or recurrence) were included as cases. Controls were adult patients scheduled for ocular surgery that involved a conjunctival incision for a disease not involving the conjunctiva and unrelated to ultraviolet light. History of prior surgery in the index eye was an exclusion criterion for controls. Eligible participants who gave written informed consent to participate were enrolled.

### *Demographic and Occupational Data*

Data on age, sex, marital status and educational history were collected. Questions included: residential history (regions lived in for  $\geq 1$  year), lifetime occupational history (including whether based mainly indoors or outdoors), hours of sun exposure on an average day, patterns of wearing hats, caps or sunglasses, and cigarette smoking history. Participants with regular partners who smoked cigarettes were classified as passive smokers.

### *Clinical examination*

For potential cases (participants with conjunctival lesions) a detailed clinical and slit lamp examination was performed, to document clinical features of the tumours. High-resolution digital photographs were taken. For potential controls the ocular surface was examined at the slit lamp before surgery to exclude any conjunctival lesions.

### *Surgical excision & histopathology*

All lesions were excised under local infiltration anaesthetic using an operating microscope with a 3mm clear margin. Specimens were placed directly into buffered formalin and subsequently examined at the histopathology laboratory at the MP Shah Hospital, Nairobi. All the histology slides were stained with haematoxylin and eosin and examined by one pathologist (TO). For controls a 2mm by 2mm piece of conjunctiva was excised and immediately placed in RNALater tissue collection RNA stabilization solution (Ambion Inc, Austin, Texas, USA) for further molecular studies.

### *HIV / CD4 Count Assays*

Individuals with a confirmed diagnosis of OSSN were tested for HIV and CD4 cell count four weeks after the surgery when they returned for results. Controls were tested for HIV and CD4 at the time of surgery. Pre-test counselling was provided individually to all participants by a counsellor. Venous whole blood was tested at the Kenya Aids Vaccine Institute (KAVI) for Clinical Research laboratory at the University of Nairobi for HIV initially using Vironostika

antigen/antibody kit (Biomerieux, Marcy l'Etoile, France) then later the Alere Determine HIV-1/2 Ag/Ab (Alere, CITY, USA) and Trinity Unigold (Trinity Biotech, Jamestown, USA) when Vironostika became unavailable. CD4 count was measured using FacsCount (Becton Dickinson, Franklin Lakes, USA). Samples from Sabatia Eye Hospital and Kitale District Hospital were tested for HIV using Alere Determine HIV-1/2 Ag/Ab (Alere, CITY, USA) and for CD4 count using FacsCount (Becton Dickinson, Franklin Lakes, USA). We also asked about antiretroviral (ART) use.

#### *Serum vitamin A assays*

Blood samples collected without EDTA were immediately wrapped in aluminium foil to prevent degradation from light. They were transported to the KAVI laboratory in a cool box within an hour from nearby centres (KNH and KEU) or couriered on ice packs from more distant centres (SEH and KDH). On arrival samples were immediately centrifuged at 2500 revolutions per minute for 10 minutes in a dimly lit room, aliquoted into cryovials, labelled, re-wrapped in aluminium foil and stored in a freezer at -80°C. Samples were batched and shipped on dry ice to the Tropical Diseases Research Centre's Nutrition Unit in Ndola, Zambia. Retinol was quantified using high performance liquid chromatography.<sup>28</sup> The quantitation of retinol was done using the SHIMADZU Prominence HCT2010 HPLC (Kyoto, Japan). Individuals with serum retinol <30µg/dl were considered vitamin A deficient.

#### *Sample size determination*

This case-control study was nested within a randomised controlled trial of post-operative 5-fluorouracil eye drops to reduce recurrent OSSN. The sample size of 131 cases and 131 controls provides 90% power to detect a difference in prevalence of a given exposure of 40% in controls and 60% in cases.

#### *Statistical Analysis*

Data were managed in an Access database (Microsoft), cleaned and transferred into STATA version 12.1 (StataCorp, College Station, Texas, USA) for analysis. In this analysis we compared the cases and controls for the proportions with HIV/ART status, vitamin A deficiency, cigarette smoking and for levels of UV radiation exposure. We also compared cases and controls for the mean or median for CD4 count, number of cigarettes smoked daily and serum retinol levels. CD4 counts were graded by the WHO criteria.<sup>29</sup> All analyses were adjusted for age, sex and study centre. Multivariable logistic regression analysis was used to estimate odds ratios (ORs) and 95% confidence intervals (CIs). The likelihood ratio test was used to assess statistical significance of associations. Variables that were associated with the

outcome on univariable analyses at a level of  $p < 0.05$  were included in the multivariable analysis and then those with  $p < 0.2$  were retained in the model.

## Results

Five potential cases and six potential controls declined to participate. Two hundred and sixty-two participants were recruited: 131 cases and 131 controls frequency-matched by age group, sex and centre. About two-thirds were females (72% of cases and 65% of controls,  $p = 0.23$ ). The mean age and standard deviation (SD) of cases and controls were 42.1 years (SD=13.1) and 43.3 years (SD=13.2), respectively ( $p = 0.43$ ). The controls all had surgery for conditions without primary conjunctival pathology: lacerations ( $n = 41$ ), traumatic cataract ( $n = 39$ ), vitreous haemorrhage ( $n = 29$ ), retinal detachment ( $n = 18$ ) and squint surgery ( $n = 4$ ).

After adjusting for the matching variables, OSSN was significantly associated with lower education level (OR=4.24, 95%CI 1.33-13.53 for no education vs more than secondary), history of allergic conjunctivitis (OR=30.8, 95%CI 4.05-233) and outdoor occupations (OR=1.73, 95%CI 1.03-2.91; Table 10.2). There was a strong association with HIV infection (OR=19.0, 95%CI 8.87-40.5) and lower CD4 count (OR=38.16, 95%CI 8.15-178.7 for CD4  $< 200$  cells/mm<sup>3</sup> compared with CD4  $\geq 500$  cells/mm<sup>3</sup>). Participants living with HIV but not on ART were at the greatest risk (OR=39.4, 95%CI 8.35-185) compared with HIV non-infected participants, Table 10.2.

Independent risk factors for OSSN are shown in Table 10.3. Participants who HIV positive and not on ART were at the greatest risk (adjusted OR=48.30, 95%CI 7.53-309.9 compared with HIV negative participants), and there was also a very strong association with history of allergic conjunctivitis (adjusted OR=80.20, 95%CI 8.62-746.29). The duration of exposure to the sun per day in their occupations was higher among cases than controls (6.9 hours/day vs 4.6 hours/day,  $p < 0.001$ ). There was also a strong independent protective effect of wearing a hat or cap outdoors (OR=0.21, 95%CI 0.07-0.63).

## Discussion

OSSN appears to be a disease driven by multiple risk factors. In this study we set out to examine several of these in a large case-control study in Kenya nested within a randomised controlled trial, and confirmed established risk factors such as exposure to ultraviolet radiation and HIV-infection and some potential new ones such as allergic conjunctivitis.



This study design has several strengths compared with previous case-control studies. Most notably, previous studies have used controls with benign lesions which are on the causal pathway for OSSN, and this is likely to under-estimate the magnitude of their effects. For example, HIV is an established risk factor for OSSN, but we found a much stronger association of HIV and OSSN than previously reported in a meta-analysis of six case-control studies in East and Southern Africa (summary OR=6.17; 95%CI: 4.83-7.89).<sup>2</sup> Five of those studies were conducted in the era before ART programs were available or scaled up in the region while one was conducted in 2010 when ART was available in Ugandan public hospitals and did not report on ART use.<sup>30</sup> HIV is also associated with more severe OSSN disease. A study in India that compared HIV infected OSSN patients with HIV negative OSSN patients found that HIV infection was associated with larger tumours and a higher incidence of extension to the cornea, sclera and orbit but there was no data reporting ART use.<sup>31</sup> Although we had CD4 data on only 59 cases and 76 controls, it was intriguing that CD4 count was not a significant risk factor after multivariable adjustment. There may have been confounding with ART as those with low CD4 counts would be started on treatment and their CD4 count would subsequently rise. We observed that those on ART had higher mean CD4 counts than those who were not. (see footnote table 10.3). There was also an overlap in the confidence intervals between HIV infected people on ART and not on ART suggesting that ART did not seem to significantly change the effect of HIV infection on OSSN. This is further supported by the observation that OSSN is still common in Africa despite availability of ART programs for over a decade. Perhaps the effect of HIV on OSSN may not be through CD4 counts but rather a yet to be understood pathway. HIV-associated premature ageing may play a role in the aetiology as advancing age increases cancer risk.<sup>32</sup>

Another aspect of our study design is that we enrolled controls after cases had been recruited. There may be systematic differences between incident and prevalent OSSN cases which are difficult to identify in previous case-control studies that enrolled cases and controls concurrently.

Our study also focused on modifiable risk factors in order to identify strategies for prevention. We found a similar effect for duration of solar ultraviolet exposure outdoors to a study in Uganda (adjusted OR=1.7; 95% CI: 1.2-2.4 for cases exposed to 2-4 hours and OR=1.8; 95% CI: 1.1 - 3.1 for those exposed to  $\geq 5$  hours daily).<sup>11</sup> The association between OSSN and UV radiation has been shown by results from cancer registries and the previously mentioned case-control study in Uganda.<sup>2,11,33</sup> The latter had two types of controls per case; patients attending the eye clinic for reasons other than OSSN, and patients originally recruited as cases but whose histology was non-OSSN.<sup>11</sup> UV radiation affects the nasal limbus more than other parts

of the eye which explains why there is a higher proportion of both benign and malignant conjunctival lesions nasally than temporally.<sup>2,34,35</sup> Although cases had worked for a shorter period at their current occupations (10 years vs 15 years,  $p=0.04$ ), they were more likely to have outdoor occupations than controls (65% vs 50%) and had longer daily exposure to the sun at work ( $p<0.001$ ). The association we observed between less education and OSSN could have been due to those less educated people (particularly less than secondary school level) having jobs with greater sun exposure (means range from 6.5 – 8.4 hours/day) than controls (4.6 hours/day) but it persisted on adjustment suggesting residual confounding or an independent effect. The observed protective effect of wearing of hats while outdoors is consistent with UV radiation being a risk factor of OSSN. The earlier Uganda study did not find hats protective (OR=1.3; 95%CI 0.8 - 2.2).<sup>11</sup> We did not find sunglasses protective similar to the same Uganda study.

We found a relatively high prevalence of history of allergic conjunctivitis among cases (21.5%) which contrasts with previous studies. The aforementioned case-control study in Uganda reported no OSSN cases with allergic conjunctivitis, and a descriptive study in Tanzania found a prevalence of 1.9%.<sup>11,36</sup> The Uganda study examined for allergy in the nasal quadrant of the conjunctiva but they were unlikely to find allergy in adults in their 30s and 40s as typically the onset is in childhood and is rare after the age of 30 years. Allergic conjunctivitis is common in Africa. Studies in Ghana and Nigeria found allergic conjunctivitis in up to 40% of school children and 33% of University students respectively.<sup>37,38</sup> The disease also tends to be quite severe with limbal hypertrophy as shown in a Rwandan study where 98% of school children with vernal keratoconjunctivitis (VKC) had limbal disease.<sup>39</sup> Though not fully understood, limbal stem cells may be the progenitors in the pathophysiology of OSSN.<sup>40</sup> It is unclear whether allergic conjunctivitis or its treatment with steroids is the cause per se. One hypothesis may be that chronic allergic conjunctivitis is associated with a milieu of inflammation mediators which increases the probability of DNA errors during mitosis of stem cells at the limbus. Using corneal confocal microscopy, a study found that patients with VKC had more cells with a high nuclear to cytoplasm ratio (26.4% vs 7.5%), more activated cells (59% vs 10%) and inflammatory cells (75.4% vs 0) compared to controls.<sup>41</sup> On the contrary the other hypothesis may be that prolonged steroid use causes immunosuppression (like HIV might) which predisposes to OSSN.

This study had various weaknesses. Selection bias may be present if potential controls with a less serious disease than OSSN were not inclined to participate. The refusal rates were however not different for cases at 5/273 (1.8%) and 6/273 (2.2%) for controls. Recall bias could not be ruled out as cases are more likely to remember about exposures more than

controls. We had considerable missing data on HIV, CD4 count and vitamin A as not all excised cases returned post operatively for testing. The classification of occupations is not ideal. We would have preferred one that classifies occupations by possible exposure to carcinogens. Existing systems such as Kenya National Occupational Classification System (KNOCS) which is derived from the International Standard Classification of Occupations (ISCO) are designed for economic purposes not epidemiological studies.<sup>42</sup>

In conclusion we identified modifiable risk factors. HIV control interventions are now available, exposure to UV radiation can be reduced and indeed we found that wearing of hats was protective, while allergic conjunctivitis can be treated more aggressively in younger people. In addition, the results of this study corroborate what is known about the pathophysiology of OSSN where the limbus stem cells appear to be the main focus of disease. However, the latency period between first exposure to these risk factors and causation of OSSN is still not known. The role of CD4 count in OSSN still remains to be elucidated and why OSSN usually affects one eye is still an enigma. Measures to control HIV, prevent sun exposure such as wearing hats, and control allergic conjunctivitis are recommended.

## References

1. Lee GA, Hirst LW. Ocular surface squamous neoplasia. *Survey of ophthalmology* 1995; **39**(6): 429-50.
2. Gichuhi S, Sagoo MS, Weiss HA, Burton MJ. Epidemiology of ocular surface squamous neoplasia in Africa. *Tropical medicine & international health : TM & IH* 2013; **18**(12): 1424-43.
3. Tunc M, Char DH, Crawford B, Miller T. Intraepithelial and invasive squamous cell carcinoma of the conjunctiva: analysis of 60 cases. *British Journal of Ophthalmology* 1999; **83**(1): 98-103.
4. Gichuhi S, Macharia E, Kabiru J, et al. Clinical Presentation of Ocular Surface Squamous Neoplasia in Kenya. *JAMA ophthalmology* 2015; **133**(11): 1305-13.
5. Nguena MB, van den Tweel JG, Makupa W, et al. Diagnosing ocular surface squamous neoplasia in East Africa: case-control study of clinical and in vivo confocal microscopy assessment. *Ophthalmology* 2014; **121**(2): 484-91.
6. Porges Y, Groisman GM. Prevalence of HIV with conjunctival squamous cell neoplasia in an African provincial hospital. *Cornea* 2003; **22**(1): 1-4.
7. Holcombe DJ, Lee GA. Topical Interferon Alfa-2b for the Treatment of Recalcitrant Ocular Surface Squamous Neoplasia. *American journal of ophthalmology* 2006; **142**(4): 568-71.e3.
8. McClellan AJ, McClellan AL, Pezon CF, Karp CL, Feuer W, Galor A. Epidemiology of Ocular Surface Squamous Neoplasia in a Veterans Affairs Population. *Cornea* 2013; **32**(10): 1354-8.
9. Ateenyi-Agaba C, Dai M, Le Calvez F, et al. TP53 mutations in squamous-cell carcinomas of the conjunctiva: evidence for UV-induced mutagenesis. *Mutagenesis* 2004; **19**(5): 399-401.
10. Newton R. A review of the aetiology of squamous cell carcinoma of the conjunctiva. *British journal of cancer* 1996; **74**(10): 1511-3.
11. Waddell K, Kwehangana J, Johnston WT, Lucas S, Newton R. A case-control study of ocular surface squamous neoplasia (OSSN) in Uganda. *International journal of cancer Journal international du cancer* 2010; **127**(2): 427-32.
12. NASA. Earth at perihelion. [http://science.nasa.gov/science-news/science-at-nasa/2001/ast04jan\\_1/](http://science.nasa.gov/science-news/science-at-nasa/2001/ast04jan_1/) (accessed 3rd September 2015).
13. Ateenyi-Agaba C, Weiderpass E, Smet A, et al. Epidermodysplasia verruciformis human papillomavirus types and carcinoma of the conjunctiva: a pilot study. *British journal of cancer* 2004; **90**(9): 1777-9.
14. Ateenyi-Agaba C. Conjunctival squamous-cell carcinoma associated with HIV infection in Kampala, Uganda. *Lancet* 1995; **345**(8951): 695-6.
15. Yu JJ, Fu P, Pink JJ, et al. HPV infection and EGFR activation/alteration in HIV-infected East African patients with conjunctival carcinoma. *PloS one* 2010; **5**(5): e10477.
16. Moubayed P, Mwakyoma H, Schneider DT. High Frequency of Human Papillomavirus 6/11, 16, and 18 Infections in Precancerous Lesions and Squamous Cell Carcinoma of the Conjunctiva in Subtropical Tanzania. *American Journal of Clinical Pathology* 2004; **122**(6): 938-43.
17. Guthoff R, Marx A, Stroebel P. No evidence for a pathogenic role of human papillomavirus infection in ocular surface squamous neoplasia in Germany. *Current eye research* 2009; **34**(8): 666-71.
18. de Koning MN, Waddell K, Magyezi J, et al. Genital and cutaneous human papillomavirus (HPV) types in relation to conjunctival squamous cell neoplasia: a case-control study in Uganda. *Infectious agents and cancer* 2008; **3**: 12.
19. Sen S, Sharma A, Panda A. Immunohistochemical localization of human papilloma virus in conjunctival neoplasias: a retrospective study. *Indian journal of ophthalmology* 2007; **55**(5): 361-3.
20. Simbiri KO, Murakami M, Feldman M, et al. Multiple oncogenic viruses identified in Ocular surface squamous neoplasia in HIV-1 patients. *Infectious agents and cancer* 2010; **5**: 6.
21. Pfister RR, Renner ME. The corneal and conjunctival surface in vitamin A deficiency: a scanning electron microscopy study. *Investigative ophthalmology & visual science* 1978; **17**(9): 874-83.

22. Baeten JM, McClelland RS, Richardson BA, et al. Vitamin A deficiency and the acute phase response among HIV-1-infected and -uninfected women in Kenya. *Journal of acquired immune deficiency syndromes (1999)* 2002; **31**(2): 243-9.
23. Tabrizi SN, McCurrach FE, Drewe RH, Borg AJ, Garland SM, Taylor HR. Human papillomavirus in corneal and conjunctival carcinoma. *Australian and New Zealand journal of ophthalmology* 1997; **25**(3): 211-5.
24. Hirst LW, Axelsen RA, Schwab I. Pterygium and associated ocular surface squamous neoplasia. *Archives of ophthalmology* 2009; **127**(1): 31-2.
25. Joanna R, Renata Z, Witold P, Malgorzata S, Bernaczyk P, Chyczewski L. The evaluation of human papillomavirus and p53 gene mutation in benign and malignant conjunctiva and eyelid lesions. *Folia histochemica et cytobiologica / Polish Academy of Sciences, Polish Histochemical and Cytochemical Society* 2010; **48**(4): 530-3.
26. Chui J, Coroneo MT, Tat LT, Crouch R, Wakefield D, Di Girolamo N. Ophthalmic pterygium: a stem cell disorder with premalignant features. *The American journal of pathology* 2011; **178**(2): 817-27.
27. Di Girolamo N. Association of human papilloma virus with pterygia and ocular-surface squamous neoplasia. *Eye (Lond)* 2012; **26**(2): 202-11.
28. Thurnham DI, Smith E, Flora PS. Concurrent liquid-chromatographic assay of retinol, alpha-tocopherol, beta-carotene, alpha-carotene, lycopene, and beta-cryptoxanthin in plasma, with tocopherol acetate as internal standard. *Clinical chemistry* 1988; **34**(2): 377-81.
29. WHO. WHO case definitions of HIV for surveillance and revised clinical staging and immunological classification of HIV-related disease in adults and children. Geneva: WHO Press; 2007.
30. Vella S, Schwartlander B, Sow SP, Eholie SP, Murphy RL. The history of antiretroviral therapy and of its implementation in resource-limited areas of the world. *AIDS (London, England)* 2012; **26**(10): 1231-41.
31. Kamal S, Kaliki S, Mishra DK, Batra J, Naik MN. Ocular Surface Squamous Neoplasia in 200 Patients: A Case-Control Study of Immunosuppression Resulting from Human Immunodeficiency Virus versus Immunocompetency. *Ophthalmology* 2015; **122**(8): 1688-94.
32. Pathai S, Lawn SD, Gilbert CE, et al. Accelerated biological ageing in HIV-infected individuals in South Africa: a case-control study. *AIDS (London, England)* 2013; **27**(15): 2375-84.
33. Newton R, Ferlay J, Reeves G, Beral V, Parkin DM. Effect of ambient solar ultraviolet radiation on incidence of squamous-cell carcinoma of the eye. *Lancet* 1996; **347**(9013): 1450-1.
34. Coroneo M. Ultraviolet radiation and the anterior eye. *Eye & contact lens* 2011; **37**(4): 214-24.
35. Gichuhi S, Macharia E, Kabiru J, et al. Clinical Presentation of Ocular Surface Squamous Neoplasia in Kenya. *JAMA ophthalmology* 2015.
36. Poole TR. Conjunctival squamous cell carcinoma in Tanzania. *The British journal of ophthalmology* 1999; **83**(2): 177-9.
37. Kumah D, Lartey S, Yemanyi F, Boateng E, Awuah E. Prevalence of allergic conjunctivitis among basic school children in the Kumasi Metropolis (Ghana): a community-based cross-sectional study. *BMC ophthalmology* 2015; **15**(1): 69.
38. Oladigbolu KK, Abah ER, Chinda D, Anyebe EE. Pattern of eye diseases in a university health service clinic in northern Nigeria. *Nigerian journal of medicine : journal of the National Association of Resident Doctors of Nigeria* 2012; **21**(3): 334-7.
39. De Smedt SK, Nkurikiye J, Fonteyne YS, Tuft SJ, Gilbert CE, Kestelyn P. Vernal Keratoconjunctivitis in School Children in Rwanda: Clinical Presentation, Impact on School Attendance, and Access to Medical Care. *Ophthalmology* 2012; **119**(9): 1766-72.
40. Gichuhi S, Ohnuma SI, Sagoo MS, Burton MJ. Pathophysiology of ocular surface squamous neoplasia. *Experimental eye research* 2014; **129C**: 172-82.
41. Leonardi A, Lazzarini D, Bortolotti M, Piliago F, Midena E, Fregona I. Corneal Confocal Microscopy in Patients with Vernal Keratoconjunctivitis. *Ophthalmology* 2012; **119**(3): 509-15.

42. Kenya National Bureau of Statistics. Kenya National Occupational Classification Standard (KNOCS-2000). In: Ministry of Labour, editor.; 2000.
43. National AIDS and STI Control Programme (NAS COP) Kenya. Kenya HIV estimates, 2014.

**Table 10.1 Study Centres and the 2013 HIV prevalence in their catchment areas<sup>42</sup>**

<b>Study centre</b>	<b>County<sup>b</sup></b>	<b>HIV prevalence (%)</b>
Kenyatta National Referral Hospital <sup>a</sup>	Nairobi	8.0
	Machakos	5.0
	Kajiado	4.4
PCEA Kikuyu Hospital	Kiambu	3.8
	Muranga	5.2
	Nyeri	4.3
	Embu	3.7
	Kirinyaga	3.3
Sabatia Eye Hospital	Vihiga	3.8
	Kakamega	5.9
	Bungoma	3.2
	Kisumu	19.3
	Homa Bay	25.7
	Siaya	23.7
	Migori	14.7
Kitale District Hospital	Trans Nzoia	5.1
	Turkana	7.6
	West Pokot	2.8

Note: The prevalence data refers to adults of age 15 - 49 years. The national prevalence was 6.0%.

<sup>a</sup> The national referral hospital receives patients from further afield including counties that may be listed under other study centres.

<sup>b</sup> the first county listed is where the study centre is located.

**Table 10.2 Univariable analysis of potential risk factors for ocular surface squamous neoplasia. This analysis is adjusted for age group, sex and study centre.**

Exposure	Cases (N=131)	Controls (N=131)	Crude OR (95% CI)	P value
Marital status, No. (%)				0.12
Single	22 (16.8)	26 (19.9)	1 [Reference]	
Married	83 (63.4)	89 (67.9)	1.12 (0.56 - 2.26)	
Divorced or Separated	8 (6.1)	6 (4.6)	1.55 (0.45 - 5.31)	
Widowed	18 (13.7)	10 (7.6)	1.88 (0.67 - 5.30)	
Highest education level, No. (%)				0.01
More than secondary	13 (9.9)	33 (25.2)	1 [Reference]	
Completed secondary school	33 (25.2)	35 (26.7)	2.26 (1.01 - 5.06)	
Some secondary school	12 (9.2)	14 (10.7)	2.00 (0.72 - 5.51)	
Completed primary school	41 (31.3)	25 (19.1)	3.55 (1.55 - 8.12)	
Some primary school	19 (14.5)	17 (13.0)	2.43 (0.94 - 6.30)	
None	13 (9.9)	7 (5.3)	4.24 (1.33 - 13.53)	
Residential area (Province)				0.15
Central	27 (20.6)	34 (26.0)	1 [Reference]	
Coast	1 (0.8)	1 (0.8)	1.25 (0.07 - 21.10)	
Eastern	13 (9.9)	9 (6.9)	1.81 (0.67 - 4.87)	
Nairobi	28 (21.4)	42 (32.1)	0.83 (0.41 - 1.70)	
North-Eastern	2 (1.5)	0	-	
Nyanza	14 (10.7)	7 (5.3)	1.79 (0.59 - 5.41)	
Rift Valley	36 (27.5)	28 (21.4)	0.97 (0.39 - 2.41)	
Western	10 (7.6)	10 (7.6)	0.75 (0.23 - 2.41)	
Duration of residence in home province, median (IQR),y	24 (10 - 39)	28 (14 - 40)	-	0.33 <sup>a</sup>
History of allergic conjunctivitis <sup>b</sup>	28 (21.5)	1 (0.9)	30.78 (4.05 - 233.75)	<0.001
Location of current occupation, No. (%) <sup>b</sup>				0.01
Indoor	45 (34.9)	62 (48.1)	1 [Reference]	
Outdoor	84 (65.1)	67 (51.9)	1.73 (1.03 - 2.91)	
Duration in current occupation, median (IQR),y	10 (5 - 20)	15 (7 - 23)	-	0.04 <sup>a</sup>
Sun exposure per day in current occupation, mean (SD), h	6.9 (3.8)	4.6 (3.2)	1.22 (1.12 - 1.32)	<0.001 <sup>c</sup>
Hat or cap worn outdoors, No. (%) <sup>b</sup>	19 (15.0)	32 (24.8)	0.60 (0.30 - 1.20)	0.04



Sunglasses worn outdoors, No. (%) <sup>b</sup>	10 (7.9)	16 (12.4)	0.66 (0.28 - 1.55)	0.06
Cigarette smoking (past), No. (%) <sup>b</sup>				0.05
No	93 (71.5)	90 (70.3)	1 [Reference]	
Passive (spouse/partner smokes)	17 (13.1)	21 (16.4)	1.10 (0.47 - 2.56)	
Yes	20 (15.4)	17 (13.3)	1.12 (0.54 - 2.34)	
Cigarette smoking (current), No. (%) <sup>b</sup>				0.02
No	115 (89.2)	111 (88.1)	1 [Reference]	
Passive (spouse/partner smokes)	4 (3.1)	9 (7.1)	0.55 (0.15 - 2.00)	
Yes	10 (7.8)	6 (4.8)	1.63 (0.55 - 4.77)	
Duration of cigarette smoking, mean (SD), y	13.5 (8.6)	12.7 (10.0)	-	0.79 <sup>c</sup>
No. of cigarettes smoked daily, median (IQR), y	9 (5 - 20)	7 (5 - 10)	-	0.60 <sup>a</sup>
HIV infection <sup>d</sup> , No. (%)	62 (74.7)	14 (13.6)	18.96 (8.87 - 40.51)	<0.001
HIV infection & ART use <sup>e</sup> , No. (%)				<0.001
HIV-	21 (16.0)	89 (67.9)	1 [Reference]	
HIV +/ ART-	17 (13.0)	2 (1.5)	39.37 (8.35 - 185.64)	
HIV+ / ART+	40 (30.5)	12 (9.2)	14.50 (6.42 - 32.74)	
No HIV or ART data	53 (40.5)	28 (21.4)	7.22 (3.69 - 14.11)	
CD4 count <sup>f</sup> , median (IQR), cells/mm <sup>3</sup>	251 (118 - 670)	796 (619 - 1063)	-	<0.001 <sup>a</sup>
CD4 WHO category, No.(%),cells/mm <sup>3</sup>				<0.001
≥500	20 (15.3)	64 (48.9)	1 [Reference]	
350 - 499	6 (4.6)	9 (6.9)	2.42 (0.75 - 7.82)	
200 - 349	11 (8.4)	1 (0.8)	39.63 (4.73 - 332.14)	
<200	22 (16.8)	2 (1.5)	38.16 (8.15 - 178.70)	
No CD4 data	72 (55.0)	55 (42.0)	3.87 (2.07 - 7.23)	
Vitamin A deficiency (<30 µg/dL) <sup>g</sup> , No. (%)	5 (8.8)	5 (5.8)	1.25 (0.30 - 5.23)	0.50
Serum retinol, median (IQR), µg/dL	44.9 (37.6 - 56.2)	51.0 (39.7 - 64.7)	-	0.03 <sup>a</sup>

Abbreviations: SD, standard deviation; IQR, interquartile range

<sup>a</sup> Wilcoxon-Mann-Whitney U test

<sup>b</sup> There were missing data on allergic conjunctivitis (24 participants), occupational location (4), hat or sunglasses use (6), cigarette smoking (7)

<sup>c</sup> t test

<sup>d</sup> The denominator here is 83 cases and 103 controls who were tested for HIV

<sup>e</sup> We used the combined HIV/ART variable because the effect of HIV would be related to ART use

<sup>f</sup> There were 59 cases and 76 controls who had a CD4 test

<sup>g</sup> The denominator here is 57 cases and 86 controls who had a vitamin A test

**Table 10.3 Multivariable logistic regression analysis for being an OSSN case.**

Exposure	Adj OR <sup>a</sup> (95% CI)	P value
HIV infection & ART use <sup>a</sup>		<0.001
HIV-	1 [Reference]	
HIV +/- ART-	48.30 (7.53 - 309.90)	
HIV+ / ART+	19.02 (6.55 - 55.26)	
No HIV or ART data	9.37 (3.76 - 23.34)	
History of allergic conjunctivitis	80.20 (8.62 - 746.29)	<0.001
Sun exposure in current occupation	1.23 (1.08 - 1.39)	0.001
Hat or cap worn outdoors	0.21 (0.07 - 0.63)	0.01
Highest education level	1.24 (0.95 - 1.63)	0.12

<sup>a</sup>We used the combined HIV/ART variable because the effect of HIV would be related to ART use. The mean (SD) CD4 count with respect to HIV and ART was; HIV- was 926(298) cells/mm<sup>3</sup>; HIV+/ART- was 258(196) cells/mm<sup>3</sup>; HIV+ / ART+ was 314(225) cells/mm<sup>3</sup>; missing HIV/ART data was 136 (101) cells/mm<sup>3</sup>.

## **Chapter 11. Delay along the care-seeking pathway of patients with ocular surface squamous neoplasia in Kenya**





**Registry**

T: +44(0)20 7299 4646  
F: +44(0)20 7299 4656  
E: registry@lshtm.ac.uk

## RESEARCH PAPER COVER SHEET

**PLEASE NOTE THAT A COVER SHEET MUST BE COMPLETED FOR EACH RESEARCH PAPER INCLUDED IN A THESIS.**

### SECTION A – Student Details

<b>Student</b>	Stephen Gichuhi
<b>Principal Supervisor</b>	Matthew J. Burton
<b>Thesis Title</b>	Epidemiology and management of ocular surface squamous neoplasia in Kenya

**If the Research Paper has previously been published please complete Section B, if not please move to Section C**

### SECTION B – Paper already published

Where was the work published?			
When was the work published?			
If the work was published prior to registration for your research degree, give a brief rationale for its inclusion			
Have you retained the copyright for the work?*	Choose an item.	Was the work subject to academic peer review?	Choose an item.

*\*If yes, please attach evidence of retention. If no, or if the work is being included in its published format, please attach evidence of permission from the copyright holder (publisher or other author) to include this work.*

### SECTION C – Prepared for publication, but not yet published

Where is the work intended to be published?			
Please list the paper's authors in the intended authorship order:	Stephen Gichuhi, Ephantus Macharia, Joy Kabiru, Alain M'bongo Zindamoyen, Hilary Rono, Ernest Ollando, Joseph Wachira, Rhoda Munene, Timothy Onyuma, Mandeep S. Sagoo, David Macleod, Helen A. Weiss, and Matthew J. Burton		
Stage of publication	<b>Not yet submitted</b>		

### SECTION D – Multi-authored work

For multi-authored work, give full details of your role in the research included in the paper and in the preparation of the paper. (Attach a further sheet if necessary)	I coordinated and actively led the field work for this paper. Supervision was provided by Matthew Burton throughout. I also performed the statistical analysis, with some guidance from Helen Weiss and David Macleod. I wrote the paper with consideration of comments from co-authors.
--	--

**Student Signature:** Stephen Gichuhi

**Date:** 4th February 2016

**Supervisor Signature:** M. J. Burton

**Date:** 4th February 2016

# Delay along the care-seeking journey of patients with ocular surface squamous neoplasia in Kenya

## Authors:

Stephen Gichuhi MBChB, M.Med<sup>1,2</sup>, Joy Kabiru MBChB, M.Med<sup>3</sup>, Alain M'bongo Zindamoyen MBChB, M.Med<sup>3</sup>, Hilary Rono MBChB, M.Med<sup>4</sup>, Ernest Ollando MBChB, M.Med<sup>5</sup>, Joseph Wachira MBChB, M.Med<sup>6</sup>, Rhoda Munene MBChB, M.Med<sup>6</sup>, Timothy Onyuma MBChB, M.Med<sup>7</sup>, Mandeep S. Sagoo PhD, FRCOphth<sup>8,9,10</sup>, David Macleod MSc<sup>1,11</sup>, Helen A. Weiss MSc, PhD<sup>1,11</sup> and Matthew J. Burton PhD, FRCOphth<sup>1,9</sup>

## Affiliations:

<sup>1</sup>International Centre for Eye Health, London School of Hygiene and Tropical Medicine, Keppel Street, London, WC1E 7HT, UK

<sup>2</sup>Department of Ophthalmology, University of Nairobi, P.O Box 19676-00202, Nairobi, Kenya <sup>3</sup>PCEA Kikuyu Eye Unit, PO Box 45, Kikuyu, Kenya

<sup>4</sup>Kitale District Hospital, PO Box 98-30200, Kitale, Kenya

<sup>5</sup>Sabatia Eye Hospital, PO Box 214-50311, Wodanga, Kenya

<sup>6</sup>Kenyatta National Hospital, PO Box 20723-00202, Nairobi, Kenya

<sup>7</sup>MP Shah Hospital, Department of Pathology, PO Box 14497-00800, Nairobi, Kenya

<sup>8</sup>UCL Institute of Ophthalmology, 11-43 Bath Street, London EC1V 9EL, UK

<sup>9</sup>Moorfields Eye Hospital, 162 City Road, London, EC1V 2PD, UK

<sup>10</sup>St. Bartholomew's Hospital, W Smithfield, London EC1A 7BE, London, UK

<sup>11</sup> MRC Tropical Epidemiology Group, London School of Hygiene and Tropical Medicine, Keppel Street, London, WC1E 7HT,

## Corresponding Author:

Stephen Gichuhi  
International Centre for Eye Health  
London School of Hygiene & Tropical Medicine  
Keppel Street, London WC1E 7HT  
United Kingdom  
Tel. +44 (20) 7636 8636 ext. 8257  
[stephen.gichuhi@lshtm.ac.uk](mailto:stephen.gichuhi@lshtm.ac.uk)

## Email contacts

Stephen Gichuhi, [Stephen.Gichuhi@lshtm.ac.uk](mailto:Stephen.Gichuhi@lshtm.ac.uk)  
Joy Kabiru, [joykabiru@yahoo.com](mailto:joykabiru@yahoo.com)  
Alain M'bongo Zindamoyen, [zindamoyen@yahoo.com](mailto:zindamoyen@yahoo.com)  
Hilary Rono, [hkrono@yahoo.com](mailto:hkrono@yahoo.com)  
Ernest Ollando, [eollando@yahoo.com](mailto:eollando@yahoo.com)  
Joseph Wachira, [drjwachira@gmail.com](mailto:drjwachira@gmail.com)  
Rhoda Munene, [drmmunene@gmail.com](mailto:drmmunene@gmail.com)  
Timothy Onyuma, [tonyuma@mpshahhosp.org](mailto:tonyuma@mpshahhosp.org)  
Mandeep S. Sagoo, [mandeep.sagoo@moorfields.nhs.uk](mailto:mandeep.sagoo@moorfields.nhs.uk)  
David Macleod [david.macleod@lshtm.ac.uk](mailto:david.macleod@lshtm.ac.uk)  
Helen A. Weiss, [helen.weiss@lshtm.ac.uk](mailto:helen.weiss@lshtm.ac.uk)  
Matthew J. Burton, [matthew.burton@lshtm.ac.uk](mailto:matthew.burton@lshtm.ac.uk)

## Financial support

SG received funding from the British Council for Prevention of Blindness (BCPB) fellowship programme. MJB is supported by The Wellcome Trust (Grant Number 098481/Z/12/Z). HAW and DM are supported by the MRC and DFID (Grant Number G0700837). The funding organizations had no role in the design or conduct of this research.

## Conflict of interest

None of the authors have any proprietary interests or conflicts of interest related to this submission.

This submission has not been published anywhere previously and is not simultaneously being considered for any other publication.

**Running head**

Delayed care for ocular surface squamous neoplasia - Kenya

**Word count:** Abstract 249; Text 3554

## **ABSTRACT**

### **Purpose**

To assess referral pathway and treatment delay for patients with ocular surface squamous neoplasia (OSSN) in Kenya.

### **Methods**

Adults with conjunctival lesions presenting to four eye centres were asked about their occupations, when they noticed the growth, health facilities visited in seeking care, cost of consultation, surgery, medicines and histopathology and dates at each step. The time-to-presentation was divided into quartiles and correlates analysed using ordinal logistic regression.

### **Results**

We evaluated 158 first-time presenters with OSSN. Most were women (102 [65%]), living with HIV (78/110 tested [71%]), with low to medium income (127 [80%]). Most of the HIV patients (49/78 [63%]) were in antiretroviral care programs. About half (88/158, [56%]) presented directly to the study centres while the rest were referred. Indirect presenters sought care earlier than direct presenters (median 2.0 months vs 5.5 months) and travelled a shorter distance to the first health facility (median 20km vs 30km) but had surgery later (median 12.5 months vs 5.5 months). Visits beyond the first health facility for indirect presenters markedly increased delay (median 7.3, 29.0, 37.9, and 32.0 months for 1-4 facilities, respectively). Delay was associated with number of health facilities visited (adjusted ordered OR=9.12; 95%CI 2.83-29.4,  $p<0.001$ ) and being female (adjusted ordered OR=2.42; 95%CI 1.32-4.44,  $p=0.004$ ).

### **Conclusions**

Referral delays definitive treatment for OSSN. Women were more likely to experience delay. Despite regular contact with the health system for those with known HIV infection, delays occurred. Early detection and referral of OSSN in the HIV service, might reduce delays.

## INTRODUCTION

Ocular surface squamous neoplasia (OSSN) usually presents as a defined lesion of the conjunctiva and/or cornea. In temperate countries it presents as a rare, slow-growing tumour mostly affecting elderly men. In contrast, in sub-Saharan Africa (SSA) OSSN is more common than in other global regions (1.38 and 1.18 cases/100000/year in males and females respectively in Africa vs 0.18 and 0.08 cases/100,000/year in males and females respectively worldwide). It is also more aggressive in SSA, predominantly affects people living with HIV (PLWH), and occurs with similar frequency in men and women.<sup>1,2</sup> A study from Kenya found that people with no formal education were at higher risk of OSSN and presented with larger tumours than more educated individuals.<sup>3</sup> Late presentation with large tumours and orbital spread is not uncommon in Africa.<sup>4-6</sup> Surgery is the mainstay of treatment and if it is provided in a timely manner, outcomes can be very good with very low recurrence rates.<sup>7</sup>

The Kenya health care referral system is organized into six levels.<sup>8</sup> The first level comprises community units run by community health workers. Services here focus on health promotion and treatment of minor ailments. Dispensaries form the second level. The third level comprises health centres with basic outpatient care, minor surgical services, basic laboratory services, maternity care, and limited inpatient facilities. They also coordinate the community units under their jurisdiction. Levels 4 and 5 are secondary-care hospitals providing curative services, and some training centres. Level 6 are tertiary referral facilities that offer specialised care and training to health workers. There are also a number of private and mission hospitals.

In Africa, accessing eye health services is a major challenge. A study in the Kibera slums and Dagoretti area of Nairobi found that the main barriers to utilization of eye health services were a lack of a perceived need for treatment (49% of respondents), lack of money (33% of respondents), while a small proportion (8%) did not know where to obtain help.<sup>9</sup> A study from Tanzania found that for eye trauma cases an injury at the weekend, use of topical treatment, and visiting other facilities were independently associated with delay of more than 24 hours in accessing specialist eye care. Circular journeys were common where patients repeatedly visited health facilities that were unable to treat the injury.<sup>10</sup>

Cancer is a growing problem in Africa. The age-standardised incidence rates for most cancers increased by more than 10% in most African countries between 1990 and 2013.<sup>11</sup> A literature review of current cancer prevention approaches revealed that the major impediments to good care include a lack of awareness, limited human and financial resources, limited vaccine use (with regard to human papilloma virus), inadequacy of cancer registries, fear, cultural reasons (such as examination by doctors of the opposite sex) and competing health demands.<sup>12</sup> A



study from Rwanda examined health system delays in breast cancer presentation and diagnosis of more than 6 months and found that low levels of education and consulting a traditional healer before a nurse or doctor were the main predictors of delay after adjusting for sociodemographic and clinical characteristics.<sup>13</sup> Visiting 5 or more health facilities before the diagnosis was associated with even longer delay in that study. The experiences of breast cancer, Kaposi's sarcoma and lymphoma patients in the only oncology centre in Cameroon show that 35% of patients waited >6 months after the first sign of disease before presenting to the health system, while diagnosis was made >3 months after presentation in 47% of cases.<sup>14</sup> In the Cameroon study the total delay between first sign of cancer and a correct diagnosis was >6 months for 63% of patients. There are few data on access to eye cancer services. This study was conducted to describe the presentation and referral "journey" that OSSN patients travel in Kenya, describing the time spent, identifying the points of delay and determining the factors associated with delay.

## **MATERIALS AND METHODS**

This study was conducted in Kenya between July 2012 and July 2014. We used Ministry of Health records to identify four eye centres that performed the highest number of conjunctival excision biopsies between 2008 and 2011. The centres were Kenyatta National Hospital in Nairobi, PCEA Kikuyu Eye Unit (25 km from Nairobi in Central Kenya), Kitale district hospital in the north Rift Valley (490km from Nairobi) and Sabatia Eye Hospital (300km from Nairobi) in the western highlands bordering Lake Victoria. These centres receive referrals from surrounding health facilities.

The study was approved by the Kenyatta National Hospital – University of Nairobi Ethics and Research Committee and the London School of Hygiene and Tropical Medicine Ethics Committee. It adhered to the tenets of the Declaration of Helsinki. All participants gave informed written consent to take part in the study before enrolment.

We prospectively recruited consecutive adult patients ( $\geq 18$  years) presenting to the four centres with any conjunctival lesion (first presentation or recurrence) suspected to be OSSN and scheduled for surgical excision. A detailed history was taken using a structured questionnaire before surgery. Participants were asked when they had first noticed the ocular lesion. To document the referral route taken prior to presentation, participants were asked to list the health facilities they had visited, their location, dates visited, advice given and total cost of clinical care to the patient (consultation, tests, surgery and medications). The first facility the patient visited was denoted to as Facility 1, the second one visited (either as a result of

formal referral from the first or self-initiated referral) was denoted Facility 2 and so on. A comprehensive clinical examination was conducted at the slit lamp, including measurement of the longest lesion diameter using the slit lamp beam and scale. Participants underwent surgical excision under local anaesthesia. A histopathologist examined all the tissue specimens at MP Shah Hospital laboratory, Nairobi. Individuals who had histologically confirmed OSSN were offered a HIV test; if this was positive they were offered a referral for care and a CD4 count test. The detailed description of clinical assessment, surgery, tissue handling and testing have been previously published.<sup>3</sup>

Treatment “delay” was defined as the time between becoming aware of the lesion and having surgery. For the purpose of this analysis we only included individuals who had histologically confirmed OSSN. As recurrence after a prior excision is likely to influence health-seeking behaviour and the journey followed, we excluded those with recurrent lesions from this analysis.

Data on the other health facilities visited by patients prior to presentation to one of the four study centres (location, health system level, ownership etc.) were obtained from the Kenya Ministry of Health web-based master facility list (<http://www.ehealth.or.ke/facilities/>) accessed on 15<sup>th</sup> November 2015. Information about the availability of ophthalmic surgical facilities (eye operating theatre) at each of these other health facilities was obtained from the Kenya Ministry of Health, Department of Ophthalmic Services (DOS). One-way distances travelled by road from the patients’ home town to the various health facilities and study centres were estimated using Google Maps following the roads that public vehicles would use.

We compared patients who presented directly to one of the four centres (“direct presenters”) with those who had visited other health facilities prior to presenting to a study centre (“indirect presenters”). Characteristics of the two groups were compared using the chi-squared test for proportions, and the t-test or Mann-Whitney U-test as appropriate for continuous variables. We traced the care seeking journey to describe the time taken, and the advice given at each stage. To investigate factors associated with delayed presentation we subdivided the total time in the range from awareness to surgery into quartiles and created an ordered categorical outcome variable. Ordinal logistic regression was used to estimate odds ratios (OR) and 95% confidence intervals (95%CI).

The likelihood ratio test was used to assess which factors from the univariable analysis would be included in the multivariable regression model. Variables that were associated with delay at a level of  $p < 0.1$  in the univariable model were included in an initial multivariable model. The

final multivariable model included variables which were independently associated with the outcome ( $p < 0.05$ ). All statistical analyses were performed using Stata version 12.1 (StataCorp, College Station, Texas, USA).

## RESULTS

500 individuals with conjunctival lesions enrolled in this study and underwent surgical excision. Of these, 191 (38.2%) were diagnosed with OSSN by histopathology. Among these, 158 (83%) had new lesions and 33 (17%) had recurrent lesions (at least one prior excision at the same site).

The care-seeking journey of the 158 patients with new lesions was analysed: 88 (55.7%) presented directly to study centres and 70 (44.3%) presented indirectly via one or more other health facilities (Figure 11.1). Overall, the mean age was 41.9 years (SD 12.0) and the majority were females (102 [65%]). Education levels were variable, 125 (79%) had completed primary school or above, and 67 (42%) had completed secondary school. The majority worked mostly outdoors (101 [65%]). Most occupations were low or middle income in nature (127 [80%]) and were predominantly in the agricultural sector. HIV status and CD4 count were obtained for patients who returned after surgery (110 [70%]). Of these, 78 (71%) were HIV positive, of whom 49 (63%) were already on antiretroviral therapy (ART).

The numbers of individuals taking different routes to the study centres and the time spent along each stage on the care-seeking journey is illustrated in Figure 11.1. Most indirect presenters (56, [80%]) visited one other health facility before going to the study centres. Overall, despite having a shorter time to first presentation, indirect presenters took longer to receive surgery than direct presenters (5.5 vs 9.6 months,  $p = 0.001$ ). The additional time in getting from the first health facility to the study centre was largely responsible for this difference. The longest delay in the whole care pathway occurred when patients went from the first facility to a second one (median 6.1 months, IQR 3.1-12.2). Referral beyond the first facility markedly increased delay.

The demographic and clinical characteristics of participants, by type of presentation, are shown in Table 11.1. There was little evidence of a difference between direct and indirect presenters by age, marital status, education, occupation or HIV status. There was weak evidence that indirect presenters were more likely to be female than direct presenters (71% vs 59%;  $p = 0.11$ ). There was evidence that the main presenting symptom was different ( $p = 0.03$ ) between the two groups, with pain more common in the direct presenters (17.1% vs

2.9%). At the time of presentation at the study centres for surgery the median tumour diameter in both directly and indirectly presenting patients was 6mm ( $p=0.52$ ) and the histological spectrum of OSSN was similar between the groups ( $p=0.87$ ). Kikuyu Eye Unit and Kenyatta National Hospital had a significantly larger proportion of referrals than the other two study centres ( $p<0.001$ ). Direct presenters travelled a longer distance to the first health facility (study centre) than indirect presenters (median 30km vs 20 km,  $p=0.003$ ).

The median cost of care was similar in the two groups at 3800 (IQR 3800-4800) Kenyan Shillings (KSh) for direct presenters and 3880 (IQR 3800-4100) KSh for indirect presenters. Costs incurred along the indirect route were mainly a subsidised consultation fee charged in government hospitals as most of the participants studied did not receive surgery there plus the cost at the study centre. Costs at the study centres (including consultation, surgery, post-operative medication and histopathology) were: Kikuyu Eye Unit 3800KSh, Kenyatta National Hospital 4000KSh, Sabatia 4800 KSh and Kitale 3500 Ksh. All histology was done at MP Shah Hospital to reduce inter-observer variation in the diagnosis. Tissue specimens from Sabatia and Kitale hospitals were sent to Nairobi for histopathology using a courier service which added to the costs.

The level of the health facility and the availability of an operating theatre at the place where patients presenting indirectly first went to are shown in Table 11.2. For 24 patients it was not possible to determine whether surgical facilities were available, mostly because the patient could not correctly name the facility. The most common points of entry into the health system for indirect presenters were at level 5 county referral hospitals (22 [31.4%]) and private clinics (13 [18.6%]). It is noteworthy that for the majority of facilities an operating theatre was available (37 [53%]). All four of the study centres have a dedicated ophthalmic operating theatre.

The advice given to indirectly presenting patients at the other facilities is shown in Table 11.3. At each point patients were referred, advised to re-attend for follow up or advised to have surgery. It is not clear why some health facilities with operating theatres did not offer surgery. Regardless of the advice, all patients eventually went to the study centres at various time points. From the first facility visited, 32 patients were formally referred to a study centre. Of these, 29 (91%) followed this advice and went directly to a study centre within a median of 2.3 months (IQR 1.2–3.9), while three patients went via other clinics first and reached a study centre (at 1, 3 and 42 months). Out of the 31 advised to re-attend for follow up, only one returned to the same facility seven months later and was then referred to one of the study centres for surgery. The other 30 either self-referred to a study centre (20 [65%]) and received surgery with a median time of 6.1 months (IQR 3.0–11.9) or to another clinic (10 [32%]). The

five who were advised to have surgery all went to the study centres within a median (IQR) duration of 5.6 (2.3 – 11.5) months.

There was a modest linear relationship between duration of symptoms and the lesion size (Figure 11.2) for direct presenters ( $p=0.01$ ), but not indirect presenters ( $p=0.41$ ). For the direct presenters, those who present later tended to have a larger lesion, with an expected increase in size of 0.09mm per month (95% CI 0.03-0.16). There is little evidence that the relationship between symptom duration and tumour size was different in direct and indirect presenters ( $p=0.33$ ). Delay was associated with larger tumour size at presentation (OR 1.07, 95%CI 1.01-1.13,  $p=0.02$ ). The median (IQR) tumour diameter was 5.6 (4.2-7.0), 5.0 (4.2-7.1), 6.4 (4.2-11.5) and 7.6 (5.4-10.0) millimetres (mm) in the following delay categories; 0.4-3.2, 3.3-7.0, 7.1-15.6 and 15.7-190.5 months respectively.

Analysis of the predictors of delay is shown in Table 11.4. On multivariable ordered logistic regression, the number of health facilities visited in the care pathway followed and being female are associated with increased delay. Participants who followed an indirect path were twice as likely to be in a higher delay group than those in the direct pathway (adjusted OR=2.3, 95%CI 1.5-3.7;  $p<0.001$ ). Similarly, females were twice as likely to be in a higher delay group than males (adjusted OR=2.1; 95% CI 1.15-3.81,  $p=0.02$ ).

## **DISCUSSION**

This study identified various challenges along the journey to treatment for new patients with OSSN. Firstly, referral significantly delayed surgery and delay was associated with larger tumours at the time of surgery. Patients in the indirect route initially presented earlier than those who went directly to study centres perhaps because it was a shorter distance and the cost of care was lower. However, surgery was more delayed in the indirect route compared to the direct (5.5 months vs 9.6 months,  $p=0.001$ ), particularly if the patients visited more than one health facility. This correlates well with the finding that the number of facilities visited before was an important predictor of delay in receiving surgery.

Secondly, we found being female was another important predictor of delay. Gender disparities in access to health care services have also been identified in East Africa for other ocular diseases such as eye trauma and cataract with females having relatively more difficulty.<sup>10, 15</sup> A study on access to cataract surgery in Tanzania found that some women needed to seek permission from their husbands before going to hospital or may rather put up with the adversity of poor eye health for fear of being seen as a burden in the family.<sup>15</sup> Women are less likely

than men to be the financial decision makers with regard to seeking health care. In addition, they may have other responsibilities to consider before going to hospital such as child care and home upkeep. Although there is limited information on gender-specific utilization of cancer services in Africa, particularly for OSSN, we hypothesize that women with household and child-care responsibilities have more difficulty attending health facilities, particularly if distant referrals are made.

With respect to the patients reported advice and treatment provided at facilities other than the four study centres there is an intrinsic limitation in that we do not know how many other (if any) people had excisions in the other health facilities who never came to one of the study centres. There is no reporting of this to the central Ministry of Health. However, it would appear that advising follow up for suspicious lesions needs to be supported by more than just a clinical impression. At the first health facility level, 20 of 31 patients who were advised to return for follow up went to the study centres and had surgery within median 6 months (mean 13 months) and were found to have OSSN (Table 11.3). Only one patient at the first facility took the follow up advice and by the time of review seven months later was referred for surgery and was found to have OSSN. While we have no information on how the lesions looked at earlier time points, they may have appeared either benign or were suspicious of malignancy and progressed rather rapidly within a few months, underscoring two things, that OSSN in East Africa is an aggressive disease and that distinguishing OSSN from benign lesions clinically is challenging as they can look very similar.<sup>3</sup>

It is still unclear what drives the decision to present to a first health facility once the person become aware of the tumour. Perhaps it is more the absolute size rather than the rate of growth or combination of the two. We found only a modest difference in growth rates between direct and indirect presenters. It is likely that the duration and growth rates will vary. Pain maybe an important driver of the decision; we found that pain was more common among the direct presenters ( $p=0.02$ ).

The majority of participants were living with HIV and were already in contact with HIV care and treatment programs. Despite this, they still experienced delay. There could be various explanations for this. Firstly, awareness about OSSN among HIV health workers may be limited. Secondly, patients on ART may find it particularly challenging to seek care for OSSN. Over half (44/81 [54%]) the patients on ART had advanced or severe immunosuppression and thus at high risk for comorbidities such as tuberculosis.<sup>16</sup> Thirdly, due to stigma around HIV they may not feel safe or comfortable in other health facilities. A recent study in rural western

Kenya found that cervical cancer stigma was highly correlated with HIV stigma (correlation coefficient 0.72).<sup>17</sup>

We did not find income or level of formal education a barrier to presentation despite most of our patients (80%) being in the low to medium income group. The majority worked in farming. Most employment (83%) nationwide is in the informal sector so it is difficult to know the real earnings as they are not captured in tax systems.<sup>18</sup> In Kenya half of healthcare expenditure (51.1%) is paid for out-of-pocket.<sup>19</sup> The gazetted monthly basic minimum wages for the agricultural industry during the study period was an average of KSh 5704 in 2012 rising to KSh 6503 in 2013 and remained the same in 2014 which was comparable to the fees charged at the study centres.<sup>20</sup> However the opportunity cost of lost income during the care-seeking period for the patient and other adults involved in supporting this care could not be estimated. A study in Kenya found that households spend over 10% of their annual income on healthcare payments with the poor spending more than 33%.<sup>21</sup> The mean annual total spending per household (both inpatient and outpatient) was KSh 16,000 (£114) in urban areas and KSh 5600 (£40) in rural areas. Only about 7% of Kenyans have private health insurance.<sup>20</sup> The National Health Insurance Fund (NHIF) run by the government is the dominant insurance provider. The maximum contribution was KSh 320 (about £2) per month until April 2015 when it was increased to KSh 1700 (£12) per month. NHIF used to pay for the inpatient bed charge only, therefore day surgery (the norm for OSSN surgery) would not be covered. This situation has now been reviewed. The cost of travel is not captured in this analysis. Usually most patients in Kenya would travel to hospitals accompanied by a relative or friend, further increasing the cost of care.

This study had several weaknesses. It did not address the availability of eye surgeons or other surgeons skilled enough and adequately equipped with the right surgical instruments to excise conjunctival lesion as a cause of referral and hence delay. This data was not available to us. The presence or absence of an operating theatre is probably not the determining factor for referral - it is likely to be the availability of an appropriately skilled surgeon. Our analysis of the flow through the health system did not address why the patients did what they did. To answer this would require a qualitative study.

In conclusion, women and those who visited more health facilities were at increased risk of delay. We observed various health system delays. Referral beyond the first point of contact was a major cause of delay. It is also unclear why patients who are in regular contact with the health system through HIV care programs have delayed presentation. There is need to evaluate if health education about OSSN and the ocular effects of HIV infection particularly

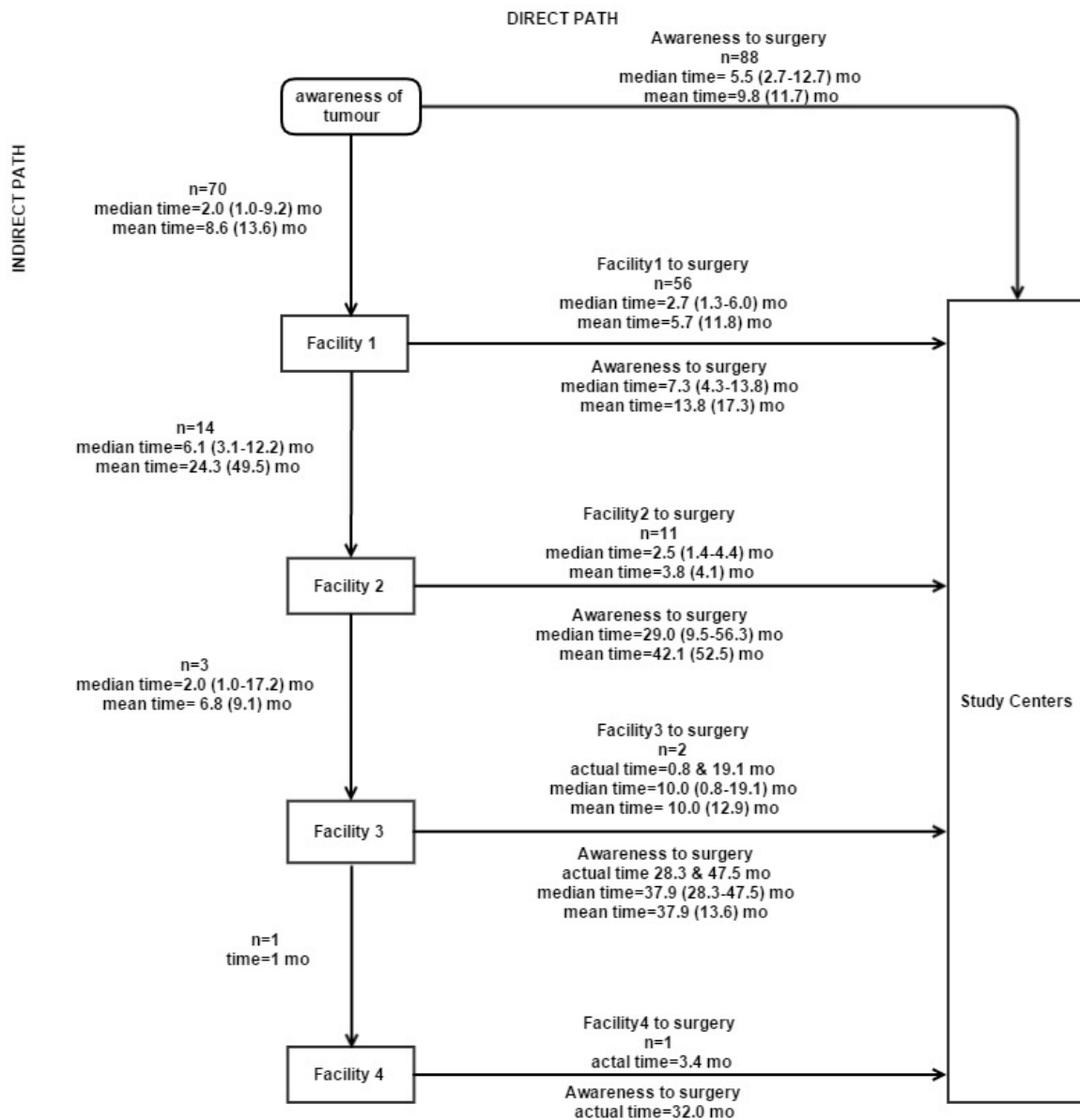
among HIV care workers is a barrier to the provision of timely intervention. Systematic OSSN screening could be considered in HIV care programmes. Patients with pain presented more rapidly. The cost to the patient of treating OSSN (excluding transport costs) was equivalent to a month's wages. It has been suggested that cancer care programs could learn from HIV programs by mainstreaming cancer into the health system together with advocacy and improved health worker training.<sup>22</sup>



## References

1. Gichuhi S, Sagoo MS, Weiss HA, Burton MJ. Epidemiology of ocular surface squamous neoplasia in Africa. *Trop Med Int Health*. Dec 2013;18(12):1424-1443.
2. Tiong T, Borooah S, Msosa J, et al. Clinicopathological review of ocular surface squamous neoplasia in Malawi. *Br J Ophthalmol*. Aug 2013;97(8):961-964.
3. Gichuhi S, Macharia E, Kabiru J, et al. Clinical Presentation of Ocular Surface Squamous Neoplasia in Kenya. *JAMA Ophthalmol*. Nov 1 2015;133(11):1305-1313.
4. Chisi SK, Kollmann MK, Karimurio J. Conjunctival squamous cell carcinoma in patients with human immunodeficiency virus infection seen at two hospitals in Kenya. *East Afr Med J*. May 2006;83(5):267-270.
5. Ogun GO, Ogun OA, Bekibele CO, Akang EE. Intraepithelial and invasive squamous neoplasms of the conjunctiva in Ibadan, Nigeria: a clinicopathological study of 46 cases. *Int Ophthalmol*. Oct 2009;29(5):401-409.
6. Masanganise R, Magava A. Orbital exenterations and squamous cell carcinoma of the conjunctiva at Sekuru Kaguvi Eye Unit, Zimbabwe. *Cent Afr J Med*. Aug 2001;47(8):196-199.
7. Waddell KM, Downing RG, Lucas SB, Newton R. Corneo-conjunctival carcinoma in Uganda. *Eye (Lond)*. Aug 2006;20(8):893-899.
8. Ministry of Health. Kenya health sector referral strategy 2014-2018; 2014.
9. Ndegwa LK, Karimurio J, Okelo RO, Adala HS. Barriers to utilisation of eye care services in Kibera slums of Nairobi. *East Afr Med J*. Oct 2005;82(10):506-508.
10. Al-Attas AH, Williams CD, Pitchforth EL, O'Callaghan CO, Lewallen S. Understanding delay in accessing specialist emergency eye care in a developing country: eye trauma in Tanzania. *Ophthalmic Epidemiol*. Mar 2010;17(2):103-112.
11. Fitzmaurice C, Dicker D, Pain A, et al. The Global Burden of Cancer 2013. *JAMA Oncol*. Jul 2015;1(4):505-527.
12. Busolo DS, Woodgate RL. Cancer prevention in Africa: a review of the literature. *Glob Health Promot*. Jun 2015;22(2):31-39.
13. Pace LE, Mpunga T, Hategekimana V, et al. Delays in Breast Cancer Presentation and Diagnosis at Two Rural Cancer Referral Centers in Rwanda. *Oncologist*. Jul 2015;20(7):780-788.
14. Price AJ, Ndom P, Atenguena E, Mambou Nouemssi JP, Ryder RW. Cancer care challenges in developing countries. *Cancer*. Jul 15 2012;118(14):3627-3635.
15. Geneau R, Lewallen S, Bronsard A, Paul I, Courtright P. The social and family dynamics behind the uptake of cataract surgery: findings from Kilimanjaro region, Tanzania. *Br J Ophthalmol*. Nov 2005;89(11):1399-1402.
16. National AIDS/STI Control Program (NAS COP). Guidelines on Use of Antiretroviral Drugs for Treating and Preventing HIV Infection: A rapid advice; 2014.
17. Rosser JI, Njoroge B, Huchko MJ. Cervical Cancer Stigma in Rural Kenya: What Does HIV Have to Do with It? *J Cancer Educ*. May 17 2015.
18. Kenya Institute for Public Policy Research and Analysis (KIPPRA). *Kenya Economic Report 2013*. 2013.
19. Chuma J, Okungu V. Viewing the Kenyan health system through an equity lens: implications for universal coverage. *Int J Equity Health*. 2011;10:22.
20. Kenya National Bureau of Statistics. *Economic survey 2015*. 2015.
21. Chuma J, Maina T. Catastrophic health care spending and impoverishment in Kenya. *BMC Health Serv Res*. 2012;12:413.
22. International C. Scaling up cancer diagnosis and treatment in developing countries: what can we learn from the HIV/AIDS epidemic? *Annals of Oncology*. April 1, 2010 2010;21(4):680-682.

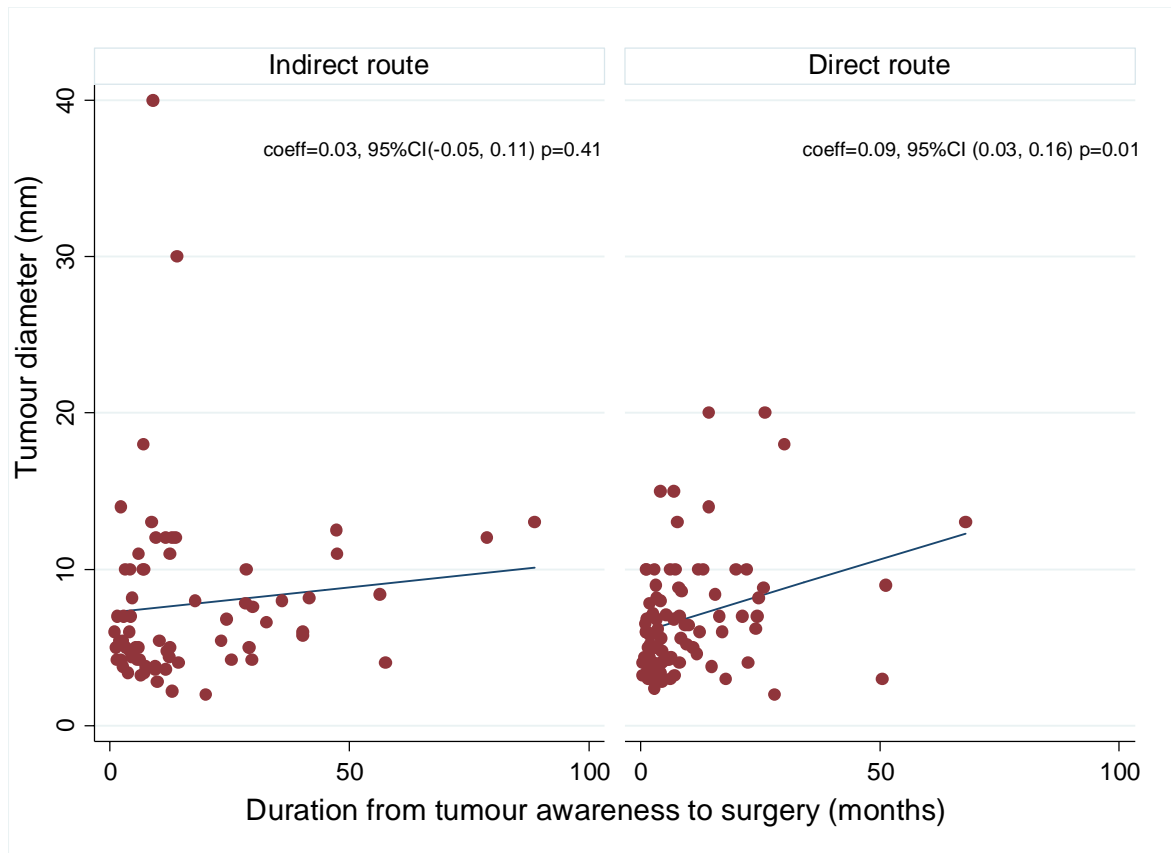
**Figure 11.1 The care-seeking journey followed by 158 new patients with ocular surface squamous neoplasia and the time taken in months for each step.**



**NOTE:** median(IQR), mean(SD).

The term Facility in this figure refers to the sequence of facilities visited rather than the hierarchical position of the facility in the health system. For instance, Facility 1 refers to the first facility a patient visited. Facility 2 is the second facility a patient who was referred from the first facility went to and so on.

**Figure 11.2 Scatterplots showing the change in tumour size against the time between becoming aware of the tumour and having surgery.**



**Table 11.1 Demographic and clinical characteristics of 158 OSSN patients who either presented directly or indirectly via other health facilities to the study centres**

Demographic feature	Direct presenters N=88		Indirect presenters N=70		p-value <sup>a</sup>
	n	(%)	n	(%)	
Age in years, mean (SD), y	42.5	(12.0)	41.1	(12.0)	0.47 <sup>c</sup>
Sex, No. (%)					0.11
Male	36	(40.9)	20	(28.6)	
Female	52	(59.1)	50	(71.4)	
Marital status, No. (%)					0.21
Single	16	(18.2)	9	(12.9)	
Married	55	(62.5)	49	(70.0)	
Divorced or Separated	3	(3.4)	6	(8.6)	
Widowed	14	(15.9)	6	(8.6)	
Highest education level, No. (%)					0.25
Completed secondary or higher	33	(37.5)	34	(48.6)	
Completed primary or some secondary	33	(37.5)	25	(35.7)	
None or some primary	22	(25.0)	11	(15.7)	
Location of primary occupation, No. (%)					0.66
Indoor	29	(33.0)	26	(37.1)	
Outdoor	57	(64.8)	44	(62.9)	
Missing data	2	(2.2)	0	0	
Employment					0.23
Unemployed/no regular income	5	(5.7)	8	(11.4)	
Low to middle income	69	(78.4)	58	(82.9)	
High income	10	(11.4)	4	(5.7)	
Missing data	4	(4.6)	0	0	
HIV infection/ART use, No. (%)					0.42
HIV-	15	(25.0)	17	(34.0)	
HIV+/ART-	15	(25.0)	14	(28.0)	
HIV+/ART+	30	(50.0)	19	(38.0)	
CD4 count in cells/mm <sup>3</sup> , median(IQR)	344	(148 – 802)	219	(120 – 670)	0.42 <sup>d</sup>
HIV-associated immunodeficiency by CD4 count in cells/mm <sup>3</sup> , No. (%)					0.28
None or not significant (≥500)	15	(37.5)	14	(34.2)	
Mild (350-499)	5	(12.5)	3	(7.3)	
Advanced (200-349)	9	(22.5)	5	(12.2)	
Severe (<200)	11	(27.5)	19	(46.3)	
Main symptom, No. (%)					0.03
Lump	53	(60.2)	48	(68.6)	
Pain	15	(17.1)	2	(2.9)	
Redness	6	(6.8)	8	(11.4)	
Others	14	(15.9)	12	(17.1)	
Tumour diameter in mm, median(IQR)	6.0	(4.3 – 8.5)	6.0	(4.2 – 10.0)	0.52 <sup>d</sup>
Histopathology, No. (%)					0.87
CIN I (mild dysplasia)	5	(5.7)	4	(5.7)	
CIN II (moderate dysplasia)	13	(14.8)	9	(12.9)	
CIN III (severe dysplasia)	19	(21.6)	13	(18.6)	
Carcinoma-in-situ	0	0	1	(1.4)	
SCC – poorly differentiated	1	(1.4)	1	(1.4)	
SCC – moderately differentiated	45	(51.1)	35	(50.0)	
SCC – well differentiated	5	(5.7)	7	(10.0)	
Study Centre, No. (%)					<0.001
Kikuyu Eye Unit	42	(47.7)	55	(78.6)	
Kenyatta National Hospital	4	(4.6)	9	(12.9)	
Sabatia Eye Hospital	25	(28.4)	3	(4.3)	
Kitale District Hospital	17	(19.3)	3	(4.3)	

Distance from home to study centre or to 1st health facility in km, median(IQR) <sup>b</sup>	30 (20 – 89)	20 (5 – 56)	0.003 <sup>d</sup>
Cost of care in KSh, median (IQR)	3800 (3800-4800)	3880 (3800-4100)	0.01 <sup>d</sup>

Abbreviations: ART – antiretroviral therapy; CIN – conjunctival intraepithelial neoplasia; SCC- squamous cell carcinoma; KSh – Kenyan shillings

<sup>a</sup> testing whether the distribution of each demographic feature is the same in direct and indirect presenters

<sup>b</sup> 1 patient had missing data on distance, 48 missing data on HIV and 77 on CD4 count

<sup>c</sup> t-test with unequal variances

<sup>d</sup> Mann-Whitney U-test

**Table 11.2 The type of health facilities represented by Facility 1 in the care-seeking journey. This shows where indirect presenters first entered the health system and the availability of operating theatres in those clinics.**

Health facility	Operating theatre available				TOTAL n(%)
	None	General theatre	Eye unit theatre	Unknown	
Dispensary or Health Centre	1	0	0	5	6 (8.6)
District or sub-district hospital	0	3	-	2	5 (7.1)
County referral hospital	0	5	17	0	22 (31.4)
Private clinic	2	0	8	3	13 (18.6)
Mission hospital	0	1	3	2	6 (8.6)
Outreach eye camp	6	0	0	0	6 (8.6)
Facility not identified	0	0	0	12	12 (17.1)
<b>TOTAL, N(%)</b>	<b>9 (12.9)</b>	<b>9 (12.9)</b>	<b>28 (40.0)</b>	<b>24 (34.3)</b>	<b>70 (100.0)</b>

NOTE: General theatre refers to an operating theatre that is shared by all departments. Eye unit theatre means the eye unit has its own operating theatre.

**Table 11.3 Advice given to 70 new patients with OSSN at each health facility along the indirect care-seeking journey and whether the health facility had an operating theatre.**

Step in journey	Advice given			Total patients seen
	Follow up n(%)	Surgery Offered n(%)	Referred n(%)	
<b>Facility 1</b>	<b>31 (44.3)</b>	<b>5 (7.1)</b>	<b>32 (45.7)</b>	<b>70<sup>a</sup></b>
Theatre available	13	4	18	37
No theatre	1	0	2	3
missing information	17	1	12	30
<b>Facility 2</b>	<b>3 (21.4)</b>	<b>2 (14.3)</b>	<b>9 (64.3)</b>	<b>14</b>
Theatre available	1	1	7	9
No theatre	0	0	1	1
missing information	2	1	1	4
<b>Facility 3</b>	<b>1 (33.3)</b>	<b>1 (33.3)</b>	<b>1 (33.3)</b>	<b>3</b>
Theatre available	0	0	1	1
No theatre	0	0	0	0
missing information	1	1	0	2
<b>Facility 4</b>	<b>0</b>	<b>0</b>	<b>1 (100)</b>	<b>1</b>
Theatre available	0	0	0	0
No theatre	0	0	0	0
missing information	0	0	1	1

<sup>a</sup> There was missing data on the advice given to 2 patients at the first facility

The term Facility in this figure refers to the sequence of facilities visited rather than the hierarchical position of the facility. For instance, Facility 1 refers to the first facility a patient visited. Facility 2 is the second facility a patient who was referred from the first facility went to and so on.

**Table 11.4 Predictors of delay in presentation of 158 new patients with ocular surface squamous neoplasia, sub-divided into quartiles.**

Factor	0.4 – 3.2 months (N=38)	3.3 – 7.0 months (N=41)	7.1 – 15.6 months (N=40)	15.7 – 190.5 months (N=39)	Univariate ordered proportional OR (95% CI)	p- value	Adjusted ordered proportional OR (95% CI)	p- value
Distance from home to first health facility or study centre, mean(SD) km	71 (102.0)	63 (82.3)	44 (49.6)	66 (96.3)	1.00 (0.99-1.00)	0.54	-	
Total cost of care, mean (SD) Ksh	4102 (596.0)	4000 (496.3)	4218 (1594.7)	4289 (835.9)	1.00 (0.99-1.00)	0.32		
Care pathway followed, No (%)						<0.001		<0.001
Direct	27 (30.7)	25 (28.4)	19 (21.6)	17 (19.3)	1.00 (REF)		1.00 (REF))	
1 facility visited	11 (19.6)	15 (26.8)	18 (32.1)	12 (21.4)	1.56 (0.85-2.83)		1.38 (0.75-2.54)	
2 or more facilities visited	0	1 (7.1)	3 (21.4)	10 (74.1)	12.93 (3.79-44.06)		13.03 (3.78-44.94)	
Sex, No. (%)								0.01
Male	18 (32.1)	18 (32.1)	12 (21.4)	8 (14.3)	1.00 (REF)	-	1.00 (REF)	
Female	20 (19.6)	23 (23.6)	28 (27.5)	31 (30.4)	2.29 (1.27-4.15)	0.006	2.31 (1.25-4.24)	
Age, mean(SD) y	42 (13.0)	40 (11.8)	46 (13.6)	39 (8.3)	0.99 (0.97-1.02)	0.69	-	
Marital status, No. (%)						0.59	-	
Single	2 (8.0)	11 (44.4)	3 (12.0)	9 (36.0)	1.00 (REF)			
Married	28 (26.9)	24 (23.1)	31 (29.8)	21 (20.2)	0.60 (0.28-1.31)			
Divorced or Separated	1 (11.1)	5 (55.6)	1 (11.0)	2 (22.2)	0.61 (0.17-2.26)			
Widowed	7 (35.0)	1 (5.0)	5 (25.0)	7 (35.0)	0.81 (0.27-2.45)			
Highest education level, No. (%)						0.23	-	
Completed secondary or higher	14 (20.9)	19 (28.4)	15 (22.4)	19 (28.4)	1.00 (REF)			
Completed primary or some secondary	12 (20.7)	16 (27.6)	14 (24.1)	16 (27.6)	1.01 (0.54-1.89)			
None or some primary	12 (36.4)	6 (18.2)	11 (33.3)	4 (12.1)	0.55 (0.26-1.17)			
Occupation, No. (%)						0.95	-	
High income	3 (21.4)	3 (21.4)	6 (42.9)	2 (14.3)	1.00 (REF)			
Low-Medium income	31 (24.4)	35 (27.6)	30 (23.6)	31 (234)	0.96 (0.37-2.48)			
Unemployed	4 (30.8)	3 (23.1)	3 (23.1)	3 (23.1)	0.82 (0.21-3.12)			
HIV infection & ART use, No. (%) <sup>a</sup>						0.07	-	
HIV-	11 (34.4)	10 (31.3)	6 (18.8)	5 (15.6)	1.00 (REF)			
HIV+/ART-	6 (20.7)	11 (37.9)	8 (27.6)	4 (13.8)	1.41 (0.58-3.40)			
HIV+/ART+	11 (22.5)	9 (18.4)	12 (24.5)	17 (34.7)	2.57 (1.13-5.88)			



Main symptom, No. (%)					1.07 (0.94-1.21)	0.32
Lump	24 (23.8)	24 (23.8)	29 (28.7)	24 (23.8)		
Pain	7 (41.2)	5 (29.4)	2 (11.8)	3 (17.7)		
Redness	4 (28.6)	4 (28.6)	2 (14.3)	4 (28.6)		
Others	3 (11.5)	8 (30.8)	7 (26.9)	8 (30.8)		

<sup>a</sup> There were 48 participants with missing HIV/ART data

**Chapter 12. Topical 5-Fluorouracil (5FU) following surgery for ocular surface squamous neoplasia (OSSN) in Kenya: a randomised, double-blind, placebo-controlled trial**





**Registry**

T: +44(0)20 7299 4646  
F: +44(0)20 7299 4656  
E: registry@lshtm.ac.uk

## RESEARCH PAPER COVER SHEET

**PLEASE NOTE THAT A COVER SHEET MUST BE COMPLETED FOR EACH RESEARCH PAPER INCLUDED IN A THESIS.**

### SECTION A – Student Details

<b>Student</b>	Stephen Gichuhi
<b>Principal Supervisor</b>	Matthew J. Burton
<b>Thesis Title</b>	Epidemiology and management of ocular surface squamous neoplasia

**If the Research Paper has previously been published please complete Section B, if not please move to Section C**

### SECTION B – Paper already published

Where was the work published?	The Lancet Global Health		
When was the work published?	May 2016		
If the work was published prior to registration for your research degree, give a brief rationale for its inclusion			
Have you retained the copyright for the work?*	No	Was the work subject to academic peer review?	Yes

*\*If yes, please attach evidence of retention. If no, or if the work is being included in its published format, please attach evidence of permission from the copyright holder (publisher or other author) to include this work.*

### SECTION C – Prepared for publication, but not yet published

Where is the work intended to be published?	
Please list the paper's authors in the intended authorship order:	
Stage of publication	Choose an item.

### SECTION D – Multi-authored work

For multi-authored work, give full details of your role in the research included in the paper and in the preparation of the paper. (Attach a further sheet if necessary)	I coordinated and actively led the field work for this paper. I recruited and followed up participants, carried out the clinical examinations and performed some of the surgeries. Field supervision was provided by Matthew Burton throughout. I also performed the statistical analysis, with some guidance from Helen Weiss. I wrote and submitted the paper with consideration of comments from co-authors.
--	---

**Student Signature:** Stephen Gichuhi

**Date:** 17th May 2016

**Supervisor Signature:** M. J. Burton

**Date:** 17th May 2016

# Topical fluorouracil after surgery for ocular surface squamous neoplasia in Kenya: a randomised, double-blind, placebo-controlled trial

Stephen Gichuhi, Ephantus Macharia, Joy Kabiru, Alain M'bongo Zindamoyen, Hilary Rono, Ernest Ollando, Joseph Wachira, Rhoda Munene, John Maina, Timothy Onyuma, Mandeep S Sagoo, Helen A Weiss, Matthew J Burton



## Summary

**Background** Ocular surface squamous neoplasia (OSSN) is an aggressive eye tumour particularly affecting people with HIV in Africa. Primary treatment is surgical excision; however, tumour recurrence is common. We assessed the effect of fluorouracil 1% eye drops after surgery on recurrence.

**Methods** We did this multicentre, randomised, placebo-controlled trial in four centres in Kenya. We enrolled patients with histologically proven OSSN aged at least 18 years. After standard surgical excision, participants were randomly allocated to receive either topical fluorouracil 1% or placebo four times a day for 4 weeks. Randomisation was stratified by surgeon, and participants and trial personnel were masked to assignment. Patients were followed up at 1 month, 3 months, 6 months, and 12 months. The primary outcome was clinical recurrence (supported by histological assessment where available) by 1 year, and analysed by intention to treat. The sample size was recalculated because events were more common than anticipated, and trial enrolment was stopped early. The trial was registered with Pan-African Clinical Trials Registry (PACTR201207000396219).

**Findings** Between August, 2012, and July, 2014, we assigned 49 participants to fluorouracil and 49 to placebo. Four participants were lost to follow-up. Recurrences occurred in five (11%) of 47 patients in the fluorouracil group and 17 (36%) of 47 in the placebo group (odds ratio 0.21, 95% CI 0.07–0.63;  $p=0.01$ ). Adjusting for passive smoking and antiretroviral therapy had little effect (odds ratio 0.23; 95% CI 0.07–0.75;  $p=0.02$ ). Adverse effects occurred more commonly in the fluorouracil group, although they were transient and mild. Ocular discomfort occurred in 43 of 49 patients in the fluorouracil group versus 36 of 49 in the placebo group, epiphora occurred in 24 versus five, and eyelid skin inflammation occurred in seven versus none.

**Interpretation** Topical fluorouracil after surgery substantially reduced recurrence of OSSN, was well-tolerated, and its use recommended.

**Funding** British Council for Prevention of Blindness and the Wellcome Trust.

**Copyright** © Gichuhi et al. Open Access article distributed under the terms of CC BY.

## Introduction

Ocular surface squamous neoplasia (OSSN) covers a range of conjunctival and corneal diseases, from intra-epithelial dysplasia to invasive squamous cell carcinoma.<sup>1</sup> Risk factors for OSSN include ultraviolet radiation, HIV infection, and human papillomavirus infection.<sup>2</sup> In temperate regions, OSSN is uncommon, usually growing slowly, and most often affects elderly men. By contrast, in sub-Saharan Africa, OSSN is more common and aggressive.<sup>3</sup> It affects younger adults, predominately women (around two-thirds of cases), and is strongly associated with HIV infection (in about 70% of cases). OSSN has a wide range of clinical phenotypes and late presentation with invasive orbital disease is not uncommon (figure 1). Surgical excision is the mainstay of treatment, although primary chemotherapy has also been used (appendix). OSSN often recurs after surgery. The highest recorded recurrence is 67%.<sup>4</sup> Recurrence is a particular problem in sub-Saharan Africa, where it typically occurs in

30–40% of patients.<sup>4–7</sup> In temperate climates, recurrence typically occurs in 5–25% of patients (appendix). Surgical outcomes seem to be affected by delays in diagnosis, tumour size, histological grade, ocular location, scleral invasion, excision margin involvement, prior excision, and coexisting xeroderma pigmentosum.<sup>5,8,9</sup> Several adjunctive treatment regimens are used during or after surgery to reduce recurrence: cryotherapy, topical chemotherapy (mitomycin and fluorouracil), interferon alfa-2b, retinoic acid, and radiotherapy (appendix p 1, 3, 7, 11, 13, 14). Most data on adjuvant treatment are case series. There is one previous randomised trial, from Australia, which assessed the effectiveness of topical mitomycin and there are no trial data on interventions for people with HIV.<sup>10,11</sup> Radical surgery (enucleation or exenteration) is usually needed for advanced disease.<sup>12</sup>

The antimetabolite fluorouracil is often used in ophthalmology, particularly for its anti-scarring properties during surgical procedures (trabeculectomy, pterygium

*Lancet Glob Health* 2016;  
4: e378–85

See [Comment](#) page e347

London School of Hygiene & Tropical Medicine, London, UK (S Gichuhi MMed, Prof H A Weiss PhD, M J Burton PhD); Department of Ophthalmology, University of Nairobi, Nairobi, Kenya (S Gichuhi); PCEA Kikuyu Eye Unit, Kikuyu, Kenya (E Macharia HND, J Kabiru MMed, A M Zindamoyen MMed); Kitale District Hospital, Kitale, Kenya (H Rono MMed); Sabatia Eye Hospital, Wodanga, Kenya (E Ollando MMed); Kenyatta National Hospital, Nairobi, Kenya (J Wachira MMed, R Munene MMed); UHEAL Foundation, Nairobi, Kenya (J Maina CICT); Department of Pathology, MP Shah Hospital, Nairobi, Kenya (T Onyuma MMed); UCL Institute of Ophthalmology, University College London, London, UK (M S Sagoo FRCOphth); Moorfields Eye Hospital, London, UK (M S Sagoo, M J Burton PhD); and St Bartholomew's Hospital, London, London, UK (M S Sagoo)

Correspondence to:  
Dr Stephen Gichuhi,  
International Centre for Eye  
Health, London School of  
Hygiene & Tropical Medicine,  
London WC1E 7HT, UK  
[stephen.gichuhi@lshtm.ac.uk](mailto:stephen.gichuhi@lshtm.ac.uk)

See Online for appendix

### Research in context

#### Evidence before this study

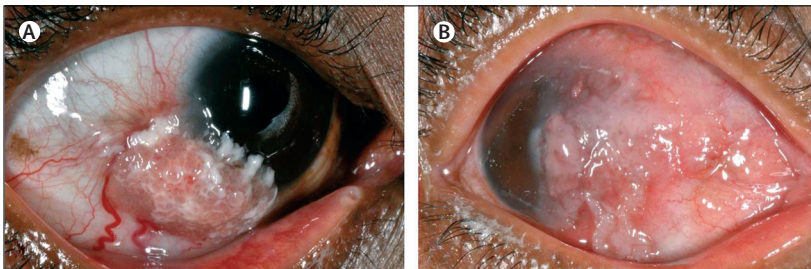
Ocular surface squamous neoplasia (OSSN) is an eye cancer, common in people with HIV. A Cochrane systematic review from 2013 showed no evidence from trials for the effectiveness of interventions used in this population. We searched electronic databases (PubMed, Embase, The Cochrane Library), clinical trial registries (WHO International Clinical Trials Registry Platform and the US National Institutes of Health ClinicalTrials.gov), and international conference proceedings of HIV/AIDS and AIDS-related cancers from the AIDS Education Global Education System for studies published up to Aug 31, 2015, irrespective of language or publication status. We used the terms “randomized controlled trial”, “controlled clinical trial”, “randomized”, “placebo”, “drug therapy”, “randomly”, “trial”, “conjunctiva\*”, “ocular surface”, “carcinoma”, “cancer”, “neoplasia”, “neoplasm”, “neoplastic”, “dysplasia”, “dysplastic”, “squamous”, and “squamous cell”. We found only one trial, on topical mitomycin in a non-HIV-infected population in Australia. We identified some case series and case reports (appendix). Only series that reported recurrence as an outcome were included.

#### Added value of this study

Our study provides the first evidence from a trial of the effectiveness of fluorouracil as adjunctive treatment for OSSN. Our results show that the simple and relatively inexpensive use of 4 weeks of fluorouracil 1% eye drops after surgical excision substantially reduced the relative risk of recurrence compared with placebo and was safe. There were transient side-effects, such as watery eye, discomfort when taking the drops, and eyelid skin inflammation but these were mostly mild and resolved in a few weeks after completion of 4 week treatment.

#### Implications of all the available evidence

Recurrence is a huge issue in the management of this common and aggressive eye disease. Fluorouracil does not need stringent storage conditions and cytotoxics have a low risk of contamination. It is on the WHO Essential Medicines List, and is a widely available and low-cost option, particularly in sub-Saharan Africa, which has the highest incidence of OSSN in the world. Translation of these trial results into clinical practice is therefore feasible.



**Figure 1: Ocular surface squamous neoplasia**  
Moderately differentiated conjunctival squamous cell carcinoma, (A) moderate size, (B) large lesion involving the cornea, limbus, and extending to the fornix. Fornix involvement is often associated with orbital spread.

excision, and lacrimal surgery).<sup>13</sup> Eye drops containing 1% fluorouracil have also been used for several years to treat patients with OSSN after tumour excision (appendix p 11), on the basis of case series, which suggest that fluorouracil reduces tumour recurrence and is safe.<sup>14–20</sup> However, there are no data from trials. Fluorouracil is widely available and relatively cheap in sub-Saharan Africa, therefore, if shown to be an effective adjuvant, it would be a deliverable intervention.

We assessed whether use of fluorouracil 1% eye drops could reduce recurrence of OSSN following surgical excision in Kenya.

## Methods

### Study design and participants

We did a double-blind, parallel-group, randomised, placebo-controlled trial at four centres in Kenya: Kenyatta National Hospital Eye Clinic in Nairobi, PCEA Kikuyu Eye Unit in central Kenya, Sabatia Eye Hospital in

western Kenya, and Kitale District Hospital in the north Rift Valley.

We enrolled consecutive patients presenting with suspicious conjunctival lesions. Entry criteria were: histologically proven OSSN involving two or fewer quadrants; attendance for follow-up within the first 2 months after excision; healing of the excision site; and age at least 18 years. Exclusion criteria were: previous treatment with topical antimetabolite drugs such as fluorouracil or mitomycin to the same eye or systemic cytotoxic drugs; extensive disease requiring more radical surgery than a simple excision; and pregnant or breastfeeding mothers. Patients were not enrolled if they did not think that they could return for follow-up.

All participants gave written informed consent before enrolment. Ethics approval was granted by the Kenyatta National Hospital/University of Nairobi ethics and research committee and the London School of Hygiene & Tropical Medicine ethics committee. Approval was also obtained from the Kenya Pharmacy and Poisons Board to produce and use the active intervention drops because they are not commercially available.

An independent data and safety monitoring board oversaw the study, confirmed data integrity, and approved the results and report for release. Trial personnel received good clinical practice training and certification. This study adhered to the tenets of the Declaration of Helsinki.

### Randomisation and masking

Participants were randomly assigned (1:1) to either fluorouracil 1% or placebo eye drops. The fluorouracil eye drops were prepared by dilution of fluorouracil

50 g/L solution for injection in hydroxypropyl methylcellulose 0.7% artificial tear eye drops. The placebo was the same hydroxypropyl methylcellulose 0.7% artificial tear eye drops.

The randomisation sequence was generated by computer by the trial statistician using Stata (version 12). The permuted block size (known only to the statistician) varied randomly between two and four, and randomisation was stratified by surgeon. The allocation sequence was transferred to the manufacturing pharmacy, where an independent pharmacist applied labels with sequential code numbers to the appropriate eye drop bottles. Participants, clinicians, and study personnel were masked to the allocation: the bottles, liquid content, and packaging had identical appearances. The supervising clinician at each of the four study centres issued the trial drug to participants. The allocation followed the order of enrolment.

### Procedures

Lesions involving two or fewer quadrants of the conjunctiva were fully excised with a 4 mm clear margin by the no-touch technique, with use of an operating microscope and under local anaesthesia.<sup>21</sup> Absolute alcohol was applied to any corneal component of the tumour to loosen it and facilitate dissection. The conjunctival component was dissected down to bare sclera. Cryotherapy was not applied, because it is not generally available in sub-Saharan Africa. Topical adrenaline, and where necessary mild diathermy, were used for haemostasis. The conjunctiva around the defect was undermined and mobilised for primary closure. Specimens were placed on suture-pack polystyrene, to keep the tissue flat and oriented for the pathologist, and fixed in 10% neutral buffered formalin. All histopathological tests were done centrally and reported by a single pathologist. Combined gentamicin 0.3% and prednisolone acetate 1% eye drops were applied four times per day for 3–4 weeks after surgery. Patients were reviewed after about 4 weeks to confirm wound healing and for recruitment into the trial.

Participants were asked to self-administer one drop of their allocated medication four times a day to the affected eye for 4 weeks. Each participant was given a 28 day medication diary to monitor treatment. They were asked to record each dose taken or missed. The record card had a similar diary for adverse effects (pain or burning sensation, excessive tears, and redness).

Participants underwent a detailed ophthalmic examination with a slit-lamp biomicroscope before surgery and at about 1 month after surgery. After enrolment, follow-up visits were scheduled for 1 month, 3 months, 6 months, and 12 months after randomisation. Participants were telephoned 1 week before their appointments to remind them. Individuals who missed follow-up visits were contacted by telephone. At each follow-up visit, a symptom history was taken and a

detailed ophthalmic examination was done for evidence of recurrent disease. On each examination, high-resolution digital images of the surface of the eyes were taken. In addition, we assessed whether the lacrimal drainage system was blocked using the dye disappearance test. Fluorescein dye was applied in both eyes in the inferior conjunctival fornix and the tear film observed with the cobalt blue light of the slit lamp after 5 min for clearance of the dye. The presence of dye after this time was considered positive, indicating a functional or anatomical blockage.

HIV status was initially tested by ELISA using Vironostika antigen/antibody kit (Biomerieux, France) then later changed to rapid tests with Alere Determine HIV-1/2 Ag/Ab (Alere, USA) and Unigold (Trinity Biotech, USA). CD4 count was measured with FacsCount (Becton Dickinson, USA). Serum retinol concentration was quantified by high-performance liquid chromatography (SHIMADZU Prominence HCT2010, Japan).

When an obvious regrowth was found, re-excision for treatment and histopathology was advised. If a small potentially suspicious change was observed, it was initially photographed, the size measured, and the participant examined more frequently than the scheduled study visits. If on subsequent visits the lesion had progressed, the lesion was re-excised and sent for histopathology; the date of recurrence was recorded as the first time the possible regrowing lesion was noticed.

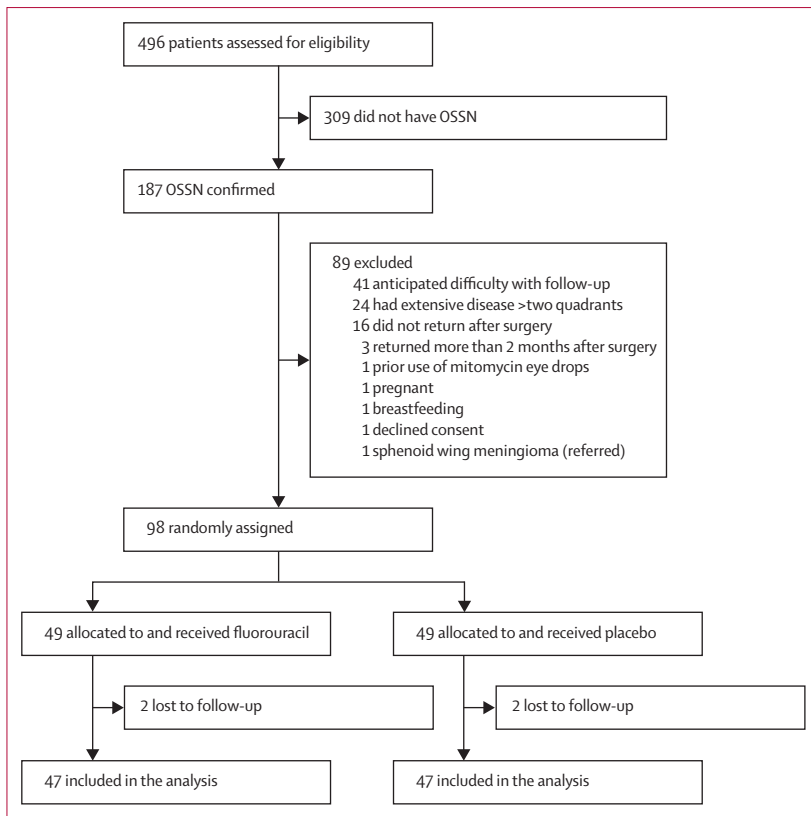
### Outcomes

The primary outcome was clinical recurrence of the lesion at any time during the first year of follow-up, confirmed by histological assessment where available. The secondary outcomes were time to recurrence, cofactors of recurrence, and adverse events.

Primary outcome events were assessed and confirmed centrally by an ophthalmologist, who had either directly examined all patients at Kenyatta National Hospital and Kikuyu Eye Unit, or reviewed the clinical images from Sabatia Eye Hospital and Kitale District Hospital, supported by histopathological results. For cases where histopathology was not available, mostly because the participant did not return for the repeat surgery, the images of recurrent lesions were reviewed by two consultant ophthalmologists experienced in OSSN in east Africa to confirm clinical recurrence. Adverse effects were monitored by reviewing the medication diary with the participant and asking about discomfort and tearing.

### Statistical analysis

Case series of the use of surgical excision with or without adjuvant fluorouracil treatment have reported recurrences in 3.2–43% of patients.<sup>7,19,22,23</sup> Assuming a recurrence of 20% in the control group and 10% in the treatment group, power of 80%, and a two-sided  $\alpha$  of 5%, the target sample size was initially calculated to be 219 participants in each group. 1 year into the study, we



**Figure 2: Trial profile**  
OSSN=ocular surface squamous neoplasia.

noted that recruitment was slow but recurrences were more common overall than anticipated, so after review by the trial steering committee in discussion with the data safety and monitoring board, a pragmatic decision was made to revise the sample size assuming that 30% of patients in the placebo group and 5% in the treatment group would have disease recurrence. As such, a sample size of 43 participants in each group would provide 80% power to detect an absolute difference in recurrence rates of 25%.

The analysis was predefined. We compared the two groups for balance in terms of predefined factors that could have a bearing on aetiology or recurrence: age, sex, smoking history, outdoor occupation, HIV status, CD4 count, vitamin A concentration, tumour size, prior excision, and histological grade.<sup>3,5,8,9</sup> The primary analysis of the primary outcome and the safety analysis were done by intention to treat. Data were managed in Microsoft Access, cleaned, and transferred into Stata (version 12.1) for analysis.

We calculated the numbers of events, person-months, and rate of recurrence in each group. We estimated the effect size as the odds ratio (OR) for recurrence, estimated by logistic regression, with 95% CIs. We adjusted the crude OR for the seven surgeons as a random effect and for additional baseline factors that were greater in one

group than the other.<sup>24</sup> We analysed the effect of the intervention on time to recurrence with Kaplan-Meier survival curves, and we used Cox regression to estimate hazard ratios and 95% CIs, adjusting for substantial baseline imbalances. To assess whether survival was the same by treatment group, we used the log rank test. We report the risk of any adverse effects at any follow-up in the treated eye by group.

The trial is registered with the Pan-African Clinical Trials Registry, number PACTR201207000396219.

### Role of the funding source

The funders had no role in study design, data collection, data analysis, data interpretation, or writing of the report. The corresponding author had full access to all the data in the study and had final responsibility for the decision to submit for publication.

### Results

Between August, 2012, and July 2014, 496 patients with conjunctival lesions had surgical excision followed by histopathological tests. 187 of these patients had OSSN and 309 had other pathological disease types. For all participants with OSSN, only one eye was involved. 89 (48%) of 187 patients were ineligible. Therefore, we enrolled 98 patients (figure 2). 49 patients were assigned to receive fluorouracil eye drops and 49 were assigned to placebo. 58 of 98 patients were enrolled at Kikuyu Eye Unit, 20 at Sabatia Eye Hospital, 12 at Kitale District Hospital, and eight at Kenyatta National Hospital. The final follow-up visits were scheduled for 12 months, although we included data from up to 13 months for late participants. Follow-up was completed in July, 2015. Four individuals without a recorded recurrence (two from each group) did not complete a full year of follow-up.

The main reasons for exclusion were: inability to return for regular follow-up (n=41), extensive disease requiring radical surgery (n=24), not returning at all after surgery (n=16), or returning more than 2 months after surgery (n=3; figure 2). There were no significant differences between the enrolled and non-enrolled patients in terms of age, sex, smoking, HIV infection, or stage of OSSN (excluding larger tumours; data not shown).

The mean age of all participants was 41.0 years (SD 11.3) and most were female. Baseline characteristics were reasonably balanced between the two groups with the exception of past passive cigarette smoking and use of antiretroviral therapy, which were more common in the placebo group than in the fluorouracil group, and therefore were adjusted for in the primary analysis (table 1).

By the end of follow-up, recurrent lesions had developed in 22 eyes of 22 participants. The four participants who did not complete a full year of follow-up were excluded from the primary analysis of clinical recurrence of the lesion by 1 year. Lesion recurrence was significantly less common in the

	Fluorouracil group (n=49)	Placebo group (n=49)
Sex		
Male	17 (35%)	14 (29%)
Female	32 (65%)	35 (71%)
Age (years)	39.1 (9.2)	42.9 (13.0)
Marital status*		
Single	6 (12%)	11 (22%)
Married	32 (65%)	28 (58%)
Divorced or separated	4 (8%)	2 (4%)
Widowed	7 (14%)	7 (14%)
Formal education (years)*		
Tertiary (>12)	5 (10%)	4 (8%)
Secondary completed (12)	18 (37%)	20 (41%)
Some secondary (8–12)	4 (8%)	6 (12%)
Primary completed (8)	13 (27%)	11 (22%)
Some primary (<8)	6 (12%)	4 (8%)
None	3 (6%)	3 (6%)
Past cigarette smoking*		
No	41 (84%)	32 (67%)
Yes	5 (10%)	4 (8%)
Passive (spouse or partner smokes)	3 (6%)	12 (25%)
Current cigarette smoking†		
No	44 (90%)	41 (87%)
Yes	3 (6%)	0 (0%)
Passive (spouse or partner smokes)	2 (4%)	6 (13%)
Cigarettes smoked daily	9 (6)	13 (13)
Years of cigarette smoking	10.7 (6.8)	16.2 (7.4)
Location of current occupation*		
Indoors	20 (41%)	19 (40%)
Outdoors	29 (59%)	29 (60%)
Wears hat or cap outdoors†	8 (16%)	6 (13%)
Wears sunglasses outdoors†	4 (8%)	4 (9%)
HIV infection‡	29 (63%)	31 (71%)
Use of antiretroviral therapy§	10 (22%)	19 (42%)
CD4 count (cells per µL)¶	444 (370)	460 (421)
Serum retinol concentration (µg/L)	489 (157)	529 (215)
Vitamin A deficiency (serum retinol <300 µg/L)	3 (6%)	3 (6%)
Tumour diameter (mm)	5.9 (2.6)	6.3 (2.4)
Prior excision	8 (16%)	9 (19%)
Histological grading of tumours		
CIN 1	4 (8%)	4 (8%)
CIN 2	13 (27%)	8 (16%)
CIN 3	11 (22%)	14 (29%)
Carcinoma in situ	0 (0%)	1 (2%)
Poorly differentiated squamous cell carcinoma	1 (2%)	1 (2%)
Moderately differentiated squamous cell carcinoma	17 (35%)	18 (37%)
Well differentiated squamous cell carcinoma	3 (6%)	3 (6%)
Surgical margin involvement	21 (43%)	19 (39%)

(Table 1 continues in next column)

	Fluorouracil group (n=49)	Placebo group (n=49)
(Continued from previous column)		
Stage of OSSN**		
T1N0M0	15 (31%)	9 (18%)
T2N0M0	10 (20%)	9 (18%)
T3N0M0	23 (47%)	31 (63%)
T3N1M0	1 (2%)	0 (0%)

Data are n (%) or mean (SD). \*Data missing for one participant in the placebo group. †Data missing for two participants in the placebo group. ‡Data missing for three participants in the fluorouracil group and five in the placebo group. §Data missing for three participants in the fluorouracil group and four in the placebo group. ¶Data missing for eight participants in the fluorouracil group and 11 in the placebo group. ||Data missing for ten participants in the fluorouracil group and 13 in the placebo group. \*\*As per the American Joint Committee on Cancer. CIN=cervical intra-epithelial neoplasia. OSSN=ocular surface squamous neoplasia.

**Table 1: Baseline characteristics**

fluorouracil group (five [11%] of 47 patients) than in the placebo group (17 [36%] of 47 patients; crude OR 0.21, 95% CI 0.07–0.63;  $p=0.01$ ). This effect remained significant when adjusted for use of antiretroviral therapy and passive cigarette smoking (OR 0.23, 95% CI 0.07–0.75;  $p=0.02$ ). The relative risk of recurrence was reduced by 70.7% and the absolute difference was 25.6%. Treatment with fluorouracil after surgery for four patients would therefore prevent an estimated one recurrence (number needed to treat 3.9, 95% CI 2.4–11.8).

16 of 22 recurrent lesions underwent repeated surgical excision and recurrent OSSN was confirmed by histopathology in all cases. Re-excision was not done for six recurrent cases: four participants in the placebo group did not return for repeat surgery or further follow-up after the recurrence was noted, and two participants in the placebo group died before re-excision could be done (one from a presumed myocardial infarction and one from HIV-related complications). The images of these cases were reviewed by two ophthalmologists experienced in OSSN in east Africa. All were judged to be recurrent OSSN disease on clinical grounds, in the context of previous histologically confirmed OSSN.

There was a significant difference in the recurrence rate between the two groups over the follow-up period (hazard ratio [HR] 0.24, 95% CI 0.09–0.66;  $p=0.01$ ; figure 3), which changed slightly after adjusting for smoking and use of antiretroviral therapy (HR 0.32, 95% CI 0.11–0.95;  $p=0.04$ ). The test for proportional hazards assumption showed that the assumption of proportionality was appropriate ( $p=0.59$ ). Median tumour-free survival was 7.3 months (IQR 2.3–13.5) in the fluorouracil group and 4.8 months (3.0–7.6) in the placebo group but the difference was not statistically significant ( $p=0.23$ ).

Sensitivity analysis, assuming the four participants who did not complete 1 year of follow-up did not have a



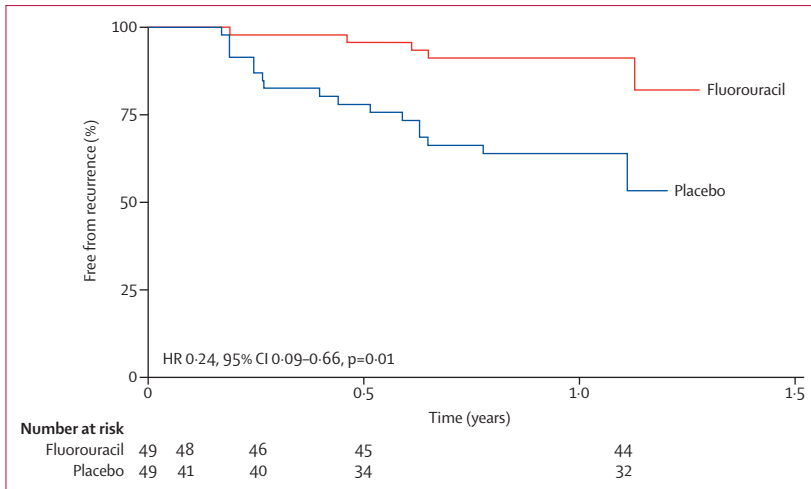


Figure 3: Kaplan-Meier analysis of time to recurrence

	Fluorouracil group (n=49)	Placebo group (n=49)	p value
Epiphora	..	..	..
1 month	24 (49%)	5 (10%)	<0.001
3 months*	3 (6%)	2 (4%)	0.66
6 months†	1 (2%)	0 (0%)	0.32
12 months‡	4 (8%)	0 (0%)	0.04
Positive dye disappearance test	..	..	..
At baseline	0 (0%)	1 (2%)	0.32
1 month	6 (12%)	1 (2%)	0.05
3 months*	1 (2%)	0 (0%)	0.32
6 months†	0 (0%)	0 (0%)	-
12 months‡	0 (0%)	0 (0%)	-
Discomfort in the treated eye at 1 month‡	..	..	0.004
Occasional discomfort	21 (43%)	30 (61%)	..
Discomfort for <5 min	12 (24%)	3 (6%)	..
Discomfort for ≥5 min	4 (8%)	2 (4%)	..
Discomfort making treatment difficult	6 (12%)	1 (2%)	..
Eyelid inflammation at 1 month	7 (14%)	0 (0%)	<0.001
Any adverse event	..	..	0.005§
1 month	34 (69%)	19 (39%)	..
3 months	10 (20%)	9 (18%)	..
6 months	5 (10%)	1 (2%)	..
12 months	7 (14%)	6 (12%)	..

\*48 patients in the fluorouracil group and 47 in the placebo group because of loss to follow-up. †47 participants in each group because of loss to follow-up.  
 ‡No participant reported any discomfort at 3 months, 6 months, or 12 months.  
 §Computed with the stratified log-rank test for equality of survivor functions.

**Table 2: Adverse events**

recurrence in the first year, made little difference to the results (crude OR 0.21, 95% CI 0.07–0.64, p=0.01; adjusted OR 0.25, 95% CI 0.08–0.79, p=0.02; HR 0.25, 95% CI 0.07–0.67, p=0.01; adjusted HR 0.33, 95% CI

0.11–0.97, p=0.04) and the number needed to treat remained at four (4.1, 95% CI 2.5–12.5).

Tumour size at baseline was a significant cofactor of recurrence (crude OR 1.27, 95% CI 1.04–1.54, p=0.02). Participants who had a recurrence had significantly larger mean tumour diameter (7.3 mm, SE 0.26) than did patients who did not have a recurrence (5.8 mm, SE 0.66; p=0.01). There was no effect modification by tumour size or rate of tumour growth before surgery, defined as tumour diameter divided by duration between noticing the growth and time of surgery, assuming a linear rate (likelihood ratio test p=0.49). The mean growth rate was 1.6 mm per month (SE 0.61) in patients who had a recurrence and 1.7 mm per month (SE 0.22) in patients who did not. Surgical margin involvement was not a significant cofactor for recurrence (crude OR 1.28, 95% CI 0.49–3.33, p=0.62) and nor was having invasive carcinoma rather than carcinoma in situ at baseline (crude OR 1.09, 95% CI 0.42–2.81, p=0.87).

Adverse effects were more common in the fluorouracil group than in the placebo group, as shown by analysis of the time to first adverse event (p=0.005; table 2). Epiphora (watery eye) was more common in the fluorouracil group than in the placebo group and the dye disappearance test became transiently positive in six patients in the fluorouracil group at 1 month. None of the participants with epiphora had a positive dye disappearance test at 1 year. Ocular discomfort was more common in the fluorouracil group than in the placebo group at 1 month (p=0.004). In one (2%) patient, discomfort was sufficient to discontinue treatment after 3 weeks. After the 1 month visit, no participants reported ocular discomfort.

Seven participants, all in the fluorouracil group, developed inflammation or irritation of the eyelid skin after about 2–3 weeks of treatment. This was attributed to overflow spillage of the eye drop onto the skin. All skin changes fully resolved within 1 month. We advised all further enrollees to apply drops while holding a piece of tissue paper against the lid; subsequently, no episodes of eyelid skin irritation occurred.

## Discussion

We showed that 4 weeks of treatment with topical fluorouracil 1% after surgical excision substantially reduced the 1 year recurrence of OSSN tumours. The study was done in a region with a relatively high incidence of OSSN, which is often associated with HIV infection, and where patients often present late with advanced disease. Tumour recurrence has been a major problem in managing this disease. Most of our participants were relatively young, and women outnumbered men, the typical demographic pattern in Africa.<sup>3</sup> The whole range of OSSN disease was represented, enabling us to draw a general conclusion about the effectiveness of the intervention.

This study was the first randomised controlled trial of topical fluorouracil as adjunctive treatment for OSSN.

However, our results are consistent with those of non-randomised case series of adjuvant fluorouracil, which have reported similarly low proportions of recurrence.<sup>14–20</sup> Some investigators have reported the effectiveness of fluorouracil as primary treatment in presumed OSSN lesions without surgical excision and histopathological assessment.<sup>14</sup> We chose to test fluorouracil in this setting because it is cheap and readily available with a history of use and wide acceptance for other types of ophthalmic surgery. Fluorouracil is on WHO's list of essential drugs. It does not require stringent storage conditions such as refrigeration. Therefore, the translation of this result into clinical practice, given the resource limitations of the Kenyan health system and other similar settings, is realistic. Because surgical cryotherapy is not routinely available, topical fluorouracil is therefore an alternative strategy to prevent recurrence.

The only other randomised study of treatment for OSSN was a placebo-controlled, crossover trial of topical mitomycin for 48 patients from Australia.<sup>10</sup> However, that study has several distinct differences to our study, which probably limit the relevance to settings such as Kenya. First, only partial incisional biopsy samples were taken for diagnosis; the tumours were not excised. Given the advanced and aggressive disease in Africa, complete surgical removal of the lesion is the preferred approach. Second, the casemix was different: patients with squamous cell carcinoma were excluded from the Australia study, the population group was older than ours (mean age 67 years), predominantly male (75%), and probably not infected with HIV (no data were provided). Although the lesions regressed clinically on treatment with mitomycin, more than half of patients had persistent OSSN on repeat histological assessment of the lesion site 1 year after treatment.

Overall, the use of topical fluorouracil was associated with transient side-effects: watery eye, discomfort when taking the drops, and eyelid skin inflammation. However, these were mostly mild and resolved after the completion of treatment. A transiently positive dye disappearance test indicates temporary reversible obstruction of the nasolacrimal duct, a known complication of fluorouracil treatment.<sup>18</sup> The most significant adverse effect was the eyelid skin inflammation. This was reliably prevented by protecting the skin with a tissue while applying the drops to catch any overflow. Epiphora was reported by 10% of participants at 1 month in the placebo group and 61% reported occasional discomfort at 1 month. We think that these effects were not caused by the placebo, which was a bland lubricant, but rather related to having recently had, often extensive, excision surgery to remove a tumour. It is quite common for excision of conjunctival lesions, OSSN or other pathology such as a pterygium, to result in a degree of ocular surface inflammation and irritation that can persist for several weeks. Such effects are especially common in young people of African origin, who are more likely to scar and have inflammation than

are older white patients.<sup>25</sup> Overall, we think that these side-effects can be partly mitigated, do not usually represent a problem after cessation of treatment, and are outweighed by the benefit of the reduced tumour recurrence.

Adjunctive fluorouracil probably works through its effect on residual OSSN cells that are left after surgical excision. It interferes with DNA and RNA processes through several active metabolites.<sup>26</sup> Fluorodeoxyuridine monophosphate inhibits thymidylate synthase, blocking thymidylate production, and thus DNA replication. Rapidly dividing neoplastic cells are much more vulnerable to thymidine depletion than are normal cells. Fluorodeoxyuridine triphosphate is misincorporated into DNA and fluorouridine triphosphate is misincorporated into RNA. These different metabolites disrupt crucial cellular mechanisms, triggering apoptosis.

We were able to follow up participants to 1 year. This was attributable to two factors. First, we excluded people who said that they would be unlikely to return for follow-up. Second, the study team were careful to build and maintain good relationships with study participants, and actively communicated with those who missed follow-up visits.

Our study has several limitations. First, recruitment was slower than anticipated, resulting in a smaller study than originally anticipated. The initial study size was based on previously reported recurrence rates from several case series, with heterogeneous inclusion criteria, treatment regimens, and follow-up.<sup>4,7,19,22,23,27,28</sup> However, the higher than expected recurrence rate and high retention enabled us to have good power with a smaller sample size. In common with other studies from Africa, the recurrence rate in both groups was higher than that reported in many case series from temperate countries. This difference is possibly because OSSN in this population, with a high proportion of patients who are HIV positive, is more aggressive and patients probably present later with more advanced disease.

Second, not all the cases of clinical recurrence had re-excision and histopathological tests done. However, all suspected recurrences for which histopathological results were available were confirmed as recurrent OSSN, which suggests that our clinical judgment in this situation is highly concordant with the pathology.

Third, we excluded a high proportion of potential participants. The most common reason for exclusion was that the patient was unlikely to return for follow-up. Excluding those who did not think they could return helped us achieve good follow-up among those who were enrolled in the trial. However, there was no systematic difference between participants and excluded patients in terms of age, sex, HIV status, smoking status, or OSSN grade (when those with large lesions requiring alternative radical surgery were excluded). This finding suggests that our results can be generalised. The participants who were lost to follow-up attended at least the first visit after

randomisation and were recurrence-free at that point. The challenge of ensuring high follow-up rates in Kenyans with HIV has been reported previously.<sup>29</sup>

Fourth, we excluded individuals with very large tumours that required either enucleation or exenteration. This exclusion could reduce the generalisability of the findings. However, such patients are not suitable for less radical surgery and topical chemotherapy, as the tumour is already invading the deeper tissues of the orbit. Finally, there were some differences in adverse events by group, which could have led to unmasking. However, we think that this is unlikely: discomfort was common and similar in each group at 1 month, and eyelid inflammation, positive dye disappearance test, and epiphora after 1 month were uncommon.

In conclusion, 4 weeks of topical fluorouracil 1% after surgical excision of OSSN substantially reduced the 1 year recurrence of tumours. The treatment is safe, generally well tolerated, and easy to use. Fluorouracil is widely available, affordable, and easy to formulate into eye drops. It is suitable in settings without cryotherapy. Fluorouracil eye drops are an effective and realistic intervention to improve outcomes for people with OSSN.

#### Contributors

SG, MSS, HAW, and MJB designed the study and interpreted the data. SG did the literature search. SG, EM, JK, AMZ, HR, EO, JW, RM, JM, and TO collected data. SG, HAW, and MJB analysed data and obtained funding. SG wrote the first draft of the Article, all authors revised it. JK, AMZ, HR, EO, JW, RM, and JM provided administrative, technical, and material support. HAW and MJB supervised the study.

#### Declaration of interests

We declare no competing interests.

#### Acknowledgments

SG received funding from the British Council for Prevention of Blindness fellowship programme. MJB is supported by the Wellcome Trust (grant number 098481/Z/12/Z).

#### References

- Lee GA, Hirst LW. Ocular surface squamous neoplasia. *Surv Ophthalmol* 1995; **39**: 429–50.
- Gichuhi S, Ohnuma S, Sagoo MS, Burton MJ. Pathophysiology of ocular surface squamous neoplasia. *Exp Eye Res* 2014; **129**: 172–82.
- Gichuhi S, Sagoo MS, Weiss HA, Burton MJ. Epidemiology of ocular surface squamous neoplasia in Africa. *Trop Med Int Health* 2013; **18**: 1424–43.
- Birkholz ES, Goins KM, Sutphin JE, Kitzmann AS, Wagoner MD. Treatment of ocular surface squamous cell intraepithelial neoplasia with and without mitomycin C. *Cornea* 2011; **30**: 37–41.
- Chebbi A, Bouguila H, Boukari M, et al. Prognosis of primary malignant tumors of the conjunctiva. *J Fr Ophthalmol* 2015; **38**: 477–85 (in French).
- Bonanno A, Esmali B, Fingeret MC, Nelson DV, Weber RS. Social challenges of cancer patients with orbitofacial disfigurement. *Ophthalm Plast Reconstr Surg* 2010; **26**: 18–22.
- Chisi SK, Kollmann MK, Karimurio J. Conjunctival squamous cell carcinoma in patients with human immunodeficiency virus infection seen at two hospitals in Kenya. *East Afr Med J* 2006; **83**: 267–70.
- Galor A, Karp CL, Oellers P, et al. Predictors of ocular surface squamous neoplasia recurrence after excisional surgery. *Ophthalmology* 2012; **119**: 1974–81.
- Sudesh S, Rapuano CJ, Cohen EJ, Eagle RC Jr, Laibson PR. Surgical management of ocular surface squamous neoplasms: the experience from a cornea center. *Cornea* 2000; **19**: 278–83.
- Hirst LW. Randomized controlled trial of topical mitomycin C for ocular surface squamous neoplasia: early resolution. *Ophthalmology* 2007; **114**: 976–82.
- Gichuhi S, Irlam JH. Interventions for squamous cell carcinoma of the conjunctiva in HIV-infected individuals. *Cochrane Database Syst Rev* 2013; **2**: CD005643.
- Ogun GO, Ogun OA, Bekibele CO, Akang EE. Intraepithelial and invasive squamous neoplasms of the conjunctiva in Ibadan, Nigeria: a clinicopathological study of 46 cases. *Int Ophthalmol* 2009; **29**: 401–09.
- Abraham LM, Selva D, Casson R, Leibovitch I. The clinical applications of fluorouracil in ophthalmic practice. *Drugs* 2007; **67**: 237–55.
- Nutt RJ, Clements JL, Dean WH. Ocular surface squamous neoplasia in HIV-positive and HIV-negative patients and response to 5-fluorouracil in Angola. *Clin Ophthalmol* 2014; **8**: 2435–40.
- Bahrami B, Greenwell T, Muecke JS. Long-term outcomes after adjunctive topical 5-fluorouracil or mitomycin C for the treatment of surgically excised, localized ocular surface squamous neoplasia. *Clin Experiment Ophthalmol* 2014; **42**: 317–22.
- Al-Barrag A, Al-Shaer M, Al-Matary N, Al-Hamdani M. 5-Fluorouracil for the treatment of intraepithelial neoplasia and squamous cell carcinoma of the conjunctiva, and cornea. *Clin Ophthalmol* 2010; **4**: 801–08.
- Midena E. Treatment of conjunctival squamous cell carcinoma with topical 5-fluorouracil. *Br J Ophthalmol* 2000; **84**: 268–72.
- Rudkin AK, Muecke JS. Adjuvant 5-fluorouracil in the treatment of localised ocular surface squamous neoplasia. *Br J Ophthalmol* 2011; **95**: 947–50.
- Yeatts RP, Engelbrecht NE, Curry CD, Ford JG, Walter KA. 5-Fluorouracil for the treatment of intraepithelial neoplasia of the conjunctiva and cornea. *Ophthalmology* 2000; **107**: 2190–95.
- Parrozzani R, Lazzarini D, Alemanni-Rubio E, Urban F, Midena E. Topical 1% 5-fluorouracil in ocular surface squamous neoplasia: a long-term safety study. *Br J Ophthalmol* 2011; **95**: 355–59.
- Shields CL, Shields JA. Tumors of the conjunctiva and cornea. *Surv Ophthalmol* 2004; **49**: 3–24.
- Tabin G, Levin S, Snibson G, Loughnan M, Taylor H. Late recurrences and the necessity for long-term follow-up in corneal and conjunctival intraepithelial neoplasia. *Ophthalmology* 1997; **104**: 485–92.
- Waddell KM, Downing RG, Lucas SB, Newton R. Corneo-conjunctival carcinoma in Uganda. *Eye (Lond)* 2006; **20**: 893–99.
- Kahan BC. Accounting for centre-effects in multicentre trials with a binary outcome—when, why, and how? *BMC Med Res Methodol* 2014; **14**: 20.
- Broadway D, Grierson I, Hitchings R. Racial differences in the results of glaucoma filtration surgery: are racial differences in the conjunctival cell profile important? *Br J Ophthalmol* 1994; **78**: 66–75.
- Longley DB, Harkin DP, Johnston PG. 5-Fluorouracil: mechanisms of action and clinical strategies. *Nat Rev Cancer* 2003; **3**: 330–38.
- Zaki AA, Farid SF. Management of intraepithelial and invasive neoplasia of the cornea and conjunctiva: a long-term follow up. *Cornea* 2009; **28**: 986–88.
- Russell HC, Chadha V, Lockington D, Kemp EG. Topical mitomycin C chemotherapy in the management of ocular surface neoplasia: a 10-year review of treatment outcomes and complications. *Br J Ophthalmol* 2010; **94**: 1316–21.
- Hassan AS, Fielding KL, Thuo NM, Nabwera HM, Sanders EJ, Berkley JA. Early loss to follow-up of recently diagnosed HIV-infected adults from routine pre-ART care in a rural district hospital in Kenya: a cohort study. *Trop Med Int Health* 2012; **17**: 82–93.

## General discussion and future work

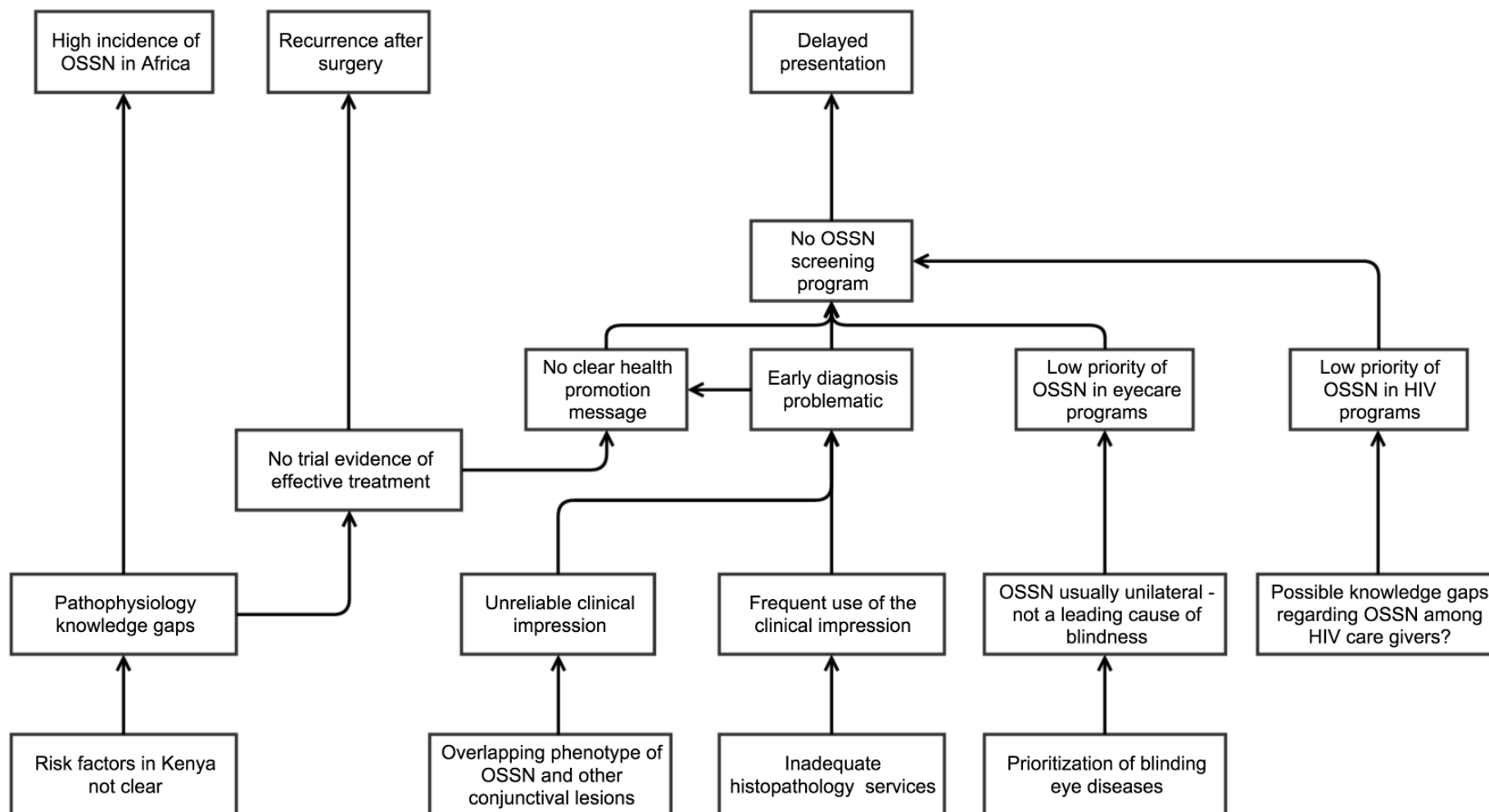


## Chapter 13. Discussion

Ocular surface squamous neoplasia is a complex multifaceted problem. (Figure 13.1) This project aimed to address some of the knowledge gaps in this complex web. The most prominent problems we see with regard to OSSN in sub-Saharan Africa are a high incidence, recurrences after surgery and delayed presentation. This discussion will take a logical framework approach examining each problem in turn and delving into the underlying causes as shown in Figure 13.1.

The systematic review we conducted on the epidemiology of OSSN confirmed that the incidence in Africa is the highest in the world and that women here were at similar risk as men unlike other regions of the world where male disease predominated. The case-control study we conducted showed that in the Kenyan setting this situation is driven by a combination of modifiable risk factors all which are more common in Africa than in other parts of the world, namely, HIV, exposure to solar UV radiation outdoors and allergic conjunctivitis. We also identified that wearing hats was protective. The role of HPV remains unclear as studies show a lot of variation. It is also still unclear why the incidence is equally high in both males and females but prevalence seems higher in females. It may be related to HIV being a strong risk factor for OSSN. Females have a higher biological susceptibility to HIV and other sexually transmitted infections (STI) which may contribute to the high incidence.<sup>1</sup> Women survive longer with HIV than men perhaps from better ART compliance and acceptance which would explain the high prevalence.<sup>2</sup> The pathophysiology review implicated the limbal stem cells as the possible nidus of neoplastic transformation in OSSN. The nasal limbus is particularly susceptible to UV radiation. The finding of allergic conjunctivitis as a risk factor is new yet consistent with the limbal stem cells being the origin of OSSN. The findings of this review closely reflect what the case-control study found. Knowledge on how the risk factors interact and the lead time between exposure and disease is evolving. However it is still not clear why OSSN is often unilateral. Possible entry points for prevention would therefore need to focus on women especially in prevention and control of HIV, wearing hats while outdoors and effective control of allergic conjunctivitis in children and adolescents. A better understanding of the pathophysiology would also highlight more options for therapeutic intervention focusing on stem cells and genetic modification rather than just the rapidly dividing tumour cells that current therapies seem to target.

**Figure13.1. The OSSN problem tree. This diagram illustrates the negative aspects of the existing situation at the top and the cause-and-effect relationships between them in a logic-frame approach.**



Recurrences highlight the need for effective treatments and the need to provide this in a timely fashion. The trial we conducted provides a feasible local option. The value of experience is demonstrated by a surgeon in Uganda who reported very low recurrence rates (3.2%).<sup>3</sup> Without trial evidence of an effective treatment for OSSN it would be difficult for health policy makers to make robust recommendations and health promotion messages would be hampered if they highlighted a disease whose treatment remained unclear.

Various factors may be responsible for delayed presentation of OSSN. The absence of a screening or early detection program is hampered by various factors. OSSN does not meet most of the criteria for screening described by Wilson and Jungner in 1968 and now adopted by the WHO.<sup>4</sup> (Table 13.1) Early diagnosis is a particularly challenging. We also found that a single histological type would show varying phenotype among affected patients. There is much geographic variation worldwide in the phenotype of OSSN, the male to female ratio, age and HIV association (Chapters 1 & 7). Clinical distinction between OSSN and other benign conjunctival lesions is difficult (Chapter 7). They have similar features and this could partly be related to a common pathophysiological pathway. Similar UV-related mutations of the p53 tumour suppressor gene and HPV have been observed in OSSN and benign lesions that some of the latter are considered pre-malignant.<sup>5, 6</sup> Toluidine blue vital staining is challenged by high false positives and was not as specific as a clinical assessment by a trained ophthalmologist as we saw in the examination of photographs but it may have value for screening performed by other health care workers (Chapter 8 & 9). The dye is easy to reconstitute from commercially available powder which would make it widely available in sub-Saharan Africa.

The diagnosis is further complicated by various other issues. Firstly, histopathology though the gold standard for diagnosis is not without pitfalls. It is not widely available in sub-Saharan Africa. Secondly, it is subjective and prone to inter- and intra-individual variation.<sup>7</sup> Tissue specimens are generally small as most tumours were 6.8mm wide (Chapter 7). Tissue preparation and sectioning sometimes causes shearing off the superficial layers which can lead to misinterpretation of the depth and margin involvement (see Figure 2b&h in Chapter 3). Thirdly, the terminology 'ocular surface squamous neoplasia' has been described as conceptually friendly but clinically perilous because it may refer to intraepithelial neoplasia (which some surgeons may call pre-malignant) or invasive squamous cell carcinoma or both.<sup>8</sup> The American Joint Committee on Cancer recognizes squamous cell carcinoma but does not use the term OSSN. Fourthly, distinctions within the continuum of OSSN such as different degrees of intraepithelial neoplasia and invasive carcinoma may not be clinically relevant to management, bearing no association with response to treatment. Finally, the histological

descriptions of OSSN appear bent towards conjunctival disease and do not address corneal disease – whether primary or secondary involvement. Indeed even what we call benign is considered by some to be pre-malignant.

At program level there are competing priorities in sub-Saharan Africa. The incidence of OSSN is low compared to leading cancers such as breast, cervix, lung and prostate. It is not a leading cause of blindness so it receives no attention from eyecare programs. Although strongly associated with HIV, it is not in the radar screen of HIV care programs. We found that most of our patients experienced delay despite already being enrolled in HIV care programs. Although we now have evidence of the efficacy of 5FU, it is not registered as an eye medication. It is an injection registered for gastrointestinal cancer treatment but has been used off-label in ophthalmology for a long time. This leaves OSSN as an orphan disease.

There are also geographical variations in cost of treatment of OSSN. A recent US study found that surgical treatment was more expensive than medical treatment with interferon therapy (mean, \$17 598; SD, \$7624) vs mean, \$4986; SD, \$2040).<sup>9</sup> In Africa surgery can be delivered for a small fraction of the US cost. In the Kenyan context 5FU is affordable, available and effective. The cost of a 4-week treatment course of 5FU eyedrops is 320 Kenyan shillings (US\$ 3.2 or Sterling £ 2.1). OSSN patients tended to have low education so advocacy is difficult. It is therefore hard to find a champion for the disease unlike other cancers that may affect famous people and get attention.

In the prevailing circumstances, it was difficult to put together a health promotion message without evidence of effective treatment or suitable early diagnosis.

This project provided information to fill in some of the gaps and we plan some future work to gain more new information. The planned future work will help to increase our understanding of the pathophysiology and at program level, evidence for the effectiveness of a health education tool to improve the referral of OSSN patients in the country. However, wide geographical variation in disease patterns and risk factors may make joint mitigation efforts worldwide difficult.



**Table 13.1 Wilson & Jungner criteria for screening and how OSSN performs on each.**

	<b>Criteria</b>	<b>OSSN situation</b>
1	The condition should be an important health problem	Incidence compared to leading cancers is low. Competing priorities in the health sector
2	There should be an accepted treatment for patients with recognized disease	Yes
3	Facilities for diagnosis and treatment should be available	Inadequate
4	There should be a latent or early symptomatic stage	Early stage exists
5	There should be a suitable test for examination	Histopathology
6	The test should be acceptable to the population	Requires surgery but on the whole acceptable
7	The natural history of the condition, including development from latent to declared disease, should be understood	Unclear
8	There should be an agreed policy on who to treat as patients	Not in place yet
9	The cost of case finding (including diagnosis and treatment of patients diagnosed) should be economically balanced in relation to possible expenditure on medical care as a whole	Unclear
10	Case finding should be a continuing process and not a 'once and for all' project	No program in place yet

## References

1. Kersh EN, Ritter J, Butler K, et al. Relationship of Estimated SHIV Acquisition Time Points During the Menstrual Cycle and Thinning of Vaginal Epithelial Layers in Pigtail Macaques. *Sexually transmitted diseases* 2015; **42**(12): 694-701.
2. Cornell M, Schomaker M, Garone DB, et al. Gender differences in survival among adult patients starting antiretroviral therapy in South Africa: a multicentre cohort study. *PLoS Med* 2012; **9**(9): e1001304.
3. Waddell KM, Downing RG, Lucas SB, Newton R. Corneo-conjunctival carcinoma in Uganda. *Eye (Lond)* 2006; **20**(8): 893-9.
4. Wilson JMG, Jungner G. Principles and Practice of Screening for Disease *Public Health Papers* 1968; **34**: 1-163.
5. Joanna R, Renata Z, Witold P, Malgorzata S, Bernaczyk P, Chyczewski L. The evaluation of human papillomavirus and p53 gene mutation in benign and malignant conjunctiva and eyelid lesions. *Folia histochemica et cytobiologica / Polish Academy of Sciences, Polish Histochemical and Cytochemical Society* 2010; **48**(4): 530-3.
6. Di Girolamo N. Association of human papilloma virus with pterygia and ocular-surface squamous neoplasia. *Eye (Lond)* 2012; **26**(2): 202-11.
7. Margo CE, Harman LE, Mulla ZD. The reliability of clinical methods in ophthalmology. *Survey of ophthalmology* 2002; **47**(4): 375-86.
8. Margo CE, White AA. Ocular surface squamous neoplasia: terminology that is conceptually friendly but clinically perilous. *Eye (Lond)* 2014; **28**(5): 507-9.
9. Moon CS, Nanji AA, Galor A, McCollister KE, Karp CL. Surgical versus Medical Treatment of Ocular Surface Squamous Neoplasia: A Cost Comparison. *Ophthalmology* 2015.

## Chapter 14. Future work

The following future work is planned.

- i) Stem cells study – we conducted immunohistochemistry staining of different histological types of OSSN and some benign lesions for stem cell markers. Various stains reported to stain stem cells in other tumours were used. The objective was to study the stem cell patterns if any in OSSN. A manuscript is in preparation.
- ii) Human papilloma virus (HPV) serotypes in OSSN – we extracted viral DNA from a set of OSSN lesions for genome sequencing to study what types of HPV may be involved in OSSN. Most other studies have used diagnostic kits that focused on cervical cancers. We hope our study will reveal a wider array of genotypes of HPV. The sequencing component is still ongoing.
- iii) OSSN sequencing – we have held preliminary discussions with the Sanger Institute in Cambridge to study the genetic mutations in OSSN tumours. The aim is to further explore the gene mutations in OSSN that may be associated with UV radiation, HIV, HPV and smoking.
- iv) Health Education and Early Detection (HEED) study – I have obtained a post-doctoral fellowship grant (£90,000) from the Queen Elizabeth Jubilee Trust Fund through the Commonwealth eye health consortium (<http://cehc.lshtm.ac.uk/>) to conduct a pilot project to promote early awareness and early referral of OSSN in Kenya.
- v) Validation study to see the effectiveness of the algorithm for screening by other health workers (non-Ophthalmologists).
- vi) Make 5FU available in Kenya as effectiveness has been demonstrated. We would need to work with the Kenya Pharmacy and Poisons Control Board and the manufacturer who produced it for the study.
- vii) Long-term follow up of 5FU trial participants – we continue following up our trial participants with the aim of reporting 3-year results.

## Appendices

1. *Diagnosing ocular surface squamous neoplasia in East Africa: case-control study of clinical and in vivo confocal microscopy assessment.*
2. *Ocular rhinosporidiosis mimicking conjunctival squamous papilloma in Kenya – a case report*
3. Ethics committee approvals
4. RCT registration, regulatory authority approval and protocol



# RightsLink®

## Creative Commons Attribution License (CC BY)

This article is available under the terms of the [Creative Commons Attribution License \(CC BY\)](#). You may distribute and copy the article, create extracts, abstracts, and other revised versions, adaptations or derivative works of or from an article (such as a translation), to include in a collective work (such as an anthology), to text or data mine the article, including for commercial purposes without permission from Elsevier. The original work must always be appropriately credited.

Permission is not required for this type of reuse.

**CLOSE WINDOW**

Copyright © 2016 [Copyright Clearance Center, Inc.](#) All Rights Reserved.

Comments? We would like to hear from you. E-mail us at [customercare@copyright.com](mailto:customercare@copyright.com)

# Diagnosing Ocular Surface Squamous Neoplasia in East Africa

## Case-Control Study of Clinical and In Vivo Confocal Microscopy Assessment

Marie B. Nguena, MMed,<sup>1</sup> Jan G. van den Tweel, MD, PhD,<sup>2</sup> William Makupa, MMed,<sup>1</sup> Victor H. Hu, PhD, MRCOphth,<sup>1,3</sup> Helen A. Weiss, MSc, PhD,<sup>4</sup> Stephen Gichuhi, MBChB, MMed,<sup>3,5</sup> Matthew J. Burton, PhD, FRCOphth<sup>1,3</sup>

**Objective:** To examine the reliability of clinical examination and in vivo confocal microscopy (IVCM) in distinguishing ocular surface squamous neoplasia (OSSN) from benign conjunctival lesions.

**Design:** Case-control study.

**Participants:** Sixty individuals with conjunctival lesions (OSSN and benign) and 60 age-matched controls with normal conjunctiva presenting to Kilimanjaro Christian Medical Centre, Moshi, Tanzania.

**Methods:** Participants were examined and photographed, and IVCM was performed. Patients with conjunctival lesions were offered excisional biopsy with histopathology and a human immunodeficiency virus (HIV) test. The IVCM images were read masked to the clinical appearance and pathology results. Images were graded for several specific features and given an overall categorization (normal, benign, or malignant). A group of 8 ophthalmologists were shown photographs of conjunctival lesions and asked to independently classify as OSSN or benign.

**Main Outcome Measures:** Comparison of the histopathology diagnosis with the clinical and IVCM diagnosis.

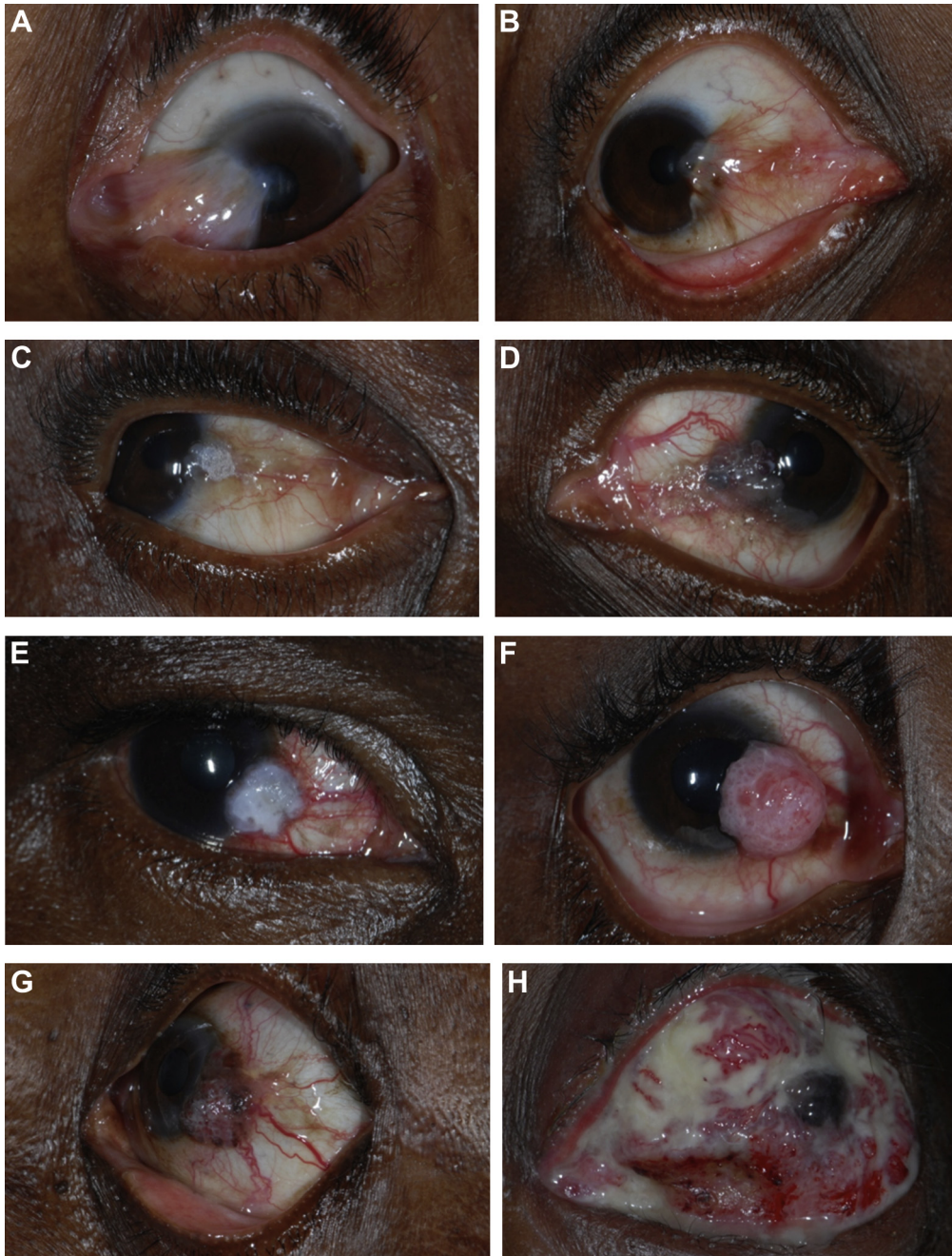
**Results:** Fifty-two cases underwent excisional biopsy with histopathology; 34 were on the OSSN spectrum, 17 were benign, and 1 was lymphoma. The cases and controls had comparable demographic profiles. Human immunodeficiency syndrome infection was more common in OSSN compared with benign cases (58.8% vs. 5.6%; odds ratio, 24.3, 95% confidence interval [CI], 2.8–204;  $P = 0.003$ ). Clinically, OSSN lesions more frequently exhibited feeder vessels and tended to have more leukoplakia and a gelatinous appearance. Overall, the ophthalmologists showed moderate agreement with the histology result (average kappa = 0.51; 95% CI, 0.36–0.64). The masked grading of IVCM images reliably distinguished normal conjunctiva. However, IVCM was unable to reliably distinguish between benign lesions and OSSN because of an overlap in their appearance (kappa = 0.44; 95% CI, 0.32–0.57). No single feature was significantly more frequent in OSSN compared with benign lesions. The sensitivity and specificity of IVCM for distinguishing OSSN from benign conjunctival lesions were 38.5% and 66.7%, respectively.

**Conclusions:** In East Africa, conjunctival pathology is relatively common and can present significant diagnostic challenges for the clinician. In this study, neither clinical examination nor IVCM was found to reliably distinguish OSSN from benign conjunctival pathology because of an overlap in the features of these groups. Therefore, IVCM cannot currently replace histopathology, and management decisions should continue to rely on careful clinical assessment supported by histopathology as indicated. *Ophthalmology* 2014;121:484-491 © 2014 by the American Academy of Ophthalmology.

Ocular surface squamous neoplasia (OSSN) is the most common malignant ocular surface disease in Africa.<sup>1–3</sup> It ranges from small areas of conjunctiva intra-epithelial neoplasia (CIN) to large invasive squamous cell carcinoma (SCC).<sup>4</sup> There has been a marked increase in the incidence of this disease in East Africa over the last couple of decades, attributed to human immunodeficiency virus (HIV)/AIDS.<sup>3,5–7</sup> The disease now presents at a younger age than previously and affects more women than men. Although HIV positivity is a well-defined major risk factor

for OSSN, approximately half of all cases in East Africa are HIV positive and the role of other etiologic factors needs to be defined.<sup>4,7</sup> Data from case-control studies suggest that damage from ultraviolet light exposure in equatorial regions may be important.<sup>7</sup> Human papilloma virus has been postulated to be involved, but its contribution remains uncertain despite several studies.<sup>8</sup>

One of the challenges facing clinicians managing OSSN is distinguishing early neoplastic from benign lesions (Fig 1A, B). This is a particular problem in East Africa,



**Figure 1.** Photographs of a pterygium and various grades of ocular surface squamous neoplasia: pterygium (A), conjunctiva intra-epithelial neoplasia (CIN) 1 (B), CIN 3 (C), carcinoma in situ (D), squamous cell carcinoma (SCC) grade 1 (E), SCC grade 2 (F), SCC grade 3 (G), and SCC with orbital invasion (H).

where benign conjunctival changes (pterygium, pingeculum) are relatively common. There is probably an overlap in the clinical features of these different benign lesions and OSSN, with no signs being exclusive to OSSN, although this has not been formally evaluated. Some features have been reported to be more common in advanced cases of OSSN.<sup>4</sup> Histopathology is necessary to confirm a diagnosis of OSSN. However, pathology services are generally scarce in East Africa outside larger

centers. As a result, many lesions are excised without pathologic analysis.

The standard approach for treating suspected OSSN is an excisional biopsy, often with cryotherapy to the conjunctival margin and sometimes with topical chemotherapy.<sup>9,10</sup> An initial incisional biopsy is usually performed for larger lesions to make a diagnosis to plan treatment. In recent years, there has been a move to consider primary topical chemotherapy for suspected OSSN without a tissue

diagnosis.<sup>11</sup> Given the potential uncertainty of diagnosis based on clinical signs alone, several groups have investigated whether *in vivo* confocal microscopy (IVCM) can help distinguish cases of OSSN.<sup>12–16</sup> These reports of relatively few cases (26 in the whole literature) have tended to conclude that IVCM may be helpful in making a diagnosis of OSSN. Several specific features, such as irregular cell size, hyper-reflectivity, prominent bright nucleoli (“starry night appearance”), and mitotic figures, have been singled out as potential markers for OSSN.<sup>13</sup>

We report a prospective study of patients with conjunctival lesions presenting to an ophthalmic unit in Tanzania. We investigate the diagnostic accuracy of the clinical examination and whether certain features help to distinguish OSSN from benign lesions. Second, we evaluate the utility of IVCM in identifying OSSN in a masked study of conjunctival lesions.

## Methods

### Ethical Approval

This study adhered to the tenets of the Declaration of Helsinki. It was reviewed and approved by the Kilimanjaro Christian Medical Centre (KCMC) Ethics Committee, Tanzania.

### Study Design and Participants

In this case-control study, we compared individuals with conjunctival lesions (“cases,” either benign or OSSN) with individuals with clinically normal conjunctiva (“controls”). Recruitment of both cases and controls was conducted at the Department of Ophthalmology, KCMC Hospital, Moshi, Tanzania, from May to November 2011. Cases were consecutive individuals presenting with a conjunctival lesion that on clinical grounds required surgical excision. For each case, we recruited a control presenting for a condition that was not affecting the ocular surface and who had healthy conjunctiva on slit-lamp examination (e.g., cataract). These control participants were age-matched to the corresponding case ( $\pm 5$  years). All participants were aged 18 years or older. The study was explained to eligible study subjects, and written informed consent was obtained before enrollment. All enrolled patients with conjunctival lesions received counseling and were offered testing for HIV, which is standard of care at KCMC. Patients with a positive HIV test result were referred to the Comprehensive Treatment Center.

### Clinical Assessment

Patients with conjunctival lesions were asked about symptoms (ocular pain, irritation, itchiness, redness, decreased vision, proptosis, and discharge). Participants were asked where they lived within Tanzania and their main occupation. The surface of the eye was carefully examined with a slit lamp for conjunctival pathology. We recorded lesion location and size and the presence of specific features, including fibrovascular tissue (Fig 1A, B), leukoplakia (Fig 1C), gelatinous appearance (Fig 1D), feeder vessels (Fig 1D), papilliform structure (Fig 1F), limbal involvement, and orbital invasion (Fig 1H). The lesions were photographed using a digital single lens reflex camera with a macro lens.

## *In Vivo* Confocal Microscopy Examination

*In vivo* confocal microscopy examination of the bulbar conjunctiva was performed using the Heidelberg Retina Tomograph 3 in combination with the Rostock Corneal Module (Heidelberg Engineering GmbH, Dossenheim, Germany). A sterile, disposable polymethylmethacrylate cap was mounted on the head of the confocal microscope, and a drop of topical anesthetic (proparacaine 0.5%) was instilled into the inferior fornix of the eye before the examination. For cases, the lesion and surrounding areas were scanned. For controls, the temporal or nasal inter-palpebral conjunctiva was scanned. Representative images of the examined conjunctiva were obtained using the “volume scan” mode, which collects a series of 40 parallel images 2  $\mu$ m apart; both surface (starting at the epithelium) and deeper sets of scans were performed.

All confocal images were graded over a 2-day period, after recruitment had been completed. Two ophthalmologists (M.B.N., M.J.B.) jointly examined all the images; they were masked to the case/control status, clinical features, and histopathology results. The grading of the images was based on separately examining each of the 40 parallel images in each of the volume scan stacks. The following features, which are said to be potentially discriminating in previous studies, were evaluated: variable epithelial cell size, hyperreflectivity, presence of mitotic cells, and prominent bright nucleoli (“starry night appearance”) (Fig 2).<sup>13</sup> An overall provisional categorization based on the IVCM findings was made: (1) normal, (2) abnormal benign, or (3) abnormal malignant.

### Surgical Treatment

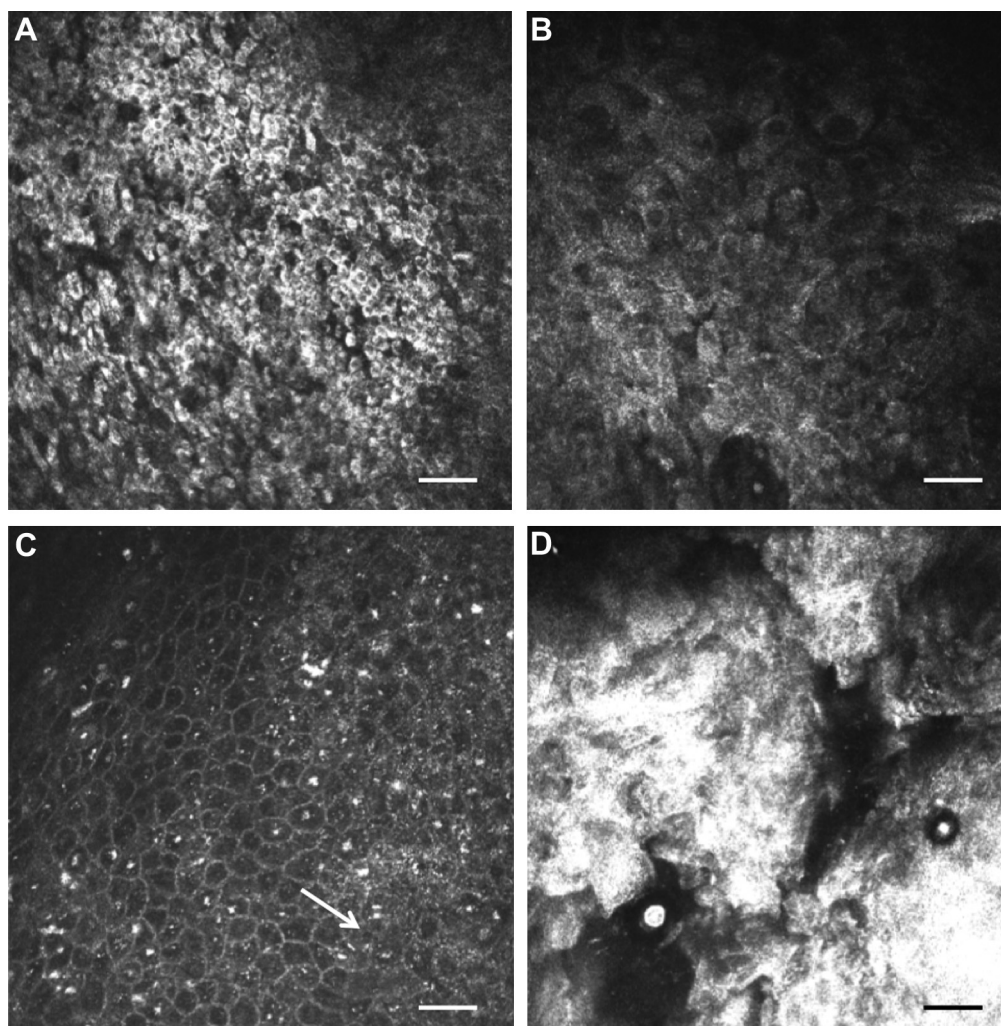
Lesions were treated surgically. Small to medium-sized lesions that were clinically suspicious for OSSN were fully excised using the “no touch technique” with a 3- to 4-mm margin of healthy-looking tissue. Surgical sponges saturated with 5-fluorouracil were applied to the excision site for 5 minutes followed by irrigation with normal saline. 5-Fluorouracil treatment was not used if the case was thought to be benign pathology, such as a pterygium. Incisional biopsies were performed for large lesions to obtain tissue for histology assessment. If malignant pathology was confirmed, radical surgery (enucleation or exenteration) was then offered to the patient. Biopsy tissue was not collected from the normal controls.

### Histopathology

Biopsy specimens from the cases were immediately placed in 10% formaldehyde solution. These were mounted in paraffin wax, and 5- $\mu$ m sections were cut perpendicular to the conjunctival surface and stained with hematoxylin–eosin. All specimens were examined by a single pathologist (J.G.T.). Ocular surface squamous neoplasia was classified using the standard definitions for mild (CIN I), moderate (CIN II), and severe (CIN III) dysplasia, carcinoma *in situ*, and invasive SCC.<sup>17</sup> Squamous cell carcinoma was subdivided by the degree of differentiation: well (I), moderate (II), and poor (III).

### Clinical Diagnosis Study

To evaluate the ability of clinicians to correctly distinguish between benign and malignant conjunctival lesions, we showed a group of 8 ophthalmologists (3 consultants and 5 residents) a series of 43 photographs of lesions for which a histologic diagnosis also was available by the time this component was conducted. This included a mixture of benign and neoplastic pathologies. They were asked to independently write down their diagnosis and whether they thought it was benign or malignant.



**Figure 2.** In vivo confocal microscopy images of conjunctival ocular surface squamous neoplasia. **A**, Small hyper-reflective cells. **B**, Large hyper-reflective cells of variable size. **C**, Possible mitotic figure (*arrow*) and prominent basal cell nucleoli. **D**, Amorphous, possibly keratinized material. Scale bar 50  $\mu$ m.

## Data Analysis

Data were entered into Access 2007 (Microsoft Corp., Redmond, WA) and analyzed using Stata 11.0 (StataCorp LP, College Station, TX). Demographic characteristics of cases and controls were compared by conditional logistic regression. For the purpose of analysis, occupation was condensed to “indoors” or “outdoors” and region of residence to “Kilimanjaro region” and “outside Kilimanjaro region.” The Wilcoxon rank-sum test was used to compare the ages between cases and control because the distribution was skewed. The frequency of clinical signs and symptoms in benign and neoplastic lesions was compared using the Fisher exact test.

The Kappa statistic was used to assess the agreement between the categorized tissue diagnosis (benign or OSSN), and clinical diagnosis made from photographs by the 8 ophthalmologists (benign or OSSN). To calculate an average value, the kappa statistics for each grader were transformed to Z scores using the Fisher Z transformation, averaged, and then back-transformed to a kappa statistic. The clinical and IVCN features were analyzed in relation to the histologic diagnosis. Associations between the tissue diagnosis and the presence of specific clinical or IVCN features

were assessed by the Fisher exact test. Agreement between the categorized tissue diagnosis (normal, benign, or malignant) and the masked IVCN grading (normal, benign, or malignant) was assessed by a weighted Kappa statistic.

## Results

### Study Participants

Sixty individuals with conjunctiva lesions (cases) and 60 age-matched controls with healthy ocular surfaces were recruited. The cases and controls had comparable demographic profiles: age, sex, region of origin, and occupational history (Table 1).

### Diagnoses

Five cases declined surgical excision of their lesions, and a further 3 cases had surgical excision without histopathology, leaving 52 of 60 cases with a histologic diagnosis (Table 1). For 34 cases, the histologic diagnosis was on the OSSN spectrum, 17 had benign lesions, and 1 case had lymphoma. Of the 8 cases without



Table 1. Demographic Characteristics and Diagnoses of Study Participants

Characteristics	Cases	Controls	Total	P Value*
	N = 60	N = 60		
Female	30 (50%)	36 (60%)	66 (55%)	0.28
Region (Kilimanjaro)	35 (58.3%)	39 (65.0%)	74 (61.6%)	0.45
Occupation (outdoor)	35 (58.3%)	30 (50.0%)	65 (54.1%)	0.34
Age (yrs)				
Mean	43.5	43.7	43.6	0.95
Range	23–80	21–75	21–80	
Histologic diagnosis				
CIN I	2 (3.3%)	—	—	
CIN II	3 (5.0%)	—	—	
CIN III	5 (8.3%)	—	—	
CIS	5 (8.3%)	—	—	
SCC I	12 (20.0%)	—	—	
SCC II	4 (6.6%)	—	—	
SCC III	3 (5.0%)	—	—	
Lymphoma	1 (1.6%)	—	—	
Pterygium	5 (8.3%)	—	—	
Pingueculum	3 (5.0%)	—	—	
Papilloma	3 (5.0%)	—	—	
Other benign lesions	6 (10.0%)	—	—	
No histopathology	8 (13.3%)	—	—	
Control diagnosis				
Normal examination	—	26 (43.3%)	—	
Diabetic retinopathy	—	10 (16.6%)	—	
Cataract	—	9 (15.0%)	—	
Glaucoma	—	3 (5.0%)	—	
Astigmatism	—	6 (10.0%)	—	
Hyperopia	—	1 (1.6%)	—	
Presbyopia	—	3 (5.0%)	—	
Optic atrophy	—	1 (1.6%)	—	
Myopia	—	1 (1.6%)	—	

CIN = conjunctiva intra-epithelial neoplasia; CIS = carcinoma in situ; SCC = squamous cell carcinoma.

\*P value from conditional logistic regression for sex, region, and occupation and from Wilcoxon rank-sum test for age.

histology, the clinical diagnosis was OSSN in 6, pterygium in 1, and pingueculum in 1. Biopsy tissue was not collected from control participants with clinically normal conjunctiva. The most common clinical diagnoses of controls were normal examination results, diabetic retinopathy, and cataract (Table 1).

### Symptoms and Signs

Among individuals with conjunctival lesions, there was no difference in the frequency of various symptoms between benign and OSSN cases (Table 2). However, OSSN cases had a shorter time to presentation, suggesting a more symptomatic or rapidly evolving lesion (3.7 vs. 8.8 months;  $P = 0.03$ ). Several clinical signs were more frequently found in eyes with OSSN (with borderline statistical significance): feeder vessel, leukoplakia, and gelatinous appearance (Fig 1, Table 2). A fibrovascular appearance was more frequent among benign lesions. The OSSN lesions tended to be larger than benign lesions, although this difference was not significant (Wilcoxon rank-sum  $P = 0.8$ ).

### Human Immunodeficiency Virus and Conjunctival Lesions

Among the 52 cases (benign and OSSN) with a tissue diagnosis, there was a strong association between HIV and OSSN (58.8%)

Table 2. Symptoms and Clinical Signs by Histologic Diagnosis

	OSSN Cases	Benign Cases*	P Value†
Symptom			
Irritated red eye	21 (61.7%)	8 (44.4%)	0.26
Discharge	20 (58.8%)	11 (61.1%)	1.00
Foreign body sensation	14 (41.1%)	10 (55.5%)	0.39
Decreased vision	8 (23.5%)	3 (16.6%)	0.73
Pain	5 (14.7%)	5 (27.7%)	0.29
Proptosis	5 (14.7%)	1 (5.5%)	0.65
Itchy	2 (5.8%)	1 (5.5%)	1.00
Mean duration (mos, 95% CI)	3.7 (2.4–5.8)	8.8 (3.9–19)	0.029
Sign			
Feeder vessel	30 (88.2%)	11 (61.1%)	0.034
Limbal involvement	26 (76.4%)	9 (50.0%)	0.07
Leukoplakia	15 (44.1%)	3 (16.6%)	0.07
Gelatinous	13 (38.2%)	2 (11.1%)	0.055
Pedunculated	4 (11.7%)	2 (11.1%)	1.00
Papilliform	2 (5.8%)	1 (5.5%)	1.00
Orbital invasion	2 (5.8%)	0 (0.0%)	0.54
Fibrovascular tissue	1 (2.9%)	7 (44.4%)	0.001

CI = confidence interval; OSSN = ocular surface squamous neoplasia.

\*Including 1 lymphoma case.

†P values calculated using Fisher exact test for variables except duration, which was calculated by Wilcoxon rank-sum test.

compared with benign cases (5.6%) (odds ratio, 24.3; 95% confidence interval [CI], 2.8–204;  $P = 0.003$ ) (Table 3). Human immunodeficiency virus infection also tended to be more frequent in people with SCC compared with CIN (68.4% vs. 46.7%;  $P = 0.2$ ).

### Reliability of the Clinical Diagnosis

Eight ophthalmologists were shown a consecutive series of 43 images of conjunctival lesions and asked to classify them into 2 broad categories of benign and neoplastic. Their diagnoses were compared with the histopathology results, and kappa statistics were calculated: average kappa statistic 0.51 (95% CI, 0.36–0.64). Two ophthalmologists had “fair” agreement (kappas of 0.21 and 0.40), 3 ophthalmologists had “moderate” agreement (0.41–0.60), and 3 ophthalmologists had “substantial” agreement (0.61–0.80). The correct diagnosis was made in 56% to 86% of the cases.

### In Vivo Confocal Microscopy

In vivo confocal microscopy was attempted on all 120 cases and controls, and the scans were graded in a masked manner. Three controls were excluded because of inadequate IVCN images. Histopathology results were available for 52 of 60 cases. The archived IVCN images from 8 of 52 of the cases were not of

Table 3. Human Immunodeficiency Virus Test Results by Tissue Diagnosis of Conjunctival Lesions

Tissue Diagnosis	HIV Positive	OR	95% CI	P Value
Benign lesions*	1/18 (5.6%)	1	—	—
CIN	7/15 (46.7%)	14.9	1.56–142	0.019
SCC	13/19 (68.4%)	36.8	3.93–344	0.002

CI = confidence interval; CIN = conjunctiva intra-epithelial neoplasia; HIV = human immunodeficiency virus; OR = odds ratio; SCC = squamous cell carcinoma.

\*Including 1 lymphoma case.

Table 4. In Vivo Confocal Microscopy Features by Disease Group, Based on Masked Grading

IVCM Features	Controls	Benign Cases*	OSSN Cases	P Value <sup>†</sup>	P Value <sup>‡</sup>
	N/57 (%)	N/18 (%)	N/26 (%)		
Hyper-reflective cells				<0.001	0.9
None	54 (94.7%)	7 (38.3%)	12 (46.1%)		
<50%	3 (5.3%)	7 (38.8%)	8 (30.7%)		
>50%	0 (0.0%)	4 (22.2%)	6 (23.1%)		
Variation in cell size				<0.001	0.5
Uniform	55 (96.4%)	9 (50%)	17 (65.3%)		
Mild	1 (1.7%)	6 (33.3%)	4 (15.3%)		
Marked	1 (1.7%)	3 (16.7%)	5 (19.2%)		
Starry night appearance of basal cells				0.001	0.8
Nil	57 (100%)	14 (77.7%)	22 (84.6%)		
Few to many	0 (0.0%)	2 (11.1%)	1 (3.8%)		
Amorphous material	0 (0.0%)	2 (11.1%)	3 (11.5%)		

IVCM = in vivo confocal microscopy; OSSN = ocular surface squamous neoplasia.  
 \*Including 1 lymphoma case.  
<sup>†</sup>P value is for the comparison of normal controls with all cases (benign and malignant combined) by Fisher exact test.  
<sup>‡</sup>P value is for the comparison of benign with malignant cases, by Fisher exact test.

sufficient quality for masked grading. Therefore, the analysis of IVCM was limited to 101 participants: 44 cases (with both histopathology and adequate scans) and 57 controls.

The IVCM images were examined for the presence of specific features: hyper-reflective cells, variation of cell size, mitotic cells, and “starry night” appearance of the basal layer (Fig 2, Table 4). Several lesions showed marked surface changes on IVCM with extensive, hyper-reflective material with large irregular cellular structure. A possible mitotic cell was observed in only 1 lesion (Fig 2C). Among the 57 controls with IVCM images, 3 had some hyper-reflective cells and 2 showed some variation in epithelial cell size. For each of the graded features, there were statistically significant differences in their frequency between the normal controls and cases (benign and malignant combined). However, we found no evidence for a difference in the frequency of these IVCM features between benign and malignant conjunctival lesions.

Each set of IVCM images was given an overall classification by the masked readers: normal, benign abnormal, or malignant. The comparison of this overall IVCM classification with the histopathology diagnosis is shown in Table 5. Agreement was found to be moderate with an unweighted kappa score of 0.44 (95% CI, 0.32–0.57). The linear weighted kappa score was 0.54 (95% CI, 0.40–0.67). The sensitivity and specificity of IVCM for distinguishing OSSN from benign conjunctival lesions were 38.5% (95% CI, 0.21–0.59) and 66.7% (95% CI, 0.41–0.86), respectively.

**Discussion**

Timely detection and treatment of OSSN are challenges in East Africa, with many patients only presenting when the lesion is already established. The reasons for this are many: Access to eye care services outside the major urban centers is generally limited; therefore, patients may delay traveling

Table 5. Comparison of the Overall Classification from the In Vivo Confocal Microscopy Based on Masked Grading (Normal, Benign, or Malignant) versus the Final Histologic Diagnosis

Tissue Diagnosis	IVCM Diagnosis			Total
	Normal	Abnormal Benign	Malignant	
Normal control	50	7	0	57
Benign lesion	4	8	6	18
Malignant lesion	5	11	10	26
Total	59	26	16	101

IVCM = in vivo confocal microscopy.  
 Grey shading highlights where there was agreement.

for treatment until the lesion is more obvious and symptomatic. When patients do present, there can be further delay in making the diagnosis of OSSN because initially it may be thought to be a benign lesion. Delayed or missed diagnosis can have considerable effects on ocular morbidity and even mortality.

In this study based in an East African ophthalmic referral center, OSSN was a common cause of conjunctival pathology, with presentation rates comparable to those in previous reports from this unit.<sup>3,4</sup> Time between onset of symptoms and presentation was shorter for OSSN than for benign lesions, possibly because OSSN develops more rapidly. However, some individuals with OSSN had noticed a problem many months earlier. Strategies are needed to raise general awareness that growths on the eye need prompt attention. This is particularly important in people who have a known diagnosis of HIV, but this needs to be done in a way that minimizes stigma.

There is an overlap in the clinical signs of (early) OSSN and some benign lesions (Fig 1A, B). However, a number of features tended to be more frequent in cases of OSSN: feeder vessels, gelatinous appearance, and leukoplakia. These and other signs could form the basis of a diagnostic algorithm to assist the clinician in identifying OSSN cases, and they warrant further study in a larger data set. Overall, the 8 ophthalmologists, most of whom had seen many cases of OSSN previously, achieved only moderate agreement with the histologic diagnosis. There was a wide range in their diagnostic accuracy, suggesting that if the key features that point to a diagnosis of OSSN can be identified and emphasized in training, there should be scope to improve the detection rate.

The prevalence of HIV infection in OSSN cases was comparable to that in previous studies from the region.<sup>4</sup> Human immunodeficiency virus seems to be a risk factor for developing more severe disease, being more frequent among cases with SCC than CIN. There was no difference in the time between the onset of symptoms and the presentation between SCC and CIN, suggesting that HIV infection permits a more rapid progression in the disease.

In vivo confocal microscopy is a potentially useful tool in the management of several external eye diseases. It has been particularly helpful in the diagnosis of acanthamoeba and filamentary fungal keratitis.<sup>18</sup> We have also found the technique informative in the study of conjunctival scarring

in trachoma.<sup>19</sup> In the present study, masked analysis of IVCN clearly distinguished between normal conjunctiva and lesions (benign or malignant). A few clinically normal controls had some minor changes on IVCN, which might be attributable to solar radiation damage. In contrast, it was not possible to reliably distinguish between OSSN and benign conjunctival lesions because there seems to be an overlap in the IVCN features of these various conditions. We did not identify any features that were exclusive to OSSN. Of particular note was the finding that there were several cases of OSSN that were classified as normal on IVCN.

Our conclusion that IVCN does not reliably distinguish OSSN from other conjunctival pathology contrasts with earlier reports that suggest it may be possible to use it for this purpose.<sup>12–16</sup> However, these earlier reports, mostly from Europe (where the disease spectrum is different), have tended to be of relatively few cases. Moreover, with the exception of 1 series of 4 cases, benign lesion controls have not been recruited for comparison. Finally, the assessment of the images was not masked in all but 1 of the previous studies.<sup>16</sup> Without systematic masked comparison with benign lesions, it is difficult to know how useful the observed features are. Studies of the IVCN appearance of pterygium have reported hyper-reflective epithelial cells, a feature previously said to be associated with OSSN.<sup>20,21</sup> This is the first time IVCN has been used in Africa to study OSSN. Overall, the disease tends to be more advanced and aggressive in this context, and clinical/IVCN features may show significant variation from studies of Caucasian patients with disease largely unassociated with HIV. Further validation is needed using masked grading of OSSN and other conjunctival pathology in other settings.

### Study Limitations

First, histopathology was not available for all conjunctival lesions because the patient declined surgery or the surgeon did not send a sample for analysis. Second, it was not always possible to obtain IVCN scans of sufficient quality for the masked grading, usually because the patient was unable to tolerate the examination. Third, the masked analysis was limited to the set of stored volume scans; in practice, the formation of a diagnostic impression with IVCN is based on a continuous, dynamic examination in which the examiner is not masked to the clinical appearance of the eye. A limitation of current IVCN technology is that it is not possible to identify exactly where on the lesion the scan is collected from; therefore, it is not possible to put it in exact correspondence with findings from histopathology. Finally, the conclusions of this study may not be generalizable to the use of IVCN to detect OSSN in other settings if the distribution of disease stage is different.

In conclusion, ocular surface squamous neoplasia remains a major clinical challenge in the East African context. A simple and cheap diagnostic test to help distinguish benign from malignant pathology would be of considerable utility in the East African context, where pathology services may not be readily available.

### References

1. Pola EC, Masanganise R, Rusakaniko S. The trend of ocular surface squamous neoplasia among ocular surface tumour biopsies submitted for histology from Sekuru Kaguvi Eye Unit, Harare between 1996 and 2000. *Cent Afr J Med* 2003;49:1–4.
2. Nagaiah G, Stotler C, Orem J, et al. Ocular surface squamous neoplasia in patients with HIV infection in sub-Saharan Africa. *Curr Opin Oncol* 2010;22:437–42.
3. Poole TR. Conjunctival squamous cell carcinoma in Tanzania. *Br J Ophthalmol* 1999;83:177–9.
4. Makupa II, Swai B, Makupa WU, et al. Clinical factors associated with malignancy and HIV status in patients with ocular surface squamous neoplasia at Kilimanjaro Christian Medical Centre, Tanzania. *Br J Ophthalmol* 2012;96:482–4.
5. Parkin DM, Wabinga H, Namboozee S, Wabwire-Mangen F. AIDS-related cancers in Africa: maturation of the epidemic in Uganda. *AIDS* 1999;13:2563–70.
6. Ateenyi-Agaba C. Conjunctival squamous-cell carcinoma associated with HIV infection in Kampala, Uganda. *Lancet* 1995;345:695–6.
7. Waddell K, Kwehangana J, Johnston WT, et al. A case-control study of ocular surface squamous neoplasia (OSSN) in Uganda. *Int J Cancer* 2010;127:427–32.
8. Di Girolamo N. Association of human papilloma virus with pterygia and ocular-surface squamous neoplasia. *Eye (Lond)* 2012;26:202–11.
9. Shields CL, Shields JA. Tumors of the conjunctiva and cornea. *Surv Ophthalmol* 2004;49:3–24.
10. Waddell KM, Downing RG, Lucas SB, Newton R. Corneoconjunctival carcinoma in Uganda. *Eye (Lond)* 2006;20:893–9.
11. Sturges A, Butt AL, Lai JE, Chodosh J. Topical interferon or surgical excision for the management of primary ocular surface squamous neoplasia. *Ophthalmology* 2008;115:1297–302.
12. Duchateau N, Hugol D, D'Hermies F, et al. Contribution of in vivo confocal microscopy to limbal tumor evaluation [in French]. *J Fr Ophtalmol* 2005;28:810–6.
13. Alomar TS, Nubile M, Lowe J, Dua HS. Corneal intra-epithelial neoplasia: in vivo confocal microscopic study with histopathologic correlation. *Am J Ophthalmol* 2011;151:238–47.
14. Falke K, Zhivov A, Zimpfer A, et al. Diagnosis of conjunctival neoplastic lesions by confocal in-vivo microscopy [in German]. *Klin Monbl Augenheilkd* 2012;229:724–7.
15. Xu Y, Zhou Z, Xu Y, et al. The clinical value of in vivo confocal microscopy for diagnosis of ocular surface squamous neoplasia. *Eye (Lond)* 2012;26:781–7.
16. Parrozzani R, Lazzarini D, Dario A, Midena E. In vivo confocal microscopy of ocular surface squamous neoplasia. *Eye (Lond)* 2011;25:455–60.
17. Font RL, Croxatto JO, Rao NA. Tumors of the Eye and Ocular Adnexa. Washington, DC: American Registry of Pathology; 2006. AFIP Atlas of Tumor Pathology. Fourth series, fasc. 5.
18. Hau SC, Dart JK, Vesaluoma M, et al. Diagnostic accuracy of microbial keratitis with in vivo scanning laser confocal microscopy. *Br J Ophthalmol* 2010;94:982–7.
19. Hu VH, Weiss HA, Massae P, et al. In vivo confocal microscopy in scarring trachoma. *Ophthalmology* 2011;118:2138–46.

20. Labbe A, Gheck L, Iordanidou V, et al. An in vivo confocal microscopy and impression cytology evaluation of pterygium activity. *Cornea* 2010;29:392–9.
21. Wang Y, Zhao F, Zhu W, et al. In vivo confocal microscopic evaluation of morphologic changes and dendritic cell distribution in pterygium. *Am J Ophthalmol* 2010;150:650–5.

## Footnotes and Financial Disclosures

---

Originally received: May 14, 2013.

Final revision: September 6, 2013.

Accepted: September 18, 2013.

Available online: December 9, 2013. Manuscript no. 2013-770.

<sup>1</sup> Department of Ophthalmology, Kilimanjaro Christian Medical Centre, Moshi, Tanzania.

<sup>2</sup> Department of Pathology, University Medical Centre, Utrecht, The Netherlands.

<sup>3</sup> International Centre for Eye Health, Faculty of Infectious and Tropical Diseases, London School of Hygiene & Tropical Medicine, London, United Kingdom.

<sup>4</sup> Department of Infectious Disease Epidemiology, Faculty of Epidemiology and Population Health, London School of Hygiene and Tropical Medicine, London, United Kingdom.

<sup>5</sup> Department of Ophthalmology, University of Nairobi, Nairobi, Kenya.

Financial Disclosure(s):

The author(s) have no proprietary or commercial interest in any materials discussed in this article.

V.H.H. is supported by a fellowship grant from the British Council for the Prevention of Blindness (Barrie Jones Fellowship). M.J.B. is supported by the Wellcome Trust (080741/Z/06/Z). The funding organizations had no role in the design or conduct of this research.

Correspondence:

Matthew J. Burton, PhD, FRCOphth, International Centre for Eye Health, London School of Hygiene and Tropical Medicine, Keppel St., London, WC1E 7HT, UK. E-mail: [matthew.burton@lshtm.ac.uk](mailto:matthew.burton@lshtm.ac.uk).

## Copyright

© 2014 Gichuhi et al.; licensee BioMed Central Ltd.

This is an Open Access article distributed under the terms of the Creative Commons Attribution License (<http://creativecommons.org/licenses/by/2.0>), which permits unrestricted use, distribution, and reproduction in any medium, provided the original work is properly credited.

Source: <http://www.ncbi.nlm.nih.gov/pmc/articles/PMC4234295/>

CASE REPORT

Open Access

# Ocular rhinosporidiosis mimicking conjunctival squamous papilloma in Kenya – a case report

Stephen Gichuhi<sup>1,2\*</sup>, Timothy Onyuma<sup>3</sup>, Ephantus Macharia<sup>4</sup>, Joy Kabiru<sup>4</sup>, Alain M'bongo Zindamoyen<sup>4</sup>, Mandeep S Sagoo<sup>5,6</sup> and Matthew J Burton<sup>2,5</sup>

## Abstract

**Background:** Ocular rhinosporidiosis is a chronic granulomatous infection caused by a newly classified organism that is neither a fungus nor bacterium. It often presents as a benign conjunctival tumour but may mimic other ocular conditions. It is most often described in India. In Africa cases have been reported from South Africa, Kenya, Tanzania, Malawi, Uganda, Congo and Ivory Coast.

**Case presentation:** A 54 year old man was seen in Kenya with a lesion that resembled a conjunctival papilloma. We report resemblance to conjunctival papilloma and the result of vital staining with 0.05% Toluidine Blue.

**Conclusion:** Ocular rhinosporidiosis occurs in East Africa. It may resemble conjunctival squamous papilloma. Vital staining with 0.05% Toluidine blue dye did not distinguish the two lesions well.

**Keywords:** Ocular rhinosporidiosis, *Rhinosporidium seeberi*, Conjunctival papilloma, Toluidine-blue, Africa

## Background

Rhinosporidiosis is a chronic granulomatous infection of the mucous membranes (nasal, oral, ocular and rectal) caused by *Rhinosporidium seeberi* [1]. This is an unusual unicellular pathogen that is difficult to culture and whose taxonomic classification has been controversial. It has been variously hypothesized to be a cyanobacterium (prokaryote), a eukaryotic Mesomycetozoa or a fungus [2]. Currently it is domiciled in the Mesomycetozoa class (also known as the DRIP clade, or Ichthyosporea). The term Mesomycetozoa derives from “Meso-” (in the middle of), “-myceto-” (fungi) and “-zoa” (animals). This is a heterogeneous group of microorganisms at the animal-fungal boundary. The Mesomycetozoa are a small group of protists, which are mostly parasites of fish and other animals.

Rhinosporidiosis affects both adults and children and is commonly seen in otolaryngology. The largest reported case series of rhinosporidiosis consisting of 462 cases in India found that the disease mainly occurs in the nose and nasopharynx (81.1%) while the eye was affected in 14.2% [3]. Another series of 34 cases from

India also found nasal and nasopharyngeal involvement in 85% while the eye was affected in 9% of cases [4]. A case involving multiple parts of the body; the nares, multiple areas of the skin, the external urethral meatus, glans of penis and the perineum has been reported in India [5].

Ocular rhinosporidiosis affecting the conjunctiva was first described in India in 1912 [6]. Currently most published reports on rhinosporidiosis of the eye have been reported from Asia mainly from India, Sri Lanka, Nepal and Bangladesh. In Africa it has been reported in South Africa, Malawi, Zambia, Kenya, Uganda, Tanzania, Congo, Ivory Coast, and Cameroon [7-13]. None of the cases in Africa were initially diagnosed as ocular rhinosporidiosis, perhaps a sign of its rarity.

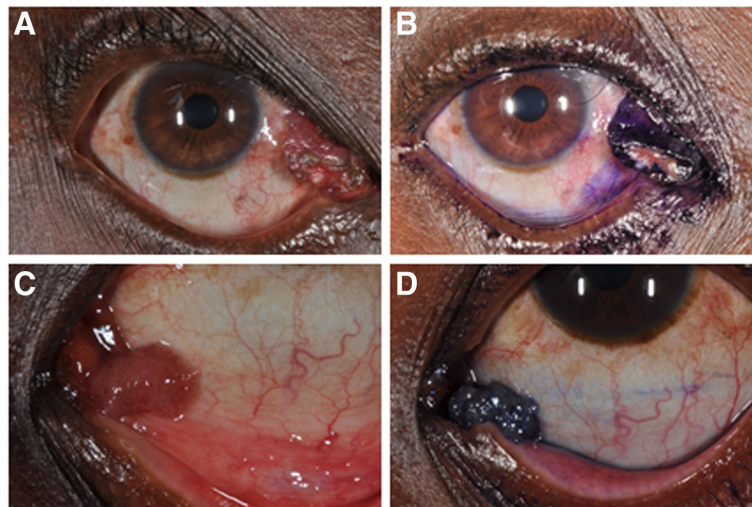
How the disease is acquired remains an enigma. Rhinosporidiosis has been associated with migrants from endemic areas [14-16]. Although it is an infectious disease, as lesions are always associated with the presence of the pathogen, there is limited data on how it might be transmitted [15]. It is presumed to be acquired through traumatized nasal mucosa and spread to other sites by autoinoculation. As most rhinosporidiosis lesions arise from the nose, it is feasible that ocular involvement may occur by spreading from the nose through the lacrimal

\* Correspondence: sgichuhi@uonbi.ac.ke

<sup>1</sup>Department of Ophthalmology, University of Nairobi, Nairobi, Kenya

<sup>2</sup>London School of Hygiene and Tropical Medicine, London, UK

Full list of author information is available at the end of the article



**Figure 1 Pre-operative clinical photographs.** A & B – shows the ocular rhinosporidiosis lesion in the region of the right medial canthus. C & D - shows squamous papilloma in the left medial canthus area from another patient for comparison. Both lesions are shown before and after vital staining with 0.05% Toluidine Blue.

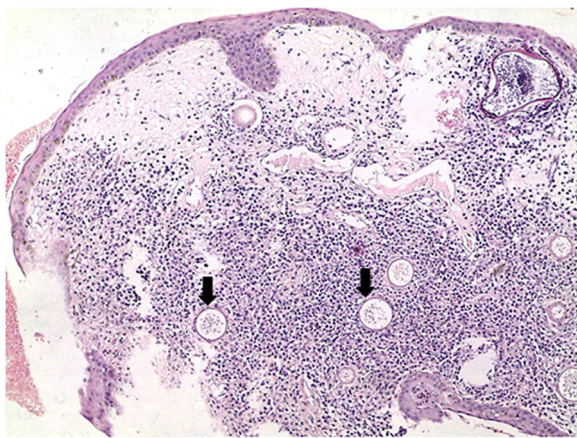
sac to the plica of the conjunctiva. This hypothesis is however unproven.

Ocular rhinosporidium most often presents as a polypoid mass of the palpebral conjunctiva [17]. It may also present as a lacrimal sac diverticulum [18], recurrent chalazion [19], conjunctival cyst [20], chronic follicular conjunctivitis in contact lens wearers [21], peripheral keratitis [22], scleral melting [23], ciliary staphyloma [24] or simulate a tumour of the eyelid [25] or periorbital skin [26]. Large conjunctival lesions may cause mechanical ectropion [27]. Lacrimal sac disease may present with bloody tears [16].

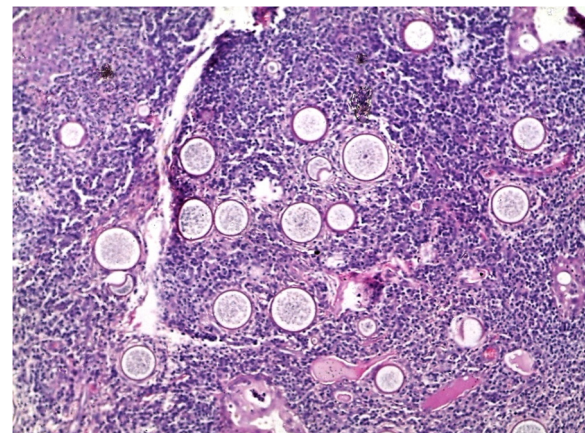
In a series of 63 cases from India that included nasal, nasopharyngeal and ocular disease, routine haematology tests did not show any abnormality and while cytology

of smears obtained via fine needle aspiration or cytology has a role in diagnosis, the mainstay remains histology [28]. Vital staining with Toluidine blue has been described for diagnosis of conjunctival tumours but not for rhinosporidiosis [29].

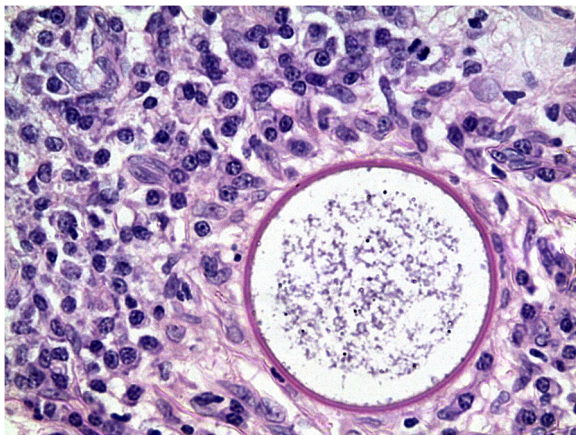
The treatment is surgical excision with or without cautery at the base and recurrence is described as rare [30]. Scleral melting may be treated with a tectonic corneal graft [31]. There are reports that the following agents are effective in vivo: imidocarb dipropionate, diminazine aceturate, cycloserine, dapsone, trimethoprim-suphadiazine, ketoconazole, sodium stibogluconate, and amphotericin B [32]. Dapsone is the most commonly reported drug and combination therapy to prevent drug resistance is recommended. A laboratory study in India found that biocides



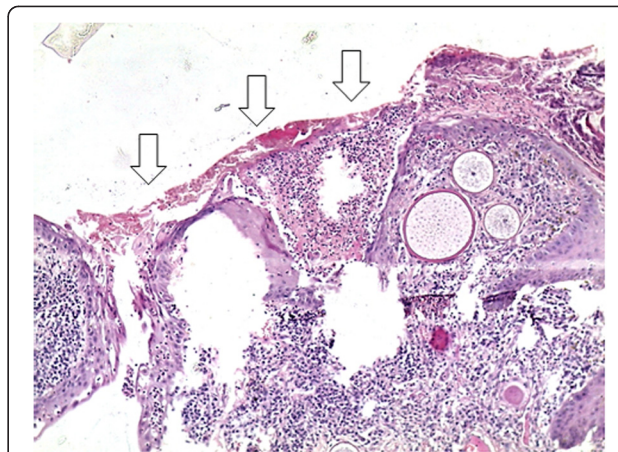
**Figure 2 Photomicrograph of ocular rhinosporidiosis stained with Haematoxylin & Eosin (H & E  $\times 10$ ) showing multiple sporangia within the conjunctival stroma (block arrows).**



**Figure 3 Multiple sporangia with a reactive mixed inflammatory cell infiltrate (H & E  $\times 20$ ).**



**Figure 4** Sporangium at higher magnification filled with endoconidia and surrounded by plasma cells and lymphocytes (H & E  $\times 40$ ).

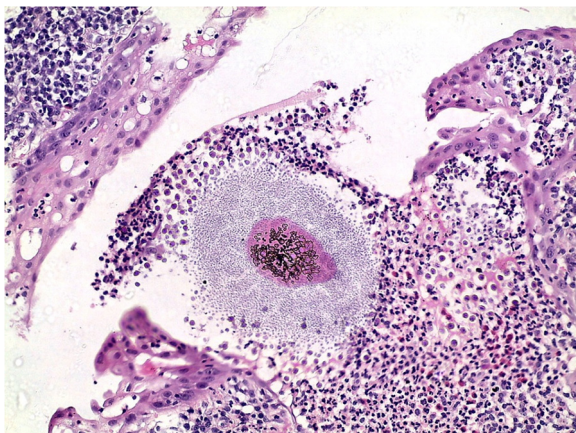


**Figure 6** Ulcerated surface epithelium (open arrows) with a fibrin plaque and granulation tissue on the basal side of the ulcer (H & E  $\times 20$ ).

including hydrogen peroxide, glutaraldehyde, chloroxyleneol, chlorhexidine, cetrimide, thimerosal, 70% ethanol, iodine in 70% ethanol, 10% formalin, povidone-iodine, sodium azide and silver nitrate caused metabolic inactivation with or without altered structural integrity of the endoconidia of *Rhinosporidium seeberii* but no human trials have been reported [33]. Human anti-rhinosporidial antibody is not directly protective against the endoconidia [34].

### Case presentation

A 54-year-old male presented to the eye clinic at the PCEA Kikuyu Hospital on the outskirts of Nairobi with a 16 month history of a painless lump on the surface of the right eye. Concerned about the appearance, he attributed the lesion to a foreign body that entered that eye while he was trimming a hedge.

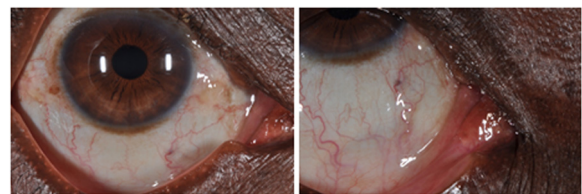


**Figure 5** Burst sporangium with discharged microsporangia surrounded by an inflammatory cell infiltrate (H & E  $\times 40$ ).

No other family member or neighbour had a similar disease. Social history included living in Homa Bay district on the shores of Lake Victoria from birth to 18 years age, then Kapsabet, a highland area in the Rift Valley until the age of 26 years, followed by Nairobi. He had resided in a low-income area of Nairobi for the past 11 years. Occupational history included working as a gardener for the last 10 years and a cook for 5 years prior to that. Although he grew up in a lakeside area, he had not dived or swum in stagnant water in the recent past.

On examination he had a pedunculated 6 $\times$ 11 mm wide fleshy mass at the medial canthus of the right eye (Figure 1), which was pink with some intrinsic pigmentation. It had a papilliform surface with vascular tufts and some epithelial ulceration. There was no discharge or conjunctival injection. The mass was not attached to the lid but arose from the plica semilunaris. On vital staining with 0.05% Toluidine Blue it was coloured deep blue except at the ulcerated surface, similar to the staining of a papilloma. The clinical diagnosis was of conjunctival papilloma and surgical excision under local anaesthetic was undertaken.

Histological analysis revealed multiple sporangia in the conjunctival stroma, an ulcerated squamous epithelium covered by a fibrin plaque whose underlying tissue showed granulomatous tissue, mixed inflammatory cells



**Figure 7** Post-operative photographs showing no recurrence 6 months after excision of ocular rhinosporidiosis.



with lymphocytes showing a maturation spectrum and numerous thick walled sporangia filled with nucleated basophilic endoconidia (Figures 2, 3, 4, 5 and 6). A diagnosis of ocular rhinosporidiosis was made.

There was no recurrence 6 months after excision was performed (Figure 7).

## Conclusions

Ocular rhinosporidiosis occurs in East Africa. It may resemble conjunctival squamous papilloma. Although toluidine blue has been used as a vital stain of conjunctival lesions, in this case, it was unable to distinguish between an infective and neoplastic cause.

## Consent

Written informed consent was obtained from the patient for publication of this case report and any accompanying images. A copy of the written consent is available for review by the Editor of this journal.

## Competing interests

The authors declare that they have no competing interests.

## Authors' contributions

SG first evaluated the case, took clinical photographs and conceived the report idea. EM performed the excision surgery. TO performed the histopathological assessment and made the diagnosis. JK reviewed the case on follow up. AMZ coordinated patient and institutional consent for publication of this clinical material. MSS and MJB evaluated the clinical and histopathology photographs. All authors read and approved the final manuscript.

## Acknowledgements

Dr. E.W. Walong of the Department of Human Pathology, University of Nairobi for taking the histology photographs.

## Author details

<sup>1</sup>Department of Ophthalmology, University of Nairobi, Nairobi, Kenya.

<sup>2</sup>London School of Hygiene and Tropical Medicine, London, UK.

<sup>3</sup>Department of Pathology, MP Shah Hospital, Nairobi, Kenya. <sup>4</sup>PCEA Kikuyu Hospital Eye Unit, Kikuyu, Kenya. <sup>5</sup>Moorfields Eye Hospital, London, UK. <sup>6</sup>UCL Institute of Ophthalmology, University College London, London, UK.

Received: 1 August 2013 Accepted: 3 April 2014

Published: 8 April 2014

## References

1. Arseculeratne SN: Rhinosporidiosis: what is the cause? *Curr Opin Infect Dis* 2005, **18**(2):113–118.
2. Vilela R, Mendoza L: The taxonomy and phylogenetics of the human and animal pathogen *Rhinosporidium seeberi*: a critical review. *Rev Iberoam Micol* 2012, **29**(4):185–199.
3. Sudarshan V, Goel NK, Gahine R, Krishnani C: Rhinosporidiosis in Raipur, Chhattisgarh: a report of 462 cases. *Indian J Pathol Microbiol* 2007, **50**(4):718–721.
4. Makannavar JH, Chavan SS: Rhinosporidiosis—a clinicopathological study of 34 cases. *Indian J Pathol Microbiol* 2001, **44**(1):17–21.
5. Mallick AA, Majhi TK, Pal DK: Rhinosporidiosis affecting multiple parts of the body. *Trop Dr* 2012, **42**(3):174–175.
6. Duke-Elder S: *Diseases of the Outer Eye*. 11th edition. St. Louis: Mosby; 1965.
7. Salazar Campos MC, Surka J, Garcia Jardon M, Bustamante N: Ocular rhinosporidiosis. *S Afr Med J* 2005, **95**(12):950–952.
8. Pe'er J, Gnessin H, Levinger S, Averbukh E, Levy Y, Polachek I: Conjunctival oculosporidiosis in east Africa caused by *Rhinosporidium seeberi*. *Arch Pathol Lab Med* 1996, **120**(9):854–858.
9. Venkataramaiah NR, van Raalte JA, Shabe JK: Rhinosporidiosis in Tanzania. *Trop Geogr Med* 1981, **33**(2):185–187.
10. Kaimbo KW, Parys-Van Ginderdeuren R: Conjunctival rhinosporidiosis: a case report from a Congolese patient. *Bull Soc Belge Ophthalmol* 2008, **309–310**:19–22.
11. Dago-Akribi A, Ette M, Diomande MI, Kioffi Y, Honde M, D'Ordock AF, Beaumel A: Clinico-pathologic aspects of rhinosporidiosis in the Ivory Coast. Report of 9 cases observed over 18 years. *Ann Pathol* 1993, **13**(2):97–99.
12. Naik KG, Shukla SM: Rhinosporidiosis in Zambia. *Med J Zambia* 1980, **14**(5):78–80.
13. Ravise P, Le Gonidec G, Moliva B: [Report on first 2 cases of rhinosporidiosis in Cameroon]. *Bulletin de la Societe de pathologie exotique et de ses filiales* 1976, **69**(3):222–224.
14. Sood N, Agarwal MC, Gugnani HC: Ocular rhinosporidiosis: a case report from Delhi. *J Infect Dev Ctries* 2012, **6**(11):825–827.
15. Arseculeratne SN: Recent advances in rhinosporidiosis and *Rhinosporidium seeberi*. *Indian J Med Microbiol* 2002, **20**(3):119–131.
16. Belliveau MJ, Strube YN, Dexter DF, Kratky V: Bloody tears from lacrimal sac rhinosporidiosis. *Can J Ophthalmol Can J Ophthalmol* 2012, **47**(5):e23–e24.
17. Ghosh AK, De Sarkar A, Bhaduri G, Datta A, Das A, Bandyopadhyay A: Ocular rhinosporidiosis. *J Indian Med Assoc* 2004, **102**(12):732–764.
18. Varshney S, Bist SS, Gupta P, Gupta N, Bhatia R: Lacrimal sac diverticulum due to Rhinosporidiosis. *Indian j otolaryngol head and neck surgery: official publication of the Assoc Otolaryngologists of India* 2007, **59**(4):353–356.
19. Mukhopadhyay S, Shome S, Bar PK, Chakrabarti A, Mazumdar S, De A, Sadhukhan K, Bala B: Ocular rhinosporidiosis presenting as recurrent chalazion. *Int Ophthalmol* 2012, 1–3. PMID 22986579.
20. Lavaju P, Arya SK, Kumar B, Upadhaya P: Conjunctival rhinosporidiosis presenting as a cystic mass—an unusual presentation. *Nepal J Ophthalmol: NEJOPH* 2010, **2**(2):157–159.
21. Suh LH, Barron J, Dubovy SR, Gaunt ML, Ledee DR, Miller D, Fell JW, Forster RK: Ocular rhinosporidiosis presenting as chronic follicular conjunctivitis in a contact lens wearer. *Arch Ophthalmol* 2009, **127**(8):1076–1077.
22. Bhomaj S, Das JC, Chaudhuri Z, Bansal RL, Sharma P: Rhinosporidiosis and peripheral keratitis. *Ophthalmic Surg Lasers* 2001, **32**(4):338–340.
23. De Doncker RM, de Keizer RJ, Oosterhuis JA, Maes A: Scleral melting in a patient with conjunctival rhinosporidiosis. *Br J Ophthalmol* 1990, **74**(10):635–637.
24. Talukder AK, Rahman MA, Islam MN, Chowdhury MH: Ciliary staphylocoma: very rare sequelae of conjunctival rhinosporidiosis. *Mymensingh Med J: MMJ* 2004, **13**(1):86–87.
25. Sharma KD, Shrivastav JB, Agarwal S: Ocular rhinosporidiosis simulating a tumour. *Br J Ophthalmol* 1958, **42**(9):572–574.
26. Vallarelli AF, Rosa SP, Souza EM: Rhinosporidiosis: cutaneous manifestation. *An Bras Dermatol* 2011, **86**(4):795–796.
27. Mandal SK, Bhakta A, Mandal A, Biswas BK: Giant mass conjunctival rhinosporidiosis causing severe mechanical ectropion. *J Indian Med Assoc* 2012, **110**(5):328–329.
28. Sinha A, Phukan JP, Bandyopadhyay G, Sengupta S, Bose K, Mondal RK, Choudhuri MK: Clinicopathological study of rhinosporidiosis with special reference to cytodiagnostics. *J cytol/Indian Acad Cytologists* 2012, **29**(4):246–249.
29. Romero IL, Barros Jde N, Martins MC, Ballalai PL: The use of 1% toluidine blue eye drops in the diagnosis of ocular surface squamous neoplasia. *Cornea* 2013, **32**(1):36–39.
30. Mithal C, Agarwal P, Mithal N: Ocular and adnexal rhinosporidiosis : the clinical profile and treatment outcomes in a tertiary eye care centre. *Nepal J Ophthalmol* 2012, **4**(1):45–48.
31. Jacob P, Rose JS, Hoshing A, Chacko G: Tectonic corneal graft for conjunctival rhinosporidiosis with scleral melt. *Indian J Ophthalmol* 2011, **59**(3):251–253.
32. Arseculeratne SN: Chemotherapy of Rhinosporidiosis: a Review. *J Infect Dis Antimicrob Agents* 2009, **26**(1):21–27.
33. Arseculeratne SN, Atapattu DN, Balasoorya P, Fernando R: The effects of biocides (antiseptics and disinfectants) on the endospores of *Rhinosporidium seeberi*. *Indian J Med Microbiol* 2006, **24**(2):85–91.
34. Arseculeratne SN, Atapattu DN, Eriyagama NB: Human anti-rhinosporidial antibody does not cause metabolic inactivation or morphological damage in endospores of *Rhinosporidium seeberi*, in vitro. *Indian J Med Microbiol* 2005, **23**(1):14–19.

doi:10.1186/1471-2415-14-45

Cite this article as: Gichuhi et al.: Ocular rhinosporidiosis mimicking conjunctival squamous papilloma in Kenya – a case report. *BMC Ophthalmology* 2014 **14**:45.

# London School of Hygiene & Tropical Medicine

Research Grants & Contracts Office  
Keppel Street, London WC1E 7HT

Tel +44 (0) 20 7927 2626 (direct) Fax +44 (0) 20 7580 5636  
e-mail: [patricia.henley@lshtm.ac.uk](mailto:patricia.henley@lshtm.ac.uk)  
[www.intra.lshtm.ac.uk/trials](http://www.intra.lshtm.ac.uk/trials)



Our ref: QA364

9 January 2012

Dr Stephen Gichuhi  
Research Student  
Dept of Clinical Research  
LSHTM

Dear Dr Gichuhi,

## Re: The epidemiology, aetiology, pathophysiology and diagnosis of ocular surface squamous neoplasia in Kenya: a case-control study

As the authorised representative for the London School of Hygiene & Tropical Medicine (LSHTM), I can confirm that LSHTM will act as the identified Research Sponsor, the organisation which takes responsibility for the initiation, management, and/or financing of a clinical trial, for the above titled project. I can confirm that the research proposal has been reviewed, assessed and registered by the Clinical Trials Sub-Committee.

It is the Chief Investigator's responsibility to ensure that members of the research team comply with all local regulations applicable to the performance of the project, including, but not limited to: the Declaration of Helsinki (2008), ICH Good Clinical Practice Guidelines (1996), and for projects conducted in the UK: the Medicines for Human Use (Clinical Trials) Regulations (2004), the Research Governance Framework for Health and Social Care (2005), the Data Protection Act (1998) and the Human Tissue Act (2004).

LSHTM carries Non Negligent Harm Insurance and Professional Negligence Insurance applicable to this study:

	Non Negligent Compensation	Medical Malpractice
<b>Insurer</b>	Lloyds (MarketForm)	Lloyds (MarketForm)
<b>Certification No.</b>	11/00066390	11/00066391
<b>Finance Cover</b>	£5 million pounds sterling	£10 million pounds sterling

The Non-Negligent harm policy is worldwide, with the exception of the United States and Canada. The policy is subject to terms, conditions and exceptions.

LSHTM Sponsorship is conditional on the project receiving applicable ethical and regulatory approval, complying with LSHTM policies and procedures, as well as successful contract and agreement negotiations from the Research Grants and Contracts Office, where relevant, before the study commences.

A copy of the ethics and regulatory approval letters **must** be sent to the Clinical Trials QA Manager prior to the study commencing. Sponsorship is dependent on obtaining local approval for all sites where the research is being conducted. It is recommended that all members of the study team attend Good Clinical Practice (GCP) training every two years.

Yours sincerely,

A handwritten signature in blue ink, appearing to read 'Patricia Henley'.

Patricia Henley  
Clinical Trials QA Manager  
on behalf of the Clinical Trials Sub-Committee

## **POLICY DOCUMENT COVERING SPONSORSHIP, WITH REGARD TO CLINICAL TRIALS**

The main responsibilities of Sponsor delegated to the Chief/Principal investigator are:

(i) Authorisations

- Obtain favourable opinion from ethics committee
- Request clinical trial authorisation (CTA) from Regulatory Authority (as required)
- Study submitted to public database (eg [www.clinicaltrials.gov](http://www.clinicaltrials.gov))
- Give notice of amendments to the protocol
- Give notice a trial has ended

(ii) Good Clinical Practice and conduct (GCP)

- Put and keep in place arrangements to adhere to GCP
- Ensure all members of study team receive appropriate training in GCP
- Take appropriate urgent safety measures

(iii) Pharmacovigilance

- Keep records of all adverse events reported by investigators
- Ensure recording and prompt reporting of suspected unexpected serious adverse reactions (SUSARS)
- Ensure investigators are informed of SUSARS
- Ensure all SUSARS including those in third countries entered into European database
- Provide annual list of suspected serious adverse reactions and a safety report

(iv) Trial Management

- Quality Control (monitoring)
- Medical Expertise
- Data Handling, and Record Keeping
- Investigator Selection
- Delegation of Responsibilities
- Record access for QA/QC and regulatory inspectors
- Clinical Trial/Study Reports
- Study Design

(v) Investigational Medicinal Product (IMP)

- Ensure Investigational Medicinal Products are available to participants free of charge
- Information on IMP kept up to date
- Manufacturing, Packaging, Labelling, and Coding of IMP
- Supplying and Handling of IMP

The main responsibilities retained by the Sponsor are:

(i) RGCO / Finance

- Contracts & Agreements
- Compensation to Subjects and Investigators
- Financing
- Confirmation of indemnity

(ii) Clinical Trials QA Manager

- Project review and organisational risk assessment
- Quality Assurance (audits)
- Investigation of non-compliance

# London School of Hygiene & Tropical Medicine

Research Grants & Contracts Office  
Keppel Street, London WC1E 7HT



Tel +44 (0) 20 7927 2626 (direct) Fax +44 (0) 20 7580 5636  
e-mail: [patricia.henley@lshtm.ac.uk](mailto:patricia.henley@lshtm.ac.uk)  
[www.intra.lshtm.ac.uk/trials](http://www.intra.lshtm.ac.uk/trials)

Our ref: QA363

9 January 2012

Dr Stephen Gichuhi  
Research Student  
Dept of Clinical Research  
LSHTM

Dear Dr Gichuhi,

**Re: A double-masked randomised placebo-controlled trial of adjuvant topical 5-fluorouracil (5FU) treatment following surgical excision of ocular surface squamous neoplasia**

As the authorised representative for the London School of Hygiene & Tropical Medicine (LSHTM), I can confirm that LSHTM will act as the identified Research Sponsor, the organisation which takes responsibility for the initiation, management, and/or financing of a clinical trial, for the above titled project. I can confirm that the research proposal has been reviewed, assessed and registered by the Clinical Trials Sub-Committee.

It is the Chief Investigator's responsibility to ensure that members of the research team comply with all local regulations applicable to the performance of the project, including, but not limited to: the Declaration of Helsinki (2008), ICH Good Clinical Practice Guidelines (1996), and for projects conducted in the UK: the Medicines for Human Use (Clinical Trials) Regulations (2004), the Research Governance Framework for Health and Social Care (2005), the Data Protection Act (1998) and the Human Tissue Act (2004).

LSHTM carries Non Negligent Harm Insurance and Professional Negligence Insurance applicable to this study:

	<b>Non Negligent Compensation</b>	<b>Medical Malpractice</b>
<b>Insurer</b>	Lloyds (MarketForm)	Lloyds (MarketForm)
<b>Certification No.</b>	11/00066390	11/00066391
<b>Finance Cover</b>	£5 million pounds sterling	£10 million pounds sterling

The Non-Negligent harm policy is worldwide, with the exception of the United States and Canada. The policy is subject to terms, conditions and exceptions.

LSHTM Sponsorship is conditional on the project receiving applicable ethical and regulatory approval, complying with LSHTM policies and procedures, as well as successful contract and agreement negotiations from the Research Grants and Contracts Office, where relevant, before the study commences.

A copy of the ethics and regulatory approval letters **must** be sent to the Clinical Trials QA Manager prior to the study commencing. Sponsorship is dependent on obtaining local approval for all sites where the research is being conducted. It is recommended that all members of the study team attend Good Clinical Practice (GCP) training every two years.

Yours sincerely,

Patricia Henley  
Clinical Trials QA Manager  
on behalf of the Clinical Trials Sub-Committee

## POLICY DOCUMENT COVERING SPONSORSHIP, WITH REGARD TO CLINICAL TRIALS

The main responsibilities of Sponsor delegated to the Chief/Principal investigator are:

- (i) Authorisations
  - Obtain favourable opinion from ethics committee
  - Request clinical trial authorisation (CTA) from Regulatory Authority (as required)
  - Study submitted to public database (eg [www.clinicaltrials.gov](http://www.clinicaltrials.gov))
  - Give notice of amendments to the protocol
  - Give notice a trial has ended
- (ii) Good Clinical Practice and conduct (GCP)
  - Put and keep in place arrangements to adhere to GCP
  - Ensure all members of study team receive appropriate training in GCP
  - Take appropriate urgent safety measures
- (iii) Pharmacovigilance
  - Keep records of all adverse events reported by investigators
  - Ensure recording and prompt reporting of suspected unexpected serious adverse reactions (SUSARS)
  - Ensure investigators are informed of SUSARS
  - Ensure all SUSARS including those in third countries entered into European database
  - Provide annual list of suspected serious adverse reactions and a safety report
- (iv) Trial Management
  - Quality Control (monitoring)
  - Medical Expertise
  - Data Handling, and Record Keeping
  - Investigator Selection
  - Delegation of Responsibilities
  - Record access for QA/QC and regulatory inspectors
  - Clinical Trial/Study Reports
  - Study Design
- (v) Investigational Medicinal Product (IMP)
  - Ensure Investigational Medicinal Products are available to participants free of charge
  - Information on IMP kept up to date
  - Manufacturing, Packaging, Labelling, and Coding of IMP
  - Supplying and Handling of IMP

The main responsibilities retained by the Sponsor are:

- (i) RGCO / Finance
  - Contracts & Agreements
  - Compensation to Subjects and Investigators
  - Financing
  - Confirmation of indemnity
- (ii) Clinical Trials QA Manager
  - Project review and organisational risk assessment
  - Quality Assurance (audits)
  - Investigation of non-compliance



**Observational / Interventions Research Ethics Committee**

Dr Stephen Gichuhi  
Research student  
CRD/ ITD  
LSHTM

20 November 2012

Dear Dr Gichuhi,

**Study Title:** **Epidemiology and management of ocular surface squamous neoplasia in Kenya**  
**LSHTM ethics ref:** **6096**  
**LSHTM amend no:** **A369**

Thank you for your application of 31 October 2012 for the amendment above to the existing ethically approved study and submitting revised documentation. The amendment application has been considered by the Interventions Committee.

**Confirmation of ethical opinion**

On behalf of the Committee, I am pleased to confirm a favourable ethical opinion for the above amendment to research on the basis described in the application form, protocol and supporting documentation as revised, subject to the conditions specified below.

**Conditions of the favourable opinion**

Approval is dependent on local ethical approval for the amendment having been received, where relevant.

**Approved documents**

The final list of documents reviewed and approved by the Committee is as follows:

Document	Version	Date
LSHTM amendment application	n/a	
Amended protocol OSSN Case control study protocol with pilot staining submitted to LSHTM ethics	2	19/10/2012

**After ethical review**

Any further changes to the application must be submitted to the Committee via an E2 amendment form. The Principal Investigator is reminded that all studies are also required to notify the ethics committee of any serious adverse events which occur during the project via form E4. At the end of the study, please notify the committee via form E5.

Yours sincerely,

**Professor Andrew J Hall**  
Chair  
[ethics@lshtm.ac.uk](mailto:ethics@lshtm.ac.uk)  
<http://intra.lshtm.ac.uk/management/committees/ethics/>



**Observational / Interventions Research Ethics Committee**

Dr Stephen Gichuhi  
Research student  
CRD/ ITD  
LSHTM

20 November 2012

Dear Dr Gichuhi,

**Study Title:** A double-masked randomised placebo-controlled trial of adjuvant topical 5-fluorouracil (5FU) treatment following surgical excision of ocular surface squamous neoplasia

**LSHTM ethics ref:** 6097

**LSHTM amend no:** A370

Thank you for your application of 31 October 2012 for the amendment above to the existing ethically approved study and submitting revised documentation. The amendment application has been considered by the Interventions Committee.

**Confirmation of ethical opinion**

On behalf of the Committee, I am pleased to confirm a favourable ethical opinion for the above amendment to research on the basis described in the application form, protocol and supporting documentation as revised, subject to the conditions specified below.

**Conditions of the favourable opinion**

Approval is dependent on local ethical approval for the amendment having been received, where relevant.

**Approved documents**

The final list of documents reviewed and approved by the Committee is as follows:

Document	Version	Date
LSHTM amendment application	n/a	
amended OSSN RCT protocol v2	2	19/10/2011

**After ethical review**

Any further changes to the application must be submitted to the Committee via an E2 amendment form. The Principal Investigator is reminded that all studies are also required to notify the ethics committee of any serious adverse events which occur during the project via form E4. < At the end of the study, please notify the committee via form E5.

Yours sincerely,

**Professor Andrew J Hall**

Chair

[ethics@lshtm.ac.uk](mailto:ethics@lshtm.ac.uk)

<http://intra.lshtm.ac.uk/management/committees/ethics/>



**Observational / Interventions Research Ethics Committee**

Stephen Gichuhi  
Research Degree Student  
CR / ITD  
LSHTM

19 June 2013

Dear Dr. Gichuhi,

**Study Title:** **Epidemiology and management of ocular surface squamous neoplasia in Kenya**  
**LSHTM ethics ref:** **6096**  
**LSHTM amend no:** **A422**

Thank you for your application of 21 May 2013 for the amendment above to the existing ethically approved study and submitting revised documentation. The amendment application has been considered by the Interventions Committee.

**Confirmation of ethical opinion**

On behalf of the Committee, I am pleased to confirm a favourable ethical opinion for the above amendment to research on the basis described in the application form, protocol and supporting documentation as revised, subject to the conditions specified below.

**Conditions of the favourable opinion**

Approval is dependent on local ethical approval for the amendment having been received, where relevant.

**Approved documents**

The final list of documents reviewed and approved by the Committee is as follows:

Document	Version	Date
LSHTM amendment application	n/a	
Amended protocol OSSN Case control study protocol	3	6/5/2013

**After ethical review**

Any further changes to the application must be submitted to the Committee via an E2 amendment form. The Principal Investigator is reminded that all studies are also required to notify the ethics committee of any serious adverse events which occur during the project via form E4. An annual report form (form E3) is required on the anniversary of the approval of the study and should be submitted during the lifetime of the study. At the end of the study, please notify the committee via form E5.

Yours sincerely,

**Professor John DH Porter**  
**Chair**

[ethics@lshtm.ac.uk](mailto:ethics@lshtm.ac.uk)

<http://intra.lshtm.ac.uk/management/committees/ethics/>





## OBSERVATIONAL/INTERVENTIONS RESEARCH ETHICS COMMITTEE

19 January 2012

Stephen Gichuhi

Dear Stephen

**Study Title:** A double-masked randomised placebo-controlled trial of adjuvant topical 5-fluorouracil (5FU) treatment following surgical excision of ocular surface squamous neoplasia

**LSHTM ethics ref:** 6097

**Department:** Infectious and Tropical Diseases

The Committee reviewed the above application.

### Documents reviewed

The documents reviewed were:

<i>Document</i>	<i>Version</i>	<i>Date</i>	
LSHTM ethics application	n/a	19/01/12	
Protocol	V1.0	19/01/12	
Information Sheet	V1.0	19/01/12	
Consent form	V1.0	19/01/12	

### Provisional opinion

The Committee would be content to give a favourable ethical opinion of the research, subject to receiving a complete response to the request for further information set out below.

The Committee delegated authority to confirm its final opinion on the application to the Chair.

### Further information or clarification required

- Please provide a reference for the 20% recurrence rate - the document mentions 30-66% recurrence within 2 years only currently.
- Clarify why 5-fluorouracil was selected over mitomycin or interferon - was this simply an issue of cost?

When submitting your response to the Committee, please send revised documentation where appropriate underlining or otherwise highlighting the changes you have made and giving revised version numbers and dates.

If the Committee has asked for clarification or changes to any answers given in the application form, please do not submit a revised copy of the application form; these can be addressed in a covering letter to the Committee.  
Yours sincerely,

**Professor Andrew J Hall**  
Chair

25<sup>th</sup> January 2012

Prof. Andrew J. Hall

**Study Title:**                    **A double-masked randomised placebo-controlled trial of adjuvant topical 5-fluorouracil (5FU) treatment following surgical excision of ocular surface squamous neoplasia**

**LSHTM ethics ref:**        **6097**

**Department:**                **Infectious and Tropical Diseases**

Thank you for your letter dated 19<sup>th</sup> January 2012 requesting further information and clarification.


Regarding the 20% recurrence rate, operationally, published rates mostly vary between 30-60% (summarised in the appendix attached) and involve a surgical technique in which the tumour is excised and the sclera left bare. The lowest rate is 3.2% from a surgeon in Uganda who is probably the most experienced in East Africa. In our study we will have fairly experienced surgeons and the surgical technique will involve primary closure of the excision site by mobilizing adjoining conjunctiva or using a conjunctival autograft. We think this would reduce the recurrence rate to below 30%. In addition, if we used 30% for sample size calculation, we would require a smaller sample but 20% would increase the sample size. We chose to use a more conservative estimate.

With respect to the choice of 5FU, this was based on the fact that it is less costly, has lower ocular toxicity and is more easily available in East Africa. This would make translation of the trial results easier in the East African eye care setting. In addition, there is no published trial evidence that either 5FU, Mitomycin C or Interferon is better than the other for the treatment of ocular surface squamous neoplasia.

Yours sincerely,

Stephen Gichuhi

Encs. Summary of published recurrence rates



UNIVERSITY OF NAIROBI  
COLLEGE OF HEALTH SCIENCES  
P O BOX 19676 Code 00202  
Telegrams: varsity  
(254-020) 2726300 Ext 44355

KNH/UON-ERC  
Email: uonkuh\_erc@uonbi.ac.ke  
Website: www.uonbi.ac.ke  
Link: uonbi.ac.ke/activities/KNHUoN



KENYATTA NATIONAL HOSPITAL  
P O BOX 20723 Code 00202  
Tel: 726300-9  
Fax: 725272  
Telegrams: MEDSUP, Nairobi

Ref. No.KNH/ERC/R/47

17<sup>th</sup> April 2014

Dr. Stephen Gichuhi  
Dept.of Ophthalmology  
School of Medicine  
University of Nairobi

Dear Dr.Gichuhi

**Re: Approval of annual renewal – Epidemiology and management of ocular surface squamous Neoplasia(OSSN) in Kenya (P459/11/2011)**

Refer your communication of March 24, 2014.

This is to acknowledge receipt of the study progress report and hereby grant you annual extension of approval for ethical research Protocol **P459/11/2011**.

The renewal periods are 15<sup>th</sup> March 2014 –14<sup>th</sup> March 2015.

This approval is subject to compliance with the following requirements:

- a) Only approved documents (informed consents, study instruments, advertising materials etc) will be used.
- b) All changes (amendments, deviations, violations etc) are submitted for review and approval by KNH/UoN ERC before implementation.
- c) Death and life threatening problems and severe adverse events (SAEs) or unexpected adverse events whether related or unrelated to the study must be reported to the KNH/UoN- ERC within 72 hours of notification.
- d) Any changes, anticipated or otherwise that may increase the risks or affect safety or welfare of study participants and others or affect the integrity of the research must be reported to KNH/UoN ERC within 72 hours.
- e) Submission of a request for renewal of approval at least 60 days prior to expiry of the approval period. *(Attach a comprehensive progress report to support the renewal).*
- f) Clearance for export of biological specimens must be obtained from KNH/UoN-Ethics & Research Committee for each batch of shipment.


Protect to Discover

- g) Submission of an *executive summary* report within 90 days upon completion of the study  
This information will form part of the data base that will be consulted in future when processing related research studies so as to minimize chances of study duplication and/or plagiarism.

For more details consult the KNH/UoN -ERC website [www.uonbi.ac.ke/activities/KNHUoN](http://www.uonbi.ac.ke/activities/KNHUoN)


Kindly forward the informed consent documents for endorsement with updated stamp.

Yours sincerely



**PROF. M.L. CHINDIA**  
**SECRETARY, KNH/UON-ERC**

- c.c. The Deputy Director CS, KNH  
The Principal, College of Health Sciences, UoN  
The Chairperson, KNH/UoN-ERC  
The Dean, School of Medicine, UoN  
The Chairman, Dept. of Ophthalmology, UoN



**UNIVERSITY OF NAIROBI**  
**COLLEGE OF HEALTH SCIENCES**  
P O BOX 19676 Code 00202  
Telegrams: varsity  
(254-020) 2726300 Ext 44355

**KNH/UON-ERC**  
Email: [nonknh\\_erc@uonbi.ac.ke](mailto:nonknh_erc@uonbi.ac.ke)  
Website: [www.uonbi.ac.ke](http://www.uonbi.ac.ke)  
Link: [uonbi.ac.ke/activities/KNHUoN](http://uonbi.ac.ke/activities/KNHUoN)

**KENYATTA NATIONAL HOSPITAL**  
P O BOX 20723 Code 00202  
Tel: 726300-9  
Fax: 725272  
Telegrams: MEDSUP, Nairobi

Ref. No.KNH/ERC/R/62

7<sup>th</sup> May 2013

Dr. Stephen Gichuhi  
Dept of Ophthalmology  
School of Medicine  
University of Nairobi

Dear Dr. Gichuhi

**Re: Approval of annual renewal – study titled “Epidemiology and management of ocular surface squamous neoplasia(OSSN) in Kenya (P459/11/2011)”**

---

Refer your communication of 11<sup>th</sup> April 2013.

This is to grant you annual extension of approval for ethical research Protocol P459/11/2011.

The renewal periods are 15<sup>th</sup> March 2013 – 14<sup>th</sup> March 2014.

This approval is subject to compliance with the following requirements:

- a) Only approved documents (informed consents, study instruments, advertising materials etc) will be used.
- b) All changes (amendments, deviations, violations etc) are submitted for review and approval by KNH/UoN ERC before implementation.
- c) Death and life threatening problems and severe adverse events (SAEs) or unexpected adverse events whether related or unrelated to the study must be reported to the KNH/UoN- ERC within 72 hours of notification.
- d) Any changes, anticipated or otherwise that may increase the risks or affect safety or welfare of study participants and others or affect the integrity of the research must be reported to KNH/UoN ERC within 72 hours.
- e) Submission of a request for renewal of approval at least 60 days prior to expiry of the approval period. (Attach a comprehensive progress report to support the renewal).
- f) Clearance for export of biological specimens must be obtained from KNH/UoN-Ethics & Research Committee for each batch of shipment.


“Protect to discover”

- g) Submission of an executive summary report within 90 days upon completion of the study  
This information will form part of the data base that will be consulted in future when processing related research studies so as to minimize chances of study duplication and/or plagiarism.

For more details consult the KNH/UoN -ERC website [www.uonbi.ac.ke/activities/KNHUoN](http://www.uonbi.ac.ke/activities/KNHUoN)

Kindly forward the informed consent documents for endorsement with updated stamp.

Yours sincerely



**PROF. A.N. GUANTAI**  
**CHAIRPERSON, KNH/UON-ERC**

- c.c. The Deputy Director CS, KNH  
The Principal, College of Health Sciences, UoN  
The Dean, School of Medicine, UoN  
The Chairman, Dept. of Ophthalmology, UoN



**UNIVERSITY OF NAIROBI  
COLLEGE OF HEALTH SCIENCES**

P O BOX 19676 Code 00202  
Telegrams: varsity  
(254-020) 2726300 Ext 44355

**KNH/UON-ERC**

Email: [uonknh\\_erc@uonbi.ac.ke](mailto:uonknh_erc@uonbi.ac.ke)  
Website: [www.uonbi.ac.ke](http://www.uonbi.ac.ke)  
Link: [www.uonbi.ac.ke/activities/KNHUoN](http://www.uonbi.ac.ke/activities/KNHUoN)



**KENYATTA NATIONAL HOSPITAL**

P O BOX 20723 Code 00202

Tel: 726300-9

Fax: 725272

Telegrams: MEDSUP, Nairobi

Ref: KNH-ERC/ MOD/475

19<sup>th</sup> December 2012

Dr. Stephen Gichuhi  
Dept. of Ophthalmology  
School of Medicine  
University of Nairobi

Dear Dr. Gichuhi

**Re: Approval of modifications study titled "Epidemiology and management of ocular surface squamous neoplasia in Kenya" (P459/11/2011)**

---

Refer your communication of October 10, 2012.

Your letter dated 10<sup>th</sup> October 2012 refers.

The KNH/UoN-ERC has reviewed your request and has granted approval to:

1. Include Sabatia Mission, Kitale and Homa Bay District hospital as study sites.
2. Included Dr. Onyuma to replace Prof. Rana who passed on.
3. Include participants with history of allergic conductivities without clear history of topical steroid use and also participants from the randomized trial presenting with recurrences.
4. Conduct human papillomavirus genome sequencing on a small sample of 20 at the Sanger Institute.
5. Use UNITID instead of KEMRI to carry out PCR Tests.

**NB:** You need to revise the informed consent documents to remove Prof. K.M. Bhatt's name as she is no longer a member of the KNH/UoN-ERC.

Yours sincerely

**PROF.A.N. GUANTAI  
SECRETARY, KNH/UON-ERC**

c.c. The Deputy Director CS, KNH  
The Principal, College of Health Sciences, UoN  
The Dean, School of Medicine, UoN  
The Chairman, Dept. of Ophthalmology, UoN

*"Protect to Discover"*



**UNIVERSITY OF NAIROBI**  
COLLEGE OF HEALTH SCIENCES  
P O BOX 19676 Code 00202  
Telegrams: varsity  
(254-020) 2726300 Ext 44355

**KNH/UON-ERC**  
Email: [uonknh\\_erc@uonbi.ac.ke](mailto:uonknh_erc@uonbi.ac.ke)  
Website: [www.uonbi.ac.ke](http://www.uonbi.ac.ke)  
Link: [www.uonbi.ac.ke/activities/KNHUoN](http://www.uonbi.ac.ke/activities/KNHUoN)



**KENYATTA NATIONAL HOSPITAL**  
P O BOX 20723 Code 00202  
Tel: 726300-9  
Fax: 725272  
Telegrams: MEDSUP, Nairobi

Ref: KNH-ERC/A/56

15<sup>th</sup> March 2012

Dr. Stephen Gichuhi  
Dept. of Ophthalmology  
School of Medicine  
University of Nairobi

Dear Dr. Gichuhi

**RESEARCH PROPOSAL: "EPIDEMIOLOGY AND MANAGEMENT OF OCULAR SURFACE SQUAMOUS NEOPLASIA IN KENYA"(P459/11/2011)**

---

This is to inform you that the KNH/UoN-Ethics & Research Committee (ERC) has reviewed and **approved** your above revised research proposal. The approval periods are 15<sup>th</sup> March 2012 to 14<sup>th</sup> March 2013.

This approval is subject to compliance with the following requirements:


- a) Only approved documents (informed consents, study instruments, advertising materials etc) will be used.
- b) All changes (amendments, deviations, violations etc) are submitted for review and approval by KNH/UoN ERC before implementation.
- c) Death and life threatening problems and severe adverse events (SAEs) or unexpected adverse events whether related or unrelated to the study must be reported to the KNH/UoN ERC within 72 hours of notification.
- d) Any changes, anticipated or otherwise that may increase the risks or affect safety or welfare of study participants and others or affect the integrity of the research must be reported to KNH/UoN ERC within 72 hours.
- e) Submission of a request for renewal of approval at least 60 days prior to expiry of the approval period. (*Attach a comprehensive progress report to support the renewal*).
- f) Clearance for export of biological specimens must be obtained from KNH/UoN-Ethics & Research Committee for each batch of shipment.
- g) Submission of an *executive summary* report within 90 days upon completion of the study  
This information will form part of the data base that will be consulted in future when processing related research studies so as to minimize chances of study duplication and/or plagiarism.

For more details consult the KNH/UoN -ERC website [www.uonbi.ac.ke/activities/KNHUoN](http://www.uonbi.ac.ke/activities/KNHUoN)

**"Protect to Discover"**



Yours sincerely



**PROF A.N. GUANTAI**  
**SECRETARY, KNH/UON-ERC**

- c.c. The Deputy Director CS, KNH  
The Principle, College of Health Sciences, UON  
The Dean, School of Medicine, UON  
The Chairman, Dept. of Ophthalmology, UON  
The HOD, Records, KNH  
Supervisors: Dr. Mathew Burton, London School of Hygiene & Tropical Medicine  
Dr. Helen Weiss, London School of Hygiene & Tropical Medicine



**REPUBLIC OF KENYA  
MINISTRY OF HEALTH  
PHARMACY AND POISONS BOARD**

Telegrams: "MINIHEALTH", Nairobi  
Telephone: Nairobi 020 2716905/6 , 3562107  
Cellphone: 0733 – 884411/0720608811  
Fax: 2713409

PHARMACY AND POISONS BOARD HOUSE  
LENANA ROAD  
P.O. BOX 27663-00506  
NAIROBI

When replying please quote

**Ref. No. PPB/ECCT/12/04/01/2014(116)**

**15<sup>th</sup> December 2014**

**Dr. Stephen Gichuhi**

**Principal Investigator ECCT/12/04/01**

**University of Nairobi, College of Health sciences**

**Department of Ophthalmology**

**P. O Box 19676, 00202**

**Nairobi, Kenya**

Dear Sir,

**Re: ECCT/12/04/01: A Double- masked Randomized Placebo-controlled Trial of Adjuvant Topical 5-Fluorouracil (5FU) Treatment following Surgical Excision of Ocular Surface Squamous Neoplasia.**

Reference is made to the above study.

We acknowledge receipt of the following documents

1. Cover letter dated 15<sup>th</sup> December 2015, requesting for annual approval
2. KNH/UON ERC annual approval dated 17<sup>th</sup> April 2014
3. Progress report
4. IDMC Minutes for meeting held on 28<sup>th</sup> April 2014
5. Two SAE reports
6. Package insert for Fluracedyl published on 8<sup>th</sup> January 2002.

Upon review of the above documents, the Pharmacy and Poisons Board's Expert Committee on Clinical Trials is satisfied and grants annual approval to the research protocol: **A Double- masked Randomized**

**Placebo-controlled Trial of Adjuvant Topical 5-Fluorouracil (5FU) Treatment following Surgical Excision of Ocular Surface Squamous Neoplasia (ECCT/12/04/01).**

This approval is valid for one year and in case the study extends beyond one year, you are required to file with us the continuous review approval letter from the ERC on record for our acknowledgement before proceeding.

Please take note that it is your responsibility to inform the Pharmacy and Poisons Board of any changes to protocol, research design and procedures that could introduce new or more than minimum risk to the human subjects.

The Pharmacy and Poisons Board requires you to provide regular updates and half yearly reports, especially on Suspected Unexpected Serious Adverse Reactions (SUSARs) from the study, for monitoring purposes and involve PPB where necessary.

Upon conclusion of the study, you shall be required to send us the executive summary report of the study within 30 days while a copy of the clinical study report should be submitted within 60 days of the study closure.

Yours sincerely,



**Dr. Edward Abwao**

**For Registrar**

REPUBLIC OF KENYA  
MINISTRY OF MEDICAL SERVICES  
PHARMACY AND POISONS BOARD

Telegram: "MINIHEALTH" Nairobi  
Telephone: 020-2716905/6, 020-3562107  
Cellphone: 0733-884411/0720 608811  
Fax: 2713409  
E-mail: info@pharmacyboardkenya.org



PHARMACY AND POISONS BOARD HOUSE  
LENANA ROAD  
P. O. Box 27663-00506  
NAIROBI

When replying please quote

Ref. No. PPB/ECCT/12/04/01/12 (132)

23<sup>rd</sup> December 2013

**Dr. Stephen Gichuhi**

**Principal Investigator ECCT/12/04/01**

**University of Nairobi, College of Health sciences**

**Department of Ophthalmology**

**P. O Box 19676, 00202**

**Nairobi, Kenya**

**Re: ECCT/12/04/01: A Double- masked Randomized Placebo-controlled Trial of Adjuvant Topical 5-Fluorouracil (5FU) Treatment following Surgical Excision of Ocular Surface Squamous Neoplasia.**

Reference is made to the above study.

We acknowledge receipt of the following documents

1. Cover letter dated 23<sup>rd</sup> December 2013, requesting for annual approval
2. KNH/UON ERC annual approval dated 7<sup>th</sup> May 2013
3. Progress report
4. IDMC Minutes for meeting held on 14<sup>th</sup> February 2013

Upon review of the above documents, the Pharmacy and Poisons Board's Expert Committee on Clinical Trials is satisfied and grants annual approval to the research protocol: **A Double-masked Randomized Placebo-controlled Trial of Adjuvant Topical 5-Fluorouracil (5FU) Treatment following Surgical Excision of Ocular Surface Squamous Neoplasia (ECCT/12/04/01).**

This approval is valid for one year and in case the study extends beyond one year, you are required to file with us the continuous review approval letter from the ERC on record for our acknowledgement before proceeding.

Please take note that it is your responsibility to inform the Pharmacy and Poisons Board of any changes to protocol, research design and procedures that could introduce new or more than minimum risk to the human subjects.

The Pharmacy and Poisons Board requires you to **provide regular updates and half yearly reports**, especially on Suspected Unexpected Serious Adverse Reactions (SUSARs) from the study, for monitoring purposes and involve PPB where necessary.

Upon conclusion of the study, you shall be required to send us the executive summary report of the study within 30 days while a copy of the clinical study report should be submitted within 60 days of the study closure.

Yours faithfully,



**Dr. Edward Abwao**

**Directorate of Medicines Information and Pharmacovigilance**

**For Registrar**

REPUBLIC OF KENYA  
MINISTRY OF MEDICAL SERVICES  
PHARMACY AND POISONS BOARD

Telegram: "MINHEALTH" Nairobi  
Telephone: 020-2716905/6, 020-3562107  
Cellphone: 0733-884411/0720 608811  
Fax: 2713409  
E-mail: info@pharmacyboardkenya.org



PHARMACY AND POISONS BOARD HOUSE  
LENANA ROAD  
P.O Box 27663-00506  
NAIROBI

When replying please quote  
Ref. No. PPB/ECCT/12/04/01/12 (74)

14<sup>th</sup> June 2012

**Dr. Stephen Gichuhi**

**Principal Investigator ECCT/12/04/01**

**University of Nairobi, College of Health sciences**

**Department of Ophthalmology**

**P. O Box 19676, 00202**

**Nairobi, Kenya**

**Re: ECCT/12/04/01: A Double- masked Randomized Placebo-controlled Trial of Adjuvant Topical 5-Fluorouracil (5FU) Treatment following Surgical Excision of Ocular Surface Squamous Neoplasia.**

Reference is made to the above study.

We acknowledge receipt of your responses to the issues raised during the initial review of the above proposal.

Upon review of the submission, the Pharmacy and Poisons Board's Expert Committee on Clinical Trials is satisfied and grants approval to the research protocol: **A Double- masked Randomized Placebo-controlled Trial of Adjuvant Topical 5-Fluorouracil (5FU) Treatment following Surgical Excision of Ocular Surface Squamous Neoplasia (ECCT/12/04/01)**

In case the study extends beyond one year from the date of this letter, you are required to file with us the continuous review approval letter from the ERC on record for our acknowledgement before proceeding.

Please take note that it is your responsibility to inform the Pharmacy and Poisons Board of any changes to protocol, research design and procedures that could introduce new or more than minimum risk to the human subjects.

The Pharmacy and Poisons Board requires you to provide **regular updates and half yearly reports**, especially on Suspected Unexpected Serious Adverse Reactions (SUSARS) from the study, for monitoring purposes and involve the PPB where necessary.

Yours faithfully,



**Dr. Edward Abwao**

**Division of Medicines Information and Pharmacovigilance**

**For Registrar**



## SOUTH AFRICAN COCHRANE CENTRE

PO Box 19070, Tygerberg, 7505, South Africa;  
Francie van Zijl Drive, Parow Valley, Cape Town  
Tel: +27 21 938 0438; Fax: +27 21 938 0836  
E-mail: [cochrane@mrc.ac.za](mailto:cochrane@mrc.ac.za)



24 July 2012

To Whom It May Concern:

**re: Adjuvant topical 5fluorouracil (5FU) for ocular surface squamous neoplasia**

As project manager for the Pan African Clinical Trial Registry ([www.pactr.org](http://www.pactr.org)) database, it is my pleasure to inform you that your application to our registry has been accepted. Your unique identification number for the registry is PACTR201207000396219.

Please be advised that you are responsible for updating your trial, or for informing us of changes to your trial.

Additionally, please provide us with copies of your ethical clearance letters as we must have these on file (via email, post or fax) at your earliest convenience if you have not already done so.

Please do not hesitate to contact us at +27 21 938 0506 or email [aabrams@mrc.ac.za](mailto:aabrams@mrc.ac.za) should you have any questions.

Yours faithfully,

Amber Abrams  
[www.pactr.org](http://www.pactr.org) Project Manager  
+27 021 938 0506





**1. Title**

A double-masked randomised placebo-controlled trial of adjuvant topical 5-fluorouracil (5FU) treatment following surgical excision of ocular surface squamous neoplasia.

## Table of Contents

1. Title .....	1
2. Investigators, co-investigators and supervisors.....	3
3. Collaborating institutions .....	5
4. Funding agency .....	5
5. Summary .....	5
6. Background .....	5
7. Rationale.....	8
8. Research question .....	8
9. Objectives.....	8
10. Study design and Methodology.....	9
11. Ethical considerations.....	20
12. Data management.....	21
13. Study limitations and how to minimize them .....	23
14. Timeline .....	23
15. References .....	24
16. Appendix.....	28
Appendix 1 Statistical analysis plan .....	28
Appendix 2 – Flow chart for reporting of safety events.....	31

**2. Investigators, co-investigators and supervisors**

Dr Stephen Gichuhi MBChB, M.Med, MBA, MSc (Epidemiology)

Research Degree Student

International Centre for Eye Health (ICEH)

Faculty of Infectious and Tropical Diseases

London School of Hygiene & Tropical Medicine

Senior Lecturer

Department of Ophthalmology

University of Nairobi

PO Box 19676-00202

Nairobi.

Tel: +254-722873059 (m), +254-20-2726300 ext. 43776 (o)

Email: [sgichuhi@uonbi.ac.ke](mailto:sgichuhi@uonbi.ac.ke)

Signed: \_\_\_\_\_

*Supervisor:*

Dr Matthew Burton PhD, MA, MBBCh, DTM&H, MRCP, FRCOphth

Senior Lecturer

International Centre for Eye Health (ICEH)

Faculty of Infectious and Tropical Diseases

London School of Hygiene & Tropical Medicine

Keppel Street

London, WC1E 7HT

Tel: +44 (0)20 7958 8359

Fax: +44 (0)20 7958 8317

Email: [matthew.burton@lshtm.ac.uk](mailto:matthew.burton@lshtm.ac.uk)

Signed: \_\_\_\_\_

*Co-supervisor:*

Dr Helen Weiss MSc PhD

Reader (Epidemiology and Biostatistics)

Faculty of Epidemiology and Population Health

London School of Hygiene and Tropical Medicine

Keppel Street

London WC1E 7HT

Tel: +44 (0) 20-7612-7872

Fax: +44(0) 20-7958-8325

Email: [Helen.weiss@lshtm.ac.uk](mailto:Helen.weiss@lshtm.ac.uk)

Signed:

*Co-investigators:*

Dr. Joy Kabiru MBChB, M.Med  
Consultant Ophthalmologist  
PCEA Kikuyu Hospital Eye Unit  
[joykabiru@yahoo.com](mailto:joykabiru@yahoo.com)

Dr. T. Onyuma MBChB, M.Med  
Consultant Pathologist  
MP Shah Hospital  
[tonyuma@mpshahhosp.org](mailto:tonyuma@mpshahhosp.org)

Prof. Walter Jaoko MBChB, MTMed, PhD  
Kenya Aids Vaccine Initiative (KAVI)  
University of Nairobi  
[wjaoko@kaviuon.org](mailto:wjaoko@kaviuon.org)

Dr. Mandeep Sagoo MB PhD FRCS  
Senior Lecturer and Consultant Ophthalmologist (Ocular Oncology)  
UCL Institute of Ophthalmology & Moorfields Eye Hospital  
London  
[sagoo@doctors.org.uk](mailto:sagoo@doctors.org.uk)

Dr. Olando MBChB, M.Med  
Consultant Ophthalmologist  
Sabatia Eye Unit

Dr. Hilary Rono MBChB, M.Med  
Consultant Ophthalmologist  
Kitale District Hospital

Dr. Ochieng MBChB, M.Med  
Consultant Ophthalmologist  
Homa Bay District Hospital

### **3. Collaborating institutions**

- i) London School of Hygiene & Tropical Medicine
- ii) University of Nairobi
- iii) Kenyatta National Hospital
- iv) PCEA Kikuyu Hospital Eye Unit
- v) UCL Institute of Ophthalmology & UCL Cancer Institute
- vi) Sabatia Eye Unit
- vii) Kitale District Hospital
- viii) Homa Bay District Hospital

### **4. Funding agency**

Funding has been provided by the British Council for Prevention of Blindness (BCPB) to Dr Stephen Gichuhi to conduct this project as a PhD fellowship, registered at the London School of Hygiene & Tropical Medicine (LSHTM).

### **5. Summary**

In East Africa, ocular surface squamous neoplasia (OSSN) is a relatively common aggressive disease affecting younger adults. Treatment usually involves surgical excision, however, recurrent disease is quite common (up to 30-66% by 30 months afterwards) and there have been no randomised controlled trials to investigate how to reduce this. For a long time topical 5-fluorouracil (5FU) has been widely used as adjuvant therapy following surgical excision, with many case reports and series in the literature. However, it has not been formally tested in a randomised controlled trial and so we currently do not know if it is effective in preventing recurrent tumours, particularly in the context where more expensive adjuvants or surgical equipment are not readily available.

We propose to conduct a randomised controlled trial to determine whether OSSN recurrence can be reduced by adjuvant topical 5FU chemotherapy following excision. Following surgical excision of histopathologically confirmed OSSN, participants will be randomised to either 5FU eyedrops, or placebo drops to be taken four times a day for 1 month. Patients will be followed for one year to assess the effect. The primary outcome measure is histopathologically confirmed recurrent OSSN.

### **6. Background**

Ocular surface squamous neoplasia (OSSN) is a spectrum of disease that ranges from non-invasive intra-epithelial dysplasia of the conjunctiva and cornea (CCIN), through to

invasive squamous cell carcinoma (SCC).<sup>1</sup> In recent decades OSSN has undergone an epidemiological shift. In more temperate countries, it remains a rare, slow growing tumour of elderly males.<sup>2</sup> In contrast, in tropical countries, particularly in Eastern Africa, it is now more common, more aggressive, affects younger people and slightly more women than men.<sup>3-6</sup> Patients often present late with advanced tumours.<sup>5</sup> It seems likely that much of this increased burden of disease is attributable to the HIV/AIDS epidemic.<sup>7</sup> Even though OSSN is not a target condition within Vision 2020, a WHO initiative to prevent avoidable blindness by the year 2020, it frequently leads to a poor quality of life, visual disability and death. In September 2010 the “International Agency for Prevention of Blindness (IAPB)/Vision2020 Workshop on Research for Global Blindness Prevention” identified specific research priorities.<sup>8</sup> It was recognised that for Africa there was a need for research on HIV-related conditions to better define the epidemiology and determine context-specific management approaches.

Reliable prevalence and incidence estimates of the numbers of individuals affected have been difficult to ascertain and vary considerably. At one extreme, in one study from Kenya based in HIV testing clinics, 7.8% of HIV-infected adults were found to have conjunctival tumours which were found to be OSSN on histopathology.<sup>5</sup> The Kenyan national HIV prevalence is 7.4%% (2.22 million) so it was suggested that over 170,000 Kenyans might have some degree of OSSN.<sup>9</sup> In contrast, a relatively low annual incidence estimate of 2.2/100,000 has been suggested in a study from Tanzania, based on the number of cases being operated in eye units.<sup>6</sup> From the clinical perspective OSSN represents a significant component of the ophthalmic “work-load” in East Africa and is associated with a high level of morbidity for the patient, as exenteration is often needed for those with late presentation or recurrent disease. However, OSSN receives little or no attention from either ophthalmic or HIV care programs.

The epidemiology, aetiology and pathophysiology of OSSN in East Africa is not well understood. There is an association with HIV; however, a significant proportion (about 30%) of people with OSSN are not infected with HIV, suggesting that other factors also contribute to the excess burden of disease in this region.<sup>7, 10-12</sup> The interaction between CD4 T-lymphocyte levels in HIV+ individuals and OSSN has not been described. The relationship between human papilloma virus (HPV) and OSSN remains unclear; some studies have reported associations and others have not.<sup>13-18</sup> This is probably because of variations in methodology and the specific HPV types that have been looked for. There are 120 genotypes of HPV.<sup>19</sup> Some are cutaneous and others mucosal. Cutaneous types are more frequently found in OSSN than the mucosal types.<sup>16, 20</sup> Generally only a

very limited sub-set of the many different HPV types have been investigated. It seems plausible that ultraviolet (UV) solar radiation also plays a role; the risk is higher with increasing time spent in daylight and a specific mutation associated with UV radiation has been found more frequently in OSSN tissue.<sup>21, 22</sup> The importance of vitamin A in maintaining the health of the ocular surface is well known. About 40-50% of HIV-infected adults have low levels of vitamin A (serum retinol <30 µg/dL or <1.05 µmol/L).<sup>23, 24</sup> The potential role of vitamin A deficiency in OSSN has not previously been investigated.

A Cochrane systematic review found no randomised controlled clinical trials of any interventions for the treatment of OSSN.<sup>25</sup> Most tumours are surgically excised. Very large tumours that have spread to the orbit are usually managed by exenteration (removal of the eye and orbital content). However, results in terms of OSSN recurrence rates are very variable. Although one series by a very experienced surgeon reported low recurrence rates,<sup>12</sup> under routine operational conditions in Africa and elsewhere the recurrence rates are much higher: reports generally range between 30% and 66% 30 months afterwards.<sup>5, 26, 27</sup> Recurrences start as early as one month later within the first year after excision.<sup>26, 28, 29</sup>

To try to reduce recurrence rates various adjuvant chemotherapy treatments are sometimes used: mitomycin-C (MMC), 5-fluorouracil (5FU) or interferon (IFN) α-2B.<sup>27, 28, 30, 31</sup> 5FU is less toxic and less costly than MMC while IFN is the most expensive and difficult to obtain.<sup>31</sup> 5FU is one of the most commonly used antimetabolites in ophthalmic practice, used for its anti-scarring properties in a wide variety of surgical operations such as trabeculectomy, pterygium surgery and lacrimal surgery.<sup>32</sup> 5FU is a pyrimidine analogue first synthesized in 1957 by Duschinsky et al.<sup>33</sup> It is a pro-drug with two active metabolites that have cytotoxic effects.<sup>34</sup> One of them, 5-fluoro-2'-deoxyuridine-5'-monophosphate (FdUMP), binds to the enzyme thymidylate synthetase which is critical for the synthesis of thymidylate, resulting in the inhibition of DNA synthesis. The other, 5-urouridine-5'-triphosphate (FUTP) interferes with RNA synthesis.<sup>35</sup> The primary antineoplastic mechanism of action of 5FU is thought to be through FdUMP. This mechanism is cell-cycle specific, affecting only those cells in the S (synthesis) stage.<sup>32, 35</sup> Various reports show that therapy with topical 5FU has been used for a long time in different parts of the world but the effectiveness of this practice has not been formally tested in a randomised trial.<sup>28, 31, 36-39</sup> The first report was in 1995.<sup>36</sup> In one study, topical 1% 5FU was used alone, without concurrent surgery or radiotherapy.<sup>37</sup> Case-series study of the long-term efficacy and safety of topical 5FU 1% given alone or as adjuvant therapy following surgical excision reported recurrence rates of <10% and

no evidence of long term toxicity or morbidity except rarely epiphora (excessive watering of the eyes) thought to be due to scarring of the tear drainage passage.<sup>39, 40</sup> Adjuvant therapy is however rarely used in sub-Saharan Africa, although 5FU is available and affordable. Randomised controlled trials are needed to identify the optimal treatment for this condition to minimise recurrence rates, visual loss and death from conjunctival squamous cell carcinoma in the East African setting.

## **7. Rationale**

Ocular surface squamous neoplasia is a common and often difficult to treat disease in ophthalmic practice in East Africa. Recurrent tumours often complicate the treatment. There is a need for interventions to reduce recurrence rates. Post-operative 5FU drops have been used for many years to treat patients following tumour excision, although there is no trial data on this. There is a need for a randomised controlled trial (RCT) to determine whether this is effective and should become standard practice. If this trial has a positive outcome, 5FU eye drops are cheap and easily available. They do not have stringent storage conditions and have low risk of contamination. Patients can also apply it for themselves. Provision of this intervention on a public health scale is therefore feasible.

## **8. Research question**

In adults with primary OSSN, does adjuvant chemotherapy with topical 1% 5FU applied four times daily for one month reduce the recurrence rate over a period of one year than surgical excision alone?

## **9. Objectives**

### **a) Broad Objective**

To determine whether the recurrence of OSSN can be reduced through the use of adjuvant topical chemotherapy.

### **b) Primary Objective**

To compare the one-year recurrence rate of OSSN with or without adjuvant topical 5FU 1% eye drops applied 4 times daily for one month after surgical excision of OSSN tumours which involve less than 2 quadrants of the conjunctiva.

### **c) Secondary objectives**



- i) To compare the mean time-to-recurrence of OSSN with or without adjuvant topical 5FU 1% eye drops applied 4 times daily for one month after surgical excision of OSSN tumours which involve less than 2 quadrants of the conjunctiva.
- ii) To determine the co-factors of recurrence of OSSN with or without adjuvant topical 5FU 1% eye drops applied 4 times daily for one month after surgical excision of OSSN tumours which involve less than 2 quadrants of the conjunctiva.
- iii) To determine the adverse effects of adjuvant topical 5FU 1% eye drops applied four times daily for one month after surgical excision of OSSN tumours.

## 10. Study design and Methodology

### **Overview:**

This trial is part of an integrated set of studies that will investigate the epidemiology, aetiology, pathophysiology, diagnosis and treatment of OSSN. Figure 1 below illustrates how patients will flow through the various components of the trial. A case-control study component which will be examining the epidemiology, aetiology, pathophysiology and diagnosis is being submitted in for review in a companion application to this one.

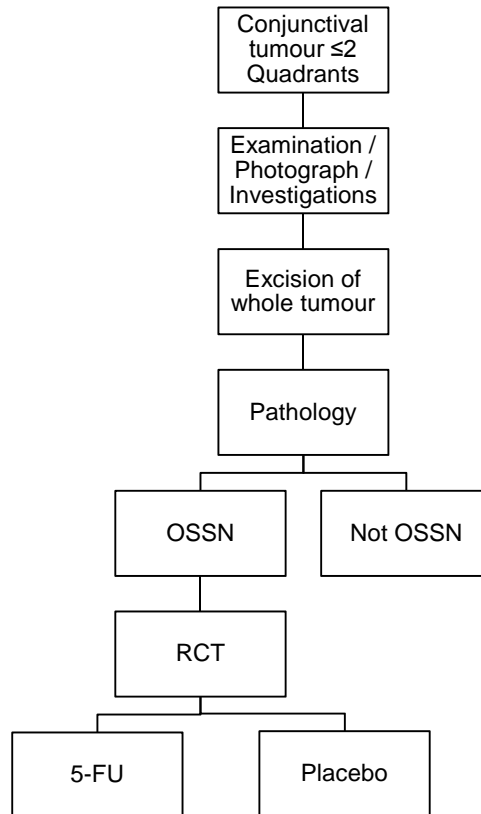
### a) Study design

A double-masked randomised placebo-controlled trial of adjuvant topical 5-fluorouracil (5FU) treatment following surgical excision of OSSN will be conducted. Tumours involving two or less quadrants of conjunctiva that is suspected to be OSSN will be surgically excised under local anaesthetic. All the surgeons involved in this study would undergo standardisation training to ensure uniform good quality surgery is performed using the “no touch” technique.<sup>41</sup> An experienced pathologist will examine the excision specimen for evidence of OSSN within one week of excision. Patients will be reviewed in the clinic four weeks after the surgery to confirm that the excision site has healed. Those with a histopathology report of OSSN will be invited to participate in the RCT. Those who give consent will be enrolled and randomised to one of two treatment arms; 1% 5FU or placebo eye drops applied four times daily for four weeks starting after the excision site has healed. The participants will be followed up for one year (at 1, 3, 6, and 12 months after intervention allocation).

The primary outcome will be the recurrence of the tumour at any time during the first year of follow up defined as histological confirmation of OSSN from a re-excision biopsy. The mean time-to-recurrence; co-factors of recurrence; and rate of “clinical recurrence” (defined in secondary objective iii) of OSSN will also be investigated in a secondary

analysis of the primary outcome. The secondary outcome will be adverse effects of 5FU eye drops.

Figure 1. Randomised controlled trial.



b) Study population

This study will be conducted in 5 eye centres namely;

- i) Kenyatta National Hospital eye clinic
- ii) PCEA Kikuyu Eye Unit in Kenya
- iii) Sabatia Eye Unit
- iv) Kitale District Hospital
- v) Homa Bay District Hospital

These are busy eye units with a weekly operating list in the minor theatre where conjunctival tumours are excised or incision biopsies taken. The hospitals have access to Voluntary Counselling and Testing (VCT) facilities and Comprehensive Care Centres (CCC) for HIV that can offer adequate care and support for study participants who are HIV infected.

Inclusion criteria:

1. Histologically proven ocular surface squamous neoplasia (OSSN)
2. Healed excision site.
3. At least 18 years of age.

Exclusion criteria:

1. Prior treatment with topical antimetabolite drugs such as 5FU, Mitomycin C (MMC) to the same eye or systemic cytotoxic drugs.
2. Patients that may need more radical surgery than a simple excision eg. intraocular extension or features suggestive of metastasis such as fornix or regional lymph node involvement.
3. Pregnant or breastfeeding mothers.

c) Intervention arms

Surgical excision under infiltration local anaesthesia will be performed in the standard technique of dissecting down to bare sclera. The widest diameter of the tumour will be measured in millimetres with a pair of callipers. A 4mm-wide margin beyond the visible edge of the tumour will be used as the incision line. The “no-touch” excision technique described by Shields et al will be used.<sup>39</sup> The excised tissue specimen will be immediately fixed with 10% neutral buffered formalin in a specimen bottle labelled with the study number and sent to the histopathology laboratory with a structured request form similarly labelled. An additional elliptical piece of conjunctiva about 2x2mm wide next to the tumour will be excised and sent fresh for SLRP and HPV studies. The defect left at the surgical bed will be closed by mobilizing a conjunctival flap or tenon’s capsule flap from the adjoining area or placing a conjunctival autograft. After excision, all participants will be treated with oral analgesics and combined Gentamicin 0.3% and prednisolone acetate 1% eye-drops four times daily until wound healing is complete.

Individuals will be randomly allocated to one of two arms in the trial: (1) topical 5-fluorouracil 1% drops; (2) topical placebo drops. The interventions will be packaged into plastic eye drop bottles. Patients will be asked to self-administer the drops four times a day to the affected eye for four weeks.

- a. Topical 5-fluorouracil 1% will be reconstituted from locally available 5FU injection 250mg/5ml Fluracedyl (Pharmachemie Ltd) by a pharmaceutical manufacturer in Kenya (Ivee Aqua EPZ Ltd.) and diluted in Hydroxypropyl Methylcellulose 0.7% (Ivyomoicell® Ivee Aqua EPZ Ltd, to a concentration of 1%.

- b. The placebo will be the same diluent solution used to make up the 5FU drops, namely Hydroxypropyl Methylcellulose 0.7% (Ivyomoicell® Ivee Aqua EPZ Ltd.).

d) Randomisation

A random allocation sequence will be generated on computer by a statistician at the London School of Hygiene and Tropical Medicine (LSHTM) using STATA software (Stata Corporation, College Station, TX, USA). Random permuted blocks will be used. The block size will be randomly varied to prevent guessing the intervention assignment. Separate randomisation lists will be prepared for each surgeon. The lists will be used by one research staff member to label and allocate treatment bottles. The allocation sequence will be concealed from the other investigators as only this staff member and the statistician will handle the randomisation list.

e) Masking

The participants, the surgeon, the ophthalmologist performing the clinical examinations and the pathologist examining the recurrence specimens will be masked to the treatment arm allocation. The bottles of eye drops will appear similar and only identified by code numbers. The ID number on the bottle will not provide a clue as to whether it is 5FU or placebo. The pharmacy will not know the content of each bottle. The pharmaceutical manufacturer will have a code generated by the statistician to use in making the eye drops. Unmasking of an individual's treatment will be performed on recommendation of the data safety and monitoring board (DSMB).

f) Follow up

After the wound has healed participants will be allocated to the intervention arm then followed-up at 1 month, 3 months, 6 months and 12 months after the date of intervention allocation. They will be carefully examined for signs of recurrent tumours and photographed on each occasion.

g) Primary end point and analyses

*Primary analysis of primary endpoint:*

The primary outcome will be the clinical recurrence of the tumour at any time during the first year of follow-up, and where available confirmed by histology. During follow up, if the outcome assessor notices a possible recurrence, it will be re-excised and sent for histopathology. We will compare the proportion of recurrences at one year in the two intervention arms. Intention-to-treat analysis will be used. The measure of effect will be the

odds ratio with 95% confidence intervals. Kaplan-Meier analysis will be used to plot the survival curves for both arms up to the final visit at one year.

#### *Secondary analysis of primary endpoint*

##### I. mean time-to-recurrence of OSSN

The time-to-recurrence will be the number of person-months between surgery and the date the recurrence was first noted clinically. Person-months will be calculated for each arm and the two compared. Cox regression will be used to assess the impact of the intervention on time-to-recurrence. The hazard ratio will be estimated with Cox regression, adjusting for substantial baseline imbalances if appropriate.

##### II. Co-factors of recurrence

Factors that may influence the primary outcome will be analysed. This will include HIV infection, CD4 count, age and sex of participant, use of highly active anti-retroviral therapy (HAART), HPV infection and serum vitamin A levels. Effect modification by the surgeon, size of initial OSSN tumour, and rate of growth will be analysed. The association between any of these co-factors and the primary outcome will be reported using odds ratios and their 95% confidence intervals.

#### h) Secondary outcome

The main secondary outcome will be to assess the safety of using topical 5-fluorouracil 1% four times daily for one month. We would monitor adverse events. The most commonly reported adverse effect is epiphora but we would monitor all other events as shown below.

DEFINITIONS - The following definitions shall be adopted for safety reporting:

Adverse Event (AE): any untoward medical occurrence in a clinical trial participant administered a medicinal product and which does not necessarily have a causal relationship with this treatment. *An AE can therefore be any unfavourable and unintended sign (including an abnormal laboratory finding), symptom, or disease temporally associated with the use of an investigational medicinal product (IMP), whether or not considered related to the IMP.*

Adverse Reaction (AR): all untoward and unintended responses to an IMP related to any dose administered. *All AEs judged by either the reporting investigator or the sponsor as having reasonable causal relationship to a medicinal product qualify as adverse reactions. The expression reasonable causal relationship means to convey in general that there is evidence or argument to suggest a causal relationship.*

Unexpected Adverse Reaction: an AR, the nature or severity of which is not consistent with the applicable product information (eg investigator's brochure for an unapproved investigational product or summary of product characteristics (SmPC) for an authorised product). *When the outcome of the adverse reaction is not consistent with the applicable product information this adverse reaction shall be considered as unexpected. Side effects documented in the SmPC which occur in a more severe form than anticipated are also considered to be unexpected.*

Serious Adverse Event (SAE) or Serious Adverse Reaction: any untoward medical occurrence or effect that at any dose

- Results in death
- Is life-threatening – *refers to an event in which the subject was at risk of death at the time of the event; it does not refer to an event which hypothetically might have caused death if it were more severe*
- Requires hospitalisation, or prolongation of existing inpatients' hospitalisation
- Results in persistent or significant disability or incapacity
- Is a congenital anomaly or birth defect

Medical judgement shall be exercised in deciding whether an AE/AR is serious in other situations. Important AE/ARs that are not immediately life-threatening or do not result in death or hospitalisation but may jeopardise the subject or may require intervention to prevent one of the other outcomes listed in the definition above, shall also be considered serious.

Suspected Unexpected Serious Adverse Reaction (SUSAR): any suspected adverse reaction related to an IMP that is both unexpected and serious.

CAUSALITY - Most adverse events and adverse drug reactions that occur in this study, whether they are serious or not, will be expected treatment-related toxicities due to the drugs used in this study. The assignment of the causality will be made by the investigator responsible for the care of the participant using the definitions in the table below.

If any doubt about the causality exists the local investigator shall inform the study site coordinator who will notify the Chief Investigators. The pharmaceutical companies and/or other clinicians may be asked to advise in some cases.

In the case of discrepant views on causality between the investigator and others, all parties will discuss the case. In the event that no agreement is made, the Kenya Pharmacy and Poisons Board and the Kenyatta National Hospital Ethics Review Committee will be informed of both points of view.

Table 1. Assignment of causality of adverse events and adverse drug reactions.

<b>Relationship</b>	<b>Description</b>
<b>Unrelated</b>	There is no evidence of any causal relationship
<b>Unlikely</b>	There is little evidence to suggest there is a causal relationship (e.g. the event did not occur within a reasonable time after administration of the trial medication). There is another reasonable explanation for the event (e.g. the participant's clinical condition, other concomitant treatment).
<b>Possible</b>	There is some evidence to suggest a causal relationship (e.g. because the event occurs within a reasonable time after administration of the trial medication). However, the influence of other factors may have contributed to the event (e.g. the participant's clinical condition, other concomitant treatments).
<b>Probable</b>	There is evidence to suggest a causal relationship and the influence of other factors is unlikely.
<b>Definitely</b>	There is clear evidence to suggest a causal relationship and other possible contributing factors can be ruled out.
<b>Not assessable</b>	There is insufficient or incomplete evidence to make a clinical judgement of the causal relationship.

REPORTING PROCEDURES - All adverse events shall be reported. Depending on the nature of the event the reporting procedures below shall be followed. Any questions concerning adverse event reporting shall be directed to the study coordinator in the first instance. A flowchart is given in appendix 4 to aid in the reporting procedures.

i) Non serious Adverse Reactions (ARs)/Adverse Events (AEs)

All such events, whether expected or not, shall be recorded in the toxicity section of the relevant case report form and sent to the study coordinator within one month of the form being due.

ii) Serious Adverse Reactions (SARs)/Serious Adverse Events (SAEs)

Fatal or life threatening Serious Adverse Events (SAEs), Serious Adverse Reactions (SARs) and Suspected Unexpected Serious Adverse Reactions (SUSARs) shall be reported on the day that the local site is aware of the event. The SAE form asks for nature of event, date of onset, severity, corrective therapies given, outcome and causality (i.e. unrelated, unlikely, possible, probably, definitely). The responsible investigator shall sign

the causality of the event. Additional information shall be sent within 5 days if the reaction has not resolved at the time of reporting.

iii) SAEs

An SAE form shall be completed and sent to the study coordinator for all SAEs within 24 hours. However, relapse and death due to ocular surface squamous neoplasia and hospitalisations for elective treatment of a pre-existing condition will not need reporting as SAEs.

iv) SUSARs

In the case of serious, unexpected and related adverse events, the staff at the site shall:

Complete the SAE case report form & send it immediately (within 24 hours, preferably by email), signed and dated to the study coordinator together with relevant treatment forms and anonymised copies of all relevant investigations.

Or

Contact the study coordinator by phone and then send the completed SAE form by email to the study coordinator within the following 24 hours as above.

The study coordinator will notify the Kenya Pharmacy and Poisons Board and Kenyatta National Hospital Ethics Review Committee of all SUSARs occurring during the study according to the following timelines; fatal and life-threatening within 7 days of notification and non-life threatening within 15 days. All investigators will be informed of all SUSARs occurring throughout the study.

Investigators shall report any SUSARs and /or SAEs as required by and Kenyatta National Hospital Ethics Review Committee.

**Contact details for reporting SAEs and SUSARs**

Please send SAE forms to: Dr. Stephen Gichuhi on [sgichuhi@uonbi.ac.ke](mailto:sgichuhi@uonbi.ac.ke)

**Tel: 0722873059 (Mon to Fri 09.00 – 17.00)**



i) Sample size

A power-based sample size calculation will be used. We anticipate a 20% OSSN recurrence rate by one year after surgery in the placebo arm. From a programmatic perspective in the East African setting we consider that adjuvant 5FU would be a worthwhile intervention if it halved the recurrence rate to 10%. Using Stata IC 11 to calculate sample size, a sample of 438 cases of OSSN (219 in each arm) would have 80% power and 95% confidence to detect a relative reduction in the risk of recurrence of 50% from 20% to 10% in the 5FU arm at one year. Including 15% extra for loss to follow-up would make a total of 504, 252 in each arm.

j) Recruitment, consenting and retention procedures

Together the study centres surgically treat about 7 new cases of OSSN each week on designated operating lists (about 360/year). Therefore we anticipate that we will be able to comfortably recruit the necessary sample size within 15 months.

Participants for the trial will be recruited from a concurrent case-control study that will be going on at the two centres. The project will be publicised using flyers and announcements at various forums that ophthalmologists and ophthalmic clinical officers meet and also eyecare institutions to encourage referrals. The websites of eye care professional associations and also the East Africa Journal of Ophthalmology (EAJO) will also carry the announcement.

During the case-control study participants with conjunctival tumours will have clinical examinations, digital photographs, surgical excision and histology done. After excision, they will be treated with oral analgesics and combined Gentamicin 0.3% and Prednisolone acetate 1% eye-drops four times daily until wound healing is complete. Usually this takes 3-4 weeks. In the interim period, histology reports will be ready. The reports that indicate OSSN will be flagged and the patients noted for potential recruitment into the trial. Their medical records will be checked to screen for eligibility. During the review visit, the clinician will discuss treatment options and refer the patient to a research nurse who will give more details about the study. The informed consent process will be conducted by an ophthalmic research nurse trained in the procedures involved in the study. The study information sheet will be given to them, read to them in an appropriate language and discussed by the research nurse. Any questions will be answered. The study information sheet will include questions to test understanding. For illiterate patients, the study will be explained in an appropriate language with illustrations. Enrolment into the study will be dependent on witnessed informed consent,

which will be recorded on a consent form marked by the patient (signature or thumb print). Those who give consent will be enrolled into the study and given a study number. A record of potentially eligible people who decline to participate will be kept for reporting purposes.

To aid participant retention in the study locator information and telephone contacts will be collected and updated on every visit. Contact information of a next of kin or other person who may be contacted in case the participant is unreachable will be requested. Participants will provide a sketch map of their area of residence. A research nurse will remind participants about their appointments one week before via telephone. If the participant does not make a clinic visit within a week of their expected date of appointment they will be rang again and a convenient date set up within the next week. If they are unreachable on phone after a reasonable number of attempts, the next of kin will be contacted. If the latter is unavailable after a reasonable number of attempts, a home visit will be made by the research nurse

k) Data collection procedures

Initial data will have been collected during the case-control study. A structured case record form (CRF) will be used in an interview to collect socio-demographic data and an occupational, medical and care-seeking history. The following will be done during the case-control phase of the study.

**Examination:** The eyes will be examined using a stereoscopic biomicroscopic slit lamp. The clinical features of the tumour will be noted (in particular, leukoplakia, redness, whether the surface is gelatinous, fornix involvement, feeder vessels and regional lymph node involvement). The size of the tumour will be estimated by measuring its widest diameter and the maximum diameter perpendicular to the first one using the slit lamp scale. Intraocular extension will be assessed using ocular ultrasound. Fornix involvement will be assessed clinically and with orbital ultrasound. A line drawing of the tumour will be made in the case record form (CRF). Digital photographs of the tumour will be taken in primary gaze and with the tumour centred. The area of the tumour will be measured in square millimetres from the photographs using Image J software (NIH, Bethesda, USA).

**Histopathology:** Since the PCEA Kikuyu Eye Unit laboratory has no facility for histology they have an arrangement where tissue specimens are usually transferred to the Department of Pathology MP Shah hospital where one of the co-investigators

reports them (FSR). The tissue will be embedded in paraffin and cut into sections for haematoxylin and eosin staining and the slide examined by a histopathologist. The laboratory diagnosis will be recorded on the request form and sent to the clinic record. A participant will be considered to have OSSN if histology shows any stage of dysplasia or invasive squamous cell carcinoma.

After the participant is enrolled in the trial, the clinical information from the case-control study will be maintained. The following will be done at the first post operative and all follow up visits.

**Examination:** The eyes will be examined using a stereoscopic biomicroscopic slit lamp; initially to document that the excision site is healed and subsequently to check for recurrent tumours. The eye will be photographed on each visit as outlined earlier. Presence of epiphora will be assessed by taking history and doing the fluorescein dye disappearance test in both eyes.

If a recurrence is noted, the procedures above for surgery and histopathology will be followed.

l) Management of other health conditions

Patients who are HIV-infected will be referred to the Comprehensive Care Center (CCC) in the hospital for appropriate care. Adverse effects associated with the study drugs will be appropriately treated.

m) Quality assurance

The LSHTM will be the sponsor of this trial. We will hire staff with experience in clinical trials. All study staff will be trained and a pilot phase conducted. Data management quality procedures involving checking case record forms (CRFs) before and after filling and other subsequent procedures are described in the data management section further below.

A data safety and monitoring board (DSMB) will be constituted. The DSMB in consultation with the Trial Steering Committee will determine if an interim analysis is required to monitor if a significant difference in recurrence rates is reached at an earlier than anticipated stage or if additional recruitment is required. The DSMB will monitor reports of any adverse events, such as moderate to severe ocular surface or skin inflammation.

The laboratories to be used have been certified for good laboratory clinical practice (GCLP). The laboratories participate in External Quality Assurance (EQA) of their processes. An extra histology slide will be prepared from each tissue specimen to be examined at the Institute of Ophthalmology, part of University College London (UCL) for peer review.

The guidelines of the Kenyatta National Hospital-University of Nairobi Ethics Review Committee (KNH/UON/ERC) and LSHTM on trial monitoring and reporting will be followed. Protocol deviations will also be reported to the DSMB.

After approval by the KNH/UON/ERC this protocol will be submitted to the Kenya Pharmacy and Poisons Board for registration of the 5FU eye drops to ensure they conform to good manufacturing practices (GMP).

A Material Transfer Agreement (MTA) between the laboratories involved in the project will be prepared and approved by the Kenya Ministry of Medical Services Department of standards and regulatory services prior to any sample transfer.

n) Training procedures

Protocol training will be provided for all staff who will work on the project. In addition they will be given training updates in good clinical practice (GCP) and research ethics. They will be required to obtain GCP certification and update them regularly. The surgeons will undergo training to standardize the excision procedure.

## **11. Ethical considerations**

The principles of GCP and in particular the ethical principles of the Declaration of Helsinki will be followed in this trial. Only participants who freely give written consent will be enrolled into the study. The rights, safety and well being of participants will be assured. The protocol will be submitted for ethics review at KNH/UON/ERC & LSHTM. The investigators and research staff will have the appropriate education, training and experience. Accurate data handling, protection and confidentiality will be ensured. Quality assurance systems will be instituted as described in section (m) above. The sponsor will monitor trial activities and provide insurance.

## 12. Data management

Data clerks supervised by a data manager will check the case record forms (CRFs) to ensure full completion. Where data is missing, the CRF will be flagged on the database and clinic register for supplementary interviews to be conducted during the next follow up visit. The key unique identifier variable will be the study number. This will appear on all pages of the CRF, specimen containers and laboratory request forms. When reports are received from the laboratory, the results will be entered onto the CRF. The serial number of the source documents (laboratory reports, medical records, digital photographs) will be noted in the CRF.

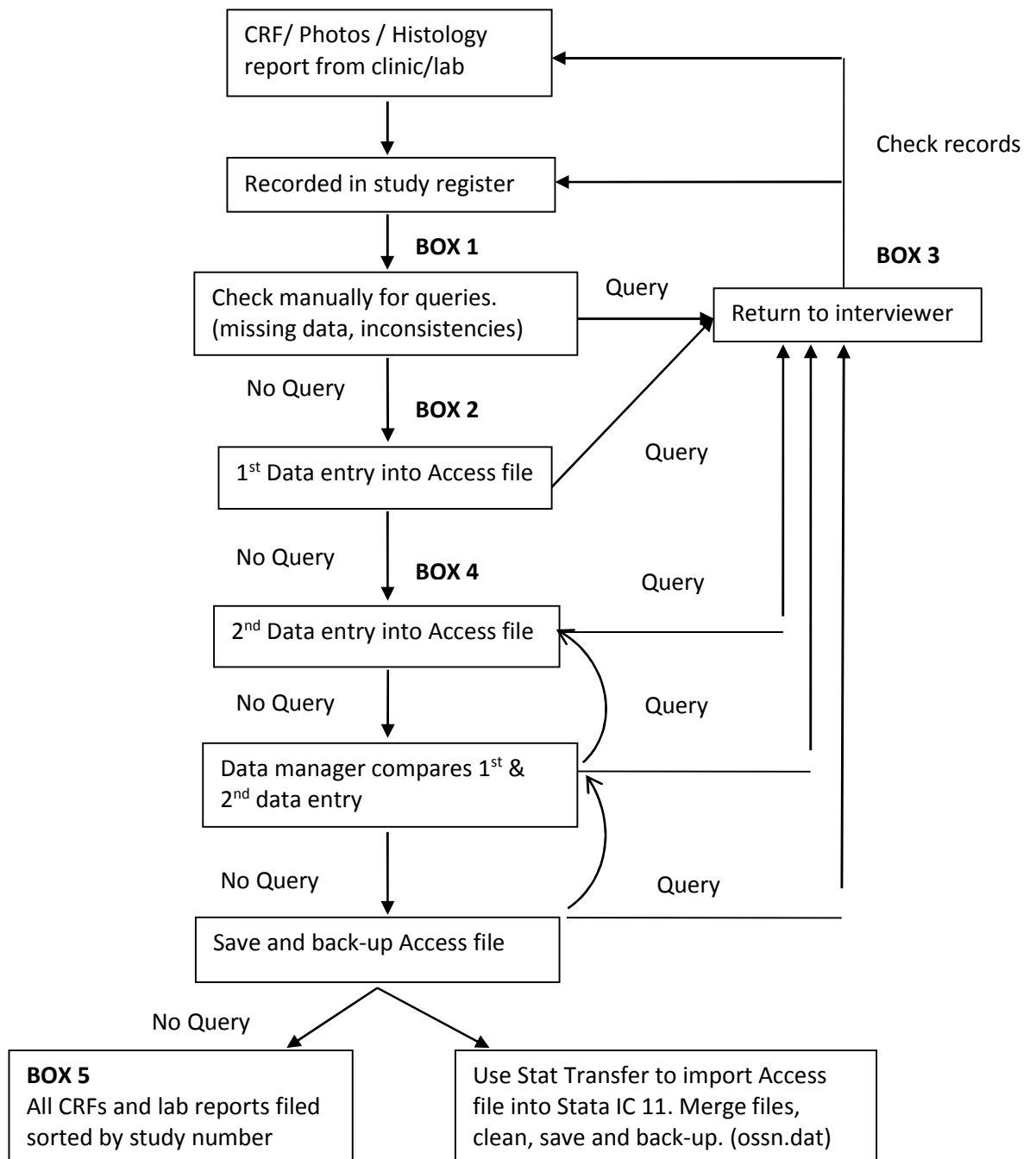
Data will be transferred from CRF to a MS Access database with an interface that appears similar to the CRF to minimize errors in data entry. The database will be designed with must-enter variables, logic checks, legal values and specified range checks built into the program to enable interactive checking during data entry. Interactive checking allows the data clerk to be prompted on the screen if an erroneous value is entered. After data entry, batch checking will be done. Batch checking will also apply the standard checks (range, legal values etc) as well as consistency checks. Verification of data entry will be done using the double entry method. This will involve data being entered twice into two separate files by two different data clerks. The two files will then be compared (using EpiData) and any discrepancies checked against the CRFs and/or source documents. The clean dataset will then be transferred from MS Access to Stata version IC 11 software (Stata Corporation, College Station, TX, USA) for analysis. In the end all CRFs and laboratory reports will be filed and boxed (box 5 Figure 2) in order of study number.

All CRFs received from the interviewers and clinicians will be recorded in a register and put in a box (Box 1 in figure 2). They will be manually checked for errors and if there is no query they will be put in a box labelled 2 for the first entry. After the first entry, the CRFs will be put in a box labelled 4 and taken for the second entry. The principal investigator will compare the first and second entry. Any CRF with a query will be marked and put in a special query box (Box 3 in Fig. 2).

On site, after the photographs are taken, the picture will be reviewed for clarity. Unclear pictures will be repeated. The picture serial number from the camera will be noted on the CRF. Pictures will be downloaded in computer in which photo databank management software is installed and backed up at the end of each day. Similarly MS

Access and Stata databases will be backed up daily on compact discs. Antivirus scans will be run daily on the computers.

Figure 2. Flow chart for data handling



### 13. Study limitations and how to minimize them

Delayed recruitment of the required sample size and loss to follow up during the trial may be a challenge. Measures to facilitate recruitment and retention are outlined in section (j) above. In addition, a 15% loss to follow up contingency has been built into the sample size calculation (section i).

### 14. Timeline

Research fellowship to start from Q4 2011 and run for three years.

Table 2. Project timeline

Activity	2011				2012				2013				2014		
	Q1	Q2	Q3	Q4	Q1	Q2	Q3	Q4	Q1	Q2	Q3	Q4	Q1	Q2	Q3
Scholarship result	■														
Finalize full protocol		■	■												
Ethics committee submission			■												
Write SOPs				■											
Equipment procurement				■											
Staff recruitment					■										
Protocol training					■										
Pilot phase					■										
Modify SOPs as needed						■									
Participant Recruitment Phase						■	■	■	■	■					
Follow-up Phase						■	■	■	■	■	■	■	■		
PhD Upgrade							■								
Data analysis													■	■	■
Write up													■	■	■

## 15. References

1. Lee GA, Hirst LW. Ocular surface squamous neoplasia. *Survey of ophthalmology*. 1995; 39(6): 429-50.
2. Lee GA, Hirst LW. Retrospective study of ocular surface squamous neoplasia. *Australian and New Zealand journal of ophthalmology*. 1997; 25(4): 269-76.
3. Poole TR. Conjunctival squamous cell carcinoma in Tanzania. *The British journal of ophthalmology*. 1999; 83(2): 177-9.
4. Pola EC, Masanganise R, Rusakaniko S. The trend of ocular surface squamous neoplasia among ocular surface tumour biopsies submitted for histology from Sekuru Kaguvi Eye Unit, Harare between 1996 and 2000. *The Central African journal of medicine*. 2003; 49(1-2): 1-4.
5. Chisi SK, Kollmann MK, Karimurio J. Conjunctival squamous cell carcinoma in patients with human immunodeficiency virus infection seen at two hospitals in Kenya. *East African medical journal*. 2006; 83(5): 267-70.
6. Furahini G, Lewallen S. Epidemiology and management of ocular surface squamous neoplasia in Tanzania. *Ophthalmic epidemiology*. 2010; 17(3): 171-6.
7. Ateenyi-Agaba C. Conjunctival squamous-cell carcinoma associated with HIV infection in Kampala, Uganda. *Lancet*. 1995; 345(8951): 695-6.
8. International Agency for Prevention of Blindness. Workshop Report: A VISION 2020 Workshop on Research for Global Blindness Prevention International Center for Eye Health (ICEH); 2010 September 27-29 2010
9. National AIDS and STI Control Programme. Kenya AIDS Indicator Survey 2007: Preliminary Report. : Ministry of Health, Kenya; 2008 Jul.
10. Mbulaiteye SM, Katabira ET, Wabinga H, Parkin DM, Virgo P, Ochai R, et al. Spectrum of cancers among HIV-infected persons in Africa: the Uganda AIDS-Cancer Registry Match Study. *International journal of cancer Journal international du cancer*. 2006; 118(4): 985-90.
11. Waddell KM, Lewallen S, Lucas SB, Ateenyi-Agaba C, Herrington CS, Liomba G. Carcinoma of the conjunctiva and HIV infection in Uganda and Malawi. *The British journal of ophthalmology*. 1996; 80(6): 503-8.
12. Waddell KM, Downing RG, Lucas SB, Newton R. Corneo-conjunctival carcinoma in Uganda. *Eye (Lond)*. 2006; 20(8): 893-9.
13. Yu JJ, Fu P, Pink JJ, Dawson D, Wasman J, Orem J, et al. HPV infection and EGFR activation/alteration in HIV-infected East African patients with conjunctival carcinoma. *PloS one*. 2010; 5(5): e10477.
14. Moubayed P, Mwakyoma H, Schneider DT. High Frequency of Human Papillomavirus 6/11, 16, and 18 Infections in Precancerous Lesions and Squamous



- Cell Carcinoma of the Conjunctiva in Subtropical Tanzania. *American Journal of Clinical Pathology*. 2004; 122(6): 938-43.
15. Guthoff R, Marx A, Stroebel P. No evidence for a pathogenic role of human papillomavirus infection in ocular surface squamous neoplasia in Germany. *Current eye research*. 2009; 34(8): 666-71.
  16. de Koning MN, Waddell K, Magyezi J, Purdie K, Proby C, Harwood C, et al. Genital and cutaneous human papillomavirus (HPV) types in relation to conjunctival squamous cell neoplasia: a case-control study in Uganda. *Infectious agents and cancer*. 2008; 3: 12.
  17. Sen S, Sharma A, Panda A. Immunohistochemical localization of human papilloma virus in conjunctival neoplasias: a retrospective study. *Indian journal of ophthalmology*. 2007; 55(5): 361-3.
  18. Simbiri KO, Murakami M, Feldman M, Steenhoff AP, Nkomazana O, Bisson G, et al. Multiple oncogenic viruses identified in Ocular surface squamous neoplasia in HIV-1 patients. *Infectious agents and cancer*. 2010; 5: 6.
  19. Bernard HU, Burk RD, Chen Z, van Doorslaer K, Hausen H, de Villiers EM. Classification of papillomaviruses (PVs) based on 189 PV types and proposal of taxonomic amendments. *Virology*. 2010; 401(1): 70-9.
  20. Ateenyi-Agaba C, Franceschi S, Wabwire-Mangen F, Arslan A, Othieno E, Binta-Kahwa J, et al. Human papillomavirus infection and squamous cell carcinoma of the conjunctiva. *British journal of cancer*. 2010; 102(2): 262-7.
  21. Waddell K, Kwehangana J, Johnston WT, Lucas S, Newton R. A case-control study of ocular surface squamous neoplasia (OSSN) in Uganda. *International journal of cancer Journal international du cancer*. 2010; 127(2): 427-32.
  22. Ateenyi-Agaba C, Dai M, Le Calvez F, Katongole-Mbidde E, Smet A, Tommasino M, et al. TP53 mutations in squamous-cell carcinomas of the conjunctiva: evidence for UV-induced mutagenesis. *Mutagenesis*. 2004; 19(5): 399-401.
  23. Visser ME, Maartens G, Kossew G, Hussey GD. Plasma vitamin A and zinc levels in HIV-infected adults in Cape Town, South Africa. *The British journal of nutrition*. 2003; 89(4): 475-82.
  24. Fufa H, Umata M, Taffesse S, Mokhtar N, Aguentaou H. Nutritional and immunological status and their associations among HIV-infected adults in Addis Ababa, Ethiopia. *Food and nutrition bulletin*. 2009; 30(3): 227-32.
  25. Gichuhi S, Irlam JJ. Interventions for squamous cell carcinoma of the conjunctiva in HIV-infected individuals. *Cochrane database of systematic reviews (Online)*. 2007; (2): CD005643.

26. Tabin G, Levin S, Snibson G, Loughnan M, Taylor H. Late recurrences and the necessity for long-term follow-up in corneal and conjunctival intraepithelial neoplasia. *Ophthalmology*. 1997; 104(3): 485-92.
27. Birkholz ES, Goins KM, Sutphin JE, Kitzmann AS, Wagoner MD. Treatment of ocular surface squamous cell intraepithelial neoplasia with and without mitomycin C. *Cornea*. 2011; 30(1): 37-41.
28. Yeatts RP, Engelbrecht NE, Curry CD, Ford JG, Walter KA. 5-Fluorouracil for the treatment of intraepithelial neoplasia of the conjunctiva and cornea. *Ophthalmology*. 2000; 107(12): 2190-5.
29. Peksayar G, Soy Turk MK, Demiryont M. Long-term results of cryotherapy on malignant epithelial tumors of the conjunctiva. *American journal of ophthalmology*. 1989; 107(4): 337-40.
30. Schechter BA, Koreishi AF, Karp CL, Feuer W. Long-term follow-up of conjunctival and corneal intraepithelial neoplasia treated with topical interferon alfa-2b. *Ophthalmology*. 2008; 115(8): 1291-6, 6 e1.
31. Sepulveda R, Pe'er J, Miden E, Seregard S, Dua HS, Singh AD. Topical chemotherapy for ocular surface squamous neoplasia: current status. *The British journal of ophthalmology*. 2010; 94(5): 532-5.
32. Abraham LM, Selva D, Casson R, Leibovitch I. The clinical applications of fluorouracil in ophthalmic practice. *Drugs*. 2007; 67(2): 237-55.
33. Duschinsky R, Plevin E, Heidelberger C. The synthesis of 5-fluoropyrimidines. *J Am Chem Soc* 1957; 79(16): 4559-60.
34. Malet-Martino M, Jolimaitre P, Martino R. The prodrugs of 5-fluorouracil. *Current medicinal chemistry Anti-cancer agents*. 2002; 2(2): 267-310.
35. Chu T, Sartorelli AC. Cancer chemotherapy. In: Katzung BG, editor. *Basic and clinical pharmacology*. 9 ed. Boston: McGraw Hill; 2004. p. 898-930.
36. Yeatts RP, Ford JG, Stanton CA, Reed JW. Topical 5-fluorouracil in treating epithelial neoplasia of the conjunctiva and cornea. *Ophthalmology*. 1995; 102(9): 1338-44.
37. Miden E. Treatment of conjunctival squamous cell carcinoma with topical 5-fluorouracil. *British Journal of Ophthalmology*. 2000; 84(3): 268-72.
38. Al-Barrag A, Al-Shaer M, Al-Matary N, Al-Hamdani M. 5-Fluorouracil for the treatment of intraepithelial neoplasia and squamous cell carcinoma of the conjunctiva, and cornea. *Clinical ophthalmology (Auckland, NZ)*. 2010; 4: 801-8.
39. Parrozzani R, Lazzarini D, Alemany-Rubio E, Urban F, Miden E. Topical 1% 5-fluorouracil in ocular surface squamous neoplasia: a long-term safety study. *The British journal of ophthalmology*. 2011; 95(3): 355-9.

40. Rudkin AK, Muecke JS. Adjuvant 5-fluorouracil in the treatment of localised ocular surface squamous neoplasia. *The British journal of ophthalmology*. 2011; 95(7): 947-50.
41. Shields CL, Shields JA. Tumors of the conjunctiva and cornea. *Survey of ophthalmology*. 2004; 49(1): 3-24.

## 16. Appendix

### Appendix 1 Statistical analysis plan

#### 1) **Participant flow**

A summary of the flow of participants through the different phases of the trial; enrolment, allocation, follow up and analysis will be made following the 2010 CONSORT flowchart (Schulz et al 2010 <http://www.consort-statement.org/consort-statement/overview0/>).

This will show the numbers eligible, consenting to take part, randomised, who received the intended treatment by arm. For each follow-up time-point the numbers seen, censored, defaulting, and permanently lost-to-follow-up will also be shown by arm. The numbers excluded at each stage and reasons for their exclusion will be noted such as reasons for declining to take part, not completing treatment, not having re-excision surgery, or discontinuing follow-up.

#### 2) **Summary of the baseline characteristics of the trial population**

A table will show a summary of baseline characteristics of the trial population such as total number involved further subdivided by study centre, age and sex.

#### 3) **Comparison of treatment groups with respect to baseline variables thought to be associated with main outcome**

The following characteristics of participants at baseline will be tabulated by arm:

- a) Socio-demographic factors: age, sex.
- b) Behavioural factors: smoking, outdoor occupation, wearing hats/caps.
- c) Clinical status: HIV status, HPV infection, CD4 count, serum vitamin A levels, tumour size and histological grade.

Categorical variables will be reported as numbers and proportions while continuous variables will be reported as mean and standard deviations if normally distributed or medians and interquartile range if their distribution is skewed. We will eyeball for differences between groups with respect to these variables but avoid any formal tests of the null hypothesis for no between-group differences since it will be assumed to hold if randomization was done properly. If one arm has appreciably more severe cases than the other – by chance – the primary analysis will be adjusted during multivariable regression.

#### 4) **Primary analysis of the primary outcome measure by intention to treat**

##### *Definition of primary end-point*

The primary outcome will be the clinical recurrence of the tumour at any time during the first year of follow-up, and where available confirmed by histology. Where histology is not available, photographs recurrent lesions will be reviewed by two consultant ophthalmologists experienced in OSSN in East Africa.

*Justification of primary outcome:*

The aim of adjuvant therapy is to reduce the rate of recurrence and therefore increase tumour-free survival after surgical excision.

- a) We will present an estimated effect of treatment on recurrence of the tumour at any time during the first year of follow up defined as clinical recurrence of OSSN OSSN from a re-excision biopsy. The numbers of events (recurrences in the first year) and risk of recurrence in both arms will be shown in a table. The odds of recurrence will be compared using the odds ratio (OR) and its 95% confidence interval adjusting for surgeon. The null hypothesis will be no treatment effect. The number needed to treat will also be estimated.
- b) We hope to achieve no less than 85% follow up and have adjusted sample size for this. If follow up is not as good as expected, sensitivity analysis will be conducted to examine the possible effect of losses to follow up to see if these may affect the treatment effect estimate.

**5) Primary analysis adjusted for baseline variables**

It is expected that the important baseline characteristics that are known to affect the risk of recurrence will be balanced between the two arms through randomisation. If the arms are found to be substantially imbalanced an appropriately adjusted logistic regression model will be used.

**6) Secondary analysis of the primary outcome****a) Effect of the intervention on time-to-first-recurrence.**

The time-to-first-recurrence variable is an estimate of the tumour-free survival period. The numbers of events, person-months and rate of recurrence in each arm will be shown. Kaplan-Meier analysis will be used to plot the survival curves for both treatment arms up to the final visit at 1 year. The Mantel-Cox hazard ratio will be used to assess the impact of the intervention on time-to-first-recurrence. The hazard ratio will be estimated with Cox regression, adjusting for substantial baseline imbalances if appropriate.

**b) Risk factors for recurrence**

A multivariate logistic regression model will be used to identify potential explanatory factors for recurrent tumour at one year, in addition to the randomised adjuvant therapy allocation. Baseline factors which will be examined in this model of recurrent tumour will include:

- i) Age
- ii) Sex
- iii) HIV status
- iv) Mean CD4 count
- v) HAART
- vi) HPV infection
- vii) Smoking
- viii) Serum Vitamin A level

c) Effect modification

We will assess effect modification of the intervention on recurrence at one year with the following factors by including an interaction term with treatment arm in the logistic regression model.

- i) Pre-operative tumour size – proxy measure will be the estimated area measured from digital photographs
- ii) Rate of tumour growth – estimated as a function of tumour size above and time in months since the participant noticed the tumour. We hypothesize that tumours with a high rate of growth have a higher propensity to recur.
- iii) Operating surgeon

**7) Analysis of adverse effects (secondary outcome)**

A secondary outcome will be the prevalence of epiphora (watering of the eyes) at 12 months. The prevalence of any epiphora and a positive dye disappearance test at any follow up visit in the treated eye will be described by arm.

**8) Sensitivity analysis**

Where expert opinion is unable to be unequivocally certain about the recurrence, sensitivity analysis will be conducted, categorizing these as non-OSSN.

Appendix 2 – Flow chart for reporting of safety events

