



UNIVERSITY OF LEEDS

This is a repository copy of *Regenerative Endodontic Technique using a combination of Amoxicillin and Metronidazole. A review and report of two cases.*

White Rose Research Online URL for this paper:  
<http://eprints.whiterose.ac.uk/92474/>

Version: Accepted Version

---

**Article:**

Nazzal Abudiak, H, Rajan, S, Karagianni, AP et al. (1 more author) (2013) Regenerative Endodontic Technique using a combination of Amoxicillin and Metronidazole. A review and report of two cases. *Quintessenz*, 64 (3). 1 - 11. ISSN 0033-6580

---

**Reuse**

Unless indicated otherwise, fulltext items are protected by copyright with all rights reserved. The copyright exception in section 29 of the Copyright, Designs and Patents Act 1988 allows the making of a single copy solely for the purpose of non-commercial research or private study within the limits of fair dealing. The publisher or other rights-holder may allow further reproduction and re-use of this version - refer to the White Rose Research Online record for this item. Where records identify the publisher as the copyright holder, users can verify any specific terms of use on the publisher's website.

**Takedown**

If you consider content in White Rose Research Online to be in breach of UK law, please notify us by emailing [eprints@whiterose.ac.uk](mailto:eprints@whiterose.ac.uk) including the URL of the record and the reason for the withdrawal request.



[eprints@whiterose.ac.uk](mailto:eprints@whiterose.ac.uk)  
<https://eprints.whiterose.ac.uk/>

**Title: Regenerative Endodontic Technique using a combination of Amoxicillin and Metronidazole. A review and discussion of two cases.**

**Authors:** Hani Abudiak<sup>1</sup>, Sadna Rajan<sup>2</sup>, Anthoula P. Karagianni<sup>3</sup>, Monty S Duggal<sup>4</sup>

<sup>1</sup>NIHR clinical lecturer, Department of Paediatric Dentistry, Leeds Dental Institute, Clarendon Way, LS2 9LU

<sup>2</sup> Postgraduate student, Department of Paediatric Dentistry, Leeds Dental Institute, Clarendon Way, LS2 9LU

<sup>3</sup> Postgraduate student, Department of Paediatric Dentistry, Leeds Dental Institute, Clarendon Way, LS2 9LU

<sup>4</sup> Professor and consultant in Paediatric Dentistry, Leeds Dental Institute, Clarendon Way, LS2 9LU

**Key words: Regenerative Endodontic Technique, non vital immature permanent incisors, bi-antibiotic paste.**

**Short Summary:**

The management of non vital anterior permanent teeth in children is a challenge for the clinicians. Once the tooth becomes non vital, the root development ceases, which renders the tooth weak and unable to withstand the physiological forces of mastication. This results in a high fracture rate, and therefore a poor prognosis in the medium to long term. Recently there has been a paradigm shift in the approach to this clinical problem through the use of regenerative endodontics. Despite many case reports, and a few case series that have been reported, the procedure is still shrouded in uncertainty as differing interventions have been used, though broadly based on similar principles. In the Department of Paediatric Dentistry at the Leeds Dental Institute we have used a particular regenerative endodontic technique (RET), using a mixture of two antibiotics (Amoxicillin and Metronidazole). In this paper, we aim to present the rationale for this technique and present two cases successfully treated and followed for up to two years.

**Background:**

The management of anterior permanent teeth in children that have become non vital as a result of a traumatic injury has always been one of the biggest challenges that has faced the clinicians. Once the tooth becomes non vital, the root development ceases at that point and the lack of further root development renders the tooth weak and unable to withstand the physiological forces of mastication, which results in a high fracture rate, and therefore a poor prognosis in the medium to long term. Traditional endodontic treatment approaches for these teeth have concentrated on achieving disinfection followed by the creation of an apical barrier against which the root filling can be condensed. This has been achieved using either an apexification approach with the use of calcium hydroxide, or more recently with the use of Mineral Trioxide Aggregate (MTA) to physically create a barrier against which the root canal can be obturated with a root filling material, such as gutta percha.

Calcium hydroxide had been the material of choice in apexification since it was first used by Kaiser in 1964 . Despite the wide use of this material, it has several limitations. Calcium hydroxide apexification requires frequent applications over several months (Finucane and Kinirons, 1999) hence requiring several appointments. Although the material is relatively inexpensive, the technique requires multiple appointments adding to the overall cost of managing these cases. The barrier formed, on the other hand, is often porous and not continuous or compact. Therefore the approach requires obturation of the canal using a technique that does not involve lateral condensation in order to prevent fracture of the thin canal walls (Shah et al., 2008). The long term use of  $\text{Ca(OH)}_2$  has been found to be associated with changes to the mechanical properties of dentine, which could later contribute to root fractures (Twati et al., 2009). It has been shown (Cvek, 1992, Al-Jundi, 2004) that teeth treated with apexification have an increases risk of root fractures. This is thought to be due to

the high alkalinity of calcium hydroxide (mostly used with apexification) which denatures the collagen of the dentin, specifically by interfering with the phosphate and the carboxylate groups within the dentinal proteins (Twati et al., 2009). Cvek et al (1992) reported fractures ranging from 77% of the most immature teeth to 28% of the most fully developed teeth when using  $\text{Ca(OH)}_2$  apexification. Finally,  $\text{Ca(OH)}_2$  has a high pH which is toxic to vital cells (Spangberg, 1969) and hence might damage the cells in its contact at the apex, which have regenerative capacity to heal periapical tissues.

The formation of an artificial apical plug could be achieved using different materials such as  $\text{Ca(OH)}_2$  powder (Kaiser, 1964), MTA (Torabinejad et al., 1995) and several other materials as summarised by Al Ansary (2006). The most common material used in artificial apical plug formation is MTA. Using MTA has several advantages over  $\text{Ca(OH)}_2$  apexification in that it is a biocompatible material, has osteoinductive properties, sets in the presence of moisture, and the treatment can be completed in a single visit (Shah et al., 2008). On the other hand, using MTA does not strengthen the remaining tooth structure. Furthermore, MTA has other disadvantages that include discoloration potential especially for grey MTA, difficult handling characteristics such as long setting time, expensive, and the difficulty in removal after setting (Parirokh and Torabinejad, 2010), in case of failure of the endodontic treatment. The use of MTA in the last decade has improved the outcomes (Bakland and Andreasen, 2012), but MTA itself is highly alkaline and is thought to make the teeth brittle and more prone to root fractures (Twati et al., 2009, Parirokh and Torabinejad, 2010).

Both these techniques have a fundamental problem in that although they allow root canal obturation, they do not contribute to any qualitative or quantitative increase in root dimensions, and the tooth remains predisposed to fracture (Cvek, 1992, Andreason et al.,

2002, Al-Jundi, 2004, Twati et al., 2009), with over half suffering root fractures and lost within the first 5-10 years of treatment, leaving the child with a treatment burden for the rest of their lives.

More recently there has been a paradigm shift in the approach to this intractable clinical problem through the use of regenerative endodontics. In order to achieve any quantitative or qualitative increase in root dimensions, it would be essential to somehow restore the blood supply to the tooth that was disrupted at the time of the traumatic injury. Only with a restored blood supply further deposition of dentin and cementum with viable odontoblasts and cementoblasts is possible. A better understanding of tissue engineering of the pulp-dentin complex has made it possible to design techniques and technologies in order to achieve regeneration of pulp-dentin complex, even long after the tooth has become non vital.

It is now accepted that the tissues surrounding the apex of an immature permanent incisor tooth in children is rich in stem cells and these stem cells have now been characterised as stem cells from apical papilla (SCAP), which are similar to dental pulp progenitor cells (Huang et al., 2008, Sonoyama et al., 2008). These cells are shown to be able to undergo odontoblastic/osteogenic, adipogenic, or neurogenic differentiation (Sedgley and Botero, 2012).

In order to harness the regenerative potential of these cells into forming a new pulp-dentin complex within a non vital tooth, few techniques have been proposed in the literature (Murray et al., 2007). Murray et al. (2007) reviewed these different techniques and summarised them as follows: (a) root canal revascularization via blood clotting, (b) postnatal stem cell therapy, (c) pulp implantation, (d) scaffold implantation, (e) injectable scaffold delivery, (f) three-dimensional cell printing, and (g) gene delivery.

These techniques are designed on the accepted principles of tissue engineering, and aim to harness the potential of stem cells in the apical papilla through the provision of a sterile environment and a scaffold within the root canal of the non-vital tooth (Huang, 2008). The use of advanced tissue engineering techniques for dental tissue regeneration, although promising, is still at the laboratory or animal trial stage (Huang, 2008).

On the other hand, several case reports/series had been published showing successful use of the conservative treatment approach with root canal disinfection using triple antibiotic paste and revascularisation via blood clotting in managing immature teeth with necrotic root canal systems (table 1). Several case reports/series (table 1) have been published and have shown the technique to have good predictable outcome and continued root development that would indicate that regeneration of the pulp-dentin complex has occurred. On the other hand, only one retrospective study has been published that has assessed the quantitative increase in radiographic measurement of root lengths and dentinal wall widths of immature permanent teeth treated using a regenerative approach (Bose et al., 2009). The authors collected post treatment radiographs of treated teeth from around the globe (54 cases) and divided them according to the intracanal medicament used into three test groups ( $\text{Ca(OH)}_2$ , Triple Antibiotic, and Formocresol). The authors also used post treatment radiographs of two control groups, MTA and non surgical root canal treatment (NSRCT). The results of their analysis showed the  $\text{Ca(OH)}_2$  and triple antibiotic groups had significantly greater increases in root lengths compared to either MTA or NSRCT. They also showed the triple antibiotic group produced significantly greater increases in dentin wall thickness compared with the other.

However, despite the plethora of case reports, there are no data based on a systematic evaluation of these techniques, and many case series that have been reported have all used differing interventions, though broadly based on similar principles.

Table 1. Some case reports and case series published in the literature showing successful use of the RET using triple antibiotic paste (Ciprofloxacin, Metronidazole and Minocyclin) and sealed using a combination of MTA and composite.

| Reference                   | Cases   | Cause  | Pulpal and periodontal diagnosis   | Irrigation solution   | Follow up | Results  |
|-----------------------------|---|--|--|---|-----------|--|
| (Banchs and Trope, 2004)    | Case report:<br>11 y boy  | Fractured dense evaginatus   | Necrotic pulp and chronic apical abscess                                       | 10 mL 5.25% NaOCl and 0.12% chlorhexidine   | 24 months | <ul style="list-style-type: none"> <li>• Complete resolution of radiolucency</li> <li>• Gradual apical closure with thickening of dentinal walls.</li> <li>• Positive response to pulpal cold test.</li> </ul>   |
| (Petrino, 2007)             | Case report:<br>8 y boy   | Not stated   | Necrotic pulp and chronic apical abscess                                       | 10 mL 5.25% NaOCl and 0.12% chlorhexidine   | 8 months  | <ul style="list-style-type: none"> <li>• Asymptomatic.</li> <li>• Apical closure with thickening dentinal walls.</li> </ul>  |
| (Thibodeau and Trope, 2007) | Case report:<br>9 y boy   | Complicated crown fracture   | Necrotic pulp and acute apical abscess   | 1.25% NaOCl   | 12 months | <ul style="list-style-type: none"> <li>• Asymptomatic.</li> <li>• Diffuse radiopacities noted in root canal system.</li> <li>• No response to pulp test (CO<sub>2</sub> ice).</li> <li>• Gradual apical development and closure.</li> </ul>  |
| (Jung et al., 2008)         | Case series:<br>1 <sup>st</sup> case:<br>10 y girl<br><br>2 <sup>nd</sup> case:<br>09y girl | 1 <sup>st</sup> case >caries<br><br>2 <sup>nd</sup> cases > not stated | 1 <sup>st</sup> cases > necrotic pulp<br><br>2 <sup>nd</sup> case > not stated | 2.5% NaOCl for 30 minutes   | 24 months | <p>Both cases:</p> <ul style="list-style-type: none"> <li>• Asymptomatic tooth.</li> <li>• Radiograph showed complete resolution of the radiolucency</li> </ul> <p>1<sup>st</sup> case:</p> <ul style="list-style-type: none"> <li>• Continued thickening of the dentinal walls</li> </ul> <p>2<sup>nd</sup> case:</p> <ul style="list-style-type: none"> <li>• The dentinal walls displayed continued thickening with closure of the apex.</li> </ul> |
| (Reynolds et al., 2009)     | Case series:<br>Two 11y girls   | Fractured dense evaginatus   | Necrotic pulps and chronic suppurative peri-radicular periodontitis            | 20 mL of 6% NaOCl then 5 mL rinse of saline then 10 mL of 2.0% chlorhexidine gluconate. | 18 months | <p>Both cases:</p> <ul style="list-style-type: none"> <li>• Asymptomatic.</li> <li>• The radiographs demonstrated evidence of periradicular bone healing and significant root development with maturation of the dentine as compared with the preoperative radiographs</li> </ul> <p>1<sup>st</sup> case:</p> <ul style="list-style-type: none"> <li>• Slight cervical discolouration was evident possibly related to the use of grey MTA.</li> </ul>  |



## **The Regenerative Endodontic Technique**

In the Department of Paediatric Dentistry at the Leeds Dental Institute we have used a particular treatment technique based on these published principles (Duggal and Twati, 2011). This technique involves disinfection followed by induction of a blood clot in the root canal system and finally a hermitically good coronal seal.

Disinfection in our technique is achieved through minimal instrumentation, irrigation with 0.5% Hypochlorite followed by using an intracanal medicament of a mixture of antibiotics left in the root canal system for two weeks. The aim of this disinfection technique is to preserve the thin dentinal walls and any viable tissues containing stem cells such as SCAP (Sonoyama et al., 2008) that may remain in the canal system. This is followed by the creation of a blood clot within the canal through inducing of bleeding from the apical stem cell rich areas into the root canal system using either sterile endodontic files or a sterile needle. The blood clot serves as a scaffold which the stem cells would use in order to repopulate the root canal system. A series of cases using this technique have been successfully treated and reported within our peer group internationally (Karagianni and Duggal, 2012).

One issue that yet remains to be resolved regards the choice of antibiotics. Many published case series promote a mixture of three antibiotics, namely Ciprofloxacin, Metronidazole and Monocycline. Indeed, a triple antibiotic pre mixed paste is also commercially available. In our opinion, it is unwise to use these pre-mixed pastes as there is little evidence in the stability of such mixtures and hence their antimicrobial efficacy. Within our team we have used this combination, but not in a pre-mixed form. We created a fresh mix of the three antibiotics just before its application in the root canal. Microbiological research within the

Department of Paediatric Dentistry on the suitability and efficacy of the three antibiotics that have been suggested for use in the literature has been carried out against the most common pathogens that are found within the root canals of teeth with necrotic pulps (Twati et al., 2011). We have found that a combination of two antibiotics (Ciprofloxacin and Metronidazole) is equally effective as when Minocycline is included in the mixture. Our initial evaluation of our cases has also shown that some had yellowish discoloration of the crowns due to the use of Minocycline, as Tetracyclines related antibiotics (Reynolds et al., 2009, Kim et al., 2010 ) are known to cause tooth discoloration. This finding, together with our microbiological data, has led us to exclude Minocycline from these treatments. We have also used a mixture of Amoxicillin and Metronidazole with similar efficacy. More research is required on the correct choice of the antibiotics that should be used within the root canal that would have a maximum efficacy and minimal side effects such as discolouration of the crowns.

Therefore, the Leeds Dental Institute regenerative Endodontic technique involves two dental visits as follows:

### **First Treatment Visit**

- The tooth is first isolated using dry dam (Directa, Upplands Visby, Sweden).
- The tooth is then accessed and the pulp extirpated. The root canal system is then irrigated with copious amounts of 0.5% sodium hypochlorite.
- The canal is then negotiated with minimal or no filing to prevent further weakening of the existing dentinal walls.
- The canal is then dried using paper points.

- Amoxicillin capsule (250mg) is then mixed with 1ml of 200 mg/5ml Metronidazole suspension in a dappen dish. An alternative could be mixing Metronidazole (100mg) and Ciprofloxacin (100mg) capsules (TriBioDent, Pharmacy production unit, Royal Victoria Infirmary, Newcastle, UK).
- The mixture of the two antibiotics is then filled into the root canal using a syringe and the plastic tube of a pink intravenous cannula (Figure 1) in order to deliver the antibiotic mixture to the entire root canal system.
- A cotton pellet is then placed to cover the root canal orifice and the access sealed with a glass ionomer cement to prevent any coronal leakage or contamination of the root canal with oral microorganisms.

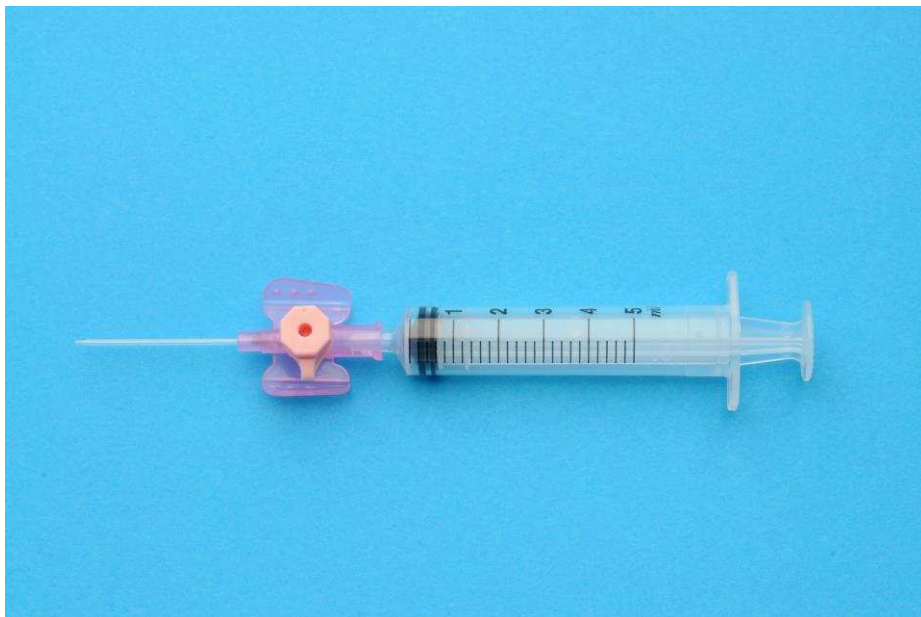

Figure 1 The bi-antibiotic paste delivery system using a 5ml syringe and the plastic part of a pink intravenous cannula.

### Second Treatment Visit

- Plain local analgesia (no vasoconstrictor) is administered and the tooth isolated and re-accessed as described above.
- The antibiotic mixture then flushed out of the root canal by irrigation with normal saline. Following this the root canal should be thoroughly dried with paper points.

- This is then followed by insertion of a sterile 23-gauge needle or a finger spreader with a length of 2 mm beyond the working length, past the confines of the root canal, into the periapical tissues to intentionally induce bleeding into the root canal. The bleeding is then allowed to fill the root canal.
- Once the root canal is filled with blood, a cotton pledget is placed in the pulp chamber and a clot allowed forming in the root canal.
- Once the clot has formed the pulp chamber in the coronal part is thoroughly cleaned to remove any remnants of the blood, which could cause discolouration in the future.
- The access cavity is then hermetically sealed with three layers of material to prevent coronal leakage and contamination; Portland cement, followed by glass ionomer and then composite resin.

The following is a description of two cases treated at our department where two non vital immature permanent incisors were treated using RET. The procedure involved the use of a mixture of two antibiotics, Amoxicillin and Metronidazole.

#### Case 1

A healthy 10 year old boy referred by his dentist for management of a traumatised upper left first permanent incisor UL1. The patient reported colliding against another child at school playground 6 month prior to that appointment. Our initial clinical and radiographic examination revealed enamel/dentine fracture of the UL1, restored by the dentist, and no signs of pulpal inflammation or necrosis. On reviewing the patient a year and a half later, a negative response to vitality testing of the UL1 was found and a diagnosis of necrotic pulp canal system was made. Radiographic examination of UL1 revealed incomplete root formation with parallel dentinal walls and chronic periapical radiolucency suggestive of

chronic periapical abscess (Figure 2,a) . After discussing treatment options with the parents, a decision was made to treat the tooth using RET. Therefore an information leaflet was given to the legal guardian and an appointment was arranged for consent and the first stage of RET treatment. This allowed the legal guardian time to consider the information given and therefore achieving informed consent.

At the next appointment, the UL1 was isolated using dry dam, accessed, and gentle extirpation was done. The canal was then irrigated using 0.5% sodium hypochlorite and dried using paper points. The tooth was then dressed with a mixture of Metronidazole (200 mg/5 ml suspension) and Amoxicillin (250mg capsule). The canal was then temporarily sealed with a cotton pledget and Fuji IX LC (GC America Inc, IL).

The patient was then seen 10 days later when the tooth was isolated and re-accessed under local analgesia. The antibiotic mixture was then flushed out of the root canal using normal saline and then thoroughly dried with paper points. This was then followed by insertion of a sterile 23-gauge needle with a length of 2 mm beyond the working length and past the confines of the root canal into the periapical tissues inducing bleeding into the root canal, allowing the blood to fill the root canal. Once the root canal was filled with blood, a cotton pledget was placed in the pulp chamber and a clot was allowed to form in the root canal.

Once the clot had formed the pulp chamber in the coronal part had been thoroughly cleaned to remove any remnants of the blood, in order to prevent discolouration of the crown.

The access cavity was then hermetically sealed with three layers of material to prevent coronal leakage and contamination; MTA, followed by glass ionomer and then composite resin.

Three months following RET treatment; no signs of infection, tenderness or discoloration were evident. Radiographic examination revealed reduction in the size of the periapical lesion and evidence of continued root development (Figure 2,b).

Nine months post RET treatment there were no signs of infection, tenderness or discoloration and radiographically the periapical (PA) radiolucency had almost completely resolved with evidence of continued root development and a apexogenesis (Figure 2,c).

Fifteen months following treatment a grey-yellow discoloration of the cervical area of the tooth was evident. Radiographic examination revealed complete resolution of the PA radiolucency, presence of a continuous periodontal ligament (PDL) space, and evidence of continued apexogenesis (Figure 2,d).

Twenty three month following RET treatment evidence of continued root development, thickening of dentinal walls and a closed apex plus thick barrier formation was evident (Figure 2,e).

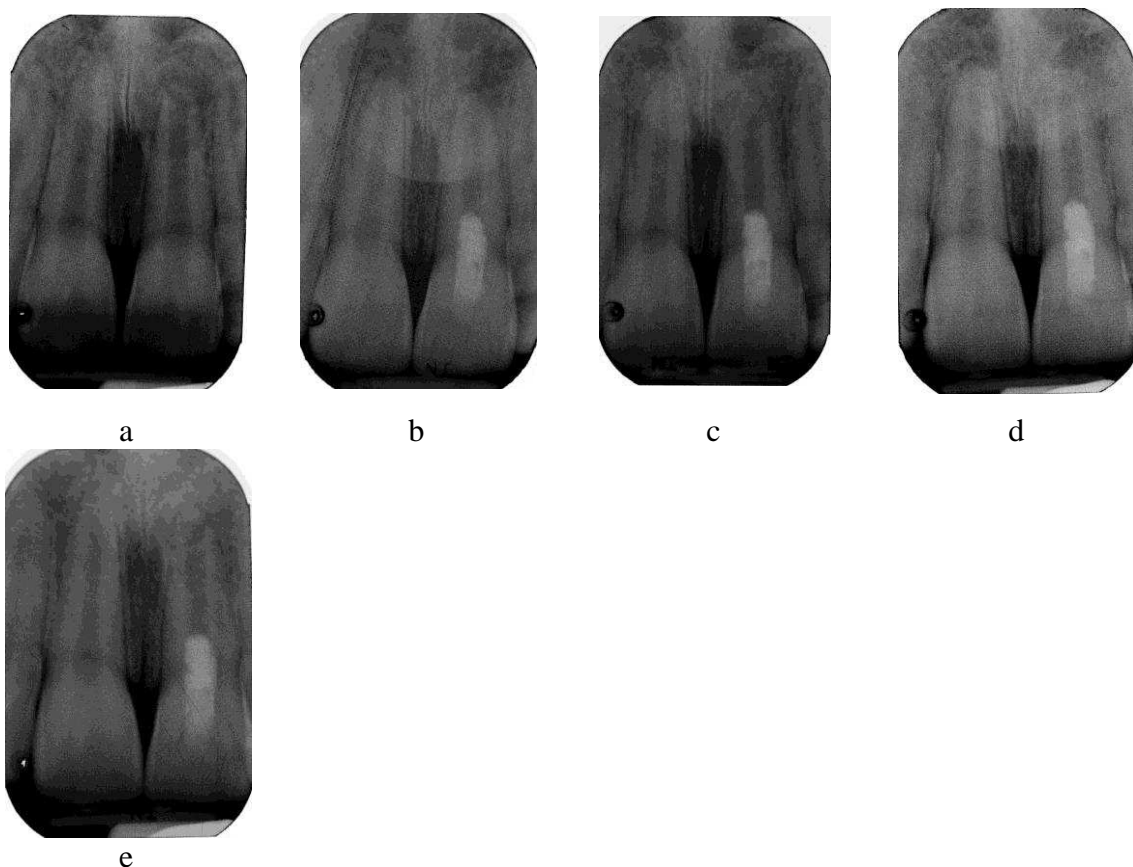


Figure 2 Periapical radiographs taken of the UL1 at pre-op stage (a), 3 months (b), 9 months (c), 15 months (d) and 23 months (e).

## Case 2

A 7 year old girl with developmental delay and poor balance presented to her dentist in March 2009 with a fractured UR1. She sustained the injury by stumbling and falling face first onto a concrete floor. No other associated trauma was reported. The next day, her dentist had restored UR1 with composite restoration. However, over a span of a year, the restorations needed replacement twice. Subsequently, the child presented with an abscess associated with the UR1. Antibiotic (amoxicillin 250mg tds) was prescribed and child referred to our department for further management of non-vital immature UR1.

On presentation, intra-oral examination showed the UR1 to be tender to percussion, had normal mobility and an associated labial sinus. Periapical radiographic examination indicated that both UR1 and UL1 had open apices (Figure 3,a). Therefore, the UR1 was diagnosed with pulp necrosis and periapical periodontitis. In addition, UR1 had an uncomplicated enamel dentine fracture and dens invaginatus.

At the first visit, local anaesthetic was administered using the Wand local anaesthesia system (Milestone Scientific, Deerfield, IL). The tooth was isolated with rubber dam, root canal was accessed and pulp extirpated. Bleeding and suppuration was present in the canal. Canal was gently irrigated with 0.5% sodium hypochlorite. The working length was confirmed with a periapical radiograph. The canal was irrigated with normal saline and dried using paper points. An antibiotic mixture of Metronidazole (200 mg/5 ml suspension) and Amoxicillin (250mg capsule) was syringed into the canal. A moist cotton pledget was placed and access cavity was temporised with Fuji IX LC (GC America Inc, IL).

At the second visit (21 days later), the patient had no complaints. The labial sinus associated to UR1 was resolving and surrounding soft tissues appeared normal. UR1 was anaesthetised and tooth isolated with rubber dam. The canal was accessed and irrigated with NaOCL followed by normal saline and dried. Clinical examination confirmed that the canal was free

of infection and discharge. Finger spreader sized medium was used to induce fresh bleeding into the canal. This was difficult and slow probably due to the vasoconstrictors in the local anaesthetic agent used. However, once the canal had filled with fresh blood, a moist cotton pledget was used to seal access cavity and left for several minutes to clot. White MTA was placed and access cavity was temporised with Fuji IX LC (GC America Inc, IL). Baseline periapical radiograph was then taken (Figure 3,b).

At 3 months review, the child had no complaints associated with the UR1. Intra-oral examination revealed absence of the sinus and normal surrounding gingiva. Colour and mobility were normal and tooth was not tender to palpation or percussion. The periapical radiograph indicated that further hard tissue deposition at the apex and continued root development occurred (Figure 3,c). No pathologies were noted.

At 6 months review after RET, UR1 remained asymptomatic with normal surrounding mucosa and gingival. Periapical radiograph revealed further thickening of the root canal walls (Figure 3,d).

At 1 year review after RET, the periapical radiograph indicated that both UR1 and UL1 had the similar root length and apex of UR1 had closed. A definite calcific bridge was visible beyond the MTA plug at the apex and further thickening of the root canal walls at the apex was noted (Figure 3,e).



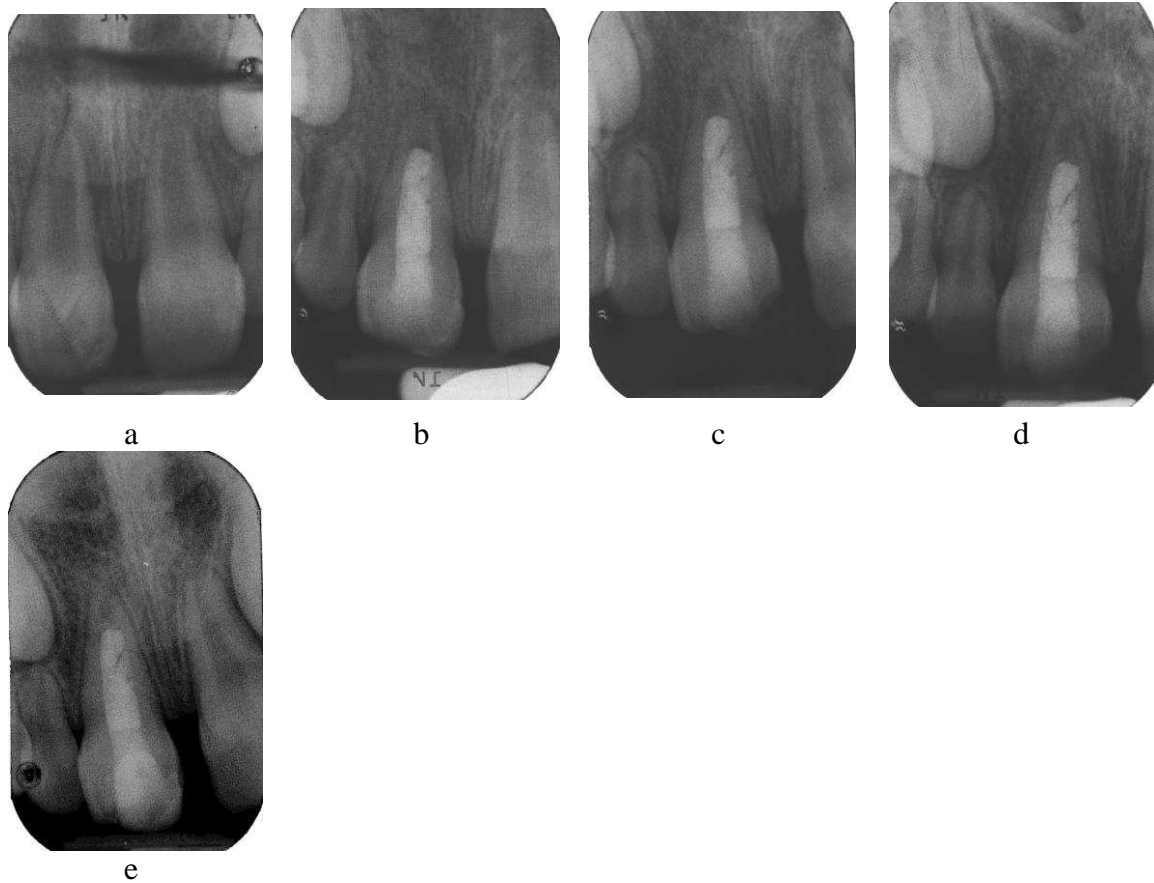


Figure 3: Periapical radiographs taken of UR1 at pre-op stage (a) baseline radiograph immediately after RET (b) 3 months review (c) 6 months review and a 1 year review (d). Tooth showed signs of vitality and continued root growth as early as 3 months.

### **Discussion:**

Recently there has been a paradigm shift in the approach to the management of non vital immature teeth with open apices through the use of regenerative endodontic techniques (RET). This technique enables quantitative (Bose et al., 2009) and qualitative (Table 1) increase in root dimensions possibly through restoring the blood supply to the tooth that was interrupted at the time of the traumatic injury. Only with a restored blood supply further deposition of dentin and cementum with viable odontoblasts and cementoblasts is possible. This had been achieved through the use of a mixture of three antibiotics (Metronidazole, Ciprofloxacin and Minocycline) and blood clot induction in the canal system (Table 1).

Using this triple antibiotic paste on some of the cases at Leeds Dental Institute, the authors observed yellowish crown discoloration which was attributed to the use of Minocycline. The use of triple antibiotic paste was found in an in vitro study to cause more discoloration to extracted bovine teeth compared to different endodontic medicaments such as Ledermix and MTA (Lenherr et al., 2012). Therefore an in vitro microbiological study, conducted at our department, lead us into excluding Minocycline from any future RET treatments (Twati et al., 2011). We now use a combination of Amoxicillin and Metronidazole in our management as we have shown in the cases presented here. In case 1, this patient was reviewed for twenty three months following his RET treatment and showed favourable outcomes such as evidence of continued root development, thickening of dentinal walls and a closed apex plus thick apical barrier formation (Figure 2,e). On the other hand, fifteen months following RET treatment; a grey-yellow discoloration of the cervical area of the tooth was evident. We attributed this to the use of grey MTA which is associated with tooth discoloration (Parirokh and Torabinejad, 2010, Lenherr et al., 2012).

This led us to use white MTA in treating case 2 which after 1 year review following RET, showed evidence of continued root formation and closed apex. A definite calcific bridge was visible beyond the MTA plug at the apex and further thickening of the root canal walls at the apex was noted (Figure 3,e). No crown discoloration was noted in this case. However, even white MTA tends to discolour in an anaerobic environment, as it still contains Bismuth for radiopacity. We now use Portland cement in our protocols which does not suffer from the same disadvantage,

Lenherr et al. (2012) conducted an in vitro study comparing the discoloration potential of different endodontic materials including grey MTA, Grey MTA with blood, White MTA, White MTA with blood, Portland cement and Portland cement with blood on extracted bovine incisors in comparison to no medicament use. Colour assessment was performed

using a spectrophotometer (VITA Easyshade compact; VITA Zahnfabrik, Bad Sa'ckingen, Germany). The authors reported the following descending sequence of discolouration potential: Grey MTA, Grey MTA with blood, Portland cement with blood, white MTA with blood, white MTA and finally Portland cement. However, these materials were applied directly onto dentine-enamel cuboid blocks rather than into the roots of the teeth at a distance from the cemento-enamel junction.

Case 2 also showed the need to use plain local analgesia (no vasoconstrictor) on the second treatment visit as that would help when inducing bleeding into the tooth. This is important as in some cases it is not easy to induce enough bleeding into the root canal.

### **Conclusion:**

The use of regenerative endodontics has caught the imagination of the dental profession, but its long term outcomes are far from clear. Systematic studies using adequate control and randomisation are required before it is recommended for general adoption for the dental profession. Although the technique is based on the general principles of tissue bio-engineering, it could be argued that the technique of injuring the apical tissue, and inducing bleeding, cannot control what tissues might grow into the root canal. Therefore, it is not possible at the moment to say with certainty whether the tissue that grows into the root canal is regenerative tissue, repair related tissue, or revascularisation. In the future, it might be possible to use growth factors in the root canal to introduce a degree of control on what tissues are regenerated into the root canal system. Many groups are currently working to understand this technique, and refine it. It is hoped that in the next decade we will be able to recommend this technique as a treatment of choice for all non vital teeth with immature roots in children and adolescents. For now we recommend that this technique be considered in those cases where the root development is so incomplete that the clinicians feel that the

prognosis would be poor with the use of MTA. In such cases if further root development or more hard tissue deposition is obtained with the use of regenerative technique, this would improve their medium to long term prognosis.

## References:

- Al-Jundi, S. Type of treatment, prognosis, and estimation of time spent to manage dental trauma in late presentation cases at a dental teaching hospital: a longitudinal and retrospective study. *Dental Traumatology*, 2004. 20, 1-5.
- Al Ansary, M. 2006. Interventions for treating traumatised non-vital immature permanent front teeth. MDentSci, University of Leeds
- Andreason, J, Farik, B & Munksgaard, E. Long-term calcium hydroxide as a root canal dressing may increase risk of root fracture. . *Dental Traumatology*, 2002. 18, 134-137.
- Bakland, LK & Andreasen, JO. Will mineral trioxide aggregate replace calcium hydroxide in treating pulpal and periodontal healing complications subsequent to dental trauma? A review. *Dental Traumatology*, 2012. 28, 25-32.
- Banchs, F & Trope, M. Revascularization of immature permanent teeth with apical periodontitis: new treatment protocol? *Journal of Endodontics*, 2004. 30, 196-200.
- Bose, R, Nummikoski, P & Hargreaves, K. A retrospective evaluation of radiographic outcomes in immature teeth with necrotic root canal systems treated with regenerative endodontic procedures. *Journal of Endodontics*, 2009. 35, 1343-9.
- Cvek, M. Prognosis of luxated non-vital maxillary incisors treated with calcium hydroxide and filled with gutta-percha. A retrospective clinical study. *Dental Traumatology*, 1992. 8, 45-55.
- Duggal, M & Twati, W 2011. Endodontic management of non-vital anterior teeth with incomplete root development. In: SPLIETH, C. H. (ed.) *Revolutions in Pediatric Dentistry*. Quintessenz Verlags-GmbH.
- Finucane, D & Kinirons, MJ. Non-vital immature permanent incisors: factors that may influence treatment outcome. *Dental Traumatology*, 1999. 15, 273-277.
- Huang, G, Sonoyama, W, Liu, Y, Liu, H, Wang, S & Shi, S. The hidden treasure in apical papilla: the potential role in pulp/dentin regeneration and bioroot engineering. *Journal of Endodontics*, 2008. 34, 645-651.
- Huang, GTJ. A paradigm shift in endodontic management of immature teeth: Conservation of stem cells for regeneration. *Journal of Dentistry*, 2008. 36, 379-386.
- Jung, I, Lee, S & Hargreaves, K. Biologically based treatment of immature permanent teeth with pulpal necrosis: A case series. *Journal of Endodontics*, 2008. 34, 876-87.
- Kaiser, H. Management of wideopen canals with calcium hydroxide. Read before the Americal Association of Endodontics 1964 Washington.
- Karagianni, A & Duggal, M. Regenerative Endodontic Therapy (RET) for management of non vital immature permanent teeth. 11th Congress of the European Academy of Paediatric dentistry OPD125. Place 2012. Published.
- Kim, J, Kim, Y, Shin, S, Park, J & Jung, I. Tooth discoloration of immature permanent incisor associated with triple antibiotic therapy: a case report. *Journal of Endodontics*, 2010 36, 86-91.
- Lenherr, P, Allgayer, N, Weiger, R, Filippi, A, Attin, T & Krastl, G. Tooth discoloration induced by endodontic materials: a laboratory study. *International Endodontic Journal*, 2012. no-no.
- Murray, PE, Garcia-Godoy, F & Hargreaves, KM. Regenerative endodontics: a review of current status and a call for action. *Journal of Endodontics*, 2007. 33, 377-90.
- Parirokh, M & Torabinejad, M. Mineral Trioxide Aggregate: A Comprehensive Literature Review—Part III: Clinical Applications, Drawbacks, and Mechanism of Action. *Journal of Endodontics*, 2010. 36, 400-413.

- Petrino, JA. Revascularization of necrotic pulp of immature teeth with apical periodontitis. *Northwest Dentistry*, 2007. 86, 33-5.
- Reynolds, K, Johnson, J & Cohenca, N. Pulp revascularization of necrotic bilateral bicuspid using a modified novel technique to eliminate potential coronal discoloration: a case report. *International Endodontic Journal*, 2009. 42, 84–92.
- Sedgley, C & Botero, T. Dental Stem Cells and Their Sources. *Dental Clinics of North America* 2012. In press (available online <http://www.sciencedirect.com/science/article/pii/S0011853212000365>).
- Shah, N, Logani, A, Bhaskar, U & Aggarwal, V. Efficacy of revascularization to induce apexification/apexogenesis in infected, nonvital, immature teeth: a pilot clinical study. *Journal of Endodontics*, 2008. 34, 919-925.
- Sonoyama, W, Liu, Y, Yamaza, T, Tuan, R, Wang, S, Shi, S & Huang, G. Characterization of the apical papilla and its residing stem cells from human immature permanent teeth: a pilot study. *Journal of Endodontics*, 2008. 34.
- Thibodeau, B & Trope, M. Pulp revascularization of a necrotic infected immature permanent tooth: case report and review of the literature. *Pediatric Dentistry*, 2007. 29, 47-50.
- Torabinejad, M, Hong, CU, McDonald, F & Pitt Ford, TR. Physical and chemical properties of a new root-end filling material. *Journal of Endodontics*, 1995. 21, 349-353.
- Twati, W, Percival, R & Duggal, M. The antimicrobial effect of various root canal medicaments used in management of immature non vital anterior teeth. *International Journal of Paediatric Dentistry*, 2011. 21 (S1) Abstract O12-101, 35.
- Twati, W, Wood, D, Liskiewicz, T & Duggal, M. Effect of non-setting calcium hydroxide and MTA on human dentine following long term application. *International Journal of Paediatric Dentistry*, 2009. 19:S1(Abstract O16-117), 43.