



University of Dundee

Trainee anaesthetist diagnosis of intraneural injection. A study comparing B-Mode ultrasound with the fusion of B-Mode and elastography in the soft embalmed Thiel cadaver model

Munimara, S.; Zeally, K. ; Schwab, A.; Columb, M.; Corner, G. A.; Eisma, R.; McLeod, Graeme

Published in:
British Journal of Anaesthesia

DOI:
[10.1093/bja/aew337](https://doi.org/10.1093/bja/aew337)

Publication date:
2016

Document Version
Peer reviewed version

[Link to publication in Discovery Research Portal](#)

Citation for published version (APA):

Munimara, S., Zeally, K., Schwab, A., Columb, M., Corner, G. A., Eisma, R., & McLeod, G. A. (2016). Trainee anaesthetist diagnosis of intraneural injection. A study comparing B-Mode ultrasound with the fusion of B-Mode and elastography in the soft embalmed Thiel cadaver model. *British Journal of Anaesthesia*, 117(6), 792-800.
DOI: [10.1093/bja/aew337](https://doi.org/10.1093/bja/aew337)

General rights

Copyright and moral rights for the publications made accessible in Discovery Research Portal are retained by the authors and/or other copyright owners and it is a condition of accessing publications that users recognise and abide by the legal requirements associated with these rights.

- Users may download and print one copy of any publication from Discovery Research Portal for the purpose of private study or research.
- You may not further distribute the material or use it for any profit-making activity or commercial gain.
- You may freely distribute the URL identifying the publication in the public portal.

Trainee anaesthetist diagnosis of intraneural injection. A study comparing B-Mode ultrasound with the fusion of B-Mode and elastography in the soft embalmed Thiel cadaver model.

Shilpa Munirama FRCA EDRA
Consultant Anaesthetist
Department of Anaesthesia
Manchester Royal Infirmary
shilpa.m@hotmail.co.uk

Kate Zealley FRCA
Specialist Registrar and Clinical Fellow in Anaesthesia
Department of Anaesthesia and Institute of Academic Anaesthesia, Ninewells Hospital & Medical School, Dundee UK
k.zealley@nhs.net

Andreas Schwab MSc
Biomedical Engineer
Institute of Medical Physics
Friedrich Alexander University-Erlangen-Nuremberg
andreas.schwab@imp.uni-erlangen.de

Malachy Columb FRCA FFICM
Intensive care Unit
Wythenshawe Hospital,
South Manchester University Hospitals,
Manchester, UK
mlacolumb@doctors.org.uk

George A Corner PhD
Emeritus Professor of Bioengineering
University of Dundee
g.a.corner@dundee.ac.uk

Roos Eisma PhD
Centre for Anatomy and Human Identification,
University of Dundee
roos.eisma@gmail.com

Graeme A McLeod FRCA FFPMRCA MD
Consultant & Honorary Clinical Professor
Institute of Academic Anaesthesia
Ninewells Hospital & Medical School
g.a.mcleod@dundee.ac.uk

Corresponding Author
Current address
Graeme A McLeod
Consultant Anaesthetist & Honorary Clinical Professor
Institute of Academic Anaesthesia
Ninewells Hospital & Medical School
g.a.mcleod@dundee.ac.uk

Keywords

Regional anaesthesia

Ultrasonography

Elastography

Running head

Elastography diagnosis of intraneural injection

ABSTRACT

Background: The incidence of intraneural injection during trainee anaesthetist ultrasound guided nerve block varies between 16% in experts and up to 35% in trainees. We hypothesised that elastography, an ultrasound-based technology that presents colour images of tissue strain had the potential to improve trainee diagnosis of intraneural injection during UGRA when integrated with B-Mode ultrasound onto a single image.

Methods: We recorded 40 median nerve blocks randomly allocated to 0.25ml, 0.5ml, 1ml volumes to 5 sites on both arms of two soft embalmed cadavers using a dedicated B-Mode ultrasound and elastography transducer. We wrote software to fuse elastogram and B-Mode videos then asked 20 trainee anaesthetists whether injection was intraneural or extraneural when visualising B-Mode videos, adjacent B-Mode and elastogram videos, fusion elastography videos or repeated B-Mode ultrasound videos.

Results: Fusion elastography improved the diagnosis of intraneural injection compared to B-Mode ultrasound, Diagnostic Odds Ratio (DOR) (95%CI) 21.7 (14.5 - 33.3) versus DOR 7.4 (5.2 - 10.6), $P < 0.001$. Compared to extraneural injection, intraneural injection was identified on fusion elastography as a distinct, brighter translucent image, geometric ratio 0.33 (95%CI: 0.16 - 0.49) $P < 0.001$. Fusion elastography was associated with greater trainee diagnostic confidence, OR (95%CI) 1.89 (1.69 - 2.11), $P < 0.001$, and an improvement in reliability, Kappa 0.60 (0.55 - 0.66).

Conclusions: Fusion elastography improved the accuracy, reliability and confidence of trainee anaesthetist diagnosis of intraneural injection.

BACKGROUND

Anaesthetists have difficulty diagnosing intraneural injection during ultrasound guided regional anaesthesia (UGRA)¹; the incidence of intraneural injection using ultrasound varies between 16% in experts and up to 35% in trainees^{2,3}. Functional impairment such as temporary neuropraxia may occur in up to 1 in 8⁴⁻⁷ patients and permanent nerve damage occurs in approximately 1 in 2,500 patients⁸. The mechanisms accounting for nerve damage include fascicle trauma, ischaemia and local anaesthetic toxicity⁹. More recently needle-epineurium contact was associated with intraneural haematoma, inflammation and myelin damage in over half of cases in animal studies¹⁰⁻¹².

Inadequate regional anaesthesia training, patient factors, or technical imaging limitations may all account for the high incidence of intraneural injection amongst trainees. Inexperienced anaesthetists struggle to align the needle in the plane of the ultrasound transducer, and have difficulty visualising the tip of the needle relative to the epineurium at the point of injection¹³. Obesity increases the distance between skin and the nerve target, dissipating acoustic energy into tissues as heat¹⁴. Nerves and adjacent tissue have similar acoustic impedance and are difficult to differentiate, and optimal resolution of tissues is limited by transducer frequency¹⁵. Alternative nerve detection techniques include electrical peripheral nerve stimulation (PNS) and needle tip opening injection pressure. PNS is associated with poorer block quality than ultrasound guidance and a four-fold greater risk of intravascular injection¹⁶. Electrical stimulation is inaccurate – at currents $\leq 0.5\text{mA}$ a motor response only occurs in three quarters of patients when the needle tip is adjacent to the nerve^{17,18}. In contrast, needle tip opening injection pressure accurately excludes intraneural injection at the 15psi threshold, but fails to differentiate between connective tissue and epineurium^{19,20}. There is a need for visual technology that offers non-experts the capacity to accurately, reliably and confidently recognise tissue displacement of test doses within peripheral nerves. The impact of such a technology would be

rapid withdrawal of the needle from the nerve and injection repeated close to but not touching the epineurium.

Elastography is a widely available, inexpensive ultrasound-based technology, available from most ultrasound manufacturers that presents colour images of strain^{21,22}, a unitless entity indicative of relative displacement of tissue. Using elastography in a routine clinical setting is difficult, however, because the anaesthetist must visualise two screens in real-time, and this has restricted elastography in our practice to a *post-hoc* analysis tool^{23,24}. During our cadaver work, we noticed that, using a 1ml test dose, intraneural injection was seen as a distinct, small, bright, round flash over the nerve. Extraneural injection was seen as a much larger, duller, asymmetrical pattern around the nerve.

Therefore, our primary objective was to fuse elastography and B-Mode images onto a single ultrasound image using engineering software, then test the ability of trainee anaesthetists to diagnose intraneural injection. Our secondary objectives were to identify variables that predicted correct diagnosis, assess the reliability of assessment, gage the level of trainee confidence for each diagnosis, measure changes in nerve cross-sectional area and brightness associated with extraneural and intraneural injection of 0.25ml, 0.5ml and 1ml volumes, and gain feedback from trainees at the end of the study.

Methods

Cadaver nerve blocks

An experienced regional anaesthetist conducted 40 ultrasound guided median nerve blocks using 0.25ml, 0.5ml and 1ml test doses in the soft embalmed Thiel cadaver to provide our engineers with data to fuse elastography with B-Mode ultrasound. We chose 0.5ml and 1ml volumes because we routinely use these as test doses, and chose 0.25ml to to evaluate trainees' recognition of ultra-low

volumes. Injections were administered at a rate of approximately 1ml every 2 seconds in order to mimic clinical practice. Using computer software, we randomly allocated nerve blocks to five sites, 2cm apart and intraneural/extraneural locations over the median nerve on both forearms of two soft embalmed Thiel cadavers on two occasions, one week apart within the Centre for Anatomy and Human Identification (CAHID), University of Dundee. We recorded nerve blocks using B-Mode ultrasound and proprietary elastography using a Zonare (Mountain View, CA) Z.one ultrasound scan engine build release 4.2 and a cross-correlation elastography algorithm.

Software Development

We wrote software using MATLAB 7.9 software (Mathworks, Natick, MA) with Image Acquisition and Image Processing Toolboxes in order to combine the B-Mode and elastography images. First, we converted colour elastogram videos to 8-bit grayscale videos, then reduced “salt and pepper” noise by applying a 2D median filter (Fig 1). Secondly, we chose brightness thresholds between 0 and 255 on an 8-bit grayscale map for each block in order to create a white image replicating the shape of the elastogram strain pattern on a black background. The resultant pattern, visualised as a white, ebbing and flowing area, was termed enhanced elastography. Third, we superimposed the enhanced elastography image onto the B-Mode image. The strain pattern was visualised as a white “ghost” like shadow in order that the underlying nerve could be visualised underneath. This image was termed fusion elastography (Fig 1). B Mode, elastography and fusion videos were converted to constituent TIFF files and analysed using ImageJ, NLM, Washington DC.

Image measurement

From our videos we measured the area and brightness of: (i) the median nerve before and during nerve block; (ii) the coloured strain pattern on the elastogram and; (iii) the white strain pattern on the fused B-Mode and elastography image.

Two independent raters, using the freehand drawing tool of ImageJ, circumscribed the cross sectional area of the median nerve and elastogram displacement on every 4th video frame recorded at a frequency of 8.s⁻¹. Each image was calibrated to a standard 7.28 pixels mm⁻². For analysis, we noted the pre-block cross sectional nerve area, and the maximum cross sectional area of the nerve, colour elastogram and white fusion image during injection. Tissue brightness was automatically calculated by ImageJ as the sum of gray values between 0 (black) and 255 (white) of all pixels within outlined regions of interest divided by the number of pixels. In order to calculate the brightness of colour strain patterns each pixel was converted to grayscale using the weighted formula recommended by ImageJ whereby: gray = (0.299*red + 0.587*green + 0.114*blue).

Expert Assessment

Two UGRA experts met and agreed which injections were intraneural or extraneural by detailed analysis of B-Mode and fused B-Mode images. Experts judged intraneural injection as increase in the cross-sectional area of the nerve on B-mode images and overlay of the fused image on the nerve.

Anaesthetist training

Our study received ethical approval from the University of Dundee non-clinical Ethics committee and the University of Dundee Thiel Advisory Committee. All trainees within the East of Scotland School of Anaesthesia were invited by e-mail to participate; twenty responded and voluntarily opted into the study. Before analysis of images, trainees were taught to recognise intraneural and extraneural injection on B-Mode, elastography and fusion elastography videos. Trainees were shown four training videos. The first showed an ultrasound guided median nerve block recorded in an anonymous patient showing circumferential spread of local anaesthetic, followed by nerve distention secondary to accidental intraneural injection. The second demonstrated a well conducted interscalene block in a patient using B-Mode ultrasound and elastography, illustrating good

perineural spread between the nerve roots of C5 and C6 on both modalities. The third highlighted an intentional sciatic intraneural injection in the soft embalmed cadaver demonstrating intraneural swelling on B-Mode ultrasound and intraneural colour enhancement using elastography. The fourth video showed examples of intraneural and extraneural injection using fusion elastography.

Assessment

We started our study when each rater was satisfied that they had gained sufficient knowledge to understand the patterns seen on B-Mode ultrasound and elastography during extraneural and intraneural injection.

Assessment occurred on two separate occasions. Trainees were asked to interpret 40 B-Mode ultrasound videos, then the same B-Mode videos paired with adjacent elastography videos. One week later, raters were asked to interpret 40 fused elastography and B-Mode videos then repeat the assessment of the initial B-Mode ultrasound videos. The latter evaluation was termed test - retest.

Because assessment of 80 videos in one sitting is arduous, we decided to conduct the second half of the experiment one week later, to reduce the effects of tiredness on trainee image interpretation and to lessen any effect of memory on performance.

Raters assessed the first static frame of each video over 5 seconds in order to identify anatomical structures. Each video was then run for 12 seconds and raters were asked to diagnose whether injection was extraneural or intraneural. Our primary end point was the diagnosis of intraneural injection and our secondary end point was diagnostic confidence for each video measured on a 3-point categorical scale (1 = low, 2 = medium, 3 = high). In order to replicate clinical practice, no repeated viewings were permitted.

Questionnaire

At the end of the study, trainees were asked overall how realistic B-Mode images were using a 1 to 5 categorical score where 1 = not very realistic and 5 = very realistic. Trainees were also asked how confident they were overall diagnosing intraneural and extraneural injection using each imaging modality using a 1 to 5 a categorical score where 1 = not very confident and 5 = very confident.

Statistical analysis

The diagnostic accuracy of each modality was calculated using 2x2 tables to categorise rater diagnosis of intraneural or extraneural injection according to actual diagnosis. From this data we calculated the sensitivity and specificity of each modality, the positive likelihood ratio and diagnostic odds ratio. Concordance between raters was expressed as Kappa. Correct diagnosis was modelled using stratified logistic regression model (NCSS, Utah) and (Logxact, Cytel, Cambridge, MA) which controlled for repeated measures. Our model covariates included: trainee rater diagnosis, trainee rater confidence, ultrasound modality; duration of anaesthetic training; cadaver; side of injection; injection sequence and volume. Area and brightness data was log transformed and anti-logged for presentation. Data is presented as geometric mean and geometric ratio with 95% confidence interval (95%CI). Mean Difference was calculated using Tukey-Kramer's All Pairs Simultaneous Confidence Intervals analysis of overall confidence used Kruskal-Wallis: all pairwise comparisons (Dwass-Steel-Christlow-Fligner). $P < 0.05$ was considered significant.

No power analysis was conducted as this was the first study to investigate elastography as a means of diagnosing intraneural injection. Trainees were a broad representation of UK trainees and had achieved the appropriate standards of the training curriculum of the Royal College of Anaesthetists (RCOA).

Results

We successfully recorded 40 procedures randomised to 22 intraneural and 18 extraneural blocks. Experts agreed 18 blocks were extraneural, (6 - 0.25ml, 6 - 0.5ml and 6 - 1ml) and that 22 blocks were intraneural (7 - 0.25, 7 - 0.5ml and 8 - 1ml). A coloured strain pattern was seen with all injections. All fusion images were characterised by a white transparent, ghost-like strain pattern overlying the B-Mode image.

Image characteristics

Typical examples of intraneural and extraneural injection on B-Mode, elastography and fusion images are shown in Fig 2.

Diagnosis of intraneural injection

Mean (95%CI) diagnostic Odds Ratio for intraneural injection increased from 7.4 (5.2 – 10.6) using B-Mode ultrasound to 21.7 (14.5 - 33.3) using fusion elastography $P < 0.001$ (Table 1). However, there was no difference in diagnostic performance when comparing B-Mode ultrasound videos with combined B-Mode and Elastography or when re-testing B-Mode videos (Table 1).

Prediction of Correct Diagnosis

Compared to B-Mode ultrasound, diagnosis improved in 7 out of 20 trainees using combined B-Mode and elastography; in 9 out of 20 trainees on re-testing B-Mode ultrasound and in 17 out of 20 trainees using fusion elastography (Fig 2). Logistic regression analysis (Table 3) showed that independent predictors of correct diagnosis were fusion elastography OR (95%CI) 1.77 (1.39 – 2.25), $P < 0.001$, right side of cadavers OR (95%CI) 1.37 (1.36 – 1.64), $P < 0.001$, and choosing extraneural injection OR (95%CI) 3.15 (2.64 – 3.77), $P < 0.001$.

Cross-Sectional Area

Geometric mean cross-sectional area differed between modes of imaging ($P < 0.001$). There was no difference in cross-sectional nerve area between extraneural and intraneural groups either before (geometric ratio 0.12 (95%CI: -0.35 – 0.58), $P = 0.99$) or after nerve block (geometric ratio 0.35 (95%CI: -0.11 – 0.82), $P = 0.27$), Fig 4(A).

Intraneural injection was associated with a reduction in tissue displacement on the elastogram geometric ratio 0.48 (95%CI: 0.02 - 0.95), $P = 0.04$, but not on the fusion elastogram, geometric ratio 0.27 (95%CI: 0.19 – 0.74), $P = 0.62$, Fig 4(A).

Cross-sectional nerve area did not change in response to intraneural injection of 0.25ml, 0.5ml or 1ml volumes, (1ml vs 0.25ml geometric ratio 0.01 (-0.48 – 0.49), $P = 1.0$), Fig 4(B). Extraneural injection of 0.25ml, 0.5ml and 1ml volumes showed a dose response (1ml vs 0.5ml geometric ratio 0.22 (-0.36 – 0.81), $P = 0.84$; 1ml vs 0.25ml geometric ratio 0.47 (-0.11 – 1.06), $P = 0.17$).

Brightness

Geometric mean brightness differed between modes of imaging, $P < 0.001$, intraneural and extraneural injection $P < 0.001$ and volume, $P = 0.005$.

There was no difference in brightness between extraneural and intraneural groups either before (geometric ratio 0.07 (95%CI: -0.10 – 0.24), $P = 0.91$) or after nerve block (geometric ratio 0.05 (95%CI: -0.10 – 0.21), $P = 0.96$). Intraneural injection was associated with an increase in nerve brightness using fusion elastography geometric ratio 0.33 (95%CI: 0.16 - 0.49), $P < 0.001$, Fig 4C.

Reliability

Fusion elastography was associated with an improvement in diagnostic reliability, Kappa 0.60. Expert diagnosis concorded exactly, Kappa 1.0. Taking confidence levels into account, expert concordance was Kappa 0.80 (95%CI: 0.68 – 0.92).

Trainee Feedback

Trainees had greater confidence diagnosing individual images using fusion elastography OR (95%CI) 1.89 (1.69 – 2.11), $P < 0.001$ (Table 1). Four trainees thought images were very realistic, 14 thought images were realistic, 1 neither realistic or unrealistic and 1 unrealistic. Reflecting overall on the study, trainees were more confident using fused elastography than B-Mode ultrasound, $P < 0.001$ or elastography, $P < 0.001$.

Discussion

Our study showed that trainee diagnosis of intraneural injection was better using fused B-Mode and elastography videos compared to separate, adjacent B-Mode and elastography videos or B-Mode videos. The likelihood of correctly diagnosing intraneural injection using fusion elastography was almost twice that of other imaging modalities. Fusion elastography was associated with greater trainee confidence and improved diagnostic reliability. Diagnostic success was not improved by retesting trainees with B-Mode videos.

Strengths of study

The strength of this study was that we enhanced the functionality of proprietary elastography then translated it as a simulator of intraneural injection. Early identification of intraneural injection allows anaesthetists to withdraw the needle, reposition it outwith the epineurium, reducing the potential for nerve damage. Although historical reports suggest no adverse clinical outcome secondary to subepineural injection^{25 26}, recent data¹⁰⁻¹² describe nerve inflammation, intraneural hematoma,

fascicle damage and reduction in compound muscle action potential amplitudes secondary to needle trauma in animals. Thus, our teaching innovation also has the potential with development to improve patient safety by acting as an early warning system.

Trainee diagnosis was improved, notably, by both reducing the proportion of false negative and false positive results. Nevertheless, there remained a tendency, similar to the results of Krediet et al²⁷, for trainee anaesthetists to over-diagnose extraneural injection one third more often than intraneural injection when using B-Mode ultrasound. We have no indication from our results why this should be so as there was no disagreement between experts, and volume of injectate and grade of anaesthetist had no effect on the results. One surprising result was the improved odds of obtaining the correct diagnosis when examining videos from the right side of the cadaver. We have difficulty accounting for this result as B-Mode images from the left and right arms were similar. The shape of extraneural strain patterns is much more variable than intraneural strain patterns and our result may reflect small differences in needle tip position and pathways of least resistance within local anatomy.

Our previous work^{23 24} demonstrated the feasibility of elastography as an adjunct to B-Mode ultrasound during UGRA by demonstrating distinctive, colour patterns around nerves. Exact needle tip position, volume and rate of injection, tissue elasticity, and probe compression are all likely to alter the ebbing and flowing of fluid within connective tissue spaces and, thus, elastogram patterns tend to differ in size and shape between patients. Our study confirmed this observation and showed that using 1ml test doses, extraneural fusion elastogram area was approximately 33% greater than intraneural fusion elastogram area. We are confident that a such a difference would be readily perceived by anaesthetists routinely using 1ml test doses.

In marked contrast, intraneural injection in our study was characterised by similar cross-sectional

areas using B-Mode, elastography and fusion elastography imaging modalities and 0.25ml, 0.5ml and 1ml volumes (Fig 3), and a brighter focused targeting of intraneural injection using fusion elastography. Intraneural injection was brighter (Fig 3) because the brightness of the mixed echogenic nerve enhanced the brightness of the overlying strain pattern. In contrast, extraneural injection was duller because the strain pattern was superimposed on relatively hypoechoic muscle.

We hypothesize that nerve expansion was limited by stiff epineurium, and local anaesthetic spread both radially and longitudinally within the nerve taking the path of least resistance. Maximum nerve cross sectional nerve area was 35% greater with intraneural injection compared to extraneural injection, equivalent to a 650µm increase in nerve diameter within a hypothetical 4mm wide round nerve (Appendix).

This study was made possible by the physical and functional properties of the soft embalmed cadaver²⁸. Cadavers are embalmed for 4 to 6 months within a vat containing an antiseptic mixture of glycols, nitrates and acids. Cadavers are life-like, have full movement of joints, and may be used for 3 years. Skin and tissue are soft and moist, providing good conditions for ultrasound, and fascial integrity is retained, giving feedback during needle insertion.

Weaknesses of study

A criticism of our study was that we failed to confirm intraneural injection using injection of dye and anatomical dissection. Both experts have a great deal of experience of elastography and concurred with all diagnoses. Nevertheless, we are aware that consultants without elastography experience would not attain such accuracy and that a learning curve is necessary. Although diagnostic sensitivity of intraneural diagnosis improved by one fifth, our test result cannot be regarded as sufficient to apply as yet to clinical practice. Another criticism is that we asked trainees to interpret videos without the benefit of haptic feedback. The sensation of touch conveyed from the tip of the needle aids interpretation and enhances learning during UGRA. Our intention is to incorporate the simulation of intraneural injection into our training courses using the soft embalmed cadaver in

order that competency is achieved both in nerve block and the early recognition of intraneural injection.

Meaning of the study

Real-time detection of intraneural injection remains a challenge in clinical practice because ultrasound equipment and operators lack sufficient confidence and accuracy. Increase in clinical morbidity such as obesity, diabetes obese and ageing-related chronic illness will increase the need for UGRA but, as such, will become be technically more difficult. We have shown that fusion elastography may be a valuable diagnostic training aid and, indicated that it has the potential for further development as a visible warning signal that may prevent further harm. Development of an accurate and reliable detector of intraneural injection will probably require a computing solution such as machine learning in order to extract and analyse image data. The advantage of using computers is that diagnosis would be instant, and visualised or heard as an alarm, and algorithms would automatically improve with increased use.

Funding Nil

Declaration of Interests. Professor McLeod and Dr Columb are members of the associate editorial board of the British Journal of Anaesthesia. Dr Columb is statistical advisor to the British Journal of Anaesthesia.

References

1. Neal JM, Wedel DJ. Ultrasound guidance and peripheral nerve injury: is our vision as sharp as we think it is? *Reg Anesth Pain Med* 2010; **35**:335-337
2. Liu SS, YaDeau JT, Shaw PM, Wilfred S, Shetty T, Gordon M. Incidence of unintentional intraneural injection and postoperative neurological complications with ultrasound-guided interscalene and supraclavicular nerve blocks. *Anaesthesia* 2011; **66**:168-74
3. Hara K, Sakura S, Yokokawa N, Tadenuma S. Incidence and effects of unintentional intraneural injection during ultrasound-guided subgluteal sciatic nerve block. *Reg Anesth Pain Med* 2012; **37**:289-293
4. Borgeat A, Ekatodramis G, Kalberer F, Benz C. Acute and nonacute complications associated

- with interscalene block and shoulder surgery. A prospective study. *Anesthesiology* 2001; **95**: 875-880
5. Brull R, McCartney CJ, Chan VW, El-Beheiry H. Neurological complications after regional anaesthesia: contemporary estimates of risk. *Anesth Analg* 2007; **104**:965-974
 6. Liu SS, Zayas VM, Gordon MA, Beathe JC, Maalouf DB, Paroli L, Liguori GA, Ortiz J, Buschiazio V, Ngeow J, Shetty T, Ya Deau JT. A prospective, randomise, controlled trial comparing ultrasound versus nerve stimulator guidance for interscalene block for ambulatory should surgery for postoperative neurological symptoms. *Anesth Analg* 2009; **109**:265-71
 7. Fredrickson MJ, Kilfoyle DH. Neurological complication analysis of 1000 ultrasound guided peripheral nerve blocks for elective orthopaedic surgery: a prospective study. *Anaesthesia* 2009; **64**:836-44
 8. Barrington M, Watts SA, Gledhill SR, Thomas RD, Said SA, Snyder GL, Tay VS, Jamrozik K. Preliminary Results of the Australasian Regional Anaesthesia Collaboration. A Prospective Audit of More Than 7000 Peripheral Nerve and Plexus Blocks for Neurologic and Other Complications. *Reg Anesth Pain Med* 2009; **34**:534-541
 9. Hogan QH. Pathophysiology of peripheral nerve injury during regional anesthesia. *Reg Anesth Pain Med* 2008; **33**: 435-41
 10. Steinfeldt T, Nimphius W, Werner T, Vassiliou T, Kill C, Karakas E, Wulf H, Graf J. Nerve injury by needle nerve perforation in regional anaesthesia: does size matter? *Br J Anaesth* 2010; **104**:245-53
 11. Steinfeldt T, Wiesmann T, Nimphius W, Cornelius V, Eismann D, Kratz T, Hadzic A, Wulf H, Werner T. Perineural hematoma may result in nerve inflammation and myelin damage. *Reg Anesth Pain Med* 2014; **39**:513-9
 12. Steinfeldt T, Poeschl S, Nimphius W, Graf J, Zoremba M, Mueller H-H, Wulf H, Dette F. Forced needle advancement during needle-nerve contact in a porcine model. *Anesth Analg* 2011; **113**:417-20
 13. Barrington MJ, Wong DM, Slater B, Ivanusic JJ, Ovens M. Ultrasound-guided regional anaesthesia: how much practice do novices require before achieving competency in ultrasound needle visualization using a cadaver model. *Reg Anesth Pain Med* 2012; **37**:334-349
 14. Wells PN, Liang HD. Medical ultrasound: imaging of soft tissue strain and elasticity. *J R Soc Interface* 2011; **8**: 1521-1549.
 15. Diagnostic Ultrasound: Physics and Equipment 2nd edition Editors: Hoskins P, Martin K, Thrush A. Cambridge University Press, 2003
 16. Munirama S, McLeod G. A systematic review and meta-analysis of ultrasound versus electrical stimulation for peripheral nerve location and blockade. *Anaesthesia* 2015; **70**: 1084-91
 17. Tsai TP, Vuckovic I, Dilberovic F. Intensity of the stimulating current may not be a reliable indicator of intraneural needle placement. *Reg Anesth Pain Med* 2008; **33**:207-210
 18. Wiesmann T, Bornträger A, Vassiliou T, Hadzic A, Wulf H, Müller HH, Steinfeldt T. Minimal current intensity to elicit an evoked motor response cannot discern between needle-nerve contact and an intraneural needle insertion. *Anesth Analg* 2014; **118**:681-6
 19. Gadsden JC, Latmore M, Levine D, Robinson A. Opening injection pressure consistently detects needle-nerve contact during ultrasound-guided interscalene brachial plexus block. *Anesthesiology* 2014; **120**:1246-1253

20. Gadsden JC, Choi JJ, Lin E, Robinson A. High Opening Injection Pressure Is Associated With Needle-Nerve and Needle-Fascia Contact During Femoral Nerve Block *Reg Anesth Pain Med* 2016; **41**:50-55
21. Ophir J, Céspedes I, Ponnekanti H, Yazdi Y, Li X. Elastography: a quantitative method for imaging the elasticity of biological tissues. *Ultrason Imaging* 1991; **13**:111-34
22. Garra BS. Imaging and estimation of tissue elasticity by ultrasound. *Ultrasound Q* 2007; **23**:255-68
23. Munirama S, McLeod GA, Eisma R, Schwab A, Corner G, Soames R, Cochran S. Application of sonoelastography to regional anaesthesia: a descriptive study with the Thiel embalmed cadaver model. *Ultrasound* 2012; **20**:41-48
24. Munirama S, Satapathy AR, Eisma R, Schwab A, Corner G, Cochran S, McLeod GA. Translation of sonoelastography from Thiel cadaver to patients for peripheral nerve blocks. *Anaesthesia*. 2012; **67**:721-8
25. Bigeleisen PE. Nerve puncture and apparent intraneural injection during ultrasound-guided axillary block does not invariably result in neurologic injury. *Anesthesiology* 2006; **105**:779-83.
26. Sala Blanch X, López AM, Carazo J, Hadzic A, Carrera A, Pomés J, Valls-Solé J. Intraneural injection during nerve stimulator-guided sciatic nerve block at the popliteal fossa. *Br J Anaesth* 2009; **102**:855-61.
27. Krediet AC, Moayeri N, Bleys RL, Groen GJ. Intraneural or extraneural: diagnostic accuracy of ultrasound assessment for localizing low-volume injection. *Reg Anesth Pain Med* 2014; **39**:409-13.
28. Eisma R, Wilkinson T. From silent teachers to models. *PLoS Biol* 2014; **12**: e1001971.

Shilpa Munirama devised the concept, conducted the anatomy study and wrote the paper

Kate Zealley conducted the trainee study

Andreas Schwab wrote the MATLAB software, combined the videos and helped conduct the anatomy study

Malachy Columb conducted the statistical analysis

George A Corner provided Medical Physics technical support

Roos Eisma chose and prepared the cadavers

Graeme A McLeod devised the concept, coordinated the study and wrote the paper

Table 1 Diagnosis of intraneural injection. B-Mode ultrasound, the combination of B-Mode and Elastography, Fusion elastography and B-Mode (re-test) ultrasound. Positive likelihood ratio (LR+) = sensitivity/(1-specificity) Negative likelihood ratio (LR-) = (1-sensitivity)/specificity. Diagnostic Odds Ratio = LR+/LR-. Concordance between raters expressed as Kappa.

Table 2 Univariate and multivariate analysis. Outcome = correct diagnosis. Independent predictors of correct diagnosis were fusion elastography, injection on the right side of the cadavers and choosing extraneural injection as the diagnosis.

	Sensitivity (%)	Specificity (%)	PPV+	PPV-	LR (+) (95%CI)	LR (-) (95%CI)	Kappa (95%CI)	Odds Ratio (95%CI)	Diagnostic Odds Ratio (95%CI)	P-value
B-Mode	59.6 (54.8 - 64.2)	83.4 (79.2 - 87.1)	81.3 (76.6 - 85.4)	63.1 (58.6 - 67.4)	3.60 (2.83 - 4.60)	0.48 (0.43 - 0.55)	0.42 (0.36 - 0.48)	Reference	7.4 (5.2 - 10.6)	
B-Mode + Elastography	55.1 (50.3 - 59.7)	81.1 (76.7 - 85.1)	78.5 (73.6 - 83.0)	59.0 (54.5 - 63.4)	2.92 (2.33 - 3.69)	0.55 (0.49 - 0.62)	0.35 (0.29 - 0.41)	0.83 (0.67 - 1.04)	5.3 (3.8 - 7.4)	0.10
B-Mode (re-test)	63.8 (59.1 - 68.3)	81.0 (76.6 - 84.9)	80.1 (75.5 - 84.2)	65.0 (60.5 - 69.4)	3.35 (2.70 - 4.21)	0.45 (0.39 - 0.51)	0.45 (0.39 - 0.51)	1.07 (0.85 - 1.33)	7.5 (5.3 - 10.6)	0.57
Fusion Elastography	72.1 (67.7 - 76.3)	89.4 (85.8 - 92.4)	89.3 (85.6 - 92.3)	72.3 (67.9 - 76.4)	6.81 (5.04 - 9.28)	0.31 (0.27 - 0.36)	0.60 (0.55 - 0.66)	1.70 (1.35 - 2.15)	21.7 (14.5 - 33.3)	<0.001

Covariate	Univariate analysis		Multivariate analysis	
	Odds Ratio (95%CI)	P-value	Odds Ratio (95%CI)	P-value
Actual diagnosis				
Intraneural	-----			
Extraneural	3.17 (2.66 – 3.79)	<0.001	3.15 (2.64 – 3.77)	<0.001
Training year				
2	-----			
3	0.78 (0.50 – 1.20)	0.27		
4	0.74 (0.42 – 1.33)	0.35		
5	0.83 (0.36 – 1.90)	0.78		
6	0.96 (0.50 – 1.85)	1.00		
8	2.00 (0.57 – 7.21)	0.34		
Cadaver				
1	-----			
2	0.94 (0.89 – 0.99)	0.01		
Side				
Left	-----			
Right	1.50 (1.31 – 1.72)	<0.001	1.37 (1.36 – 1.64)	<0.001
Volume				
0.25 – 1ml	0.96 (0.74 – 1.23)	0.72		
Trainee confidence				
1 – 3	1.89 (1.69 – 2.11)	<0.001		
Imaging mode				
B-Mode	-----			
B-Mode + elastography	0.83 (0.67 – 1.04)	0.10	1.00 (0.69 – 1.46)	0.99
B-Mode re-test	1.07 (0.85 – 1.33)	0.57	1.05 (0.82 – 1.34)	0.70
Fusion	1.70 (1.35 – 2.15)	<0.001	1.77 (1.39 – 2.25)	<0.001

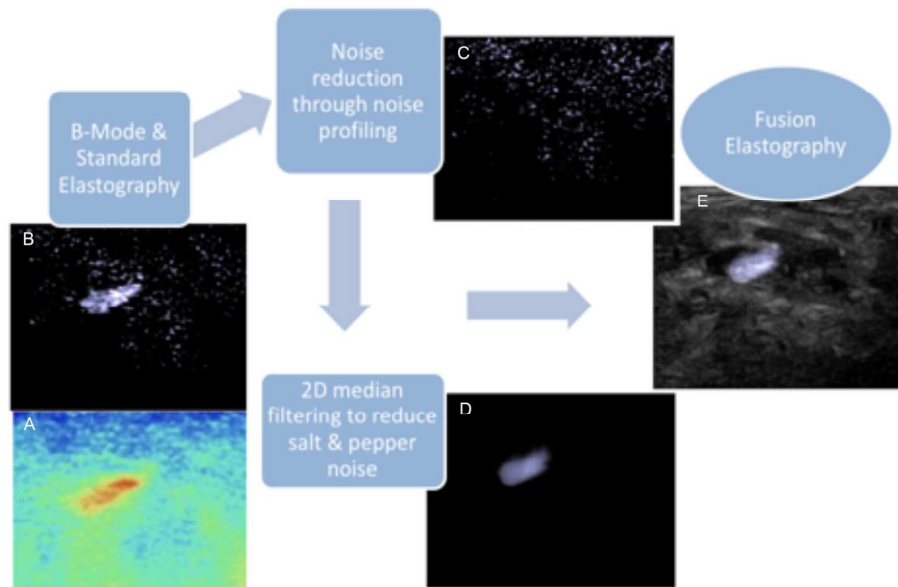


Fig 1. Software engineering of ultrasound guided regional anaesthesia videos. Image shows typical B-Mode image (A) and colour elastogram (B) on left. Images converted to 8-bit grayscale and ultrasound background "noise" reduced using noise profiling procedures (C) and 2D median filter. Brightness thresholds chosen between 0 and 255 on an 8-bit grayscale map for each block in order to create a white image replicating the shape of the elastogram strain pattern on a black background. White, ebbing and flowing area termed enhanced elastography (D). Superimposed onto B-Mode image (E). Visualised as a translucent white "ghost" like shadow in order that the underlying nerve could be visualised underneath. This image (E) was termed fusion elastography

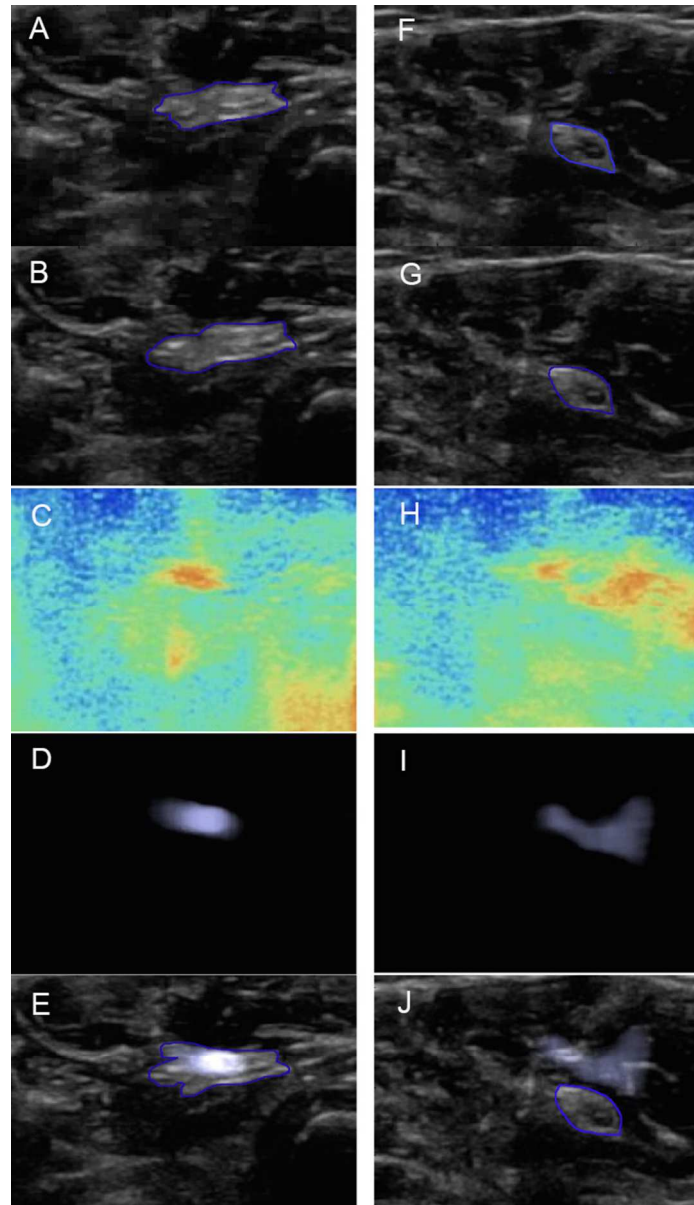


Fig 2. Pre-injection B-Mode, post-injection B-Mode, standard elastography, enhanced elastography and fusion elastography images captured from video of median nerve block within soft embalmed Thiel cadaver. The edge of the median nerve is highlighted in blue. Left hand column (A – E) shows typical response to intraneural injection. Image A shows a median nerve with typical mixed echogenicity. Image B shows expansion and reduced echogenicity of the same median nerve in response to 0.5ml injection. The elastogram, image C, shows a small, linear red and yellow pattern. The enhanced elastogram image D, is the black and white conversion of image C, and shows a round white object 5mm in diameter and the same, object transposed onto the median nerve onto the fusion elastogram, image E. Note the object is transparent and brighter on image E. The right hand column shows response to extraneural injection (F – J). The perineural elastogram displacement is greater in images H and I compared to the intraneural displacement in images C and D.

