



University of Dundee

Microultrasound and small bowel inflammation

Cox, Benjamin F.; Seetohul, Vipin; Lay, Holly; Cochran, Sandy

Published in:
2015 IEEE International Ultrasonics Symposium, IUS 2015

DOI:
[10.1109/ULTSYM.2015.0304](https://doi.org/10.1109/ULTSYM.2015.0304)

Publication date:
2015

Document Version
Peer reviewed version

[Link to publication in Discovery Research Portal](#)

Citation for published version (APA):
Cox, B. F., Seetohul, V., Lay, H., & Cochran, S. (2015). Microultrasound and small bowel inflammation: Tissue phantom studies. In 2015 IEEE International Ultrasonics Symposium, IUS 2015. [7329307] Institute of Electrical and Electronics Engineers. DOI: 10.1109/ULTSYM.2015.0304

General rights

Copyright and moral rights for the publications made accessible in Discovery Research Portal are retained by the authors and/or other copyright owners and it is a condition of accessing publications that users recognise and abide by the legal requirements associated with these rights.

- Users may download and print one copy of any publication from Discovery Research Portal for the purpose of private study or research.
- You may not further distribute the material or use it for any profit-making activity or commercial gain.
- You may freely distribute the URL identifying the publication in the public portal.

Take down policy

If you believe that this document breaches copyright please contact us providing details, and we will remove access to the work immediately and investigate your claim.

Microultrasound and Small Bowel Inflammation: Tissue Phantom Studies

Benjamin F Cox
School of Medicine
University of Dundee
Dundee, UK
Bcox@dundee.ac.uk

Vipin Seetohul, Holly Lay, Sandy Cochran
School of Engineering
University of Glasgow
Glasgow, UK
Sandy.Cochran@glasgow.ac.uk

Abstract—Capsule endoscopy represents a highly convenient but limited means of imaging inflammatory conditions of the small bowel. The inclusion of high frequency microultrasound into a capsule endoscope has the potential to enhance diagnostic capabilities with subsurface imaging of the bowel wall. Experimental studies on abattoir-obtained porcine small bowel have been carried out as an ethical means to characterize healthy and altered tissue in a preclinical setting as well as to explore other means of imaging pathology. Samples of small bowel were cannulated and perfused with phosphate buffered saline followed by variable dilutions of polystyrene microspheres. All samples were scanned with a purpose built step scanner employing a 47 MHz single element transducer. Results indicated that tissue high frequency ultrasound demonstrated sufficient sensitivity to detect the disruption normal histology with microsphere infusion. The combination of microultrasound and capsule endoscopy has the potential to enhance the diagnostic capabilities with improved qualitative and quantitative dimensions.

Keywords—Small Bowel; Inflammation; Leukocytes; Microultrasound; Capsule Endoscopy

I. INTRODUCTION

Inflammatory small bowel conditions such as Crohn's disease and Celiac disease represent commonly encountered gastrointestinal disorders that significantly impact on the health and well-being of patients. Diagnosis and management often require imaging techniques ranging from CT and MRI to endoscopic methods. Video capsule endoscopy (VCE) has been indicated in the management of both conditions because of its ease of use and patient acceptance as compared to standard endoscopy [1]. However, despite wide acceptance there are a number of shortcomings associated with its use.

A salient limitation of VCE is the restricted imaging capability which presents a view of the surface mucosa only,

without the benefit of transmural penetration into the depth of the tissue. This reduces sensitivity as diagnosis is dependent on optical manifestations of disease which are generally associated with later (i.e. overt) stages. Furthermore, differentiation between disorders with similar visual appearance and assessment of submucosal disease are difficult. The latter point is particularly important when assessing Crohn's disease for an acute flare, as it manifests itself as a transmural disease [2].

The authors aim to address this deficiency by developing Ultrasound Capsule Endoscopy (USCE) that will allow full thickness ultrasound imaging of the bowel wall. Specifically work is under way to utilize microultrasound (μ US) to provide a high resolution image of the walls of the bowel for improved diagnosis and management of gastrointestinal disorders.

μ US refers to frequencies typically a minimum factor of 1.5 times higher than the conventional clinical maximum of 20 MHz [3]. μ US has already demonstrated its ability to characterize gastrointestinal (GI) tissue with a high degree of correspondence to histological analysis [4, 5] (Fig. 1). Part of this high fidelity correlation between μ US imaging and histology is inherent in the ability of high frequency US to provide high resolution images, at micrometer resolution. However, this ability is balanced by a decreasing depth of tissue penetration with increasing frequency because of increased interaction of the ultrasound with tissue microstructures, with subsequent energy loss to scattering and absorption.

This paper describes experimental work in determining the suitability of μ US for the detection and characterization specifically of inflammatory bowel conditions. Our objective is to characterize healthy and altered small bowel tissue *ex vivo* with a mechanically scanned single-element high frequency ultrasound transducer.

This work is supported by the UK Engineering and Physical Sciences Research Council under its Sonopill programme (EP/K034537)

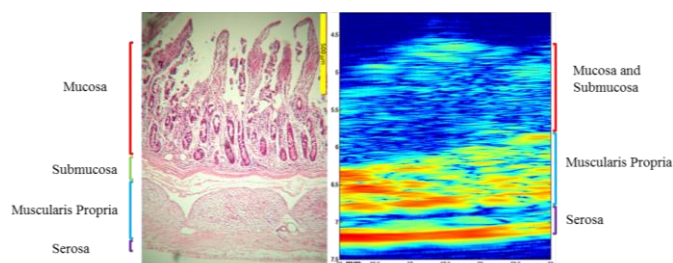


Figure 1. Haematoxylin and Eosin (H&E) porcine small bowel slide (4x magnification)(left) and cropped section (56-59 mm) of a 47 MHz μ US scan (right) for comparison. The μ US image demonstrates good correlation with the H&E slide. Despite employing perfusion fixation techniques, formalin use resulted in tissue shrinkage due to protein cross linking. Clear separation between the mucosa (m) and submucosa (sm) is not apparent in the μ US scan. However, from a quantitative aspect interstitial infiltration has the potential to change the acoustic properties of the m/sm and attenuate the muscularis propria (mp) signal. Properties to be examined include acoustic impedance, attenuation and backscatter. X and Y scales are in millimeters.

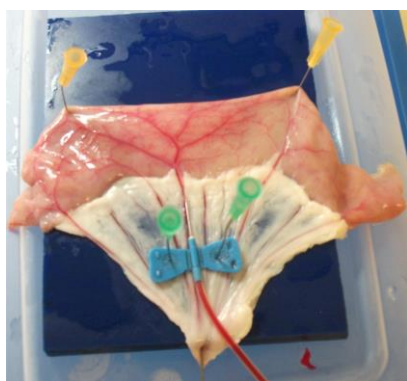


Figure 2. Successful cannulation of a mesenteric vessel. This allows perfusion of the bowel section with degassed phosphate buffered saline (dPBS) and microspheres to mimic leukocyte infiltration.

II. MATERIALS AND METHODS

A. Materials

Porcine small bowel samples were obtained from an abattoir (Medical Meat Supplies, Rochdale, UK). Individual porcine bowel sections measuring 15 - 20 cm in length were obtained with attached mesentery and mesenteric vessels. Samples were individually vacuum packed and frozen prior to delivery.

Prior to each experiment an individual section was thawed with a running cold water bath whilst still vacuum packed. The thawed tissue lumen was rinsed with tap water. Next, the tissue was pinned using Microlances (Becton Dickinson, Oxford, UK) and a mesenteric vessel was cannulated with a

Table 1. Microsphere Dilution and Infusion Rates

Sample Date and Number	Fluoresbrite™ Multifluorescent 1.0 micron Microspheres (Manufacturer Concentration 4.55×10^{10} particles/ml)	
	Microsphere Dilution	Volumes and Rates
01OCT1501	1:10 Microspheres to dPSB	30 ml dPSB 200 ml/hr 10 ml Spheres + dPSB 200 ml/hr 10 ml dPSB 200 ml/hr
01OCT1502	1:20 Microspheres to dPSB	30 ml dPSB 200 ml/hr 10 ml Spheres + dPSB 200 ml/hr 10 ml dPSB 200 ml/hr
02OCT1501	1:20 Microspheres to dPSB	30 ml dPSB 200 ml/hr 8 ml Spheres + dPSB 100 ml/hr 10 ml dPSB 200 ml/hr
02OCT1502	1:30 Microspheres to dPSB	30 ml dPSB 200 ml/hr 10 ml Spheres + dPSB 100 ml/hr 10 ml dPSB 200 ml/hr
02OCT1503	1:30 Microspheres to dPSB	30 ml dPSB 200 ml/hr 10 ml Spheres + dPSB 50 ml/hr 10 ml dPSB 200 ml/hr

23G Butterfly Winged Infusion Set (Hospira, Warwickshire, UK). Successful cannulation was checked by infusing approximately 1 - 2 ml red dyed fluid. Cannulation was considered successful when the dye would track through the bowel vasculature (Figure 2). After the vessel patency check, the infusion tubing was connected to a B.Braun Perfusor pump (B.Braun, Sheffield, UK). The pump is equipped with a pressure alarm that halts perfusion if pressure rises above 9 mmHg, thus avoiding potential tissue damage. Post perfusion, the tissue was cut along the upper edge where the mesentery inserts into the bowel. This allowed for μ US scanning across the short axis of the bowel. It should be noted that the tissue was assumed pathology free as it was collected from animals for consumption.

The purpose of perfusion was to return the tissue to near physiologic conditions and rehydrate, to improve signal clarity of the respective histological layers, and to allow the infusion of microspheres to mimic leukocyte infiltration. Samples were perfused with 50 ml degassed phosphate buffered saline (dPBS) in total. A 10x strength PBS solution (Fisher Scientific, Loughborough, UK) was mixed with deionized water and boiled for 3 minutes to ensure thorough degassing. The solution was then allowed to cool to room temperature.

Baseline samples were perfused with 50 ml dPBS at 200 ml/hr. Infusion of 1 μ m diameter fluorescent microspheres (Polysciences Inc, PA, USA) was achieved with an initial 30 ml volume at 200 ml/hr followed by a 10 ml dPBS solution of variable dilution microspheres at variable perfusion rates to facilitate extravasation from capillary lumen to tissue interstitium (Table 1). Following the 10 ml microsphere infusion, 10 ml dPBS at 200 ml/hr was used to flush the line.

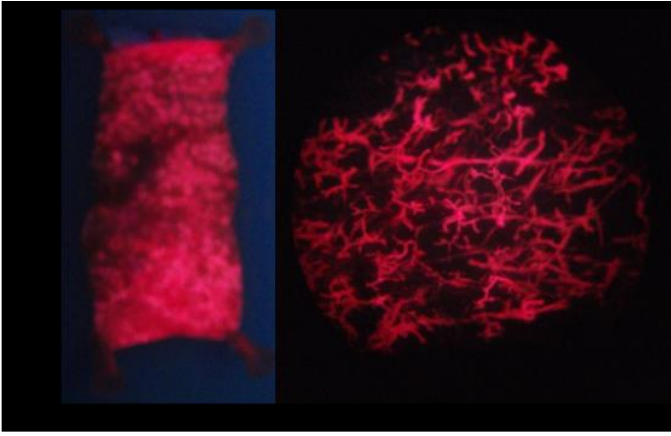


Figure 3. Fluorescently-illuminated camera image (left) post-perfusion of a 1:10 microsphere dilution. The image indicates satisfactory distribution of the microspheres within the tissue across the short axis of the bowel. Fluorescently-illuminated photomicrograph (40x magnification) (right) post 1:10 microsphere infusion. Image depicts a well maintained capillary structure with little to no extravasation of the spheres into the interstitium. Whilst this successfully alters the acoustic properties of the tissue, it does not faithfully reflect the nature of leukocyte interstitial infiltration during the process of inflammation.

Afterwards the sample was rinsed with dPBS to remove any accumulated mucous, debris and luminal microspheres. The tissue was checked with a handheld florescent lamp (UVP, Cambridge, UK) to ensure adequate microsphere infusion. This also allowed results to be checked microscopically using air-fixed slides with fluorescent illumination. The tissue was then moved to a μ US scanning chamber comprising an acoustic absorber covered with 2% agar (w/w) (Fisher Scientific, Loughborough, UK) in a 135 x 85 x 55 mm³ plastic tub. The agar was covered with 1 - 2 mm depth ultrasound coupling gel (Diagnostic Sonar Ltd, Livingston, UK) to ensure that the serosa was lifted from the agar, thus producing distinct acoustic signals. The samples were pinned using 4x 25G Microlances

(Becton Dickinson, UK) and submerged in dPBS to a level allowing sufficient depth for immersion of the front face of the μ US transducer. The transducer was then focused on the mucosa and/or submucosa of the tissue [6].

B. Scanner

Tissue scanning was performing using a custom built micro-stepped mechanical scanner. The scanning system consisted of a transducer stage stepped in 20 μ m increments along the short axis of the tissue. The ultrasound transducer was pulsed and receive echoes (P/R) were measured and amplified using a DPR500 (JSR Electronics, USA) the signals digitized using a 2.5 GS/s oscilloscope (MDO3014, Agilent Technologies, USA). Motor and electronic control of the system, as well as digital processing, was achieved through a custom LABVIEW program (National Instruments, UK).

The microultrasound transducer was a single-element, physically-focused piezo-composite with a centre frequency of 47 MHz and a bandwidth of 31% (AFM Ltd, UK). B-scan 2D image reconstruction was accomplished with MatLab (Mathworks, USA) using a Hilbert transform for envelope detection prior to log-compression. The log-compressed data

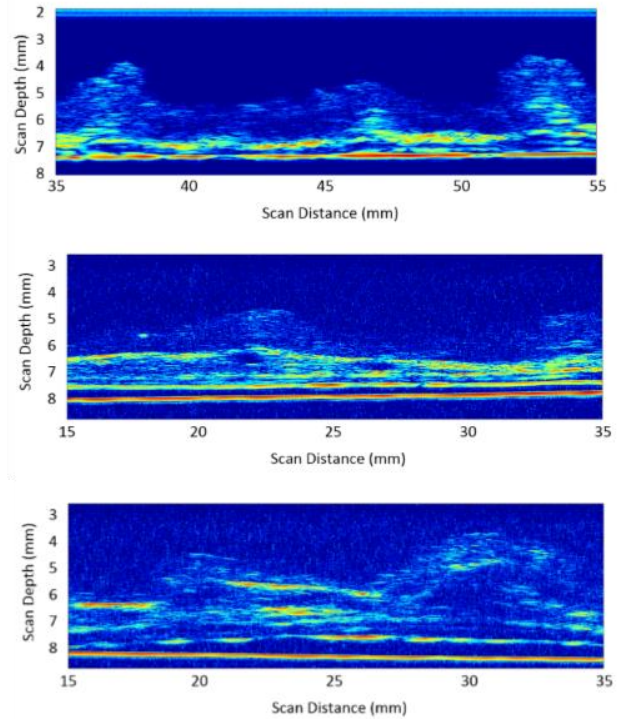


Figure 4. Microultrasound images of a baseline dPBS-only perfused tissue (top) plus 02OCT1502 scan (bottom) depicting an infusion of 1:30 microspheres at 100 ml/hr. The baseline image depicts subtle uppermost mucosal and submucosal signal with a deeper but more intense muscularis propria signal followed by a serosal signal. Microsphere infusion demonstrates interruption of the normal histologic arrangement as compared to the baseline scan, with changes to areas of intensity as opposed to the normal signal of the muscularis propria. All scans were performed with a 47 MHz single-element piezocomposite transducer.

was then mapped to a heat map for analysis, with red corresponding to high echoic areas and blue representing low echoic areas [6].

III. RESULTS

Examination of the microsphere infused tissue under fluorescent illumination indicated that satisfactory particle tissue distribution has been achieved (Figure 3). Microscopic examination of the air-fixed slides indicated that the majority of spheres remained intravascular as indicated by the excellent preservation of the capillary network (Figure 3). This would indicate that, even with prolonged absence of physiologic circulation, the tissue is able to maintain vascular integrity. Fluid perfusion resulted in adequate baseline tissue μ US imaging as indicated by separation of the distinct histological layers as shown in Figure 4. This baseline image was then used for comparison with the microsphere perfused tissue. Serial μ US scans of the variable concentration of the microspheres also indicate that they are capable of altering the acoustic property of tissue, resulting in a disrupted histological pattern as compared to baseline scans, Figure 4.

IV. CONCLUSIONS AND FUTURE WORK

Our experiments indicate that μ US demonstrates sufficient sensitivity in regards to imaging disruption of the normal histological architecture of the small bowel when infused with microspheres. Additionally we have demonstrated that the abattoir obtained porcine small bowel is appropriate for preclinical testing of high frequency μ US. Further investigation into leukocyte phantoms is warranted to better mimic the influx of leukocytes during inflammatory periods.

The use of ultrasound in the diagnosis and management of inflammatory bowel conditions is not novel. A number of researchers have used and advocated the use of transabdominal sonography (TABS) to image celiac disease [7 - 9], relying on standard frequencies in the range 5 - 12 MHz to image the bowel. However this practice relies on a collection of nonspecific findings such as bowel thickening, increased luminal fluid, mesenteric lymphadenopathy and enhanced peristalsis. Other difficulties include distinguishing adjacent bowel loops from lesions and body habitus preventing adequate visualization. Furthermore these signs, plus clinical correlation, only serve to heighten physician concern and prompt further testing.

Infiltration and accumulation of leukocytes in the interstitium of the bowel can be considered ideal in terms of detection with μ US. In principle, an increasing aggregation of lymphocytes will produce a new backscatter profile (i.e. echogenicity change due to increased lymphocyte scatterers) as compared with healthy tissue. In turn this will produce an altered mucosal image whilst simultaneously diminishing imaging of deeper structures due to increased interaction with leukocyte nuclei. This concept was explored by Sharma [10] to detect early precancerous changes associated with mutated adenomatous polyposis coli (Apc) in murine bowel models.

By combining the aforementioned principle with USCE, we will be able achieved direct bowel imaging producing high resolution imaging that relies on direct evidence of inflammation via interstitial lymphocyte infiltration that does not rely on nonspecific findings. Furthermore, direct bowel imaging will allow the development of objective imaging based on acoustic property changes that accompany pathologic changes. Quantitative ultrasound techniques that rely on the

effects of scatterers in addition to changes to impedance and attenuation will provide information independent of optical variables and provide clinicians with further diagnostic evidence.

ACKNOWLEDGMENTS

We extend our thanks to Robyn Duncan for the histology preparation and Thineskrishna Anbarasan for the baseline μ US scan.

REFERENCES

- [1] Mustafa BF, Samaan M, Langmead L, Khasraw M. Small bowel video capsule endoscopy: an overview. *Expert Rev Gastroenterol Hepatol*. 2013 May;7(4):323-9.
- [2] Rendi, M., Upton, M., Swanson, P.E., Yunes, M.,. (udated Sep 17 2015). *Crohn Disease Pathology*. Available: <http://emedicine.medscape.com/article/1986158-overview>. Last accessed 05OCT15.
- [3] Vogt M, Opretzka J, Perrey C, Ermert H.,. Ultrasonic microscanning. *Proceedings of the Institution of Mechanical Engineers, Part H: Journal of Engineering in Medicine*, 2010, 224(2), pp.225-240
- [4] Wiersema, M.J. & Wiersema, L.M.,. Ultrasonography of the gastrointestinal wall: histologic correlates. *Gastrointestinal Endoscopy*. 1993, pp.499-504.
- [5] Ødegaard S, Nesje LB, Lærum OD, Kimmey MB.,. High-frequency ultrasonographic imaging of the gastrointestinal wall. *Expert review of medical devices*. 2012 9(3), pp.263-73.
- [6] Thineskrishna Anbarasan, Christine E. M. Démoreé, Holly Lay, Mohammed R. S. Sunoqrot, Romans Poltarjonoks, Sandy Cochran, Benjamin F. Cox. Development of small bowel tissue phantom for microultrasound (μ US) investigation. Ed: Rasooly A., Pickril B., Biosensor Technologies. Springer, 2015. In Press.
- [7] Nylund, K.,. Sonography of the small intestine. *World Journal of Gastroenterology*. 2009 15(11), p.1319.
- [8] Fraquelli M, Colli A, Colucci A, Bardella MT, Trovato C, Pometta R, Pagliarulo M, Conte D. Accuracy of ultrasonography in predicting celiac disease. *Arch Intern Med*. 2004 Jan 26;164(2):169-74.
- [8] Bartusek D, Valek V, Husty J, Uteseny J. Small bowel ultrasound in patients with celiac disease. Retrospective study. *Eur J Radiol*. 2007 Aug;63(2):302-6.
- [9] S. Sharma, "Micro-Ultrasound Imaging of Tissue Dysplasia," Doctoral Thesis, University of Dundee, 2015.