

The use of needle guidance software within interventional radiology

DOBSON, Stephanie and HARCUS, James

Available from Sheffield Hallam University Research Archive (SHURA) at:

<http://shura.shu.ac.uk/12694/>

This document is the author deposited version. You are advised to consult the publisher's version if you wish to cite from it.

Published version

DOBSON, Stephanie and HARCUS, James (2016). The use of needle guidance software within interventional radiology. In: United Kingdom Radiological Congress, Liverpool, 6-8th June 2016. (Unpublished)

Copyright and re-use policy

See <http://shura.shu.ac.uk/information.html>

Stephanie Dobson – Aintree University Hospital
James Harcus – Sheffield Hallam University

Background

Advancements in the last decade have allowed for the commercialisation of Cone Beam CT (CBCT) imaging. CBCT provides 3D images which can be reconstructed into multi-planar images. (Angle, 2013) Needle guidance software combines 3D CBCT imaging with needle trajectory planning software and real time fluoroscopy imaging. The use of CBCT and needle guidance software can negate the use of the traditional CT fluoroscopy based examination.

How it works

A Cone Beam CT of the area under examination is performed. Needle guidance software then allows for accurate planning of needle guided interventional procedures. Whereby the operator plans out the needles path from the lesion to the proposed skin entry point, avoiding any vital anatomical structures. The imaging system then calculates the optimal imaging angulations (progression views), the 3D dataset and virtual trajectory are co-registered. This allows a needle path to be projected upon the 2D fluoroscopic image.

Procedures

Needle guidance software can be used for a variety of procedures including:

- Vertebroplasty
- Kyphoplasty
- Biopsies
- Drainages
- Injections
- Ablations

Fig 1: Entry point

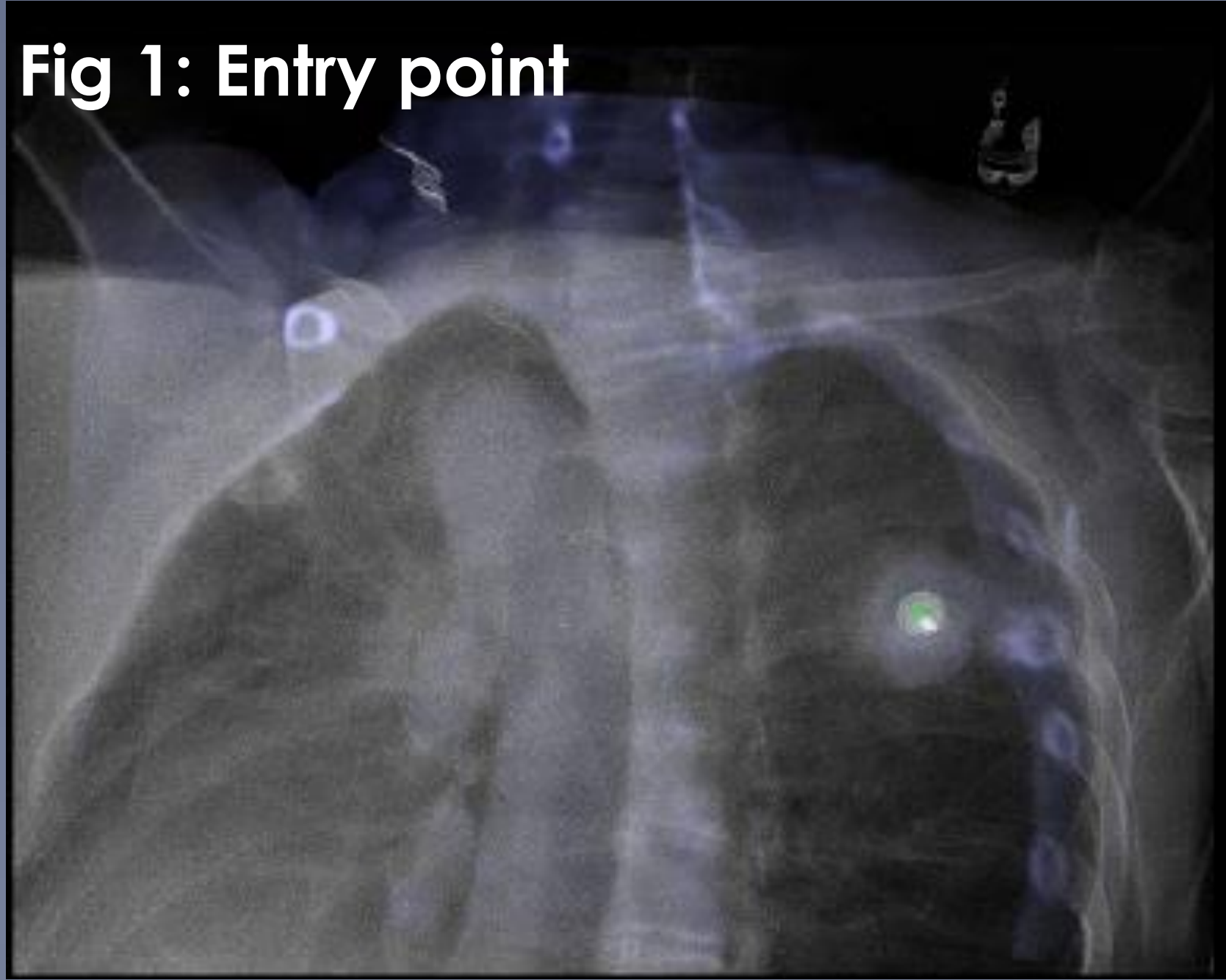
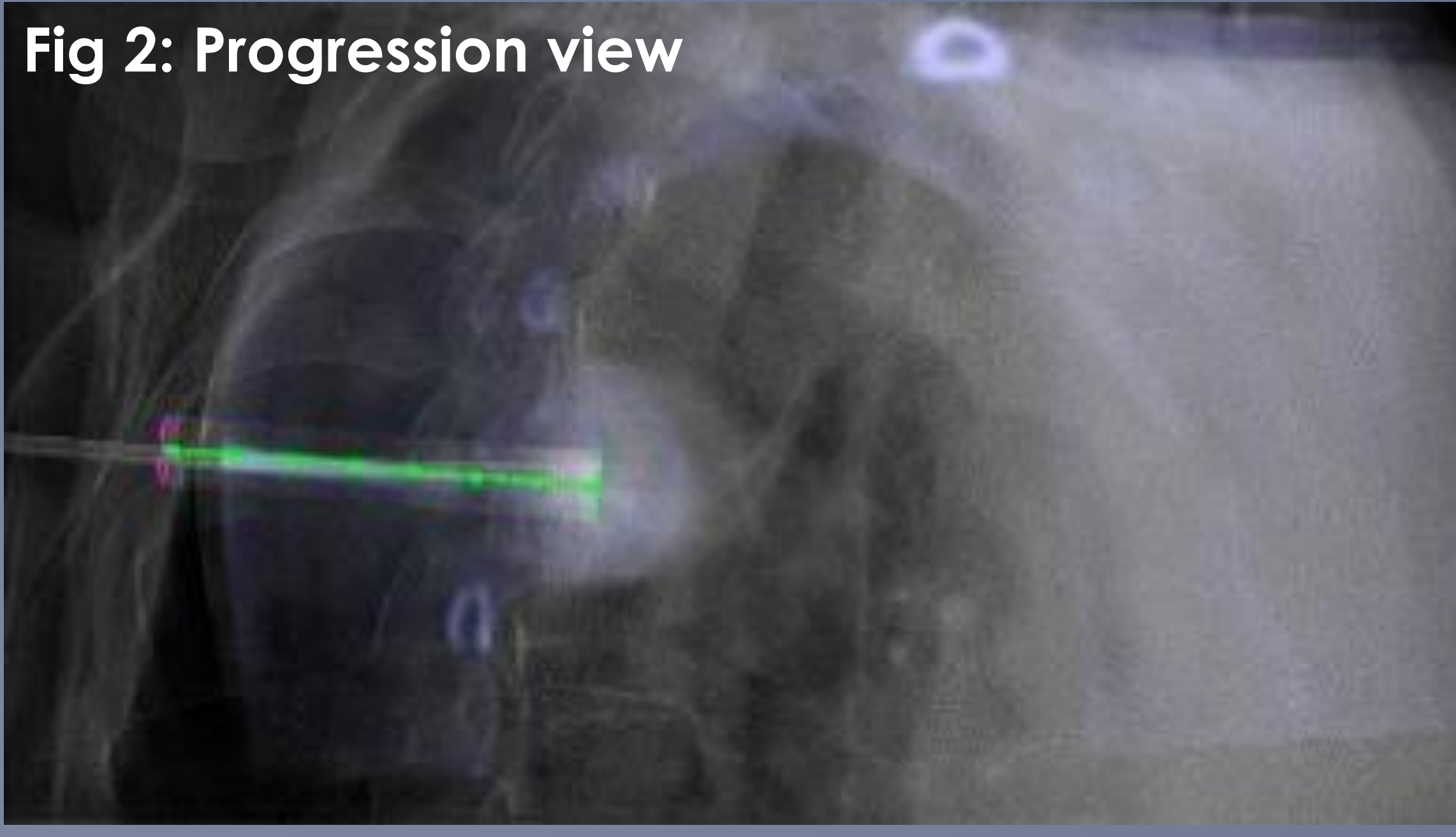


Fig 2: Progression view

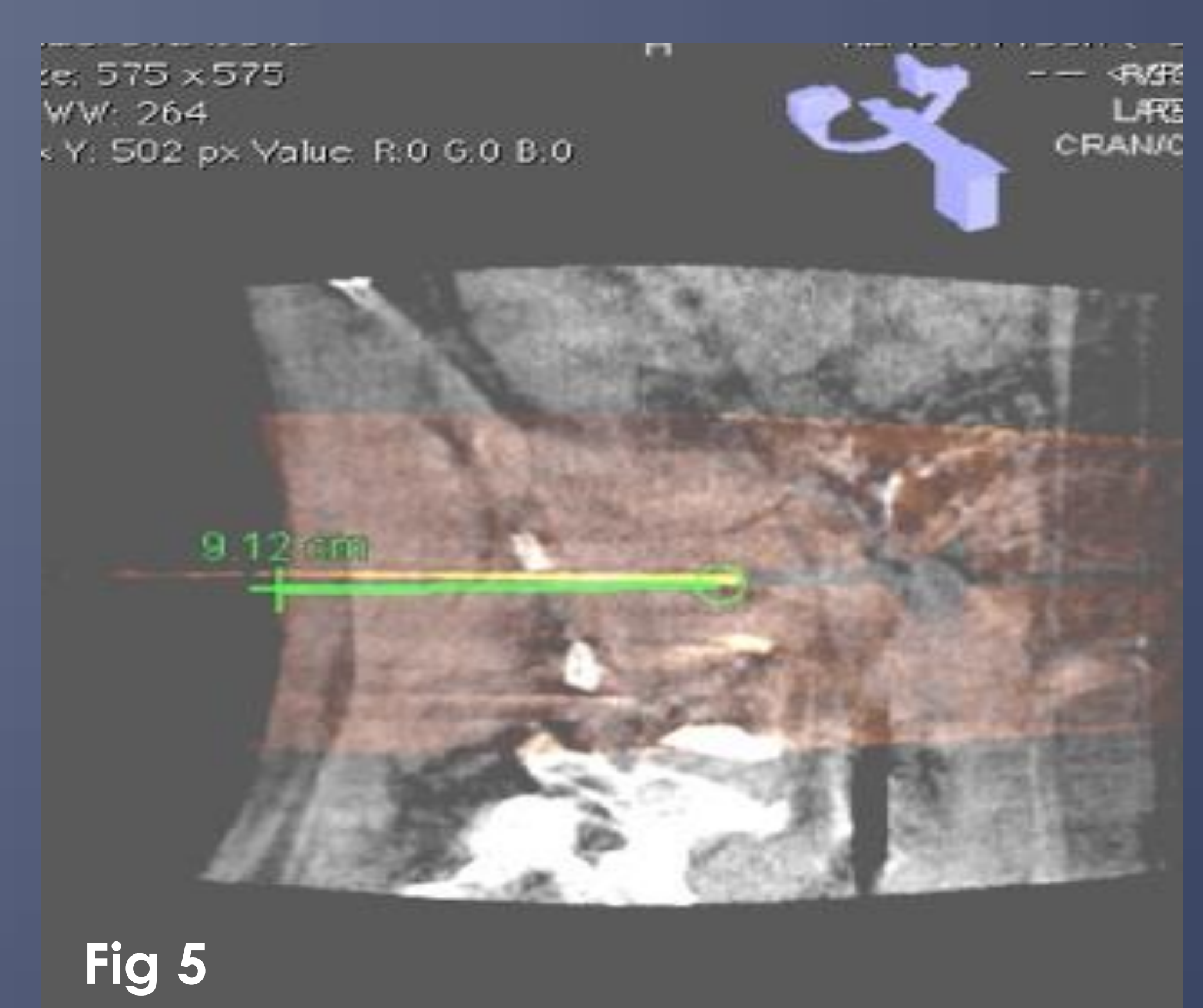
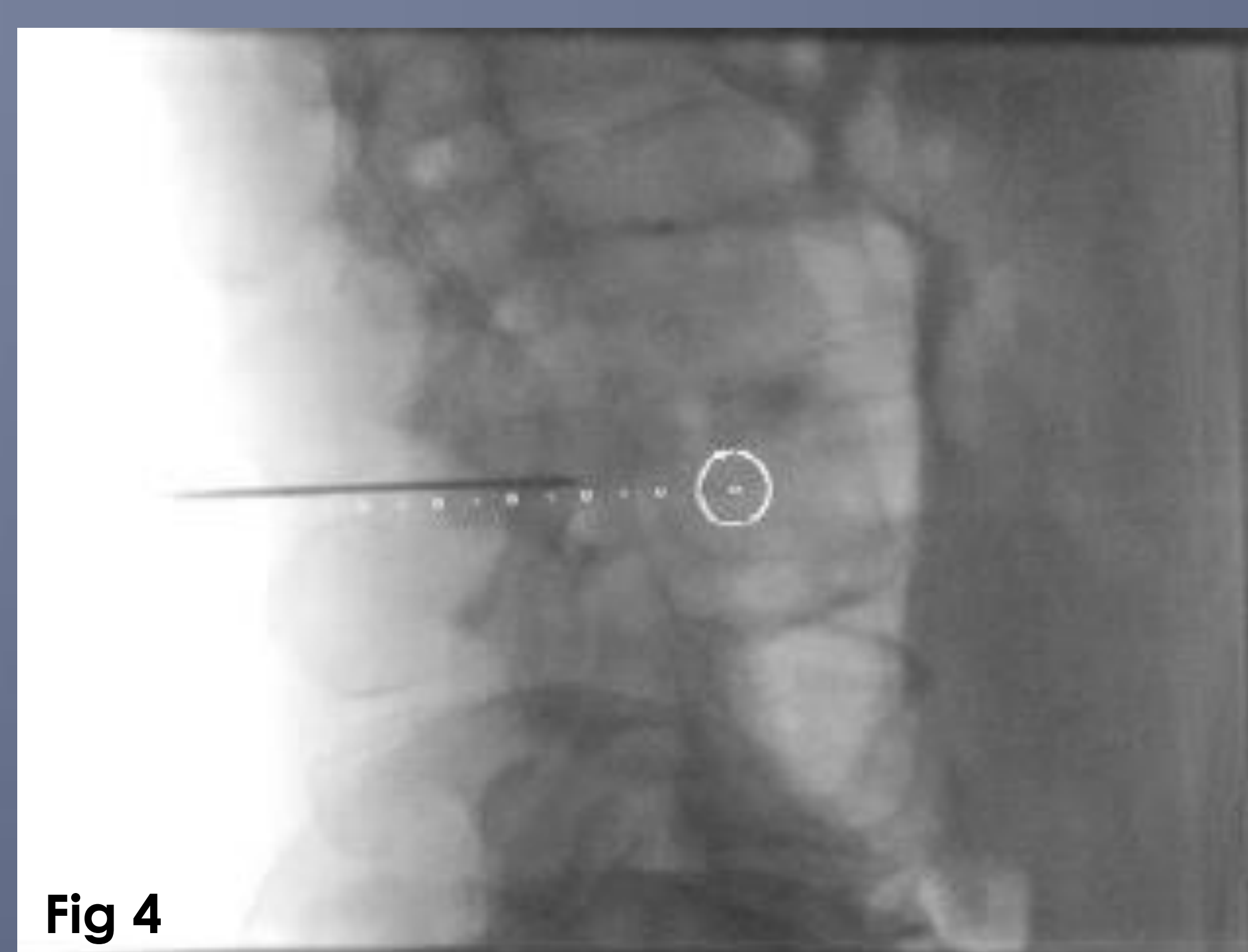
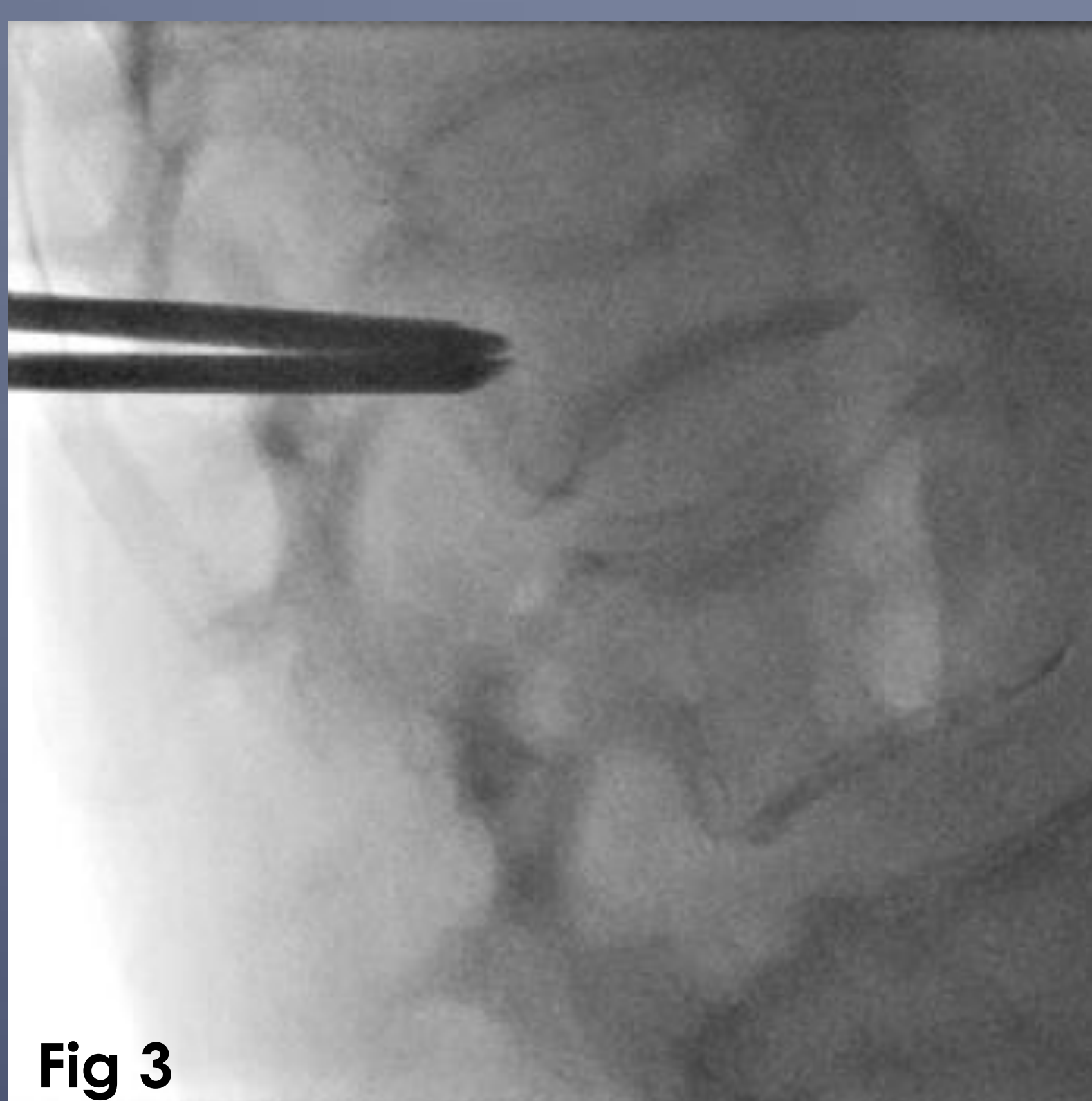


The entry point is used to determine an accurate skin entry point (Fig 1).

Once the interventional needle has been advanced a few centimetres. The c-arm is moved to one of the pre-planned progression views. The needles progression can be visualised on the 2D fluoroscopic image in relation to the virtual trajectory that was planned. (Fig 2)

A further progression view is available. These progression views can be switched between throughout the interventional procedure. (Braak et al, 2010)

Advantages	Disadvantages
A single imaging orbit can produce a complete volume dataset, allowing for Submillimetre isotropic reconstructions can be created (Orth et al, 2008)	Operator dependant need high levels of skill and knowledge The is also the radiation implications to consider - ALARA and Radiation Protection
Patients can remain stationary throughout.	Patient movement impacts on needle guidance in 2 main ways.
Both fluoroscopic (Fig 3) and needle guidance (Fig 4) are available as separate images to allow for evaluation of needle progression - this is not limited to any plane of imaging e.g. Axial only imaging within CT	1. Firstly the time for imaging system to complete the volume data set for the CBCT/3D dataset is longer than a conventional CT scan. 2. If the patient moves the 2D fluoroscopic image will be accurate were as the needle guidance virtual trajectory will no longer relate to the new patient condition.
Easy access to patient for drug and care administration	
More space for the intervention radiologist to work	
Compact design	
Real time fused CBCT, Needle guidance and fluoroscopic image allow for accurate needle placement (Fig 5).	



Conclusion

The use of needle guidance software has allowed the Interventional Radiologist to perform examinations that were once only possible CT to be performed within Interventional Suites. This allows for better management and care of the patients, by facilitating improved access to the patient throughout the procedure but also easy access to the staff and facility's that an IR suite provide. The successful use of Needle Guidance software is down to confidence, knowledge and skill base of operator and the radiographer. As with all new technologies, the more experience and practise gained, the better the performance outcomes will be.

References

- ANGLE, John F. (2013). Cone-Beam CT: Vascular Applications. *Techniques in vascular and interventional radiology*, **16** (3), 144-149.
- BRAAK, S. J., et al. (2010). Real-Time 3D Fluoroscopy Guidance During Needle Interventions: Technique, Accuracy, and Feasibility. *American journal of roentgenology*, **194** (5), W445-W451.
- BRAAK, SiccoJ, et al. (2013). Feasibility Study of Needle Placement in Percutaneous Vertebroplasty: Cone-Beam Computed Tomography Guidance Versus Conventional Fluoroscopy. *Cardiovascular and interventional radiology*, **36** (4), 1120-1126.
- ORTH, Robert C., WALLACE, Michael J. and KUO, Michael D. (2008). C-arm Cone-beam CT: General Principles and Technical Considerations for Use in Interventional Radiology. *Journal of vascular and interventional radiology*, **19** (6), 814-820