

The departmental impact of magnetic resonance imaging in the management of cervical cancer brachytherapy: a discussion paper

WARREN, M. J. and EDDY, Angela

Available from Sheffield Hallam University Research Archive (SHURA) at:

<http://shura.shu.ac.uk/8408/>

This document is the author deposited version. You are advised to consult the publisher's version if you wish to cite from it.

Published version

WARREN, M. J. and EDDY, Angela (2012). The departmental impact of magnetic resonance imaging in the management of cervical cancer brachytherapy: a discussion paper. *Journal of Radiotherapy in Practice*, 11 (04), 201-208.

Repository use policy

Copyright © and Moral Rights for the papers on this site are retained by the individual authors and/or other copyright owners. Users may download and/or print one copy of any article(s) in SHURA to facilitate their private study or for non-commercial research. You may not engage in further distribution of the material or use it for any profit-making activities or any commercial gain.

Original Article

The departmental impact of magnetic resonance imaging in the management of cervical cancer brachytherapy: a discussion paper

M.J. Warren¹, A. Eddy²

¹Radiotherapy Group, North West Medical Physics, Christie NHS Foundation Trust, Wilmslow Road, Manchester, UK, ²Sheffield Hallam University, Robert Winston Building, Collegiate Crescent Campus, Sheffield, UK

Abstract

This discussion paper will explore the impact of using Magnetic Resonance Imaging (MRI) in the treatment of cervical cancer with brachytherapy. It is written from the perspective of current departmental practice in the UK and aims to highlight the issues associated with using MRI as a tool for image guided brachytherapy planning. To support the discussion, a literature review was undertaken focussing specifically on the use of MRI in brachytherapy treatment planning for cervical cancer. Results from planning case studies and clinical series were analysed, and the literature showed that image guided brachytherapy treatment planning is a promising development. MRI assisted planning could theoretically be implemented in centres that have access to a MRI scanner. Alternative brachytherapy technologies (e.g. Computed Tomography (CT) assisted planning), and alternative radiotherapy modalities (e.g. an external beam radiotherapy boost), were not found to be superior in effect or of implementation. Although MRI shows great promise, the evidence base for MRI in brachytherapy planning for cervical cancer is currently limited and therefore careful implementation and evaluation is required. It is suggested by the authors that new methods of working are devised to ensure consistency and quality in implementation and delivery, and that outcomes are measured and audited to evaluate efficacy.

Keywords

Brachytherapy; magnetic resonance imaging (MRI); cervical cancer; planning

INTRODUCTION

Brachytherapy has historically played an important part in the treatment of cervical cancer. In the 1940's, brachytherapy was undertaken via the manual insertion of live sources such as radium, and dosimetric techniques—such as the Manchester System were developed in tandem. The Manchester System was then

adapted for use with Low Dose Rate (LDR) afterloading machines and is still widely used.^{1–3}

In the UK, 63% of centres currently use LDR machines, and 73% of centres currently plan treatments with orthogonal x-rays.⁴ The Manchester System is still widely used, with dose prescribed to points based upon applicator geometry rather than tumour topography or Organs At Risk (OAR). However, the vast majority (83%) of these UK centres anticipate using image guided planning for brachytherapy

Correspondence to: Warren MJ, BSc (Hons) Radiotherapy, Bsc (Hons) Physics, Radiotherapy Group, North West Medical Physics, Christie NHS Foundation Trust, Wilmslow Road, Manchester, M20 4BX
Tel: 0161 446 8429. E-mail: markjwarren@hotmail.co.uk

within the next three years.⁴ Furthermore, LDR machines that have been popular in the UK are now coming to the end of their natural lives and are being phased out of production by their manufacturers.^{1,3} Replacement technology such as High Dose Rate (HDR) and Pulsed Dose Rate (PDR) afterloading machines offer versatility to shape dose distributions, unlike LDR machines.⁵ Therefore, there is a current opportunity for cancer centres in the UK to re-evaluate and reassess, as to how the different technological solutions available will influence future management of disease, and consider their impact upon the service.

This discussion paper will explore the impact of MRI on brachytherapy technology with specific reference to the management and treatment of cervical cancer. The role of radiotherapy in treating cervical cancer will be discussed, contextualising the use of brachytherapy, and the authors will elaborate on how this may influence the further development of brachytherapy technology and services.

Cervical cancer: A general overview and use of brachytherapy in disease management

Gynaecological cancers account for 19% of worldwide cancer, within which cancer of the cervix is the second most common.⁶ Radiotherapy is an important part of the radical management of cancer of the cervix; chemoradiotherapy is the gold standard for patients with locally advanced disease or poor prognostic indicators.^{7,8} Brachytherapy has traditionally been a common constituent of the radiotherapy treatment, providing a local boost to compliment the external beam (EBR) treatment to the whole pelvis. Doses over 50 Gy to the whole pelvis with EBR have been associated with increased complications and lower survival in cervical cancer,⁹ and hence, in combination, brachytherapy allows higher doses to be given to the primary site. However, there are still associated risks of small bowel, rectal and bladder toxicity.¹⁰

Using MRI for delivering brachytherapy to cervical tumours

Image quality and target delineation

MRI has been used in staging investigations for cervical cancer to assess the volume of disease and the parametrial, bladder, or rectal invasion. Lymph node status in the obturator, internal and external iliac groups may also be assessed with MRI, and although PET imaging is more sensitive¹¹ it is not widely available. In EBR, MRI has demonstrated superior Gross Tumour Volume (GTV) and OAR definition when compared to portal films and CT images.^{12,13} Furthermore, in a large study of patients undergoing brachytherapy after EBR, MRI showed that the visualisation of macroscopic and partially microscopic disease, as well as areas of tumour regression, was possible.¹⁴

Traditionally, brachytherapy planning has relied on using orthogonal x-rays to calculate point doses, such as to point A (Figure 1) and the International Commission on Radiation Units and Measurements (ICRU) bladder and

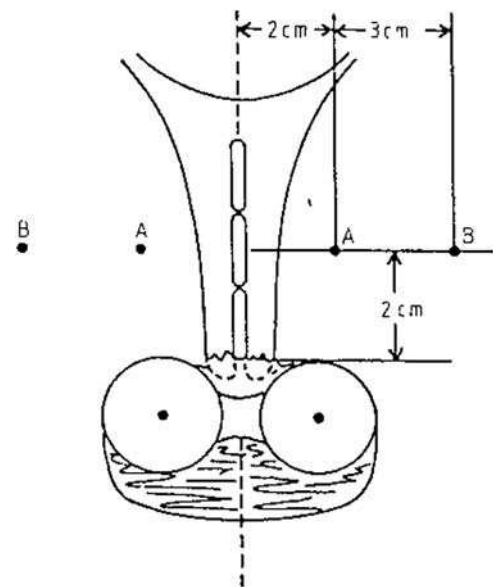


Figure 1. The position of Point A, situated 2 cm superior of the vaginal ovoids and 2 cm lateral of the intrauterine sources. (Reproduced by kind permission of Elsevier from Meredith WJ (1967) 'Radium Dosage: The Manchester System' Second Edition. Edinburgh, E&S Livingstone Ltd, p. 48.)

rectal points. The use of MRI images for patient-specific planning would allow a transition away from point doses to a volume-based analysis and reporting. The GEC-ESTRO recommendations^{15,16} suggest that areas identifiable on MRI as macroscopic disease, partially microscopic disease and tumour regression should be used to delineate target volumes at high or intermediate risk of local recurrence. These Intermediate-risk Clinical Target Volumes (IR-CTVs) or High-risk Clinical Target Volumes (HR-CTVs) can then be used to optimise plans to patient-specific disease characteristics.

Image registration and applicator reconstruction

Although no extra margins are needed for patient related uncertainties such as organ movement,¹⁵ the literature identifies a number of geometric uncertainties. Uncertainties are associated with geometric distortion from the MRI, but some studies have shown this can be limited to 2 mm in the area of treatment.¹⁷ Another possible uncertainty is 'reconstruction of the applicator'; this is the process whereby the geometry of the source channels and dwell positions are defined on three dimensional (3D) images to enable planning. Hack et al describes a method of applicator reconstruction for MRI¹⁸ via the visualisation of source channels using catheters containing copper sulphate.

Unlike when planning for EBR, electron density information is not necessary for brachytherapy planning; CT images are therefore not needed.¹⁹ However, applicator reconstruction using CT images followed by CT-MR fusion is still a widely reported method of planning in the literature.^{20,21,22,23} It has been shown that valuable information can be lost on CT in between slices and this is less likely to occur with MR reconstruction.²⁰ Although inter-observer variability due to image artefacts is evident in applicator reconstruction with MRI, the uncertainties in reconstruction can be minimised as part of a stringent quality assurance program,¹⁸ and particular care must be taken when using conformal loading patterns²⁴.

PATIENT SPECIFIC PLANNING FOR CERVICAL BRACHYTHERAPY: WHAT IS THE EVIDENCE BASE?

The GEC-ESTRO recommendations for target volume definition and dose reporting have been adopted by the Royal College of Radiologists Working Party,⁴ and are widely used in the literature to describe both planning studies and clinical results.

Planning studies are often descriptive rather than comparative, and are commonly used to report the use of a new technique, giving a synopsis of the dosimetric results. However, some of these planning studies have compared new techniques against old institutional practices.^{25,26} Planning studies also may be limited as they have small sample sizes (between one and twenty two patients in the surveyed studies) and it is therefore debatable that the results are transferable to the general patient population. Nevertheless they do provide some useful indications for future work, and importantly identify some issues that can be followed up in future studies. One study identified strategies for treating large HR-CTV and OAR close to the GTV with interstitial needles and/or adapting source dwell times.²² Another identified a subgroup of patients that were problematic to plan (severely anteflexed uterus), and subsequently developed two contrasting treatment plans that either optimised target coverage or improved organ sparing²¹.

Two papers were identified that directly compared standardised loading/prescription to point A against conformal loading using MRI images.^{25,26} Although both studies found that mean D90 (minimum dose delivered to 90% of the volume) to the GTV increased slightly when using MRI, mean rectal, bladder and small bowel D1cc (dose to 1cc of most irradiated tissue) and 2 cc results were equivocal. However, De Brabandere et al.²⁵ emphasised that the reporting of mean dose across a cohort hides the specific advantages that conformal loading brings to individual plans. For example, when altering a standardised plan, the planner would sometimes reduce a high D90 to the

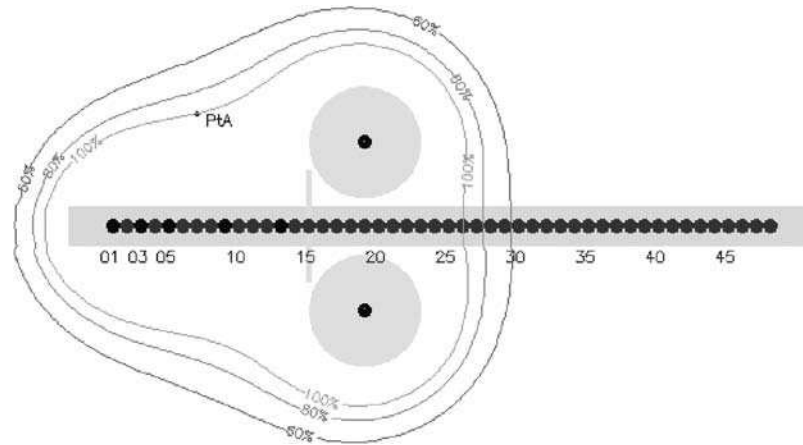


Figure 2. A cross-sectional view, through an intrauterine tube and vaginal ovoids, showing caesium pellet positions, and the resulting dose distribution. The pear shape dose distribution is representative of a Manchester System treatment, which uses a standardised pellet loading pattern.

GTV in order to reduce dose to critical structures. Similarly, doses to critical structures were sometimes increased (within tolerance) to increase D90 coverage of the GTV.

Both studies used natural modifications of existing techniques to allow MRI imaging and non-conformal loading. MRI compatible versions of traditional applicators (the ring, and tandem and ovoids, as used throughout UK centres⁴ were used and the 'pear shape' dose distribution was the common starting point for planning (Figure 2). The plans produced by three different types of applicator adapted for MRI (tandem and ovoids, individual moulds and Vienna ring) have been compared and have shown relative equivalence, with differences in dose distribution quality attributed to patient anatomy.²⁷ Additional modifications of traditional applicators have been developed, such as the insertion of interstitial needles through guide holes in the ring.²² Even when dose distributions have been deliberately kept close to the classic 'pear shape', interstitial needles enabled larger GTVs to be treated to higher doses without increasing OAR doses.^{22,26}

Clinical Results

Reporting of clinical results of MRI guided planning for gynaecological brachytherapy are

often limited to case series reports. A series from Vienna compares a cohort of consecutive patients treated at a single institution before and after a switch to MRI assisted planning.¹⁰ Data suggests that the use of MRI guidance leads to both an overall reduction of toxicity and an increase in local control and survival in a subset of patients with tumours greater than 5 cm at implant.¹⁰ The authors reported that interstitial needles allowed them to treat large tumours, which they would have normally treated with an EBR boost, but no comparison of outcomes between these two options is given. In Nayaran et al.²⁸ a survival difference was not observed after a switch from LDR to MRI-planned HDR, but a significant decrease in bowel and bladder symptoms is reported.

What are the possible alternatives to MR guided brachytherapy?

CT brachytherapy planning

In the UK, only one institution has reported on the use of 3D imaging with cervix brachytherapy.²⁹ This series from Addenbrooke's NHS Trust reported an increase in local control and decrease in complications using CT planning when compared to standard loading and prescribing to point A. The use of CT images rather than MRI was necessary due to the

impracticality of scheduling MR scans to coincide with intracavitary insertions at that institution. In the UK in 2008, only 4% of centres had access to brachytherapy planning using MRI, and it is likely that many other centres will see CT planning as an alternative.⁴ Data suggests that CT planning leads to larger target volumes than MRI,^{23,29} and this series reports a cautious use of dose optimisation as a result, with V90 for patients limited by OAR tolerance.

The Addenbrooke's series utilised a ring applicator, but does not use the additional capability of the interstitial needles, and it reported a lower increase in local control in tumours greater than 5 cm compared to the Vienna series. Addenbrooke's relies more on giving an EBR boost to patients with bulkier tumours, and so the number of patients in their series with tumours greater than 5 cm was much lower than in the Vienna series.²⁹ The use of a conventional EBR boost when brachytherapy is not possible is increasing at other UK centres, and good survival and complication rates can be seen using this technique.³⁰

What is the feasibility of the MRI-guided EBR boost for cervix carcinoma?

A number of planning case studies have been undertaken to understand the possible role of an MR-guided IMRT boost in the treatment of cervix carcinoma. Dosimetric comparison between IMRT and brachytherapy is difficult due to the dose inhomogeneity inherent in brachytherapy, but there is evidence to suggest that IMRT plans struggle to provide comparable V90 and V95 doses without compromising normal tissue tolerances.^{31,32} One planning case study reported that conventionally loaded or optimised brachytherapy in combination with a concomitant IMRT boost was superior to optimised brachytherapy alone; this was particularly profound in cases where the uterus was severely anteflexed.²¹

It must be noted that the above studies assume that as the CTV is immobilised using a stereotactic applicator, PTV margins are min-

imal. Implementation of IMRT after applicator insertion would require quick turnaround of planning and verification, which is logistically challenging.²¹ Without stereotactic immobilisation, PTV margins surrounding the cervix and uterus are greatly affected by internal organ motion, and recent studies have tried to quantify this problem in cervical cancer using MRI.^{19,33} These studies in particular have identified the influence of tumour regression and OAR filling has on the position of the GTV, and it is suggested that non-uniform margins and interfractional imaging are required if the aim is to achieve a reduction in the PTV margin to reduce OAR toxicity.

IMPLEMENTING A CHANGE IN TREATMENT DELIVERY FOR CERVICAL CANCER BRACHYTHERAPY

A change from LDR to PDR or HDR machines requires a significant change in practice regardless of an institution's decision to use MRI, as new dose and fractionation regimes would need to be determined to re-create the radiobiological effects of LDR treatment using the linear quadratic model.^{15,34} Although this model has been used previously³⁴ and is now well accepted within the radiotherapy community,³ it must be emphasised that if a large number of treatments are undertaken, any small inaccuracies in the model are more likely to have a detrimental clinical effect. So, although MR optimisation may have mitigatory role, clinical results must be closely monitored.

The introduction of MRI assisted planning introduces an additional step into a treatment process that is arguably simple and effective. The maintenance of expertise in brachytherapy has been recognised as a problem,³⁵ and MRI planning will add to the challenge of educating and training practitioners as well as maintaining those skills. To date there has been no specific research that has explored staff training needs, or evaluated the extra resources needed to plan with MRI. In the literature, the time reported to produce a plan ranged from 20 to 40 minutes

per insertion,³⁶ with around 15–20 minutes allocated for patient contouring.²⁹ HDR treatments may require multiple insertions, which could result in extra time needed for contouring. The use of interstitial needles would require the use of supplementary theatre time and the development of new skills; scheduling MRI guidance would also require additional co-ordination between infection control experts, nurse, anaesthetists, diagnostic radiographers and radiologists. CT planning would also require additional staff training, quality assurance procedures to be put in place and the appropriate scheduling of CT planning time. The limited availability of MRI to all brachytherapy service providers in the UK may require referral to neighbouring cancer centres with MRI facilities and available capacity for specific categories of patient.⁴

Although inverse planning solutions for brachytherapy have been discussed in the literature,^{2,5} the use of the ‘pear-shaped’ dose distribution is still widely accepted as an important starting point for optimisation, and severe deviations from it using inverse planning were not apparent in the literature. Therefore, manual optimisation may suffice, as no indication is given in the literature that inverse planning will reduce planning times. However, this could be a future area of exploration that would require the close collaboration between the oncologist, the dosimetrist and the rest of the planning and treatment delivery team, during the early stages of implementation.

CONCLUSION

Brachytherapy is an important part of the treatment of cervical cancer with radiotherapy, and the use of MRI in planning and delivering treatment allows the definition of macroscopic and partially microscopic disease even after initial EBR. HDR and PDR machines can simulate the current techniques, but they also facilitate the use of image guided brachytherapy planning using MRI. Uncertainties in applicator reconstruction and image fusion can be minimised by developing appropriate quality

assurance systems, which address training and resource issues.

Planning studies show the advantages of using MRI to conform dose to the target volumes identified by the GEC-ESTRO guidelines. The majority of evidence favours the approach of MR imaging with patient specific loading compared to standardised loading and prescribing the use of the Manchester System. However, the reviewed clinical results for MRI dose optimisation were limited and further clinical trials will be needed to explore this further. Although optimising plans using CT imaging work on the same principles, the limited clinical evidence so far does suggest that MRI is superior for brachytherapy, especially in patients with larger tumours. Currently those patients with large tumours or patients that cannot have brachytherapy frequently have a fractionated EBR boost instead, which may be improved in the future from the use of IMRT and MRI-CT fusion for planning. Further studies into the definition of organ movement and PTV reduction may improve outcomes for this already well-established and clinically acceptable technique. Although the skill base in IMRT is already well established, planning case studies in the literature and current logistical difficulties with dose verification would suggest that IMRT boosts cannot be used as a direct alternative to MR brachytherapy.

The process of dose optimisation throughout the literature is still reliant upon the classic ‘pear-shape’ for a starting point. Dose constraints for volumes are as yet unproven in clinical trials, so this could be an area for further exploration. However, emphasis should still be placed on ensuring that good clinical outcomes are maintained.

Evidence suggests that there is no superiority in using a particular type of applicator and it would be therefore acceptable to continue using the current styles of applicator if a switch to MRI dose optimisation was to occur. Although no formal assessment of skills and time needed to implement a change to MR brachytherapy has been published, the use of

interstitial needles, particularly in conjunction with MRI guidance, would require a new set of skills across professions, as well as additional time and new logistical solutions. Dedicated staff across disciplines should be appointed to co-ordinate learning during the introduction of MRI planning, and education and training should be offered along with the dissemination of knowledge to the wider professional team.³⁵ These staff, dependent on their scope of practice could be at consultant/advanced practice level,³⁵ and further role extension and development of radiographers could be utilised more, for example in vaginal vault insertions.³⁵

References

- Radstone D, Kunkler I. Cervix, body of uterus, ovary, vagina, vulva, gestational trophoblastic tumours. In: Bomford CK, Kunkler IH (eds), *Walter and Miller's Textbook of Radiotherapy, Radiation Physics Therapy And Oncology*, 6th edn. London, Churchill Livingstone, 2003, pp. 456–487.
- Dewitt KD, Hsu IC, Speight J, Weinberg VK, Lessard E, Pouliot J. 3D inverse treatment planning for the tandem and ovoid applicator in cervical cancer. *Int J Radiat Oncol Biol Phys* 2005; 63:1270–1274.
- National Institute for Health and Clinical Excellence. *Interventional procedures overview of high dose rate brachytherapy for carcinoma of the cervix*. London, National Institute for Clinical Excellence, 2005.
- The Royal College of Radiologists. *Implementing image-guided brachytherapy for cervix cancer in the UK*. London, The Royal College of Radiologists, 2009.
- Chajon E, Dumas I, Touleimat M, Magné N, Coulot J, Verstraet R, Lefkopoulos D, Haie-Meder C. Inverse planning approach for 3-D MRI-based pulse-dose rate intracavitary brachytherapy in cervix cancer. *Int J Radiat Oncol Biol Phys* 2007; 69:955–961.
- Sankaranarayanan R, Ferlay J. Worldwide burden of gynaecological cancer: the size of the problem. *Best Pract Res Clin Obstet Gynaecol* 2006; 20:207–225.
- Patrick P, Michel R. Diagnosis and management of cervical cancer. *BMJ* 2007; 345:765–768.
- Kehoe S. Treatments for gynaecological cancers. *Best Pract Res Clin Obstet Gynaecol* 2006; 20:985–1000.
- Logsdon MD, Eifel PJ. FIGO IIIB squamous cell carcinoma of the cervix: an analysis of prognostic factors emphasizing the balance between external beam and intracavitary radiation therapy. *Int J Radiat Oncol Biol Phys* 1999; 43:763–775.
- Pötter R, Dimopoulos J, Georg P, Lang S, Waldhäusl C, Wachter-Gerstner N, Weitmann H, Reinthaller A, Knocke TH, Wachter S, Kirisits C. Clinical impact of MRI assisted dose volume adaptation and dose escalation in brachytherapy of locally advanced cervix cancer. *Radiother Oncol* 2007; 83:148–155.
- Viswanathan AN. The Frank Ellis memorial lecture: the use of three-dimensional imaging in gynaecological radiation therapy. *Clin Oncol (R Coll Radiol)* 2008; 20:1–5.
- Khoo VS, Dearnaley DP, Finnigan DJ, Padhani A, Tanner SF, Leach MO. Magnetic resonance imaging (MRI): considerations and applications in radiotherapy treatment planning. *Radiother Oncol* 1997; 42:1–15.
- Barillot I, Reynaud-Bougnoux A. The use of MRI in planning radiotherapy for gynaecological tumours. *Cancer Imaging* 2006; 6:100–106.
- Dimopoulos JC, Schard G, Berger D, Lang S, Goldner G, Helbich T, Pötter R. Systematic evaluation of MRI findings in different stages of treatment of cervical cancer: potential of MRI on delineation of target, pathoanatomic structures, and organs at risk. *Int J Radiat Oncol Biol Phys* 2006; 64:1380–1388.
- Haie-Meder C, Pötter R, Van Limbergen E, Briot E, De Brabandere M, Dimopoulos J, Dumas I, Hellebust TP, Kirisits C, Lang S, Muschitz S, Nevinson J, Nulens A, Petrow P, Wachter-Gerstner N; Gynaecological (GYN) GEC-ESTRO Working Group. Recommendations from Gynaecological (GYN) GEC-ESTRO Working Group (I): concepts and terms in 3D image based 3D treatment planning in cervix cancer brachytherapy with emphasis on MRI assessment of GTV and CTV. *Radiother Oncol* 2005; 74:235–245.
- Pötter R, Haie-Meder C, Van Limbergen E, Barillot I, De Brabandere M, Dimopoulos J, Dumas I, Erickson B, Lang S, Nulens A, Petrow P, Rownd J, Kirisits C; GEC ESTRO Working Group. Recommendations from gynaecological (GYN) GEC ESTRO working group (II): concepts and terms in 3D image-based treatment planning in cervix cancer brachytherapy-3D dose volume parameters and aspects of 3D image-based anatomy, radiation physics, radiobiology. *Radiother Oncol* 2006; 78:67–77.
- Anderson C, Beenstock V, Bryant L, Chapman C et al. HDR brachytherapy of the cervix: The Mount Vernon Experience. *Brachytherapy User Group Meeting, Leeds; 2008*.
- Haack S, Nielsen SK, Lindegaard JC, Gelineck J, Tanderup K. Applicator reconstruction in MRI 3D image-based dose planning of brachytherapy for cervical cancer. *Radiother Oncol* 2009; 91:187–193.
- Huh SJ, Park W, Han Y. Interfractional variation in position of the uterus during radical radiotherapy for cervical cancer. *Radiother Oncol* 2004; 71:73–79.
- Hellebust TP, Tanderup K, Bergstrand ES, Knutsen BH, Roislien J, Olsen DR. Reconstruction of a ring applicator using CT imaging: impact of the reconstruction method

- and applicator orientation. *Phys Med Biol* 2007; 52:4893–4904.
21. Duan J, Kim RY, Elassal S, Lin HY, Shen S. Conventional high-dose-rate brachytherapy with concomitant complementary IMRT boost: a novel approach for improving cervical tumor dose coverage. *Int J Radiat Oncol Biol Phys* 2008; 71:765–771.
 22. Kirisits C, Lang S, Dimopoulos J, Berger D, Georg D, Pötter R. The Vienna applicator for combined intracavitary and interstitial brachytherapy of cervical cancer: design, application, treatment planning, and dosimetric results. *Int J Radiat Oncol Biol Phys* 2006; 65:624–630.
 23. Viswanathan AN, Dimopoulos J, Kirisits C, Berger D, Pötter R. Computed tomography versus magnetic resonance imaging-based contouring in cervical cancer brachytherapy: results of a prospective trial and preliminary guidelines for standardized contours. *Int J Radiat Oncol Biol Phys* 2007; 68:491–498.
 24. Berger D, Dimopoulos J, Georg P, Georg D, Pötter R, Kirisits C. Uncertainties in assessment of the vaginal dose for intracavitary brachytherapy of cervical cancer using a tandem-ring applicator. *Int J Radiat Oncol Biol Phys* 2007; 67:1451–1459.
 25. De Brabandere M, Mousa AG, Nulens A, Swinnen A, Van Limbergen E. Potential of dose optimisation in MRI-based PDR brachytherapy of cervix carcinoma. *Radiother Oncol* 2008; 88:217–226.
 26. Lindegaard JC, Tanderup K, Nielsen SK, Haack S, Gelineck J. MRI-guided 3D optimization significantly improves DVH parameters of pulsed-dose-rate brachytherapy in locally advanced cervical cancer. *Int J Radiat Oncol Biol Phys* 2008; 71:756–764.
 27. Langa S, Nulens A, Briot E et al. Intercomparison of treatment concepts for MR image assisted brachytherapy of cervical carcinoma based on GYN GEC-ESTRO recommendations. *Radiother Oncol* 2006; 78:185–193.
 28. Narayan K, van Dyk S, Bernshaw D, Rajasooriyar C, Kondalsamy-Chennakesavan S. Comparative study of LDR (Manchester system) and HDR image-guided conformal brachytherapy of cervical cancer: patterns of failure, late complications, and survival. *Int J Radiat Oncol Biol Phys* 2009; 74:1529–1535.
 29. Tan LT, Coles CE, Hart C, Tait E. Clinical impact of computed tomography-based image-guided brachytherapy for cervix cancer using the tandem-ring applicator – the Addenbrooke’s experience. *Clin Oncol (R Coll Radiol)* 2009; 21:175–182.
 30. Barraclough LH, Swindell R, Livsey JE, Hunter RD, Davidson SE. External beam boost for cancer of the cervix uteri when intracavitary therapy cannot be performed. *Int J Radiat Oncol Biol Phys* 2008; 71:772–778.
 31. Georg D, Kirisits C, Hillbrand M, Dimopoulos J, Pötter R. Image-guided radiotherapy for cervix cancer: high-tech external beam therapy versus high-tech brachytherapy. *Int J Radiat Oncol Biol Phys* 2008; 71:1272–1278.
 32. Assenholt MS, Petersen JB, Nielsen SK, Lindegaard JC, Tanderup K. A dose planning study on applicator guided stereotactic IMRT boost in combination with 3D MRI based brachytherapy in locally advanced cervical cancer. *Acta Oncol* 2008; 47:1337–1343.
 33. van de Bunt L, Jurgenliemk-Schulz IM, de Kort GAP, Roesink JM, Terteeg RJHA, van der Heide UA. Motion and deformation for cervical cancer: what margins do we need? *Radiother Oncol* 2008; 88:234–240.
 34. Petereit DG, Sarkaria JN, Potter DM, Schink JC. High-dose-rate versus low-dose-rate brachytherapy in the treatment of cervical cancer: analysis of tumor recurrence—the University of Wisconsin experience. *Int J Radiat Oncol Biol Phys* 1999; 45:1267–1274.
 35. The Royal College of Radiologists. *The Role and Development of Brachytherapy Services in the United Kingdom*. London: The Royal College of Radiologists, 2007.
 36. Dimopoulos JCA, Kirisits C, Petric P et al. The Vienna Applicator and interstitial brachytherapy of cervical cancer: clinical feasibility and preliminary results. *Int J Radiat Oncol Biol Phys* 2006; 64:5.