Roshier, Amanda Louise (2005) Observation and quantification of pathological lesions in the musculoskeletal structures of the cervical spine. PhD thesis, University of Nottingham.

# OBSERVATION AND QUANTIFICATION OF PATHOLOGICAL LESIONS IN THE MUSCULOSKELETAL STRUCTURES OF THE CERVICAL SPINE

Amanda Louise Roshier, BSc (Hons)

Thesis submitted to the University of Nottingham
for the degree of Doctor of Philosophy

March 2005

# Abstract

This thesis describes the study carried out for the 'Observation and Quantification of Pathological Lesions in the Musculoskeletal Structures of the Cervical Spine'. In particular, this study has focused on the identification and quantification of pathological lesions of the musculoskeletal complex of the cervical spine, resulting from a whiplash injury.

Whiplash was first recognised in the early 1920's, and since this first report there has been a greater number of road users; which has led to an increase in its incidence. Whiplash is an injury of high socioeconomic importance and the ability to understand and assess this injury would benefit from a diagnostic technique. Whiplash injury is the result of a sudden movement of the head typically occurring as a result of a rear-end vehicle collision. Victims typically report varying levels of pain emanating from the neck region, although the exact cause of pain is yet to be established. This unknown pathoanatomy is a possible reason why a suitable diagnostic procedure has not been established. One suggestion is that damage occurring to the soft tissues of the neck, such as muscle and ligament, is responsible for the pain experienced following a whiplash injury. Diagnostic ultrasound is already well established and recognised for its ability to image the musculoskeletal system and identify pathologies, and for this reason is the chosen imaging modality for this study. The effectiveness of diagnostic ultrasound as a diagnostic tool of the soft tissues of the cervical region; and its ability to identify and quantify the pathoanatomy of whiplash is examined. The results of this research enabled the development of a diagnostic procedure that was carried out on whiplash patients. A future study has been suggested based on these findings for the further development of this procedure.

# Acknowledgements

*For Dad, Mum, Elly, Lee,*
*Gran, Nan, Auntie Lyn and Andy*

The marvellous richness of human experience would lose something of rewarding joy if there were no limitations to overcome. The hilltop hour would not be half so wonderful if there were no dark valleys to traverse.

- Helen Keller -

I have many to thank for helping me to climb my mountain. To my family and friends, words defy description as to how much your love and support means to me.

The work of this thesis was sponsored by the EPSRC and the AO foundation, under the guidance of Dr. Donal McNally.

# Publications

The following publications have been produced during the development of this thesis.

*Presentations*

**Roshier AL.** *Ultrasound imaging of the cervical spine.* Published in the proceedings of: Back to Back Disc Meeting. Botnar Centre, Nuffield Orthopaedic Hospital, Oxford, UK. 17th April 2002.

**Roshier AL.** *Using ultrasound to quantify musculoskeletal injuries.* Biomechanics Group Short Talk Session. University of Nottingham, Nottingham, UK. 21st October 2002.

**Roshier AL.** *Quantifying whiplash injury.* Bioengineering Group Short Talk Sessions. University of Nottingham, Nottingham, UK. 24th October 2002.

**Leung YL, Roshier AL, Johnson S, McNally DS.** *Visualisation of the cervical spine musculature using ultrasound.* Published in the proceedings of: The Society for Back Pain Research, Annual General Meeting. Royal Armouries Museum, Leeds, UK. 14th and 15th November 2002.

**Roshier AL, Leung YL, Johnson S, McNally DS.** *Cervical facet joints and discs visualised with the aid of ultrasound.* Published in the proceedings of: The Society for Back Pain Research, Annual General Meeting. Royal Armouries Museum, Leeds, UK. 14th and 15th November 2002.

**Roshier AL.** *Visualisation of the cervical musculature using ultrasound.* Published in the proceedings of: Back to Back Meeting. The Robert Jones and Agnes Hunt Orthopaedic Hospital, Oswestry, UK. 20th November 2002.

**Roshier AL.** *Cervical facet joints and discs visualised with the aid of ultrasound.* Published in the proceedings of: Back to Back Meeting. The Robert Jones and Agnes Hunt Orthopaedic Hospital, Oswestry, UK. 20th November 2002.

**Leung YL, Roshier AL, Johnson S, Kerslake R, McNally DS.** *Can ultrasound be used to image the musculature of the cervical spine?* Published in the proceedings of: The British Association of Clinical Anatomists. Sheffield, UK. 16th December 2002. *Clinical Anatomy.* 16(5): 461-465

**Leung YL, Roshier AL, Johnson S, McNally DS.** *A review of the posterior cervical spine musculature using ultrasound imaging.* Published in the proceedings of: Anatomische Gesellschaft - 98. Versammlung - . Dresden, Germany. 28th - 31st March 2003.

**Roshier AL, Leung YL, Johnson S, McNally DS.** *Appearance of facet joints and cervical intervertebral discs imaged using ultrasound.* Published in the proceedings of: Anatomische Gesellschaft - 98. Versammlung -. Dresden, Germany. 28th - 31st March 2003.

**Leung YL, Roshier AL, Johnson S, Kerslake R, McNally DS.** *Ultrasound imaging of the musculoskeletal elements of the cervical spine - Mission Impossible?* Published in the proceedings of: Ultrasonics International 2003. Granada, Spain. 30th June - 3rd July 2003.

**AL Roshier, YL Leung, S Johnson, DS McNally.** *Can ultrasound be used to image the bony components of the cervical spine?* Published in the proceedings of: Ultrasonics International 2003. Granada, Spain. 30th June - 3rd July 2003.

**Leung YL, Roshier AL, Johnson S, Kerslake R, McNally DS.** *Musculoligamentous anatomy of the cervical spine as visualised by ultrasound.* Published in the proceedings of: World Spine II. Chicago, USA. 10th - 13th August 2003

**Roshier AL, Leung YL, Johnson S, McNally DS.** *Can ultrasound be used to image cervical facet joints and discs?* Published in the proceedings of: World Spine II. Chicago, USA. 10th - 13th August 2003.

**Roshier AL** *Quantification of whiplash injury.* Set for Britain: Taking Science to Parliament - The 2003 Great British Research and R and D Show. House of Commons, London, UK. 15th March 2004

**Roshier A, Clarke A, Freeman BJC, McNally DS.** *Ultrasound identifies organic lesions following whiplash injury.* Published in the proceedings of: Spine Week 2004. Porto, Portugal. May 30th - June 5th 2004.

**Roshier AL** *Whiplash: more than a pain in the neck.* BA festival of science. University of Exeter, Exeter, UK. 6th September - 11th September 2004.

*Papers*

**Leung YL, Roshier AL, Johnson S, Kerslake R, McNally DS (2005)** Demonstration of the appearance of the paraspinal musculoligamentous structures of the cervical spine using ultrasound. *Journal of Clinical Anatomy.* **18:** 96-103

# Table of Contents

# Table of Tables

## Table of Figures

# Chapter 1: Introduction

## *1.1 Chapter Summary*

This chapter describes the background to this research and provides an overview of the work presented in this thesis. The importance of the research and its timeliness are discussed. The aims of this research project and the objectives needed to achieve these aims are identified. The layout of this thesis is described together with a brief overview of the contents for each chapter.

## *1.2 Thesis Overview*

Whiplash is one of the most illusive road traffic injuries to diagnose and treat. Its prevalence is increasing as a direct result of the significant growth in the number of road users. In genuine cases of whiplash the pain can be debilitating and may be present for years, however, there is significant evidence to indicate that it is frequently used as a generic catch all for a range of injuries; some real and some imaginary. Whiplash is also proving to be a pain in the pocket commercially. Both the victim and their employer incur loss of earnings and inconvenience. The consequential compensation claims being awarded to victims are a significant financial drain to the insurance industry. The value of the claims being made result in higher insurance premium charges which ultimately affect every consumer. With no ability to determine diagnosis and prognosis, monetary awards for the suffering caused and the amount of absence needed from work is difficult to determine.

Whiplash is the result of a sudden movement of the head typically occurring as a result of a rear-end vehicle collision but may also occur during side-impact motor vehicle collisions. Although whiplash is normally associated with accidents involving vehicles, it can also occur as a result of many other mishaps such as diving. This sudden head movement can cause soft tissue or bony injuries that may lead to a variety of clinical manifestations known as whiplash-associated disorders. An imaging modality is not available that can assess the damage caused by whiplash successfully and radiographic techniques have failed to provide a solution. Diagnostic ultrasound is an imaging technique not yet exploited for the assessment of whiplash injury, but it has the inherent capability to image soft tissues and identify tears and swelling. Diagnostic ultrasound therefore has the potential, when applied to the structures of the neck damaged by whiplash, to assist the clinician in determining the existence, level and extent of injury, as well as for the formulation and evaluation of treatment strategies.

## *1.3 Importance of this Work*

The literature relating to whiplash is abundant, and highlights it as a medical, legal and social problem. In the UK, an investigation of accident and emergency departments and calculation of the relative expenses, estimated the annual cost to the economy from whiplash as £3.1 billion (Charles Galasko personal communication 2004). The UK experiences in excess of 250,000 claims each year relating to whiplash; with an estimated annual cost to the insurance community of at least £1 billion (PartnerRe Ltd. 2000). If a technique for identifying whiplash could be identified then this could form the basis from which to develop a method for injury management, prevent malingering and save a considerable amount of money. A diagnostic procedure capable of identifying a whiplash injury does not exist, and this is probably due to the exact cause of pain experienced after a whiplash event being unknown. The research conducted in this thesis aims to identify the pathoanatomy of whiplash. This information can then be used in the development of a diagnostic technique for whiplash.

## *1.4 Timeliness of the Research*

Research into whiplash has focused on its prevention, and little if any progress has been made in the identification of the pathoanatomy of whiplash. Very little literature is available regarding the use of ultrasound to assess whiplash injuries. In the past, ultrasound as a general imaging tool was neglected as those images captured were of insufficient detail to provide useful information to the clinician. Recent advances in ultrasound technology have resulted in an interest in its use for diagnosing other musculoskeletal injuries (Bianchi *et al.*, 2002; Martinoli *et al.*, 2002; Peetrons 2002). The use of ultrasound on the neck has not been exploited and the focus has been on anterior structures such as the thyroid (McIvor *et al.*,

1993) and lymph nodes (Ahuja and Ying 2002). Advances in ultrasound technology, together with the experiences gained from these research activities indicate that it is an ideal time to investigate the use of ultrasound as a diagnostic tool for whiplash injuries.

## *1.5 Project Aims and Objectives*

The aim of this research is to evaluate traumatic failure and pathological lesions in the musculoskeletal structures of the cervical spine using diagnostic ultrasound. This information will be used to establish a methodology and provide guidelines that can be used to define the presence and extent of a whiplash injury and for monitoring the recovery process.

The specific objectives to achieve this aim are as follows:

- *understand the current research relating to this study*

A literature review will be undertaken to appreciate the current state of knowledge in those research fields relating to this whiplash study.

- *establish a technique for scanning the neck*

This objective is required so that a systematic approach for the investigation of the neck can be applied.

- *assess the normal ultrasound appearance of the neck*

Knowledge of the normal ultrasound appearance of the asymptomatic subject provides a standard reference, whereby variation to this can be used as an indication of pathology.

- *investigate the ultrasound appearance of soft tissue damage in vitro*

An understanding of the appearance of soft tissue damage *in vitro* may then be extrapolated to the *in vivo* situation.

- *investigate the ultrasound appearance of soft tissue damage in vivo*

An appreciation of the soft tissue injuries that occur *in vivo* may be translated to aid assessment.

- *investigate the ultrasound appearance of bony structures*

Investigate the ability of ultrasound to visualise these structures.

- *define a methodology that can be used to record and quantify soft tissue pathology using ultrasound*

Provide a means to assess the extent of pathology and monitor changes.

- *investigate the ultrasound appearance of the neck in whiplash patients*

Apply the understanding of all objectives to identify if ultrasound can detect the pathoanatomy of whiplash.

## 1.6 Thesis Organisation

The organisation of this thesis is described, outlining what each chapter encompasses.

*Chapter 1:* Introduction

This chapter describes the background to this research and provides an overview of the work presented in this thesis. The importance of the research and its timeliness are discussed. The aims of this research project and the objectives needed to achieve these aims are identified. The layout of this thesis is described together with a brief overview of the contents for each chapter.

*Chapter 2:* Literature Review

The research included in this thesis encompasses a wide range of disciplines. This chapter reviews the literature from those research fields related to this study. The concepts, tools and techniques developed in many of these fields are well developed and we have a very good understanding of their current applications. However, this specialised knowledge has not been previously unified in the way required to satisfy the diagnostic approach in this thesis; and for this study, their combined application has been experimental. An appreciation of the scope of knowledge from these fields will allow a greater understanding of how when combined they may prove useful to answer the question posed by this thesis.

### *Chapter 3*: Methodology

This chapter discusses the ultrasound equipment used for this study, general considerations of scanning technique and operator training, image analysis programs, the use of phantoms to measure the accuracy of the equipment and concludes with a discussion on the risks and precautions of using ultrasound. Methodology and scanning technique specific to experiments will be discussed in the relevant chapters.

### *Chapter 4*: Ultrasound of the Neck

This chapter discusses the experiments that were carried out to produce an ultrasound map of the cervical region. These investigations provided the reference material essential for the investigation of pathology later in the study by providing a normal picture to which deviations could be identified. The technique used for scanning patients is established and described. Options available for image processing are also discussed.

### *Chapter 5*: Soft Tissue Damage

In this chapter, images were collected from a variety of injuries and have been presented as case studies. These case studies enabled the author to gain a practical understanding of how soft tissue injury appears and how the repair process may be monitored with ultrasound. This activity also provided an opportunity to understand patient issues and to develop patient interaction skills.

*Chapter 6*: Quantification of Pathology Using Ultrasound

This chapter discusses the approach taken to define a quantitative technique for the assessment of soft tissue pathology. A quantitative technique was developed through a series of experimental work. An initial simulation of soft tissue injury was carried out *in vitro* to confirm *in vivo* findings from case studies and form a basis for an experimental model. An investigation of quantification of these injuries follows. These experiments provide an indication of how realistic it will be to assess whiplash injuries and what is the best approach to documenting any pathological change. An assessment of using the ultrasound equipment to quantify injury damage; as well as the effects of the operator on the results, is also considered.

*Chapter 7*: Facet Joint and Intervertebral Disc

This chapter discusses the ultrasound appearance of the bony structures of the cervical spine and a technique to view them. In addition, it assesses the use of ultrasound as an imaging modality for needle guidance in interventional procedures of the cervical spine.

*Chapter 8*: Whiplash

This final experimental chapter brings together the studies outlined in previous chapters. The groundwork for the study has been described in previous chapters where the ultrasound anatomy of the neck and how it varies between individuals has been assessed, a scanning technique for the neck has been identified, soft tissue injury signs are understood and methods to quantify these changes have been addressed. This information provides the basis for collecting images and performing diagnosis on whiplash patients. This chapter describes how a culmination of the experience gained in previous experimental chapters was used in an investigation of whiplash patients. This investigation was to assess those injuries associated with whiplash that may be identified, and monitored using ultrasound.

*Chapter 9*: Discussion

This chapter describes how the research presented in this thesis has fulfilled the aims of the research project.

*Chapter 10*: Future Work

This chapter considers the continuation of the research presented in this thesis. A discussion follows on the opportunity of establishing a whiplash clinic, the purpose of which is to recruit a large sample of whiplash patients for the assessment of their injury using diagnostic ultrasound. Results from this further study would be used to determine if ultrasound is a viable diagnostic tool for whiplash injury. Based on the author's experience; suggestions are made as to how this clinic could be implemented.

*Appendix*

Presentations produced throughout the study are included here as well as additional information.

# Chapter 2: Literature Review

## *2.1 Chapter Summary*

The research included in this thesis encompasses a wide range of disciplines. This chapter reviews the literature from those research fields related to this study. The concepts, tools and techniques developed in many of these fields are well developed and we have a very good understanding of their current applications. However, this specialised knowledge has not been previously unified in the way required to satisfy the diagnostic approach in this thesis; and for this study, their combined application has been experimental. An appreciation of the scope of knowledge from these fields will allow a greater understanding of how when combined they may prove useful to answer the question posed by this thesis.

Project objectives fulfilled in this chapter:

- understand the current research relating to this study

## *2.2 Anatomy of the Neck*

An important objective of this thesis is to image the anatomical structures of the neck. An appreciation of the anatomical structures of the neck is a prerequisite to understanding: an injury mechanism, those anatomical structures at risk, what injury mechanism could predispose these structures to failure; as well as the feasibility of imaging these structures.

### *The neck*

The neck provides a conduit between the head to the trunk and limbs. The neck contains bones, muscles, vessels, nerves and other structures connecting these areas. It also contains important endocrine glands such as the thyroid. Musculoskeletal describes both the musculature and bony elements, and in the spine, these are essential for cervical stability and motion.

### *Skeleton*

The skeleton supports the neck, protects the spinal cord and facilitates movement and posture. The neck consists of the hyoid bone, manubrium of the sternum, clavicles and seven cervical vertebrae. The cervical spine consists of seven vertebrae, including three atypical and four typical vertebrae. The typical vertebrae, C3-C6 are composed of a body, an arch and various processes (*fig. 1*). The weight bearing portion of the vertebra is called the body. The spinal cord is protected by the vertebral arch and the dorsal part of the body, which produce an opening called the vertebral foramen. The vertebral foramina of adjacent vertebrae combine to form the vertebral canal which contains the spinal cord. The arch may be considered as two halves consisting of a pedicle which attaches to the body and a lamina which continues dorsally from the pedicle to join the lamina on the opposite side. A transverse process projects from each side of the arch between the lamina and pedicle and a single bifid spinous process projects at the junction between the two lamina. These processes are for articulation and attachment of soft tissue. The spinous process may be seen and palpated as a series of bumps down the midline of the back and thus provide a useful landmark. Spinal nerves exit the spinal cord through the intervertebral foramina which are formed by notches in the pedicles of adjacent vertebrae. In each transverse process is a transverse foramen that allows passage of the vertebral arteries to the head. Additional movement and support of the vertebral column is made possible by vertebral processes. Each vertebra has a superior and an inferior articular process. Where the superior process of one vertebra articulates with the inferior process of the next superior vertebra a joint called a facet joint is produced. This overlap increases the rigidity of the vertebral column. The first two vertebrae are specialised. The atlas, the first cervical vertebra, holds up the head. It has no body and no spinous process but has large superior articular facets where it joins the base of the skull. This joint allows the 'yes' motion. The second vertebra is the axis and allows a considerable amount of rotation to produce a 'no' motion. The axis has a highly modified process on the superior side of its small body called the dens. The dens fits into the enlarged vertebral foramen of the atlas, and the atlas rotates around this process. The spinous process of the seventh cervical vertebra is not bifid and is quite pronounced and can often be seen and felt as a bump between the shoulders, providing another useful landmark.

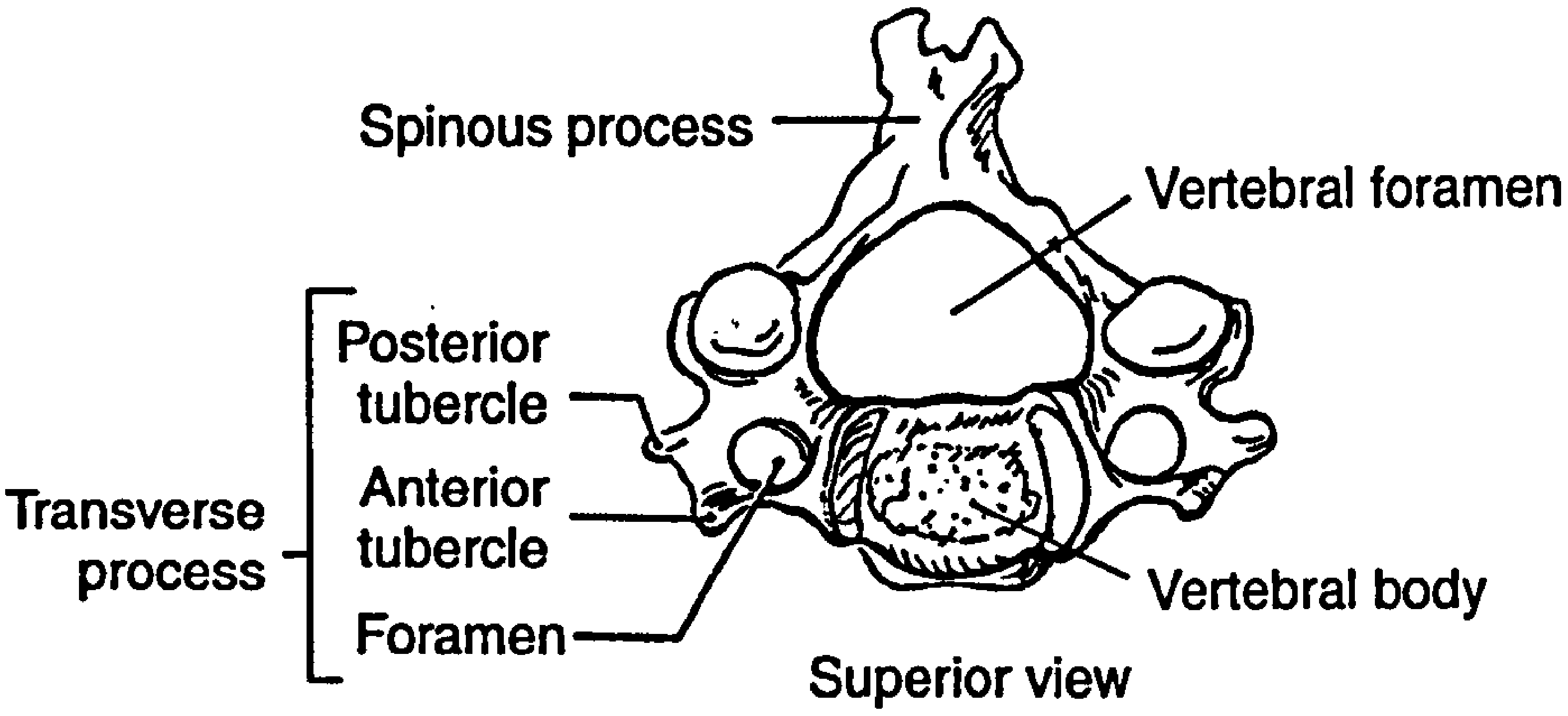

**Figure 1: Typical cervical vertebra**

*Joints of the cervical spine*

Movement of the cervical spine is enabled by joints allowing articulation of the skeletal elements. Joints of the vertebral column include joints of the vertebral bodies (intervertebral disc, uncovertebral joint), joints of vertebral arches (facet joint) and craniovertebral joints (atlantooccipital, atlantoaxial).

*Joints of the vertebral bodies*

*Intervertebral disc*

The intervertebral disc forms a joint with adjacent vertebrae called an intervertebral symphysis. A symphysis is the name given to a type of joint that consists of fibrocartilage uniting two bones. The intervertebral disc is interposed between the bodies of adjacent vertebrae providing a strong attachment between vertebral bodies (*fig. 10*). The disc is designed for weight bearing and strength. There is no disc between C1 (atlas) and C2 (axis) vertebrae.

An intervertebral disc consists of an outer fibrous part, the anulus fibrosus. The anulus fibrosus forms a ring consisting of concentric lamellae of fibrocartilage forming the circumference of the disc. The anulus fibrosus surrounds the nucleus pulposus, the gelatinous central mass. The nucleus pulposus forms the central core of the disc; it is more cartilaginous than fibrous and is normally highly elastic in young people. The disc has a high water content that is maximal at birth and decreases with advancing age. These progressive changes in elasticity and water content may predispose the disc to injury. The nucleus pulposus acts as a shock absorber for axial forces and like a semifluid ball-bearing during movement. It is avascular and receives nourishment by diffusion from blood vessels at the periphery of the anulus fibrosus and vertebral body.

### *Uncovertebral joints (Joint of Luschka)*

These synovial joints are found at the lateral and posterolateral margins of the discs, between the uncinate processes of C3 to C6 vertebrae and the bevelled surfaces of the vertebral bodies superior to them.

### *Joints of vertebral arches*

### *Facet joint (also called zygapophyseal joint, z-joint)*

The joint between adjacent vertebrae is the facet joint. This joint permits gliding movements between vertebrae, where the shape and disposition of the articular surfaces determines the type of movement possible. Facet joints are a synovial joint; a type of joint containing synovial fluid which allows considerable movement between articulating bones (*fig. 2 and fig. 3*). The articular surface of the bone is covered by smooth hyaline cartilage which aids movement, reduces friction and is resilient to wear. The joint is enclosed in a collagenous capsule. The synovial membrane covers the inside of this capsule and secretes synovial fluid to keep articulating surfaces lubricated. The capsule is richly innervated and this supports the notion of the facet joint as a pain generator. The capsule is not very strong and the surrounding ligaments running outside the capsule hold the bones together. Muscles provide the forces that produce movement of the joint. The orientations of the vertebrae of the facet joint are of particular note. The inferior facet of the vertebrae above is directed anteriorly and inferiorly, while the superior facet of the subjacent vertebrae is oriented posteriorly and superiorly. The inclination becomes more vertical at the lower cervical facet joints. The cervical facet joints are relatively flat with only minimal concavity or convexity. It is these features and their arrangement that is believed to predispose this joint to disarticulation and stretching of the capsule in a whiplash event.

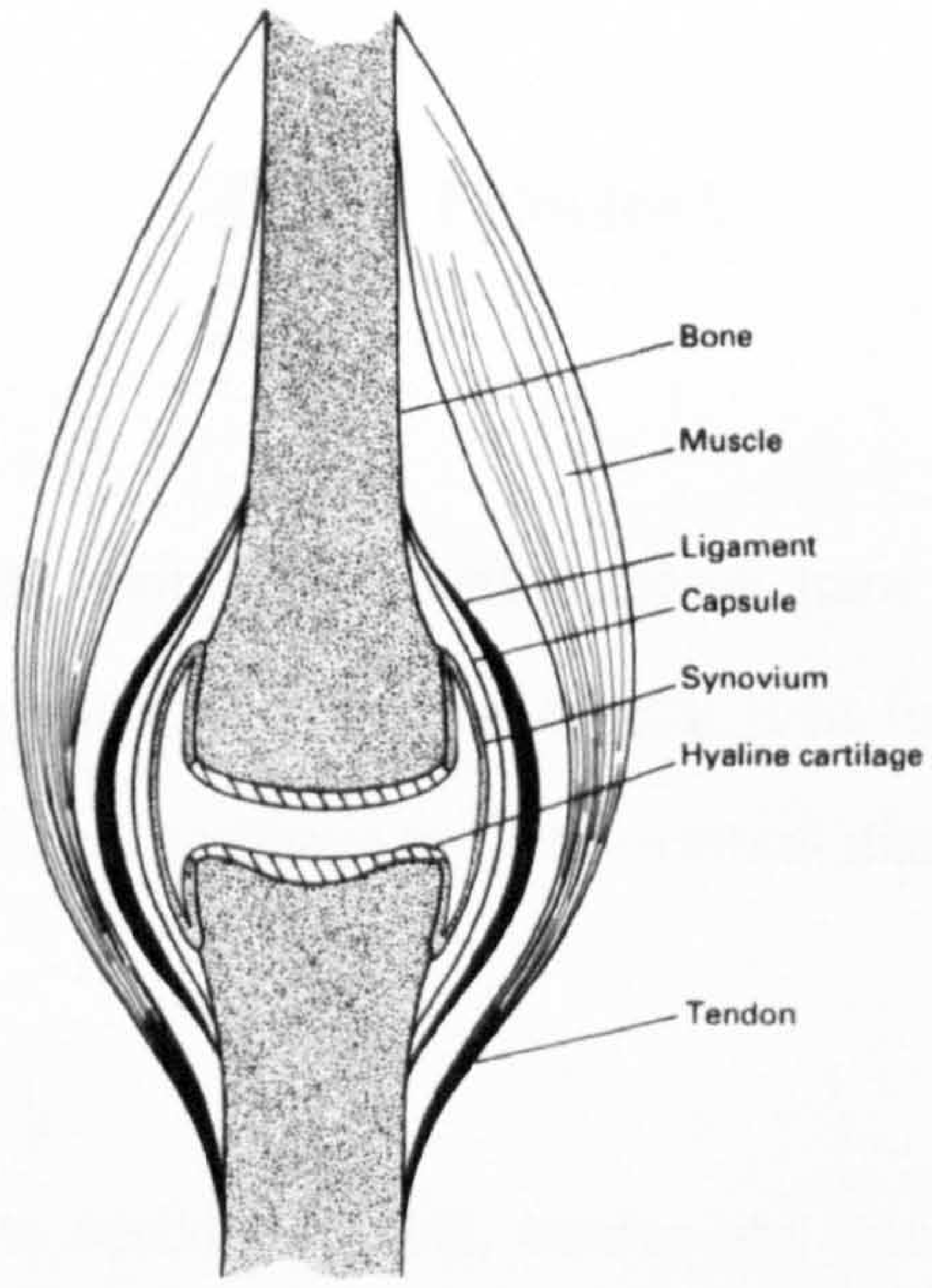

**Figure 2: Schematic of a synovial joint**

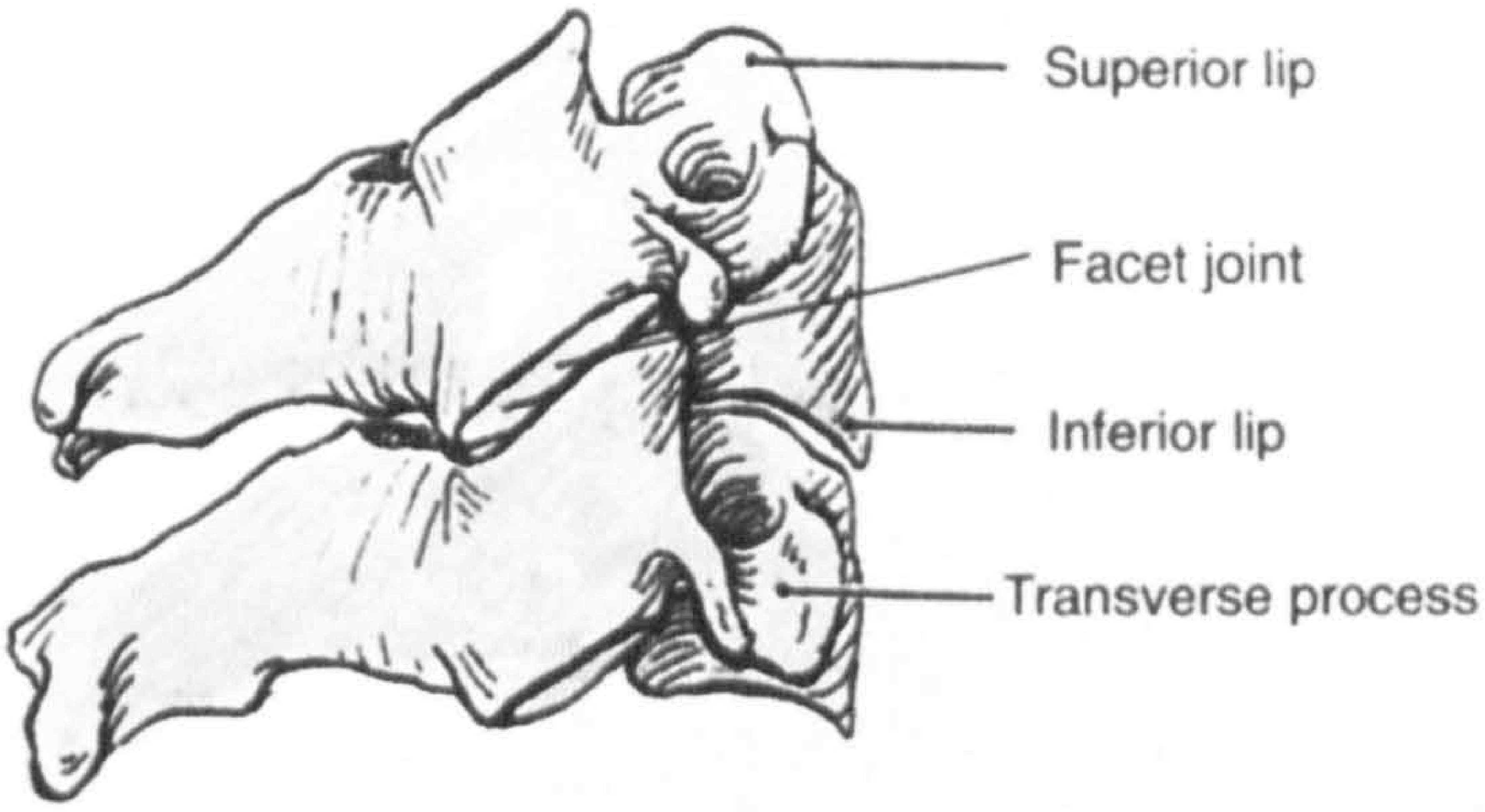

**Figure 3: Facet joint**

*Craniovertebral joints*

There are two craniovertebral joints, the atlantooccipital joint (between the skull and C1 vertebra) for flexion and extension; and the atlantoaxial joint for rotation (between C1 and C2). These are both synovial joints and have no intervertebral disc.

*Soft tissue of the neck*

Soft tissue is the term used to describe muscle, tendon and ligament tissue. These are the tissues responsible for supporting and creating movement of the skeletal components.

***Muscle***

Skeletal muscle is the connective tissue that produces the forces responsible for movement (*fig. 4*). It is contractile and elastic in nature. Muscle is composed of muscle fibres, connective tissue, blood vessels and nerves. The distribution of fibres within a muscle reflects its function. Two main types of muscle fibre exist, these are Type I (slow twitch) fibres which perform slow repetitive contractions and maintain posture. The other fibre is Type II (fast twitch) fibres which produce rapid movement but fatigue more easily. Muscle is attached to bone and other connective tissue by tendon.

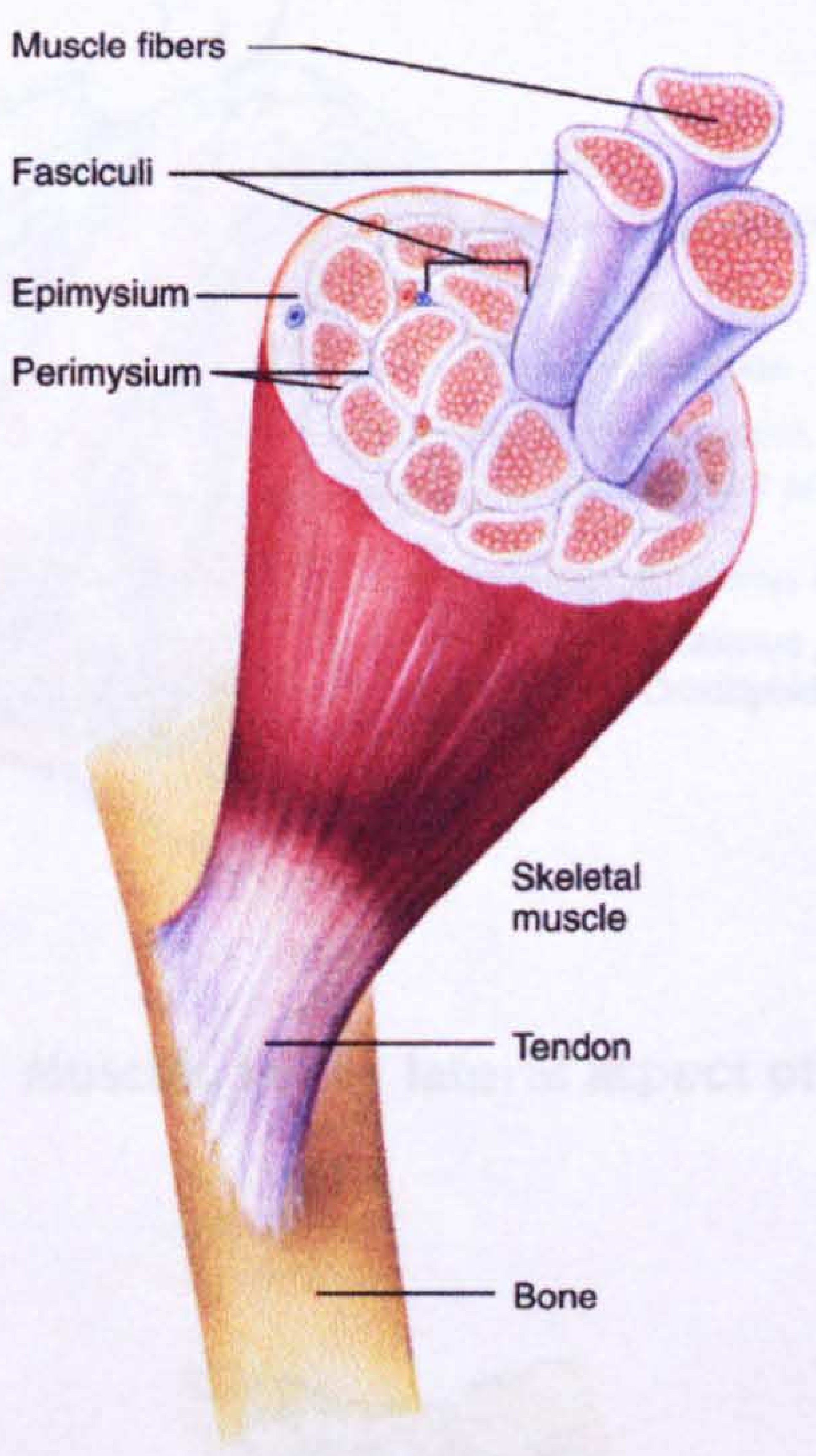

**Figure 4: Typical joint complex**

Movement of the head and neck is achieved by particular muscles. An understanding of how these muscles function assists the identification of what may be damaged following injury when a particular movement is limited or painful. Flexion is achieved by the flexors of the head and neck which lie deep within the neck along the anterior margins of the vertebral bodies. Extension of the head is by posterior neck muscles. Rotation and abduction of the head are accomplished by muscles of both the lateral and posterior groups. Adduction of the head is accomplished by abductors of the opposite side.

The following figures (*figs. 5-9*) illustrate the muscles of the cervical region and further details of these muscles can be found in Appendix B. Table 1 describes the principal muscles producing movement of the neck.

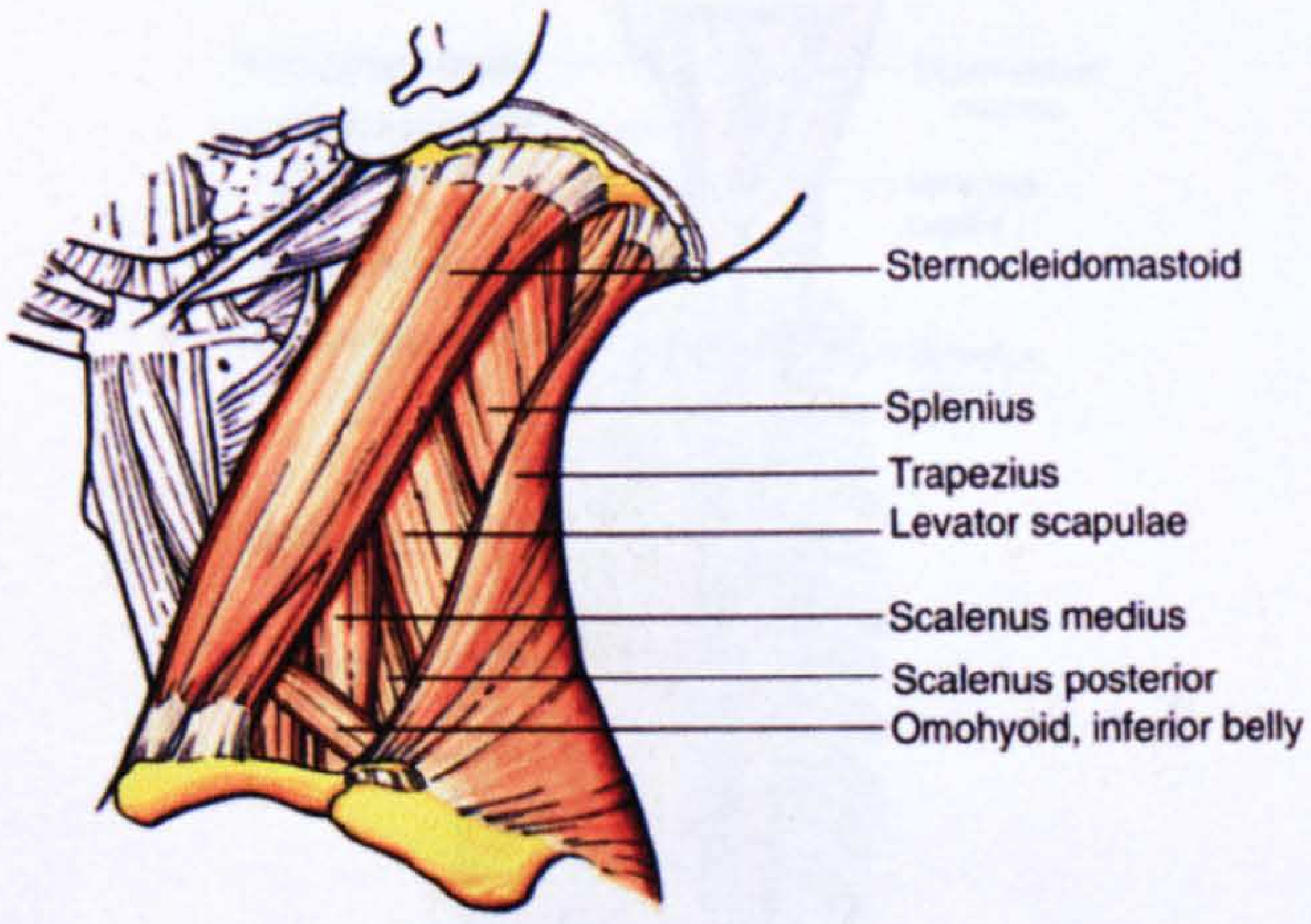

Figure 5: Muscles in the lateral aspect of the neck

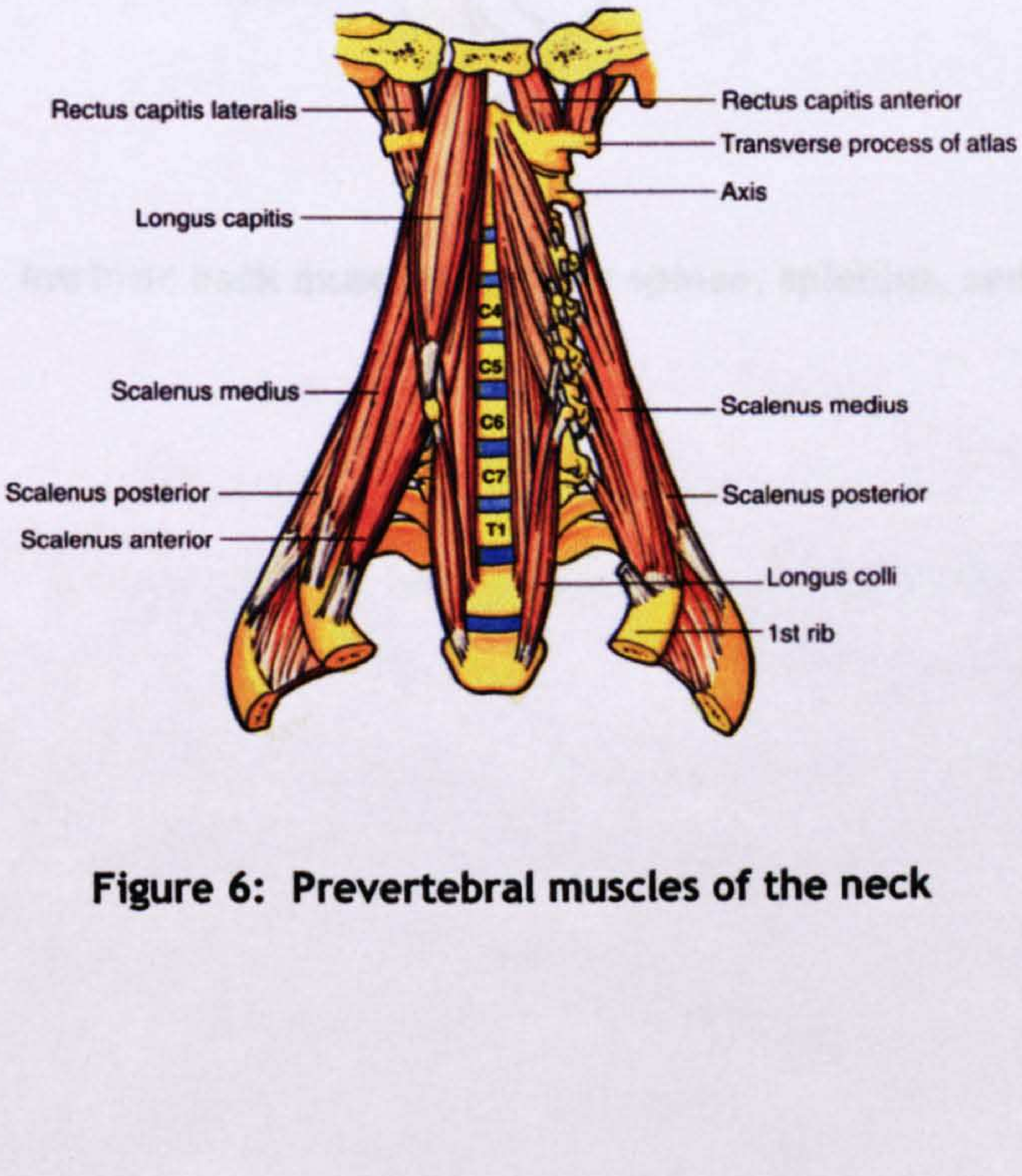

Figure 6: Prevertebral muscles of the neck

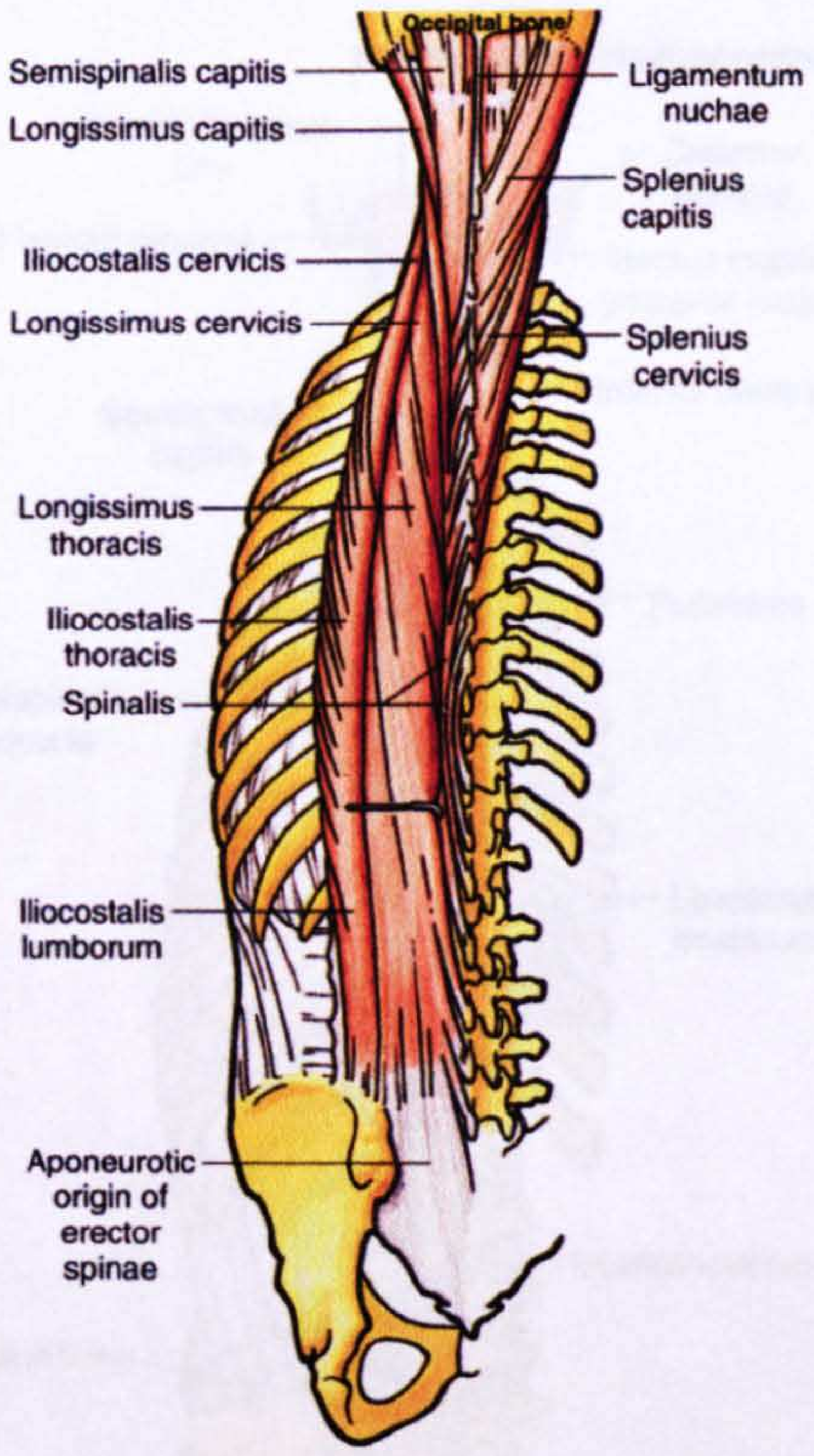

**Figure 7: Intrinsic back muscles: erector spinae, splenius, semispinalis**

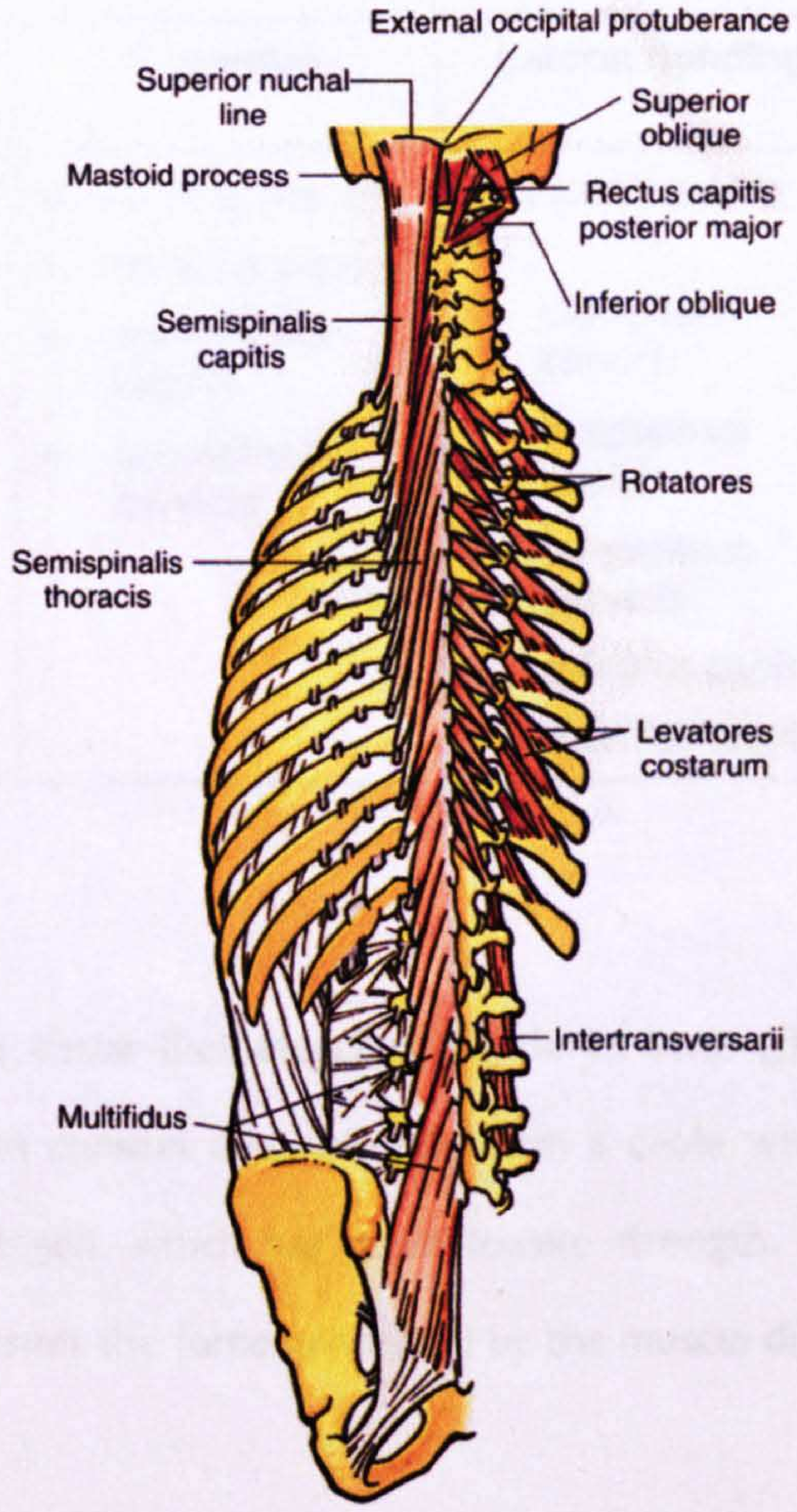

**Figure 8: Intrinsic back muscles: transversopinalis**

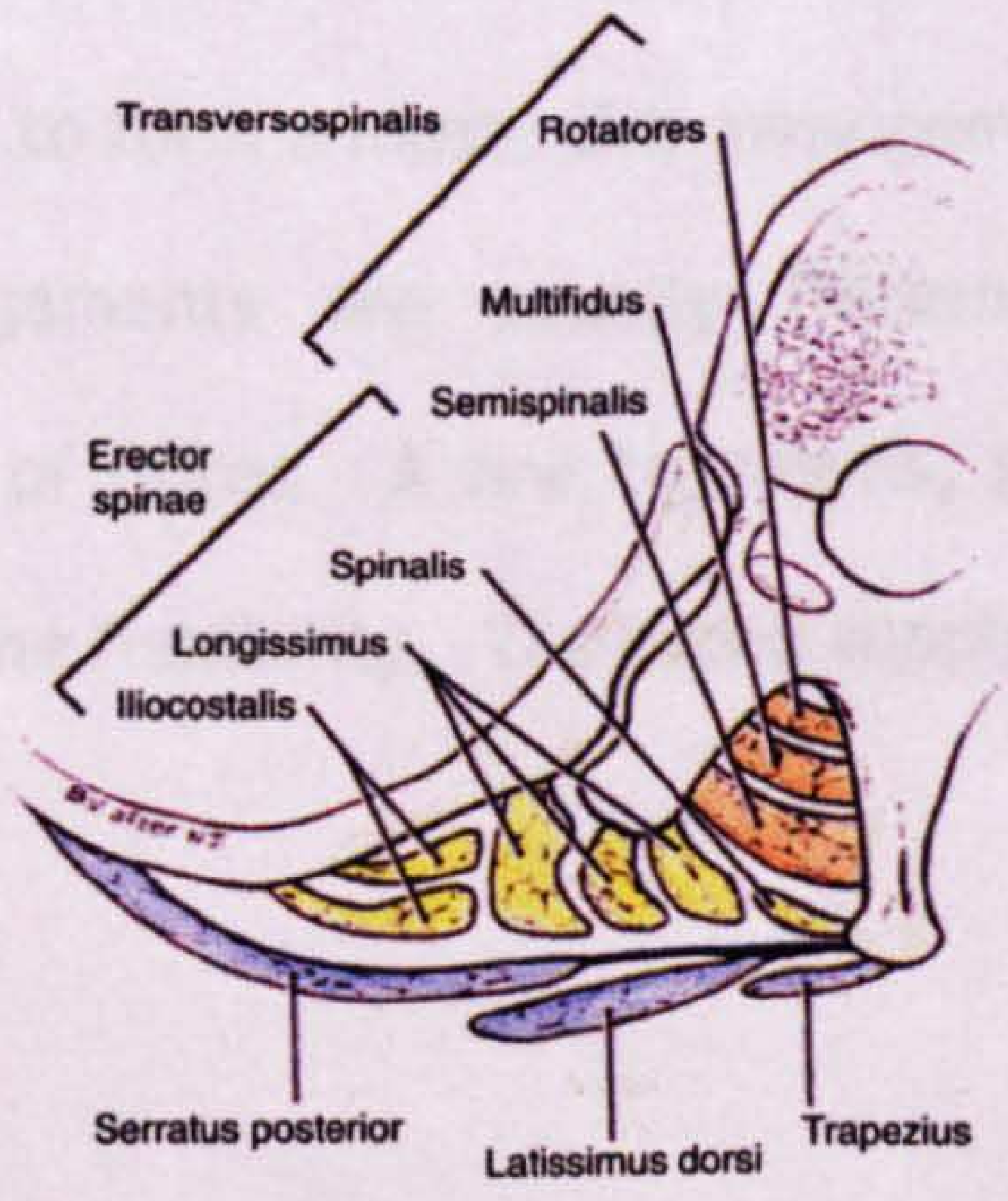

**Figure 9: Transverse section of back muscles**

**Table 1: Principal muscles producing movement of cervical intervertebral joints**

| Flexion | Extension | Lateral Bending | Rotation |
|---|---|---|---|
| *Bilateral action of:*<br>• longus colli<br>• scalene<br>• sternocleidomastoid | *Bilateral action of:*<br>• splenius capitis<br>• semispinalis capitis<br>• semispinalis cervicis | *Unilateral action of:*<br>• iliocostalis cervicis<br>• longissimus capitis<br>• longissimus cervicis<br>• splenius capitis<br>• splenius cervicis | *Unilateral action of:*<br>• rotatores<br>• semispinalis capitis<br>• semispinalis cervicis<br>• multifidus<br>• splenius cervicis |

### *Tendon*

Tendon is the connective tissue that attaches muscle to bone (*fig. 4*). Tendon consists of collagen fibres that run in parallel and normally form a cable with a circular cross section. The fibres consist of collagen, which has great tensile strength. Tendons are only slightly elastic and therefore transmit the force generated by the muscle directly to the bone.

### *Ligaments*

Ligaments attach bone to bone and provide stability; they are only slightly elastic in nature (*fig. 10*) (*see Appendix B*). In structure, ligaments are similar to tendon but of a smaller scale. Ligaments consist of dense bundles of collagen fibres running parallel to the line of pull that interweave to some extent to form a mesh; this arrangement resists tension or distractive forces. In cross-section, ligaments are usually flattened and made up of several interconnected parallel sheets of fibres. A few ligaments, such as the ligamentum flavum, contain elastin which allows some flexibility. The blood supply to ligaments is sparse.

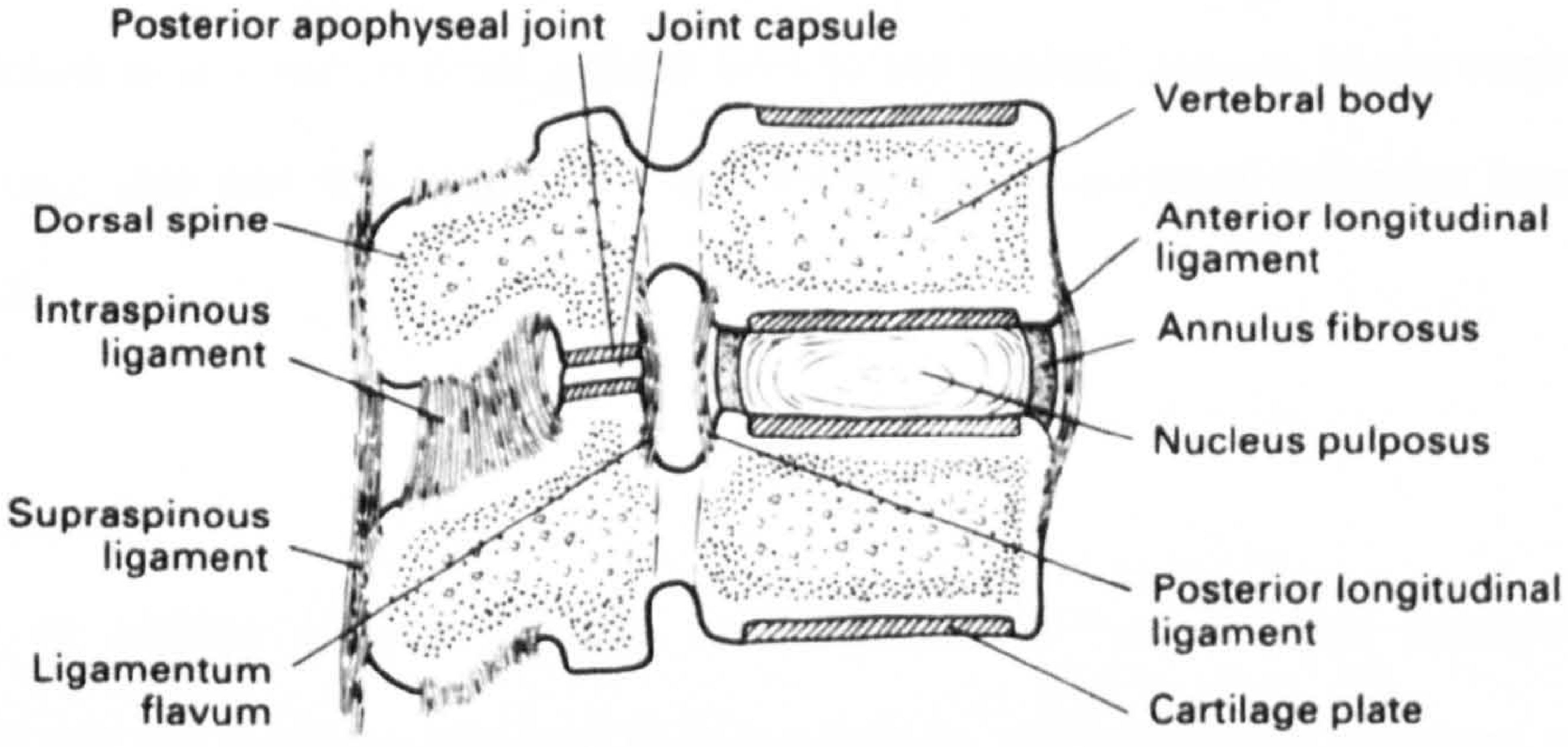

**Figure 10: Ligaments of the neck**

### *Skin and fascia*

The boundary between the neck and the environment is formed by skin. Layers of cervical fascia compartmentalise the structures of the neck. These fascia allow structures to pass over each other during swallowing and movement of the neck.

#### *Superficial fascia (subcutaneous tissue)*

Superficial fascia is a thin, loose fatty layer of connective tissue that lies between the dermis of the skin and investing layer of deep cervical fascia. It contains cutaneous nerves, blood, lymphatic vessels, variable amounts of fat, and anteriolaterally contains the platysma muscle.

#### *Deep fascia (muscular fascia)*

The deep fascia consists of three thin flat sheets of interweaving collagen fibres. These sheets are called: investing, pretracheal, and prevertebral. These sheets support the viscera (e.g. thyroid gland), muscles, vessels and deep lymph nodes.

### *Blood vessels and nerves*

Blood vessels are clearly visible on ultrasound, and the pulsatile nature of arteries can be observed making them ideal landmarks. The common carotid artery is one of the major arteries of the neck and its bifurcation makes this vessel a suitable landmark. The vagus nerve exits from the jugular foramen and is carried within the carotid sheath along with the common carotid artery and internal jugular vein to the thorax. Nerves of the neck arise from the spinal cord and exit the vertebral canal via the intervertebral foramina forming spinal nerves C1-C8.

### *Range of motion*

The range of motion of the cervical spine should be noted when considering injury mechanisms and the mobility afforded is dependent on the anatomical features of the neck. The characteristics of the vertebrae forming the cervical spine allow a great range of movement. Muscle bulk is minimal in the neck region which increases mobility. The range of motion is dependent on the age and physical ability of the subject. In theory, the head may be flexed until the chin rests on the sternum and the shoulder limits lateral flexion. A well adjusted car head restraint will prevent excessive extension. There are no anatomical structures impeding extension and rotation of the neck and it is possible that there is a risk of movement beyond the natural range of motion in these directions which would result in injury to associated structures. Flexibility is also determined by the elasticity of soft tissues and therefore exceeding our own inherent range of motion could lead to damage of these structures even before the range of movement is met.

### *Triangles of the neck*

For the description of cervical anatomy, each side of the neck is divided into anterior and posterior triangles by the obliquely situated sternocleidomastoid muscle (*fig. 11*).

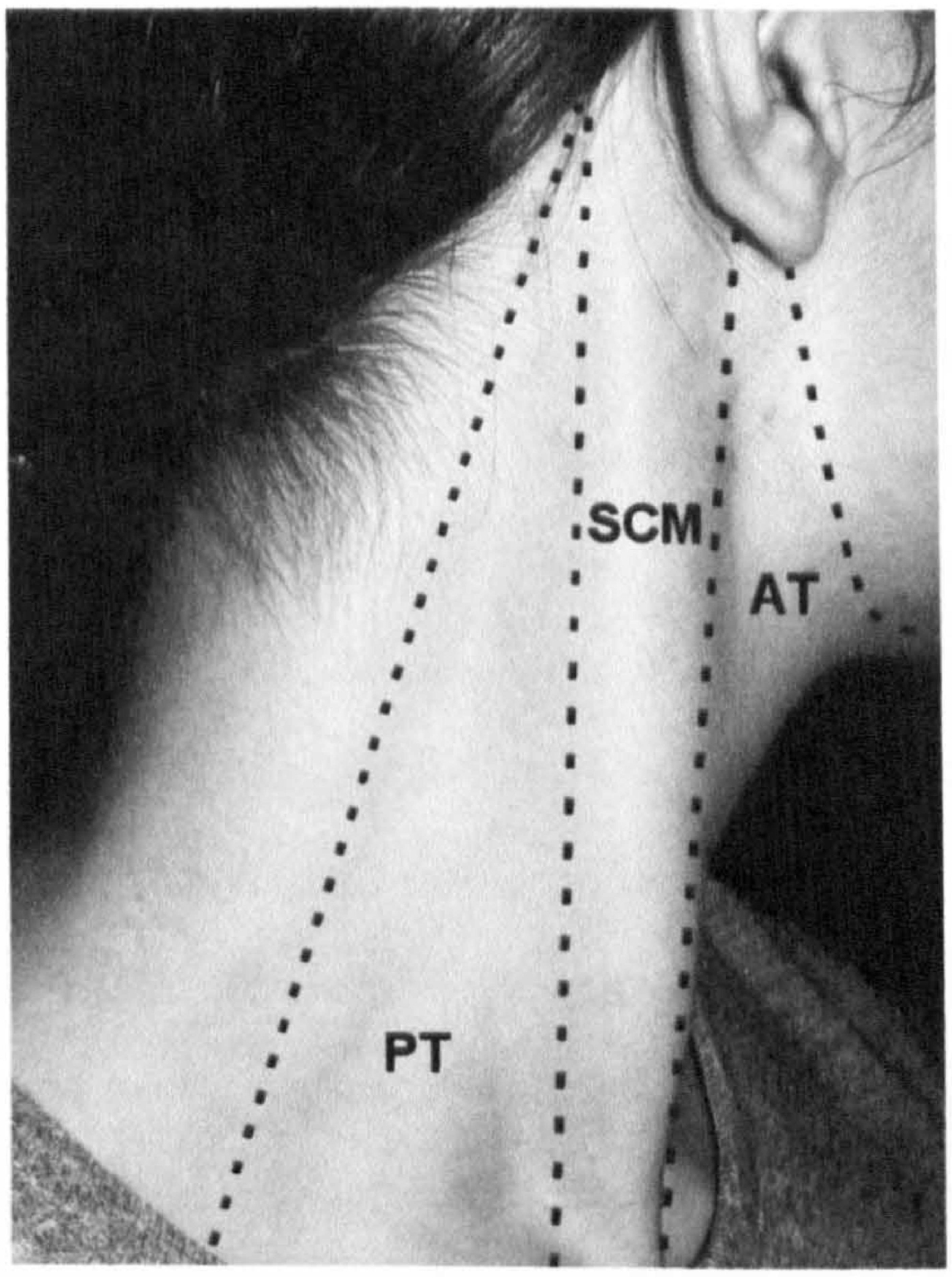

**Figure 11: Triangles of the neck**

The neck is divided into descriptive triangles to aid orientation.
(AT = anterior triangle, PT = posterior triangle, SCM = sternocleidomastoid muscle)

## *2.3 Whiplash Injury*

This section defines whiplash, discusses the aetiology of whiplash, its prevalence and the biomechanics behind the injury mechanism. Possible hypotheses for the mechanisms that result in whiplash pathology are considered.

***What is whiplash?***

Early medical reports refer to whiplash as 'railway spine'. This term was used in the 19th century to describe the persistent pain and other 'subjective symptoms' reported by railway passengers and personnel which had resulted from minor railway crashes. The modern term of whiplash was first used by Crowe in 1928 and although the term describes a mechanism of injury and not an actual illness, it is now used freely to describe both situations; debate continues as to how the term should be used. Colloquially, the term whiplash is used to describe a mechanism whereby the cervical spine undergoes a motion of rapid acceleration and deceleration, most typically as a result of motor vehicle rear-end impact. Whiplash is also used to describe the injury state of a person who has undergone this mechanism. The abundance of literature produced on whiplash, led to an initiative called The Quebec Task Force being set up to produce a comprehensive monograph on whiplash-associated disorders (Spitzer *et al.*, 1995). The Quebec Task Force defined whiplash as "an acceleration-deceleration mechanism of energy transfer to the neck". For the purpose of this thesis, the term whiplash will be used to describe both the mechanism and the injury, as this is generally how it is accepted. The whiplash injury often manifests as varying degrees of discomfort in the neck and results in a variety of signs and symptoms referred to as whiplash-associated disorders (Spitzer *et al.*, 1995). In terms of diagnosis, fractures of the vertebrae are rare (Bogduk 1986) but may be easily imaged by using such modalities as plain radiography, magnetic resonance imaging and computed tomography scans. However, the majority of injuries are more likely to be soft tissue trauma, which is not always identifiable, and as patients rarely undergo surgery, these injuries often remain undetected (Bogduk 1986). There is no consensus on the mechanism of injury or cause for the chronic pain associated with whiplash and no means of diagnosis although whiplash injuries can cause a lifetime of pain and suffering.

### *Whiplash aetiology*

Whiplash injury is typically the result of an acceleration-deceleration injury. Most often this is the consequence of rear-end or side-impact motor vehicle collisions, but the injury can happen during diving accidents and other mishaps (Spitzer *et al.*, 1995). This study will focus on those sufferers of road traffic accidents where the collision is a rear-end impact; by using this classification the injury mechanism is kept reasonably constant.

### *Prevalence*

Determining the exact prevalence of whiplash in the UK is difficult, as incident figures are not published. Potential sources for obtaining incident information are the Department for Transport, insurance companies and the National Health Service. The author approached the

Road Accident Statistics Department of the Department for Transport, UK; who hold records on vehicle accident information but found they did not have a classification category specifically for whiplash and therefore exact figures of its incidence could not be provided (Department for Transport personal communication 2004). The National Health Service has no formal definition of whiplash, and it is the author's experience of working in a hospital accident and emergency department that the term is not used because of its litigation association and sensitivity. Therefore, no information could be provided from hospital figures. A provider of risk assumption for the global insurance and capital markets; report that incident figures from the insurance industry suggest that the UK experiences in excess of 250,000 claims each year relating to whiplash; with an estimated annual cost to the economy of at least £1 billion (PartnerRe Ltd, 2000). This figure does not take into account the unknown number of sufferers not claiming.

Neck injuries are the primary complaint from car accidents (Tsuchisashi *et al.*, 1981, Olney *et al.*, 1986, Maag *et al.*, 1990) with 65% of crash victims reporting neck injuries (Olney *et al.*, 1986). Neck pain develops in 56% of patients involved in a front or side-impact accident (Deans *et al.*, 1986). Women are more at risk of whiplash injury than men (Spitzer *et al.*, 1995, Versteegen *et al.*, 2000) and this is possibly because women's necks tend to have less muscle development and are long and slender. The typical patient with a neck injury is a middle aged woman who has worn a seat belt when involved in a low speed crash (Otremski *et al.*, 1989).

Based on these estimates, the high prevalence and cost to the economy of whiplash, it was decided that an investigation into determining its diagnosis could have significant benefits to both victims and a variety of interested organisations from the medical, commercial and legal communities.

### *Biomechanics - What is the whiplash mechanism?*

Simulated whiplash events have been undertaken in an attempt to determine the whiplash mechanism. An understanding of injury mechanisms provides an indication of potential injury sites and the anatomical elements prone to injury. Experimental models of whiplash have included studies using human volunteers (Severy *et al.*, 1955), anthropomorphic dummies (Severy *et al.*, 1955), cadavers (Clemens and Burow 1972, Deng *et al.*, 2000, Luan *et al.*, 2000), animals (McNab, 1964) and mathematical models (Martinez and Garcia 1968).

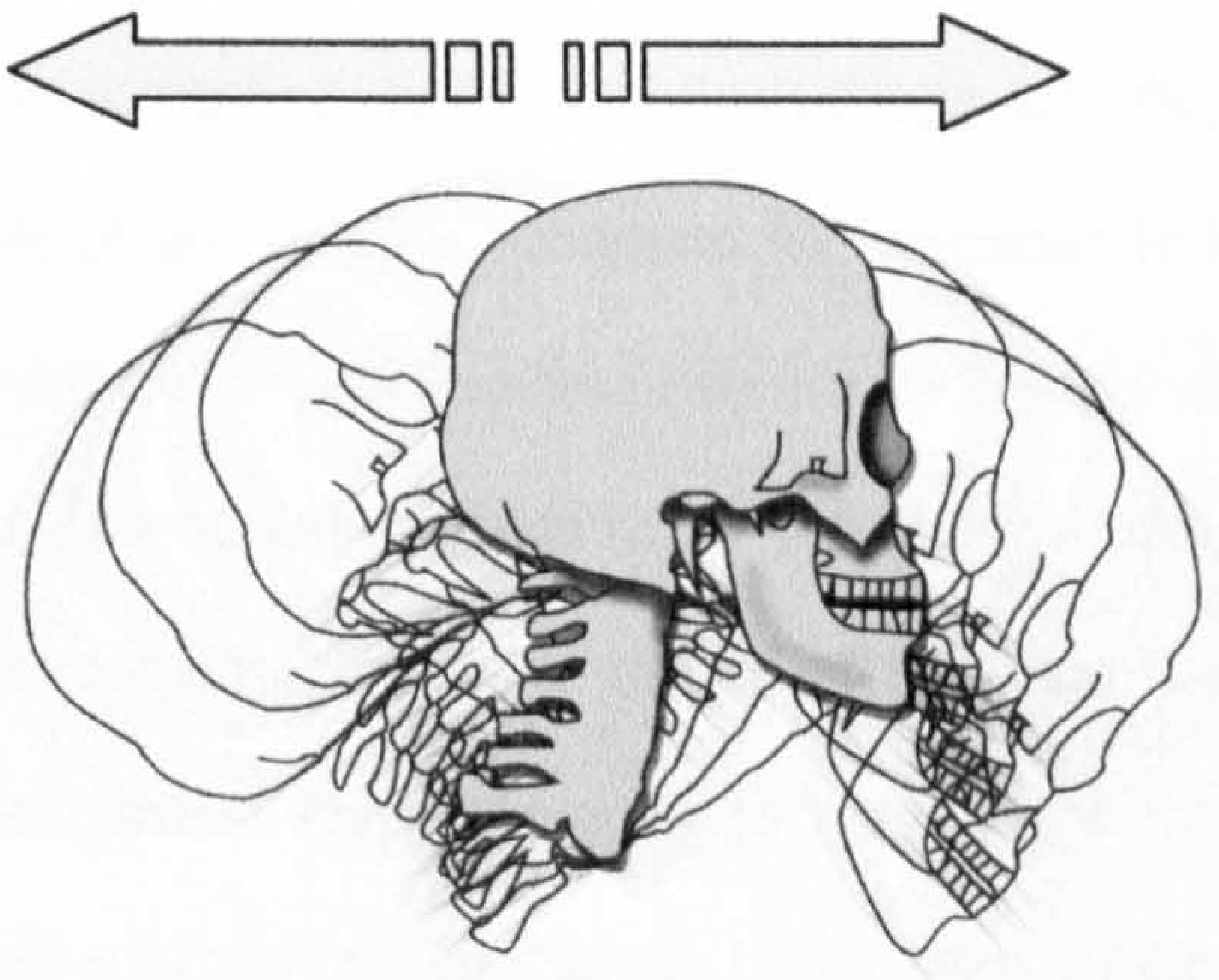

**Figure 12: Whiplash mechanism**

During a whiplash event, the motion of the torso precedes that of the neck and a bull whip effect is generated in order for the head to remain attached to the torso (*fig. 12*). This shear force is generated at each cervical level and is transmitted up the cervical spine until it reaches the occipital condyles; here the force can act on the head to cause it to move forward. This shearing action results in relative motion between adjacent vertebrae which are most pronounced at the lower cervical levels where the facet angle is less steep and where most pain is felt. There is no consensus as to how this motion of the head and neck causes whiplash-associated disorders but a number of hypotheses have been put forward. These hypotheses will be considered in this research as they provide an indication of the type of injury to expect when investigating the whiplash patients. An early hypothesis identified neck hyperextension as the injury mechanism (MacNab *et al.*, 1965). Hyperextension of the neck, even at low velocity rear-end collisions, can produce forces that result in musculoligamentous tears, haemorrhage, disc fibre damage and vertebral body fracture (Dunn and Blazar 1987). Another hypothesis suggests that pain emanates from facet joints, and a few ideas have been put forward as possible explanations for the facet joint as a source of pain. One study suggests the occurrence of a facet joint impingement injury mechanism, where a portion of the facet capsule becomes trapped between the facet joint surfaces (Ono *et al.*, 1997 and Yoganandan *et al.*, 1998). Another study attributes facet joint pain to the facets compressing into one another (Kaneoka *et al.*, 1999), while another study suggests that the facet capsule could be stretched during whiplash (Yang and Begeman 1996, Deng *et al.*, 2000). Another hypothesis of an injury mechanism for whiplash is that pressure increases in the spinal canal during whiplash, which applies pressure on the nerve roots (Aldman 1986) and dorsal root ganglion which causes pain signals to be sent to the brain (Svensson *et al.*, 1993). The hypothesis that soft tissue damage is the source of the pain has received little attention in recent years, with the current trend towards investigations into facet joint injury. By considering the role of the anatomical structures, it becomes evident why this thesis focuses on the soft tissues. The spatial position and active motion of the head is mostly under the control of the cervical muscles. The osteoligamentous region of the neck is capable of supporting only one fifth to one fourth of the weight of the head (Panjabi 1998) thus illustrating the role of muscle control. Without muscle control, the osteoligamentous structures are unable to hold the head in position, and certainly can not resist the forced motion that is created in rear-end impacts. Electromyographic studies measure the activity of muscle and have shown that the cervical muscles appear to be the first in the line of defence during a whiplash mechanism and are therefore likely to be injured first (Kumar *et al.*, 2002). Whiplash injuries are likely to be complex and progressive; with muscle followed by ligament, facet joints and the brain being injured in sequence with increasing magnitude of impact (Kumar *et al.*, 2002). Muscles maintain posture; when subjected to mechanical perturbation they respond to counteract the perturbation or restore posture. The harder the perturbation, the greater the muscle response; the higher muscular response is associated with greater tension in the muscle as greater tensile load in the tissue (Kumar *et al.*, 2002). Studies of muscle response in a whiplash event have highlighted key structures of interest. Investigations of forces produced in muscle during a rear-end crash have found the sternocleidomastoid muscle to be activated before the paraspinal muscles (Brault *et al.*, 2000, Kumar *et al.*, 2002) and the sternocleidomastoid responds with greater relative contraction than either the trapezius or splenius capitis muscles (Kumar *et al.*, 2002). Another study noted that the greatest deformation occurred in the longus colli muscle followed by the scalenus anterior then the longus capitis, sternocleidomastoid, and scalene posterior muscles (Deng and Goldsmith, 1987). When impact was offset 45° (posterolateral impact), the effect was to shift the burden of the impact over more muscle groups (Kumar *et al.*, 2004a).

It is important to be aware of the characteristics of the accident as these will influence the whiplash mechanism. In a low speed collision of 15mph the head can accelerate with enough force to cause injury to structures of the cervical spine (Severy *et al.*, 1955). The forces in the neck may be affected by human factors such as seating posture (Deng and Goldsmith 1987, Deng *et al.*, 2000), position of the head and neck (Ono *et al.*, 1997; Deng and Goldsmith 1987; Kumar *et al.*, 2004b), awareness of impending collision (Kumar *et al.*, 2002) and head restraint position.

### *What is damaged?*

The whiplash injury often manifests as varying degrees of discomfort in the neck and results in a variety of signs and symptoms referred to as whiplash-associated disorders (Spitzer *et al.*, 1995). In the Quebec Task Force report on Whiplash Associated Disorders, it was said that because of limitations in current diagnostic techniques, the exact anatomical site of injury remains largely unknown (Spitzer *et al.*, 1995). Injuries described as being a result of whiplash range from a subtle injury such as muscle strain (McNab 1964) to gross injuries such as fracture (Dunn and Blazar 1987). Symptoms may span many organ systems resulting in a variety of different problems (*see Table 2*).

**Table 2: Main complaints associated with whiplash**

| Symptom | Patients (%) |
|---|---|
| Neck pain | 88-100 |
| Headache | 54-66 |
| Shoulder pain | 40-42 |
| Dizziness | 17-25 |
| Paresthesias | 13-62 |
| Visual disturbance | 8-21 |
| Auditory disturbance | 4-18 |

(from PartnerRe Ltd. 2000)

Diagnosis of whiplash must include an appreciation of structures susceptible to injury within each phase of the injury mechanics. During the extension phase of whiplash the anterior column is strained, while posterior elements are compressed. At the craniocervical junction, the head resists forward acceleration transmitted by the neck. During the flexion phase of whiplash: posterior structures, including the posterior longitudinal ligament, interspinous ligaments, ligamentum nuchae, muscles and facet joint capsule are subjected to strain while intervertebral discs and bodies undergo compression (Johnson 1996; LaBan 1990 and Panjabi *et al.*, 1998).

Experimental studies have attempted to define those structures that are damaged following a whiplash event and an appreciation of these findings may provide clues as to the areas to expect pathological changes to occur when assessment is made using ultrasound. Musculature damaged in whiplash injuries include the sternocleidomastoid, trapezius, scaleni, (McNab 1964; Jeffreys and McSweeney 1980; Cailliet 1991); splenius capitis, semispinalis capitis, longissimus capitis, rhomboid, rectus capitis, superior and inferior oblique capitis, longus colli, and longus capitis muscles (Jeffreys and McSweeney 1980; Cailliet 1991). Hyperflexion neck injuries primarily produce ligamentous-disc trauma (Unterharnscheidt 1986; Yoganandan *et al.*, 1989) and damage to nerve roots, the posterior longitudinal ligament, the interspinous ligament, and facet joints (Unterharnscheidt 1986). Posterior muscle ruptures tend to occur near the facet joints (Jónsson *et al.*, 1991). Cervical extension experiments in animals show tears of the longus colli muscle with occasional injury to the cervical sympathetic plexus (MacNab 1971). Anterior longitudinal ligament tears also have been associated with separation of cervical discs from vertebrae (Olney *et al.*, 1986). Studies using magnetic resonance imaging suggest that whiplash trauma can cause permanent damage to the alar ligaments (Krakenes *et al.*, 2002) other studies disagree and state that the inherent variability in a normal population makes this an unreliable technique (Wilmink and Patijn 2001). Chronic whiplash symptoms include damage to the occipital or cerebral nerves, vertebral arterial compression and excess dilation of blood vessels (Barnsley 1995). Whiplash injuries that are more serious may also include cervical fracture and disc-vertebral body separation (Dunn and Blazar 1987).

Haemorrhages have been identified between the intermuscular fascial planes of the neck and have been associated with damage to the cervical sympathetic plexus (LaBan 1990). Haemorrhages have also been identified around nerve roots and in the adventitia of the vertebral arteries (LaBan 1990).

### *Considerations*

The aetiology, prevalence and biomechanics of whiplash have been discussed. The vastness and uncertainty of this field can be appreciated and because of this, this study is unable to take account of all hypotheses identified. This study will be limited to using ultrasound to investigate the hypothesis that soft tissue damage occurs to the neck following a whiplash event. During the assessment of whiplash patients, an appreciation of the accident event will provide an indication of the injury mechanism. An understanding of the injury mechanism will help to identify what structures have potentially been damaged.

## *2.4 Soft Tissue Damage*

The structure of soft tissue is altered following injury and during its subsequent repair. These changes can be diagnosed using ultrasound and this is discussed in a later section. This section provides a description of the physiology of these injuries and the repair process, as well as the timescale over which this occurs, will provide clues to assess the type of injury and the stage of repair.

### *Pathophysiology of soft tissue injury*

Injury causes damage to the structural elements of the tissue, such as muscle fibres, collagen or elastin, and is accompanied by rupture of capillaries, arterioles and venules (*fig. 13*). The extent of bleeding depends upon the vascularity (blood supply) of the tissue; muscle is more vascular than tendon and is therefore more likely to bleed. Bleeding into tissues acts as an irritant and increases the degree of inflammation. Inflammation is a complex network of vascular and cellular responses designed to resolve the pathologic insult and restore the anatomy to a level of physiological function identical to pre-injury status. This restoration is achieved by removing damaged tissue and regenerating normal tissue. Following injury, blood flow increases to the site of damage. White blood cells migrate towards the damaged tissue and remove the debris which consists of cell, damaged tissue and micro-organisms of other foreign matter. After twenty four to forty eight hours, the extravascular spaces are distended with white blood cells and fibrin forms the basis of the blood clot. The increase in blood flow, as well as cell proliferation or migration and an increased secretion of matrix material; causes expansion of the matrix resulting in visible swelling (Stauber *et al.* 1998) which pushes the structural tissue elements apart. The torn blood vessels are patched with platelets and fibrin; however, the extravasated blood is still present in the tissue. External signs of inflammation are heat, swelling, pain, redness and lack of function. Heat, swelling and redness are caused by vascular changes and the presences of inflammatory exudates. Pain is due to increased tissue tension and direct stimulation of pain fibres by pharmacologically active substances. Loss of function is partly due to swelling and tissue tension, which mechanically impede movement, and partly by a neurological reflex.

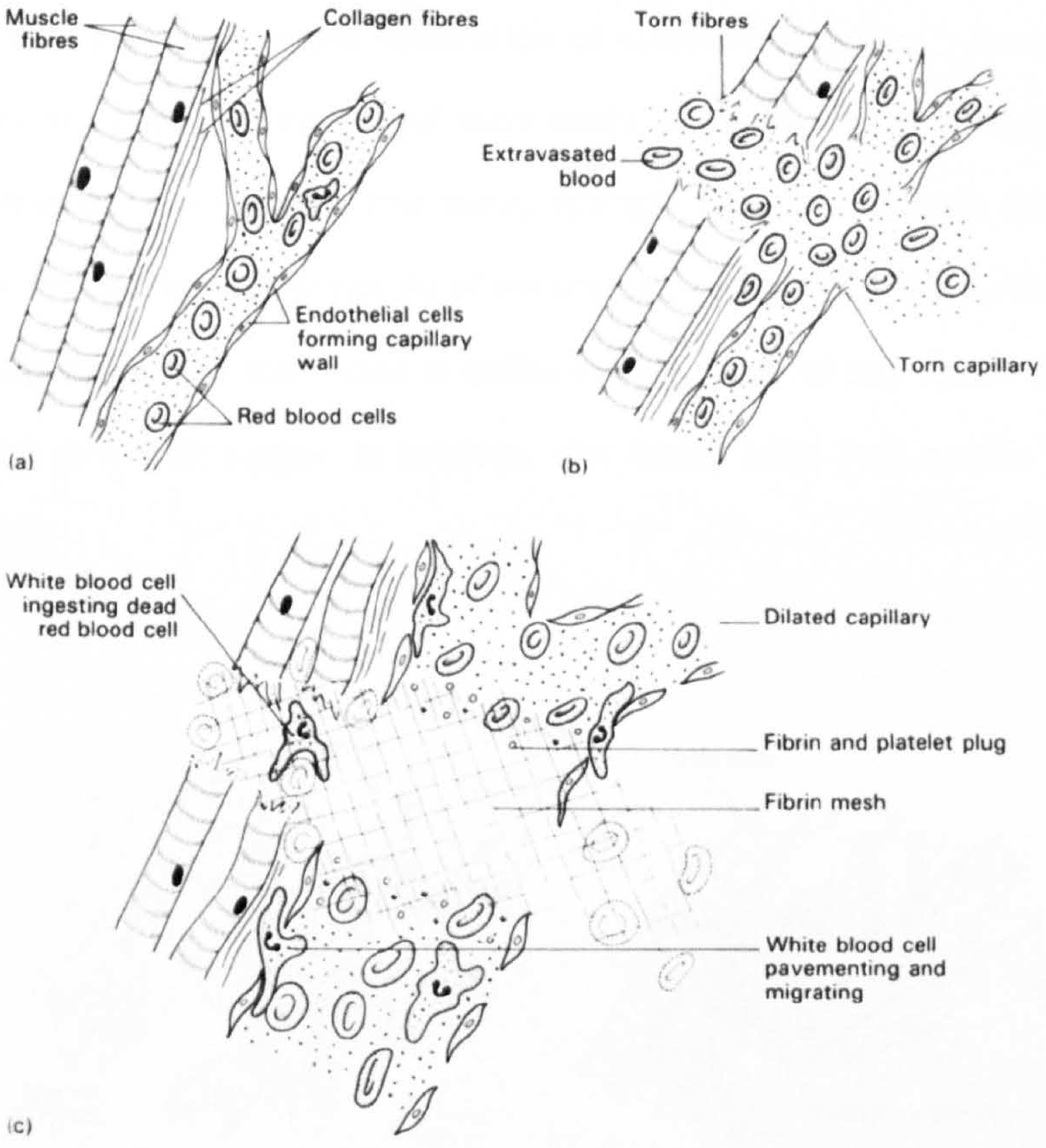

**Figure 13: Inflammatory response following soft tissue injury**

Injury causes damage to the structural elements of the tissue and is accompanied by rupture of surrounding blood vessels.

***Repair of soft tissue following injury***

Repair of the former soft tissue structure takes place with the formation of granulation tissue (which consists of blood vessels and connective tissue), which peaks around ten days after the injury (*fig. 14*). Fibroblasts are involved in continuous remodelling for months, before the scar tissue matures. Initially the matrix consists of fibronectin, which are large molecules that appear to enhance cell recruitment and wound contraction. Fibronectin may be essential for organising collagen fibrils into bundles and may act as a template for collagen fibre formation. Collagen fibres are produced and remodelled to lie along the axis of stress in the tissues. Mature scar tissue is formed which is inferior to normal tissue and has a lower breaking strength and it may also deform the original tissue and impair its function; however, mature scar tissue provides a rapid restoration of structure integrity. Muscle granulation tissue is present ten days post injury and tears easily, at twenty days, collagen formation is virtually complete but the tissue is immature, strength increases up until four months and then during the first six to twelve months of maturation, remodelling and further increases in strength take place. Muscle scar tissue is unlike muscle tissue as scar tissue is inelastic and prone to tearing at a later stage. In tendons, scar tissue takes four months to achieve its maximal strength.

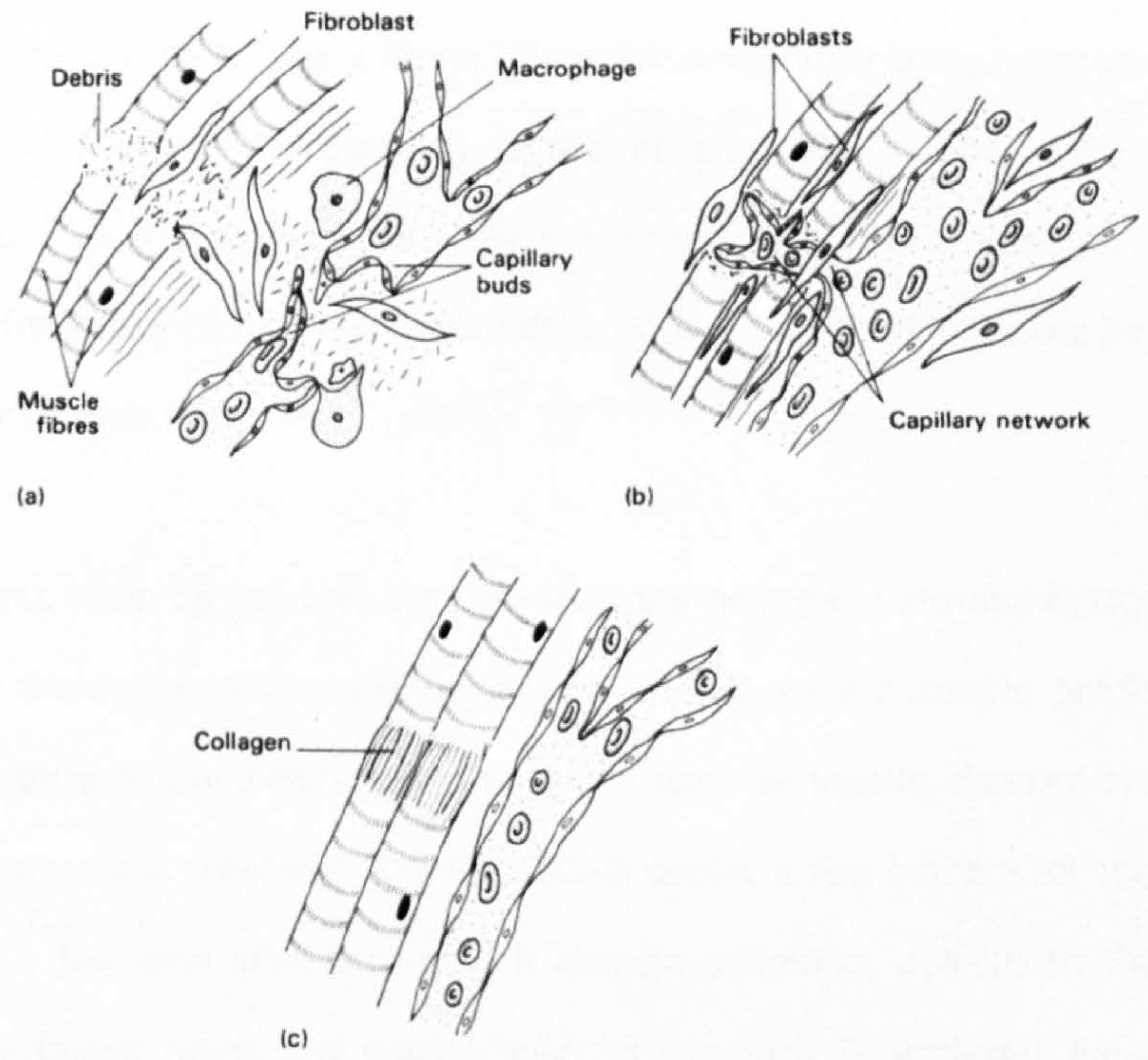

**Figure 14: Repair of soft tissue**

Injury is immediately followed by a repair process that aims to return the tissue to its original state.

### *Muscle injury*

Muscle injury often occurs when an activated muscle is forcibly stretched. Typically, such injuries often occur during athletic activities requiring bursts of speed and acceleration but this mechanism would be true of a whiplash event. In sports medicine, rupture often occurs at the musculotendinous junction (where the tendon and muscle join) or the belly of the muscle (Tidball *et al.*, 1993; Kaariainen *et al.*, 2000); although the site of failure depends on the state of activation of the muscle at the time of injury (Tidball *et al.*. 1993). Magnetic resonance imaging shows fibre disruption, oedema and haemorrhage concentrated around the musculotendinous junction or within the muscle and deep to the overlying fascia (Kneeland 1997). Full thickness tears may cause the muscle to retract and deform. On external examination, pain and tenderness is felt and sometimes there is a severe loss of movement possibly because the muscle is unable to contract (Jones *et al.*, 1986), giving further clues as to the location of injury and where to examine. The fibre composition of muscle influences susceptibility to injury, with Type II fibres (fibres for movement) being more severely affected than Type I fibres (fibres for posture) (Jones *et al.*, 1986). This could be caused by recruitment patterns or because Type I fibres are more resistant to damage. The extent of injury and the frequency of repeated injury determine whether the outcome be degeneration, regeneration or fibrosis (Devor *et al.*, 1999).

Whiplash patients often do not feel the pain until the next day following injury. This may be comparable to the delay following eccentric exercises (where a muscle produces increasing tension as the muscle lengthens), and the appearance of muscle damage symptoms called 'delayed onset muscular soreness' (DOMS). DOMS occurs a few hours after vigorous exercise and intensifies a few days after activity. It may be caused by damage to the myofibrils or injury to the adjacent fascia and pulling apart of the musculotendinous junction (Kneeland 1997). It is unknown what is responsible for this delay but a possible cause is a delay in the immune system response that results in the destruction of muscle fibres (Jones *et al.*, 1986). This response has been observed in eccentrically worked muscle but not after concentric exercise (where a muscle produces increasing tension as the muscle shortens) (Jones *et al.*, 1986). Whiplash is an eccentric event which lends itself to this idea.

### *Muscle repair*

Skeletal muscle has the ability to regenerate following injury. The success of repair depends on the extent of damage to the basement membrane. If the muscle is exposed to severe trauma, the basement membrane may be destroyed and connective tissue proliferates to form a scar. Fibrosis occurs when collagen Type 1 is deposited around the muscle fibres (Stauber *et al.*, 1998), which can decrease function and mobility. Most of the processes involved in muscle development are active following injury (Stauber *et al.*, 1998). During the healing process, two competitive events take place; these are regeneration of disrupted muscle and production of a connective tissue scar. Complete regeneration occurs within five days to several weeks (Devor *et al.*, 1999). The time required for healing depends on what proteins must be synthesised and organised into functional sarcomeres (the functional units of a muscle), or membranes. Complete recovery is possible in young subjects, muscle in older subjects takes longer to regenerate; complete recovery occurs if the injury is not severe (Devor *et al.*, 1999). Muscle can also repair by fibre branching where small fibres branch off an existing myofibre. If the fibres split from the myofibre, it has an extracellular matrix of normal dimensions and content surrounding it, however, the muscle has more connective tissue to resist further injury (Stauber *et al.*, 1998). Myositis ossificans occurs in muscle tissue when an osteoblast (a bone forming cell), invades the haematoma and matures to produce bone, this can impair function (Hudson 1998).

### *Tendon damage*

Tendon injury is identified by tenderness or chronically painful tendons and is often called tendonitis although little swelling occurs. For tendons with a tenosynovial layer, this may become inflamed in response to microtrauma or to degenerative changes and this is termed tenosynovitis; in the tendon proper the term tendinosis is applied. The degenerative pattern can assume fatty, mucoid or hyaline features. In damaged tendon, the matrix is disorganised without the usual axial, tightly woven collagen bundles, fibroblasts are more numerous and there is increased vascularity (Teitz *et al.*, 1997). There is invasion of fibroblasts and vascular granulation described as angiofibroblastic hyperplasia (Teitz *et al.*, 1997). The tendon is thickened and at the tendon insertion, calcification and cystic areas may be apparent (Teitz *et al.*, 1997). Other features include crepitis and a macroscopic or microscopic tear. Tissue damage results in the inflammatory response producing swelling, heat and pain (Birch *et al.*, 1998). Rupture results in longitudinal splitting, disintegration and angulation of collagen fibrils, a decrease in average collagen fibre diameter and if strained to failure, every fibril disintegrates (Birch *et al.*, 1998). Collagen fibres form a crimp arrangement that protects the muscle from rupture. Creep occurs when a constant load causes the tendon to lengthen with time as the crimp straightens. Excessive loads cause the tendon to fatigue and rupture. When tendon is damaged, the crimp pattern is disrupted and tensile performance is reduced (Williams *et al.*, 1985).

### *Tendon repair*

The blood supply to tendons is poor and therefore healing is slow. A microscopic tear in the tendon may initiate an inflammatory response that if not treated, is replaced by a tissue that resembles a failed repair or degenerative process that is poorly organised. This tissue has numerous blood vessels and contains fibroblasts and areas of hyaline or mucoid degeneration (Teitz *et al.*, 1997). Fibroblasts from surrounding connective tissue arrange on strands of fibrin and elongate to form collagen fibres that gradually increase in diameter (Hudson 1998). Twenty four hours after injury, remnants of crimp pattern are present and collagen fibre alignment is poor (Williams *et al.*, 1985) and there is a high turnover of newly synthesised collagen. The collagen composition found in healing tendon may affect the formation of crimp. One month after injury there are regions of crimp regularly distributed throughout the tissue, however the dimensions of crimp differ from normal tendon. Three months after injury, crimp alignment has improved. Tendon healing is slow, and does not reach full maturity in terms of fibril diameter distribution and crimp formation for at least fourteen months after injury. It may take three to six months for warmth and tenderness to disappear (Teitz *et al.*, 1997).

## 2.5 *Imaging Modalities for Whiplash*

Imaging provides information for those anatomical structures that could not otherwise be visualised by an external examination. An assessment of the image obtained can be made which forms the basis for a clinical diagnosis and therapeutic plan. Present imaging modalities used to evaluate the musculoskeletal elements of the cervical spine following whiplash injury include plain radiography, computed tomography (CT) and magnetic resonance imaging (MRI). Each of these imaging modalities specialises in its ability to image specific features and all are well established for imaging the musculoskeletal system. This section focuses on the role of these imaging modalities for the diagnosis of whiplash. The sensitivity, accuracy, specificity and limitations of these imaging modalities are presented. The cost effectiveness and patient considerations are also discussed.

### *Diagnosing whiplash*

The main difficulty with diagnosing whiplash is the high level of uncertainty of what structures are injured and the cause of the pain being generated. Due to the myriad of processes that can cause the symptoms and signs in a whiplash injury, it is not surprising that imaging findings are also diverse. Diagnosing a whiplash injury is a source of controversy because there are often limited objective findings. The exact cause of pain experienced after a whiplash event is unknown; and this may explain why a diagnostic procedure has not been identified.

The protocol used by the accident and emergency department of the Queen's Medical Centre, Nottingham, UK; is a protocol typical of current UK medical practice for a patient presenting with a suspected whiplash injury is as follows (Frank Coffey personal communication 2003). Information is collected including patient history and the nature of the accident to determine the mechanism of injury. This is followed by a physical examination where the patient's general well-being, perceived pain, mobility and neurology are assessed. Imaging modalities are utilised depending on clinical signs and symptoms, with plain radiography being carried out to rule out severe damage such as fracture. Magnetic resonance imaging or computed tomography is used if there are suspected vertebrae, disc or nerve damage. If damage is not identified the patient is discharged. Generally with a whiplash injury, these imaging techniques reveal negative results and the physician must diagnose the injury based on the nature and mechanism of injury and primarily on the indirect effects of the injury including pain, disability, palpable oedema, sleep loss and other side effects of the injury (Nordhoff 1996).

Neck injuries involving fractures are more easily identifiable; however, neck sprain without fracture poses a difficult diagnostic problem because soft tissue injuries are not usually demonstrable by using standard radiography. This adds to the patient's distress as there is no objective evidence of an injury to account for the pain. With the absence of an organic lesion, patients are often regarded as having a psychosomatic illness.

The diagnostic approaches that have been used to assess whiplash are considered including the initial clinical examination and the subsequent imaging modalities that may be chosen.

### *Clinical examination*

A clinical assessment of whiplash involves examination of a patient's general well-being, perceived pain, mobility and neurology. The patient may have existing limitations due to age, previous injury or because they are innate. In the first twenty four hours following a whiplash injury, the majority of patients report pain and stiffness in the neck and interscapular region and headache; with no neurologic deficit or radicular symptoms being observed (*see Table 3*) (Ronnen *et al.*, 1996).

**Table 3: Whiplash symptoms**

| Symptoms | No. of patients |
|---|---|
| Pain and stiffness in the neck and interscapular region | 99% |
| Headache (general) | 96% |
| Headache in the occipital region | 78% |
| Limitation in rotation | 49% |
| Limitation in flexion and/or extension | 42% |
| Loss of concentration | 34% |
| Paresthesia in the arms or hands | 24% |
| Vertigo and dizziness | 24% |
| General tiredness | 19% |
| Short-term memory disturbances | 6% |
| Personality changes | 6% |
| Disturbances with word finding | 5% |
| Neurologic deficit | 0% |
| Radicular symptoms | 0% |

Symptoms reported by 100 patients (Ronnen *et al.*, 1996)

### *Plain radiography*

Plain radiography utilises X-ray to image bony structures (*fig. 15*). Plain radiography is the imaging modality of choice for patients with whiplash injury to identify fracture, dislocation, retropharyngeal oedema, tracheal displacement and instability (El-Khoury *et al.*, 1995). Whilst plain radiography allows good visualisation of the topographical arrangement of bony components of the cervical spine, visualisation of soft tissue is not possible. It has also been demonstrated that a high incidence of cervical pathology may be present despite normal radiographs (El-Khoury *et al.*, 1995). Dynamic imaging using plain radiography has shown functional disturbances in patients suffering from whiplash injuries (Griffiths 1998). As radiography has yielded negative results, this may suggest that whiplash mainly affects soft tissues.

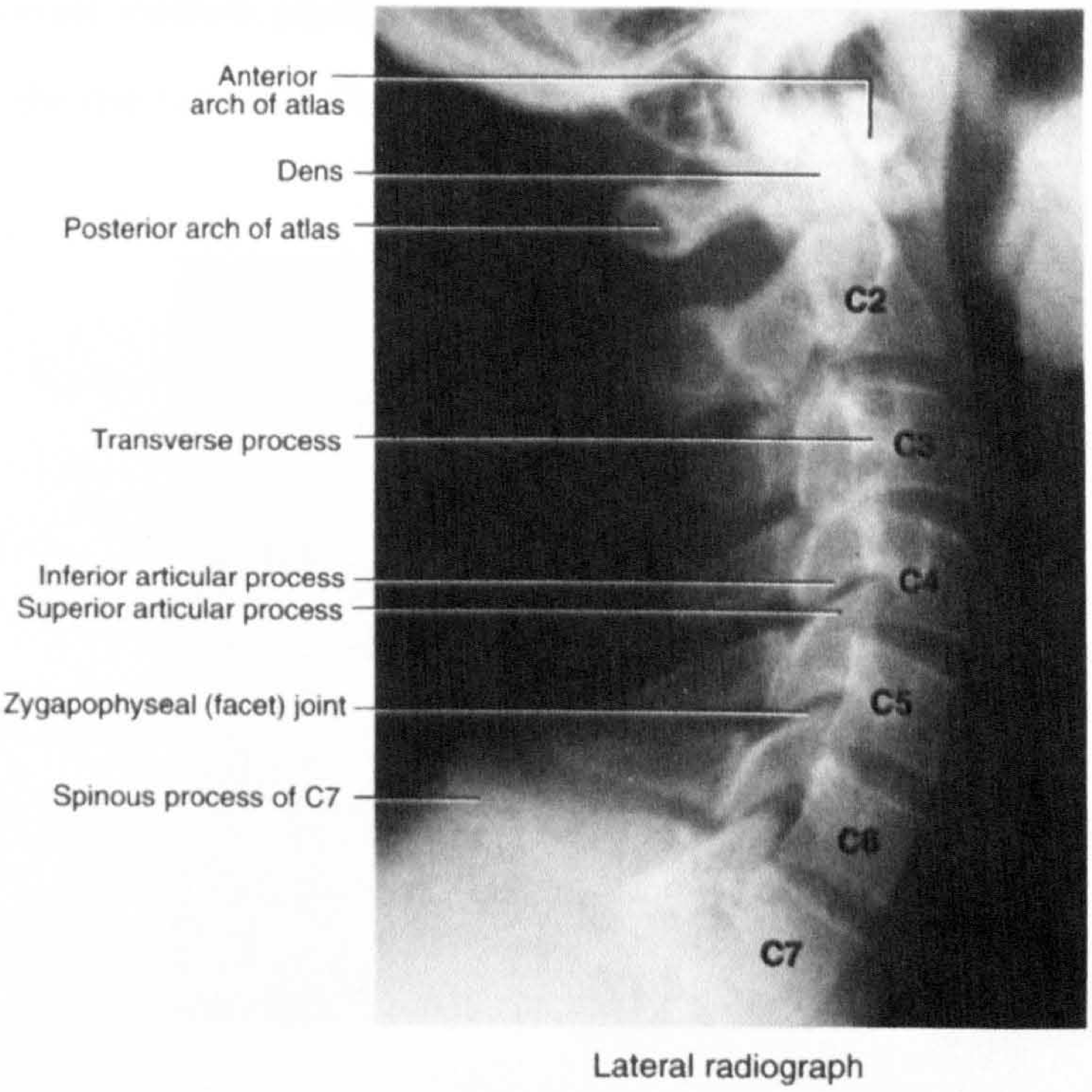

**Figure 15: Plain radiograph of the neck**
(C2-C7 = cervical vertebrae)

***Computed tomography***

Computed tomography (CT) examines the bony structures and soft tissue of the body (*fig. 16*). A low intensity X-ray tube is rotated through a 360° arc around the patient. This information is analysed in a computer that constructs the image of a 'slice' through the body at the point at which the X-ray beam was focussed and rotated. It is also possible with some computers to take several scans short distances apart and stack the slices to produce a three-dimensional image. CT allows good visualisation of the topographical arrangement of bony components of the cervical spine, soft tissues are visualised but without structural detail. Cervical discography followed by CT may be more sensitive in detecting sometimes painful anular fissures (Volle *et al.*, 1992). CT has a higher sensitivity in detecting fractures than plain radiography. CT is time consuming (Baum *et al.*, 2000) and exposes the patient to significant amounts of ionising radiation (Som 1997). For soft tissues to be visualised, a radiopaque dye of iodine (a contrast medium capable of absorbing X-rays), has to be injected intravenously and allergies to the dye can exist (Som 1997).

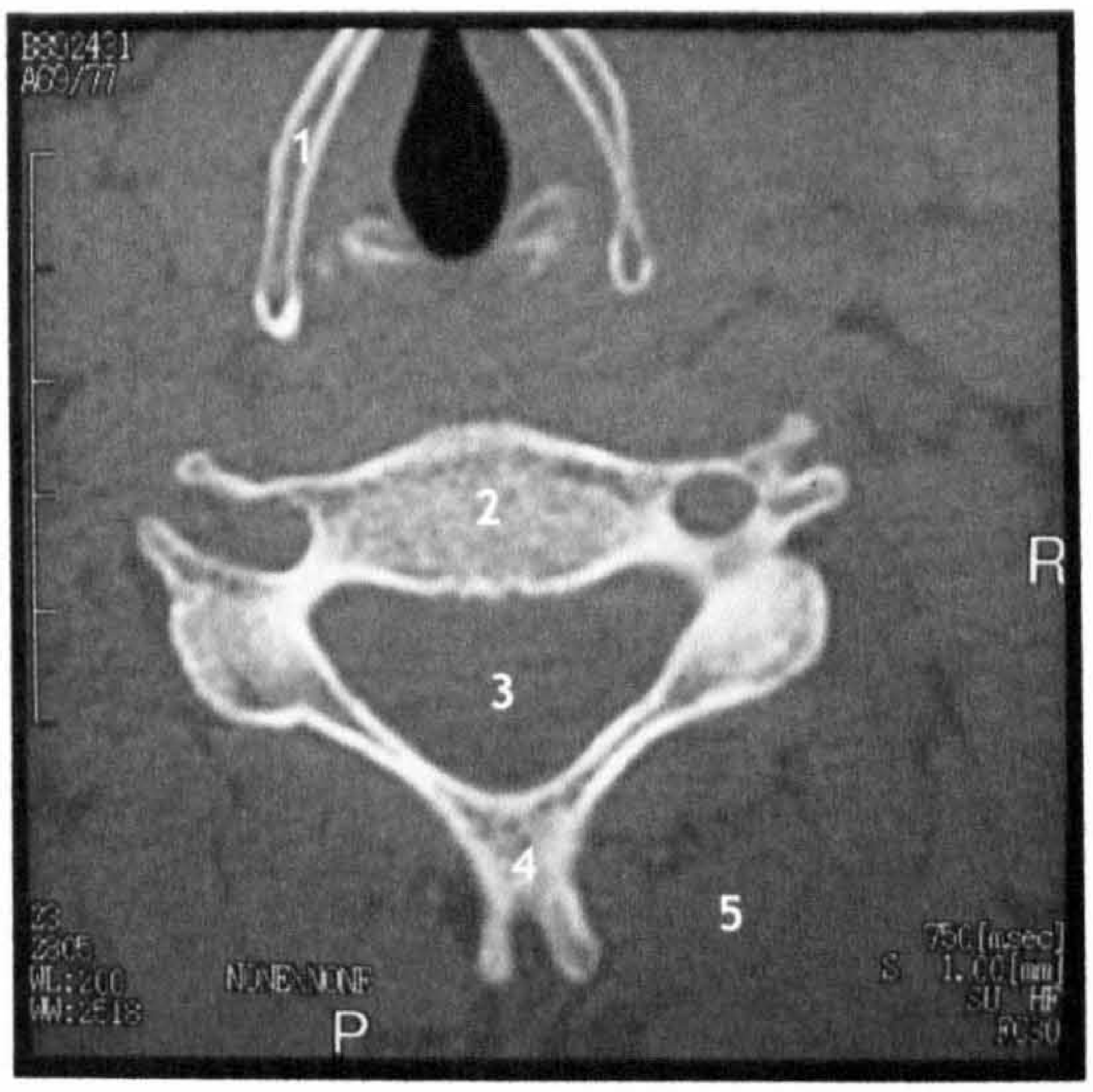

**Figure 16: Computed Tomography image of the neck**

Bony structures are well defined; surrounding musculature is apparent but lacking in architectural detail.

1 - thyroid cartilage
2 - vertebral body
3 - vertebral foramen
4 - spinous process
5 - muscle

### *Magnetic resonance imaging*

Magnetic resonance imaging (MRI) images bone and provides good soft tissue differentiation (*fig. 17*). MRI forms an image based on the behaviour of atoms in a magnetic field. Radio waves are directed at a person lying inside a large electromagnetic field. The magnetic field causes the protons of various atoms to align. The body contains large amounts of water composed of hydrogen atoms, and it is the alignment of these that is important in this imaging system. Radio waves of certain frequencies are directed at the patient that changes the alignment of these hydrogen atoms. When the radio waves are turned off, the hydrogen atoms realign in accordance with the magnetic field. The time it takes for these hydrogen atoms to realign is different for the various tissues of the body. These differences are analysed by a computer to produce images of body sections. In the clinical setting, MRI is reserved for serious cases and therefore most whiplash patients would not undergo this technique until their problem was long term, at this point any oedema or bleeding would unlikely be evident. The use of MRI to identify a whiplash injury has had various success. In one study, MRI of whiplash patients appeared to demonstrate the presence of anterior longitudinal ligament injury, vertebral end plate fracture, disc injury, disc herniation, disc injury and interspinous ligament injury (Davis *et al.*, 1991). However, these changes have been observed as normal variants or present in asymptomatic individuals (Boden *et al.*, 1990). Other MRI studies have not revealed any specific feature after whiplash with the authors of these studies stating that MRI has no role in evaluating whiplash injury (Ronnen *et al.*, 1996; Borchgrevink *et al.*, 1997; Voyvodic *et al.*, 1997). Soft tissue changes indicating bleeding or oedema were not seen in the cervical images of patients scanned within two days of injury (Borchgrevink *et al.*, 1997) which suggests soft tissue damage did not occur in this case. Dynamic imaging using MRI has shown functional disturbances in patients suffering from whiplash injuries (Nagele *et al.*, 1992). MRI is non-invasive and does not expose the patient to ionizing radiation; however, disadvantages exist. MRI may not always provide the necessary information required to evaluate pathologies such as incomplete ligamentous disruption and paraspinal soft tissue pain (Schwartz *et al.*, 1999). This is largely due to a limitation of spatial resolution and contrast within muscles and ligaments. Patient compliance can be a problem as discomfort due to claustrophobia or pain can lead to movement artefacts or incomplete sequences of images being acquired. Patients with unstable ferrous materials such as pacemakers, aneurysm brain clips and foreign bodies in the eyes; are potentially excluded from undergoing this procedure (Som 1997). The long duration required for image capture precludes the routine use of MRI for obtaining real time recordings (Duerinckx *et al.*, 1999).

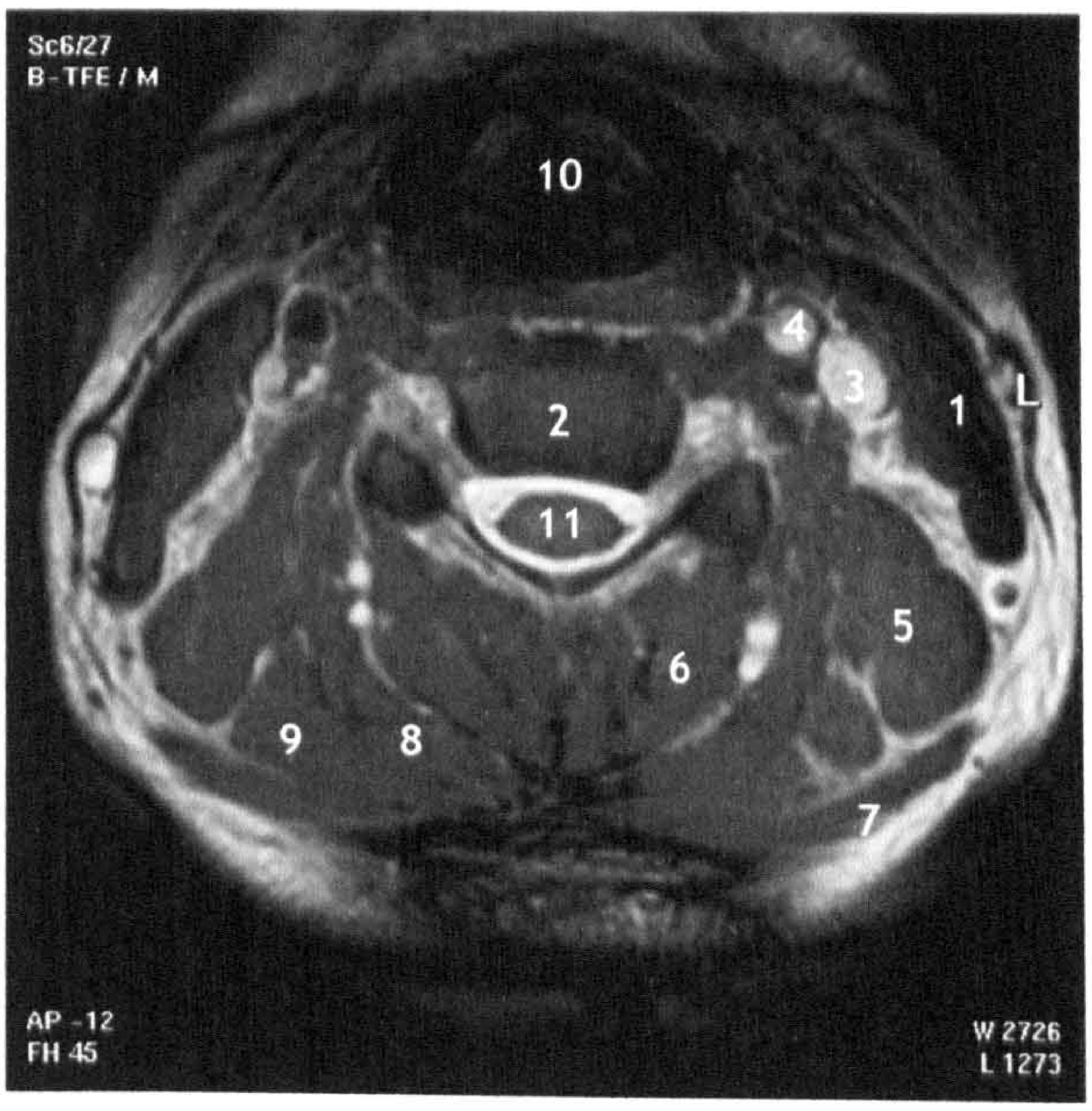

**Figure 17: Magnetic Resonance Imaging of the neck**

1 - sternocleidomastoid
2 - vertebral body
3 - internal jugular vein
4 - common carotid
5 - levator scapulae
6 - erector spinae
7 - trapezius
8 - semispinalis
9 - splenius capitis
10 - trachea
11 - spinal cord

MRI and CT scanning requires the use of expensive machinery, dedicated space implying lack of portability, trained technicians as well as experienced radiologists for image interpretation (Som 1997). Waiting times for a routine examination at the Queen's Medical Centre is less than two weeks for CT and a maximum wait of three months for musculoskeletal MRI; for both modalities urgent cases are assessed on the same day (Robert Kerslake personal communication 2004). Although MRI and CT imaging provide useful musculoskeletal information, an alternative form of imaging which yields comparable information would be attractive in terms of logistics and economics and if the modality had superior resolution this may aid soft tissue pathology diagnosis.

*Ultrasound*

The use of ultrasound as a diagnostic tool for whiplash injury is considered here; the principles of ultrasound will be discussed in a later section. The ability to use ultrasound to diagnose whiplash is controversial, and there is little documented evidence available that whiplash related signs can be seen. Ultrasound of whiplash patients has evidenced soft tissue injuries such as muscle tears, haematoma, swelling and muscle atrophy (Martino *et al.*, 1992, Shwartz *et al.*, 1999, Kristjansson 2004). In these studies, ultrasound revealed hypoechoic signals suggestive of haematoma (Shwartz *et al.*, 1999) and tears (Martino *et al.*,1992) and a loss of tissue architectural definition (Kristjansson 2004) typical of muscle atrophy, swelling and haematoma. The characteristic ultrasound appearance of these pathologies correlates well with documented musculoskeletal injuries (*see Section 2.7*). Further pathologies including disc bulges and herniations, as well as abnormalities of the facet joints and paraspinal muscles have been claimed (Kirsch and Poirier 1997). Although for this study, only an abstract is available on the World Wide Web, which obviously has the inherent problems of not being a peer reviewed article, lacking detail and there is absence of follow up work. The findings of this study must be viewed with caution; however, these results are not unbelievable, as using ultrasound to identify pathology of those mentioned structures has been achieved in other studies (Porter 1980, Hides 1995, Weiss 1996).

Ultrasound is not routinely used to diagnose whiplash, and evidence of this work is sparse with the field developing slowly. Ultrasound technology has developed considerably since many of these studies were conducted. The improved quality of ultrasound imaging enhances diagnostic capabilities, and therefore makes now an ideal time to develop these studies.

### *Using imaging devices to verify injury*

An inherent risk of imaging is that without knowing the pre and post injury state, it is impossible to know what changes have taken place as a result of injury. Those features identified as injuries may have been present before the accident, normal variance or just natural degenerative changes due to ageing. To verify changes, the ideal situation would be to have before and after images to make a valid assessment of those changes taking place. As this is not feasible in the clinical setting, imaging findings must be matched to symptoms, compared to a contralateral image (assuming this is free from pathology); and compared to asymptomatic individuals.

Whiplash is a subject where litigation expenses are high and with no diagnostic tool available, it is a doctor's note that decides the severity of the problem, a system such as this is open to malingerers. For the purpose of litigation and patient care, an imaging modality that can successfully determine an organic lesion is needed. Although there are a number of imaging techniques available to investigate the neck, they have proved unsuccessful for identifying pathology consistent with whiplash. These modalities also lack image quality, are resource intensive and have associated risks for the patient. The original ultrasound devices, although patient friendly and economical, had inadequate image clarity of soft tissue damage and were most likely discounted as a diagnostic tool for this reason. However, ultrasound technology has made considerable advances during recent years and is available at a relatively low cost when compared to other imaging techniques. Advances in technology mean that ultrasound now has the inherent ability to visualise those musculoskeletal injuries believed to be damaged in a whiplash injury.

## *2.6 Ultrasound*

The physics of ultrasound and its use as an imaging modality is discussed including details of the equipment used throughout this study. The benefits, disadvantages and weaknesses of using ultrasound technology are also reviewed.

### *Development of ultrasound*

Ultrasound is a high frequency sound wave above the human auditory range that is also produced by bats and dolphins as a means of communication and navigation. In 1880, the Curie brothers discovered a method to produce and detect these high frequency sound waves. The threat of submarines during the first world war; led to a need to see hidden underwater obstructions and a technique was developed that could detect submarines but it could not gauge their range. By the second word war, Sound Navigation and Ranging (SONAR) had evolved allowing both detection and ranging. The use of ultrasound in medicine developed as a byproduct from these engineering ventures. In 1937, the Dussik brothers were the first to describe the use of ultrasound for imaging and produced images of the head. This fuelled interest among research groups. In 1949, Wild reported that ultrasound could be use to visualise soft tissue (Wild 1950). In the early to mid 1950's, Howry developed a machine called the Somascope, meaning tissue vision; and using the findings of this machine published papers on the use of ultrasound for soft tissue investigation (Howry and Bliss 1952; Howry *et al.*, 1954). Howry's invention of a Compound Waterbath Scanner in 1954 produced detailed scans, especially of the neck (*fig. 18*).

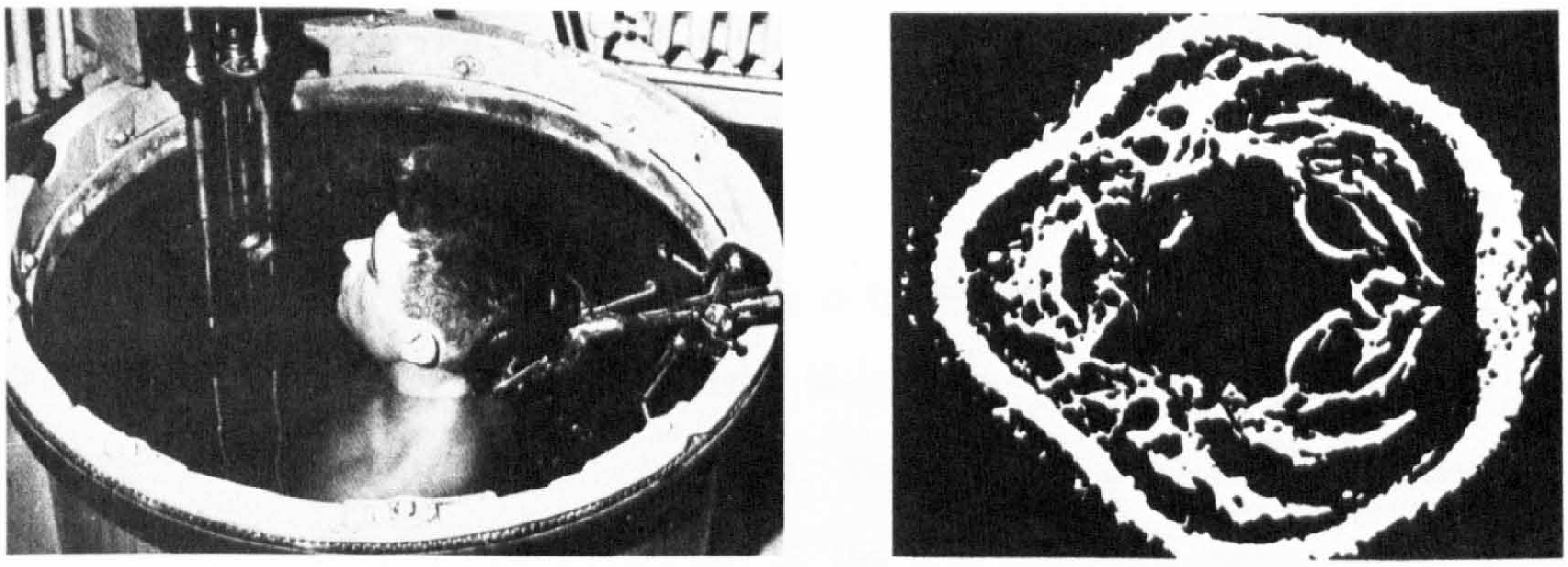

**Figure 18: Compound Waterbath Scanner**

Ultrasound cross-section of the neck.
(left = anterior, right = posterior)

### *The physics of ultrasound and instrumentation*

Sound is the transmission of mechanical vibrations through matter. These vibrations are orderly, oscillatory motions generated by an external source. Frequency is the term used to quantify these oscillations. Frequency is the number of oscillations per second performed by particles of the matter in which the sound is propagating. Ultrasound is the sound waves of extremely high frequency, above 20,000Hz, which are inaudible to the human ear. The sound waves of diagnostic ultrasound travel through the human body interacting with tissues in a way that allows it to be used for diagnostic imaging.

### *Behaviour of ultrasound*

Diagnostic ultrasound relies on the interaction of the transmitted sound wave with the structures under investigation. The ultrasound equipment locates and displays echoes based on the waves propagation speed (the speed at which a wave moves through the medium). Propagation speed is affected by acoustic impedance (the resistance offered by tissues to the movement of particles caused by ultrasound waves) (*see Appendix C*). Acoustic impedance is a function of the density (concentration of matter) and hardness (resistance of a material to compress) of a tissue (*see Appendix C*). Materials with high acoustic impedance transmit sound faster than those of low acoustic impedance. Therefore, propagation speeds are highest in solids (such as bone) and lowest in gases (*see Appendix C*). The average propagation speed of ultrasound in soft tissue is 1540m/s and this is used as a reference when mapping echo location.

The behaviour of a sound wave on meeting a boundary is dependant on the acoustic impedance of the medium the wave is moving through and the angle of incidence the wave meets boundaries within the region of interest. The behaviour of sound waves enables the identification of elements and pathologies of the musculoskeletal system based on this acoustic impedance. Tissue with high water content such as muscle, cartilage and tendon; transmit and reflect sound waves very well allowing good images of these structures to be acquired (*see Appendix C*). The ultrasound appearance created by the different architectures of these structures has been well defined and will be discussed later.

### *Attenuation*

As the ultrasound beam traverses through a medium, a phenomenon called attenuation occurs. Attenuation is the decrease in amplitude and intensity with distance as a wave travels through a medium. Attenuation is the result of the beam being reflected, refracted, absorbed or scattered due to structures of different acoustic impedance. Higher frequencies are more readily attenuated than lower frequencies and therefore to image deeper structures lower frequencies are required.

### *Reflection and refraction*

When the beam reaches a tissue interface at a perpendicular incidence, some of the beam may be transmitted and the rest is reflected back to the transducer (*fig. 19*). The amount of energy reflected is proportional to the difference in acoustic impedance between the structures forming the tissue interface (*see Appendix C*). Ultrasound waves tend to meet boundaries with an oblique incidence. If the oblique incident pulse on meeting a boundary is transmitted, this change in direction of sound is termed refraction. Not all non-perpendicular beams are refracted. Some are scattered about the tissue interface.

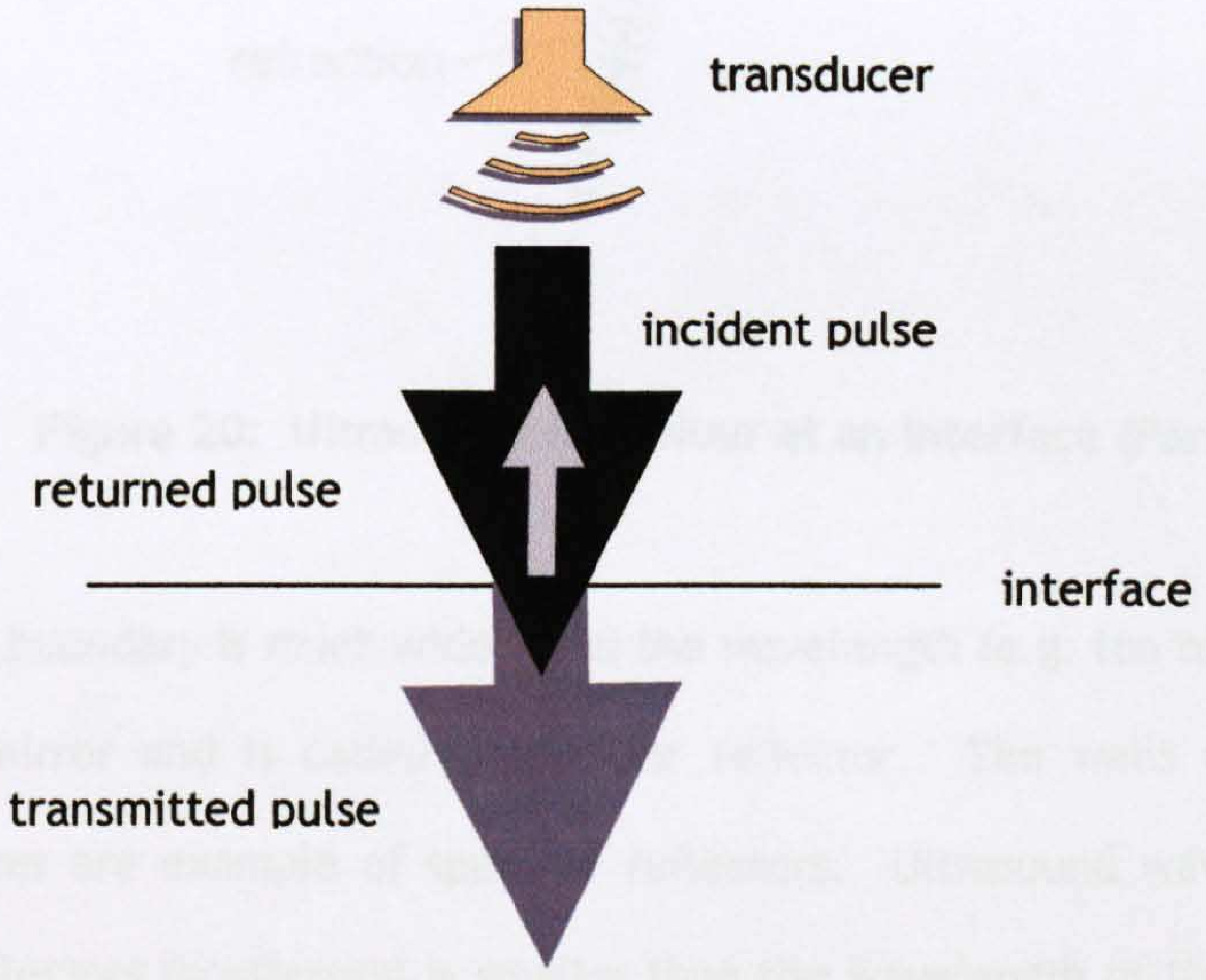

**Figure 19: Ultrasound behaviour at an interface (Part 1)**

In figure 20, a fraction of the incident wave (1) is reflected (2) at an angle equal to the angle of incidence. Another fraction (3) passes across the interface and is refracted, continuing at an angle different from the angle of incidence. The greater the difference between the acoustic impedances at an interface; then the greater the fraction that is reflected. Bone reflects ultrasound strongly so that its architecture may not be imaged and subsequently the bone produces an acoustic shadow behind its surface. The greater the ratio of the propagation speeds, the greater the refraction. In practice, this is least important when the incident angle is zero and the ultrasound wave strikes the interface perpendicularly.

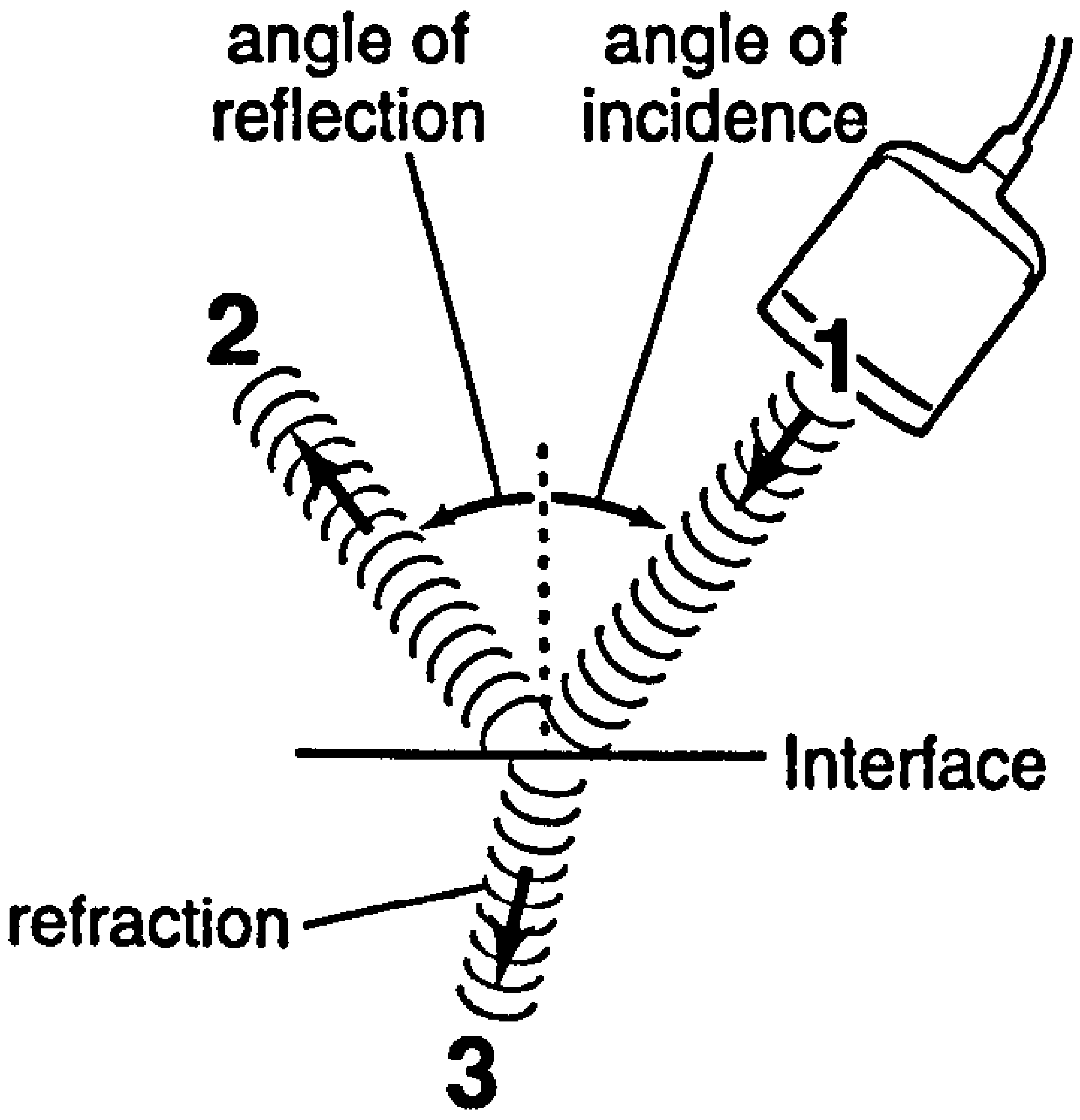

Figure 20: Ultrasound behaviour at an interface (Part 2)

If the reflecting boundary is much wider than the wavelength (e.g. ten or twenty times wider) it acts like a mirror and is called a specular reflector. The walls of blood vessels and connective tissues are example of specular reflectors. Ultrasound waves scatter when the width of the reflectors (scatterers) is smaller than the wavelength of the ultrasound. Only a small fraction of the ultrasound wave is returned back in the original direction (*fig. 21*). The effect of these scatterers is to produce 'noise' that is perceived as a granular textured background. This background may convey little if any information regarding the arrangement of reflectors, and is referred to as speckle.

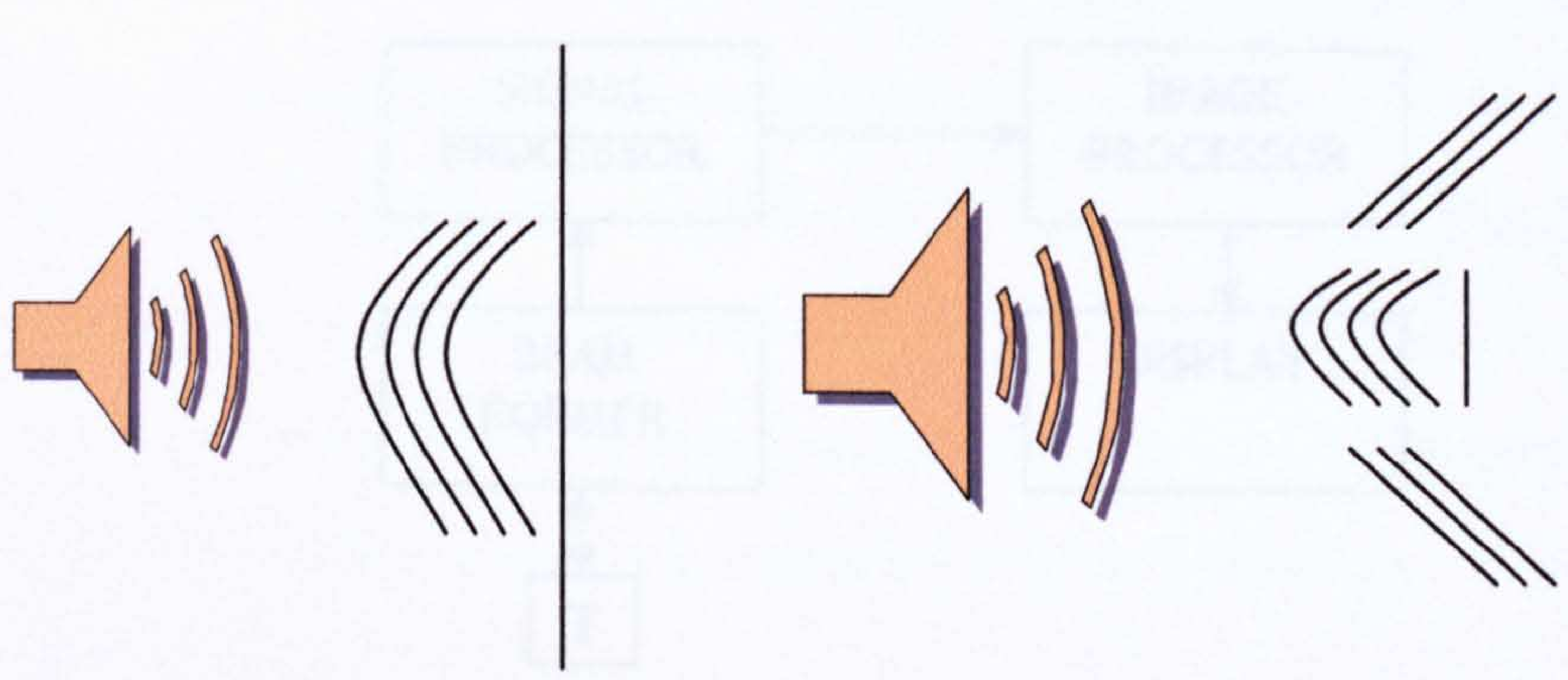

Figure 21: Ultrasound behaviour at an interface (Part 3)

The effect of boundaries makes the use of a coupling agent a requirement. The coupling agent prevents air trapped between the skin and the transducer acting as a barrier to the ultrasound waves.

### *Absorption*

Another cause of attenuation is absorption by the traversed tissues. The lost energy is imparted to the tissue in the form of heat which is possibly the basis of therapeutic ultrasound.

### *Imaging instruments: pulse-echo imaging*

Diagnostic ultrasound systems consist of a pulse-echo imaging system (*fig. 22*). A pulse is emitted from the transducer, and the system determines the returning echo strength and location of echo generation sites. Echo generation sites are determined from the direction and arrival time of echoes returning from the tissues. It is this information that produces the characteristic sonogram. The pulse-echo imaging system consists of a beam former, a signal processor, an image processor and a display.

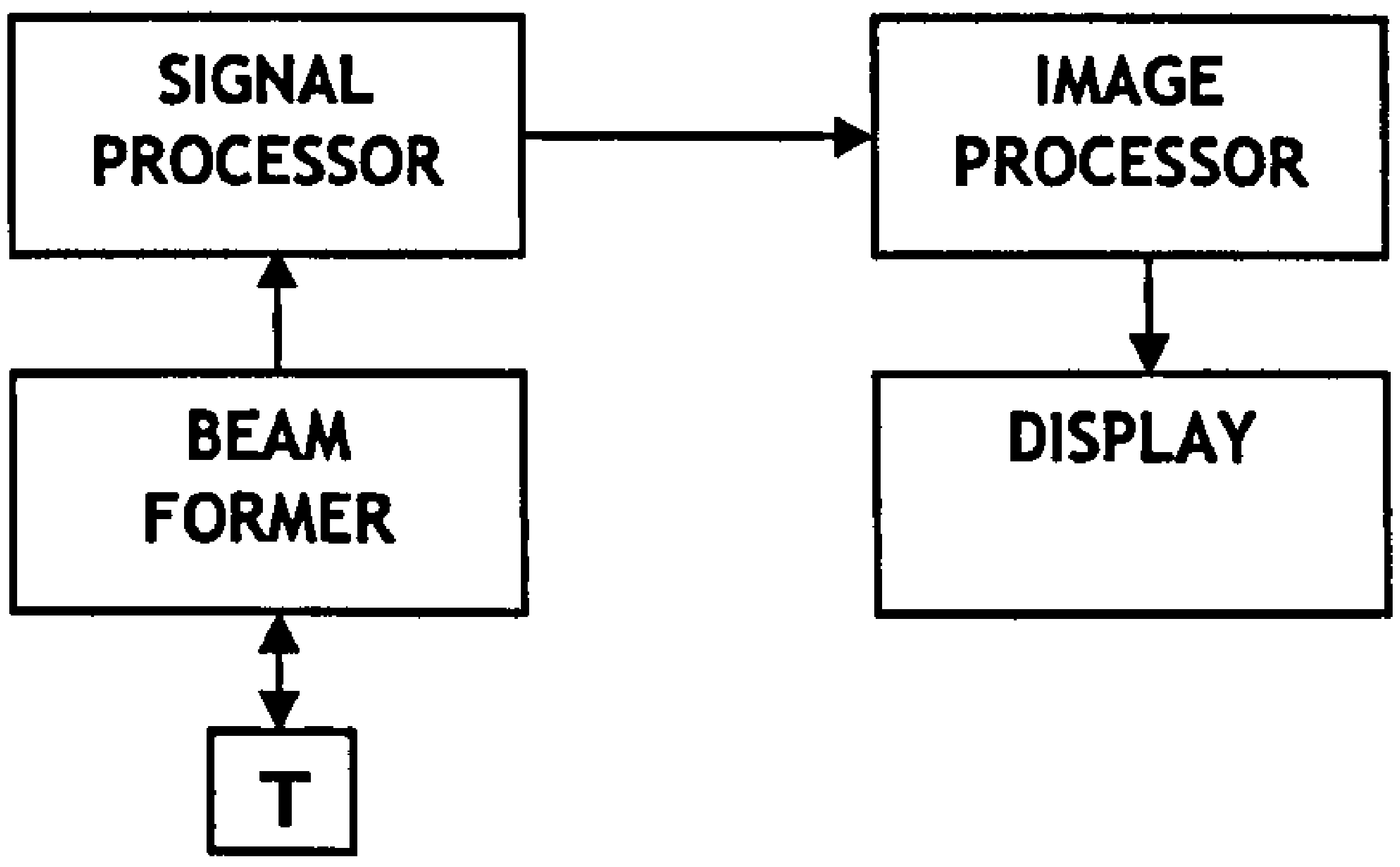

**Figure 22: Schematic of a pulse-echo system (T = transducer)**

To summarise this system, the beam former produces electric pulses that drive the transducer and performs the initial functions on returning echo voltages from the transducer. The transducer produces an ultrasound pulse for each electric pulse applied to it. For each echo received from the tissues, an electric voltage is produced by the transducer. These voltages go through the beam former to the signal processor, where they are processed to a form suitable for input to the image processor. Electronic information from the image processor drives the display, which produces a visual image of the anatomy interrogated by the system. This system may be manipulated by the operator to obtain a suitable image. A more complete discussion on this system follows.

### *Transducer*

#### *Construction and operation*

The transducer is the device responsible for transmitting ultrasound waves and receiving returning echoes. The transducer is constructed from piezoelectric (pressure-electric) crystals that have the properties to convert electrical stimulus to vibrations which produce pressure (sound) waves and vice versa. The linear-array transducer used in this study has piezoelectric elements arranged in a rectangular formation. Rectangular images are produced and are composed of many vertical, parallel scan lines. The length of this array determines the field of view. The transducer is driven by cycles of alternating voltage which apply electricity to the crystals at a specific pulse rate; the crystals produce vibrations that cause an alternating pressure that propagates from the transducer as a sound pulse. The frequency of sound produced is determined by the characteristics of the crystals in the transducer. The driving voltage must be near to the operating frequency (resonance frequency) of the transducer. The operating frequency is the natural frequency of operation for the element. The returning echo is converted into an alternating voltage pulse by the transducer.

*Focussing*

The beam emitted by a transducer in an unfocussed state has two separate fields; the near field (Fresnel Zone) and the far field (Fraunhoffer Zone). The near field is the same width as the transducer face and extends to the focal point. Beyond the focal point, the beam diverges and is called the far field. Because of this divergence, resolution in the far field is poor compared to the resolution achieved by the near field. For optimal resolution, the transducer should be focussed to the specific region of interest. Focussing moves the end of the near zone toward the transducer and narrows the beam; this can only be achieved in the near zone of a beam. Well adjusted focussing provides a narrow acoustic beam and a thinner image section; this gives better resolution of detail and a clearer image containing more information. This can be likened to the effect of a thin beam of light showing an object more clearly than a scattered beam. The linear array transducer used in this study has an electronically variable focal length that can be adjusted to the required depth.

*Detail resolution*

Resolution is the ability of the transducer to separate and define small, closely spaced structures. Resolution is determined by wavelength which is inversely proportional to the frequency. Therefore the higher the frequency, the smaller the structures that can be identified; however, high frequency has a limited depth of penetration (*see Table 4*). Lateral resolution is the ability to separate and define small structures perpendicular to the beam axis. Lateral resolution is equal to the beam width and is optimised by focussing the beam at the area of interest; this has the effect of reducing the beam width, and using high frequencies. Axial resolution is the ability of the transducer to separate and define two structures along the axis of the beam. Axial resolution is optimised by damping the crystal and increasing frequency. Elevational resolution or slice thickness is the ability to distinguish between reflectors and structures separated along a line that is perpendicular to the ultrasound image plane. Ultrasound characteristics are displayed in Table 4.

**Table 4: Ultrasound characteristics**

| Frequency (MHz) | Wavelength (mm) (assuming average velocity of sound in tissue is 1540m/s) | Imaging depth (cm) | Axial Resolution (mm) |
|---|---|---|---|
| 1 | 1.54 | ? | ? |
| 2 | 0.77 | 30 | 0.77 |
| 5 | 0.31 | 12 | 0.31 |
| 10 | 0.15 | 6 | 0.15 |
| 15 | 0.10 | 4 | 0.10 |
| 20 | 0.08 | - | - |

### *Beam former*

The user defines how much power is necessary to observe the structures of interest using the power transmitter control. This controls the amount of acoustic power transmitted by the transducer. As a safety precaution, the lowest possible power setting which allows adequate penetration should be employed. Increasing the output power to the transducer produces higher-intensity transmit pulses and larger-amplitude echoes which enable echo signals from weaker reflectors and scatterers to be visualised.

The transducer used in this study, is a linear phased array system. In this system, voltage pulses are applied to most or all of the elements but with a small time delay between them so that the pulse is sent out in a specific direction. Subsequent pulses are sent out in slightly different directions by altering the time delay and the beam direction continues to change. In this way, echoes can be generated from a specific anatomical location with several viewing angles. Echo information from these multiple views is processed to present an improved quality image. This is a form of electronic 'compounding' of the image. The combination of a linear array and electronically focussed phased array is best. This combination multiplies the user options and focussing possibilities for better image resolution.

Due to the process of attenuation, echoes returned from deeper structures are not as strong as those that come from structures that are more superficial. These echoes from deeper structures must therefore be amplified. Compensation for attenuation is achieved using the Time Gain Compensation (TGC) control. This mechanism compensates for attenuation by giving equal amplitudes of displayed echoes of equally impedant structures on the image regardless of the depth traversed or time elapsed between pulse and echo. TGC is required because echoes in the near field take less time to return to the transducer than those from the far field. TGC corrects the varying intensities of these echoes. The user decreases TGC gains in the near field and increases TGC in the far field. Care must be taken as over and under compensation can produce artefact (*see Chapter 3*). Overall gain is adjusted once the image appears to be of homogenous echo quality throughout both the near and the far field. The overall gain control controls the amplification of signals received by the transducer; it affects all echoes equally and is set subjectively so that echoes appear with appropriate brightness.

### *Signal processor*

Information from the beam former is sent to the signal processor. The signal processor is an electronic device that translates the amplified echo signals from the receiver into a form suitable for the display. Operations carried out include bandpass filtering (eliminates frequencies outside the bandwidth), demodulation (radio frequency is converted to video) and dynamic range compression (reduction of dynamic range with logarithmic amplification). This information is then input to the image processor.

### *Image processor*

The image processor receives information from the signal processor. Through pre-processing, the various amplitudes received are compressed into number values. These numbers are used to create a digital representation of the ultrasound image which may be viewed on the instrument display. This allows preferential enhancement of certain tissue types and better characterisation of the internal structure of organs. Pre-processing is performed before or during scanning (in real time); before the echo data is stored in the image memory. Pre-processing includes the ability to produce panoramic images, spatial compounding and 3D processing. The 'Diasus' used in this study does not have these pre-processing functions as it is a basic system and by not having these functions, the cost of the equipment is minimised. After pre-processing, image frames are stored in image memory. A rapid sequence of frames is acquired producing a real-time image. A freeze-frame occurs when one frame is held and displayed out of this sequence. The ultrasound equipment is able to store a number of frames before freezing and this produces the cine loop. Cine loops are viewable when the system is live; however, after this the cine loop is stored as a batch of images that must be reconstructed in external software to view later. Post-processing is carried out on the image data retrieved from memory, and determines how this information will appear on the display. Post-processing takes the numbers assigned by pre-processing and in turn assigns them to grey shades as viewed on the instrument display. Post-processing is performed on the frozen image and allows changes in grey scale (gamma correction) to give more or less display brightness to weaker echoes. Four post-processing curves for gamma correction are available on the 'Diasus' to be assigned at the operator's discretion.

### *Display*

The B-mode scan produces a grey-scale sonographic image. B-mode scans are so called as the images are produced by scanning the image in cross-section and converting the echo strength into a brightness to represent the echo on the display (hence B-mode scan or brightness scan). B-mode images watched in rapid sequence become real-time images. The display updates as the transducer or part of the body moves. A freeze option allows the displayed image to be held stationary for observation and measurements. Features of the 'Diasus' B-mode scan enables magnification in the form of a six step hardware zoom and image inversion capabilities. The brightness of the monitor may also be adjusted to improve image clarity. The monitor is best viewed in a dark room to avoid reflection from external light sources confounding the image.

### *Artefacts*

An artefact is an additional, missing or distorted image that does not conform to the real anatomy of the structure being examined. Artefacts are considered in Chapter 3.

### *Ultrasound safety*

There are no known risks with medical diagnostic ultrasound, however; it is best to assume that there is a risk as ultrasound is a form of energy and has the potential to produce a biological effect that could constitute a risk. Bio-effects have been identified from experimental observations in cell suspensions and cultures, plants and in experimental animals. The bio-effects observed include interaction mechanisms such as heating and cavitation. Absorption of ultrasound by a tissue results in a subsequent temperature rise. Biological effect may result depending on temperature and exposure time. Cavitation is the formation of gas bubbles or the behaviour of bubbles already present in a tissue. It is possible for ultrasound to produce cavitational activity that can result in damage. The American Institute of Ultrasound in Medicine (AIUM 1994) has stated that based on experimental studies, clinical bio-effects would not be expected to occur with the output intensities of most current diagnostic instruments. As a precaution, ultrasound should only be used when necessary and by using minimum output and exposure time in diagnostic examinations, a principle called ALARA (as low as reasonably achievable).

### *Why use ultrasound for this study?*

For the assessment of a whiplash injury, ultrasound as an imaging modality has been overlooked. Based on the assumption that the pathoanatomy of whiplash is soft tissue based, ultrasound would seem appropriate for this task. Ultrasound is well established as an investigative and interventional tool in the musculoskeletal system (Heckmatt and Dubowitz, 1988; Goodwin 2000; Allen and Wilson, 2001; Martinoli *et al.*, 2001; Peetrons *et al.*, 2001; Chang *et al.*, 2002; Peetrons 2002). Despite its credibility for imaging the musculoskeletal system, investigation of the elements of the spine is limited. The standard imaging techniques used to evaluate musculoskeletal components of the cervical spine are plain radiography and computed tomography (CT) for bony elements, and CT and magnetic resonance imaging (MRI) for soft tissue assessment. Although CT and MRI are both able to assess soft tissue, neither has proven successful for the assessment of a whiplash injury. MRI and CT both lack the architectural detail achieved by ultrasound and it is possible that this is the level of detail required to make an assessment. In terms of how ultrasound compares to these other imaging modalities; it has been found comparable to MRI for assessing muscle size (Bemben 2002) and slightly more successful than MRI for detecting tendon injury (Möller *et al.*, 2002). These results seem appropriate as assessment of pathology size does not require detail of architecture and therefore assessment is comparable; however, visualisation of internal tissue structure and resolution ability may give ultrasound the edge for detecting pathology. By using ultrasound as the initial diagnostic procedure, the need to use other more expensive imaging techniques may be reduced.

### *Advantages and disadvantages of ultrasound*

With advances in ultrasound imaging it is now possible to achieve superior resolution of structures than was possible in the past (Whittingham 1997; Claudon *et al.*, 2002). Ultrasound is an attractive imaging modality, being a flexible and non-invasive technique that produces detailed real-time images. The ultrasound assessment enables interaction between the examiner and the patient. The patient may give direct feedback about tenderness from transducer palpation and aid detection of injury. Compression from applying transducer under real-time evaluation can reveal important information about the composition of underlying structures and allows increased conspicuity or detection of abnormalities that may be otherwise hidden (Jacobson 1999). Dynamic imaging can reveal transient conditions related to specific position or movements, that can be absent during static examination (Jacobson 1999). Dynamic imaging allows examination of an area under movement and eliminates the need for the patient to remain still if it is uncomfortable to do so. Contralateral comparison is easily performed in the musculoskeletal system; it distinguishes significant findings from normal variants and occasionally reveals unsuspected abnormalities (Lin *et al.*, 2000). Ultrasound permits a three dimensional investigation to be carried out. Ultrasound equipment is calibrated and therefore measurements can be made in all dimensions. The fact that ultrasound is portable and requires no dedicated space makes it a useful tool. There have been no documented cases of side effects occurring because of diagnostic ultrasound and to date, there are no contraindications for its use (Healy 2002). Unlike other radiographic techniques, ultrasound does not rely on exposure to ionising radiation.

There are disadvantages associated with ultrasound but many of these may be over come with training and care. A problem with real-time image capture; is that the image captured represents a single moment of a dynamic study, and if the observer has no knowledge of the examination then interpretation can be complicated. The interpretation of images is often subjective requiring technical expertise from experienced radiologists. Possible limitations of ultrasound are that examination may be too painful to assess injured necks and this will need to be addressed. The stature of the patient may influence the ability to acquire images; for example, it may be difficult to acquire images of deeper structures in patients of larger stature.

## *2.7 Soft Tissue Appearance with Ultrasound*

Different types of soft tissue have a characteristic appearance when viewed with ultrasound. An understanding of the ultrasound appearance of normal soft tissue is required to provide a reference for identifying when changes may have occurred. In response to injury and during the recovery process, the tissue architecture is altered. These changes in structure result in changes in their ultrasound appearance. The tissues appearance with ultrasound suggests the type of injury, its extent, as well as an indication of its age and state of repair. Although many of these changes occur at an ultra-structural level, and are too small to be made visible with ultrasound, their accumulative change in appearance is evident. These changes will be used as markers in whiplash patients. The structural change that soft tissue undergoes during injury and repair and the timescales over which these changes occur are considered.

### *Structure and ultrasound properties of soft tissue*

Anisotropy should be considered when examining any musculoskeletal soft tissue structure but is most obvious in tendon and ligaments. Tendon has a regular homogenous structure which produces an ultrasound image that is very sensitive to scanning angle (Crass *et al.*, 1988; Garcia 2003). Collagen bundles have a long and smooth surface which act as specular reflectors to the ultrasound beam. Anisotropy occurs when the ultrasound beam is not perpendicular to these bundles and in the absence of these specular reflectors, an artifactual hypoechoic to anechoic appearance results (Martinoli *et al.*, 1993). Muscle is less affected by anisotropy due to its more complex histological organisation. Muscle has fewer interfaces that yield specular reflections and more nonspecular reflectors, whose amplitudes have little angle dependence. The result is little change in muscle echogenicity with changes of the angle of the transducer (Crass *et al.*, 1988). It is important to bear the effects of anisotropy in mind when assessing a tissues echogenicity. The echogenicity of a tendon is greatest when examined perpendicular to the ultrasound beam (Lin *et al.*, 2000), as the angle increases, the tendon appears more hypoechoic. Therefore, if echogenicity is used as a criterion, the angle of the ultrasound beam must be specifically defined (Crass *et al.*, 1988).

### *Ultrasound properties of muscle*

Normal muscle tissue appears as a structure with low to mid level echogenicity with hyperechoic fascial planes separating the fibres (Baatenburg de Jong *et al.*, 1993; Jacobson and van Holsbeeck 1998; Peetrons 2002). The boundaries of the muscle are clearly visible, as the epimysium surrounding the muscle is a highly reflective structure. Muscle tissue is divided by echogenic sheets of perimysial connective tissue, which gives it a speckled appearance. Epimysium, fascia, nerves and tendons appear hyperechoic relative to muscle (Peetrons 2002).

### *Ultrasound appearance of muscle damage*

Ultrasound can successfully evaluate changes in intramuscular architecture (Bleakney and Maffulli, 2002). Muscle tears appear as hypoechoic gaps, and in the acute phase, the area of muscle damage appears thickened with displacement of the outer margins due to the haematoma (Lee and Bouffard 2001). Ultrasound allows identification of partial or full thickness tears within the musculotendinous junction (Healy 2002). There are two categories to describe the mechanism of injury for muscle. The first category is caused by stretch and has three grades; grade 1: strain, with no appreciable tissue disruption, grade 2: partial thickness tears and grade 3: full-thickness tears. The second category involves direct impact or crush, and typically produces damage and haemorrhage in the muscle belly. Magnetic resonance imaging (MRI) is often unable to differentiate between category 1: grade 1 and 2 strains. Ultrasound has superior spatial resolution compared to MRI and is able to differentiate between both categories and their respective grades. The ultrasound appearance of a Grade 1 strain is hyperechogenicity within muscle associated with swelling, although this can appear normal on ultrasound. Grade 2 strains appear on ultrasound with discontinuity of the echogenic perimysial striae because of disruption of muscle fibres (Healy 2002). It is also possible to see intramuscular fluid collection or a surrounding echogenic halo (Healy 2002). Dynamic scans taken whilst asking the patient to move during active and passive contraction may allow observation of changes relative to the surrounding tissue. Movement may also increase the size of the deficit making it more conspicuous.

### *Ultrasound properties of tendon and ligament*

On ultrasound, tendons have a fibrillar pattern of parallel hyperechoic lines in the longitudinal plane and a hyperechoic round-to-ovoid shape in the transverse plane (Martinoli *et al.*, 1993). In the transverse plane, the bundles of fascicles of the tendon show as rounded echogenic foci separated by hypoechoic loose connective tissue (Ying *et al.*, 2003). Ligaments appear similar to tendon but can be differentiated by their more compact, fibrillar and hyperechoic pattern (Jacobson and van Holsbeeck 1998). Superficial ligaments are more readily and consistently identified than deeper ligaments (Lin *et al.*, 2000), this is important to bear in mind when assessing neck ligaments.

### *Ultrasound appearance of tendon and ligament damage*

Tendon tears that are either complete or partial, demonstrate a complete loss or disruption of its fibrillar pattern (Kaempffe and Lerner 1996). In chronic tears, continuous areas of atrophic scar tissue and calcification within tendons can be seen (Lee and Bouffard 2001). Loss of typical fibrillar echotexture is the most sensitive marker of tendon damage occurring both in inflammatory and degenerative disorders (Grassi *et al.*, 2000). Focal aspects of fibrillar interruptions, blurring of the tendon texture, and areas of lower echogenicity are the typical sonographic features indicating damage of the inner tendon structure (Grassi *et al.*, 2000). Partial tendon tears are characterised by hypoechoic areas; tendon fibres may be interrupted and defects are usually filled with fluid, blood, or fat (Grassi *et al.*, 2000).

### *Ultrasound properties of nerve*

Larger peripheral nerves may be identified on ultrasound (Fornage 1988). Nerves typically appear as echogenic fascicular structures and tend to be less echogenic than tendons or ligaments (Silvestri *et al.*, 1995). Peripheral nerves have a speckled appearance in cross-section, and a fascicular pattern in longitudinal plane from hypoechoic nerve fascicles and hyperechoic connective stoma (Silvestri *et al.*, 1995).

### *Ultrasound appearance of nerve damage*

Information is lacking on the ultrasound appearance of nerve damage. Benign lesions such as ganglia appear as well demarcated, anechoic cystic lesions (Bianchi *et al.*, 2001).

### *Ultrasound appearance of facet joint*

Bone cortex is hyperechoic with posterior acoustic shadowing (Baatenburg de Jong *et al.*, 1993). A thin hypoechoic rim paralleling the echogenic articular cortical surface represents hyaline cartilage (Lin *et al.*, 2000). Equine cervical facet joints were clearly visible with ultrasound, although there was no clear distinction of articular cartilages (Berg *et al.*, 2003).

### *Ultrasound appearance of facet joint damage*

Information regarding the ultrasound appearance of facet joint damage does not exist to the author's knowledge.

### *Ultrasound appearance of intervertebral disc*

Ultrasound of the intervertebral disc has focussed on imaging the lumbar region, possibly as this region is associated most commonly with back pain. *In vivo* (McNally *et al.*, 2000) and *in vitro* (Naish *et al.*, 2003) ultrasound imaging of the lumbar region produced images of the disc that contain a high degree of structural information. It is possible that these results will translate to the cervical region.

### *Ultrasound appearance of intervertebral disc damage*

In the lumbar region, *in vitro* ultrasound images of intervertebral discs relate well to their pathologic condition (Naish *et al.*, 2003). *In vivo* ultrasound has been found to be a reliable method for detecting structural changes in lumbar intervertebral discs (Tervonen *et al.*, 1991).

### *Ultrasound appearance of other tissues*

Large areas of fat cells, such as in the subcutaneous fat tissue, are hypoechoic (Reimers *et al.*, 1993). In subcutaneous tissue, several echogenic septa of connective tissue may be visible. Overall echogenicities increase with increasing thickness of the subcutaneous fat superficial to the muscle of interest and with growing muscle diameters (Reimers *et al.*, 1993). Scattering of the ultrasound beam may be the cause of slightly increasing muscle echogenicity in muscle with a large diameter (Reimers *et al.*, 1993). Muscle fibrosis proved to contribute only slightly to the echogenicity (Reimers *et al.*, 1993). Glandular structures appear as homogenous parenchymal pattern of high echogenicity and are well defined structures (Baatenburg de Jong *et al.*, 1993). Interfaces of tissue and air such as the oral cavity, pharynx, larynx, oesophagus and trachea have strong reflections (Baatenburg de Jong *et al.*, 1993). Blood vessels are echo free, tubular, and well defined, arteries display pulsatile movements. The Valsalva's manoeuvre (where the subject breathes against a closed glottis as occurs during coughing, defecation and heavy lifting) impedes venous return and may aid identification of the jugular vein (Baatenburg de Jong *et al.*, 1993).

### *Correlation between ultrasound and pathologic findings in soft tissue injury*

Ultrasound has been identified as an imaging modality that has high sensitivity and specificity in the diagnosis of soft tissue injury.

### *Muscle*

There is good correlation when the findings of histological studies of experimental muscle injury are compared with those obtained from the corresponding injured muscles *in vivo* by ultrasound (Lehto and Alanen 1987; Küllmer *et al.*, 1997; Kim *et al.*, 2002). During the early phases of healing of a muscle rupture, especially during the first week, ultrasound is useful for evaluation; as healing progresses and the amount of scar tissue decreases together with improving orientation of regenerating muscle fibres, it becomes more difficult to differentiate between normal and healing muscular tissue (Lehto and Alanen 1987).

### *Ligament and tendon*

A consistent relationship has been found between ultrasound and histopathological findings, and the specific ultrasound appearance which represented the various stages of tendon healing has been defined (Marr *et al.*, 1993). Ligaments are similar to tendon but on a smaller scale. Due to their smaller size, it is hard to identify partial tears but rupture, thickening and calcification may be identified (McNally 2002).

### *Ultrasound appearance of lesions*

#### *Haematoma*

A fresh haematoma may be hard to identify and appear as a loss of the muscles normal 'herringbone' pattern; as the haemorrhage organises, the haematoma becomes hypoechoic and may contain small bright echoes that are thought to represent fibrin clots (Hodgson and Rose 1994). Haematoma is a key sign of a muscle tear; the ideal time for the examination is between two and forty eight hours after the muscle trauma (Peetrons 2002). Before two hours, the haematoma is still in formation, after forty eight hours the haematoma can spread outside the muscle.

#### *Oedema*

Oedema of soft tissues usually appears hypoechoic and shows loss of adjacent fascial planes (Ahuja and Ying 2002). Swelling is evident with ultrasound as an increase in structure diameter, or an increase in the distance between muscle and the skin.

#### *Calcifications*

Where calcification has occurred, it typically exhibits as increased echogenicity with associated posterior acoustic shadowing (Lin *et al.*, 2000).

#### *Scar tissue*

Scar tissue will be evident on ultrasound as greater echogenicity due to its more fibrous structure than surrounding tissue.

### *Effect of age on ultrasound appearance of tissue*

The age of the subject may affect the ultrasound appearance of the tissue as older subjects may have age related degenerative changes. However, in equine tendon, age did not correlate with tendon cross-sectional area or mean echogenicity (Gillis *et al.*, 1995a).

### *The timescale of recovery and how this affects diagnosis*

Ultrasound has also been used to monitor the healing progress in tissues (Adriani *et al.*, 1995; Hollenberg *et al.*, 2000) as subsequent changes in the tissues architecture occur. Windows of opportunity appear to exist for scanning where ultrasound will be able to detect pathology. For example, scanning a patient two years after their original injury, you would not expect to find factors evident of an initial injury response. These responses, such as haematoma or oedema, would have been resolved as part of the healing process and remodelling adaptations may be too subtle to identify. However, in old injuries, scar tissue may be evident. When assessing an injury, the time elapsed since the original injury occurred must be taken into consideration as this will influence the stage of healing and therefore its ultrasound appearance. The Quebec Task Force (Spitzer *et al.*, 1995) observed that the majority of people who had sustained a whiplash injury recovered within six months. A minority had extended symptoms that required medical treatment for longer than six months. These extended symptoms are referred to as 'late chronic whiplash syndrome', and cause the greatest concern to the medical community and are a major issue for insurers. Soft tissue injuries resolve within a few months and therefore it is unlikely that these types of soft tissue injury are responsible for producing the symptoms of 'late chronic whiplash syndrome'.

Assuming that whiplash results in musculoligamentous damage, observations of damage to other structures may provide an indication of recovery time. In cases of Achilles tendon rupture, tendon thickening and heterogeneity are common during the first year, oedema and tendon defects appear to belong to the early rehabilitation period and are present after six months but of lower frequency after one year (Möller *et al.*, 2002). Muscle tears are indicated by the presence of a haematoma (Peetrons 2002). The ideal time for examination is between two and forty-eight hours after trauma, and for some muscles up to three days; after this the haematoma spreads making identification of the exact location of the tear difficult (Peetrons 2002). Muscle repair is normally complete within four months although injuries may persist and scarring may result (Peetrons 2002). After the muscle has healed, ultrasound can depict some complications such as cystic lesions or myositis ossificans (Peetrons 2002). Muscle atrophy, inflammation, avulsion and tumours may also be identified and monitored (Peetrons 2002).

## *2.8 Ultrasound of the Neck*

Studies into the use of ultrasound as a diagnostic tool of the cervical spine and musculature are limited which is probably due to the lack of familiarity with this technique (Kaempffe and Lerner 1996). The region of the spine that has received the most attention with ultrasound is the lumbar region. This is likely to be because the majority of back problems occur here due to the weight bearing function of this region. With the ability of ultrasound to image musculoskeletal regions and the lumbar spine region, these indicators suggest that this technique could be developed to become a standard option for imaging of the cervical region.

### *Anterior structures of the neck*

In the cervical spine, ultrasound has been used extensively to study anterior structures such as the thyroid gland (McIvor *et al*, 1993), lymph nodes (Ahuja and Ying, 2002), embryologically derived lesions (Baatenburg de Jong *et al.*, 1993), and vascular anomalies (Laméris 1993). The use of ultrasound to investigate the posterior structures of the cervical spine has not been exploited although it has been used to evaluate ligamentous and muscular strain in the paraspinal region (Schwartz *et al.*, 1999).

### *Ultrasound of the spine and intervertebral discs*

The use of ultrasound to image the spine has been utilised to measure the lumbosacral spine in children (Lam *et al.*, 2004) and visualise the contents of the spinal canal in infants and foetuses (Raghavendra and Epstein 1985). Its use has been directed at detecting intraspinal disease during the intraoperative period (Henegar *et al.*, 1996) and for intra-operative monitoring of spinal decompression (Raynor 1997). With chronic spinal conditions, diagnostic ultrasound has proved useful in correlating back pain with spinal canal diameter (Porter *et al.*, 1980). The structure of the intervertebral disc in the lumbar region *in vivo* has also been characterised (McNally *et al.*, 2000) and pathology *in vitro* identified (Naish *et al.*, 2003).

Ultrasound is also able to observe inflammation of nerve root area and facet joint (Weiss 1996).

### *Ultrasound of soft tissue of the spine*

Ultrasound of the soft tissues following a whiplash injury has been discussed. Other examples where ultrasound has been used to image soft tissues of the spine include quantification of the size of the splenius capitis muscle (Soltani *et al.*, 1996) and paraspinal muscle (Hides *et al.*, 1995). A study by Stipkovich (1994) focussed primarily on the ultrasound appearance of lymph nodes, but also commented on the ability of ultrasound to image neck musculature. A study that evaluated cervical and lumbar back pain using a 5MHz ultrasound transducer was unable to demonstrate abnormal echogenicity adjacent to facets in symptomatic patients. This study concluded that paraspinal ultrasound is neither accurate nor reproducible in evaluating patients with cervical and lumbar back pain (Nazarian *et al.*, 1998). However, these findings could be a result of the lack of ultrasound technology available at that time.

### *Ultrasound of the neck*

The neck was one of the first regions to be imaged with ultrasound, but this area has since received little mention or documentation. Ultrasound is a well established diagnostic tool for diagnosing musculoskeletal injuries of other regions of the body. The technology is proven and accepted, therefore it would seem that ultrasound has the unrealised potential to visualise whiplash injuries should they involve soft tissue damage.

## *2.9 Quantification*

Quantification of pathology allows an understanding of the extent of damage and assists in the monitoring of recovery. This section describes why quantification is necessary, how quantification of soft tissue injury is achieved, expected levels of accuracy, the effect of the operator and the effect of technology.

### *The need for quantification*

Two methods of measurement exist, qualitative and quantitative. The human eye, which captures the image, and the human brain, which processes the image is a surprisingly powerful system for recognition and identification. However, this type of qualitative analysis is based on the judgement of an operator and carries all the risks that are inherent in subjectivity. Quantitative analysis is far less susceptible to bias and should provide more reliable and consistent results; it also allows statistical tests to be performed that can ensure confidence in our results. Quantification may also facilitate detection of subtle changes, which might escape detection by visual assessment alone. To be able to quantify an injury enables a value to be assigned to the pathologies identified. This value can be used as a reference value, which is essential to describe the extent of damage and for monitoring the recovery process.

### *Quantification of soft tissue injuries*

Quantification of ultrasound images is complex. In many instances the evaluation is of what is essentially a two dimensional representation of a three dimensional object. This type of analysis is assumptive and because not all parameters required are available; errors may be introduced. It is therefore an accepted practise in ultrasound assessment, to make qualitative observations based on the operator's judgement to decide the presence or absence of pathology or disease. The operator may take measurements, but these are often not precise and are used as more of an indication or visual aid for the examiner. In order to make an objective assessment of the ultrasound images of this study, attempts have been made to identify techniques that enable a quantitative analysis. Firstly, the image must be acquired and the location of structures or lesions documented. Measurements taken from a standard anatomic reference point will allow the specific locations of structures and lesions to be precisely documented. This approach facilitates the comparison to contralateral structures. Location of previously described lesions can quickly and precisely be located for re-evaluation. This method has been described to locate equine tendon lesions (Pugh 1993). Following image acquisition, based on the interpretation of the following parameters: spectral, textural and contextural features; an analysis may be made. Spectral features are the average tonal variations in various bands of the visible spectrum. Tone refers to the various shades of grey resolution cells in an image. Textural features are created by the spatial or statistical distribution of these grey tones. Contextural feature is the information derived from blocks of pictorial data surrounding the area being analysed. Texture and tone are not independent concepts but form an inextricable relationship; context, texture and tone are always present in an image, one can dominate the other.

### *Methods of quantification using ultrasound*

The following techniques have been employed in previous studies to provide a quantitative assessment of image parameters.

#### *Computerised image analysis*

An integral feature of ultrasound equipment is its capacity to take on-screen measurements. The operator defines the region of interest using an input device such as a pen, trackball, keyboard or mouse. Measurement options usually include line measurement, a free-hand trace or predefined shapes such as ellipses. This technique is used to assess regions of interest such as pathology and for the measurements of structures. This analysis is also carried out by exporting images to a personal computer and using appropriate software. Where analysis is performed on software other than the ultrasound equipment, it is essential that calibration is performed.

#### *Cross-section measurements*

Ultrasound is a reliable diagnostic modality for the assessment of cross-section measurement of tendon (Ying *et al.*, 2003) and muscle (Emshoff *et al.*, 1999; Bertram *et al.*, 2003). Measurements of the masseter muscle taken at a given site; are found to be consistent and the scanning level with the highest reproducibility is halfway between the origin and insertion (Bertram *et al.*, 2003). Ultrasound has been found successful for the objective assessment of the size of an equine superficial digital flexor tendon cross-sectional area at predetermined levels in the tendon (Gillis *et al.*, 1995b). The ability of ultrasound to measure cross-section is used in this study to determine structure dimension and assess any gross changes in soft tissue size due to atrophy or swelling following injury.

### *Cine loop evaluation*

With the exception of ultrasound systems capable of producing extended field of view images (where multiple images are combined during the scan sweep), the scanning face of the transducer is too small to accommodate the full extent of the structure of interest. This limitation may be overcome by observing a collection of frames in a cine loop. For example, to ascertain the midpoint of a muscle, a cine scan of the entire muscle may be acquired and the middle frame within the total sweep frame set can then be calculated indicating the midpoint of the muscle (Watkin *et al.*, 2001). A cine loop is captured when it is necessary to gain a view of large areas of interest.

### *Gray scale analysis*

The B-mode ultrasound image produced by the majority of ultrasound systems has a pixel intensity range from 0-255 (where 0 is black and 255 is white). The composition of these pixels is termed echogenicity. Pathology results in changes in the tissues properties that are reflected by changes in echogenicity. These changes in echogenicity have been found to correlate well with histology (Watkin *et al.*, 2001). Echogenicity has been employed to measure fat and muscle composition (Scholten *et al.*, 2003), for the identification of neuromuscular disorders (Maurits *et al.*, 2003), for the objective and subjective determination of tendon lesions (Pickersgill *et al.*, 2001) and to accurately monitor tendon healing of equine superficial digital flexor tendon (Micklethwaite *et al.*, 2001; Pickersgill *et al.*, 2001). Computable textural features based on grey-tone spatial dependencies have been used to categorise rock formations (Haralick *et al.*, 1973). This application could be used for the assessment of soft tissue and pathology.

A disadvantage of assessing echogenicity is that it may be affected by factors other than pathology which could confound analysis. Factors that must be considered are the ultrasound equipment set-up and the subject to be assessed. In terms of equipment set-up, an increased gain will result in increased echogenicity; therefore, it is important to keep technical parameters constant throughout an assessment (Reimers *et al.*, 1993). In terms of the subject being scanned, both the thickness of the subcutaneous fat (layer of fat beneath the skin) and muscle diameter have to be taken into consideration, as these will affect echogenicity (Reimers *et al.*, 1993). The soft tissue structure will also have an effect on echogenicity, for example the anisotropic properties of tendon (Crass *et al.*, 1988).

In this study, analysis of echogenicity will be used for structure and pathology identification and its subsequent quantification.

*Speckle tracking and elastography*

Biological tissues experience mechanical deformation and studies have shown it to be possible to quantify this displacement using ultrasound (Revell *et al.*, 2003). A computer program is able to track the displacement of pixels within the image between one frame and the next producing a record of the relative movement of these pixels; this process is called speckle tracking. Elastography is the measurement of the elastic properties of tissue and this can be measured using the speckle tracking technique (Revell *et al.*, *in press*). Measurement of changes in mechanical deformation may provide an indication of pathology.

***Accuracy of measurements from images***

The image analysis techniques available for quantification have been discussed, the accuracy of taking measurements using these techniques will now be considered.

The accuracy of a measurement is dependent upon the following factors:

- Selecting the correct region of interest to be scanned.
- Clear and complete depiction of the structure of interest.

- The position of the calliper markers and correct selection of the boundaries.
- Use of the correct value for the velocity of ultrasound in tissue to calculate the image scale.
- The accuracy of the electronic measuring device.
- The equipment used. Although using the same equipment to undertake repeat examinations is preferable; particularly in relation to clinician familiarity with equipment; in clinical practice this is not always possible.
- The individuality of the operator, such as skill and knowledge, has an impact on the accuracy of the measurement.

The following technical questions should be considered when using a measuring device (McDicken 1991):

- Is the scale of presentation of the image as large as possible?
- Could the image be made sharper by altering the sensitivity or frequency?
- How accurate is the procedure and is it able to give clinically significant result?
- Is the measurement reproducible by the same/another operator?
- Would serial measurements improve the value of the technique?
- Are the measurements made comparable to other workers in the field?
- How many parallel sections are required for accurate calculation of volume? A greater number of sections would increase accuracy.
- How could the measurement be improved?
- Is this the best quantity to measure?

It is important to have an understanding of the limitations of a measuring system. In this study, these limitations will be considered and accuracy will be assessed.

### *How technique and technology affect image acquisition and analysis*

The capability of the equipment to provide the best representation of the structure of interest and the ability of the user to optimise the equipments performance and make use of this data will directly affect quantification. These factors are highlighted in the clinical setting where variations of technology and technique exist.

#### *Technique*

If the operator has poor technique and is unable to make the best use of the equipment, this will result in the capture of an image that does not represent the structure of interest and will ultimately obscure analysis. It is important to be aware of how the positioning of the transducer will affect the image and that it should be positioned perpendicular to the structure of interest. Movement artefact caused by the subject or transducer; should be minimised, as these will be reflected in the measurements (Emshoff *et al.*, 2003). It is important to minimise variation when repositioning the transducer at each assessment so that the same region can be assessed. Pressure on the transducer will affect structure appearance by causing deformation or a change in orientation and therefore a similar pressure should be maintained.

#### *Technology*

With the advancement of technology, the ability of ultrasound systems to depict the structure of interest and analyse improves, thus providing the potential for greater accuracy. It is important to appreciate the ability of the ultrasound system and any limitations of the equipment. The ultrasound image acquired represents a snapshot in time. What is essentially a three dimensional structure is represented as a two dimensional image. There are ultrasound systems capable of capturing a three dimensional image, the equipment used for this project does not have this capability. For the majority of the time, two dimensional analysis provides sufficient information but limitations exist:

- Two dimensional analysis allows linear dimensions and cross-sectional area to be assessed, however, an important clinical parameter is volume and this cannot be accurately determined. As a result, gross assumptions are often made when estimating the volume.

- Some views are impossible to obtain due to the arrangement of structures and other structures such as bone impeding the investigation.
- Optimal two dimensional scan views maybe overlooked and it is often the case that an image is acquired for analysis later; possibly by a different user. If a three dimensional image was captured, this would permit a virtual examination later, and the best view could be obtained.

How the acquired image will be analysed must be considered. It is important to preserve the integrity of the acquired data so that accurate measurements may be made during analysis, this is especially true when transferring images for use on other systems.

A very important component in the effective and successful use of the ultrasound equipment is operator competence. It was necessary for the author to be trained in the operation of the ultrasound equipment and to be aware of its capabilities.

### *Effect of operator on image acquisition and analysis*

We are all individuals with differing mental and physical attributes that result in unique characteristics including dexterity, interpretation and attention. To execute a task, we draw on these characteristics and therefore our individual inherent abilities lead to a variation between others in our capacity to perform.

### *Inter/intra observer variability*

For a measuring technique to be of value, it is important that it is both accurate and repeatable. In a clinical setting, it is possible that a patient could have a different examiner at a later date. In order for a valid assessment to be made, measurements need to be consistent. To understand how useful ultrasound can be as a diagnostic tool, it is important to identify the level of skill required by the operator and how interpretation varies between users. Image acquisition is found to be consistent between operators (Pickersgill *et al.*, 2001; Ying *et al.*, 2003; Klauser *et al.*, 2004). However, different operators may have different opinions regarding framework and this could result in an operator consistently returning larger/smaller measurements (Pickersgill *et al.*, 2001). Significant variability can result when different operators undertake different stages of an examination (Pickersgill *et al.*, 2001). To reduce confounding during investigations using multiple persons, one operator should undertake image analysis, although different operators may undertake image acquisition (Pickersgill *et al.*, 2001). This point must be considered; while in clinical practice, image analysis is undertaken at the time of examination by the same operator who undertook image acquisition, during research investigations or at follow-up clinical assessments, different operators would most likely be involved.

### *Skill*

Image acquisition is found to be consistent between operators of different skill (Pickersgill *et al.*, 2001). In terms of the level of skill required to make an assessment, an inexperienced musculoskeletal sonographer can achieve acceptable performance if given appropriate training (Balint and Sturrock 2001).

It is common opinion that one of the major disadvantages of musculoskeletal ultrasound is operator dependency. The operator must define what they believe is the region of interest, and it is possible that the true extent of the injury is not measured. As long as the same operator carries out any future measurements, assessment is made based on their judgement and criteria, which in turn minimises variation; and therefore the measurement is likely to be more consistent. For this study, it was important to determine: a) how transferable is the technique to assess neck pathology; b) how well the author was able to assess images, as the author will be the primary investigator. A comparison of the author's ability compared to others will ascertain the reproducibility of the assessment.

### *Quantification process*

It was important that we have a good grounding to base our quantification on, and this starts with the successful capturing of an image. An appropriate method of analysis must then be chosen. An appreciation of both the systems and our own capabilities and limitations is essential when collecting and interpreting data. Ultimately, the clinical relevance of these measurements of pathology must be ascertained.

## *2.10 Chapter Discussion*

This chapter has given an indication of the vast array of background research completed. It has identified the complexity of the technology and provided an overview of the use of ultrasound as a diagnostic aid to identify damage to the musculoskeletal system. It can be appreciated that there are many skills required together with an extensive knowledge of the subjects surrounding this topic, for these to be successfully utilised in new applications. Although ultrasound as an imaging tool for the musculoskeletal system is well established, it appears to have been neglected for the investigation of the neck. The assessment of neck injury, such as whiplash, that has an increasing incidence is in great need of having a diagnostic tool made available. Such a facility will assist the clinician and help the victim by providing early diagnosis, accurate prognosis and effective monitoring of recovery.

# Chapter 3: Methodology

## *3.1 Chapter Summary*

This chapter discusses the ultrasound equipment used for this study, general considerations of scanning technique and operator training, image analysis programs, the use of phantoms to measure the accuracy of the equipment and concludes with a discussion on the risks and precautions of using ultrasound. Methodology and scanning technique specific to experiments will be discussed in the relevant chapters.

## *3.2 Study Participants*

All subjects involved in the research of the study were over the age of 18 years old and gave their informed consent to participate. The University of Nottingham ethics committee gave approval for the inclusion of healthy subjects in the study. Inclusion of patients of the Queen's Medical Centre, Nottingham, UK was by the approval of the Queen's Medical Centre ethics committee.

### *Subject stature assessment*

Where experiments assess the ability of ultrasound to image subjects, the effect of stature will be considered. Body mass index (BMI) indicates a persons body fat calculated from their height and weight. The following formula is used to calculate BMI:

$$\text{BMI} = \frac{\text{weight in kilograms}}{\text{height in meters}^2}$$

The resulting figure from this calculation will fall into one of the following BMI categories:

Underweight = <18.5

Normal weight = 18.5 - 24.9

Overweight = 25-29.9

Obese = 30>

The way this calculation works is that according to the weight categories, any person with a BMI over twenty five would be classified as overweight. However, being rated in the overweight or obese categories does not necessarily mean that they have excess fat. These categories are based on scientific findings that the risk for disease increases as BMI increases. Other methods used to determine fat include callipers (skin-fold measurement), underwater weighing, bioelectrical impedance and computerised topography. However, these methods are either very expensive, need highly trained personnel or are not available; and therefore BMI calculation was chosen over these methods.

## *3.3 Biological Specimens*

### *Biological tissue*

Animal tissue provides an acceptable model for biological studies where information needs to be extrapolated for human tissue. Animal tissue is more readily available and avoids the ethical considerations required for the use of human tissue. The animal tissue used in these experiments included equine (horse), bovine (cow), porcine (pig) and ovine (sheep). Porcine and ovine blood was collected at slaughter in tubes containing anticoagulant. The university abattoir based at the Sutton Bonnington Campus, supplied animal tissue and blood. Specific tissue details are provided with the relevant experiment.

### *Preparation of anticoagulants*

When blood is removed from the subject, it will coagulate unless prevented by the addition of an anticoagulant. Three different mixtures of anticoagulant: anti-coagulant dextrose (ACD), sodium citrate and EDTA (disodium salt) were assessed for suitability for the purposes of this experiment by adding to a sample of blood (Rhodri Jones personal communication 2004) (*see Appendix D*). All anticoagulants performed equally well, all preventing the blood from coagulating; however, sodium citrate was chosen as it was most easily obtainable.

### *3.4 Technical Specification of the Ultrasound Equipment*

All experimental work carried out in this study utilised the same model of ultrasound equipment. The ultrasound equipment employed for this study represents what would typically be used in the clinical setting. The equipment used was a 'Diasus: Dynamic Imaging Application Specific Ultrasound' manufactured by Dynamic Imaging, Livingston, UK (*fig. 23*) (*see Appendix E*). This ultrasound equipment is a pulse-echo imaging system, the organisation and operation of this type of system has been discussed in Chapter 2; and here consideration is only given to the transducer chosen for this study. The imaging software used is Dynamic Imaging Software Version P7.03, 2001.

**Figure 23: Diasus ultrasound equipment**

*Transducer*

Three transducers of different frequency are available for use with the 'Diasus'. All transducers are ultra wideband linear-array transducers. Each frequency of transducer has a different performance characteristic with different abilities of resolution and penetration and the manufacturer describes these as follows:

*L5-10MHz transducer*: provides deep penetration. This transducer is useful for examining deep lying structures such as shoulder and thigh muscles.

*L8-16MHz transducer*: provides high resolution with outstanding image detail and tissue differentiation.

*L10-22MHz transducer*: provides detailed images of the most superficial structures.

All transducers were considered and their ability to image the neck musculoskeletal complex was assessed. It was concluded that of the three transducers available, the 8-16MHz transducer was the most appropriate frequency to use for this study. Table 5 discusses the findings from the range of transducers and figure 24 illustrates the different imaging capabilities with a comparative view of the sternocleidomastoid muscle. The 8-16MHz transducer has a good resolution to a depth of around 3cm; and this was ideal for imaging the structures of the neck and the deeper facet joints and discs.

**Table 5: Comparison of Diasus transducers**

| Transducer frequency | Penetration depth | Resolution |
|---|---|---|
| *5-10MHz* | penetration depth good | skeletal spine visualised. Structures to the spine imaged but with inadequate resolution for evaluation of soft tissue architecture. |
| *8-16MHz* | penetration depth was compromised | skeletal spine visualised and soft tissue architecture of structures was exquisite. |
| *10-22MHz* | penetration depth poor | skeletal spine not clearly visualised, very poor resolution of deep structures. Very good definition of the most superficial structures. |

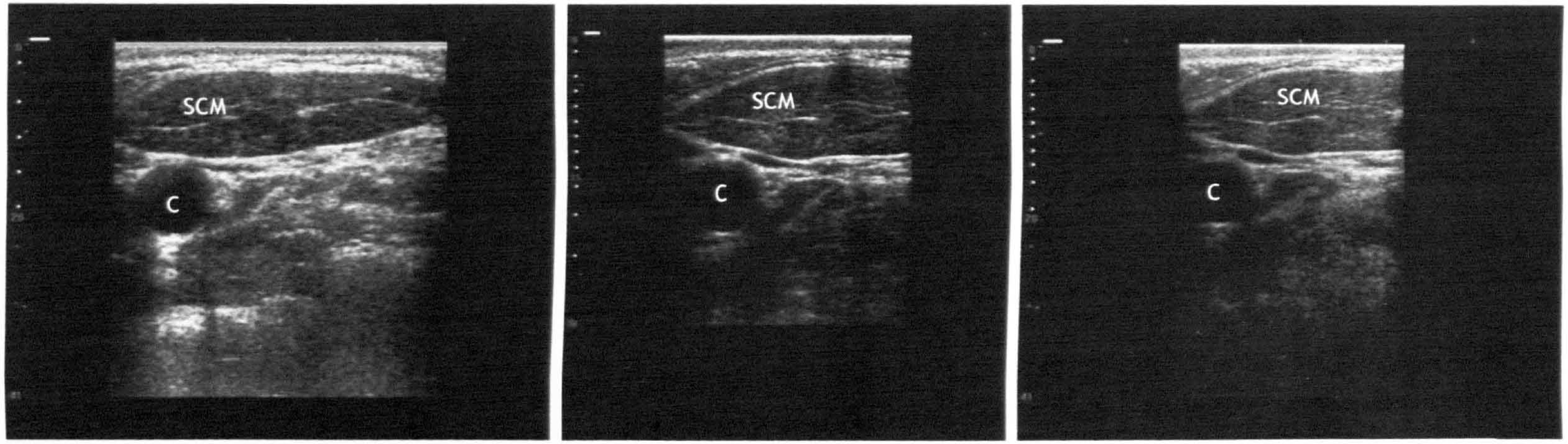

**Figure 24: Comparison of transducers**
Transverse scan of sternocleidomastoid muscle using transducers with frequencies of 5-10MHz (left), 8-16MHz (middle), 10-22MHz (right). (SCM = sternocleidomastoid, C = common carotid artery)

### *Coupling medium*

Air interferes with ultrasound transmission resulting in poor quality images. Therefore, a 'coupling medium' that excludes air is required between the transducer and the object being scanned. Two methods are commonly employed to achieve this which are called immersion scanning and contact scanning (McDicken 1991) both approaches have been applied in this study.

### *Immersion scanning (water bath scanning)*

In this technique, the transducer is coupled to the object via a water bath. A consideration of using a water bath is that the absorption of the ultrasonic pulse is negligible; and the pulse can be reflected back and forth many times. This is called reverberation and multiple reflection artefacts result. To keep these artefacts clear from the tissue, the depth of the water must be greater than the depth of the surface of interest. Artefacts are easily identified as the first reverberation echo is twice as far from the transmission pulse as is the water/skin interface echo.

### *Contact scanning*

This method involves the direct application of the transducer to the object being scanned. Coupling gel is applied or a stand-off pad used. Coupling gel is a water based gel placed between the transducer and object surface. Stand-off gel is a semi-solid block of silicone gel material and has ultrasonic properties similar to those of tissue. Stand-off gel is placed between the transducer and object surface; good contact can be made and the attenuation of the gel is such that reverberation in the stand-off layer is not a problem. A consideration when using stand-off gel is that it increases the distance between transducer and object, therefore penetrative depth through the actual structure is decreased. The coupling gel used in this study was a water soluble and hypoallergenic ultrasound transmission gel, 'Aquasonic 100' (Parker Laboratories Inc., USA) and the stand-off gel used was an aqueous ultrasound gel pad, 'Aquaflex' (Parker Laboratories Inc., USA).

Deformation of the object being scanned may occur when the transducer is applied, however this deformation can be minimised by applying a generous amount of contact gel. In a water bath, no contact is made with the structure and deformation cannot occur.

## *3.5 Scanning Procedure*

### *General considerations when scanning*

Prior to commencing this research, the author's academic background in anatomy and through background reading, ensured that the author had extensive knowledge of anatomy, particularly of the neck region in order to identify and understand the best approach for imaging the region of interest. For the purpose of examination and for the selection of the same region for follow-up examination, it is important to be able to define and identify the region of interest. The region of interest may be accurately recorded by identifying external landmarks and palpable structures; and by using a co-ordinate system whereby a measurement is made from a predetermined point to ensure the same region is identified at a later date. Structures of consistent position viewed internally using ultrasound also provide the operator with landmarks. These landmark positions and measurements are specific to the individual being scanned due to natural anatomical variation. Images were acquired with the transducer oriented in transverse and longitudinal positions to provide images in the transverse and sagittal planes respectively (*fig. 25*).

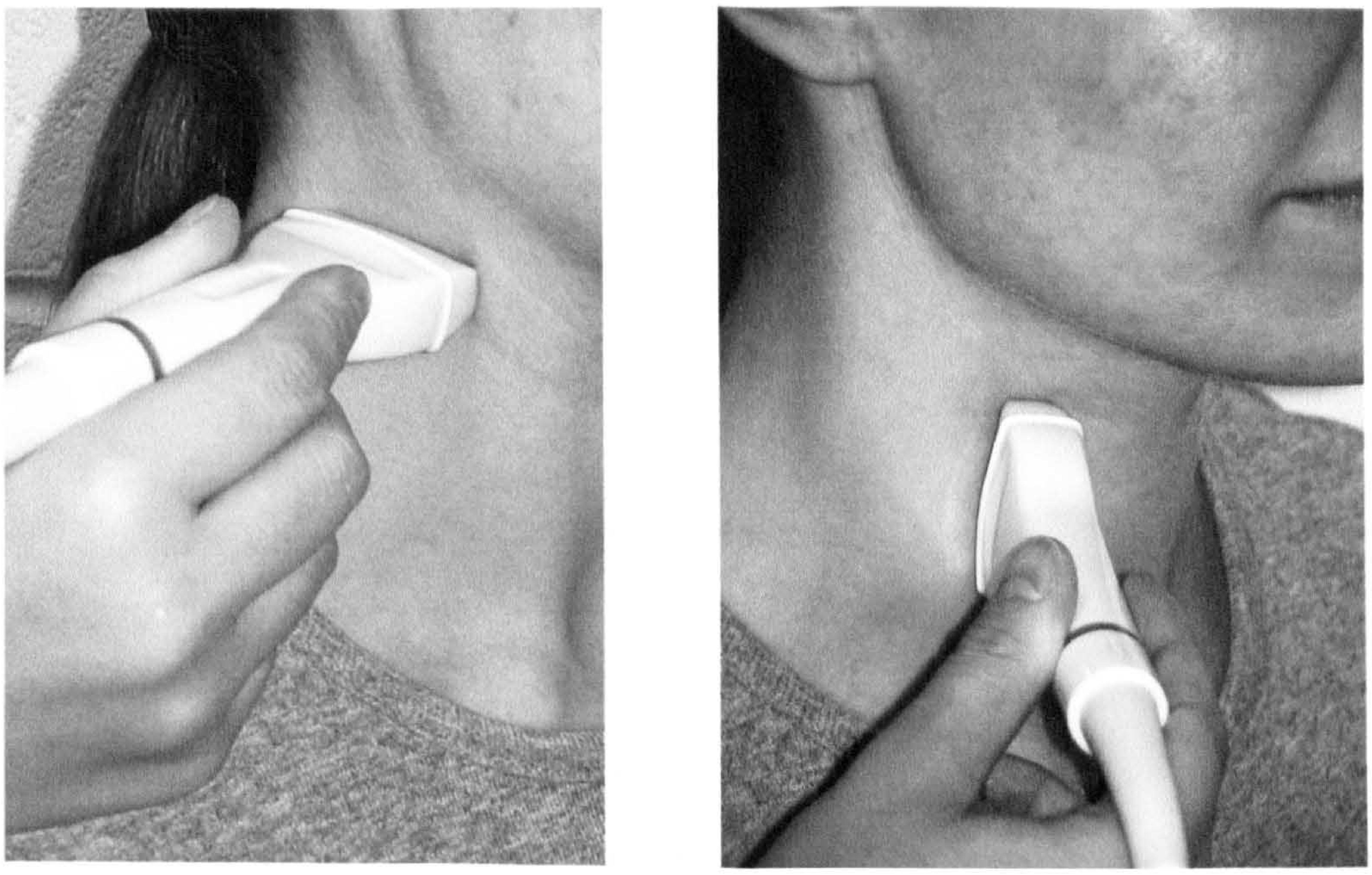

**Figure 25: Transducer orientation**

The Diasus 8-16MHz transducer in both transverse (left) and longitudinal (right) orientation.

### *Training of the operator*

Successful acquisition and interpretation of ultrasound images is highly dependent upon the skill and experience of the operator. The ability of the operator to use the equipment will affect the quality of the image obtained; therefore the author took every opportunity to gain as much experience and knowledge as possible and hone their skills. Prior to this study, the author had never used diagnostic ultrasound. To aid understanding, the author participated in musculoskeletal clinics with consultant radiologists of the Queen's Medical Centre, Nottingham, UK: Mr Robert Kerslake (Consultant Musculoskeletal Radiologist, Radiology Department) and Professor Mark Batt (Consultant and Special Professor in Sports Medicine at the Centre for Sports Medicine). Further practise of the technique and understanding were obtained from scanning colleagues, both in health and following injury; to gain an appreciation of the types of injury that can affect the musculoskeletal system. *In vitro* experiments of simulated injury on animal tissue were designed to replicate *in vivo* injuries enabling the author to gain an understanding of the ultrasound appearance of pathology, scanning technique and ideas of how to quantify pathology (*see Chapter 6*). This *in vitro* work provided an insight into the appearance of normal and pathological anatomy; in preparation for the study of patients with whiplash injuries (*see Chapter 8*). An explanation of this work will be included in the relevant experimental chapters. For consistency, the author acquired all images presented in this thesis.

### *3.6 Image Analysis*

Images were displayed in a standard format (*fig. 26*). The scale on the left of the screen alters depending on the magnification setting but in all cases, the scale represents the depth from the face of the transducer in millimetres. Arrows within the scale bar represent focus and appear red when inactive and yellow to represent the position of the focus. Data pertaining to the ultrasound settings are displayed to the right of the screen. Patient information, date and time are displayed at the top of the screen. The images captured during the process of the scan were most representative to the operator at the time as a mental image is formed which contributes to understanding of the image. Many factors contribute to how an image appears at the time it is captured such as lighting within the room, the brightness display of the monitor and the user's perception of the image on the day. From the moment the image is captured to its display in print, it is possible for the value of the image to be lost in translation.

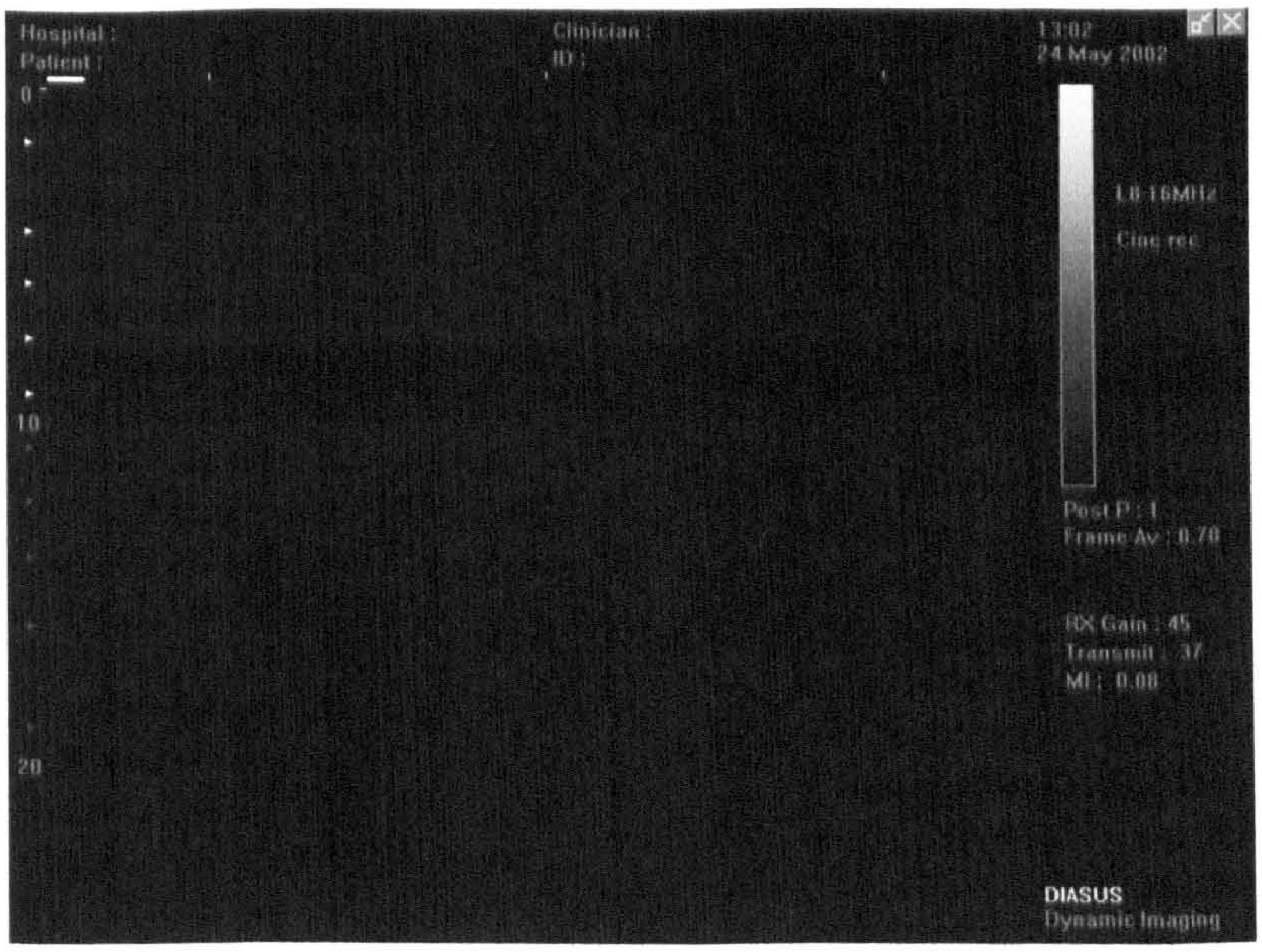
Hospital :
Patient :
Clinician :
ID :
13:02
24 May 2002
L8-16MHz
Cine rec
Post P : 1
Frame Av : 0.70
RX Gain : 45
Transmit : 37
MI : 0.08

Figure 26: Diasus display screen

Image analysis took place after the image had been captured. Measurements were made on the display screen. Calliper systems are normally an integral feature of ultrasound equipment and the 'Diasus' has this facility. Having captured the image, this was saved as a computer standard file on disk. Once an image had been saved as an image file, analysis was carried out in a graphics or image analysis package; these packages were available on a personal computer. When measurements were made on a recorded image elsewhere, it was important that the analysis software was calibrated to the image scales presented by the ultrasound display.

*Measuring a line*

The electronic calliper was used to make a measurement of a linear dimension. Measurements were superimposed on the frozen image; two marker spots were adjusted to lie on the boundaries of the structure of interest. The numeric value for the distance between the spots was displayed. Several dimensions at a time were measured in this way. A scale on the 'Diasus' display indicates the depth of the image. Accuracy was greatest when the image is displayed on the largest convenient scale as this provides the user with a clear view of the image and aids differentiation.

### *Measuring area and circumference*

To measure area and circumference, an indicator spot was moved around the area of interest using a track ball; this trajectory was superimposed over the image. The length was automatically calculated and displayed on screen. If the loop was closed by returning to the start point, values for the circumference and area were also displayed. Volume was calculated manually if the area of parallel planes of the scan, and the overall distance the region of interest spans was known. This volume was the product of the average area of the parallel scans and the depth of the region of interest.

### *Using electronic callipers*

When the indicator was placed at a point on the image, two coordinates were recorded that define the position of that point in the plane. These coordinates were the X and Y Cartesian coordinates that respectively define the horizontal and vertical distances of the point from the origin. When the operator positioned the indicator at an appropriate point, the coordinates were recorded and stored in the computer memory. The indicator was then moved to a second point and the process repeated. The indicator was normally moved continuously, and the coordinates of neighbouring points were recorded automatically. The co-ordinates were then resolved and the distance between points and area was determined.

### *Analysis away from the ultrasound equipment*

When analysis was conducted away from the ultrasound equipment using a separate computer for analysis; it was important to maintain image integrity and calibrate between the ultrasound equipment and the personal computer software. This was achieved by using the image analysis software to take measurements of the scale on the ultrasound image. This information was then used to calibrate the image with the analysis software.

Image analysis was carried out using the image analysis software 'Image J Version 1.31' (Wayne Rasband, USA). Image manipulation for presentation was carried out using 'Jasc Paint Shop Pro$^{TM}$ Version 6.0' (Jasc Software Inc, USA) and 'Adobe Photoshop CS Version 8.0' (Adobe Systems Inc, USA). Animations of images recorded in cine mode were recompiled in 'Jasc Paint Shop Pro$^{TM}$ Version 6.0' (Jasc Software Inc, USA).

### *3.7 Phantoms*

The performance of the ultrasound equipment was assessed periodically using a pre-calibrated phantom. The phantom used in this study was a 'Diagnostic Sonar Resolution Test Object - An element of the Cardiff test system' (Diagnostic Sonar Ltd., Livingston, UK) (*fig. 27*). This phantom mimicked the tissue properties of liver and simulated this tissues characteristic behaviour under ultrasound, such as scattering and attenuating properties. Nylon lines are distributed at known distance and formation throughout the phantom to provide indicators for measurements (*fig. 28*). Phantoms assess the ultrasound equipment for the following:

- detail resolution
- contrast resolution
- penetration and dynamic range
- Time Gain Compensation operation
- accuracy of depth and distance measurement

**Figure 27: Phantom device**

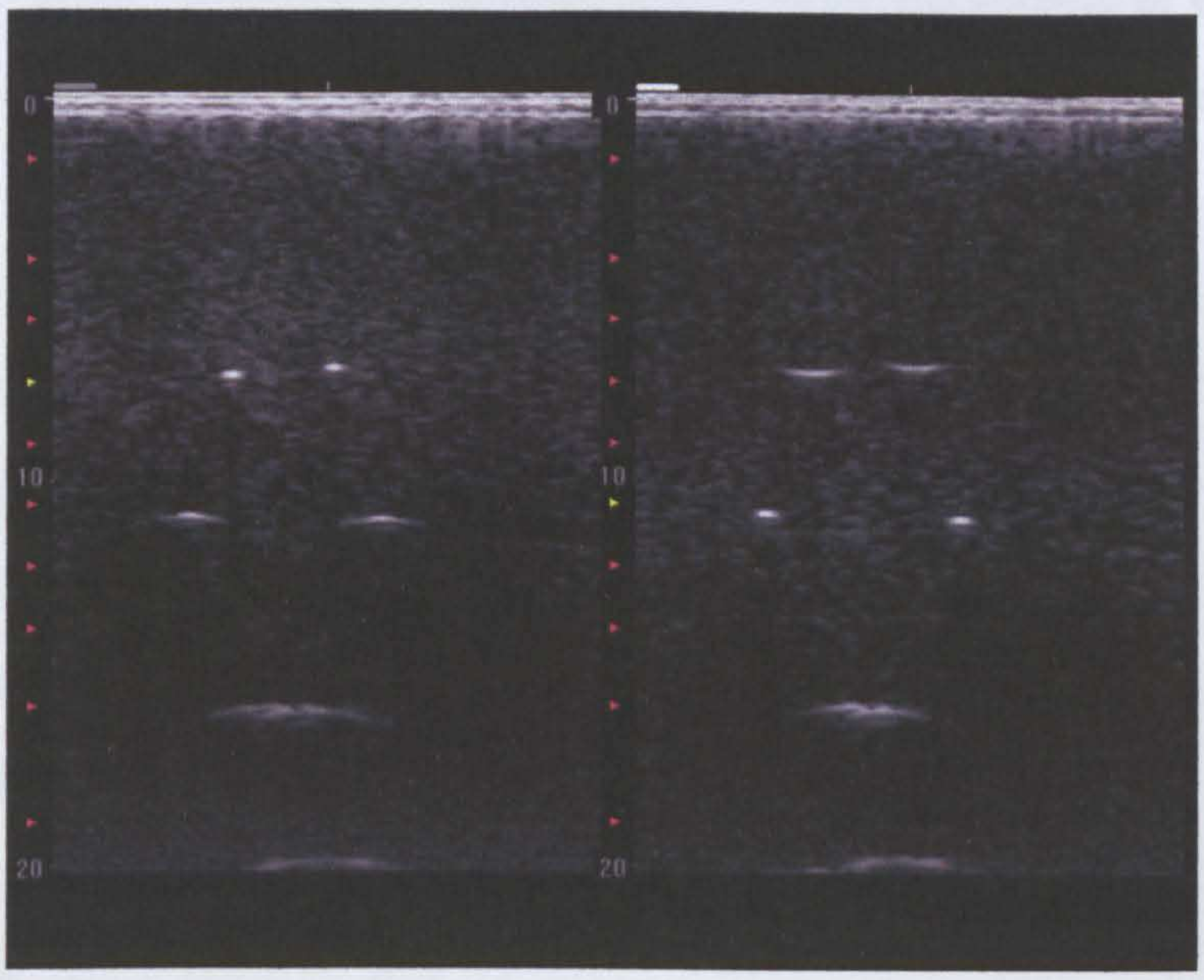

**Figure 28: Testing of focus using the phantom**

Focus set on uppermost object (left), focus set on the next object below (right).

It was important that ultrasound equipment is calibrated to ensure reliable and accurate quantification and diagnosis. This was especially important in a study that focuses on quantification. A phantom was not readily available to this study and calibration checks were made annually, however, calibration was found to be consistent. Ideally, for a study that relies heavily on quantification abilities, calibration checks need to be carried out on at least a monthly basis.

### *3.8 Artefacts*

An appreciation of artefact was essential for analysing the acquired images. An artefact is an additional, missing or distorted image that does not conform to the real image of the structure being examined. They result from distortion or attenuation of the beam and are due to many different causes such as inadequate scanning technique, and from the nature of sound and its interaction with tissues. Artefacts can impede diagnosis and in some instances aid diagnosis. Typical artefacts encountered with diagnostic ultrasound are considered:

*Incomplete insonation* - artefacts due to incomplete imaging are a source of error, since only that part of the tissue or any object that is actually in the acoustic beam will be imaged.

*Reverberation* - echoes appear on screen that do not represent any structure in the body. This occurs when the US beam encounters an interface with a very different acoustic impedance (e.g. from intestinal gas to ribs). Reverberation is identified by the appearance of equally spaced parallel lines that decrease in brightness as the distance from the transducer increases, or the production of a mirror image of the object being scanned. Reverberation can obscure tissues that lie behind.

*Refraction* - the beam deviance may be misinterpreted and produce images of structures which are out of place. This can obscure accurate measurement and depth assessment in some instances. This artefact may be prevented by keeping the transducer is angled perpendicular to the region of interest and to boundaries.

*Acoustic shadowing* - shadowing occurs when the entire beam is directed back to the transducer by a bright reflector or is absorbed. This creates a region with absence of echoes posterior to the reflector, and the area is generally clearly delineated. Bone and calcified regions act as reflectors. In some instances, acoustic shadowing may be overcome by using a different scanning angle.

*Enhancement or through transmission* - occurs when there is little attenuation of the beam. Enhancement takes place due to the increased amplitude of the displayed signals beyond the low attenuating mass. This typically occurs if the beam enters a tissue or field such as a fluid filled cyst. Enhancement allows diagnosis of a cyst and may be used to evaluate pathological characteristics of other masses.

The tissue characteristics can create artefact, significant subcutaneous fat and muscle can scatter ultrasound, making deeper structures less distinct. When abnormalities are suspected, scans are taken from a variety of angles to eliminate the possibility of artefact.

### *3.9 Chapter Discussion*

The methodology described in this chapter provides an overview of the standard equipment used throughout this study and gives reasons for its choice. The procedure used for scanning has been discussed and the author's experience and training have been outlined. The image analysis tools available on the ultrasound system and how they operate have been explained. The requirement of phantoms for establishing equipment quality control has been identified. The occurrence of artefact when imaging has been discussed together with how it can be identified and avoided. A method for evaluating the subject's stature which may affect ultrasound capabilities has been considered.

# Chapter 4: Ultrasound of the Neck

## *4.1 Chapter Summary*

This chapter discusses the experiments that were carried out to produce an ultrasound map of the cervical region. These investigations provided the reference material essential for the investigation of pathology later in the study by providing a normal picture to which deviations could be identified. The technique used for scanning patients is established and described. Options available for image processing are also discussed.

Project objectives fulfilled in this chapter:

- establishing a technique for scanning the neck - particularly of the posterior structures
- assess the normal ultrasound appearance of the neck

## *4.2 Background*

The anterior anatomy of the neck as it appears with ultrasound has been well described with regard to lymph and gland structure; however, little attention has been given to posterior structures. It was necessary to create an ultrasound map of the neck to provide reference material that would be essential for the investigation of pathology in this region later in the study. Magnetic resonance imaging is well established for soft tissue imaging and this was obtained as a comparative technique to ultrasound. The series of experiments described in this chapter establish how the anatomy of the neck appears in the healthy subject and addresses the feasibility of imaging structures. Cadaveric studies enabled a direct visualisation of neck anatomy that could be correlated with those images captured with ultrasound. A scanning technique that gave a thorough and complete examination of the neck was established and landmarks were identified that would provide useful reference points for navigation. Image processing techniques and their value to this study were investigated.

## *4.3 Series of Experiments*

The following series of experiments were conducted to establish a technique to scan and assess the normal ultrasound appearance of the neck:

Experiment 1: *Magnetic resonance imaging of the neck*

Experiment 2: *Ultrasound of the cadaveric neck*

Experiment 3: *In vivo ultrasound imaging of the neck compared with cadaveric sections*

Experiment 4: *Ultrasound anatomy of the neck in vivo*

Experiment 5: *Extended field of view imaging*

### Experiment 1: Magnetic resonance imaging of the neck

#### *Background*

Magnetic resonance imaging (MRI) was used to obtain images of the cervical region as it is a well established technique for the imaging of soft tissue structures and one that has also been used to review whiplash injury. This investigation with MRI allowed an understanding of the anatomical arrangement of the structures of the neck, as well as giving an appreciation of anatomical variation in the normal population. MRI images could be compared directly to ultrasound images to give a comparison of the two imaging techniques. The radiology department of the Queen's Medical Centre, Nottingham, UK, had recently installed a new MRI system and needed volunteers for its calibration. This calibration activity provided an opportunity to acquire images of the neck.

#### *Method*

The cervical region of three asymptomatic subjects (a 22 year old and 32 year old female, 36 year old male) was scanned using MRI and ultrasound. The MRI system used was an 'Intera 1.5 Tesla' (Philips Medical Systems, Netherlands) operated by qualified technicians of the Queen's Medical Centre, Radiology Department. The 22 year old female subject was also scanned with an 'ATL HDI 5000' (Philips Medical Systems, Netherlands) connected to a 16MHz CL15-7 linear array transducer (Philips Medical Systems, Netherlands), an ultrasound system which is capable of producing panoramic images. These panoramic images provide an extended field of view which aided understanding of the relationship of structures and facilitated comparison of ultrasound images against the MRI image as both techniques produce a cross-section view of the neck. Panoramic images were compiled from transverse images acquired continuously from the representative level of the C4/5 interspinous space. The images produced by MRI and ultrasound and their imaging processes were compared.

### *Results*

Images of the anterior and posterior structures of the neck were obtained from MR imaging (*fig. 29*) and ultrasound imaging (*figs. 30 and 31*).

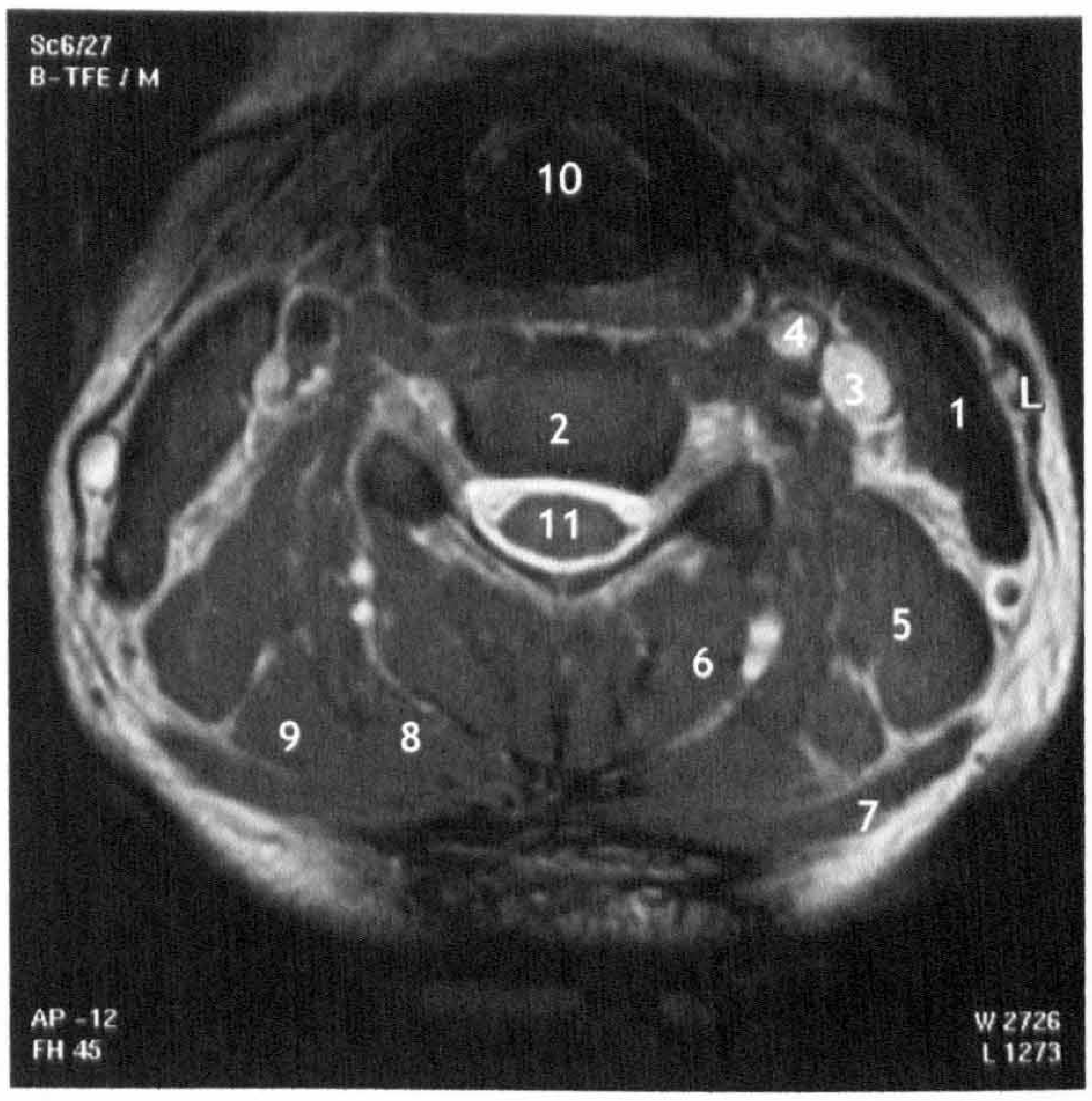

**Figure 29: Magnetic Resonance Imaging of the neck**

Cross-section view

1 - sternocleidomastoid
2 - vertebral body
3 - internal jugular vein
4 - common carotid
5 - levator scapulae
6 - erector spinae
7 - trapezius
8 - semispinalis
9 - splenius capitis
10 - trachea
11 - spinal cord

**Figure 30: Ultrasound of the anterior neck**

Transverse scan

1 - sternocleidomastoid
2 - thyroid gland
3 - common carotid artery
4 - strap muscles
5 - trachea
6 - thyroid cartilage
7 - platysma
8 - skin

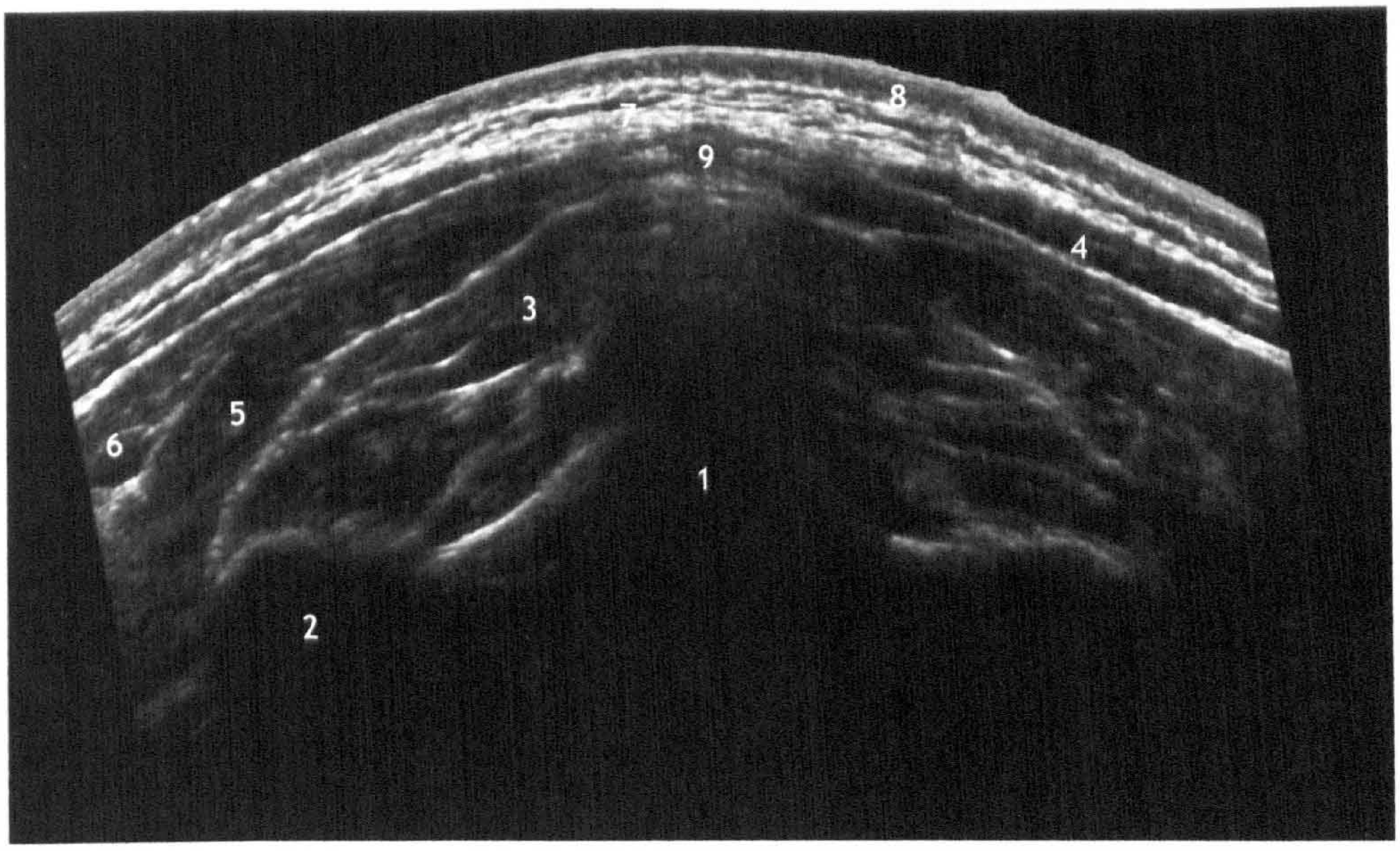

**Figure 31: Ultrasound of the posterior neck**

Transverse scan

1 - spinous process of C4
2 - transverse process C4
3 - erector spinae
4 - trapezius
5 - semispinalis
6 - splenius capitis
7 - adipose tissue
8 - skin
9 - ligamentum nuchae

The characteristics of magnetic resonance imaging and ultrasound are compared in Table 6.

**Table 6: Comparison of MRI and ultrasound**

| | MRI | Ultrasound |
|---|---|---|
| **Region of interest** | Whole section visible | Restricted by the width of transducer (for this study 26mm), although this could be increased if using equipment with panoramic imaging capabilities |
| **Measurement/identification** | Accurate slice identification and measurements identified by the system | Difficult to ascertain exact position of image although a relative position can be established at the time of imaging and noted by the user |
| **Image** | Acquisition time, static image | Real time imaging, dynamic image |
| **Tissue architecture** | Detail limited, appearing as shades of grey and structure outline | Detail exquisite, fibre orientation visible, muscle fascia visible |
| **Penetration** | Complete penetration through slice | Limited penetration (16MHz transducer), deep structures not clear |
| **Structures visible** | All structures observed | Most structures observed, exceptions being bone and cartilage and where depth of structure is such that attenuation occurs. |
| **Time to capture image** | Extensive, scans duration is approximately 45 minutes. There is a risk of motion artefact occurring. | Immediate image acquisition. Artefact may be immediately recognised and corrected. |
| **Patient feelings** | Isolated, trapped, unnatural situation (in an enclosed space), had to wear a gown | More relaxed atmosphere, not daunting, wear normal clothes |
| **Patient communication** | Limited communication | Patient freely communicates with the operator, provocative technique therefore patient can indicate affected area |
| **Risks** | Minimal exposure advised | No known side effects, although minimal exposure advised |

| | | |
|---|---|---|
| Cost | Expensive, resource intensive, needs dedicated space | Economical, minimal operators, portable |

*Extended field of view images*

The panoramic image facility of the 'ATL HDI 5000' uses successive smoothly acquired ultrasound images which undergo real-time image processing and point-matching to produce an extended field of view (Weng *et al*, 1997; Entrekin *et al*, 2001). This extended field of view image of the neck greatly enhanced the ability to appreciate the anatomical area scanned, and the layout of the structures imaged corresponds well with images acquired using MRI; however, ultrasound showed greater detail than MRI.

***Discussion***

The images acquired using MRI confirm the anatomical arrangement of structures in the cervical region and further aided understanding of the anatomy and provided images for comparison with those acquired using ultrasound. Images of both the anterior and posterior neck have enabled the formulation of an 'ultrasound map' of the neck region. The extended field of view images allows a greater appreciation of the arrangement and characteristics of structures in the neck region and aided orientation when working on the more limited size of scan afforded by the 'Diasus' equipment.

Images produced using magnetic resonance imaging and computed tomography provided a depiction of anatomical section as well delineated, shaded regions where muscle boundaries may overlap and with no detail of tissue architecture. Ultrasound surpasses these modalities with its ability to identify subtle differences between muscle groups and provide unparalleled information of the tissue architecture. This is important for the evaluation of pathology, where it may involve subtle changes to the tissue architecture and the level of imaging offered by ultrasound is essential if these changes are to be identified. In the past, images were acquired using less sophisticated ultrasound equipment with lower resolution and processing power. Interpretation of such images were sometimes difficult, however, the advent of high-resolution ultrasound equipment has made interpretation easier. It is now possible to see the intrinsic appearance of specific structures.

From the patient's perspective, ultrasound is a patient friendly technique compared to MRI which may cause patient discomfort. The virtues of ultrasound have been discussed in detail elsewhere in this document (*see Chapter* 2).

## Experiment 2: Ultrasound of the cadaveric neck

### *Background*

Cadaveric dissection is an accepted and highly valued practise for gaining an understanding of the anatomy of the living person. Dissection enabled a greater understanding of the three-dimensional arrangement of the neck region and confirmed the arrangement of structures as they appear with ultrasound. Ultrasound is an imaging modality used on the living person and one of the first questions to ask is just how much of the information gleaned from a cadaveric study can be transferred across to the living person. Ultrasound relies on the densities and properties of the material being scanned to produce an image (*see Chapter* 2). Cadaveric tissue is obviously vastly different from living tissue; trauma may be evident, dehydration of the tissue will occur, the position of the body post mortem and during the embalming procedure may alter the orientation and shape of structures and once fixed will be relatively inert in their behaviour, all this in turn can lead to distortion and artefact. Preservation of cadaveric tissue by embalming is carried out to prolong the lifespan of the material and prevent bacterial infection and decay. Fixing by its very nature will affect the properties of the tissue. The embalming procedure causes the cadaveric tissue to be harder, stronger and less elastic than during life. These changes in the tissue density and character will affect the way ultrasound behaves. Relatively, the structures will be in the same position, and to some extent proportion, and thus provide a good representation. Ultrasound images of cadaveric specimens have been successfully compared to ultrasound images of living tissue (Klauser *et al.*, 2004). It was envisaged that ultrasound scanning of cadaveric material during dissection would allow a direct evaluation of the appearance of structures and be used to confirm *in vivo* findings.

### *Method*

The subject used for this study was an 84 year old male, whose cause of death was a CVA (cardiovascular accident) who had volunteered to be used for medical research. The cadaver had been preserved in accordance with the embalming procedures of the School of Biomedical Sciences, University of Nottingham, UK (*see Appendix F*). The head and neck were removed at the level of T1. The neck was frozen at -20$^{oC}$ in a Tefcold Chest Freezer to facilitate sectioning. The neck was marked into seven sections at levels approximate to cervical levels C1 through to C7. The hyoid cartilage was palpated and used to ascertain the C4 level. Sections were marked at 2cm intervals as this is approximately the size of each anatomical level of the neck (*fig. 32*). The head was sectioned using a band saw (Startrite 14-S-5, Alfred Cox (Surgical) Ltd, Surrey, UK). Sections were defrosted and photographed from an inferior view as is typical for imaging. Sections were scanned using the 'Diasus' with the 8-16MHz linear array transducer. Scanning took place with a coupling medium of gel, and at a later stage a water bath. Analogous images were taken at the same position in a living subject. The images obtained from the dissection and ultrasound scan and living scan; were visually compared.

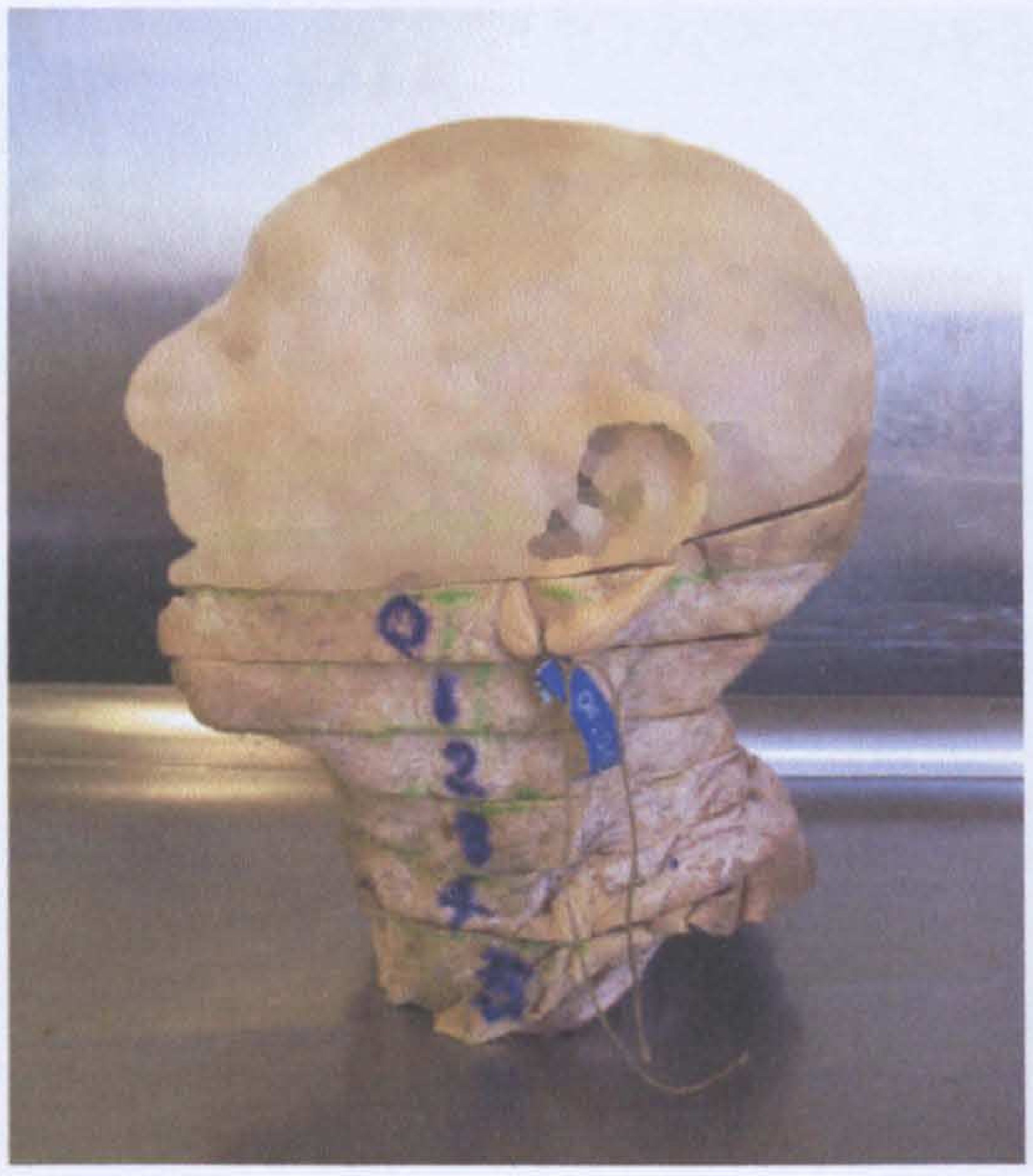

**Figure 32: Sectioned cadaver neck**
Sections approximate vertebral levels C1-T1.

### *Results*

Disappointingly, ultrasound of the cadaveric sections was unable to provide images comparable to those obtained *in vivo.* Specific muscles and tissue layers could not be identified. Penetration varied between levels. In the C1-C3 region, penetration was possible to a depth 10mm (*fig. 33*). In the C4-C7 region, penetration was deeper however, image quality was poor and structures were not discernable. Therefore, a comparison of the cadaveric specimen and the subsequent ultrasound image could not be made.

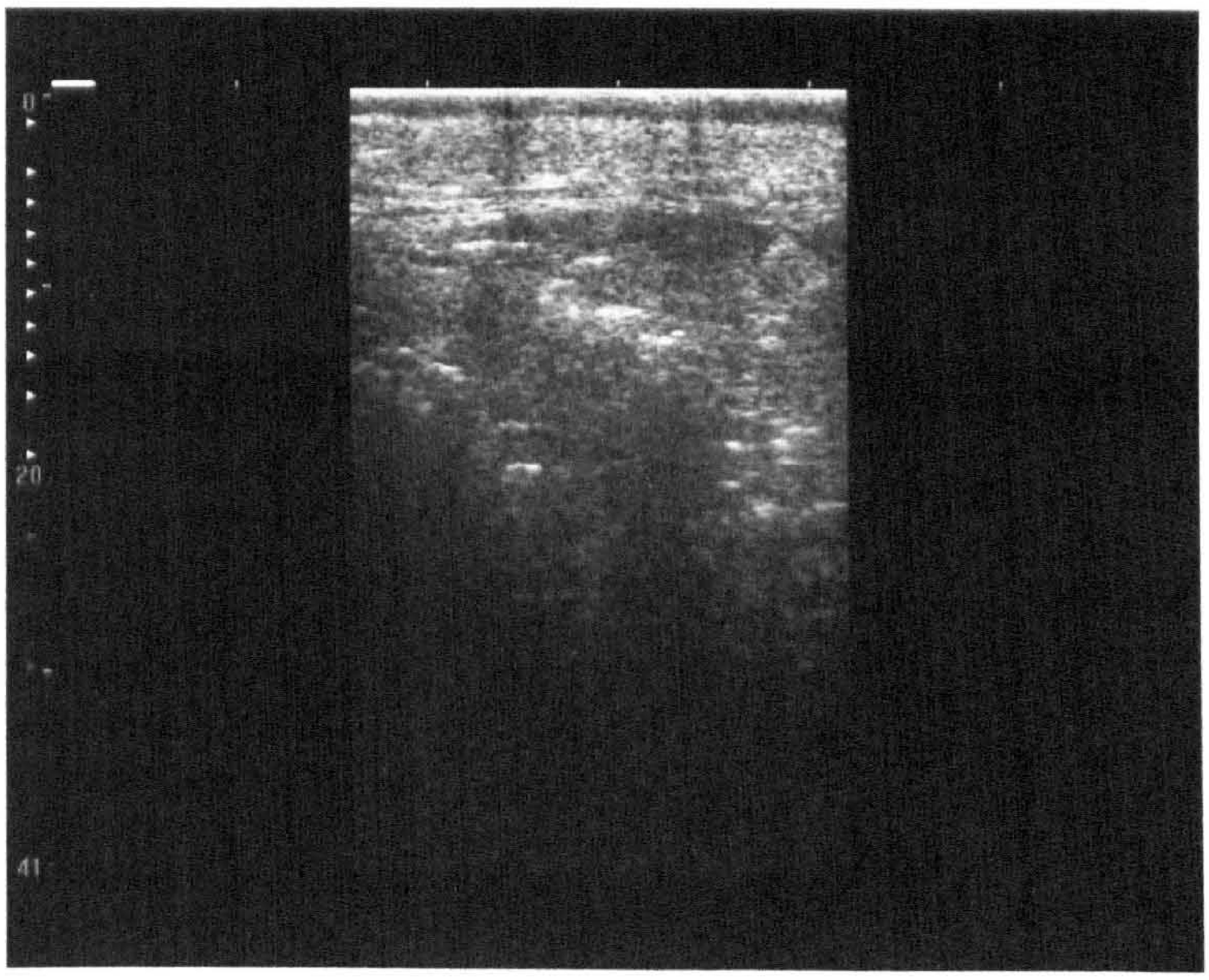

**Figure 33: Ultrasound image of cadaver neck section**
Transverse scan of section 0, taken at the level of C1/C2.

### *Discussion*

It was not possible to obtain ultrasound images of the cadaveric neck. This outcome contradicts recent studies that have found it possible to obtain ultrasound images from cadavers (Klauser *et al.*, 2004). It has been noted that fixing a tissue with an agent such as formalin will alter the ultrasonic properties of the tissue and increase attenuation by 30% at 3MHz (McDicken 1991) thus compromising imaging ability. Other researchers believe that there is no value in ultrasound investigation of cadaveric material (Stuart Foster personal communication 2004). In this study, a possible reason that images were not obtained could be due to the fixation process. The purpose of fixation is to preserve biological tissue that would otherwise deteriorate if left in its natural state. In order to retain the cellular constituents in their *in vivo* relationships to each other and prevent deterioration, the fixative formalin (a solution containing formaldehyde) is used. Formaldehyde has an ability to form cross links with soluble and structural proteins, this is achieved by forming hydroxy-methylene bridges between reactive end-groups of adjacent protein chains. In this way a matrix is formed, with soluble and insoluble proteins binding to one another. It is possible that this binding effect forms a barrier that reduces penetration of the ultrasound beam through the tissue. The fixation process is under the control of the School of Biomedical Sciences, Nottingham University Hospital, UK; and could not be altered. Ideally, a fresh specimen would be used as it is less likely to have undergone changes due to handling and fixation. Unfortunately, due to ethical considerations, it was not possible to use fresh specimens.

**Experiment 3: *In vivo* ultrasound imaging of the neck compared with cadaveric sections**

The cadaveric sections of the cervical region were compared to those images obtained from living subjects (*figs. 34-40*). Cadaveric sections are viewed inferiorly and where *in vivo* images have been acquired these have been overlaid.

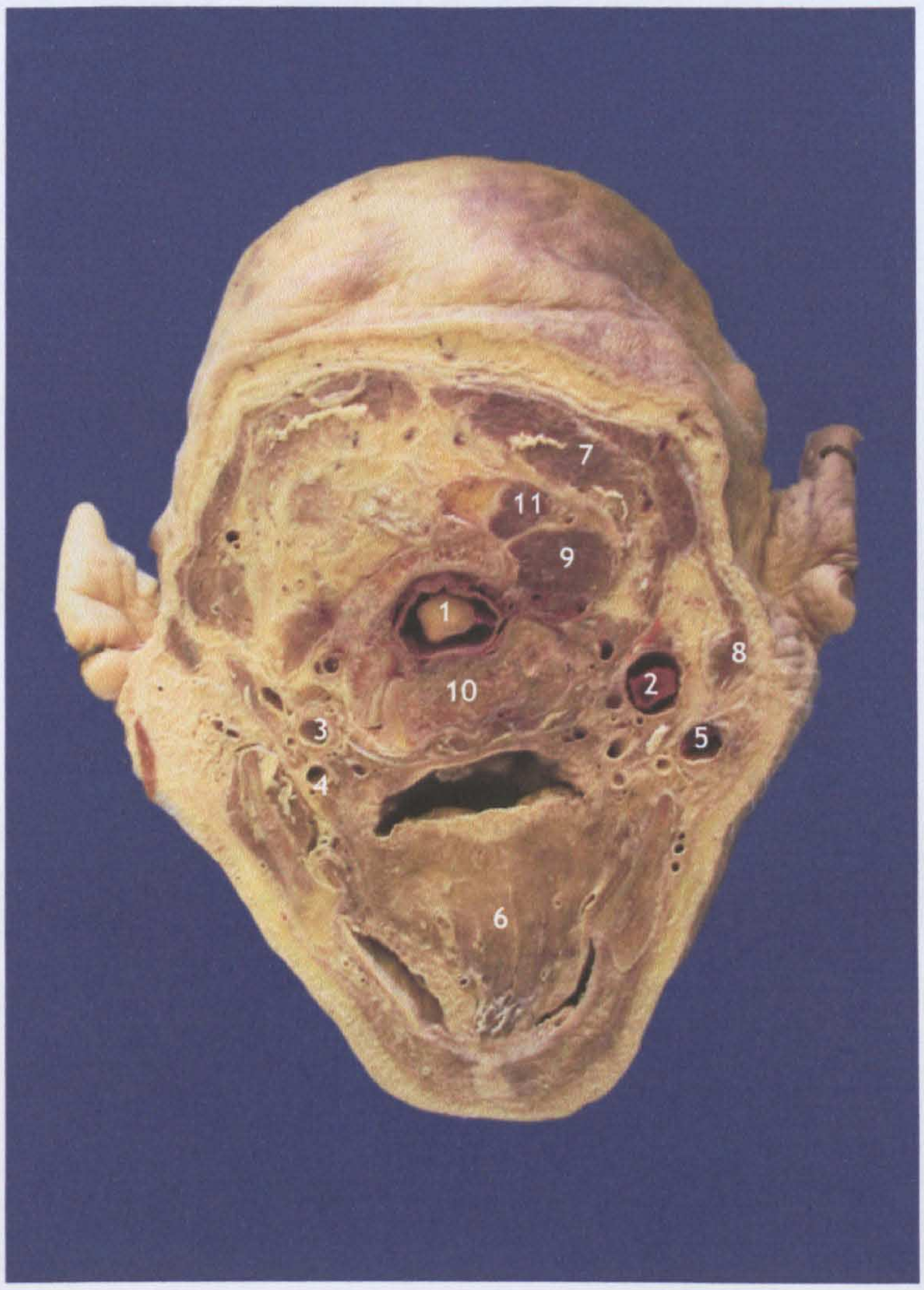

**Figure 34: Cadaver neck section 0**

Section of C1/C2 level.

1 - spinal cord
2 - internal jugular vein
3 - internal carotid artery
4 - external carotid artery
5 - external jugular vein
6 - tongue
7 - semispinalis capitis
8 - sternocleidomastoid
9 - obliquus capitis inferior
10 - vertebral body of C2
11 - rectus capitis posterior major

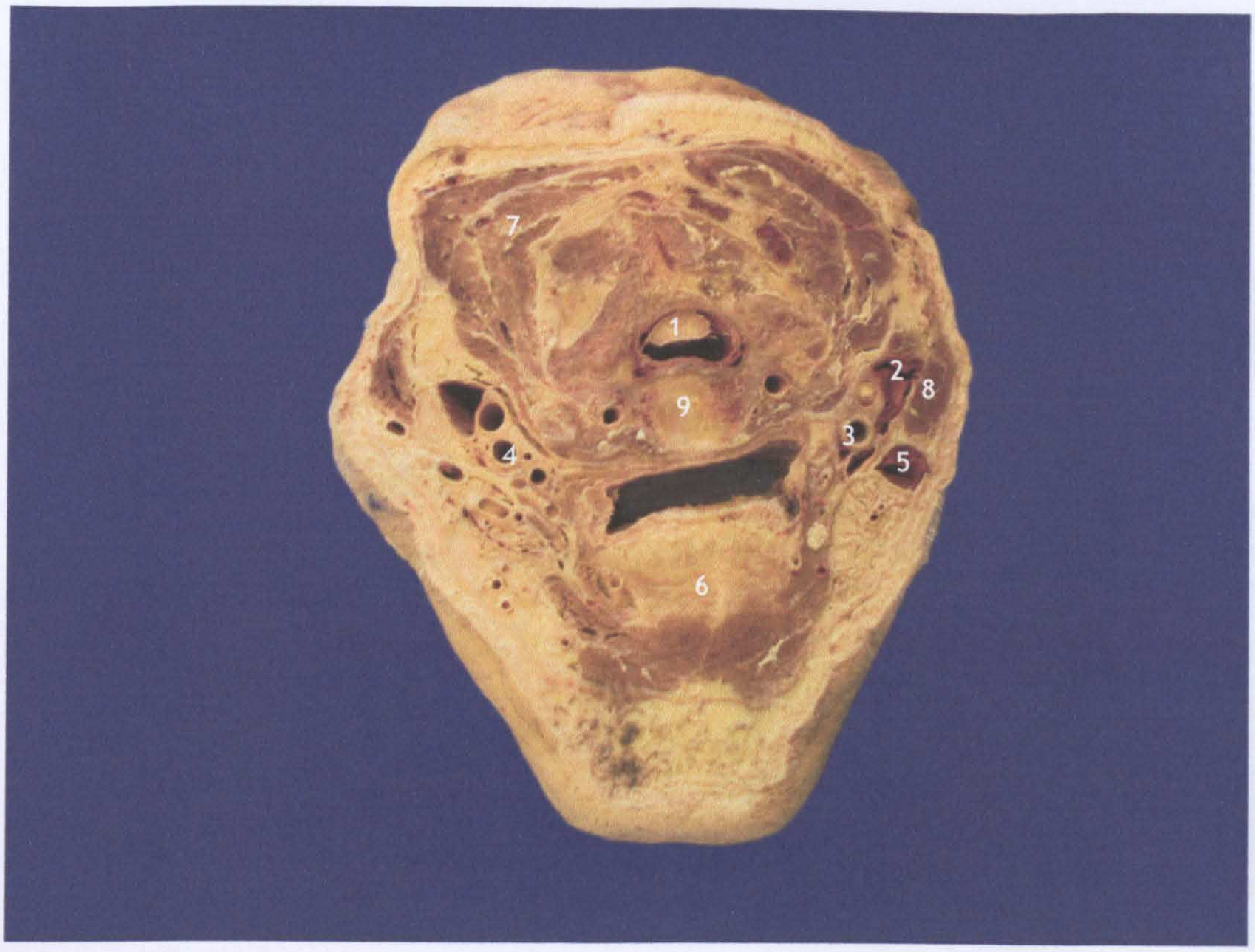

**Figure 35: Cadaver neck section 1**

Section of C2 level.

1 - spinal cord
2 - internal jugular vein
3 - internal carotid artery
4 - external carotid artery
5 - external jugular vein
6 - tongue
7 - semispinalis capitis
8 - sternocleidomastoid
9 - vertebral body of C2

**Figure 36: Cadaver neck section 2**

Section of C3 level, with corresponding *in vivo* ultrasound.

1 - spinal cord
2 - internal jugular vein
3 - internal carotid artery
4 - submandibular gland
5 - external jugular vein
6 - sternocleidomastoid
7 - semispinalis capitis
8 - splenius capitis
9 - trapezius
10 - semispinalis cervicis
11 - levator scapulae
12 - vertebral artery
13 - body of C3
14 - epiglottis

Section 2 (*fig. 36*), is a section of the C3 level. In life, the common carotid artery provides an easily recognisable landmark when viewed on ultrasound due to its pulsatile nature. The internal jugular vein may be compressed in life. The sternocleidomastoid muscle is a well defined, large, extensive, superficial muscle and is therefore readily identifiable. Structures underlying the carotid artery are difficult to differentiate.

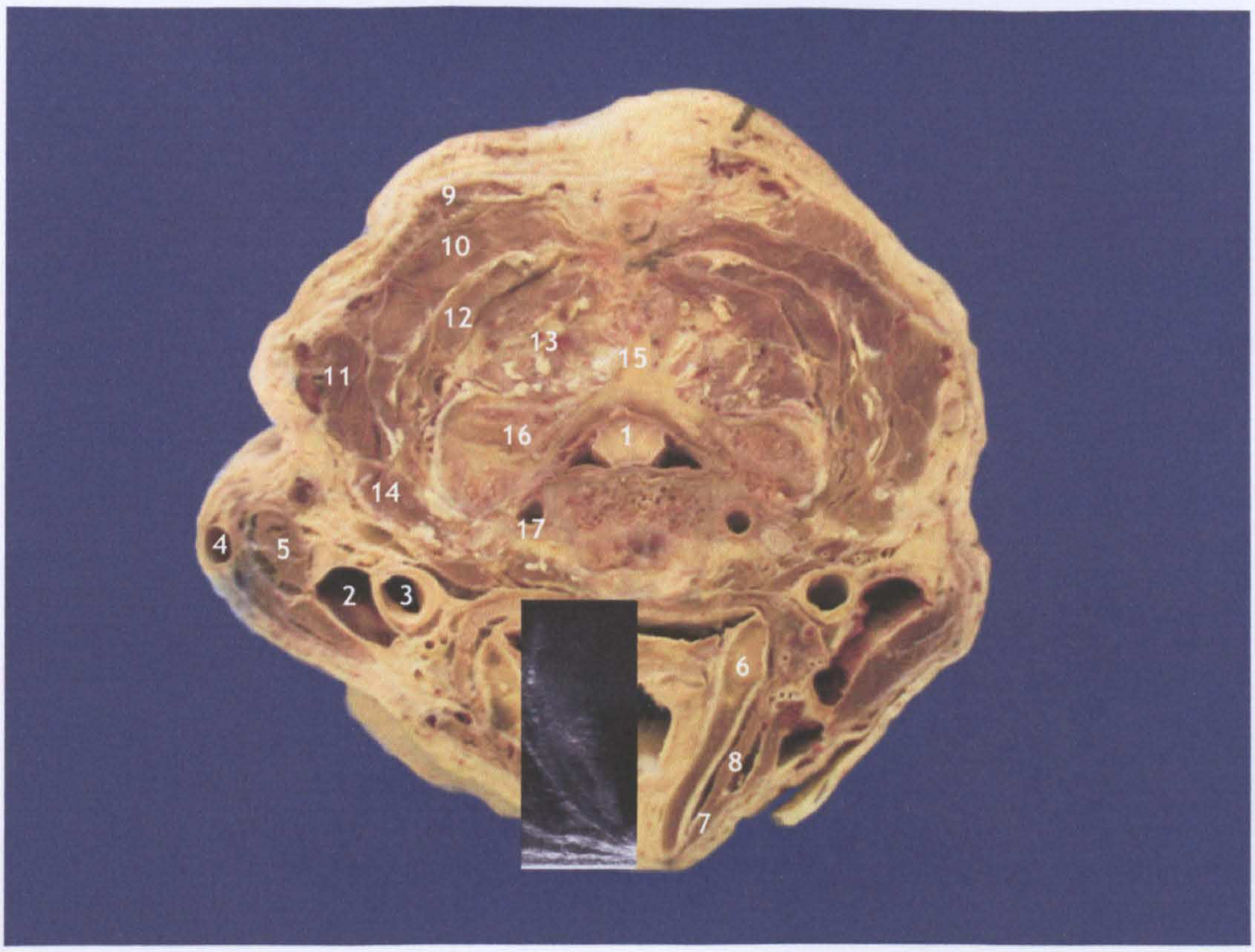

**Figure 37: Cadaver neck section 3**

Section of C5 level, with corresponding *in vivo* ultrasound.

1 - spinal cord
2 - internal jugular vein
3 - common carotid artery
4 - external jugular vein
5 - sternocleidomastoid
6 - thyroid cartilage
7 - sternohyoid
8 - omohyoid
9 - trapezius
10 - splenius capitis
11 - levator scapulae
12 - semispinalis capitis
13 - erector spinae
14 - scalenus medius
15 - spinous process of C5
16 - transverse process of C5
17 - vertebral artery

Section 3 (*fig. 37*) is taken at the level of C5. The thyroid cartilage is clearly depicted on ultrasound and penetration beyond this structure is not possible. Overlying strap muscles are identifiable.

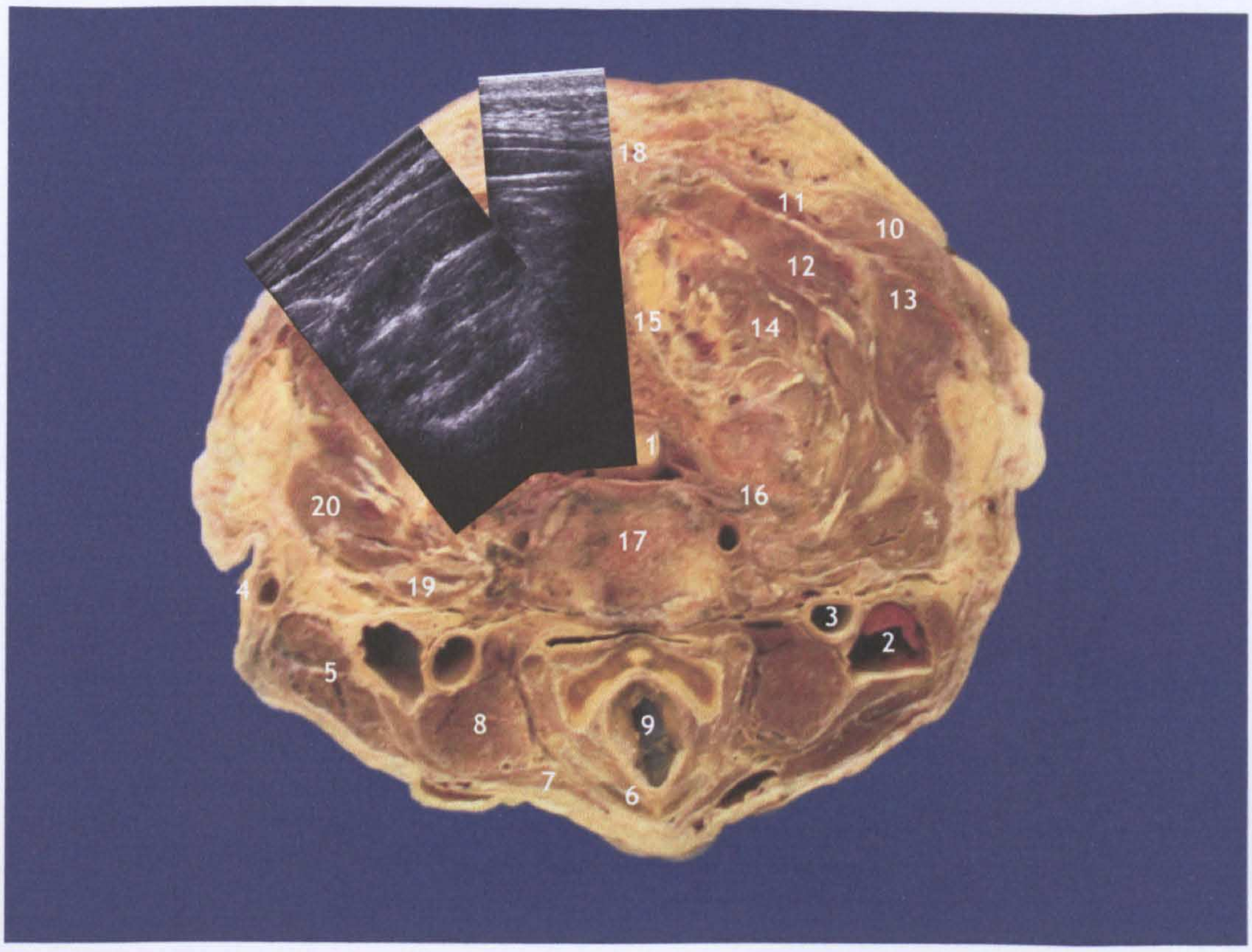

**Figure 38: Cadaver neck section 4**

Section of C6 level, with corresponding *in vivo* ultrasound.

1 - spinal cord
2 - internal jugular vein
3 - common carotid artery
4 - external jugular vein
5 - sternocleidomastoid
6 - sternohyoid
7 - omohyoid
8 - thyroid gland
9 - vocal fold
10 - trapezius
11 - splenius capitis
12 - semispinalis
13 - levator scapulae
14 - erector spinae
15 - spinous process
16 - transverse process
17 - vertebral body
18 - ligamentum nuchae
19 - scalenus anterior
20 - scalenus medius

Section 4 (*fig. 38*) is taken at the level of C6. Ultrasound of the midline clearly displays an anechoic region created by the spinous process. A vast number of muscles reside in the posterior triangle. On dissection, the deep muscles rotatores, multifidus etc... are difficult to differentiate being sparse in nature and therefore it is not thought feasible to identify these with ultrasound. The transverse processes of the cervical vertebrae can be seen deep to the musculature as a hyperechoic line.

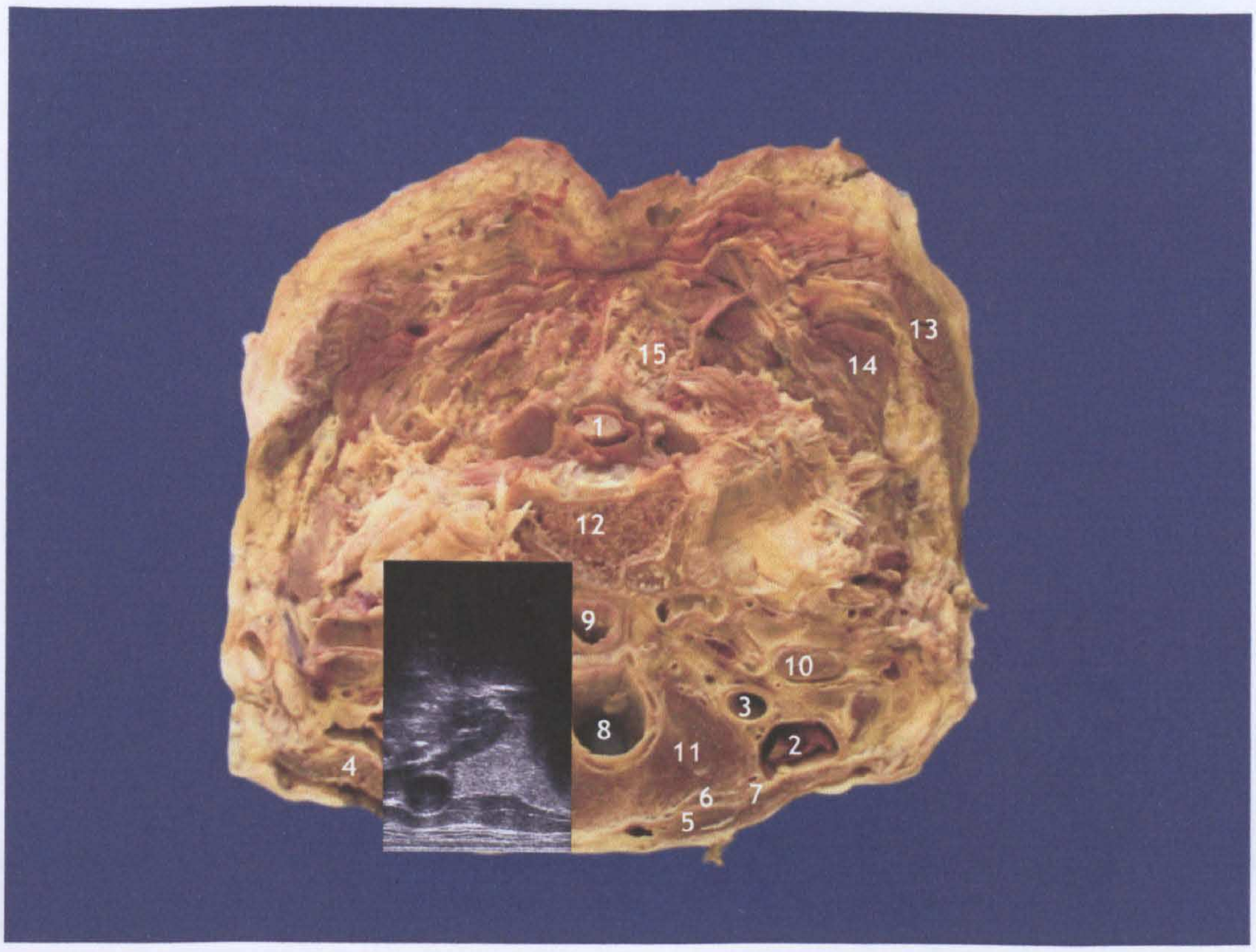

**Figure 39: Cadaver neck section 5**

Section of C7 level, with corresponding *in vivo* ultrasound.

1 - spinal cord
2 - internal jugular vein
3 - common carotid artery
4 - sternocleidomastoid
5 - sternohyoid
6 - sternothyroid
7 - omohyoid
8 - trachea
9 - oesophagus
10 - scalenus anterior
11 - thyroid gland
12 - vertebral body of C7
13 - trapezius
14 - levator scapulae
15 - erector spinae

Section 5 (*fig. 39*) is taken at the level of C7. Glandular tissue is clearly visualised on ultrasound as having a homogenous texture. On the ultrasound image, the contrast between the strap muscles and the thyroid gland is clearly demonstrated.

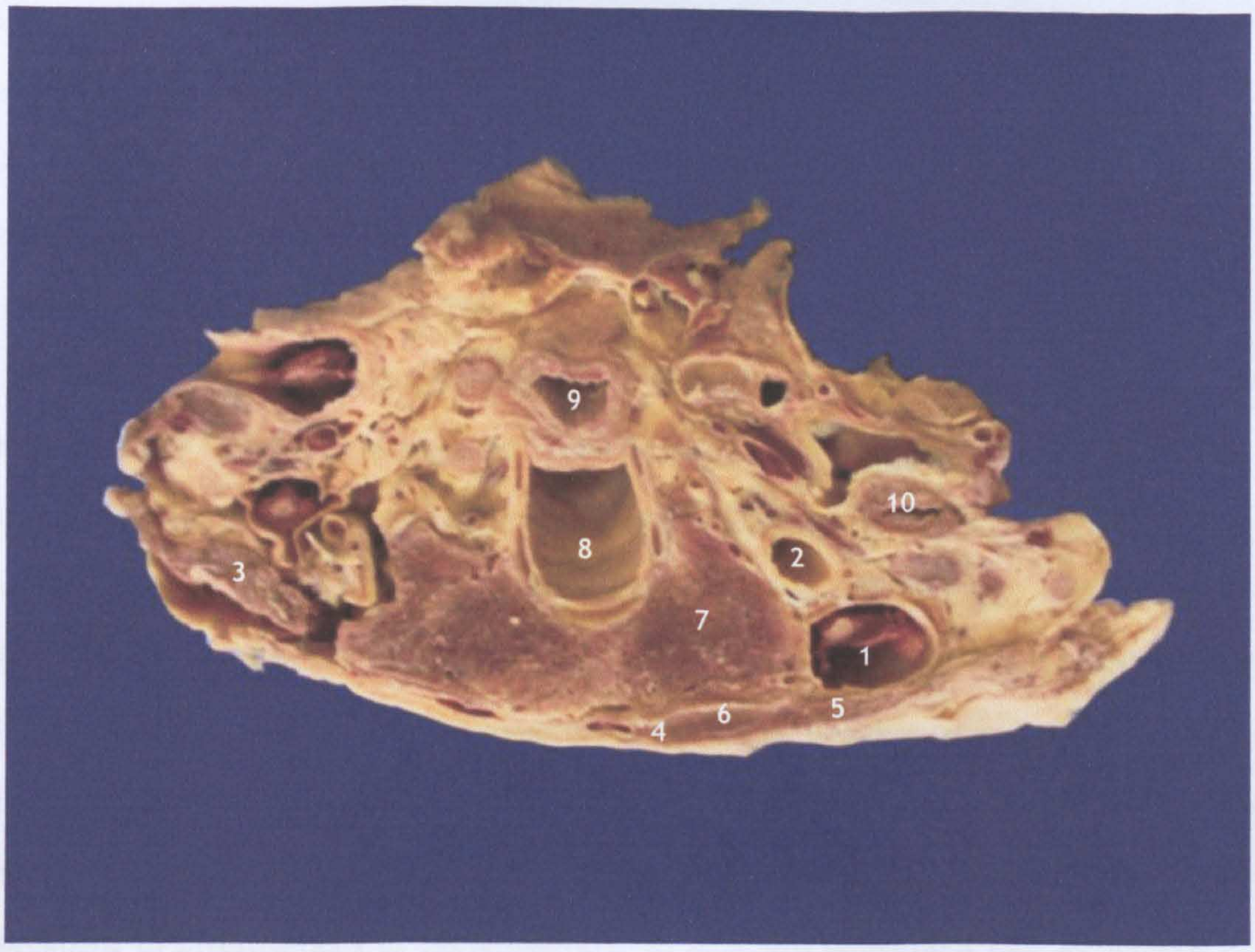

**Figure 40: Cadaver neck section 6**

Section of C7/T1 level.

1 - internal jugular vein
2 - common carotid artery
3 - sternocleidomastoid
4 - sternohyoid
5 - omohyoid
6 - sternothyroid
7 - thyroid gland
8 - trachea
9 - oesophagus
10 - scalenus anterior

### *Discussion*

These images illustrate how the structures identified on dissection were found to be well represented with ultrasound images from subjects scanned *in vivo*. Dissection highlighted that there is a difficulty differentiating specific muscles in those that are closely related or of a small structure. The erector spinae and transversospinalis group are particularly difficult to differentiate into their constituents and this justified the difficulty of identifying these using ultrasound. The platysma is a good example of a diffuse muscle that cannot always be visualised with ultrasound.

One of the aims of this series of experiments was to image the cadaver with ultrasound and compare these images directly to structures as they appear on dissection and although this was not achieved, it proved a worthwhile exercise for familiarity of neck structures and their arrangement as well as providing reference images of sectional anatomy. The information gleaned in this investigation only gives information from the dissection of one cadaver and it is important to be aware of anatomical variation through a population. Anatomical variations that can occur throughout a population include different amounts of body fat, variation in build, different development of muscles, existing pathology, congenital abnormalities and natural variation in structures. Anatomical variation aside, the sections compared well to scans taken *in vivo* and this process has clarified the appearance of the structures that will be observed in the living subject. The condition of the tissue, whether living or dead, will affect its mechanical properties and, hence, its impact on sound waves and therefore the quality of the ultrasound image. Care must be taken when extrapolating results from cadaveric specimens to investigations of living subjects; as structure dimensions may be altered as a result of the specimen condition. Ideally the best methodology to use for this experiment would be to follow Berg *et al.*, (2003) where the same subject, in this case a horse, was scanned at all stages from living to death but for obvious reasons this was not possible!

## Experiment 4: Ultrasound anatomy of the neck *in vivo*

### *Background*

The aim of this experiment was to obtain further reference material of anatomical structures and their appearance with ultrasound together with an understanding of the potential changes in anatomy due to variation of the population. A large sample was needed to ensure findings were reliable and to identify any limitations of the technique such as the stature of the subject.

### *Method*

In the initial study, ten healthy adult volunteers (five female and five male) were recruited to the study with an age range of 24-45 years (mean age 28.3 years). For this group, ultrasound images of the neck region were acquired without considering grading the quality of the image. The purpose of this study was to appreciate the feasibility of scanning the neck region. This study is detailed in Appendix I. This study developed into the one described here, where consideration was given to quantifying the quality of the images that could be acquired and the effect of the subject's stature. In this study, nine healthy adult volunteers (four female and five male) were recruited with an age range of 24-43 years (mean age 31.4 years). Both studies were performed with the permission of the subjects and in accordance with requirements of the university ethics committee.

The ultrasound equipment used in this study was 'Diasus' (Dynamic Imaging Limited, Livingston, UK) connected to an ultra wide-band 8-16MHz transducer (Dynamic Imaging Limited, Livingston, UK). To assess how subjects feel about the scanning technique, on completing the assessment each subject was asked to grade the level of comfort they felt during the scanning process on a scale of 0 (no discomfort) to 5 (intolerable).

Consideration of subjects' stature was made by recording neck circumference and calculating the body mass index (BMI) of subjects as this could have impacted on the success of imaging (*see Chapter 3*).

### *Ultrasound technique*

The subject was asked to sit and position their head and cervical spine in a neutral anatomical position, facing forwards with a straight spine. The C7 spinous process was used as a palpable reference point; and represented the inferior limit of the scanned area. The superior limit was represented by the palpable occipital process. The neck was then imaged systematically based on the anatomical triangles (*see Chapter* 2). When necessary the subject was asked to flex the neck to allow for images of the interspinous space to be acquired. Successive images were acquired of the posterior musculoskeletal architecture of the cervical spine by moving the transducer laterally from the posterior nuchal line to the posterior triangle. Scanning continued laterally from the posterior triangle over the sternocleidomastoid muscle to the anterior triangle to the posterior midline. Subjects were assessed and the visibility of the structure graded on the following scale:

- Grade 5: structure border well defined, good structure detail
- Grade 4: structure border well defined, poor structure detail
- Grade 3: structure border poorly defined, good structure detail
- Grade 2: structure border poorly defined, poor detail
- Grade 1: something visible
- Grade 0: not visible

### *Results*

The following table (*see Table 7*) details what structures of the neck were visible with ultrasound, the number of subjects where a successful image was achieved, and the grading of the quality of the image.

**Table 7: Structures of the neck identified using ultrasound**

| Structure | Is the structure visible? | In how many subjects? | Grade |
|---|---|---|---|
| | | | |
| **Superficial and lateral cervical muscles** | | | |
| platysma | Yes | 9/9 | Grade 5 = 6<br>Grade 4 =1<br>Grade 2 = 1<br>Grade 0 = 1 |
| trapezius | Yes | 9/9 | Grade 5 = 7<br>Grade 4 = 2 |
| sternocleidomastoid | Yes | 9/9 | Grade 5 = 9 |

| | | | |
|---|---|---|---|
| **Suprahyoid muscles** | | | |
| digastric | Yes | 9/9 | Grade 5 = 3<br>Grade 4 = 5<br>Grade 2 = 1 |
| stylohyoid | No | 0/9 | Grade 0 = 9 |
| mylohyoid | Yes | 9/9 | Grade 5 = 3<br>Grade 4 =5<br>Grade 2 = 1 |
| geniohyoid | No | 0/9 | Grade 0 = 9 |
| | | | |
| **Infrahyoid muscles** | | | |
| sternohyoid | Yes | 10/9 | Grade 5 = 6<br>Grade 4 = 1<br>Grade 2 = 2 |
| sternothyroid | Yes | 9/9 | Grade 5 = 3<br>Grade 4 = 3<br>Grade 2 = 2<br>Grade 1 = 1 |
| thyrohyoid | Yes | 8/9 | Grade 5 = 1<br>Grade 4 = 3<br>Grade 2 = 3<br>Grade 1 = 1<br>Grade 0 = 1 |
| omohyoid | Yes | 9/9 | Grade 5 = 5<br>Grade 4 = 2<br>Grade 2 =2 |
| | | | |
| **Anterior vertebral muscles** | | | |
| longus colli | Yes | 2/9 | Grade 2 = 1<br>Grade 1 = 1<br>Grade 0 = 7 |
| longus capitis | Yes | 2/9 | Grade 2 = 1<br>Grade 1 = 1<br>Grade 0 = 7 |
| rectus capitis anterior | No | 0/9 | Grade 0 = 9 |
| rectus capitis lateralis | No | 0/9 | Grade 0 = 9 |

| | | | |
|---|---|---|---|
| **Lateral vertebral muscles** | | | |
| scalenus anterior | Yes | 9/9 | Grade 5 = 2<br>Grade 4 = 2<br>Grade 2 = 3<br>Grade 1 = 2 |
| scalenus medius | Yes | 9/9 | Grade 5 = 1<br>Grade 4 = 2<br>Grade 2 = 4<br>Grade 1 =2 |
| scalenus posterior | No | 0/9 | Grade 0 = 9 |
| scalenus minimus (*pleuralis*) | No | 0/9 | Grade 0 = 9 |
| | | | |
| **Deep muscles of the back** | | | |
| splenius capitis | Yes | 9/9 | Grade 5 = 8<br>Grade 2 = 1 |
| splenius cervicis | Yes | 9/9 | Grade 5 = 3<br>Grade 4 = 1<br>Grade 3 = 3<br>Grade 2 = 2 |
| erector spinae (divides into 3): | | | |
| • iliocostalis cervicis | Yes | 9/9 | Grade 3 = 1<br>Grade 2 = 7<br>Grade 1 = 1 |
| • longissimus | Yes | 9/9 | Grade 3 = 1<br>Grade 2 = 7<br>Grade 1 = 1 |
| o cervicis | Yes | 9/9 | Grade 3 = 1<br>Grade 2 = 7<br>Grade 1 = 1 |
| o capitis | Yes | 9/9 | Grade 3 = 1<br>Grade 2 = 7<br>Grade 1 = 1 |
| • spinalis | Yes | 9/9 | Grade 3 = 1<br>Grade 2 = 7<br>Grade 1 = 1 |
| o cervicis | Yes | 9/9 | Grade 3 = 1<br>Grade 2 = 7<br>Grade 1 = 1 |

| | | | |
|---|---|---|---|
| o capitis | Yes | 9/9 | Grade 3 = 1<br>Grade 2 = 7<br>Grade 1 = 1 |
| transversospinalis (divides into 3): | | | |
| • semispinalis | | | |
| o cervicis | Yes | 9/9 | Grade 5 = 1<br>Grade 4 = 2<br>Grade 2 = 4<br>Grade 1 = 2 |
| o capitis | Yes | 9/9 | Grade 5 = 1<br>Grade 4 = 2<br>Grade 2 = 4<br>Grade 1 = 2 |
| • multifidus | Yes | 8/9 | Grade 3 = 1<br>Grade 2 = 5<br>Grade 1 = 2<br>Grade 0 = 1 |
| • rotatores | Yes | 8/9 | Grade 3 = 1<br>Grade 2 = 5<br>Grade 1 = 2<br>Grade 0 = 1 |
| | | | |
| **Minor deep layer** | | | |
| interspinales | Yes | 2/9 | Grade 1 = 2<br>Grade 0 = 7 |
| intertransversarii | Yes | 2/9 | Grade 1 = 2<br>Grade 0 = 7 |
| | | | |
| **Muscles connecting the upper limb with the vertebral column** | | | |
| trapezius (see above) | | | |
| rhomboideus major | Yes | 9/9 | Grade 5 = 7<br>Grade 4 = 2 |
| rhomboideus minor | Yes | 9/9 | Grade 5 = 6<br>Grade 4 = 2<br>Grade 2 = 1 |

| | | | |
|---|---|---|---|
| levator scapulae | Yes | 9/9 | Grade 5 = 9 |
| | | | |
| **Ligament** | | | |
| alar ligaments | No | 0/9 | Grade 0 = 9 |
| ligamnetum nuchae | Yes | 9/9 | Grade 5 = 4<br>Grade 4 = 3<br>Grade 1 = 2 |
| intervertebral disc | Yes | 9/9 | Grade 5 = 4<br>Grade 4 = 2<br>Grade 2 = 1<br>Grade 1 = 2 |
| supraspinous ligament | No | 0/9 | Grade 0 = 9 |
| interspinous ligaments | No | 0/9 | Grade 0 = 9 |
| thin loose capsules | No | 0/9 | Grade 0 = 9 |
| ligamentum flava | No | 0/9 | Grade 0 = 9 |
| anterior longitudinal ligament | Yes | 1/9 | Grade 1 = 1<br>Grade 0 = 8 |
| posterior longitudinal ligament | Yes | 1/9 | Grade 1 = 1<br>Grade 0 = 8 |
| | | | |
| **Bone** | | | |
| thyroid cartilage | Yes | 9/9 | Grade 5 = 6<br>Grade 3 = 1<br>Grade 2 = 2 |
| facet joint | Yes | 8/9 | Grade 5 = 1<br>Grade 4 = 6<br>Grade 2 = 1<br>Grade 0 = 1 |
| vertebrae | Yes | 9/9 | Grade 5 = 1<br>Grade 4 = 6<br>Grade 2 = 2 |
| spinous process | Yes | 9/9 | Grade 5 = 1<br>Grade 4 = 4<br>Grade 2 = 2<br>Grade 1 = 2 |

| | | | |
|---|---|---|---|
| transverse process | Yes | 6/9 | Grade 5 = 1<br>Grade 4 = 3<br>Grade 2 = 1<br>Grade 1 = 1<br>Grade 0 = 3 |
| trachea | Yes | 8/9 | Grade 5 = 3<br>Grade 4 = 2<br>Grade 2 = 3<br>Grade 0 = 2 |
| hyoid bone | Yes | 7/9 | Grade 4 = 2<br>Grade 2 = 3<br>Grade 1 = 2<br>Grade 0 = 2 |
| | | | |
| **Blood Vessels and Nerves** | | | |
| common carotid artery | Yes | 9/9 | Grade 5 = 9 |
| external jugular vein | Yes | 3/9 | Grade 5 = 3<br>Grade 0 = 6 |
| internal jugular vein | Yes | 9/9 | Grade 5 = 9 |
| | | | |
| **Glands and nodes** | | | |
| thyroid gland | Yes | 9/9 | Grade 5 = 9 |
| lymph nodes | Yes | 8/9 | Grade 5 = 7<br>Grade 4 = 1<br>Grade 0 = 1 |
| submandibular gland | Yes | 9/9 | Grade 5 = 9 |

Comparable images were obtained from all subjects; normal anatomical variations were observed. On completing the scan, all subjects graded the comfort of the scan as 0, no discomfort.

Using the scanning technique developed as a result of this experiment, a review of the structures of the neck follows. Figure 41 provides orientation of the ultrasound scans.

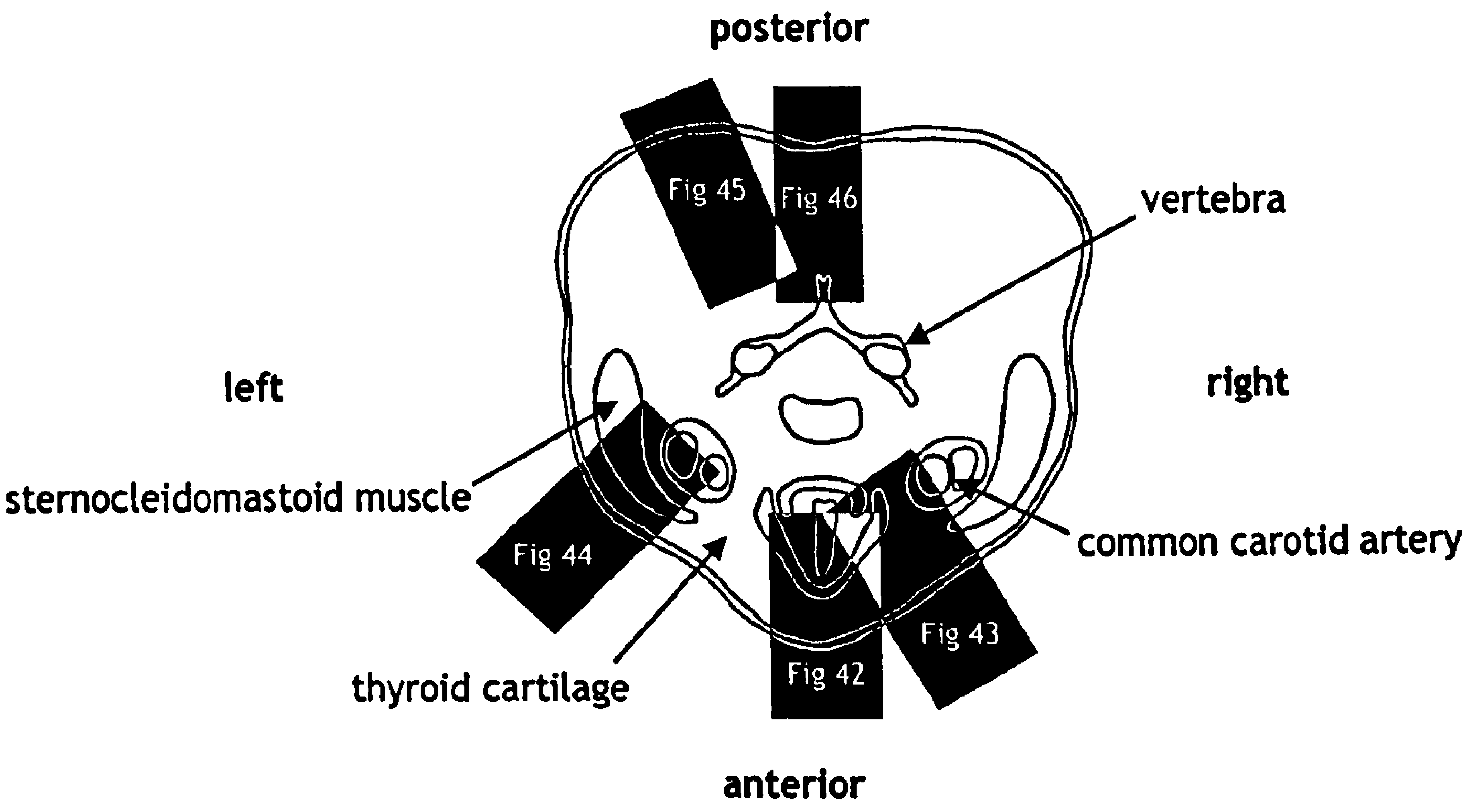

Figure 41: Transducer positions on the neck

*Anterior midline (fig. 42)*

The thyroid cartilage was clearly displayed on the anterior midline scan and provided a consistent landmark. The strap muscles (sternohyoid, omohyoid) could be clearly seen overlying the thyroid. The vocal folds may be identified and seen to move when the subject is asked to speak.

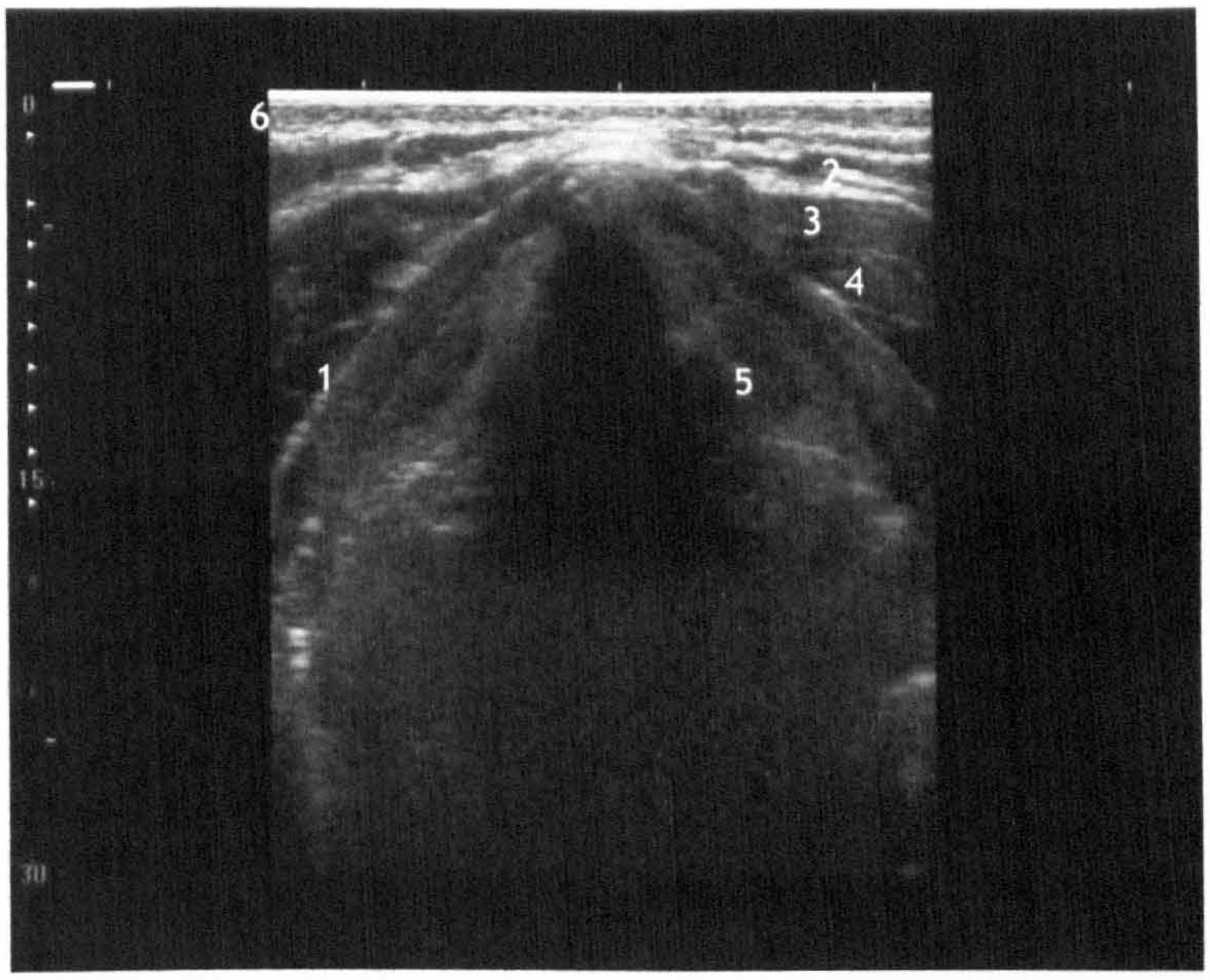

**Figure 42: Anterior midline scan of neck**

1 - thyroid cartilage
2 - platysma
3 - sternohyoid
4 - omohyoid
5 - vocal fold
6 - skin

*Anterior triangle (fig. 43)*

Good anatomical landmarks of consistent position were identified to aid orientation of the neck. These included the carotid artery (pulsatile), submandibular gland (acoustically homogeneous in appearance), and thyroid cartilage of the neck (well delineated). The thyroid gland has a homogenous echo texture with a smooth and regular outline. Transverse positioning of the transducer revealed superficial tissue such as fat and platysma which were seen as linear echoes. In the longitudinal view however, the fibres of platysma were seen as a thin layer of linear echoes. With the transducer in a transverse position and using the thyroid cartilage as a landmark, it was possible to better visualise the bellies of the strap muscles by moving the transducer laterally, cranially and caudally. The upper and lower limits of the anteriorly scanned area were delineated by the submandibular gland (superiorly) and clavicle (inferiorly).

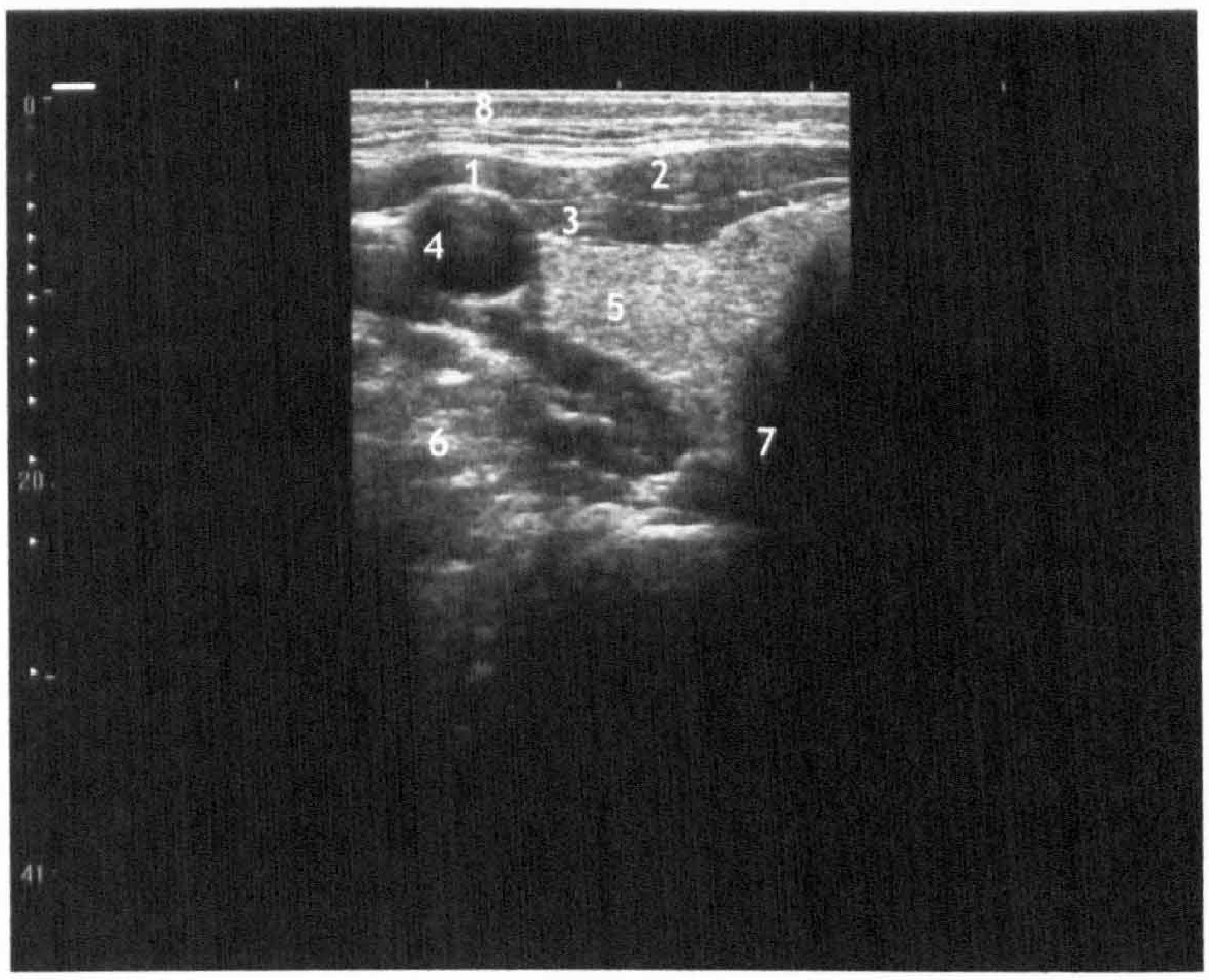

**Figure 43: Anterior triangle scan of neck**

1 - omohyoid
2 - sternohyoid
3 - sternothyroid
4 - common carotid artery
5 - thyroid gland
6 - scalenus anterior
7 - trachea
8 - skin

*Sternocleidomastoid muscle (fig. 44)*

The sternocleidomastoid muscle obliquely divides the anterior and posterior triangles of the neck. The sternocleidomastoid muscle is less echogenic than the thyroid, with a well defined outline that varies from circular to ovoid in section. Structural detail is exquisite in this muscle and the separation of its two heads to the clavicle and sternum can be clearly seen.

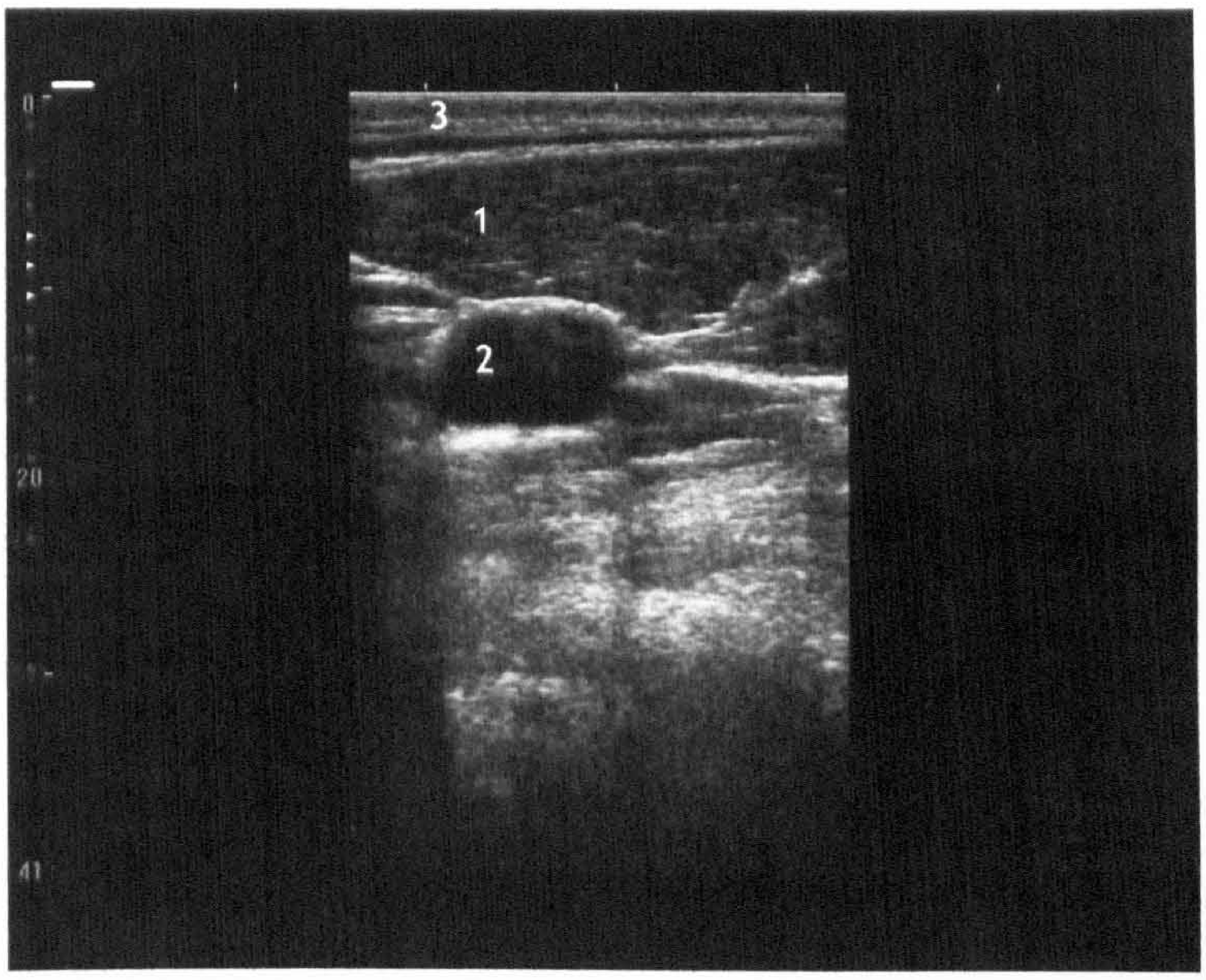

**Figure 44: Sternocleidomastoid scan of neck**

1 - sternocleidomastoid 2 - common carotid artery 3 - skin

*Posterior triangle (fig.45)*

With the application of the transducer along the posterior border of sternocleidomastoid, it was possible to demonstrate clearly the appearance of trapezius, levator scapulae, semispinalis and splenius lying superficial to the erector spinae muscles. Differentiation of erector spinae muscles is complex. In some subjects muscle facia is depicted, in others separation is poorly defined. In all cases, the tissue architecture is poorly defined in the erector spinae group and transversospinalis.

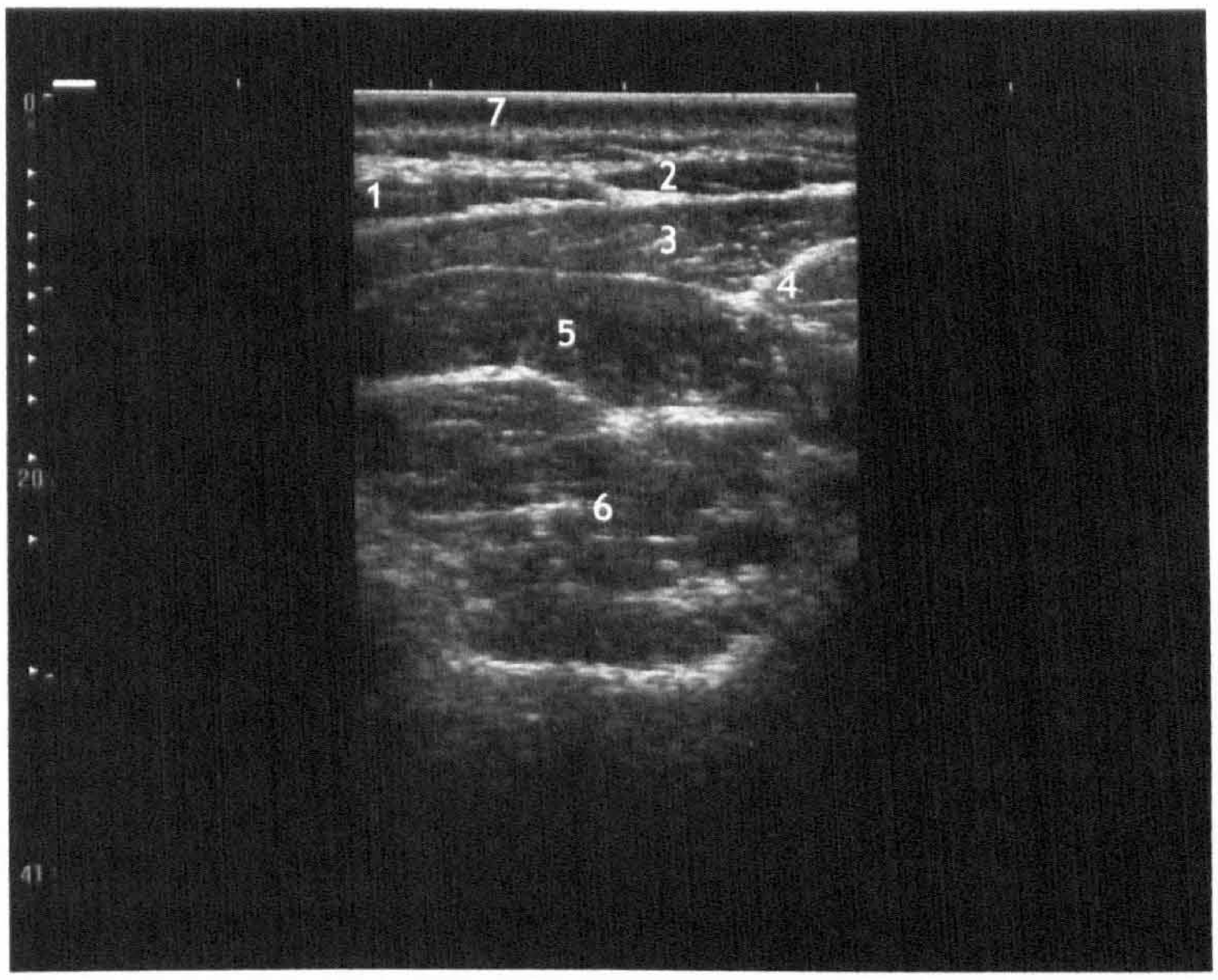

**Figure 45: Posterior triangle scan of neck**

1 - trapezius
2 - levator scapulae
3 - splenius capitis
4 - splenius cervicis
5 - semispinalis
6 - erector spinae
7 - skin

### *Posterior midline (fig. 46)*

Direct placement of the transducer onto the spinous process of C7 demonstrated an area of acoustic shadowing. The transverse processes of the vertebrae were depicted by a bright linear echo. As the transducer was moved laterally, the architectural details of the posterior musculature could be clearly seen. Trapezius was located at the level of C4/5 and was seen to insert into the spinous processes at this level. Its muscle fibres radiated laterally forming a distinctive shape. On ultrasound it appeared as two superficial triangular areas with the apices meeting in the midline with the ligamentum nuchae. A longitudinal scan clearly depicted ligamentum nuchae as a superficial structure beneath the skin represented by hyperechoic parallel lines. Immediately deep to trapezius, splenius could also be visualised. The remainder of the erector spinae group of muscles were seen to lie superficial to the laminae of the cervical vertebrae.

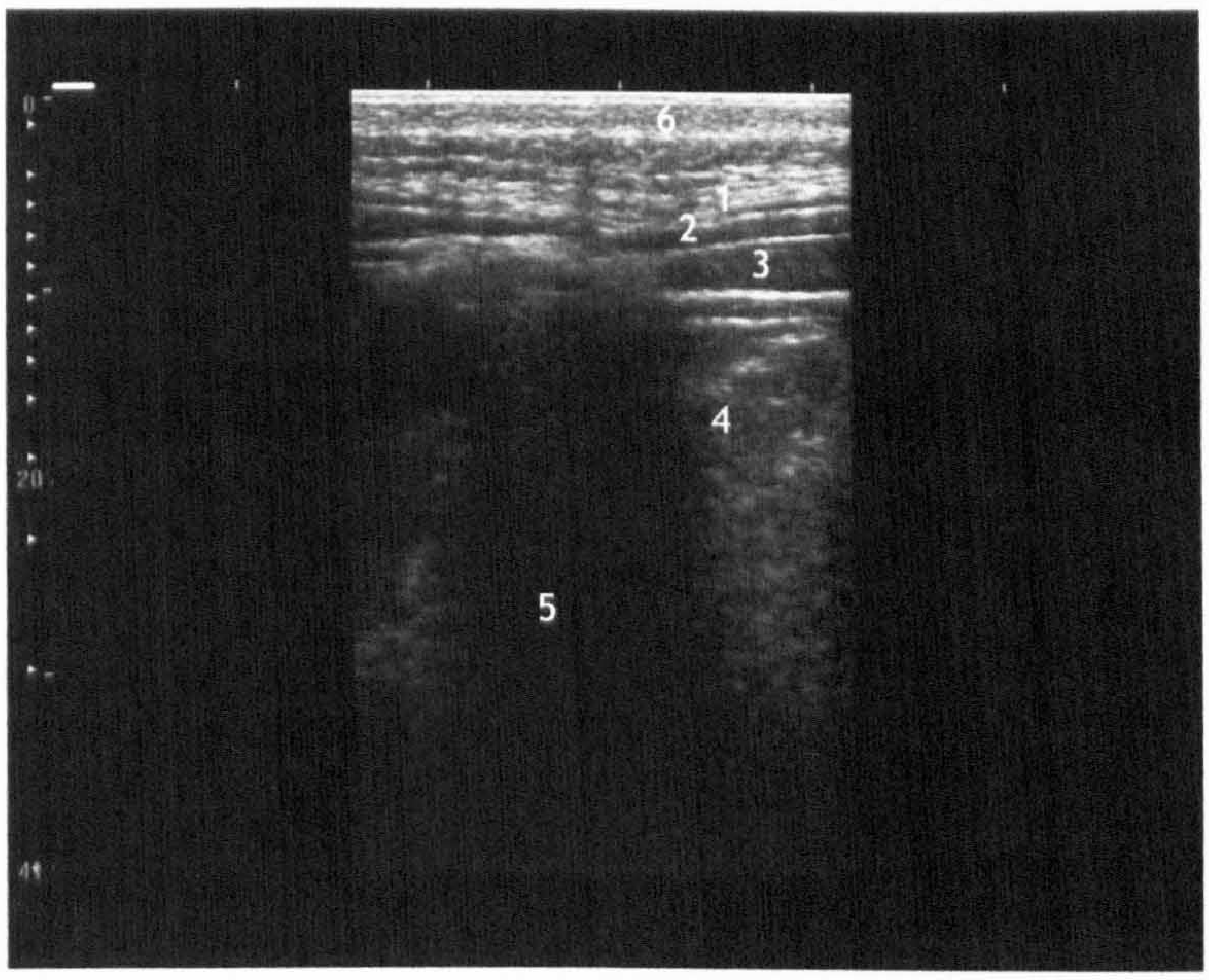

**Figure 46: Posterior midline scan of neck**

1 - trapezius
2 - splenius capitis
3 - semispinalis
4 - erector spinae
5 - spinous process
6 - skin

### *Structural detail*

Detailed structural characteristics of the neck musculature were obtained. Muscular structures were demonstrated by their characteristic fibrillar pattern, highly echogenic perimysium and where present, their pennate nature and fibre direction were discernible. A transverse scan of muscle tissue revealed a cross section of the muscle fibres (*fig. 47*); a longitudinal view of the muscle revealed the longitudinal view of the fibres (*fig. 48*). The ligamentum nuchae appeared as regular tightly packed fibres arranged in a linear fashion. Lymph nodes appeared as hypoechoic structures less than 1cm in diameter.

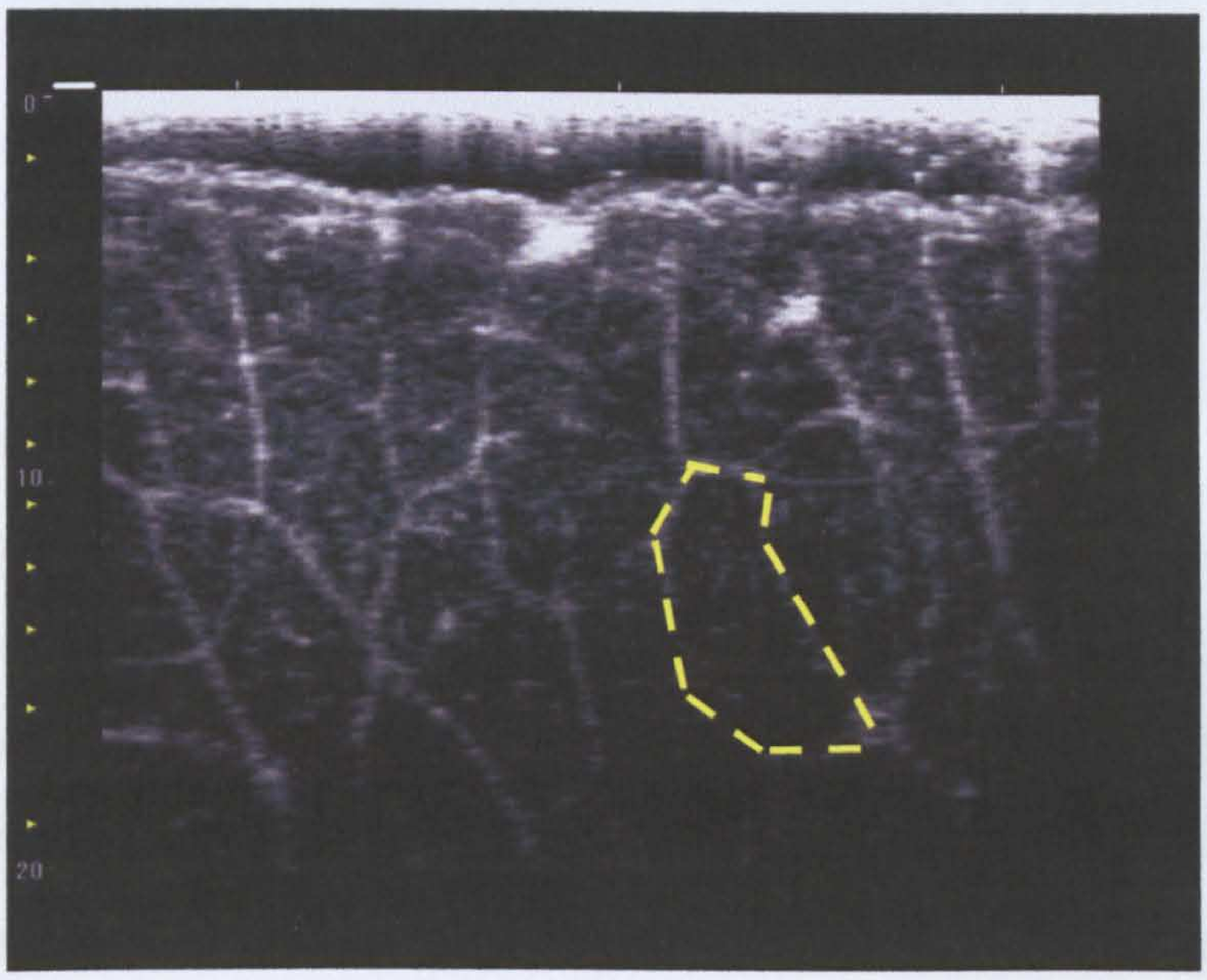

**Figure 47: Transverse scan of porcine muscle *in vitro***
Cross-section of muscle fibres (yellow outline = fibre bundle)

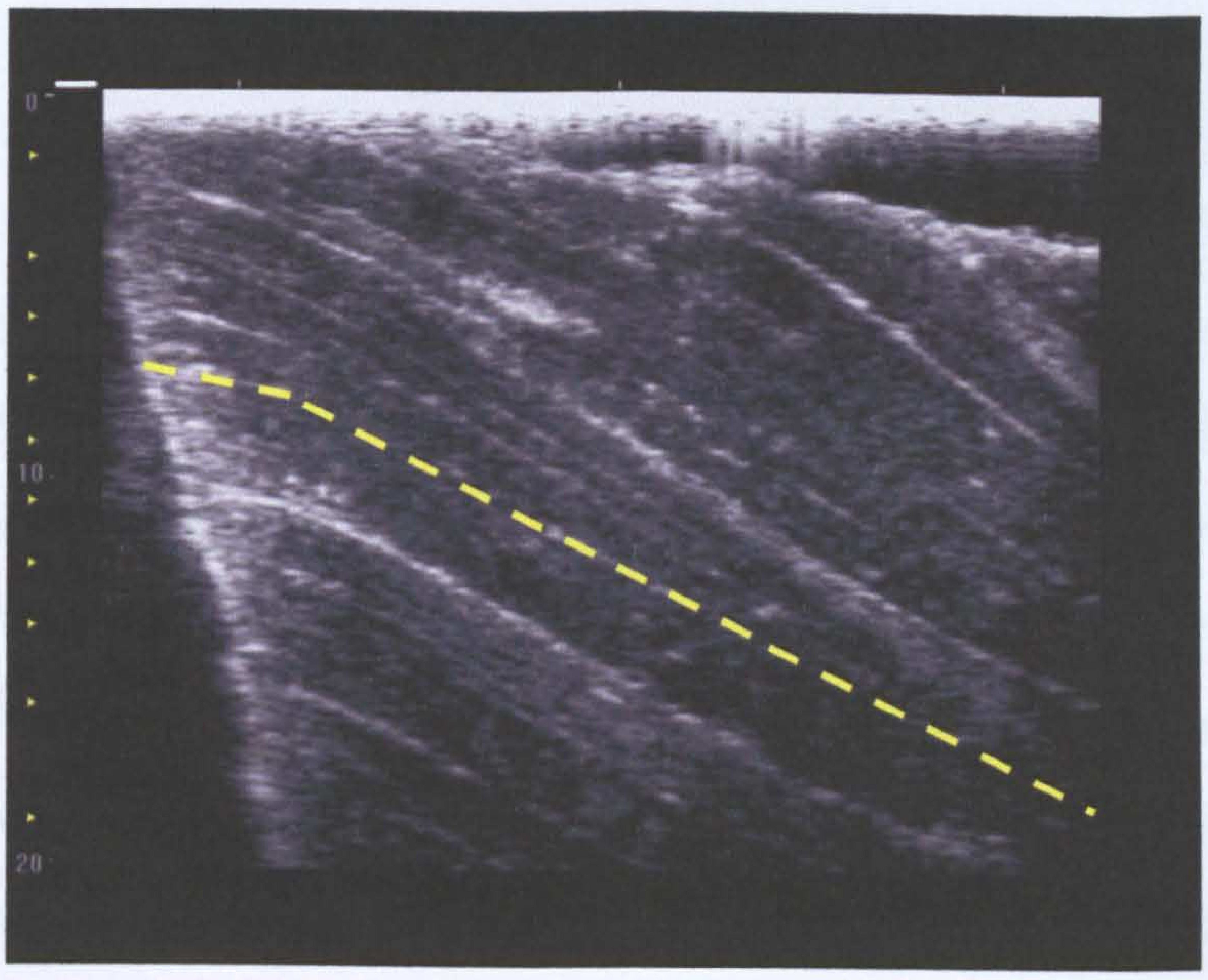

**Figure 48: Longitudinal scan of porcine muscle *in vitro***
Longitudinal view of muscle fibres (yellow line = fibre)

*Skeletal structures and intervertebral discs*

Skeletal components of the cervical spine that were visible within this region included the intervertebral discs and facet joints (*see Chapter 7*). With the transducer positioned longitudinally, commencing at the apex formed between sternocleidomastoid and levator scapulae, and moved in a cranial to caudal direction, it was possible to visualise consistently the echogenic posterolateral margins of the articular masses and the intervening facet joints. The intervertebral discs could be seen using an anterolateral approach.

*Ligaments*

The ligamentum nuchae could be identified; other ligaments could not be imaged due to artefact being produced from bony structures obscuring the view of ligaments combined with the small size of these ligaments.

*Blood vessels*

The vascular bundle of the common carotid artery and internal jugular vein are situated deep to the sternocleidomastoid muscle and lateral to the thyroid gland. These vessels are very accessible for ultrasonography, and their characteristics make them ideal reference structures. Visualisation of the carotid bifurcation was used to provide an anterior reference point, as its position is consistent and readily identifiable due to its pulsatile nature. The carotid artery appears as a tubular structure with hyperechoic walls and an echo-free centre; the walls are smooth and difficult to compress with the transducer; it can be seen to bifurcate into its internal and external branches. The internal jugular vein is lateral to the carotid artery and the walls are more easily compressed. The internal jugular vein varies in diameter during the different phases of respiration and during the Valsalva's manoeuvre (where the subject breathes against a closed glottis as occurs during coughing, defecation and heavy lifting). The external jugular vein is superficial to the sternocleidomastoid muscle and is easily compressed by the transducer.

### *Effect of stature*

For subjects with a larger BMI, penetration was compromised due to attenuation caused by an increase in depth either by muscle or subcutaneous fat. Subcutaneous fat also has the effect of scattering the ultrasound beam and contributing to attenuation. The muscle boundaries of athletic subjects were found to be more distinct compared to sedentary subjects. In these athletic subjects, it was also observed that particular muscles relating to specific sporting activities were more developed and also received a higher grading. An example of this is that one of the subjects participated regularly in swimming and running activities and had a well developed levator scapulae and scalenus anterior muscle. Where muscles are more developed, they are easier to identify due to their larger size accentuating their appearance.

### *Discussion*

This experiment confirms the findings of previous ultrasound studies in other regions of the body, namely that ultrasound is able to demonstrate very clearly those features discussed by utilising the acoustic properties of different tissue types. Ultrasound is extensively used for examining the anterior structures of the neck (*see Chapter* 2) and this study demonstrates that structures of the posterior aspect of the neck can be clearly visualised. The current investigation demonstrates the level of detail which can be appreciated using contemporary high frequency linear array ultrasound transducers. Detail of internal muscle structure is readily appreciated and the underlying osseous elements, facet joints and intervertebral discs can be seen. Future studies should consider grading the quality of the scan for each specific structure. For example, an assessment could be made of the structure on either side of the neck as well as identifying individual structures such as each vertebra.

The stature of the subject affects the image quality and the visibility of structures. With increasing body mass index, musculature and fat, the visibility of deep structures decreases. With this frequency of transducer (8-16MHz), the depth of penetration was adequate to a depth of 30mm. Increased distance between the transducer and structure of interest caused by muscle or fat increases the path the wave must travel (penetration depth). Fat also has the effect of scattering the ultrasound wave which results in de-focussing of the beam and a subsequent decrease in penetration. In subjects with a slender stature, deeper structures are more easily depicted; however, muscles may not be well developed and are therefore harder to differentiate. In subjects of athletic build, muscle definition was clearer although bulkier muscles led to an increase in distance and therefore deeper structures were less well depicted. To overcome the limitations of imaging people of a large stature, a machine with harmonic imaging capabilities could be employed. Harmonic imaging is a signal processing technique that minimises noise and improves signal to noise ratio having the effect of reducing artefact.

With knowledge of the normal ultrasound appearance of neck musculature, an application for its use in the clinical setting to determine pathologies is possible. The scanning procedure was accepted by all subjects who found no discomfort with the scan. Subjects were asked directly to grade the comfort of the scan; in future patients should have the opportunity to answer this question in private, as it is possible that this response does not reflect their true opinion.

The images acquired in this experiment represent a single moment in time for what is a dynamic process. The ability to scan in real time, coupled with directed transducer placement to attain specific views, should allow the technique to be used to aid diagnosis and help guide any physical intervention. With knowledge of the normal ultrasound appearance of neck musculature, clinical applications to investigate pathologies may be developed.

## Experiment 5: Extended field of view imaging

### *Background*

Generating an image of a complete anatomical section enables a greater appreciation of the arrangement of structures aiding orientation and understanding of the extent of any damage. The size of the section the ultrasound equipment produces corresponds to the size of the transducer scan head. The scan head of the 'Diasus' acquires images with a width of 26mm. If the region of interest is larger than that shown on the scan, context may then be lost and ultimately when observing pathology, the full extent of injury may not be visualised and contrast with surrounding structures to identify the injury boundary is not possible. This shortfall may be overcome by collating these images together in the form of an extended field of view image. Some ultrasound equipment has the integral capacity to link images together, while appreciating the contours of the scanning surface to create this extended field of view. The 'Diasus' does not have this capacity and therefore an extended field of view was compiled manually from individual images. The 'Philips ATL HDI 5000' has a panoramic imaging function that enabled an extended field of view image to be constructed during scanning. Extended field of view imaging allowed exceptional visualisation of anatomical structures and relationships. Generally, panoramic processing methods match pixels along the edge of an image to generate a panoramic appearance, for the HDI 5000 system this relies on processing tissue patterns captured from within the whole image. This unique real-time pattern recognition method makes it easier and faster to perform panoramic scanning. Although an extended field of view is possible with ultrasound, a complete section is not possible as ultrasound has a limited depth of view which is dependent on the frequency used. Ultrasound is unable to view structures beyond bone.

### *Method*

#### *Manual composition of a panoramic image*

The 'Diasus' is unable to produce panoramic images. Images taken sequentially can be collated in an image editing computer package, in this instance Jasc Paintshop Pro (Jasc Software, Version 6.00) was used.

#### *Panoramic imaging function*

The 'Philips ATL HDI 5000' was able to produce an extended field of view. A panoramic image over a large area is created by continuously scanning the region of interest. As the transducer is scanned over the region of interest, old echo information is retained and new echoes are added to the image in the direction the scan plane is moving.

### *Result*

Both the manual composition (*fig. 49*) and panoramic function (*fig. 50 and 51*) enable an appraisal of the cervical region. In the manual composition, the contours of the neck have not been taken into consideration. To enable complete visualisation of the neck to include this detail; would require manipulation of the images to account for contour and the final composition would be subjective and time consuming. Both methods of producing an extended field of view image give a complete image of the neck, and therefore provide greater information and give an idea of perspective.

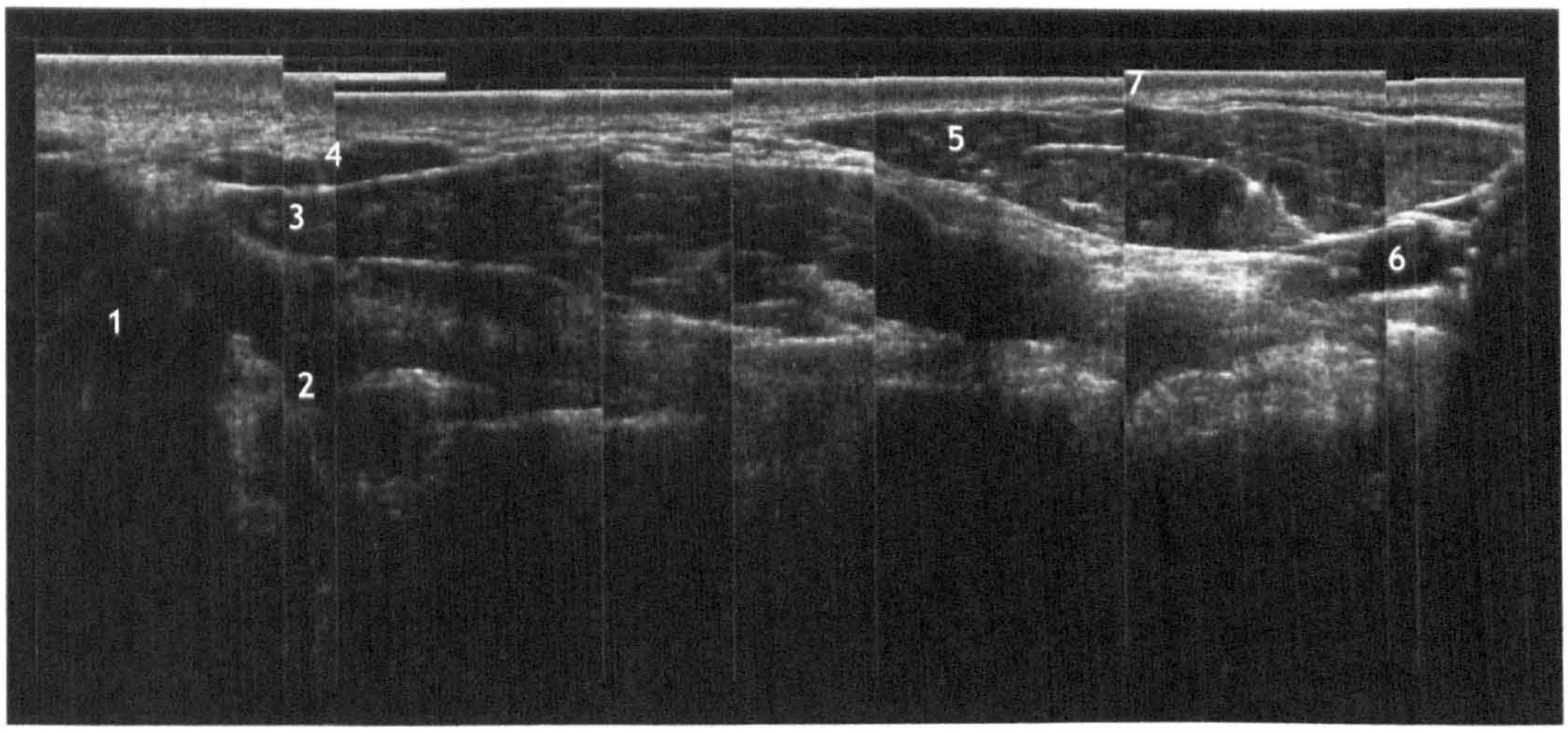

**Figure 49: Manual composite image of lateral neck**

Left side of neck, transverse scans (left = posterior, right = anterior).

1 - spinous process of C4
2 - erector spinae
3 - semispinalis
4 - trapezius
5 - sternocleidomastoid
6 - common carotid artery
7 - skin

**Figure 50: Extended field of view - anterior neck**

5 - sternocleidomastoid
6 - common carotid artery
7 - skin

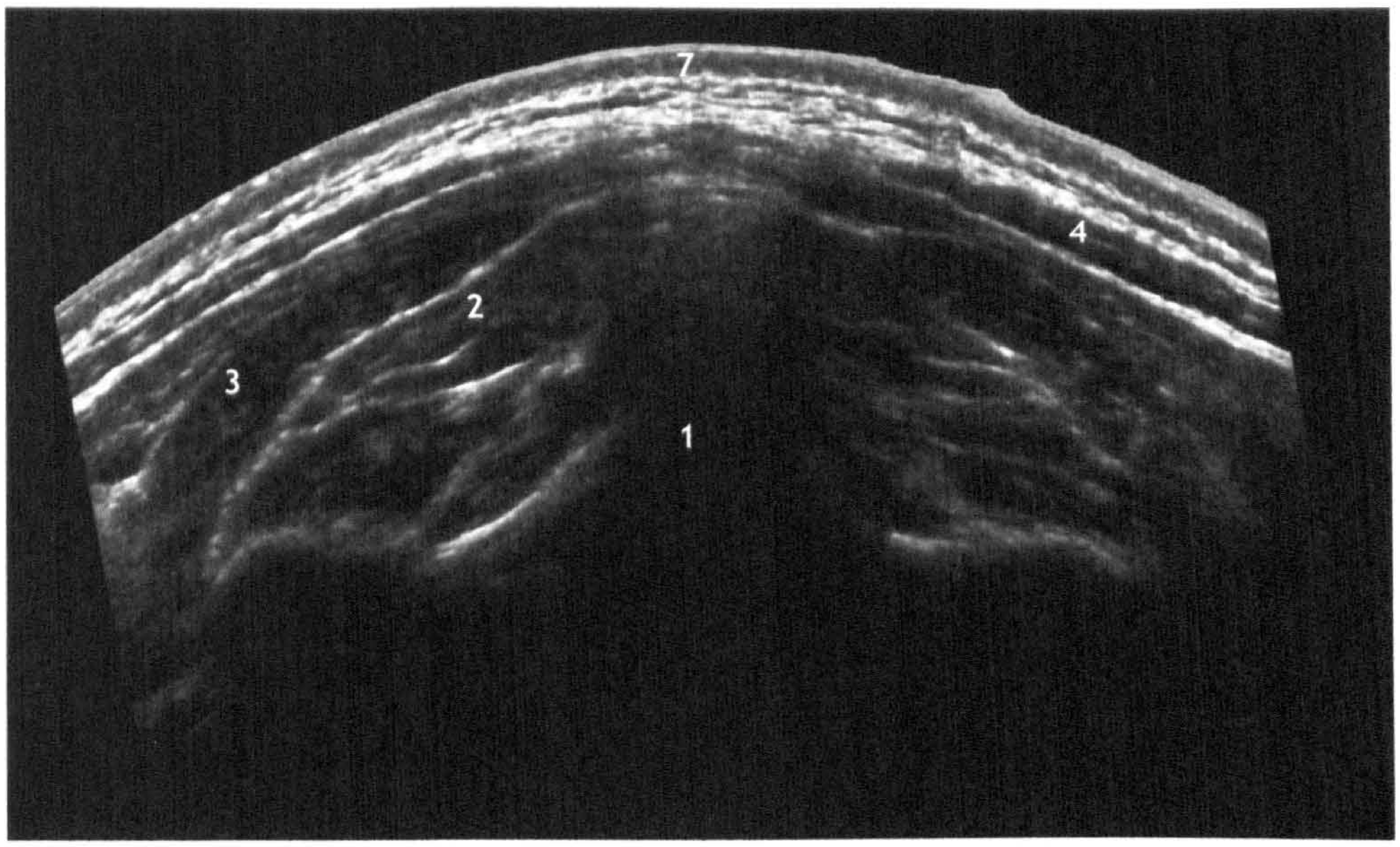

**Figure 51: Extended field of view - posterior neck**

1 - spinous process of C4
2 - erector spinae
3 - semispinalis
4 - trapezius
7 - skin

### *Discussion*

Initially, the manually constructed composite image was used as a reference. For the manual construction of an extended field of view image of the neck, this is a 'best fit' situation and the contour of the neck is not taken into account. This manual construction produced a representation that although it did not follow the neck contours; enabled an appreciation of the complete neck structure. Manual image construction is time consuming and biased by the user. Manufacturers of ultrasound machines should consider the option of a function that allows this method of image composition. Although this type of composition avoids anatomical correctness, it still enables an understanding of the region outside the range of the scan head. During the study, temporary use of another ultrasound system, a 'Philips ATL HDI 5000', was made available. This machine had the inherent capability to image an extended field of view. The extended field of view provided by the 'Philips ATL HDI 5000' produced images of the neck that appreciated contours. This greatly enhanced the ability to understand the arrangement of the anatomical area scanned; and the acceptability of such images for review is enhanced considerably.

## *4.4 Chapter Discussion*

The anatomy of the neck has been visualised with ultrasound and images produced, panoramic images have been constructed and extended field of view images have been obtained. Structures identified from images produced using ultrasound *in vivo* have correlated well with cadaveric dissection and magnetic resonance imaging. A technique has been established to allow a thorough investigation of the neck that enables visualisation of many important structures. Those structures ultrasound is capable of identifying have been noted and the ease of seeing them highlighted. A comprehensive picture of the cervical spine has been painted and provides a good grounding for later experiments where pathological changes of this region will be investigated.

# Chapter 5: Soft Tissue Damage

## *5.1 Chapter Summary*

In this chapter, images were collected from a variety of injuries and have been presented as case studies. These case studies enabled the author to gain a practical understanding of how soft tissue injury appears and how the repair process may be monitored with ultrasound. This activity also provided an opportunity to understand patient issues and to develop patient interaction skills.

Project objectives fulfilled in this chapter:

- study the ultrasound appearance of soft tissue damage *in vivo*

## *5.2 Background*

The structure of soft tissue and its appearance with ultrasound in health and following injury has been discussed (*see Chapter 2*). The author was familiar with the ultrasound appearance of tissue in health but not with pathology. Colleagues presenting with soft tissue injuries enabled the author to gain valuable experience of imaging musculoskeletal pathology. Through assessment of injuries the author hoped to perfect their technique and operation of the ultrasound equipment, improve dexterity, to be able to consider the best orientation to scan the region of interest and further their knowledge of injury pathology. These case studies would provide an opportunity to determine a suitable method for the quantification, and how to recognise those changes that take place and how they may be monitored. Assessing subjects' injuries would provide an opportunity to perfect patient communication skills and understand the best approach to ensure subjects remain comfortable throughout the scan. Consideration was given to the differentiation of pathology from artefact. As well as this opportunity for hands on experience, additional preparation took the form of background reading, studying medical cases where ultrasound has been used for assessment. The author was also able to sit in on musculoskeletal clinics with consultant radiologists from the Queen's

Medical Centre (*see Chapter 3*). This preparation gave an appreciation of what to expect when ultimately assessing whiplash injuries.

## *5.3 Experimental Work*

### *Method*

To aid assessment, a criterion was established to identify the presence of a lesion. This criterion was that a lesion could be identified as: the presence of an area demonstrating an abnormal pattern or intensity of echoes relative to the appearance of the surrounding section of tissue or contralateral region. Contralateral images were acquired to demonstrate the normal versus the injured side, being mindful that compensatory changes may occur. The ideal situation would be to have before and after injury images for comparison but this was not possible. Asymptomatic patients do not find the scanning procedure uncomfortable (*see Chapter 4*); however, it was important to find out how subjects suffering from painful injury responded to the scan. Subjects were asked to grade the comfort of scale from 0 (no discomfort) to 5 (intolerable). Subject's details and history of the accident were obtained.

### *Results*

For subjects presenting with soft tissue injuries, case studies and their ultrasound findings are presented.

**Case study 1: Subcutaneous haematoma from fall**

***Patient details:*** 22 year old female

***Cause of injury:*** The subject fell up a metal stairs and landed onto their left shin.

***Injury mechanism:*** Impact

***Time elapsed between injury and scan:*** The subject was scanned immediately after injury and the next day.

***External observation:*** 10cm below the patella bruising was observed.

***Observation with ultrasound:*** *(see fig. 52)* Ultrasound detected a region indicating a haematoma formation that correlated with the surface bruising. Resolution of surface bruising was also observed as resolution of haematoma.

***Other radiography:*** None

***Grading given for comfort of the scan:*** 0 (no discomfort)

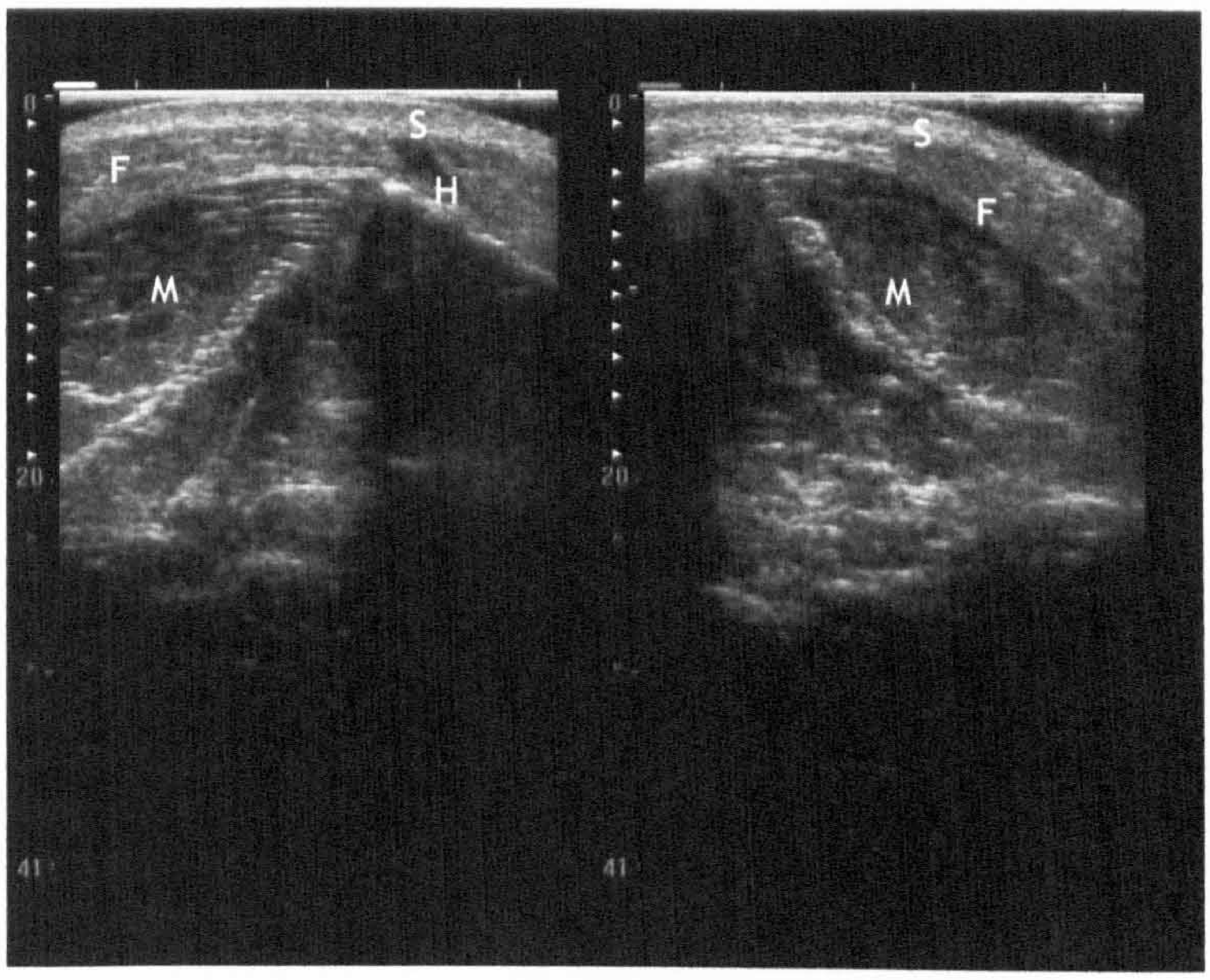

**Figure 52: Haematoma in the leg**

Transverse scan, left leg injured (left), right leg normal (right).
(H = haematoma, M = muscle, F = fascia, S = skin)

**Case study 2: Subcutaneous haematoma from fall**

***Patient details:*** 23 year old female

***Cause of injury:*** Fell over playing football

***Injury mechanism:*** Impact

***Time elapsed between injury and scan:*** Scanned one day after injury

***External observation:*** Multiple bruising on thigh

***Observation with ultrasound:*** (*see fig. 53*) Ultrasound detected multiple haematoma formation in a region that correlated with the surface bruising. Resolution of surface bruising was also observed as resolution of haematoma.

***Other radiography:*** None

***Grading given for comfort of the scan:*** 0 (no discomfort)

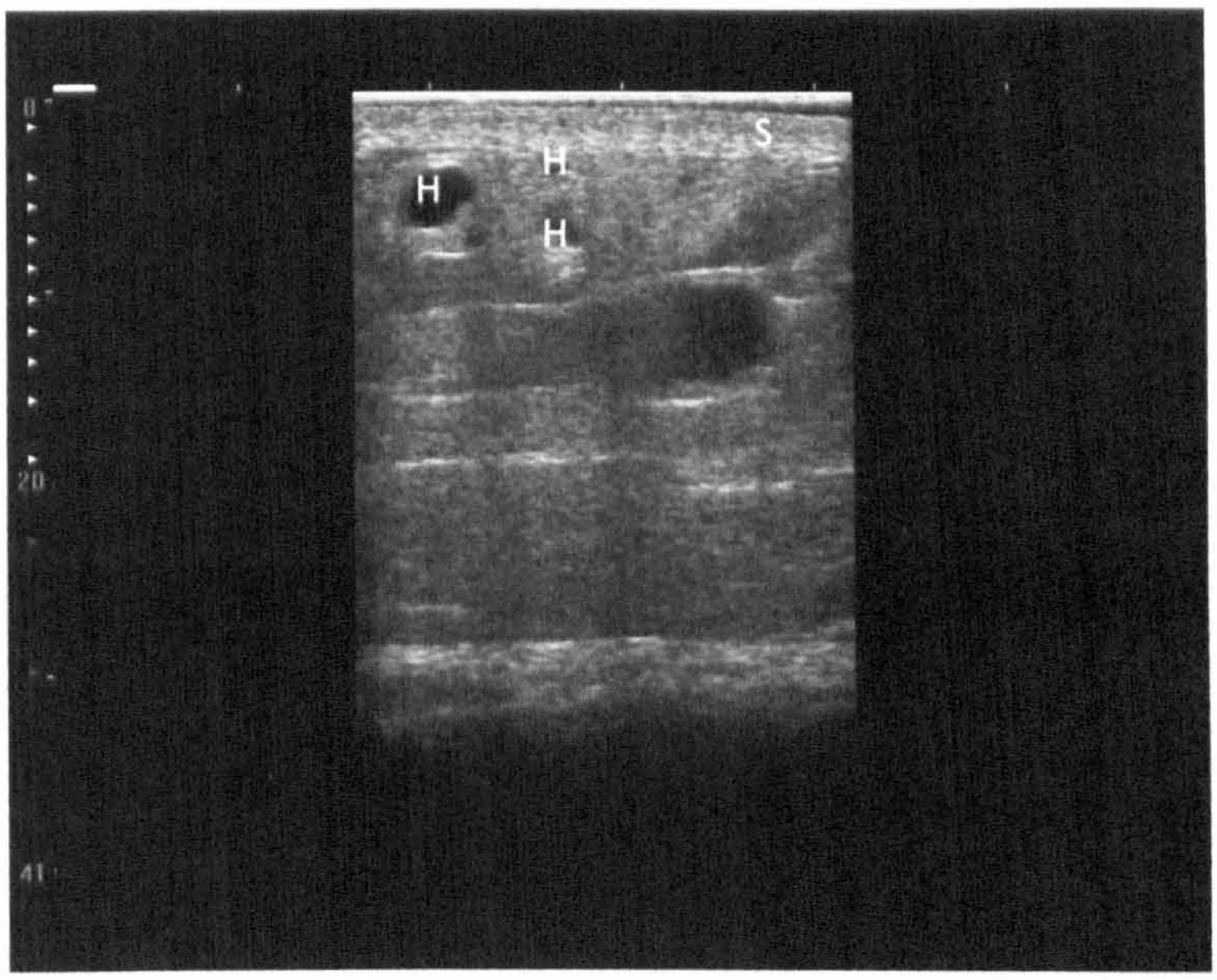

**Figure 53: Multiple haematomas in the thigh**

Transverse scan
(H = haematoma, S = skin)

**Case study 3: Subcutaneous haematoma from gun recoil**

***Patient details:*** 25 year old male

***Cause of injury:*** Repeated impact from recoil of gun butt on right arm.

***Injury mechanism:*** Impact

***Time elapsed between injury and scan:*** the following day

***External observation:*** Bruising and swelling measured over an area of 19 x 10cm (*fig. 54*)

***Observation with ultrasound:*** (*see fig. 55*) Swelling and haematoma extending over the bruised region correlated well. The region beneath the bruise was hyperechoic compared to surrounding tissue and the same area of the contralateral limb. Swelling is indicated by the hyperechoic appearance of the region and by compression of a blood vessel in this area. The artery on the injured side (left image) appears compressed when compared to the artery of the normal arm (right image). This compression of the artery occurs because of swelling which appears as an area of increased echogenicity.

***Other radiography:*** None

***Grading given for comfort of the scan:*** 0 (no discomfort)

**Figure 54: External bruising on arm**
Anterior view of upper arm.

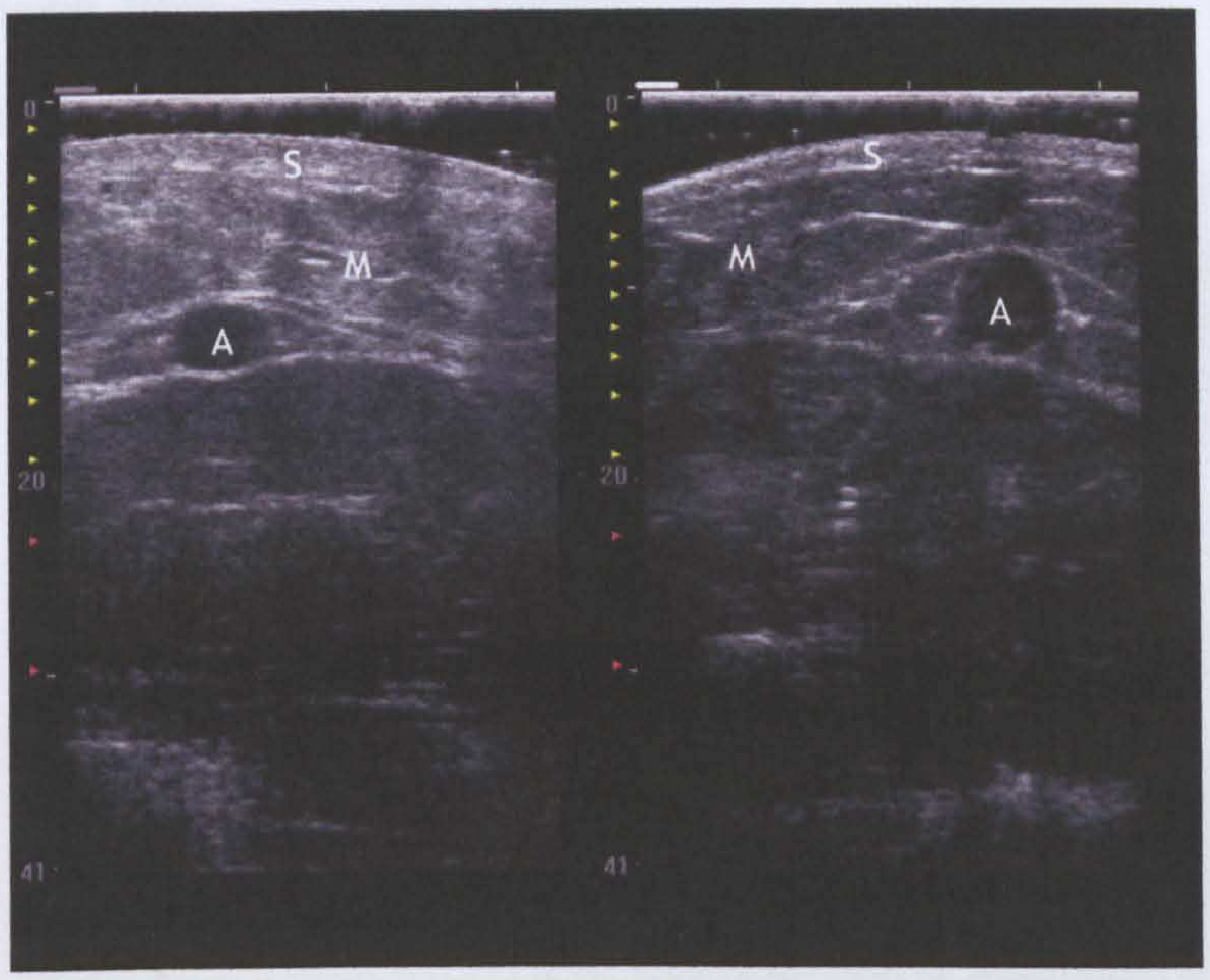

**Figure 55: Haematoma and swelling in the arm**

Anterior view, transverse scan, left arm injured (left), right arm normal (right).
(M = muscle, A = artery, S = skin)

**Case study 4: Knee injury**

***Patient details:*** 40 year old male

***Cause of injury:*** Car accident, leg injured on steering column.

***Injury mechanism:*** Impact

***Time elapsed between injury and scan:*** 3 months

***External observation:*** Swelling

***Observation with ultrasound:*** (*see fig. 56*) A fluid mass, possibly a haematoma, is indicated by an anechoic region that deforms under the pressure of the transducer. Hyperechoic strands are present within this mass and suggest organisation of the injury. This organisation would be expected as a function of a repair process and this corresponds with the age of the injury. Increased echogenicity beneath the haematoma represents swelling. Swelling and haematoma have resulted in an increase in diameter of the region which is also apparent when comparing the injured knee to the contralateral side.

***Other radiography:*** None

***Grading given for comfort of the scan:*** 0 (no discomfort)

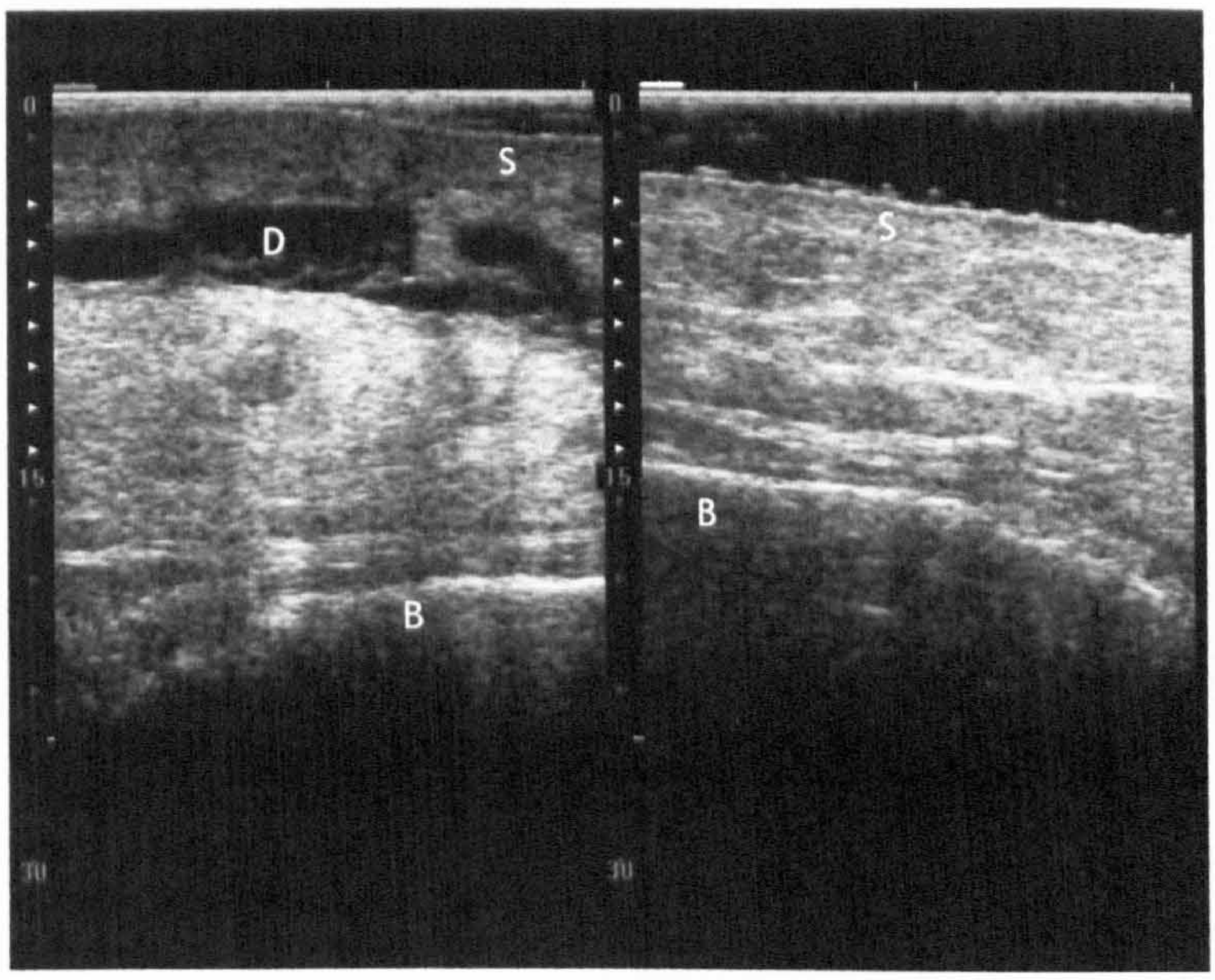

**Figure 56: Damaged knee**

Transverse scan, left knee damaged (left), right knee normal (right).
(D = area of damage, B = bone, S = skin)

**Case study 5: Sebaceous cyst**

***Patient details:*** 45 year old male

***Cause of injury:*** Progressive development of a cyst on the midline of the neck at C3

***Injury mechanism:*** Unknown

***Time elapsed between injury and scan:*** a few weeks

***External observation:*** Circular lump

***Observation with ultrasound:*** (*see fig. 57*) A sebaceous cyst appearing as a fluid filled collection that appeared anechoic on ultrasound. Enhancement artefact has occurred. Internal appearance of cyst correlated with the raised region measured externally.

***Other radiography:*** None

***Grading given for comfort of the scan:*** 0 (no discomfort)



**Figure 57: Sebaceous cyst**

Transverse scan
(C = cyst, S = skin)

**Case study 6: Fall on shoulder**

***Patient details:*** 35 year old male

***Cause of injury:*** Fell off during a bike race on a grass surface.

***Injury mechanism:*** Impact/strain

***Time elapsed between injury and scan:*** Two days. The subject was examined by a clinician of the accident and emergency department of the Queen's Medical Centre and was diagnosed as having torn a muscle.

***External observation:*** There were no external signs and therefore a region could not be defined. The subject felt general discomfort over the scapular region.

***Observation with ultrasound:*** (*see fig. 58*) Muscle structure detail was lacking in the region where discomfort was felt with an increased diameter and structures appearing hyperechoic with respect to the contralateral image. Loss of structural detail and the subsequent swelling, indicated by the hyperechoic region and anechoic region signified possible haematoma and/or swelling indicative of a muscle tear. These findings correlate well to the clinician's diagnosis of a muscle tear.

***Other radiography:*** None

***Grading given for comfort of the scan:*** 0 (no discomfort)

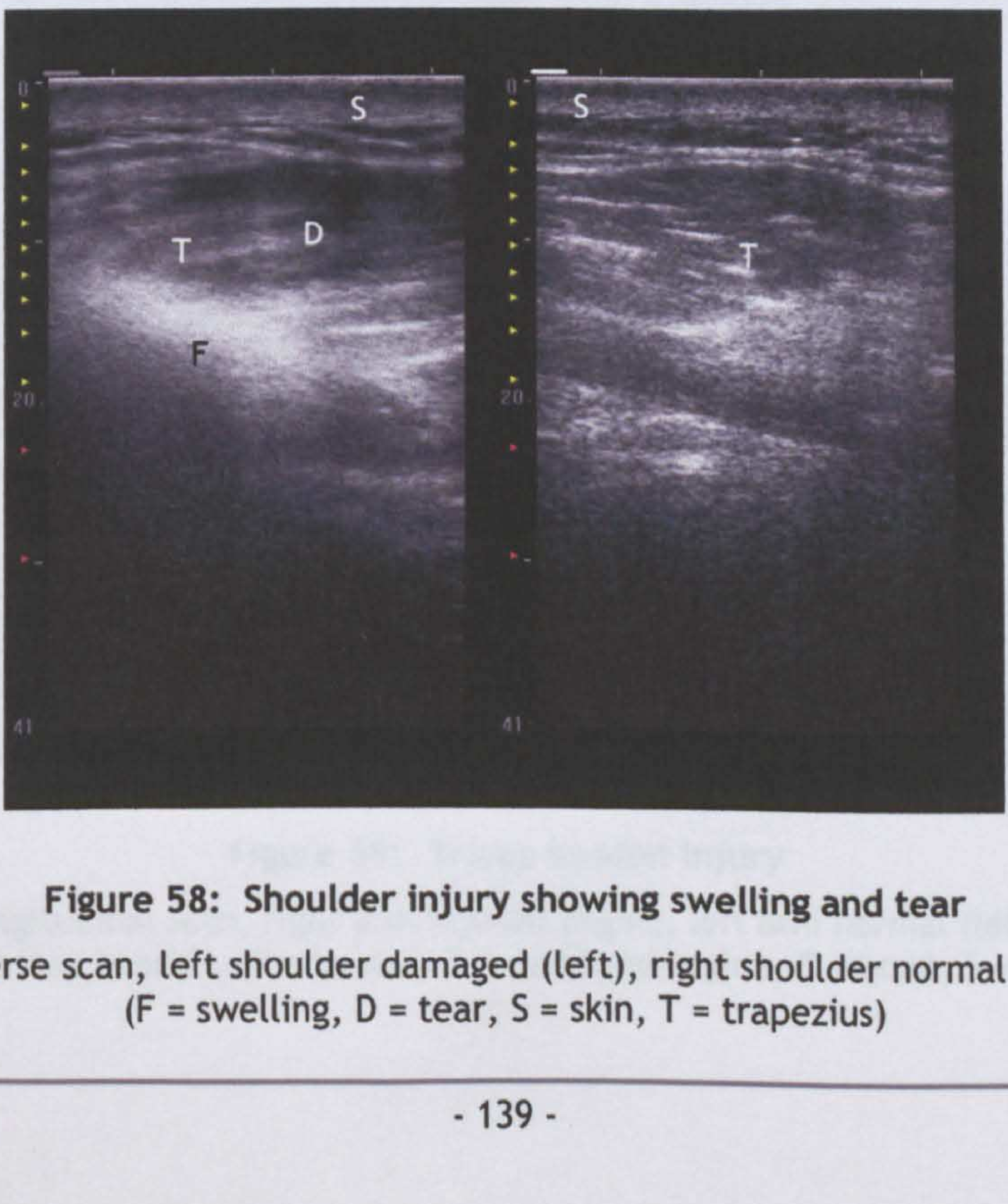

**Figure 58: Shoulder injury showing swelling and tear**

Transverse scan, left shoulder damaged (left), right shoulder normal (right).
(F = swelling, D = tear, S = skin, T = trapezius)

**Case study 7: Triceps tendon damage**

***Patient details:*** 23 year old female

***Cause of injury:*** Fall onto right elbow, hyperextension of joint

***Injury mechanism:*** Impact

***Time elapsed between injury and scan:*** Next day

***External observation:*** Swelling of elbow joint, reduced mobility and range of motion in the elbow joint, the arm was unable to extend.

***Observation with ultrasound:*** (*see fig. 59*) Contralateral imaging of the tricep tendon revealed the injured side to appear disorganised with respect to the normal side. The regular linear arrangement of tendon fibres is replaced by an anechoic region bordered by an irregular fibre arrangement. The humerus is represented by the hyperechoic region, and on the injured side this appears deeper with respect to the contralatrel image indicating swelling and increased diameter of the region.

***Other radiography:*** Subsequently imaged by a consultant musculoskeletal radiologist who confirmed the above findings.

***Grading given for comfort of the scan:*** 0 (no discomfort)

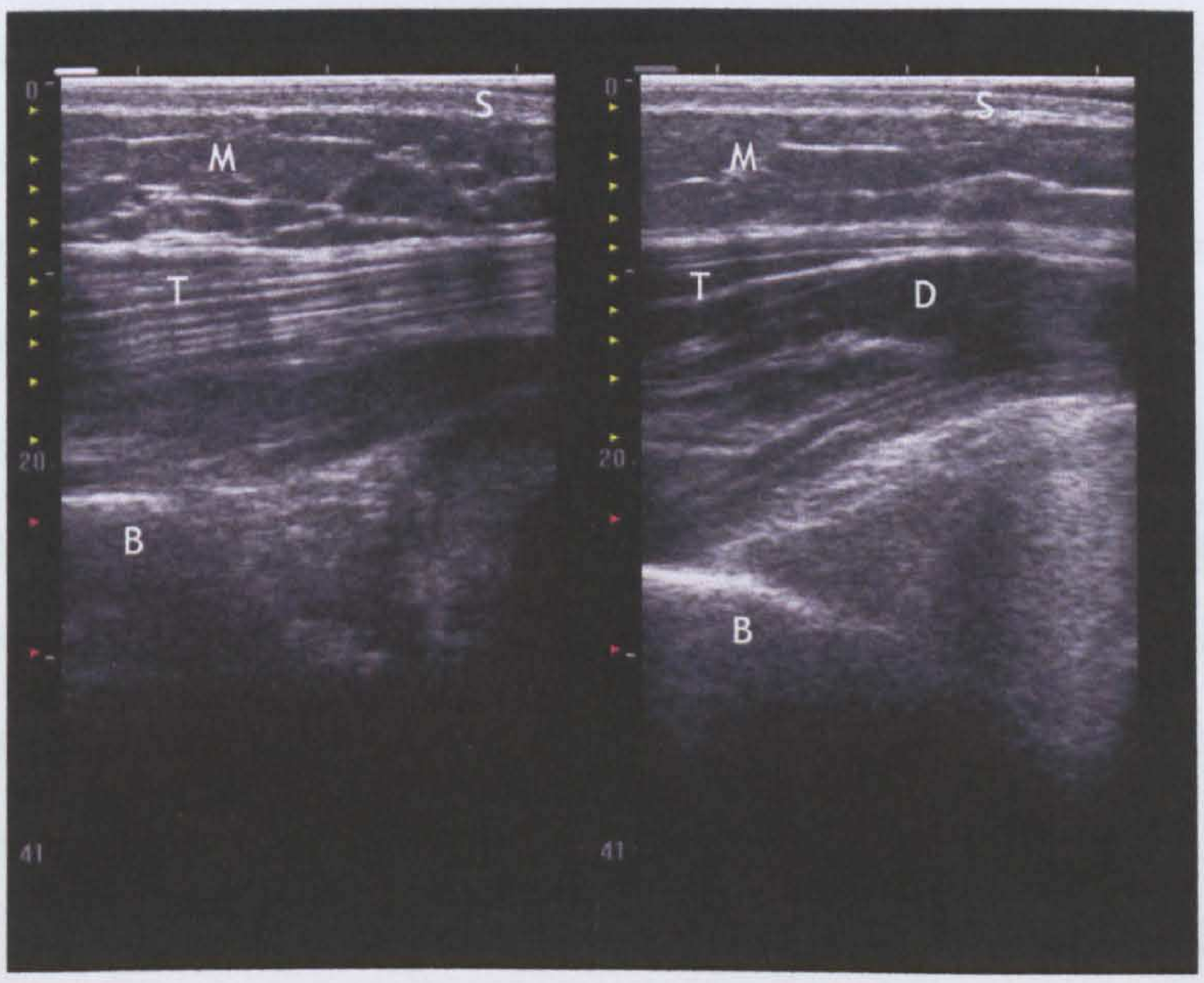

**Figure 59: Tricep tendon injury**

Longitudinal scan, right arm injured (right), left arm normal (left).
(T = tricep tendon, M = muscle, D = damaged region, B = bone, S = skin)

### *Case studies summary*

For all case studies, the symptoms were found to correlate well with ultrasound observations. Bruising results in underlying swelling or haematoma formation. Swelling appears as regions of increased echogenicity and loss of structural arrangement with an increase in structure diameter where blood vessels may be compressed. Swelling results in a loss of tissue boundary definition. Haematoma appears as well defined anechoic regions within regularly arranged structures. Tears or tendon damage result in disruption to the normal fibre arrangement and can appear as anechoic regions if the damage is extensive. Fluid collections as in the case of cysts results in an anechoic appearance often with enhancement artefact.

## *5.4 Chapter Discussion*

Various case studies have been presented which provided the author with a variety of pathologies to assess. In all cases pathology was found to correlate well with symptoms. Ideally, these case studies would have been followed up on a regular basis to monitor the pathology and observe any changes in their ultrasound appearance; unfortunately it was not possible for these subjects to commit to a follow-up program. All subjects graded the scan with 0 (no discomfort); this is important that the scanning procedure is comfortable for injured subjects as this could have been a limitation to using the technique. Discomfort can be avoided by using coupling gel which makes it possible to scan without direct contact with the subject; this therefore avoids direct provocation of the injury. Provocation is also a useful means for determining the injury site. When scanning a subject, it is not essential for the patient to remain still in an awkward position if it is uncomfortable to do so. However, changes in posture will alter the orientation of structures and this must be considered at follow-up if the subject is scanned in a different position. It was not possible to monitor the recovery process in all cases as not all subjects had the time to commit to the study. The opportunity to shadow a consultant radiologist gave the author an opportunity to appreciate how ultrasound diagnosis is carried out in a professional and clinical environment. Compilation of the case studies presented in this chapter has enabled the author to hone their technique and develop patient communication skills. The author has a greater understanding of the appearance of pathology and the examination procedure.

# Chapter 6: Quantification of Pathology Using Ultrasound

## *6.1 Chapter Summary*

This chapter discusses the approach taken to define a quantitative technique for the assessment of soft tissue pathology. A quantitative technique was developed through a series of experimental work. An initial simulation of soft tissue injury was carried out *in vitro* to confirm *in vivo* findings from case studies and form a basis for an experimental model. An investigation of quantification of these injuries follows. These experiments provided an indication of how realistic it would be to assess whiplash injuries and what would be the best approach to documenting any pathological change. An assessment of using the ultrasound equipment to quantify injury damage; as well as the effects of the operator on the results, was also considered.

Project objectives fulfilled in this chapter:

- study the ultrasound appearance of soft tissue damage *in vitro*
- quantification of soft tissue injury using ultrasound

## *6.2 Background*

One of the main objectives of this study was to quantify pathological trauma of the cervical spine. Quantification of pathology allows an understanding of the extent of damage and assists in the monitoring of recovery. Quantitative analysis is far less susceptible to bias and should provide more reliable and consistent results; it also allows statistical tests to be performed that can ensure confidence in the results. Quantification may also facilitate detection of subtle changes, which might escape detection by visual assessment alone. To be able to quantify an injury enables a value to be assigned to the pathologies identified. This value can be used as a reference value, which is essential to describe the extent of damage and for monitoring the recovery process.

The series of experiments conducted to establish a method that may be used for injury identification, documentation and quantification is described. Initially, an injury model was established that simulated the appearance and behaviour of injuries *in vivo*, once this was identified, quantification could be considered. Quantification was of simulated injuries where the extent of damage could be predetermined. This enabled an assessment of the ability to use the ultrasound equipment to depict and quantify the injury and assess the ability of the operator to accurately measure the injury. Finally, methods of analysis were considered.

## 6.3 Series of Experiments

The following series of experiments were conducted to study the ultrasound appearance of soft tissue damage and to establish a quantification technique of the soft tissue injuries suspected of occurring as a result of a whiplash injury:

Experiment 1: *Soft tissue pathology simulation experiments*
Experiment 2: *Quantification of a synthetic simulation of a soft tissue injury*
Experiment 3: *Quantification of an organic simulation of a soft tissue injury*
Experiment 4: *The effect of inter/intra observer variability on quantification*
Experiment 5: *The effect of magnification on assessment*
Experiment 6: *Echogenicity and histogram analysis*

### *Method*

#### *Ultrasound equipment*

The ultrasound equipment used in this study was 'Diasus' (Dynamic Imaging Limited, Livingston, UK) connected to an ultra wide-band 8-16MHz transducer (Dynamic Imaging Limited, Livingston, UK).

#### *Biological tissue*

The preparation of biological material has been considered previously (*see Chapter 3*).

### *Calculating absolute values*

A consideration before carrying out this quantification study was how the positioning of the on-screen callipers would affect the measurement. Accurate absolute values are difficult to obtain as defining the region of interest using callipers can introduce error. Measurement values will vary depending on whether the calliper is positioned within, on, or outside the boundary. Consistency of calliper placement can help to minimise these errors and for the purposes of this study, callipers were placed on the boundary of the region of interest.

## Experiment 1: Soft tissue pathology simulation experiments

### *Background*

The characteristic appearance of a typical *in vivo* soft tissue injury with ultrasound has been well defined (*see Chapter* 2) and the aim of this experiment was to produce a model that could replicate this. This model would also be used to verify the ultrasound images previously obtained *in vivo* (*see Chapter 5*); for example, it may be assumed that *in vivo* the appearance of an anechoic area within a muscle represents a haematoma, by creating a haematoma *in vitro* using blood, a comparison of the two images can be made to confirm expectation. This model also provides a means for developing a quantitative technique. For those experiments conducted *in vitro*, it was possible to control the extent of the injury; and to observe the essential before and after injury image; images not readily available *in vivo*. Models are useful as they enable a readily available controlled environment where values are predetermined. A model also provides a useful commodity as volunteers with musculoskeletal injuries were not readily available. Simulation of typical musculoskeletal injuries including swelling, haematoma and tear were carried out on animal tissue.

### *Method*

The following methodology describes how those soft tissue injuries typically observed in musculoskeletal injuries were simulated *in vitro*.

### *Haematoma simulation*

A haematoma is a collection of blood within tissue. In essence, it is a collection of fluid within a structure. The haematoma was simulated by injecting tissue samples with different solutions including ultrasound gel and blood, into muscle and tendon tissue. All of the solutions were fluid in nature, and muscle and tendon tissue as well as representing those tissues suspected of damage, also provided an ideal contrast medium. The muscle was divided into individual samples; only one sample was used per injection of solution to avoid contamination of solutions. Using a 19G x 2" sterile needle (BD Microlance™, BD Medical Pharmaceutical Systems, Le Pont-De-Claix, France) and a 2ml sterile syringe (BD Plastipack™, BD Medical Pharmaceutical Systems, Le Pont-De-Claix, France) the solution was injected into the tissue at a depth sufficient for the solution to be completely surrounded by the tissue; this ensured clear visibility of any changes in the tissue. To clearly visualise the needle position in the tissue, the transducer was held perpendicular to the length of the needle. After injection, the tissue was dissected to observe the distribution of the solution.

### *Swelling simulation*

Swelling is the result of a collection of interstitial fluid. To replicate this, water was injected using a 19G x 2" sterile needle (BD Microlance™) and a 2ml sterile syringe (BD Plastipack™) into muscle and tendon tissue.

### *Soft tissue tear simulation*

A tear results in disorganisation of the tissue architecture. Fibre disruption was achieved by pushing a plastic cable tie into the tendon. The cable tie was made of dense plastic and was clearly visible on ultrasound. The cable tie was used as a marker that could identify the position of the lesion in the tendon when it was removed. Fibre disruption was also achieved by inserting a size 22 non sterile, carbon steel, surgical blade (Swann-Morton Ltd., Sheffield, UK) into the muscle tissue. The position of the scalpel could be appreciated on ultrasound and used to identify the site of the lesion.

### *Results*

#### *Haematoma simulation*

In muscle and tendon, both injection of ultrasound gel and blood was clearly visible on ultrasound (*fig. 60-63*). Both solutions created a clearly discernable anechoic region. Gel contains air bubbles which were visualised with ultrasound as hyperechoic bubbles in a more hypoechoic medium surrounded by organised soft tissue. As the volume of blood or gel injected was increased, there was a visible increase in the anechoic region within the tissue architecture (fig. 60). On dissection, a pool of gel was observed which correlated well with the position of the lesion viewed with ultrasound.

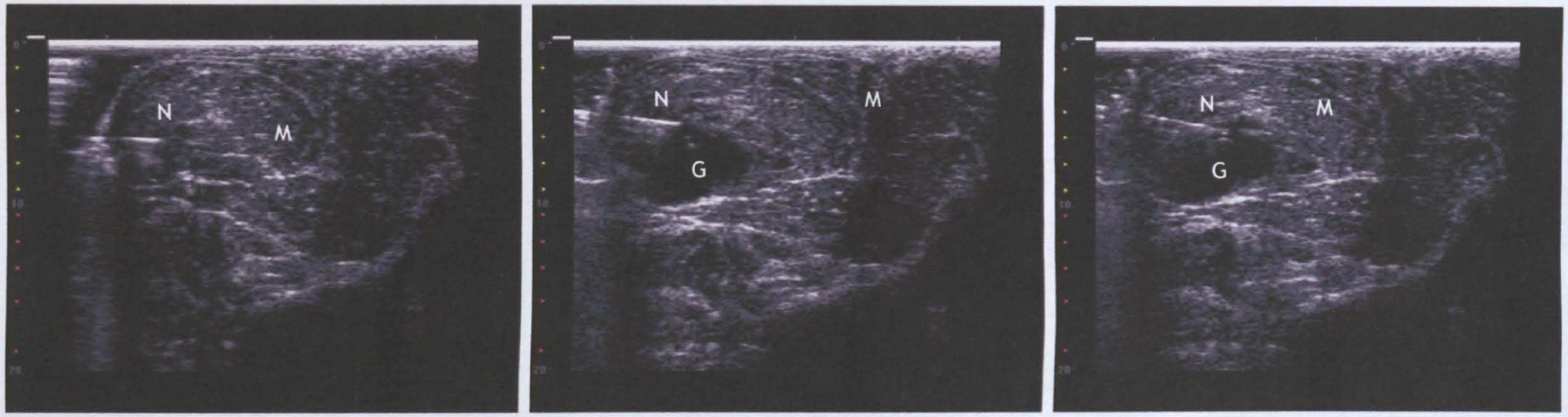

**Figure 60: Gel haematoma model in muscle**
Transverse scan of muscle before injection (left), with 0.5ml of gel injected (middle) and after 1ml of gel injected (right).
(N= needle, M = muscle, G = gel)

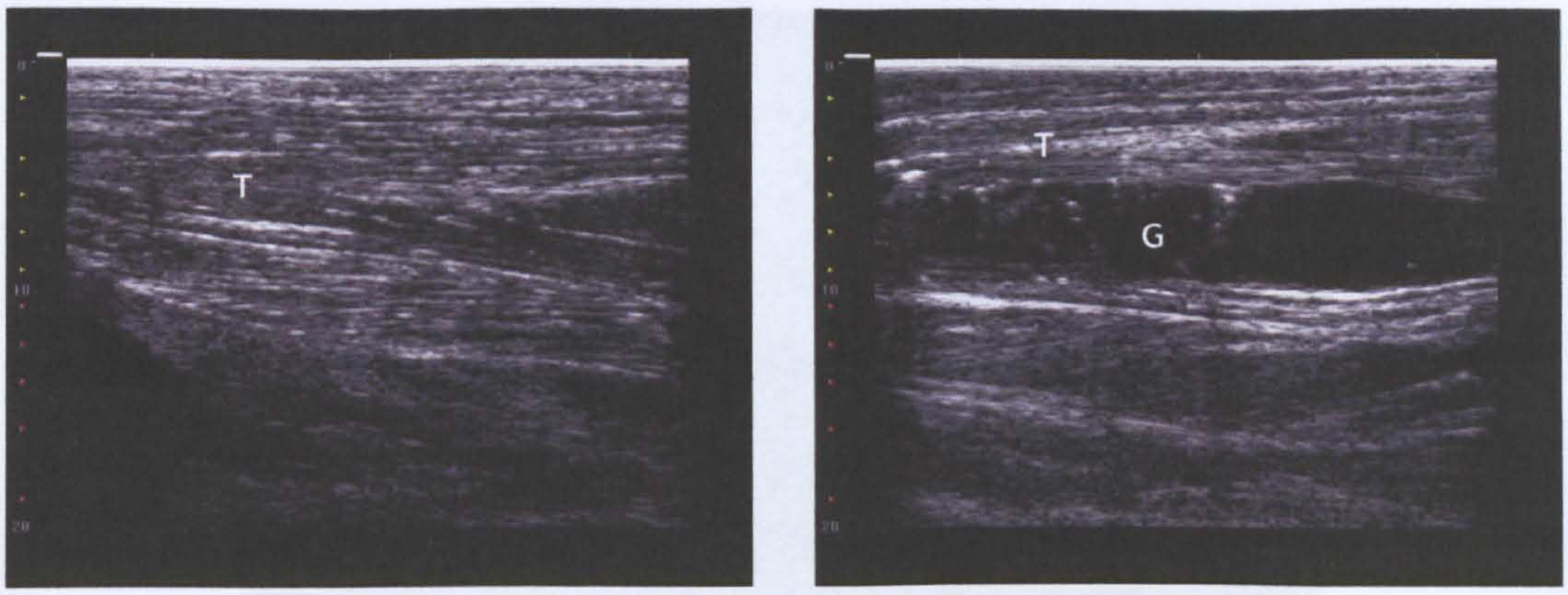

**Figure 61: Gel haematoma model in tendon (Part 1)**

Longitudinal scan of tendon before (left) and after (right) injection of gel.
(T = tendon, G = gel)

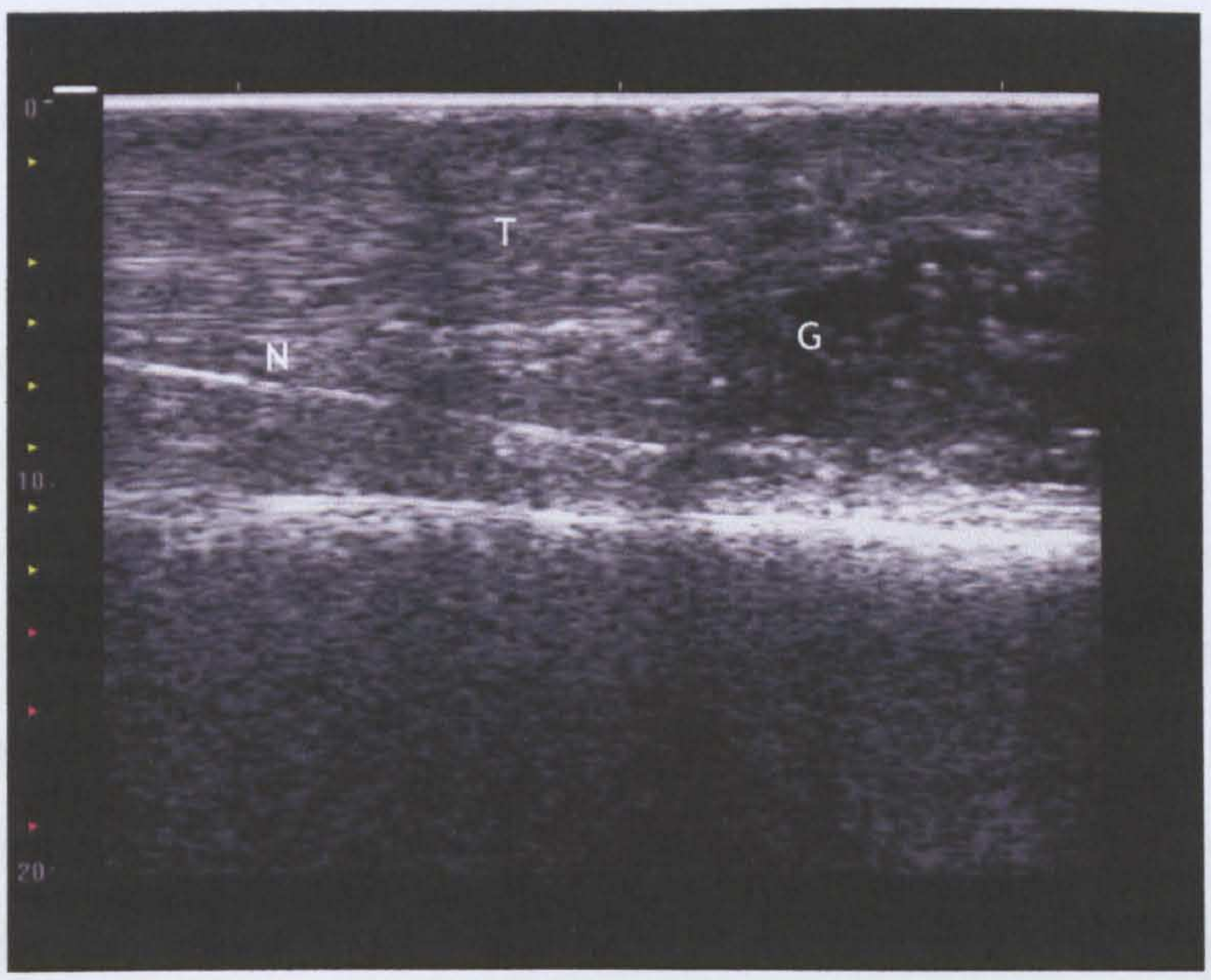

**Figure 62: Gel haematoma model in tendon (Part 2)**

Longitudinal scan of tendon after injection of gel.
(T = tendon, N = needle, G = gel)

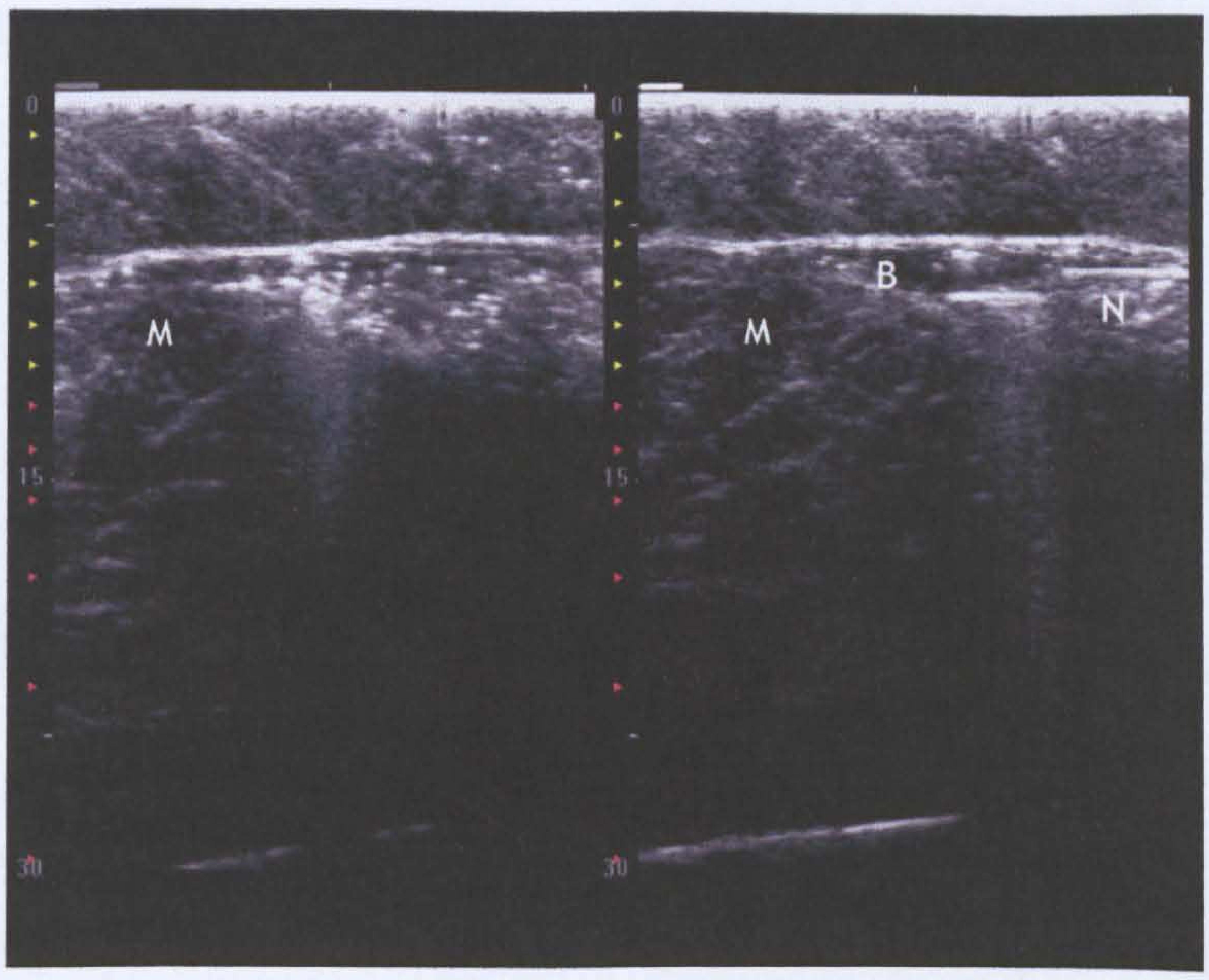

**Figure 63: Blood haematoma model in muscle**

Transverse scan of muscle before (left) and after (right) blood injection.
(N = needle, B = blood, M = muscle)

*Swelling simulation*

In muscle and tendon tissue, injection of water causes a noticeable change in fibre architecture appearance with the water appearing to distribute between the fibres (*fig. 64 and 65*). As the amount of water injected increased, there was a visible increase in fibre disruption in both tendon and muscle, an increase in the diameter of muscle but not tendon was also observed. This increase in diameter may have gone unnoticed had observation of the injection not been made. The needle is seen to be displaced with the injection of water.

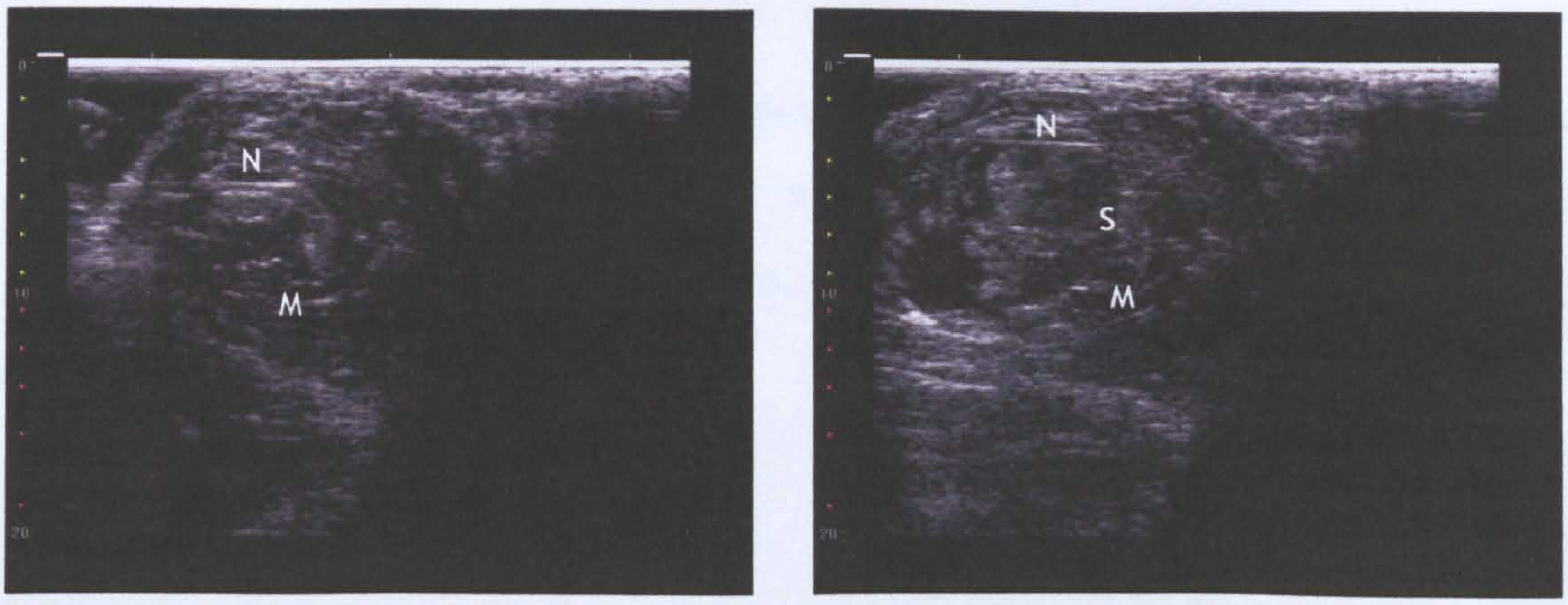

**Figure 64: Swelling model in muscle**

Transverse scan of muscle before (left) and after (right) injection of water.
(N = needle, S = swelling, M = muscle)

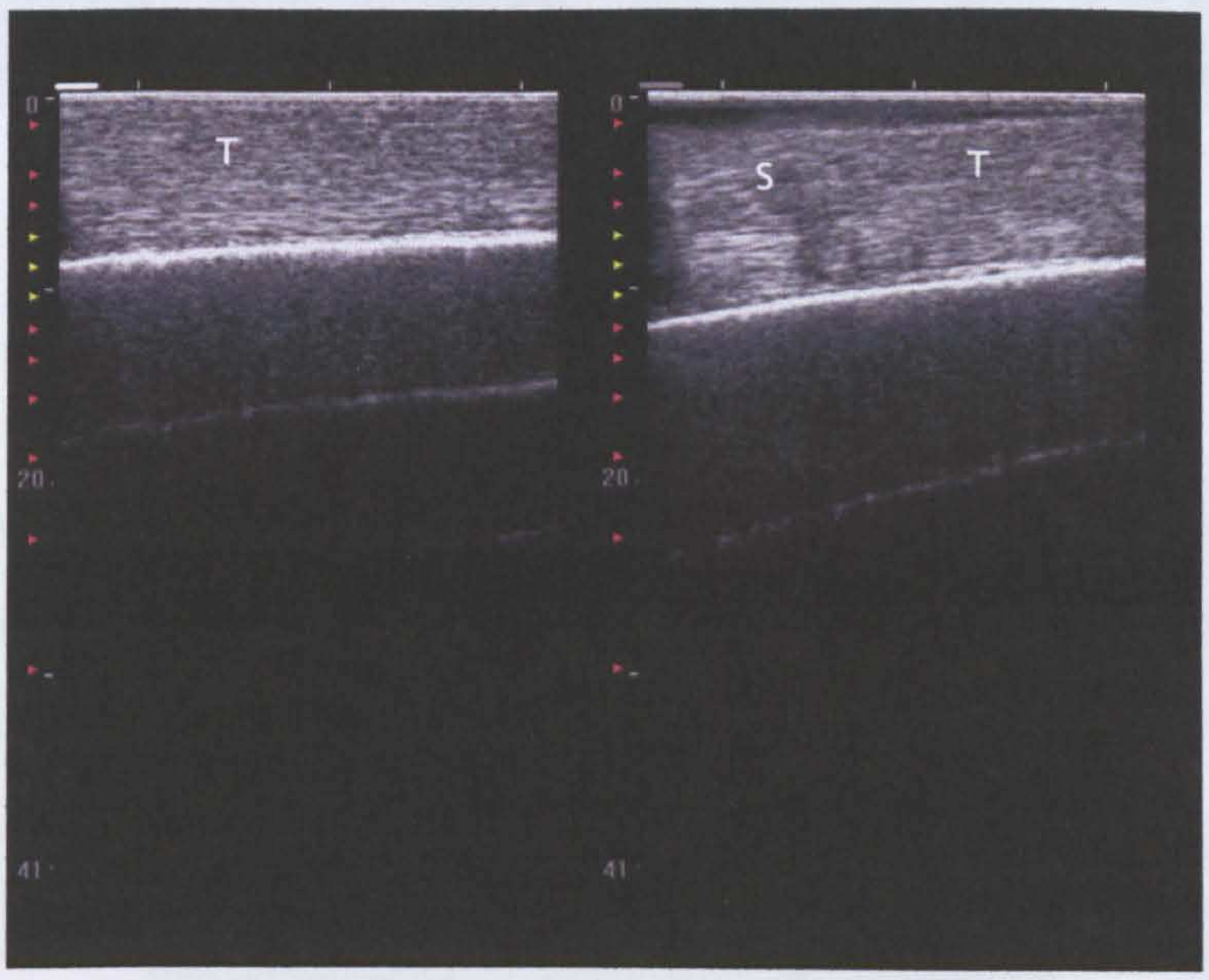

**Figure 65: Swelling model in tendon**

Longitudinal scan of tendon before (left) and after (right) injection of water.
(S = swelling, T = tendon)

*Soft tissue tear simulation*

In the equine tendon, the insertion of a plastic cable tie was clearly visible on ultrasound as a cable tie shaped hyperechoic region (*fig. 66*). The subsequent removal of the cable tie left an anechoic region with hyperechoic regions depicting fibre disruption.

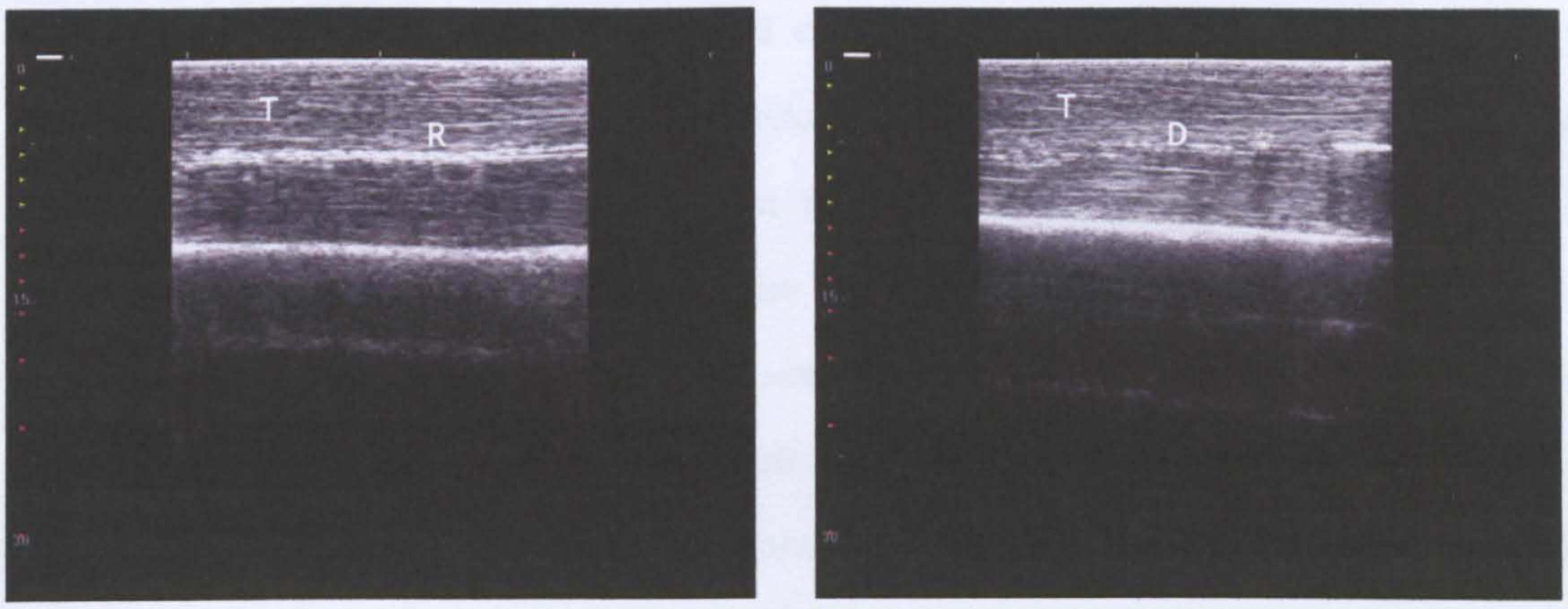

**Figure 66: Tendon tear model**

Longitudinal scan of tendon with plastic rod inserted (left) and after rod removed (right). (T = tendon, R = rod, D = tear)

In muscle tissue, the insertion of a blade appeared as a hyperechoic region with reverberation clearly representing the shape of the blade (*fig. 67*). When the blade was removed, the region of the scalpel revealed fibre disruption.

**Figure 67: Muscle tear model**

Transverse scan of muscle with scalpel inserted (left) and after scalpel removed (right). (S = scalpel, T = tear)

### *Discussion*

Soft tissue injuries simulated *in vitro* compared favourably to their *in vivo* counterparts. The success of this replication has been possible as tissue and injury characteristics were identified prior to creating these models. Ultrasound relies on the characteristics of the tissue to produce an image and these characteristics were employed when designing the models. For example, a pooling of blood creates a haematoma which is essentially a collection of fluid surrounded by a denser medium. The fluid consistency of a haematoma was simulated using water and ultrasound gel as both have a more fluid consistency than the surrounding tissue. As ultrasound utilises these different characteristics to produce an image, water and gel were ideal candidates. Water was found to spread through the fibres producing a visible change in tissue architecture as well as an overall expansion of the muscle tissue; thus it was decided that water would be a more suitable model for observing swelling. Unlike muscle, tendon did not increase in size with the introduction of water; this is likely to be due to it being less pliable than muscle and a greater force being needed to overcome the resistance. Ultrasound gel and blood provided a more comparable representation of the haematoma seen *in vivo*. Both blood and gel are more viscous than water and hence this property would not only affect how ultrasound interacts with these fluids but also will affect how the solution distributes between the soft tissue fibres. Water distributed between the soft tissue fibres, whereas blood and gel were more inclined to pool. Equine digital flexor tendon is larger than any tendon found in the human neck and is therefore not truly representative of these structures. However, this information may be extrapolated to smaller structures of a similar composition and tendon tissue also provides a good contrast and further illustrates observations of soft tissue disruption that can be used to assess quantification techniques. Where solution has been injected, it is possible that the injection process has damaged the fibres as the fluid is forced in. When injecting the solutions, resistance had to be overcome to get the solution into the tissue. In a real injury, damage would occur and these fluids would then appear whereas for this experiment the reverse effect could have been induced which may not give a true representation of the injury.

The replication of a tissue tear by incision using a scalpel is not truly representative of a tear. The scalpel gives a clean cut when in reality, a tear is unlikely to be as organised. For all the models described here, injury comprises of a multitude of events (*see Chapter 2*). When injury occurs, there is an initial inflammatory response and depending on the stage of healing, there are changes in tissue structure. In the case of a tear, it is likely that bleeding and even haematoma formation would accompany it and thus aid identification of the pathology. In the long term, such consequences as scar tissue or myositis ossificans (where muscle tissue is replaced by bone) can occur which cause areas of greater density within the tissue and hence increased echogenicity in contrast to the surrounding tissue. These injury indicators may be easier to identify than the initial injury. It has not been possible to simulate the progressive effects of injury and repair and therefore the aim to replicate the *in vivo* injury could not be completely fulfilled in this instance. However, true replication is not required as one of the purposes of creating these models is to assess the feasibility of making measurements of tissues displaying an area of abnormal pattern or intensity of echoes relative to the appearance of the surrounding section of tissue. As long as abnormalities within a tissue indicative of injury can be identified, then an attempt to measure these changes can be made.

Future observations should consider monitoring changes over time to see how the injury changes. For example, a haematoma may be observed in its fresh state where it will be of a liquid consistency and imaged progressively as it forms a more solid gelatinous mass, thus giving an appreciation of how changes in tissue property affect the appearance with ultrasound. Another factor would be to consider the massaging effect of movement and how this may alter the distribution of an injury. Tissue was observed in a constant position and it may be that movement will extenuate any fibre disruption and make injuries more visible or equally, less visible. Another approach to creating injury models is to replicate the whiplash injury mechanism. Injury could be induced using a materials test machine to replicate the forces of injury which could result in a rupture. This approach to replicate the injury mechanics of a whiplash event may provide a more realistic model of how the tissue fibres behave when stressed.

## Experiment 2: Quantification of a synthetic simulation of a soft tissue injury

### *Background*

The first experiment of this chapter has shown that it is possible to create models that simulate the ultrasound appearance of soft tissue injuries. To identify a method to quantify soft tissue injuries, a model is the ideal starting place as the dimensions and volume of the injury may be controlled. The 'Diasus' equipment used in this study is unable to formulate three-dimensional images and therefore volume must be calculated from two-dimensional information. Volume is a parameter that is simplest to calculate when dimensions are consistent; for example, it is easier to calculate the volume of a regular shape than an irregular shape. This experiment aimed to identify a methodology to quantify the dimensions of an injury as in the clinical situation, a technique is needed that can record and monitor the pathology identified during a scan.

### *Method*

Lesions were first simulated in synthetic materials prior to biological tissue; as the synthetic material chosen was more inert than a biological tissue that could be deformed. The premise being that simulation in the synthetic environment can be achieved with much more precision. To simplify quantification, a regular lesion was chosen. Although it is very unlikely that a real injury would be regular, this experiment aims to test a methodology that could be used for quantification purposes. These injury simulations did not aim to produce accurately an injury that would be found *in vivo* but to provide a region of irregularity in an otherwise homogenous structure that could then be quantified and possibly be of a likeness to a real injury. A cube and spherical shaped lesion were considered.

### *Quantification of a cube*

The synthetic material chosen to represent soft tissue was dense sponge. Although ultrasound was unable to penetrate beyond 5mm, when a region of sponge is removed, this area appears as an identifiable anechoic region and the sponge beyond the hole is visualised again to a depth not beyond 5mm. A region approximating a 1cm cube was removed to replicate the presence of a lesion (*fig. 68*). This size lesion was chosen as it was within the viewing window of the transducer thus facilitating measurement. It was not possible to precisely remove this volume due to the nature of the material; however, this approximation of volume gave an idea of the extent of the lesion. The hole was filled with gel to couple the transducer to the sponge. The lesion was scanned in both longitudinal and transverse orientations to capture images of all dimensions. These dimensions were measured with the line measurement on-screen tool. To assess the volume, the equation to calculate the volume of a cube (length x width x height) was calculated for each of the ultrasound measurements to give the volume and comparisons were made between these volumes to identify the consistency of quantifying the lesion. The cube was imaged in both transverse and longitudinal scans. Five image captures were made for both transverse and longitudinal. For each capture, measurements of the dimensions were made three times. The cube volume was calculated for each set of measurements and the average volume calculated to minimise errors introduced at image capture and during measurement.



**Figure 68: Synthetic lesion simulation (Part 1)**
Cube approximating 1cm$^3$ removed from sponge.

*Quantification of a sphere*

The diameter of a table tennis ball was measured using digital callipers and was found to measure 38mm. Using the equations for a sphere, the circumference was calculated as 119.4mm with a volume of 28730.9mm$^3$. The table tennis ball was embedded into gelatine to provide a contrast medium (*fig. 69*). A scan was taken in transverse orientation; and the point at which the circumference appears greatest was taken as the actual circumference and then used to calculate the volume. Five image captures were made of the table tennis ball, and for each three measurements of the circumference were made. The average circumference was calculated from these measurements and compared to the gold standard measurement taken of the actual table tennis ball to determine the accuracy of this measurement technique.

As an alternative method to calculate the volume, when scanning in transverse orientation, the point at which the ball first appears and then disappears can be measured and this will give a value of the diameter. Fifteen measurements were made of this and compared for consistency. This method also assesses the approach for accurately measuring lesions that extend beyond the field of view.

**Figure 69: Synthetic lesion simulation (Part 2)**
Table tennis ball embedded in gelatine.

***Results***

The outline of a cube lesion was clearly visualised using ultrasound (*fig. 70*). The average volume of the cube from dimensions measured on screen was 1085mm$^3$ (SEM = 19.8). This result shows that the volume of the lesion was consistently measured the described technique.

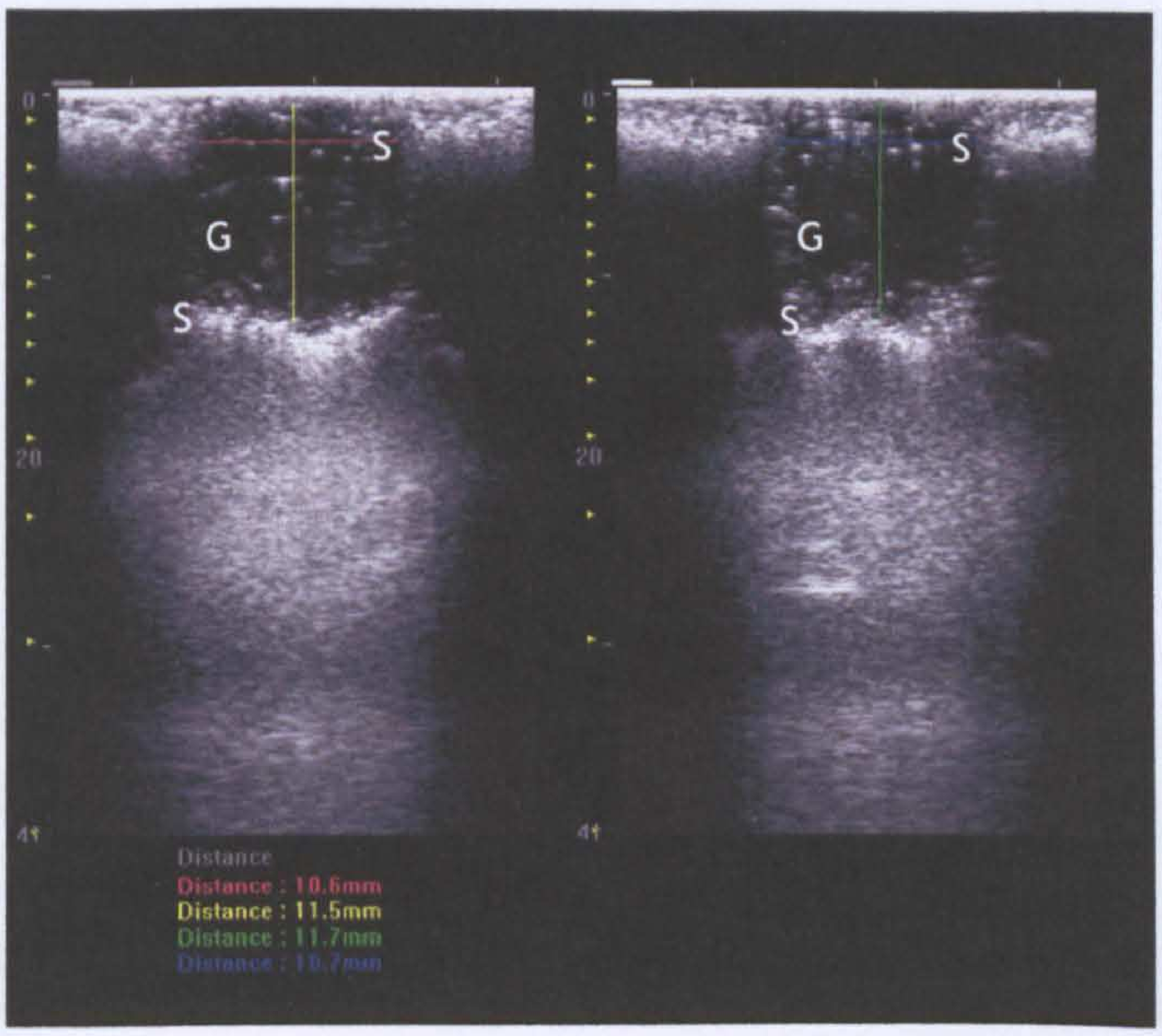

**Figure 70: Ultrasound of synthetic lesion in sponge**

Transverse (left) and longitudinal scan (right)
(S = sponge, G = gel)

For measurement of a sphere, the field of view was not large enough to accommodate the circumference of the ball; this information had to be extrapolated by positioning the ellipse measuring device on the available image and assuming its dimension by visual extrapolation (*fig. 71*). Should the field of view be large enough to accommodate the table tennis ball, the acoustic properties of the ball do not permit the ultrasound waves to pass through the ball and therefore a complete circle could not have been imaged, although the extent of the diameter would be apparent.

**Figure 71: Ultrasound of spherical synthetic lesion**

Transverse scan
(T = table tennis ball, G = gelatine)

The table tennis ball replicated a spherical lesion with unclear margins. The acoustic properties of the ball did not permit the ultrasound waves to pass through the ball and only part of the ball could be seen. From the information available, extrapolation was carried out using the on-screen elliptical measuring device and fitting the ellipse to the visible border to determine the circumference of the lesion. Using the measurements obtained using ultrasound the following equations were performed:

Equations for a sphere:

Volume = $4/3 \pi r^3$

Circumference = $2\pi$ radius

Diameter = $\frac{\text{circumference}}{\pi}$

The circumference of the ball measured with digital callipers was 119.4mm with a diameter of 38mm and a calculated volume of 28730.9mm$^3$. Using ultrasound to calculate the circumference of the table tennis ball, the average circumference measured was 116.9mm with a calculated volume of 26976.9 ± 0.81mm$^3$ (mean ± SEM = 0.81). Measurements made of the sphere using ultrasound following the extent the sphere, measured the diameter to be 43mm ± 0.92mm (mean ± SEM).

### *Discussion*

Synthetic simulation of soft tissue injuries provides a phantom of known size that can be used to assess the method of a quantitative technique. A drawback to this experiment is that it is not possible to remove precisely a volume that represents the lesion and errors will be introduced. Errors made on linear measurements will be multiplied when volume is calculated. Other approaches considered to calculate the actual volume of the phantom lesion included displacement of water measurements however, the materials used in this study are permeable to water and this approach would not work. Although the volume calculated using ultrasound measurements was not precisely indicative of the simulated lesion volume, measurements were close to the expected measurement and there was a high level of consistency between measurements. The results obtained show this to be a viable technique. If the extent of the region of interest in transverse and longitudinal scans can be identified and subsequently measured, then the volume can be calculated for these regular structures. If the region of interest exceeds the scan head then external measurements need to be made. For regular shapes such as a cube or a sphere, equations can be used to calculate the volume and thus quantify the injury. For irregular objects, assessment is open to errors in calculation due to complications collecting lesion dimension information. In the case of the sphere where diameter measurement was taken to be the distance between the point where the sphere appeared and disappeared, elevational resolution may have caused an incorrect measurement to be made. Elevational resolution is the ability to distinguish between reflectors and structures separated along a line that is perpendicular to the ultrasound image plane, and this could be a contributing factor to error. Ultimately the lesions the author is interested in quantifying are found in biological tissue where the injury could be any irregular shape. In addition, in the biological environment the tissue is not homogenous and subject to dynamic changes which will influence the appearance of the lesion. Therefore, quantification of lesions in biological tissue using this measurement technique must be separately assessed.

Measurement of the sphere shows that for lesions that exceed the scan head size, the starting point and end of the lesion can be determined. These points are determined when the lesion comes into view, which is evidenced by the change of appearance of the lesion when compared with the surrounding material. Measurements can be made externally at the points of visible change to acquire dimensions.

## Experiment 3: Quantification of an organic simulation of a soft tissue injury

### *Background*

This experiment followed on from the synthetic injury model by repeating the premise of the previous experiment but this time the sponge was replaced with animal tissue; thus providing a more realistic simulation. Soft tissue is a dynamic structure; it changes shape with movement and tension in the tissue. Other structures may push on one another and disturb shape, orientation and position. Unlike the synthetic materials used in previous models, the architecture of soft tissue is not homogenous. All of these factors influence the ultrasound appearance. It was therefore necessary to repeat quantification of simulated injuries on biological tissue to assess the feasibility of quantification.

### *Method*

See method for 'Experiment 2: Quantification of a cube'. For the reasons explained in Experiment 2, removal of an exact 1cm cube of tissue is not possible (*fig. 72*).

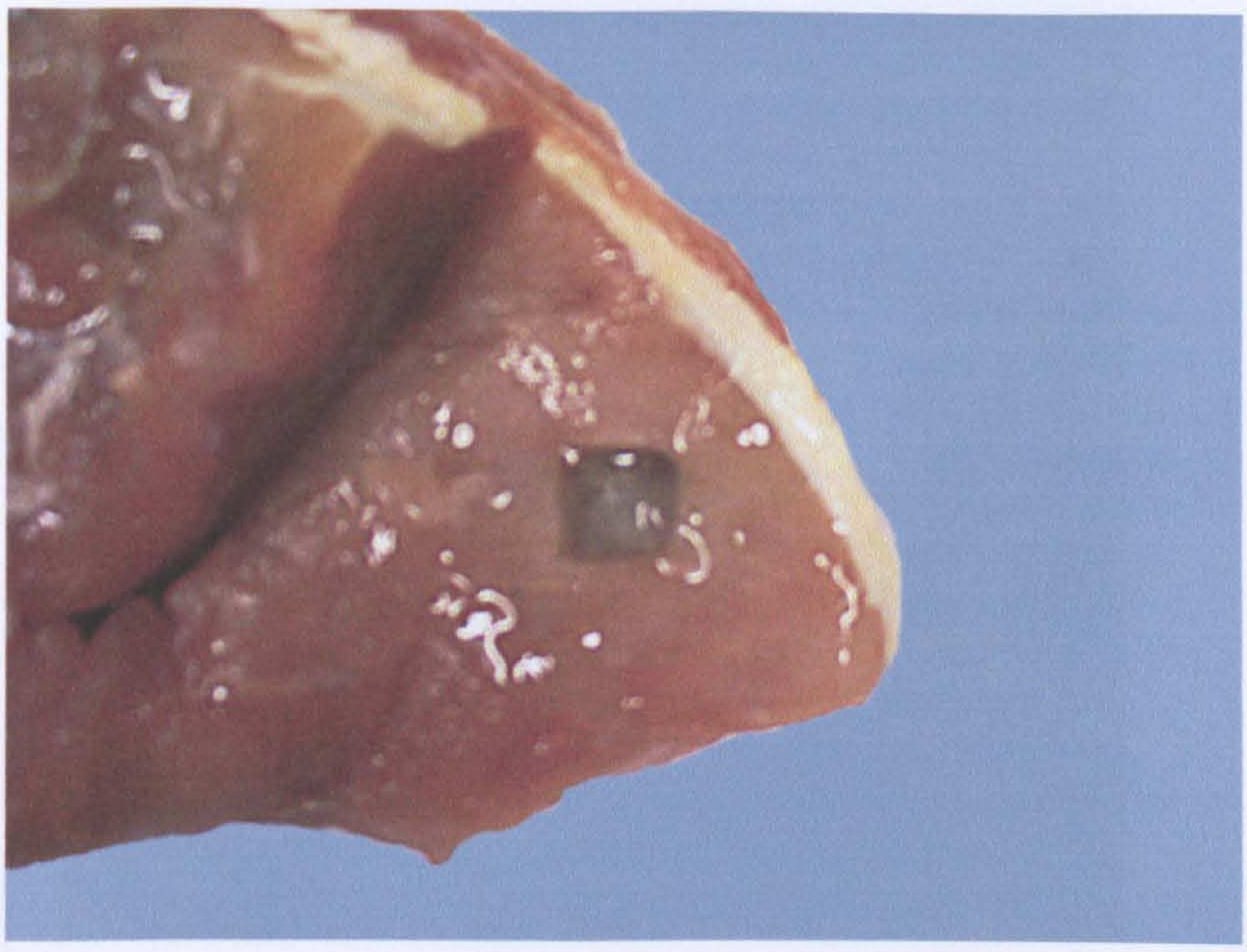

**Figure 72: Organic lesion simulation**

Cube approximating 1cm$^3$ removed from muscle.

***Results***

A cube shaped lesion was clearly visualised in biological tissue using ultrasound (*fig. 73*). Measurements of lesion dimensions using transverse and longitudinal scans; enables the lesion volume to be calculated. The average volume of the cube was calculated to be 1183.2 ± 22.1mm$^3$ (mean ± SEM) which represented well the 1cm cube of tissue that had been removed with a repeatability of better than 2%.

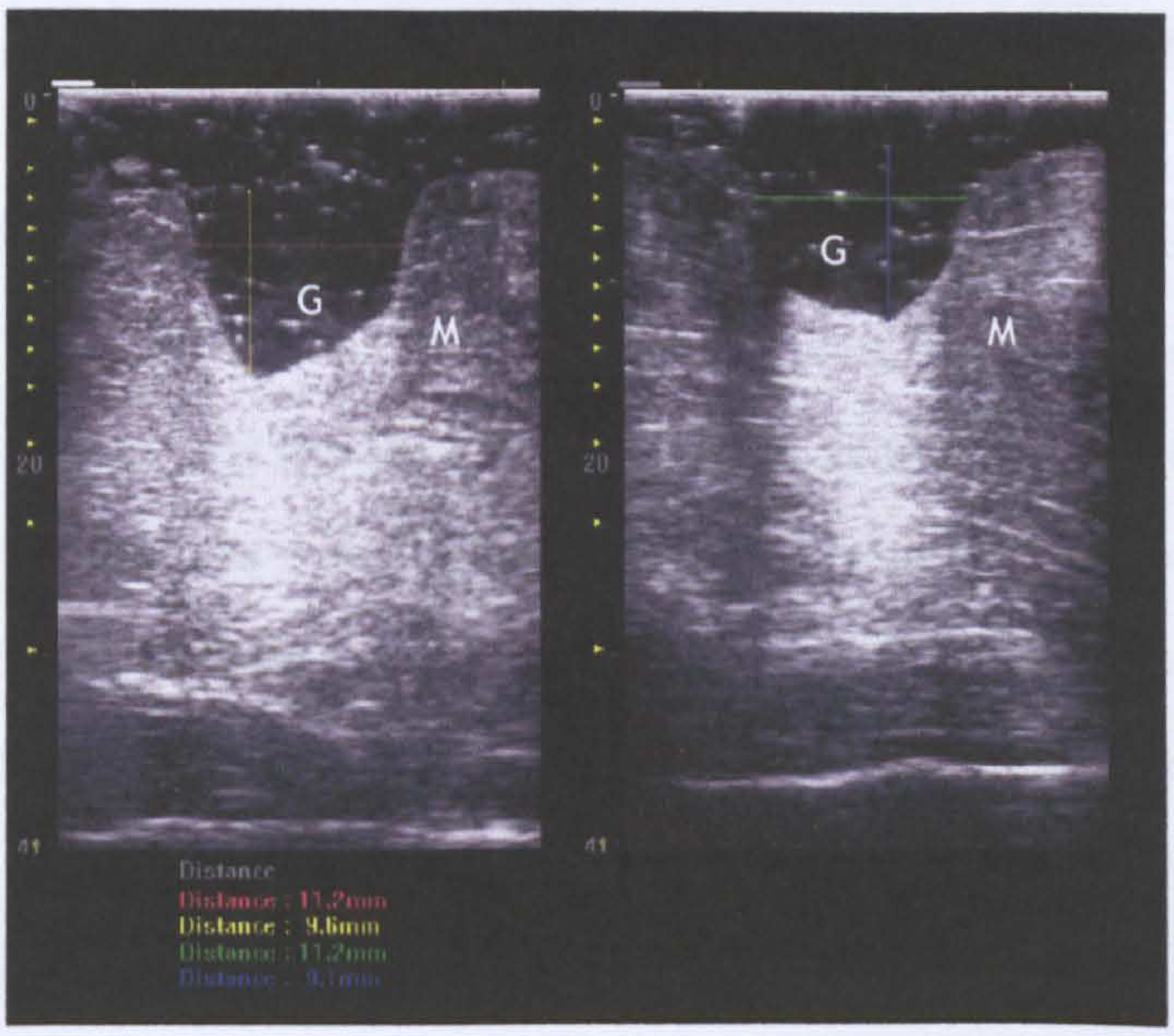

**Figure 73: Simulated cube lesion in muscle tissue**

Transverse (left) and longitudinal scan (right).
(M = muscle, G = gel)

***Discussion***

As for the previous experiment, exact introduction of a 1cm cube was not possible and therefore quantification results could only be compared for repeatability of the measurement. The measurements on ultrasound represented well the character of the lesion. The results from this study demonstrate that the volume of an organic lesion can be calculated with reasonable reproducibility if dimensions are known. The tissue was in a constant state which simplified the task of quantification. It is likely that movement will affect the appearance of this structure and therefore a consideration for diagnosis is that subjects should be imaged in the same position from one assessment to the next. For a future study, a method to consider for quantifying the size of the simulated lesion would be to fill the lesion with fluid and measure this volume. This volume of fluid could then be compared to the ultrasound measurements.

## Experiment 4: The effect of inter/intra observer variability on quantification

### *Background*

The effects of the operator's experience and interobserver and intraobserver variability have been discussed (*see Chapter 2*). This experiment assessed the different measurement facilities of the 'Diasus' and the operator's ability to use them. The integral measurement options of the 'Diasus' were investigated and these included line measurement, a freehand trace, and a predefined ellipse. How these devices work has been discussed previously (*see Chapter 2*). The success of these measurements was assessed by comparing to the gold standard of an external measurement of the cross-section area of the tendon which was obtained using digital callipers.

### *Method*

Operators were divided into groups based on their experience of using ultrasound equipment.

- *Expert group*: this group consisted of two consultant radiologists
- *Advanced group*: this group consisted of two researchers experienced in using diagnostic ultrasound for research of the musculoskeletal system
- *Novice group*: two engineering technicians with no experience of using ultrasound

### *Sample tissue*

The tissue sample used in this study was a porcine deep digital flexor tendon of the foot (*fig. 74*). Tendon provides a biological tissue with a structure consistent in shape at rest and clearly discernable from the surrounding tissue. To aid identification of the tendon on the image display, ultrasound gel was applied to surround the tendon as this enabled greater contrast between the tendon and surrounding tissue to be seen.

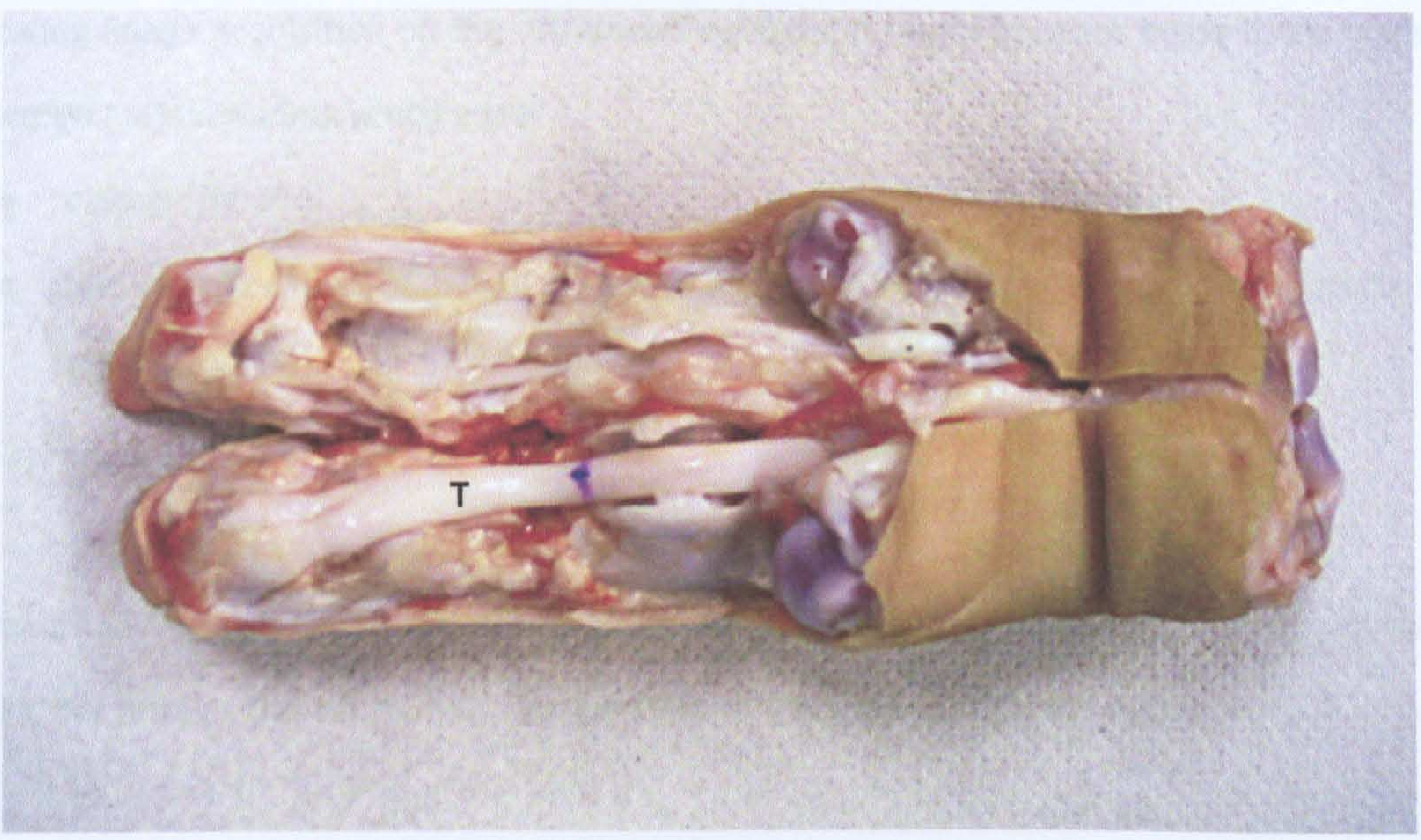

**Figure 74: Porcine tendon**
Posterior view
(T = tendon)

*Procedure*

One of the advanced operators made ten blind digital calliper measurements of the tendon cross-section area before and after testing to ensure the cross-section was consistent and had not been affected by dehydration or deformation. The average of the calliper measurements was taken to be the gold standard for the tendon cross-section area (CSA). To prevent dehydration of the tendon and subsequent changes in diameter, the tendon was kept moist. The tendon was marked with a tissue pen where images were to be taken. This ensured that all measurements taken with the digital calliper and by the operators using ultrasound were made at the same point. All measurements were made on the same day using the same sample. The operators were familiarised with the equipment. The experiment was explained to all operators and included; where the transducer was to be placed in a transverse orientation and how the tendon could be identified on ultrasound and then how to capture the image.

Following image acquisition on the ultrasound equipment, each operator made three types of on-screen measurements which were:

- ellipse (*fig. 75*)
- line measurement of height and width (these values will be used to calculate the tendon CSA) (*fig. 76*)
- trace (*fig. 77*)

To avoid any influences on the results, the operator was blind to the measurements taken during the test, as the information displayed on the monitor was covered over.

*Data capture procedure*

The operators performed the routine outlined below. The results from each type of measurement were averaged to minimise errors introduced at image capture and during measurement.

Capture image and make:
1 x ellipse measurement
1 x line measurement
1 x trace measurement
Repeat measurements twice more.

Recapture image:
1 x ellipse measurement
1 x line measurement
1 x trace measurement
Repeat measurements twice more.

Recapture image:

1 x ellipse measurement

1 x line measurement

1 x trace measurement

Repeat measurements twice more.

### *Results*

Using the digital callipers, the tendon cross section area was determined to be 13.3mm$^2$. This value was used as the gold standard and was compared with the results of the measurements made by the operators using ultrasound.

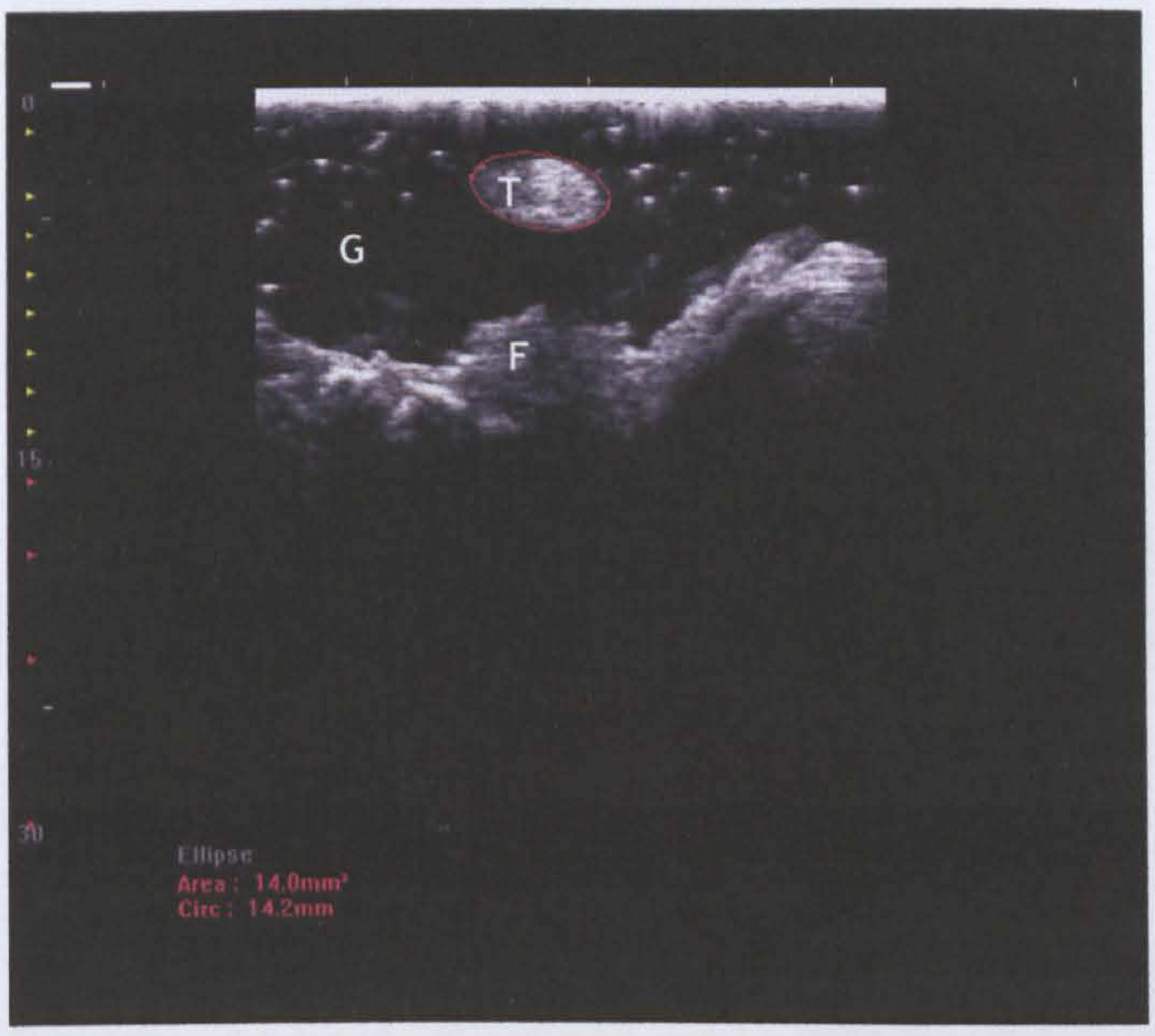

**Figure 75: Ellipse measurement**

Transverse scan
(T = tendon, G = gel, F = foot)

**Figure 76: Line measurement**

Transverse scan
(T = tendon, G = gel, F = foot)

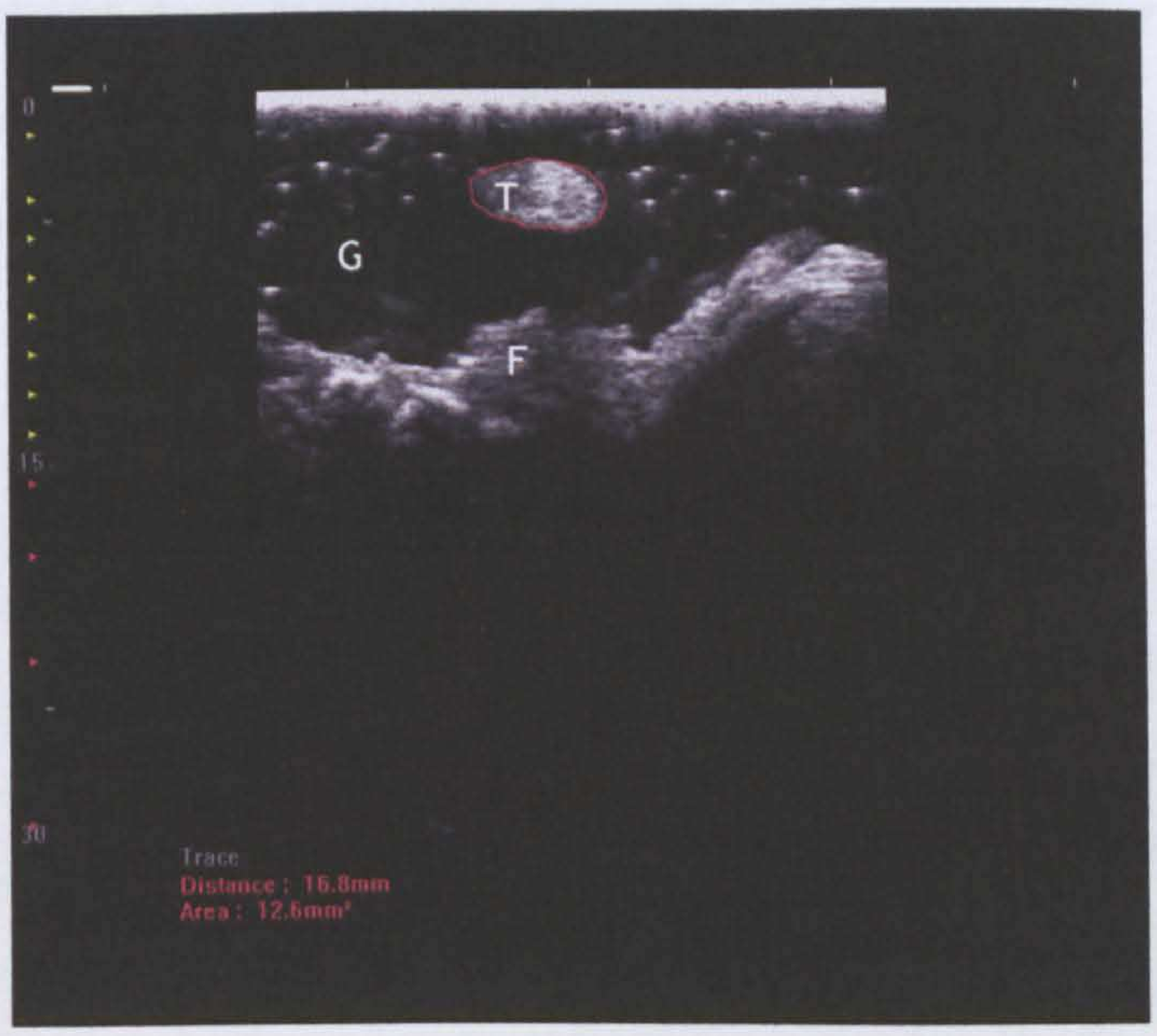

**Figure 77: Trace measurement**

Transverse scan
(T = tendon, G = gel, F = foot)

The statistical test used with the operators' results was a balanced ANOVA (ANalysis Of VAriance) which assessed the factors of operator, method and capture (where SE = standard error, ASD = absolute squared discrepancy):

Summary statistics for operator:

| Operator | Mean discrepancy (SE Mean) | Mean ASD (SE Mean) |
|---|---|---|
| Expert 1 | 2.094 (0.164) | 5.081 (0.737) |
| Expert 2 | 1.019 (0.217) | 2.264 (0.382) |
| Advanced 1 | -0.288 (0.209) | 1.214 (0.339) |
| Advanced 2 | 0.415 (0.142) | 0.693 (0.193) |
| Beginner 1 | 0.072 (0.141) | 0.525 (0.141) |
| Beginner 2 | 0.719 (0.257) | 2.240 (0.322) |

Assuming that the gold standard measurement of 13.3cm$^2$ is correct, Beginner 1 and Advanced 2 are getting the closest mean discrepancy. Advanced 1 on average underestimates the cross section area whilst Expert 1 greatly overestimates the cross section area. When the mean absolute discrepancy is observed, Beginner 1 and Advanced 2 do best with Expert 1 being least accurate.

Summary statistics for method:

| Method | Mean discrepancy (SE Mean) | Mean ASD (SE Mean) |
|---|---|---|
| Ellipse | 0.719 (0.170) | 2.041 (0.381) |
| Line | 0.236 (0.184) | 1.859 (0.362) |
| Free | 1.061 (0.136) | 2.109 (0.366) |

The line method appears to be best in terms of both statistics.

Summary statistics for capture:

| Capture | Mean discrepancy (SE Mean) | Mean ASD (SE Mean) |
|---|---|---|
| First | 0.379 (0.163) | 1.558 (0.228) |
| Second | 1.138 (0.192) | 3.239 (0.519) |
| Third | 0.499 (0.135) | 1.211 (0.213) |

The capture statistics suggest that operators do better on their first and third go than on their second.

The ANOVA test suggested that all three factors are highly significant. Both the advanced operators and one of the novice operators were found to measure the ultrasound image closest to the gold standard with one of the expert operators being least accurate (*fig. 78*). The measurement method that proved most successful was the line measurement. Statistics for capture suggested that the operators performed better on their first and third attempt than on their second.

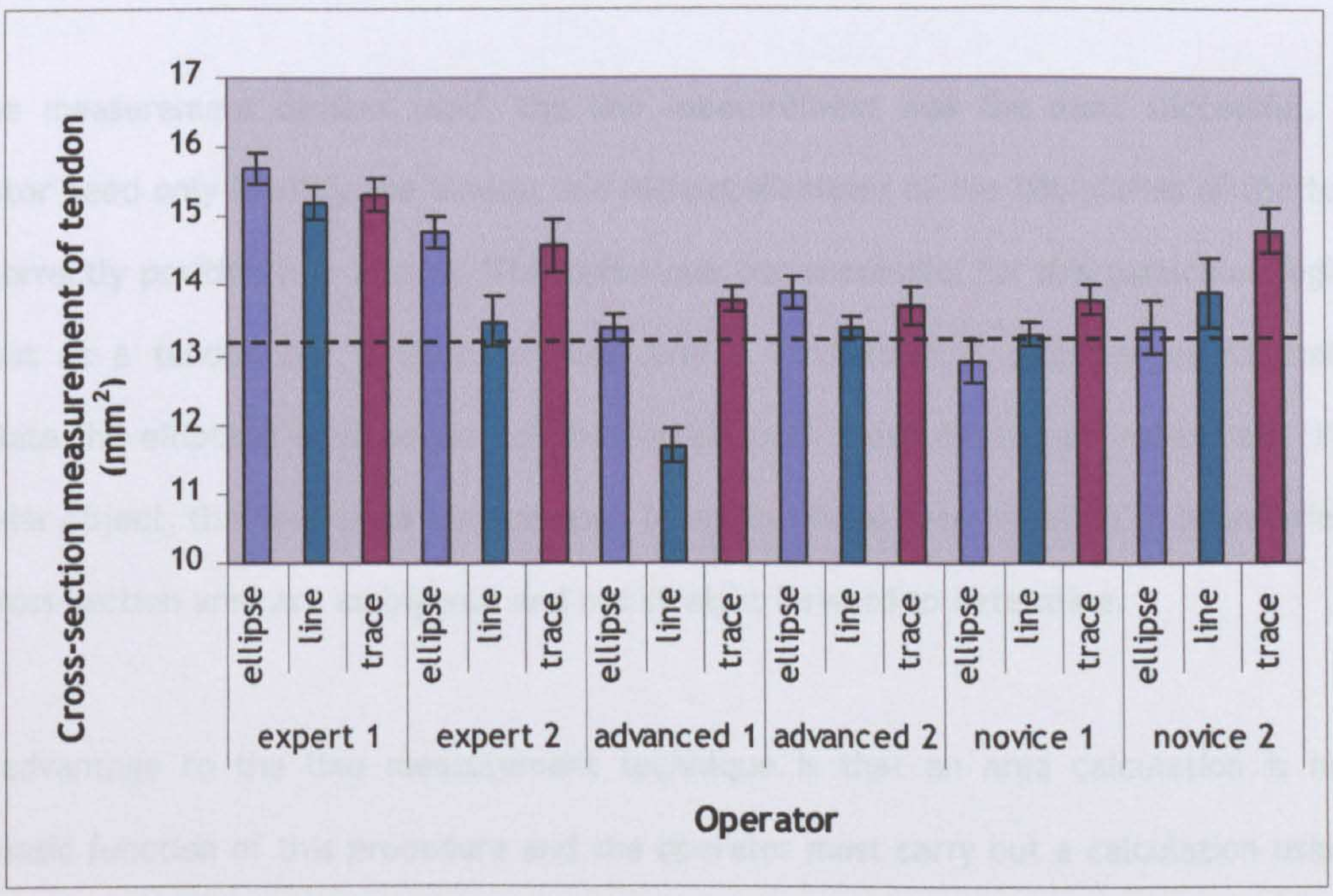

**Figure 78: Measurement method**

Broken line indicates the gold standard of 13.3mm$^2$ (SEM shown)

*Discussion*

The different image measurement tools offered by the 'Diasus' were used by a range of ultrasound operators with different experience and abilities of using ultrasound to measure a cross-sectional area of a tendon of known size. The success of the particular measurement tool, as well as the ability of the operator to perform the task was assessed. It is interesting to note that the measurements made by the novice group were closer to the gold standard than the measurements made by the experts. The occupation of the novice group was technicians in an engineering workshop, and therefore their attention to detail and their ability to make accurate measurements is probably inherent in their normal place of work. This demonstrates clearly that with suitable training, it is possible for a novice to identify correctly the region of interest to be measured, and to make accurate measurements. In this case, the region of interest, the tendon, was clearly defined and presented to the operator. In the real situation of examining a patient with a musculoskeletal injury, the challenge is first to locate and identify the lesion and then to make a subsequent diagnosis. For diagnosis to be effective and accurate requires the operator to have a high degree of knowledge and skill.

Of the measurement devices used, the line measurement was the most successful. The operator need only identify the longest and highest diameter of the boundaries of the tendon and correctly position four points. This technique was successful for this particular region of interest as a tendon has a uniform shape and a mathematical equation exists that can calculate the elliptical cross-section of the tendon from those dimensions measured. For an irregular object, this technique may be open to errors where determination of boundaries and the cross-section area are ambiguous and not straight forward to determine.

A disadvantage to the line measurement technique is that an area calculation is not an automatic function of this procedure and the operator must carry out a calculation using the line measurements; which is both time consuming and subject to error. The other measuring devices are automated and perform the calculation which is displayed on-screen. The ellipse measurement has the advantage that it performs measurement calculations which are displayed on screen, however; it can be awkward to position the tool accurately around the boundary of the tendon and this is where errors may be introduced. The trace measurement would appear to be ideal for calculating the area and displays the measurement on-screen, however; great dexterity is needed to be able to use the trackerball device to trace the region of interest making this time consuming and from experience virtually impossible to achieve an accurate depiction of the boundary.

It is interesting to note that the first and third data capture by the operators yielded a result closer to the gold standard than the second attempt. It is unclear why this would happen, and it may be simply a case of the operators attention span where they may be more cautious at the beginning, over confident for the second capture and take more care for the final capture.

It is feasible that the gold standard is inaccurate. It is possible that the digital callipers will have deformed the tendon during measurement which would account for differences between the gold standard measurement and the ultrasound assessment of cross-section area calculations.

The statistical test of the ANOVA suggests that it matters who takes the measurement, what method they use and what capture attempt they are making. When it came to assessing patients with whiplash, the author made all the measurements. Using this approach, images were assessed at all stages based on the author's criteria which will provide a more reproducible assessment.

## Experiment 5: The effect of magnification on assessment

### *Background*

This experiment investigated how changing the zoom options on the display affected the operator's ability to position correctly the different measurement devices.

### *Method*

Methodology for this experiment was as for Experiment 4; however for this experiment, only one operator, an advance skilled investigator (the author), participated. Measurements were made as before but this time each measurement was taken with the display zoom set at maximum and minimum. It is possible that in an attempt to capture the same image to be viewed on maximum and minimum zoom, that the resulting images will in fact differ. This difference could be caused when the operator alternates between maximum and minimum zoom, as the image is live and slight positioning alterations of the transducer may occur. To minimise this effect, both images were displayed simultaneously on a split screen display to ensure they appeared identical (*fig. 79*).

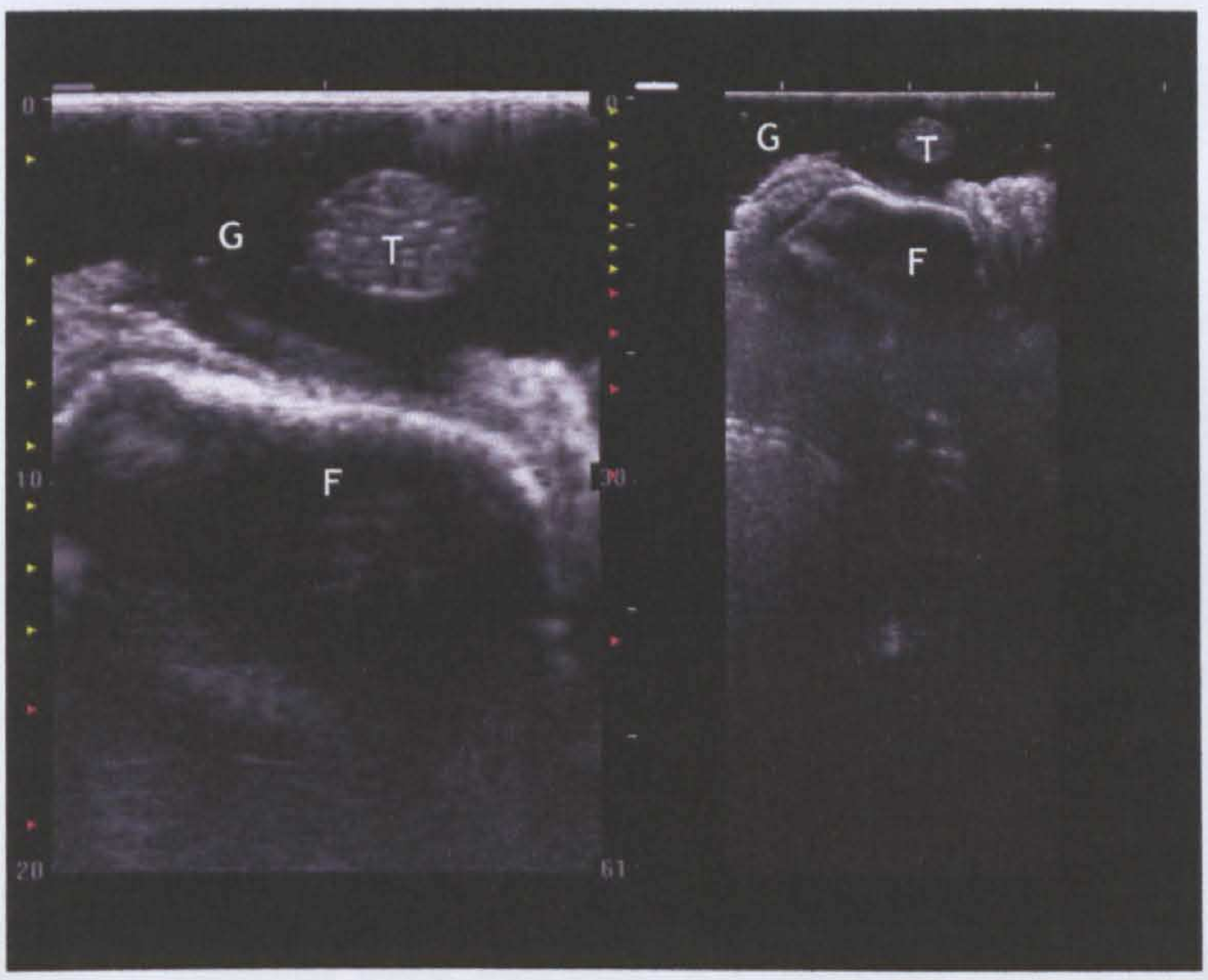

**Figure 79: Magnification effect on tendon measurement**

Transverse scan, maximum magnification (left), minimum magnification (right)
(T = tendon, G = gel, F = foot)

### *Results*

The average digital calliper measurement of the cross-sectional area of the tendon was 13.9mm$^2$. The results for cross-section measurement using different measurement methods on maximum and minimum zoom are displayed in figure 80.

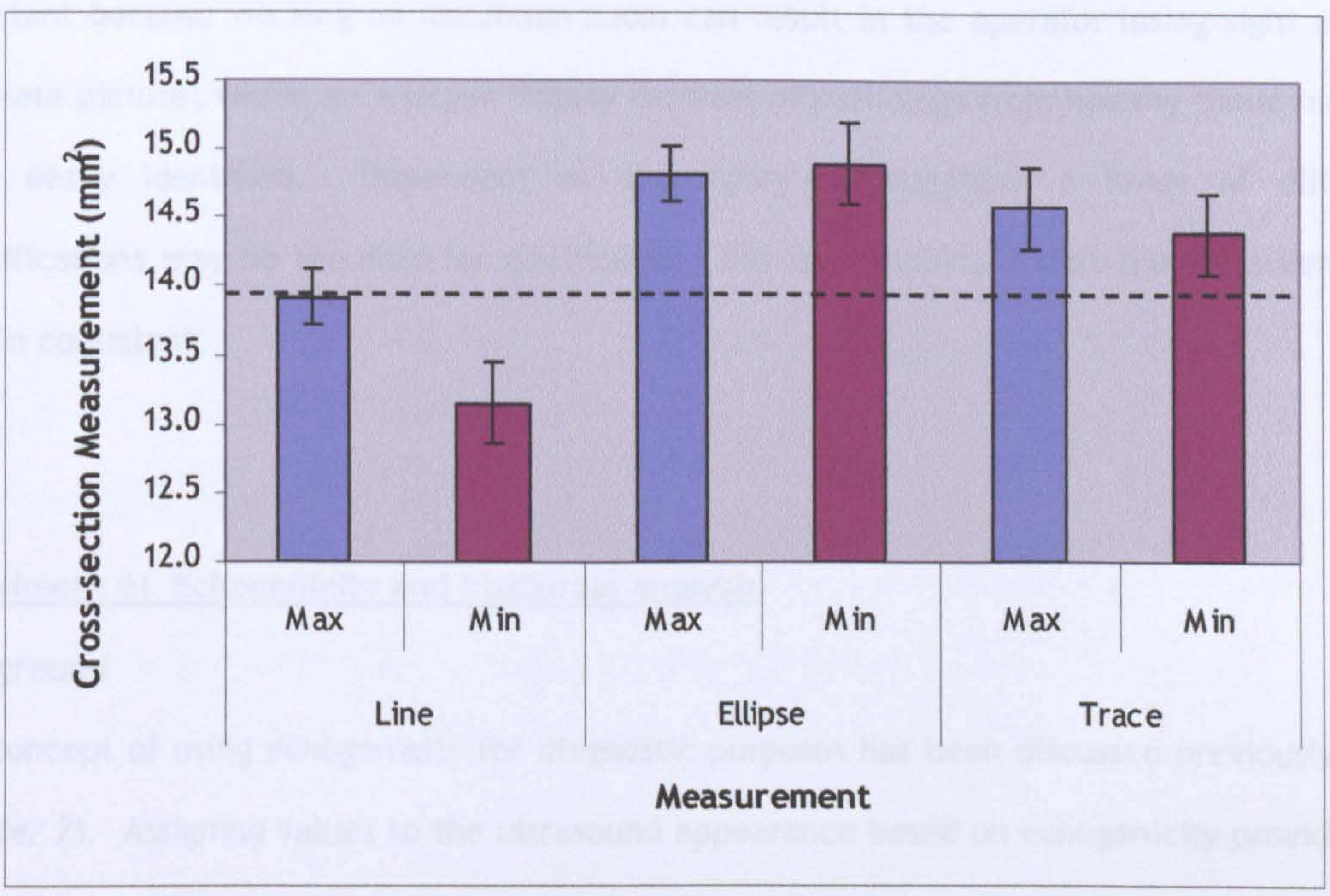

**Figure 80: Maximum and minimum zoom**

Broken line indicates gold standard of 13.9mm$^2$ (SEM shown)

| | Average measurement on maximum zoom | Average measurement on minimum zoom | Percentage difference between max and min zoom |
|---|---|---|---|
| *Line* | 13.9 | 13.2 | 5.0% |
| *Ellipse* | 14.8 | 14.9 | 0.7% |
| *Trace* | 14.6 | 14.3 | 2.1% |

An F-test for variance between using maximum and minimum zoom showed there was no significant difference in the ability of either of these functions to measure the cross-section area. Using the line measurement and calculating the cross-sectional area yielded the closest result to the measurement made with the digital calliper.

***Discussion***

The differences in the calculated area using the maximum and minimum zoom functions are not significant with differences between the two being less than 5% (*fig. 80*). This is important because working on maximum zoom can result in the operator losing sight of the complete picture; where on a larger display contrast of pathology from healthy tissue may be more easily identified. Dependent on the injury investigation, a range of differing magnifications may be required for clarification, but it is important that the measurements remain consistent.

## Experiment 6: Echogenicity and histogram analysis

### *Background*

The concept of using echogenicity for diagnostic purposes has been discussed previously (*see Chapter* 2). Assigning values to the ultrasound appearance based on echogenicity provides an opportunity for a quantitative measurement and may also assist assessment. As echogenicity is the product of many factors, assessment using this technique is susceptible to flaws. The setting of the ultrasound system will affect the echogenicity. Changing these settings within the same area will alter the echogenicity and therefore the image produced. For example, an increase in gain will produce a brighter image and thus change the proportion or range of intensities of the pixels in the grey scale. The following experiments assessed the feasibility of diagnosis using echogenicity by identifying how the system settings affect the echogenicity of the sample and consequently image analysis. Echogenicity to assess damage was considered as an alternative to measuring dimensions of pathology.

### *Method*

When scanning, it is important to keep the transducer perpendicular to the structure of interest to minimise the effect of anisotropy (*see Chapter* 2).

To assess echogenicity and provide an objective method to analyse grey level statistics, histograms were formulated. The histogram profiles were compared. Histograms can be assessed on parameters such as mean grey level, standard deviation, grey sum, minimum and maximum grey level value, and skewness and kurtosis of the histogram. Minimum and maximum grey values indicate the range of grey levels in the image. Standard deviation provides an indication of the spread of the grey level values around the mean; skewness and kurtosis are parameters that describe the shape of the histogram.

## Experiment 6a: The effect of ultrasound settings on echogenicity

### *Method*

The sternocleidomastoid muscle was imaged with low and high overall gain (*fig. 81*). Histograms were produced for each setting. Analysis of the image echogenicity using histograms was performed using the image analysis software package Image J.

### *Results*

The histograms produced for the same image viewed with low and high overall gain compensation are markedly different (*fig. 82*). This emphasises the fact that equipment settings must be noted if echogenicity is to be used to assess or quantify the presence of pathology. The histograms display a similar distribution shape but it can be seen that there is a shift to the right as the intensity is increased. This indicates that the profile of the injury will be maintained irrespective of the settings.

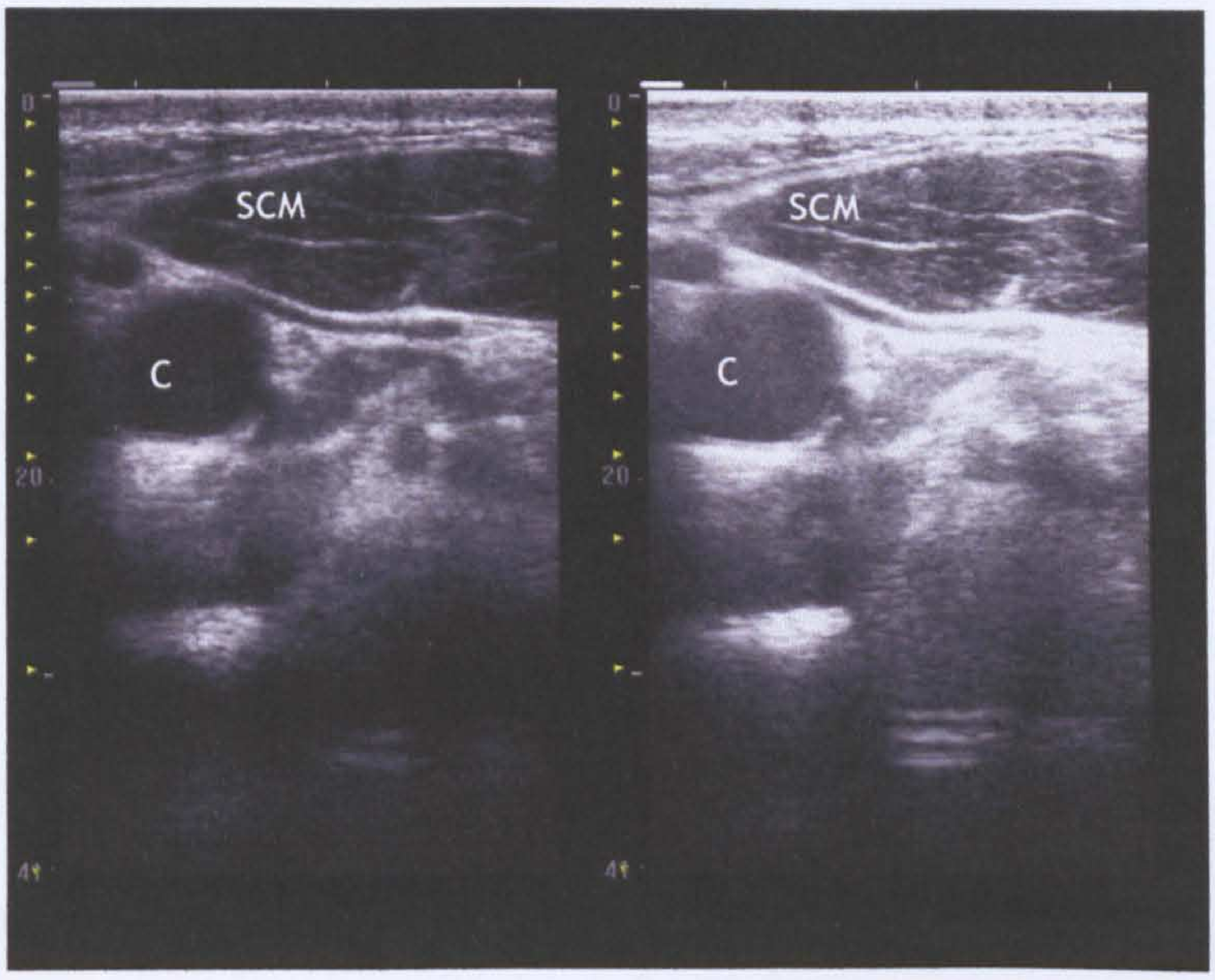

**Figure 81: Scan taken with low and high overall gain compensation**

Transverse scan
(SCM = sternocleidomastoid, C = common carotid artery)

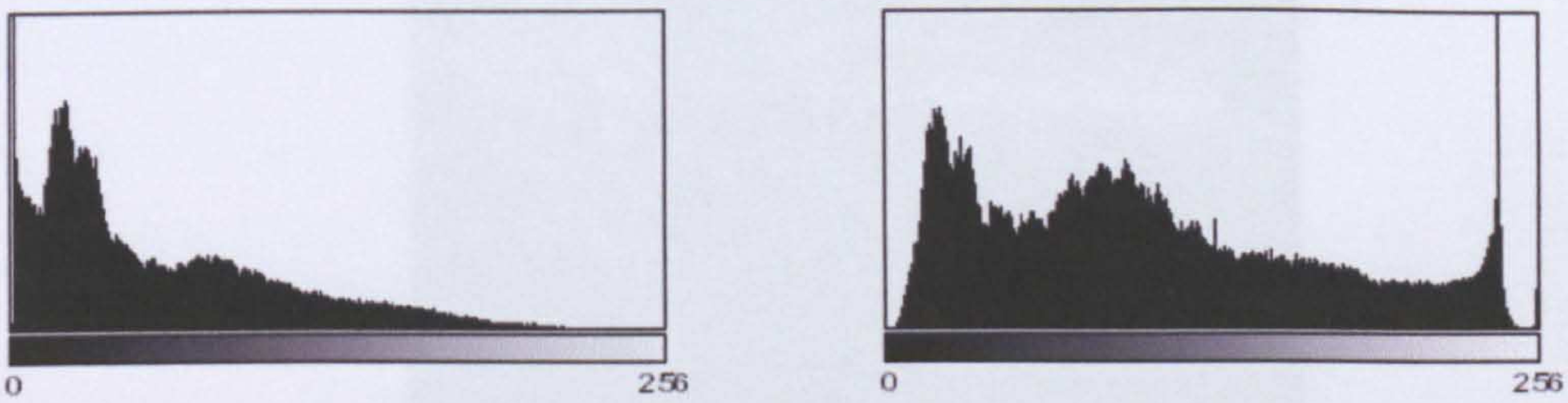

Count: 200480 Min: 0
Mean: 57.303 Max: 246
StdDev: 47.796 Mode: 1 (4794)

Count: 200480 Min: 2
Mean: 103.176 Max: 255
StdDev: 65.753 Mode: 240 (2669)

**Figure 82: Histogram of low and high set overall gain**

***Discussion***

The histograms produced from this image clearly demonstrate the effect of setting on the echogenic appearance of the image. If images are to be compared, it is important to be aware of this. Factors such as gamma correction, patients build, interference from electrical devices will affect the echogenicity.

### Experiment 6b: Using echogenicity to assess pathology

***Method***

The change in echogenicity of a normal versus injured scan was assessed. The ultrasound settings were not altered, and histogram analysis of the tendon haematoma model (as described in Experiment 1) (*fig. 83*) was made comparing the region containing the lesion to the normal region.

***Results***

The histograms clearly show a different result for the histogram of the normal region versus the histogram of the injured region (*fig. 84*).

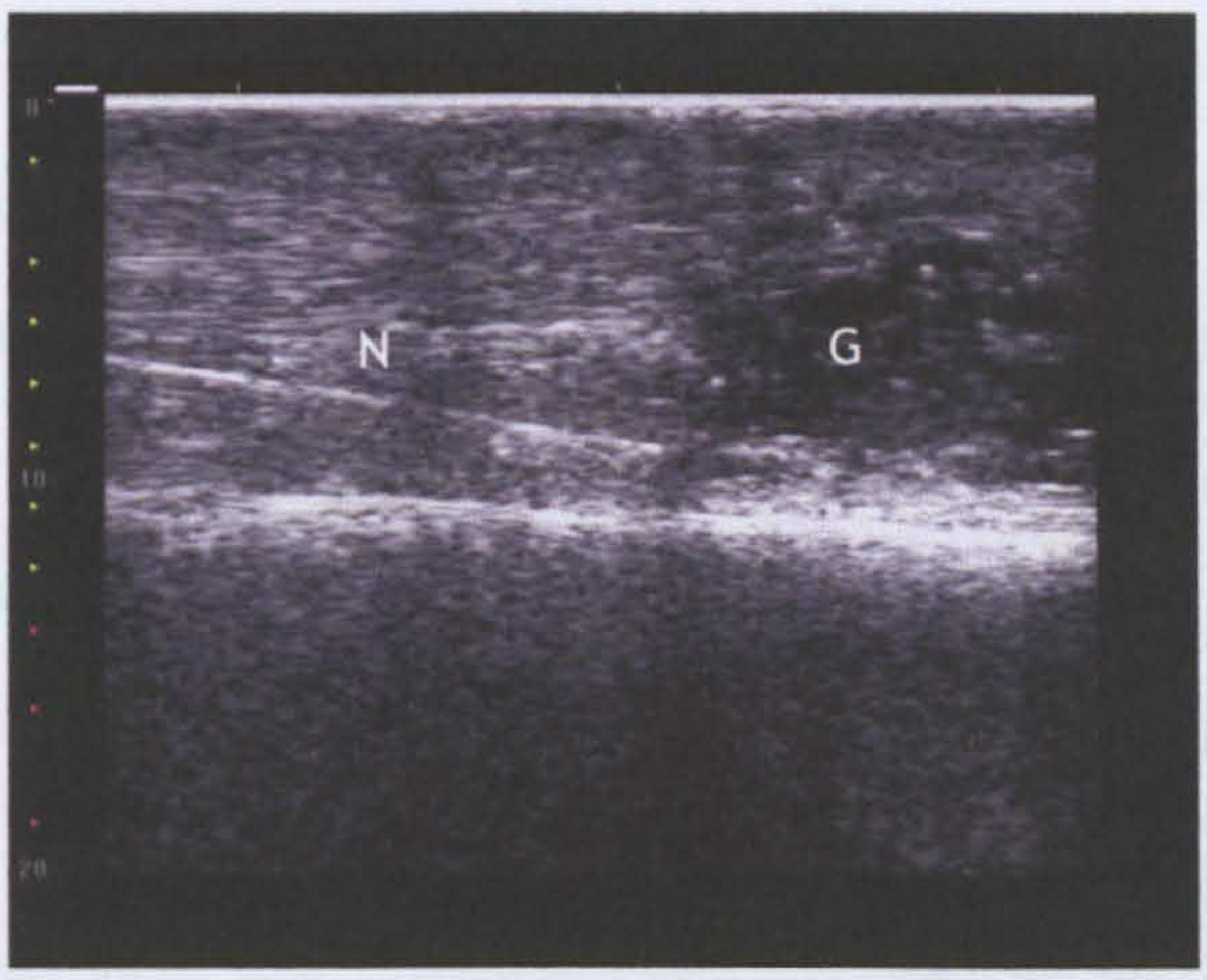

**Figure 83: Haematoma model in tendon**

Transverse scan
(N = needle, G = gel)

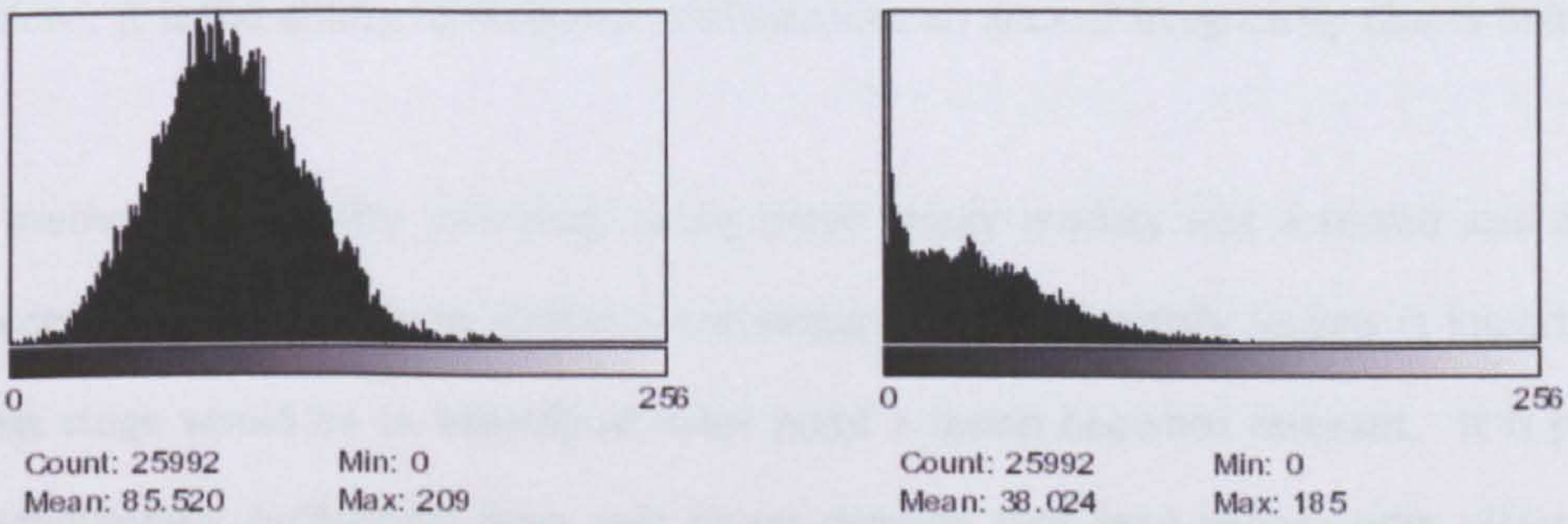

**Figure 84: Histogram of healthy tissue and a haematoma**

Healthy tissue (left), haematoma (right)

### *Discussion*

Haematoma causes an anechoic region visibly noticeable as an increase in the number of black pixels in relation to the surrounding tissue. The normal tissue has a more even distribution in comparison to the injured region which produces a skewed histogram towards the dark region pixels. It is possible that as healing occurs and the region begins to take on its former characteristics, the histogram will replicate that of the normal histogram. Further research is required to establish the normal histogram profile and this can be used for comparison.

## *6.4 Discussion for the Series of Experiments*

Injury models were created and verified from observations of pathology *in vivo*. Although these injury models represented the findings *in vivo*, however, they do not replicate the true injury mechanism. For example, in the case of haematoma and swelling models, a viscous fluid is injected which leads to noticeable fibre disruption. It is possible that the force needed to overcome the resistance causes this disruption. In the real injury event, a different mechanism resulting in fluid production will be occurring. Replication of tears does not take into account how a haematoma is a key indicator that a muscle tear is present. Therefore, if a muscle is torn and the tear is not visible a haematoma may be evident.

It should be noted that scanning was carried out directly onto the tissue surface and therefore ignores the effect of structures such as skin and fat. This does not invalidate the findings as comparison of the tissue compared to *in vivo* finds the soft tissue well replicated; as stated before, it is the ability to recognise and measure an area of irregularity that is being assessed.

A method to quantify pathology using these injury models was assessed and found to be successful. The ability to define a technique that can quantify lesions is important but the next stage would be to identify at what point a lesion becomes relevant. It is possible that asymptomatic individuals have soft tissue damage that may appear with ultrasound but it needs to be determined at what point this damage can be classified as a problem. Assuming lesions are not present in asymptomatic people and that the soft tissue damage observed in whiplash victims is specific to their injury, the benefits of lesion identification are manifold. Diagnosis of a soft tissue injury provides organic evidence of the pain. Being able to monitor the injury over time would be useful in determining the pathoanatomy of whiplash and identify if a different healing process or disturbance occurs in those that suffer long term. Monitoring may help recognise a healing process and equally, deterioration; thus allowing the necessary course of corrective action to be implemented. Ultrasound may prove useful as a means for assessing the healing process and the problems associated with healing such as fibrosis, haematomas, or myositis ossificans as well as the success of treatment strategies.

An alternative method for recording observations of lesions in whiplash patients is to make a qualitative assessment. It is common practise in the field of radiography not to make quantitative measurements as there are many pitfalls with this process (Mark Batt personal communication 2003, Robert Kerslake personal communication 2004, Paul Morgan personal communication 2004). The consensus of radiologists is that it is not necessary to quantify lesions as precise measurements are impossible to obtain; also, lesion characteristics have not been correlated with the severity of the problem. The standard practise is to make a rough measurement of the lesion that provides a reference for future assessments and gives an idea of size. Another practise for analysing images is to use visual scales; such as an assessment for a region would be defined as either small, medium or large. The image may also be graded by the severity of damage and how confident the radiographer is of the existence of pathology.

Currently, techniques are being developed that enable the quantification of the mechanical behaviour of tissue using speckle tracking and elastography techniques (Revell *et al.*, 2003, Revell *et al.*, 2004). (*see Chapter* 2). These measurements of changes in mechanical deformation have the potential to provide an indication of pathology. Future studies could assess if a characteristic change in deformation is observed in symptomatic subjects compared to asymptomatic subjects.

An important factor for consideration is the effect that the operator has on the diagnosis outcome. The operator is relied upon to capture the image that clearly represents the injury and then to carry out the correct analysis. Errors will be multiplied at every stage of the image acquisition and assessment; and it is therefore important for the methodology for assessment to be consistent so that at least a like for like assessment may be made.

*Accuracy of the Diasus ultrasound equipment*

A consideration of quantification is the capabilities of the ultrasound equipment. The on-screen distance measurement function displays measurements to a precision of 0.1mm. 'Diasus' manufacturers recommended that the accuracy of positioning the cursor is dependent on the displayed scale of the ultrasound data. The capability of the transducer to discriminate between closely positioned points is dependent on the transducer frequency and hence resolution but is not considered to be the limiting factor when taking measurements. Area measurements are displayed to 0.1mm$^2$. The ellipse and trace measurements are dependent on the distance measurement accuracy. In all cases, the error with an experienced operator is less than plus or minus 5%. The manufacturers state that the measurable resolution of the 'Diasus' is 0.05mm.

Based on the results of this series of experiments to assess whiplash patient injuries, if it is not possible to calculate the volume of a lesion; an assessment of the area the injury spans may be taken and recorded. A visual assessment and description of the ultrasound image of the injury will be included with all assessments. It is important to identify if those regions indicative of a soft tissue injury correlate with the patient's symptoms.

## 6.5 Chapter Discussion

It was necessary to develop a method that would enable a quantitative evaluation of any pathology identified using ultrasound on patients presenting with a whiplash injury. The experimental work conducted in this chapter has identified a method to achieve this. Injury models were initially created and used as a basis for investigating quantification techniques for soft tissue injury. Application of this technique to biological tissue has been considered and although not an error proof technique, it will be used when assessing patients presenting with whiplash. This technique enables collection of quantitative information regarding the extent of pathology, which may be used as a reference when the injury is reviewed later. The effect of equipment and operator on diagnostic assessment have been considered and found to be consistent and limitations have been identified.

# Chapter 7: Facet Joint and Intervertebral Disc

## *7.1 Chapter Summary*

This chapter discusses the ultrasound appearance of the bony structures of the cervical spine and a technique to view them. In addition, it assesses the use of ultrasound as an imaging modality for needle guidance in interventional procedures of the cervical spine.

Project objectives fulfilled in this chapter:

- study the ultrasound appearance of bony structures

## *7.2 Background*

In addition to soft tissue damage, several structures of the bony cervical spine have been postulated as a source of injury as a result of whiplash. Those structures being considered are cervical facet joints and discs (*see Chapter* 2). Ultrasound investigation of the bony cervical spine has been limited and imaging of the cervical facet joints and intervertebral discs for clinical assessment is traditionally achieved using plain radiography, computed tomography and magnetic resonance imaging (Kendall 1998). Ultrasound has been used to identify vertebrae and disc in the lumbar region (McNally *et al.*, 2000; Naish *et al.*, 2003) and measurements have been made in the changes in distances between the lumbar vertebrae (Ledsome *et al.*, 1996). It is possible that similar measurements could be carried out on the cervical region; and assessments made on the structure quality and measurements made to see if they could be used to indicate pathology.

Cervical facet joints (Goldthwait 1911; Steindler and Luck 1938) and intervertebral discs have been highlighted as a potential source of pain (Cloward 1959). Interventional procedures associated with these structures include steroid injections into these joints which have offered relief to some symptomatic patients (Barnsley and Bogduk 1995) (*fig. 85*) and pain provocation tests such as cervical discography have been used to confirm pain of discogenic origin and enable radiographic visualisation by the injection of an opaque solution (Cloward

1959) (*fig. 86*). Both procedures require radiographic imaging to locate the injection site. Ultrasound imaging is not routinely used for these procedures although, ultrasound imaging is utilised for a variety of needle guidance procedures including tissue biopsies (Lindequist *et al.*, 1990; Schwartz and Feig 2002) and fluid aspiration (Schwartz and Feig 2002). Ultrasound guided facet joint injections were found to be successful in equine cadavers (Nielsen *et al.*, 2003; Mattoon *et al.*, 2004).

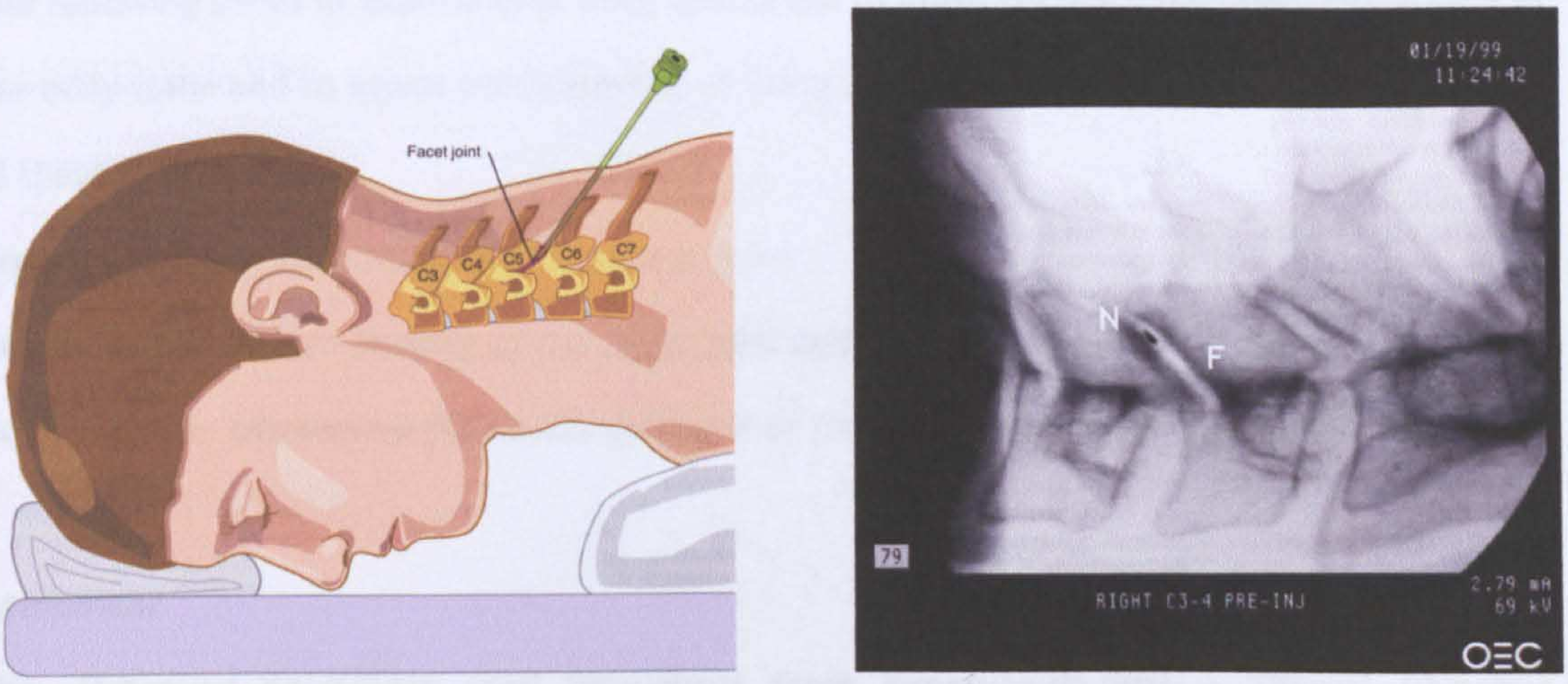

**Figure 85: Facet joint injection guided by computed tomography**
(N = needle, F = facet joint)

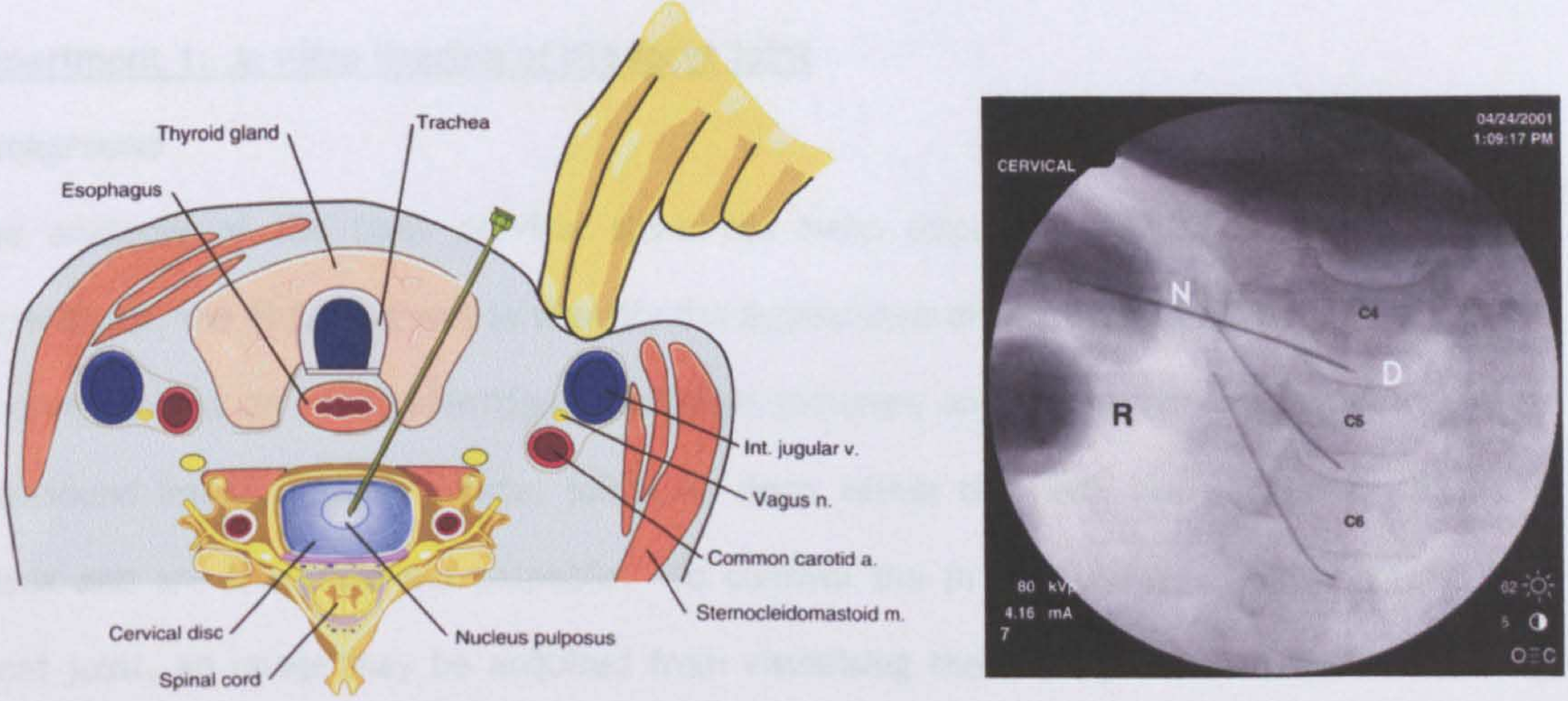

**Figure 86: Discography guided by fluoroscopy**
(N = needle, D = disc, C4 - C6 = cervical vertebrae)

## 7.3 Series of Experiments

The anatomy of these structures has been discussed previously (*see Chapter 2*). Both a transducer position to visualise these structures and the feasibility of using ultrasound in conjunction with interventional needle guidance were considered. Standard procedures for the injection of these techniques exist and therefore it was essential to assess if the transducer could visualise the needle in these positions.

The following series of experiments were conducted to illustrate the ultrasound appearance of the bony spine and to assess the feasibility of using ultrasound for needle guidance techniques of these structures:

Experiment 1: *In vitro imaging of the facet joint*

Experiment 2: *In vivo imaging of the facet joint and intervertebral disc*

Experiment 3: *Ultrasound for needle guidance of facet joint injections and discography*

### *Equipment*

The ultrasound equipment used throughout these experiments was a 'Diasus' (Dynamic Imaging Limited, Livingston, UK) connected to an 8-16MHz transducer (Dynamic Imaging Limited, Livingston, UK).

### Experiment 1: *In vitro* imaging of the facet joint

### *Background*

The anatomy of the bony cervical spine has been discussed (*see Chapter 2*). In this experiment, the objective was to identify the appearance of facet joints. The spinous process of a vertebra is an easily identifiable palpable structure and can be readily correlated to an ultrasound image; however; facet joints lie deep within the neck, surrounded by layers of tissue and are therefore not palpable. To confirm the *in vivo* ultrasound appearance of a facet joint, an image may be acquired from visualising the facet joint on a section of bony spine *in vitro* and scanning the region of interest directly. This image may then be used to identify the facet joint *in vivo*.

***Method***

Two techniques were utilised to provide a medium in which to suspend the spine for imaging. Initially, a water bath was used as a coupling medium. In later experiments where the introduction of a needle would be required, it was important to simulate the support offered by the soft tissue the needle must pass through; this was achieved by encapsulating the spine in gelatine. A complete human skeleton of the cervical section, C1-C7, was used as a model (*fig. 87*).

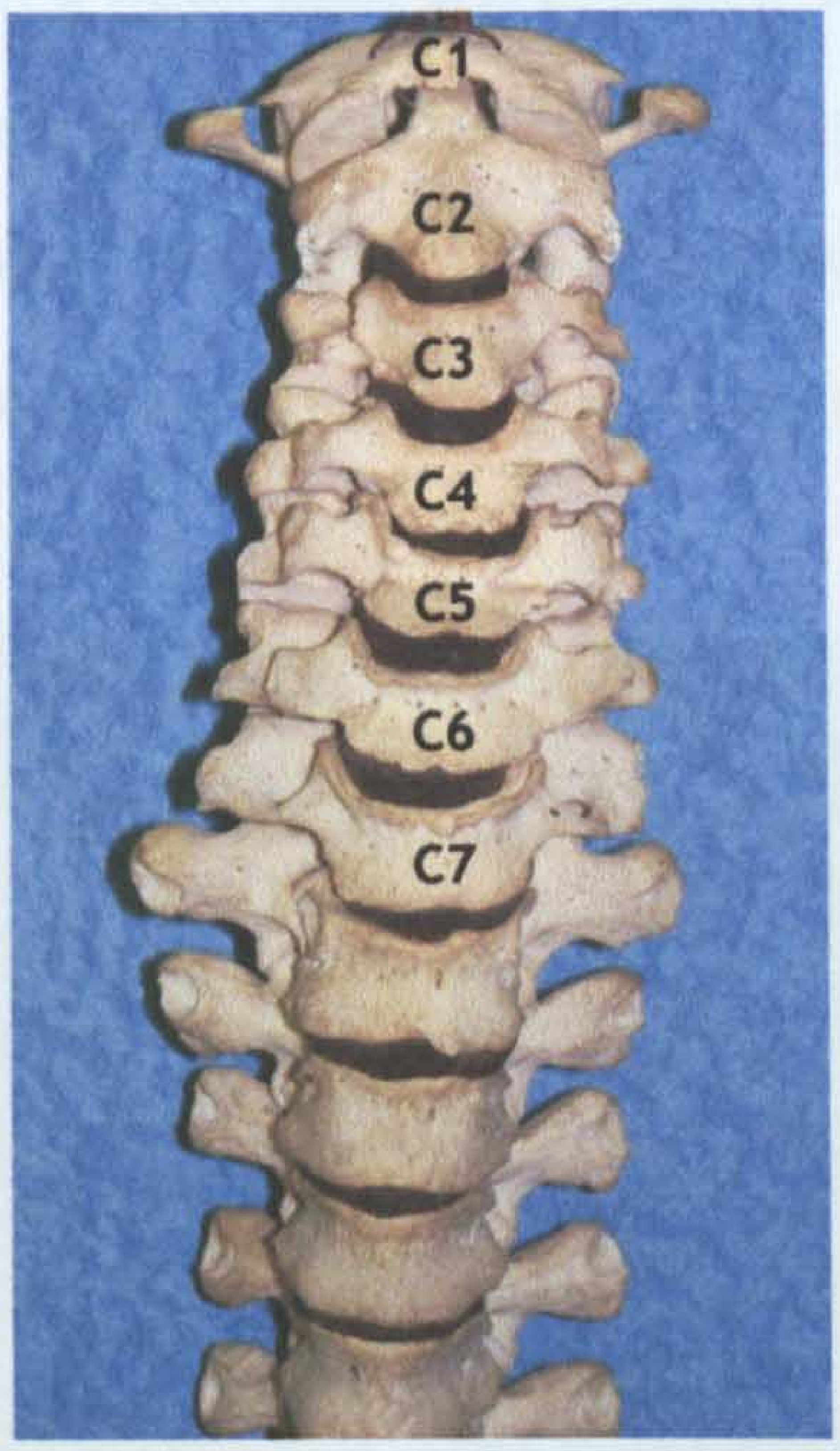

**Figure 87: Cervical spine**

Anterior view
(C1-C7 = cervical vertebrae)

*Water bath*

The cervical spine was scanned *in vitro* in a water bath (*see Chapter 3*). Facet joints were identified and scanned.

*Spine encapsulated in gelatine*

To encapsulate the spine in gelatine, a solution of gelatine (Supercook, Leeds, UK) was made up following the manufacturer's instructions to create a consistency of gelatine that was firm and opaque; this allowed a view of the structures and the relative position of the needle could be clearly visible. A mould was created by suspending the spine in a 2 litre plastic bottle into which the gelatine solution was poured and left to set; the encapsulated spine was removed from the bottle for scanning.

### *Results*

Confirmation of the *in vivo* ultrasound appearance of facet joints was achieved by imaging a section of bony cervical spine in a water bath and at a later stage from encapsulation of the spine in gelatine. Good reference images were obtained that could be used to compare to the *in vivo* appearance of facet joints. Facet joints appear as a characteristic 'V' shape caused by hyperechoic reflections from the closely spaced lateral masses of adjacent vertebra (*fig. 88*).

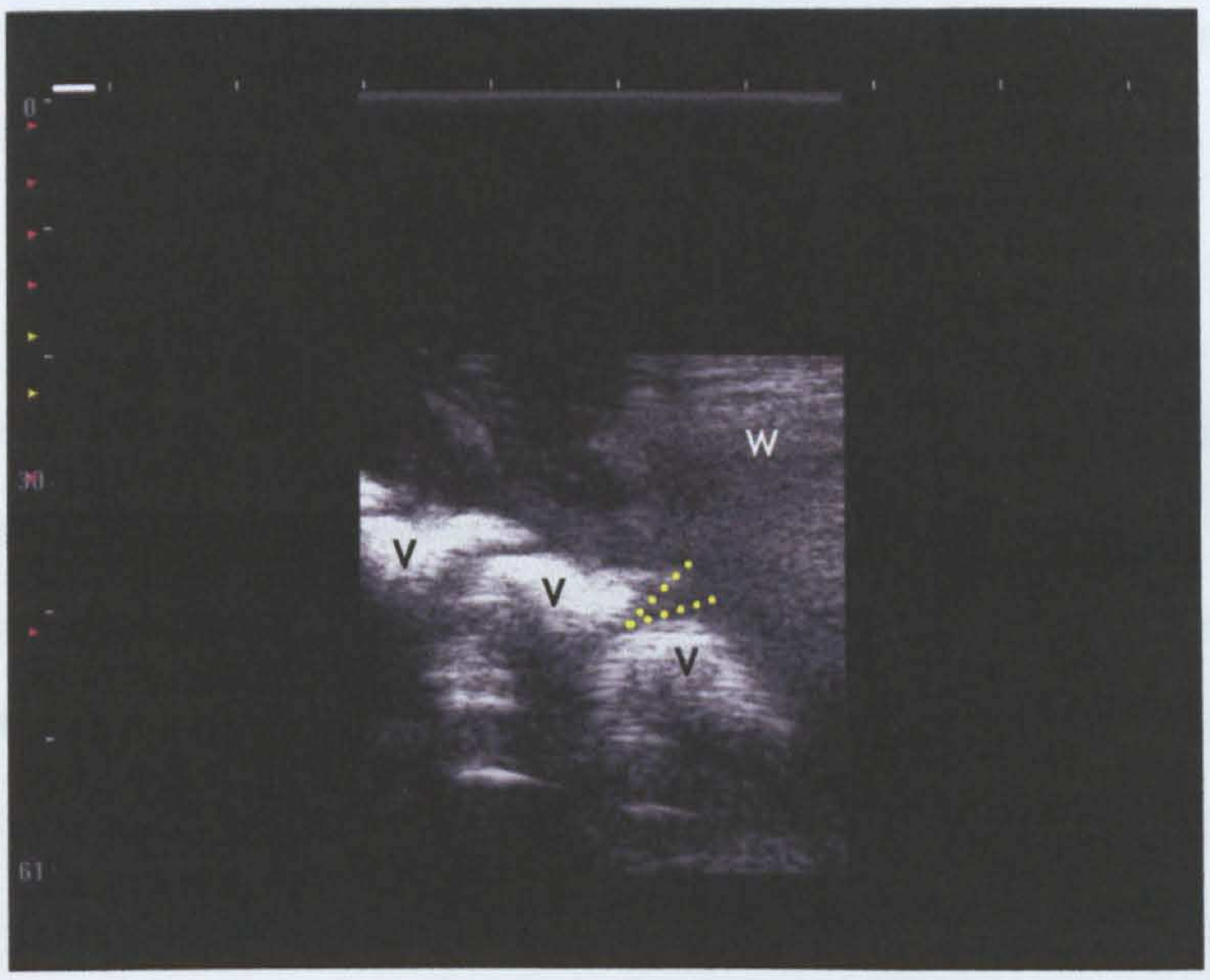

**Figure 88: Scan of spine in water bath**

Transverse scan
(Yellow dashed line illustrates the characteristic 'V shape' appearance of facet joints, V = vertebrae, W = water bath)

### *Discussion*

The facet joint is a synovial joint and has all the characteristics inherent to such (*see Chapter 2*). In this *in vitro* situation, visualisation was only possible of the bony structures as the joint capsule, disc and other soft tissue had been removed from the specimen. A complete specimen was not available for observation. For this experiment, a complete specimen was not mandatory as *in vivo* ultrasound passes freely through these soft tissue structures. Although soft tissue would have altered the clarity of the image, soft tissue would not have impeded visualisation of the bone structure, so long as the bone is within the scanning depth that the ultrasound frequency is able to penetrate.

## Experiment 2: *In vivo* imaging of the facet joint and intervertebral disc

### *Background*

An assessment of the feasibility of imaging facet joints and intervertebral discs *in vivo* was made. Needle guidance procedures approach facet joints with a posterior approach (*fig. 85*) and discography is carried out with an anterior approach (*fig. 86*). The position of the transducer for each approach was considered.

### *Method*

Subjects were scanned in a prone, lateral position which is the typical position for these injection procedures. Various transducer positions were attempted to provide a clear view of the required structure. Reference images obtained in Experiment 1 were used to assist the identification of facet joints. The subjects' stature was considered by calculating the body mass index (BMI) (*see Chapter 3*) as this could have affected the success of imaging.

### *Equipment*

The 8-16MHz transducer was found to give the best representation of facet joints and discs. As well as imaging with the 8-16MHz transducer, a 3-5MHz was also used to compare imaging capabilities. The 3-5MHz transducer obtained images of facet joints that were the same as those acquired using the 8-16MHz transducer. The 3-5MHz transducer was on loan from the Queen's Medical Centre Sports Medicine Department and therefore, as the 8-16MHz transducer was readily accessible, and as this was comparable to the 3-5MHz transducer, this was used throughout the study.

### *Results*

#### *Method for viewing facet joints and discs*

Structures of interest were most accessible and clearly seen with the subject in a prone, lateral position with head facing the contralateral side to that being examined. For the facet injection approach, the transducer was placed in the posterior triangle orientated longitudinally, initially along the posterior border of sternocleidomastoid and then moved in a cranial-caudal direction. For the discography injection approach, the transducer was placed in the anterior triangle orientated longitudinally, initially along the anterior border of sternocleidomastoid and then moved in a cranial-caudal direction. By adjusting the angle of the transducer about a fixed position, the facet joints and discs were located. Successive images of the facet joints and intervertebral discs were taken. For the posterior approach, it was found that an optimal position for transducer angle for visualisation of facet joints is 20-30° posteriorly from the coronal plane and on the coronal plane for discs.

#### *Ultrasound appearance of facet joints and intervertebral discs*

For all subjects examined, facet joints and discs were clearly visible to a depth of 30mm at intervertebral levels C3 to C6. The facet joint surface was clearly visible and appeared as a characteristic 'V' shape caused by hyperechoic reflections from the closely spaced lateral masses of adjacent vertebra (*fig. 88 and fig. 89*). Recognition of facet joints *in vivo* was achieved using the *in vitro* reference images from Experiment 1. The facet joint capsule could not be visualised. Disc regions appear as areas of high signal from the anulus fibrosus and areas of low signal from the nucleus pulposus (*fig. 90*). Paravertebral musculature was clearly demonstrated with individual muscle groups and fibre direction being discernible. However, vessels such as vertebral arteries could not be clearly delineated due to the surrounding artefacts caused by bone.

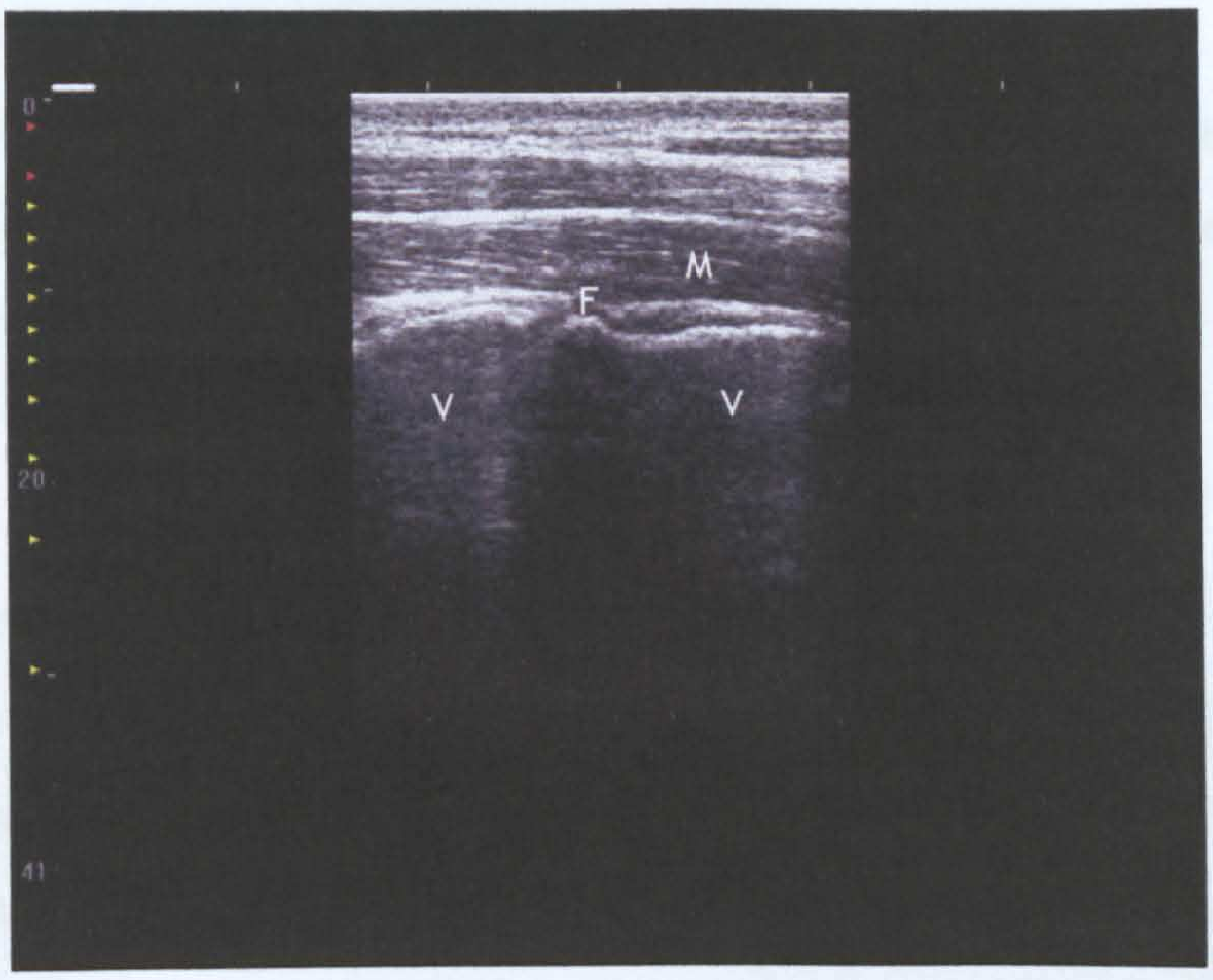

**Figure 89:** ***In vivo*** **facet joint**

Longitudinal scan
(F = facet joint, V = vertebra, M = muscle)

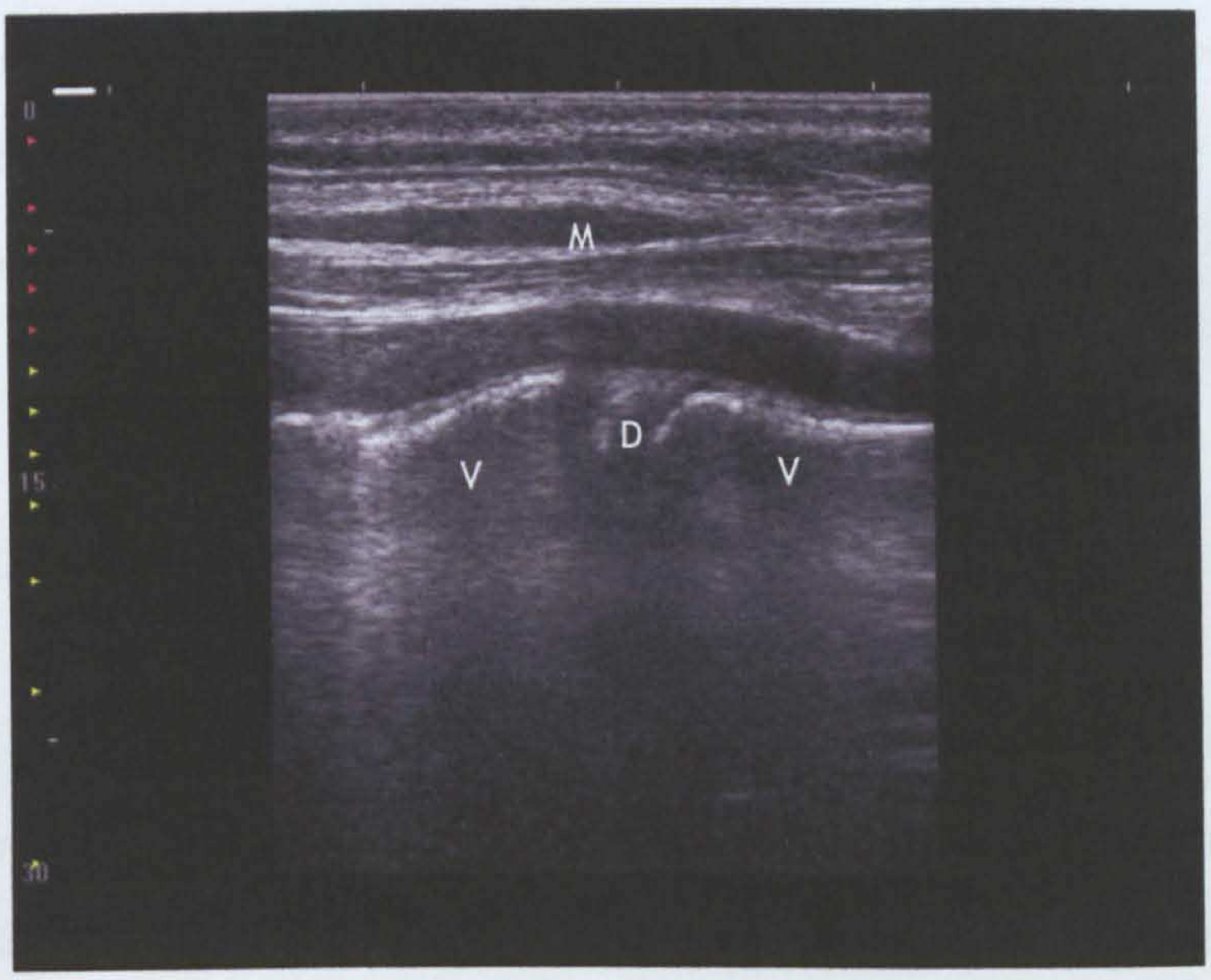

**Figure 90:** ***In vivo*** **intervertebral disc**

Longitudinal scan
(V = vertebra, D = disc, M = muscle)

### *Structure visibility*

Facet joints and discs were not visible in all subjects. The stature of the subject affects the appearance of facet joints and intervertebral discs. With increasing body mass index, musculature and fat; visibility of deep structures decreases.

### *Discussion*

The ultrasound appearance of facet joints and intervertebral discs has been described together with a technique to view these structures. In subjects of suitable stature, ultrasound is a valuable tool for the imaging of facet joints and discs. With the transducer orientated in the longitudinal plane, facet joints and discs were visible on both anterior and posterior examination. The stature of the subject being scanned affects the ability to image structures. With this frequency of transducer (8-16MHz), the depth of penetration is possible up to a maximum depth of 30mm. Increased distance between the transducer and structure of interest caused by muscle or fat increases the path the wave must travel (penetration depth). Fat also has the effect of scattering the ultrasound wave which results in de-focussing of the beam and a subsequent decrease in penetration and resolution. In subjects with a slender stature, facet joint and disc structure visibility was improved.

## Experiment 3: Ultrasound for needle guidance of facet joint injections and discography

### *Background*

Injection procedures often make use of imaging modality guidance such as fluoroscopy and plain radiography to image the position of the needle to ensure the target injection site is identified and avoid the penetration of nearby structures. Ultrasound allows a real-time evaluation of the situation and could therefore shorten the investigation time and procedure; improving the patients comfort and avoiding the inherent risks of other imaging modalities.

### *Method*

A 22 gauge x 3" sterile spine needle (Steriseal, Worcester, UK) was used to illustrate a typical needle used for these procedures. The needle guidance technique was carried out with the spine embedded in gelatine and in a water bath.

### *Results*

Facet joints and their relationship with the needle are clearly depicted (*fig. 91*). With the transducer held in a transverse plane in relation to the needle, an echogenic dot brighter than the surrounding structures indicates the position of the needle (*fig. 92*). With the transducer positioned in a longitudinal orientation, the length of the needle may be appreciated (*fig. 93*). The needle is prone to cause reverberation of the ultrasound wave which appears as multiple linear echoes, equally spaced apart. Reverberation does not inhibit the view of the needle placement, as the full length of the needle was visible.

**Figure 91: Facet joint injection**

Longitudinal scan of vertebrae showing needle contrast.
(W = water, N = needle, F = facet joint)

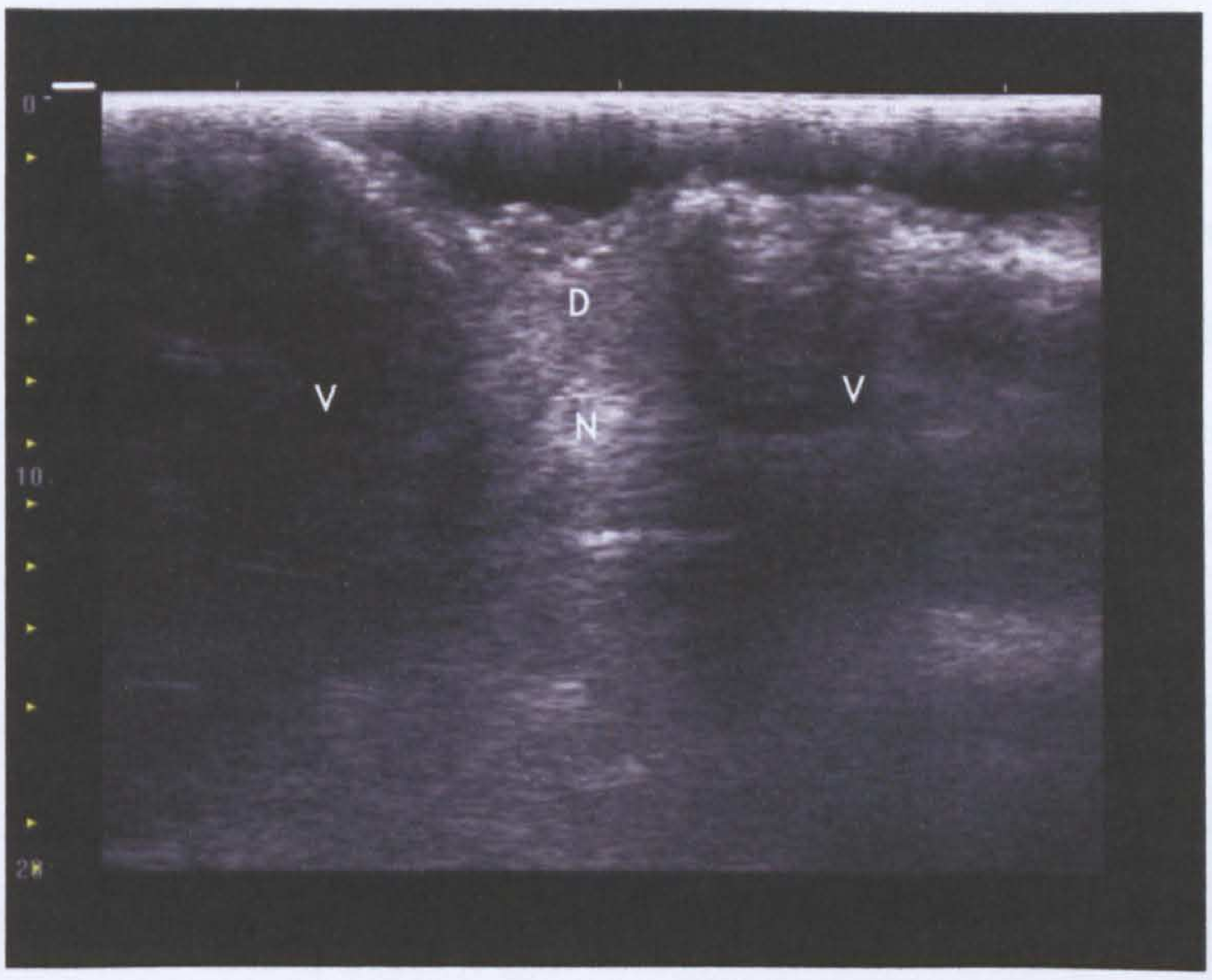

**Figure 92: Simulated discography (Part 1)**

Longitudinal scan of human disc between vertebrae *in vitro*, needle viewed in cross-section.
(V = vertebra, D = disc, N = needle)

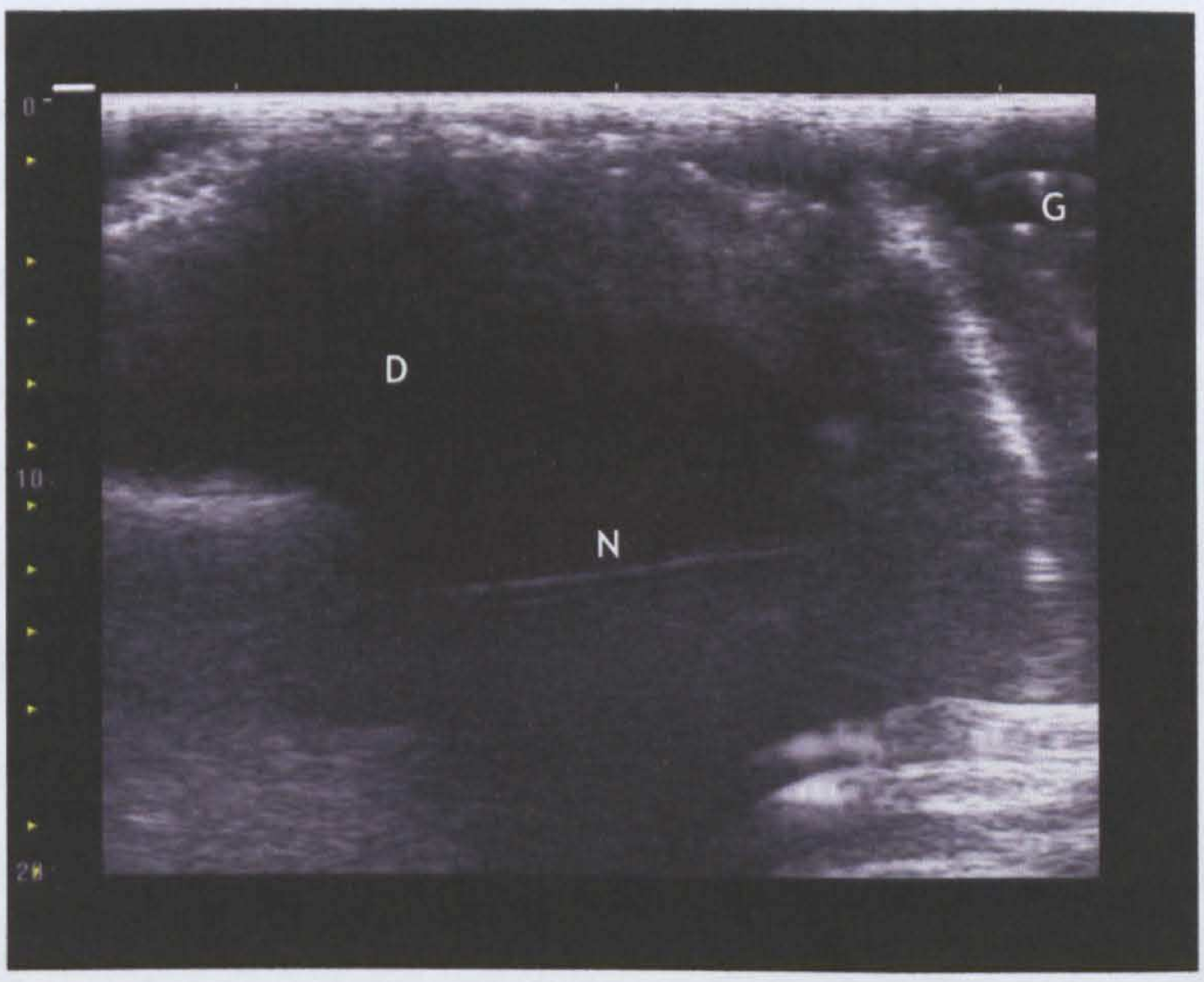

**Figure 93: Simulated discography (Part 2)**

Transverse scan of human disc *in vitro*, needle length viewed.
(D = disc, N = needle, G = gel)

### *Discussion*

Needles contrast well with the surrounding tissue providing good visibility of their position within both the facet joint and disc complex. Facet joints and discs can be identified with the transducer in a longitudinal orientation with both a posterior and anterior approach. However, facet joint blocks and discography require a set approach with the needle position which results in the needle being imaged in its transverse plane. The cross-section of the needle is displayed making identification of the needle tip ambiguous. For the needle to appear clearly on ultrasound, it must be scanned in the longitudinal plane perpendicular to the transducer to appreciate the length of the needle. An approach to assessing the success of these ultrasound guided procedures would be to carry out a mock injection where dye is used as a marker. After completing the needle guidance procedure, dissection would allow verification of the accuracy of positioning the needle using this modality; the accuracy being determined by assessing the deposition of the dye.

## *7.4 Experimental Series Discussion*

The experiments described in this chapter have demonstrated that facet joints and intervertebral discs can be clearly visualised with the contemporary ultrasound equipment that is currently available. Such is the clarity of bony structures and the surrounding soft tissue that potential pathologies may be identified. Degenerate facet joints may manifest as fluid within the joint capsule or facet joint hypertrophy (joint dimensional changes) both features of which have the potential to be seen with ultrasound. The space visible between adjoining facets could render ultrasound as a suitable technique to assist steroid injection, a technique already established using fluoroscopy (Murphy and Lieponis 1989). Changes in bone structure such as osteophytic changes within the vertebral bodies or calcification of discs may also be apparent. Prevertebral muscles are well delineated which in a trauma situation may exhibit features of a haematoma or tear. Given that it is possible to see the anulus with ultrasound within the cervical spine region, this has the potential that tears within the anulus may also be seen. The components of the disc, nucleus pulposus and anulus fibrosus, can be identified and therefore could provide a route for needle guided interventions.

The images acquired from this study represent a single moment in time for what is a dynamic process. The ability to scan in real-time, coupled with directed transducer placement to attain specific views, should allow the technique to be used to aid diagnosis and help guide any physical intervention.

## *7.5 Chapter Discussion*

Ultrasound is an imaging modality that has not been exploited to view these structures, and may provide the clinician with another mode of investigation. With further expansion of the applications of ultrasound, quantification of anatomical parameters including disc and facet dimensions may be possible. This could ultimately be used as a diagnostic tool for quantification of pathology such as degenerative disorders of the spine. With the increasing trend towards minimally invasive investigations, ultrasound provides a useful adjunct to the present imaging armamentarium.

# Chapter 8: Whiplash

## *8.1 Chapter Summary*

This final experimental chapter brings together the studies outlined in previous chapters. The groundwork for the study has been described in these chapters where the ultrasound anatomy of the neck and how it varies between individuals has been assessed, a scanning technique for the neck has been identified, soft tissue injury signs are understood and methods to quantify these changes have been addressed. This information provides the basis for collecting images and performing diagnosis on whiplash patients. This chapter describes how a culmination of the experience gained in previous experimental chapters was used in an investigation of whiplash patients. This investigation assessed those injuries associated with whiplash that may be identified and monitored using ultrasound.

Project objectives fulfilled in this chapter:

- investigate the ultrasound appearance of the neck in whiplash patients

## *8.2 Background*

A diagnostic procedure has not been recognised for the assessment of whiplash. The implementation of a variety of imaging modalities has been investigated but a suitable *modus operandi* has not yet been found (*see Chapter* 2). One of the main reasons for this is that the pathoanatomy of whiplash has yet to be identified and a multitude of injuries has been attributed for the cause of pain. This study has focussed on the premise of soft tissue damage occurring. Some investigators in the field of whiplash aetiology believe soft tissue is not damaged, in particular, they believe this is evidenced by those long-term sufferers where any soft tissue damage should have healed and therefore another factor must be the source of pain. If a soft tissue injury is part of the syndrome, perhaps this study will help to determine the aetiology of whiplash. Although it is not envisaged that a conclusive diagnostic technique will be the outcome of this project, it is hoped that the use of ultrasound will be accepted as a device for identifying the pathoanatomy of whiplash.

## *8.3 Whiplash Clinic Pilot Study*

During the completion of the background experiments, the author had developed both their knowledge and skills. In addition, a number of techniques were established for using ultrasound, and the next step was to conduct a pilot study. The aim of this pilot study was to assess the applicability of ultrasound as an imaging modality for the diagnosis of whiplash injury. This pilot study would be used to fine tune the experimental protocol for a large study on whiplash patients. The following procedures were assessed and modified in order to improve the running of the planned large study:

- accident and emergency department awareness of the study
- patient recruitment
- patient personal information
- details of the accident
- physical examination
- ultrasound assessment

### *Method*

The accident and emergency department of the Queen's Medical Centre, Nottingham, UK; provided an ideal setting to conduct this study; being one of the busiest departments in the country. Collaboration with the Queen's Medical Centre, Centre for Spinal Studies and Surgery enabled qualified spinal research fellows to assist with this research. The experiences of the spinal research fellows (Andrew Clarke and Clare Morgan-Hough) was important for this study including their clinical expertise, patient communication skills, the ability to conduct patient history collection and make a physical assessment; made them invaluable resources for the project. As well as the spinal research fellows input, the hospital ethics committee required lead investigators for the project, and a spine consultant (Brian Freeman) and an accident and emergency consultant (Frank Coffey) were recruited to oversee the project.

Initially, a two week pilot study was conducted (October 2003) to assess the study protocol, which was developed during this time, and to produce a method that would be implemented for a large scale clinic. The methodology for both studies follows and the adjustments made to this are highlighted in the relevant experimental account.

Patients and staff were made aware of the study by posters displayed throughout the accident and emergency department and waiting rooms. The poster gave the investigators contact details and advised patients of an information pack (*see Appendix* G) that could be collected from the accident and emergency department reception. Accident and emergency reception staff were also asked to distribute these information packs to patients reporting with a suspected whiplash injury. The author periodically visited the accident and emergency department to see if patients suspected with whiplash were being recruited, and to review with the nursing staff the number of whiplash patients that had visited the department and been discharged. To ensure the accident and emergency department staff awareness of the project, and enhance recruitment, the author gave a presentation at the department's monthly research meeting. The only commitment required from staff was to contact the author should a suitable patient be available.

The criterion for patients eligible for invitation to the study was that:

- the patient had been involved in a whiplash accident
- there were no time scale restrictions between accident and scan
- the treatment given by the hospital must be complete and the patient discharged

Patients presenting with whiplash injuries were first examined with the hospital's own protocol and if cleared of any major injuries such as fracture; they were then invited by nurse practitioners to take part in the pilot study. If the patient was interested, the author explained the study to them, including their involvement rights. The patient was then given an information pack to read stating what the author had already verbally explained. After the patient had read this information, they were asked if they had any questions about the study and if they would still like to participate. If the patient agreed to take part in the study, they were asked to complete and sign a consent form (*see Appendix* G). The patient was also told they could leave the study at any point and did not have to give a reason for doing so. Assessment forms for patient history and physical assessment were created based on suggestions from the Quebec Task Force (Spitzer *et al.* 1995) (*see Appendix G)*. The patient was either assessed that day or given the opportunity to return later at a time convenient to the patient. Initially the clinical research fellow assessed the patient including taking a history of the patient and details of the accident, timescale and perceived state of injury. This was followed by a physical examination comprising an assessment of range of cervical motion and neurology. After this, the author took an ultrasound scan of the neck region. A systematic examination of the neck was carried out as previously described (*see Chapter 4*). The neck was examined for signs of injury, such as haematoma, muscle tear and swelling. Images were captured if a musculoskeletal pathology was identified otherwise images were taken from the site of pain determined by the patient. Contralateral images were acquired to facilitate comparison of the injury with an allegedly injury free side. If ultrasound is to be a viable diagnostic tool for assessing whiplash injury, it is important that patients are able to tolerate the examination. Therefore, on completing the scan each patient was asked to grade the level of comfort they felt during the scanning process on a scale from 0 (no discomfort) to 5 (intolerable). It was also noted if any radiography had been conducted on the patient during the Queen's Medical Centre assessment, which could be used to obtain further information about the injury and compared to ultrasound scans. The time commitment needed by patients for the pilot study was twenty to thirty minutes.

This study protocol was reviewed and approved by the hospital ethics committee and all persons gave their informed consent prior to their inclusion in the study. The model of ultrasound equipment used in this study was a 'Diasus' (Dynamic Imaging Limited, Livingston, UK) connected to an ultra-wide band 8-16 MHz transducer (Dynamic Imaging Limited).

Over a period of two weeks, nine patients (five male and four female) with an age range of 27-45 years (mean age 31.8 years) participated in the study. Patients were scanned on the same day (5), the next day (1), after three days (1), after eight days (1) and after three months (1) of the initial accident.

### *Results*

All subjects reported neck and shoulder pain. Of the nine subjects, ultrasound examination revealed: swelling characterised by asymmetrical differences in the size of muscle blocks and echogenicity (5), differences in fibre texture appearance (3), intrafascial haematoma visualised as anechoic regions with irregular boundaries (3) and no findings (2). In all cases, the observed lesions were consistent with symptoms (*see Table 8*).

**Table 8: Summary of whiplash patients**

| Gender | Passenger position | Impact | Clinical Assessment: | | US findings | Scan grade |
|---|---|---|---|---|---|---|
| | | | Palpation | Movement | | |
| Male | Front right (driver) | Rear | Bilateral pain on palpation | All painful, extension pain free | No | 0 |
| Female | Front right (driver) | Rear | Pain in left trapezius on palpation | All painful | Fibre changes | 0 |
| Female | Front right (driver) | Driver side | Right trapezius | All painful | Swelling | 0 |
| Female | Front left (passenger) | Driver side | Left paraspinal and traps | All painful | No | 0 |
| Male | Front right (driver) | Rear | Left trap | All painful | Fibre changes | 0 |
| Male | Front right (driver) | Driver side | Bilateral pain | Extension and flexion and right rotation painful, the rest pain free | Swelling /fibre changes | 0 |
| Female | Front left (passenger) | Rear | Left paraspinal and left traps | All painful | Swelling /haematoma | 1 |
| Male | Front right (driver) | Rear | Left paraspinal and left traps, lumbar spine | All painful | Swelling /haematoma | 2 |
| Male | Front right (driver) | Rear, driver side | Paraspinal and left traps | All painful | Swelling /haematoma | 0 |

### *Ultrasound assessment of whiplash patients*

During the ultrasound assessment of whiplash patients, typical observations of pathology included the appearance of swelling (*fig. 94*), haematoma (*fig. 95*) and fibre changes (*fig. 96*).

#### *Swelling*

Swelling was identified in five of the nine patients as an increase in echogenicity, a loss of clarity in tissue architecture (*fig. 94*) or by a change in tissue diameter (*fig. 95*)

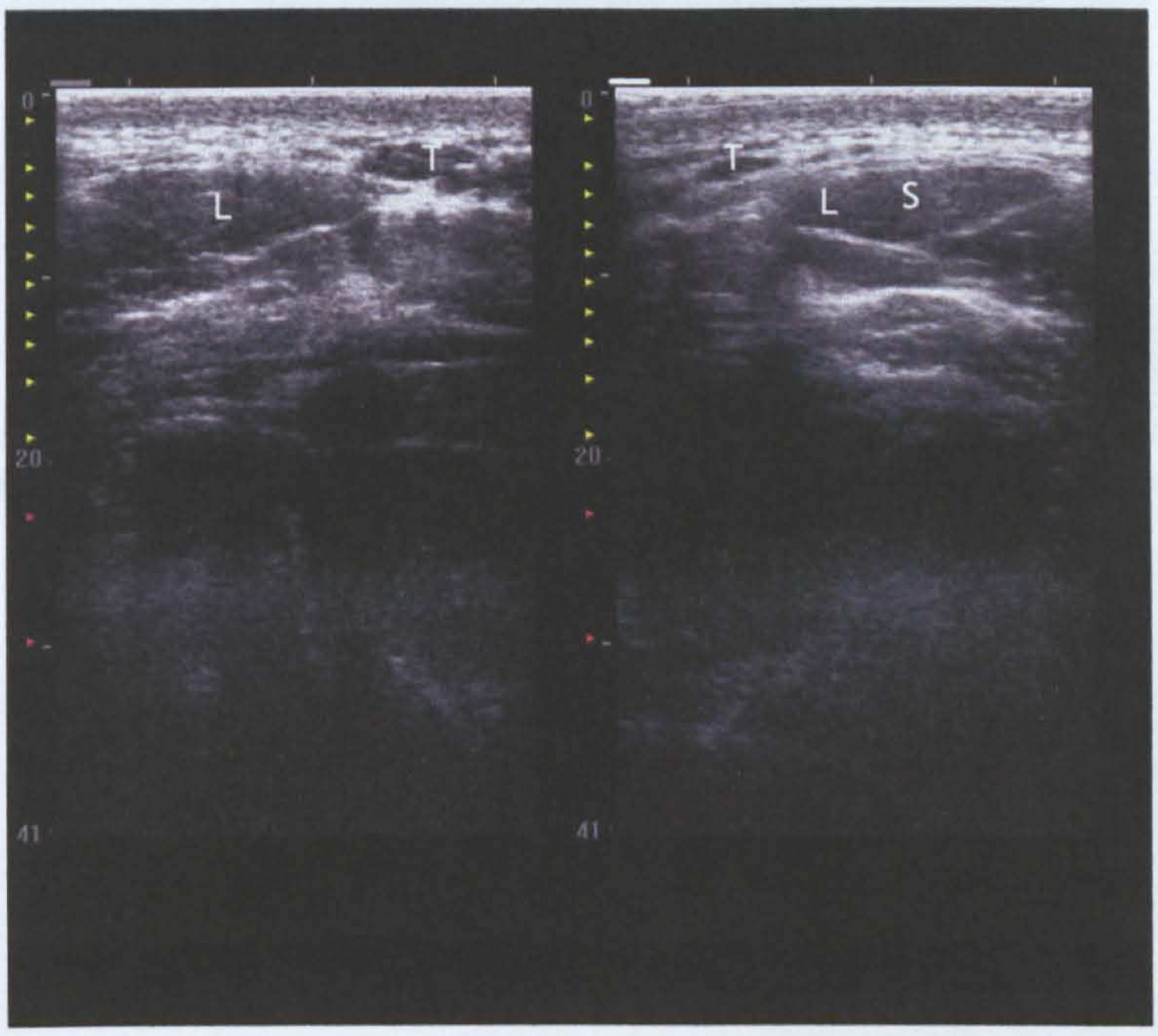

**Figure 94: Swelling (Part 1)**

Transverse scan of swelling depicted by an increase in echogenicity on right side and loss of clarity of muscle tissue architecture (right) compared to unaffected side (left).
(T = trapezius, L = levator scapulae, S = swelling)

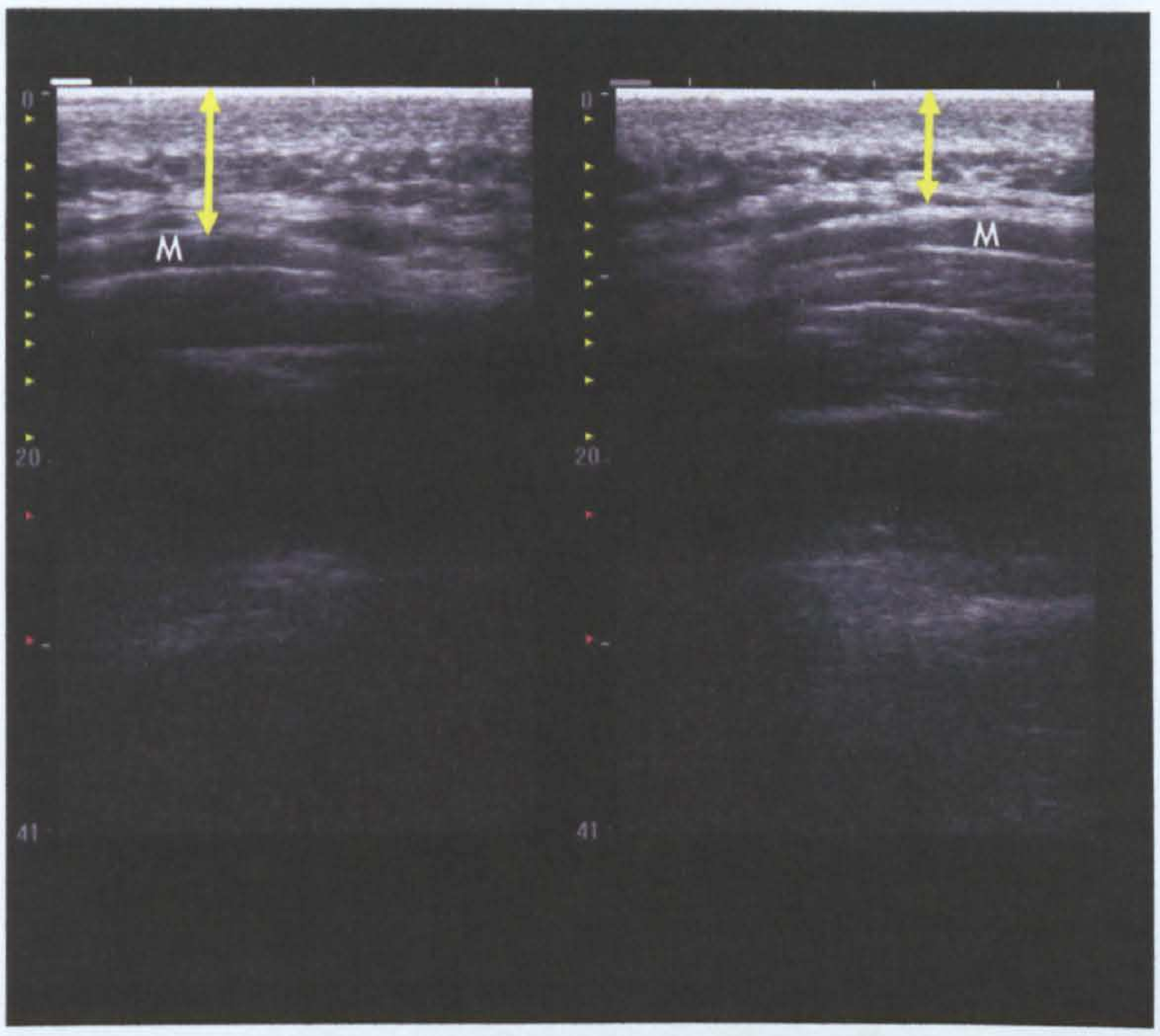

**Figure 95: Swelling (Part 2)**

Transverse scan, note increase depth between muscle and skin surface indicative of swelling (left) and increased depth of penetration in unaffected side (right).
(M = muscle, arrows = indicate depth)

*Fibre texture changes*

Fibre texture changes were identified in three of the nine patients as a change in the architecture of the tissue (*fig. 96*).

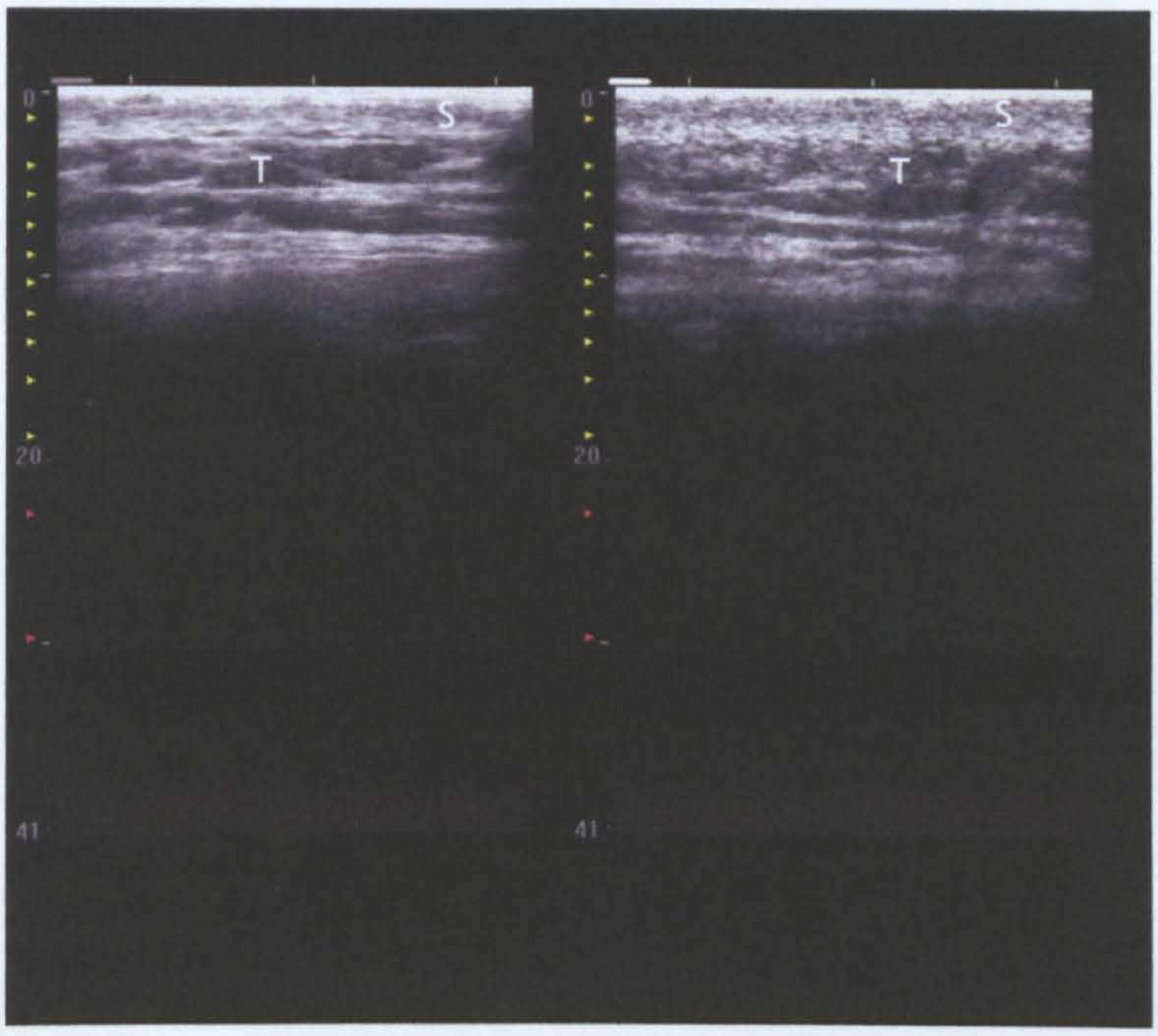

**Figure 96: Fibre texture changes**

Contralateral comparison of both sides of the neck reveal that the usual symmetry is disturbed and changes in muscle fibre appearance are evident.
(T = trapezius, S = skin)

*Haematoma*

Haematoma formation was identified in three of the nine patients as an irregular anechoic region with respect to the surrounding tissue (*fig. 97*).

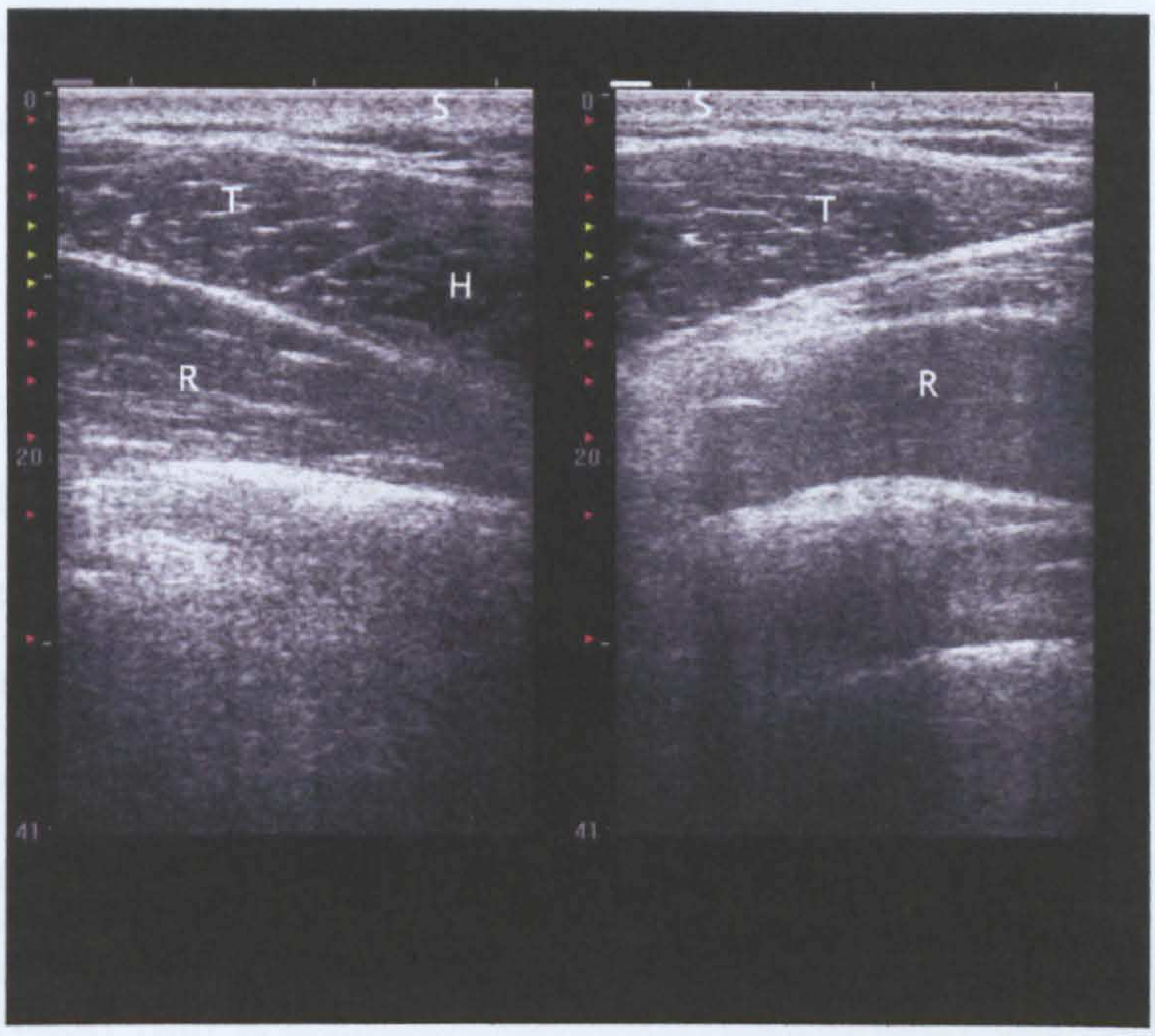

**Figure 97: Haematoma**

Transverse scan of neck region damaged side (left) and unaffected side (right). (T = trapezius, R = rhomboideus minor, H = haematoma, S = skin)

***Case Study***

The following is a case study describing the findings for one of the patients of the pilot study sample.

*History:*

A 33 year old male reported to the accident and emergency department following a rear impact automobile collision that rendered the car undrivable. The occupant was driving the vehicle (right hand drive). He did not lose consciousness; he did not hit his head and sustained no fractures. He was in excellent health before the incident and had not had a similar injury previously.

*Clinical examination:*

The patient had moderate neck and shoulder pain, reduced and painful neck movements, and moderate low back pain. When the cervical spine was palpated, tenderness and pain were experienced in the left paraspinal muscles and trapezius. No pain was felt in the shoulder when palpated. Cervical movement was limited. Shoulder movements were normal on the right but painful on the left. Neurological examination proved normal.

*Scanning:*

Scanning took place on the day of injury. A pathological lesion was identified on the left at the C4/C5 level. An irregular anechoic region in the intrafascial space between the trapezius and levator scapulae muscle was identified, representative of a haematoma formation (*fig. 98*). Such anechoic regions were found in three of the nine patients. Ultrasound images taken around the level of C5 revealed swelling in the trapezius. Swelling was characterised by increased echogenicity, increase in diameter and loss of tissue architecture clarity (*fig. 99*). The patient graded the scanning procedure as 0, no discomfort.

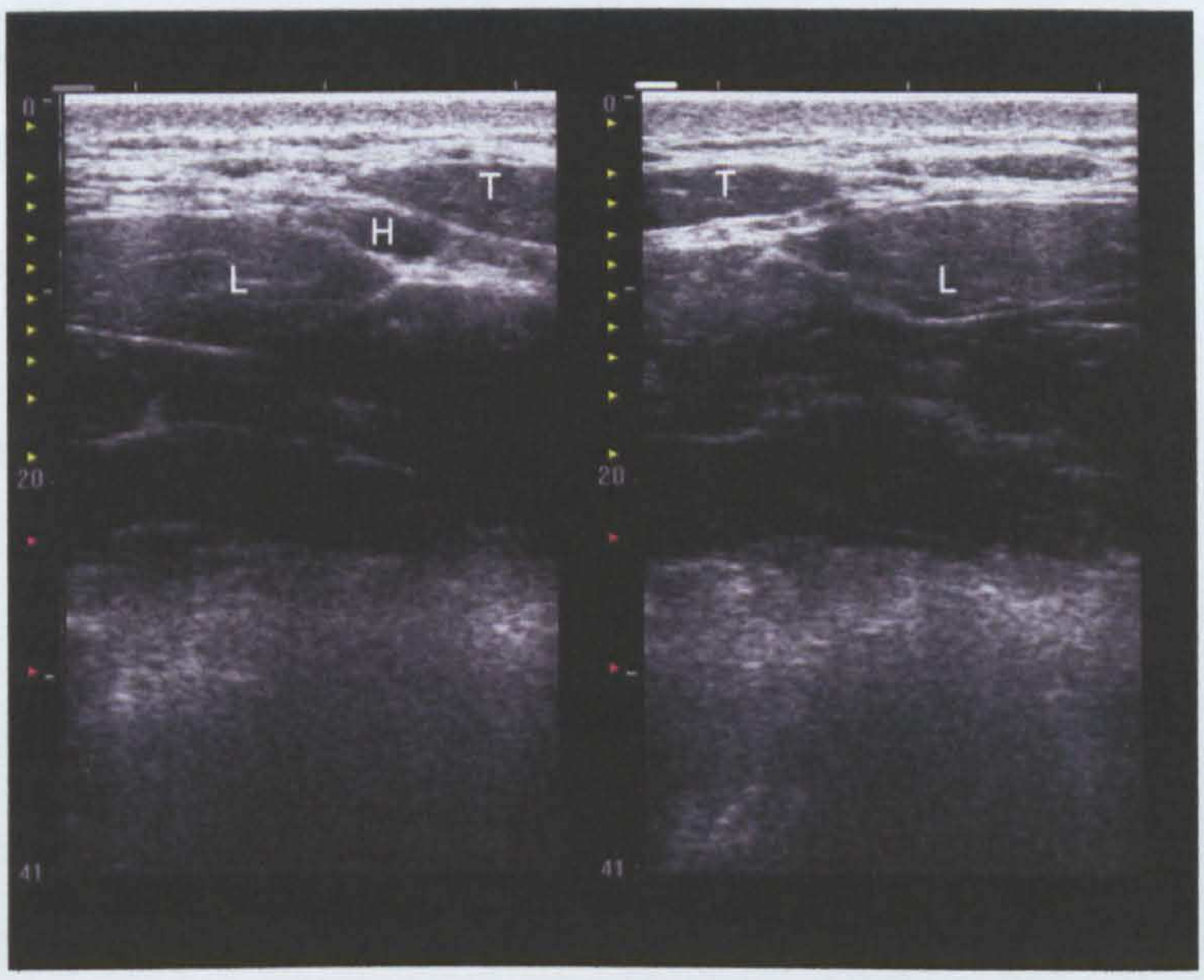

**Figure 98: Whiplash injury: haematoma**

Transverse scan of posterior midline at C4/C5 level. Anechoic irregular region between trapezius and levator scapulae indicating haematoma.
(T = trapezius, H = haematoma, L = levator scapulae)

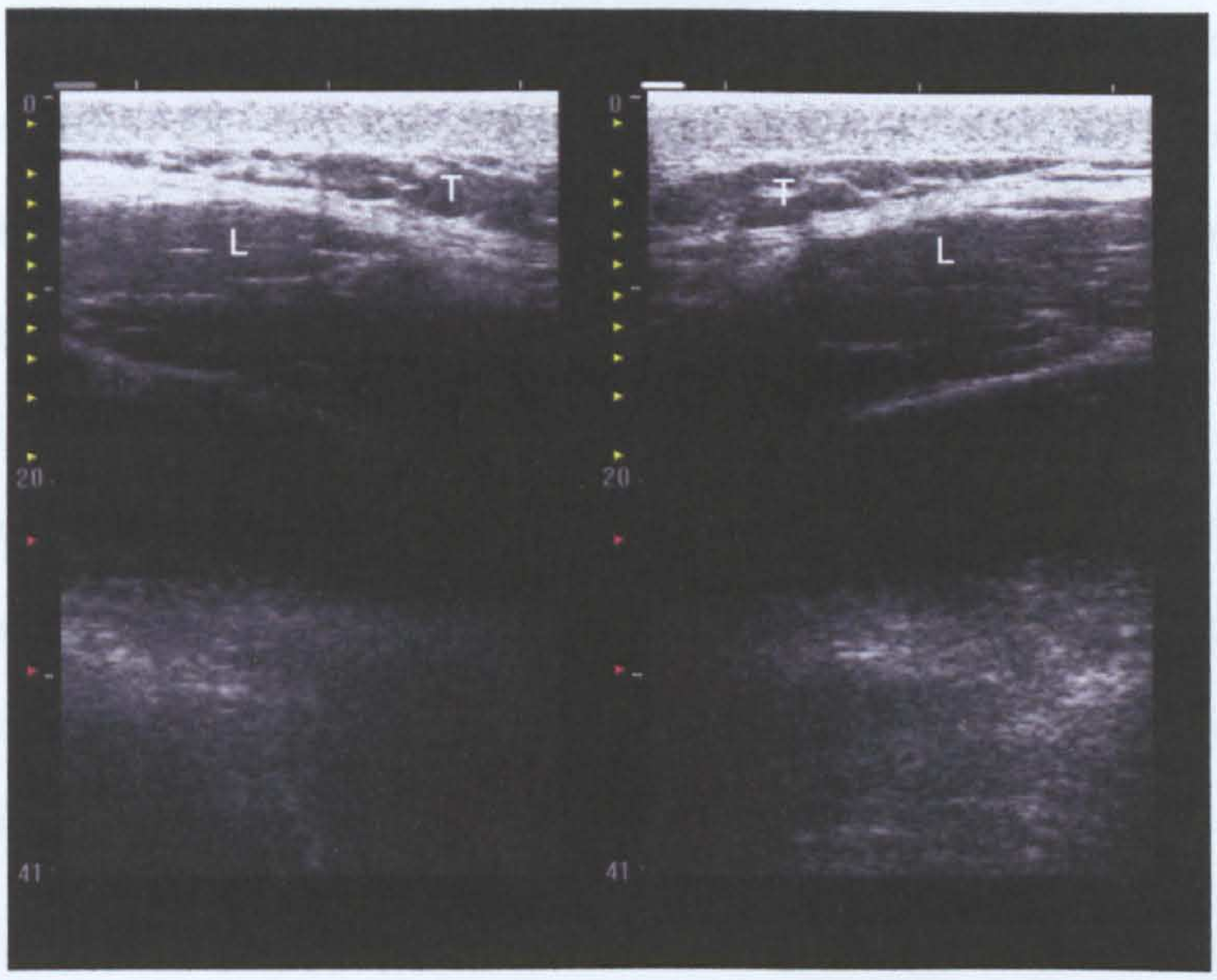

**Figure 99: Whiplash injury: swelling**

Transverse scan of posterior midline at C5 level. Increased echogenicity indicative of swelling on the left side that was painful on palpation (left) compared to less affected side (right). (T = trapezius, L = levator scapulae)

*Discussion*

The sample of patients entering into this pilot study represents a group of whiplash patients who have reported to their local hospital accident and emergency department. It has been noted from other studies that women have a greater tendency to present with whiplash. In the pilot study, both genders were equally represented; however, the sample size was small. Of this sample, two patients had experienced whiplash in the past but had made complete recovery from these previous injuries.

It is interesting to consider how seating position in the car affects whiplash injury. The driver, being in control of the vehicle, should in theory be more aware of the outside situation. This means that they may be able to prepare themselves for the impending impact which may alter the injury mechanism. The driver may or may not benefit from the action of holding the steering wheel. In this study, seven of the patients were drivers, two were passengers and all were from separate accidents. It is interesting to note that six of the nine patients reported pain on the left side. It is possible that this is related to the seatbelt. The seatbelt in right hand drive cars crosses over the driver's right shoulder and is fastened around waist level on the driver's left side. It is possible that the right shoulder is restrained by the seatbelt, whereas the left shoulder continues in a forward trajectory. From this information it would be interesting to see a larger sample and see if drivers suffered on the left and passengers suffered with right injuries. This theory does not appear to hold in this study, as two patients were passengers seated in the front left and these both experienced pain on the left. However, the sample is small; a further study would require a sample size of at least thirty six subjects to detect an effect of seatbelt position with a power of 0.8. These results do not provide a conclusive result, but highlight an important factor to consider.

Ultrasound images acquired following whiplash injury revealed soft tissue damage. A number of these soft tissue lesions were identified and they correlated well with observed signs and symptoms. For example, in the case study described, the region where the patient experienced pain, resulting in impaired movement on the left paraspinal and trapezius muscles; correlated well with the ultrasound findings.

In simulated crash test studies, haemorrhages have been identified between the intermuscular fascial planes of the neck and have been associated with damage to the cervical sympathetic plexus (LaBan 1990). It is interesting to note that a similar finding occurred in the case study.

Seven patients found the scanning procedure to be of no discomfort, and only two patients graded the scan as being mildly uncomfortable. No reasons are accountable as to why these two patients should experience discomfort. A few patients even found the scanning procedure to be relaxing and likened it to a massage. It is pleasing to find that for all patients expressing pain during neck movements and on palpation that they graded the scan as 0 (no discomfort); thus illustrating the scanning procedure to be patient friendly and that it does not cause the patient further discomfort.

The results of this study show promise for the application of ultrasound as an imaging tool for patients presenting with whiplash associated injuries. Future study will follow the progression of observed pathologies over time to provide information on the healing process. This will facilitate testing of the feasibility of using ultrasound as a diagnostic and prognostic tool. The quality of ultrasound images depends upon both the path length and the composition of overlying tissues to the region of interest. In common with the majority of ultrasound procedures, the success of imaging whiplash injury will depend upon the thickness of subcutaneous fat in the patient. Such effects require specific study as part of any future feasibility study. It was recognised that the patient's height and weight should be recorded to enable a body mass index (BMI) to be calculated.

This is the first reported hospital based study where ultrasound has been used in the early assessment of patients with whiplash. Ultrasound appears useful in defining the pathological lesion associated with whiplash. A larger study is required with longer term follow-up and correlation with clinical outcome. Repeat scanning may document the injury resolution of some of these lesions over time.

### *8.4 Chapter Discussion*

Consideration should be given to the sample available to the study. Following a whiplash injury, the onset of pain typically occurs twenty four hours after the accident, therefore people will be more likely to report the injury to their general practitioner. It could be that this study is missing a very important group, such as those reporting to general practitioners, chiropractors, physiotherapists etc... Perhaps recruiting patients attending accident and emergency departments does not allow sufficient time for signs to develop, for example, a haematoma typically takes twenty four hours to appear and therefore the scan may be too soon. Another reason is that maybe a different injury mechanism is occurring in those patients who experience an early onset of pain compared to those that have a delayed response. It is necessary to investigate whiplash patients from a variety of backgrounds and to carry out these follow-up assessments.

The ideal situation to enable identification of a whiplash injury would be to have a before and after picture of a patient. With only information post accident, defining what pathology has been caused by the accident or was a pre-existing condition is not possible. Examination of a large sample may allow identification of similar whiplash injury indicators. Once these have been identified, regular assessment of these pathologies may be made. If resolution of the pathology is found to correlate with resolution of symptoms, (e.g. pain decrease and mobility increase) these findings may provide an indication of the aetiology of whiplash.

# Chapter 9: Discussion

## *9.1 Chapter Summary*

This chapter describes how the research presented in this thesis has fulfilled the aims of the research project.

## *9.2 Were the Aims of the Study Fulfilled?*

The aim of this thesis was to evaluate traumatic failure and pathological lesions in the musculoskeletal structures of the cervical spine. Information was used to establish methodology/guidelines that can be used to define the presence and extent of a whiplash injury and monitor the recovery process. The specific objectives that were stated to achieve this aim were as follows:

1. *understand the current research relating to this study*
2. *establishing a technique for scanning the neck - particularly of the posterior structures*
3. *assess the normal ultrasound appearance of the neck*
4. *study the ultrasound appearance of soft tissue damage both in vitro and in vivo*
5. *study the ultrasound appearance of bony structures*
6. *investigate the ultrasound appearance of the neck in whiplash patients*
7. *quantification of injury using ultrasound*

These objectives have been fulfilled by the undertaking of the experiments carried out in the following chapters:

**Chapter 2: Literature Review**

Objective 1: understand the current research relating to this study

**Chapter 4: Ultrasound of the Neck**

Objective 2: establishing a technique for scanning the neck - particularly of the posterior structures

Objective 3: assess the normal ultrasound appearance of the neck

**Chapter 5: Soft Tissue Damage**

Objective 4: study the ultrasound appearance of soft tissue damage *in vivo*

**Chapter 6: Quantification of Pathology Using Ultrasound**

Objective 4: study the ultrasound appearance of soft tissue damage *in vitro*

Objective 7: quantification of soft tissue injury using ultrasound

**Chapter 7: Facet Joint and Intervertebral Disc**

Objective 5: study the ultrasound appearance of bony structures

**Chapter 8. Whiplash**

Objective 6: investigate the ultrasound appearance of the neck in whiplash patients

Although quantification of whiplash injury and monitoring of pathology was not achieved, protocols have been investigated and suggested to achieve this in future studies.

## *9.3 Conclusion*

Although the author was the main operator in the study and they lacked the expertise of a qualified radiologist, findings in this report were discussed with consultant radiologists who were in support of the research conducted and the subsequent findings. Those pathologies identified in case studies of various musculoskeletal pathologies were replicated *in vitro* to provide models that were used to identify a quantification technique. The pilot study conducted in the accident and emergency department of the Queen's Medical Centre enabled recruitment of patients presenting with whiplash injuries. Using the neck examination technique that was developed in primary studies, and knowledge of the ultrasound appearance of the structures of the neck; it was possible to conduct a thorough investigation of the neck. Patient's symptoms corresponded well with ultrasound findings and these findings suggest that soft tissue injury is a component although not necessarily an exclusive factor in the pathoanatomy of whiplash. Further studies are required of patients presenting from a variety of whiplash injury mechanisms. Follow-up assessment of these patients is needed to identify if resolution of injury occurs. If correlation is found between the pathologies identified with ultrasound and whiplash injury; this will support the hypothesis that soft tissue injury does occur in a whiplash event. This study has identified a technique to enable the quantification of soft tissue lesions. Quantification is essential for the assessment and monitoring of those pathologies identified in whiplash patients. The concluding chapter of this thesis discusses an approach to conducting a large scale study based on the experience and knowledge of the author gained from carrying out this study.

It is felt that the work presented in this thesis has yielded some useful information regarding the use of ultrasound as a diagnostic tool for whiplash. Many sites of pathology have been postulated over the years, but all have thus far been unsubstantiated by objective research evidence or have been found in controlled studies to be no more prevalent in injured than in uninjured subjects. As can be seen from the images included in this thesis; ultrasound captures in detail the soft tissue architectural properties. In structures that lend themselves to ultrasound diagnosis, the advantages of ultrasound are that it is faster, more comfortable to the patient, readily available, economical and muscles and tendons can be studied in motion and in many different orientations; which makes ultrasound an attractive imaging modality for the evaluation of soft tissue damage. Ultrasound could have a role as an initial screening tool, offering the advantages of economy, speed, patient comfort, and interaction between patient and radiologist. There is need for an objective diagnostic procedure for the assessment of whiplash injuries and ultrasound looks promising. Future developments of the ideas formulated in this thesis are discussed in the concluding chapter.

# Chapter 10: Future Work

## *10.1 Chapter Summary*

This chapter considers the continuation of the research presented in this thesis. A discussion follows on the opportunity of establishing a whiplash clinic, the purpose of which is to recruit a large sample of whiplash patients for the assessment of their injury using diagnostic ultrasound. Results from this further study would be used to determine if ultrasound is a viable diagnostic tool for whiplash injury. Based on the author's experience; suggestions are made as to how this clinic could be implemented.

## *10.2 Setting Up a Whiplash Clinic*

Towards the final months of this project, the author issued a press release detailing the preliminary findings of this study revealing that ultrasound showed promise as a diagnostic tool for whiplash injury. This press release sparked great interest from the media which led to newspaper, magazine and radio coverage as well as a television appearance (*see Appendix J*). Following this, the author has been approached by leading insurance agencies keen to sponsor the continuation of this work. The author has also been contacted by a number of whiplash sufferers who have volunteered for future studies and have asked for advice on their condition.

There is still much work to be carried out before confirmation can be given that soft tissue injury is a component of the pathoanatomy of whiplash. Future work should concentrate on continuing the work of the pilot study by setting up a whiplash clinic before it can be concluded that ultrasound is a suitable means for assessing this type of injury. The establishment of a suitably located whiplash clinic would ensure that resources are available to review a large number of cases and particular to monitor the recovery of patients. The author has considered how the whiplash clinic could be devised based on their experience gained from the work presented in this thesis; and have included suggestions. This proposal is based on a full-time student undertaking this work as three years of research towards a PhD.

### *Organisation*

The study would be based at the Queen's Medical Centre, Accident and Emergency department. Providing the project with a permanent location will facilitate the smooth operation of the study. With a permanent location, project organisers are easily contactable, clinic times of operation can be defined; all of which avoids the ambiguity which could detract people from supporting and participating in this venture. The management of a large scale project such as this requires a dedicated specialised team. Suggestions of positions and the individual duties are detailed:

*Co-ordinator* - this is the role of the PhD student. They will be responsible for the general organisation of the clinic: recruitment of patients, organising documentation, patient recall for follow-up, provide a first point of contact for patients and medical professionals. To ensure a large scale awareness of the project, the co-ordinator will actively advertise the study via bulletins, telephone conversation, e-mail and visiting the parties involved as well as planning conference attendance in the relevant fields and encouraging media representation. To assist with patient recruitment and to gather a representative sample of whiplash sufferers, the co-ordinator will also source out whiplash patients from other hospitals, local surgeries, physiotherapists, chiropractors etc... A large volume of paperwork will be generated from this study and it is important that this is kept in good order.

*Clinical staff* - clinical staff with a research position will have this role. The experience of a clinical member of the hospital staff is an asset to the project; it is also a requirement of the ethical committee that they are present when the patient is examined. Clinicians will assess the patient and may undertake the ultrasound assessment under the initial guidance of a radiologist.

*Radiologist* - the project would benefit from the assistance of a team member with considerable experience of ultrasound imaging and imaging in general. It is possible that more subtle changes in ultrasound pathology have gone undetected in the pilot study that a more experienced ultrasound user would recognise. The assistance and advice of a radiologist will be sought at the start of the project, in order to train clinicians and the PhD student on how to take an ultrasound examination and analyse results. The radiologist will give input throughout the study to ensure image quality and analysis is of a high standard.

*Researcher* - this is another role of the PhD student. The assessment of the patient by one examiner is not an easy task. An assistant aids the efficiency of the assessment process. The researcher may undertake the ultrasound assessment under the initial guidance of a radiologist. The researcher will also be responsible for the analysis of results.

### *Sample selection*

At present, the study has access to patients attending the Queen's Medical Centre accident and emergency department, Nottingham, UK. Consideration should be given to the sample size available to the study. The onset of pain following a whiplash injury typically occurs twenty fours hours after the accident, therefore people are more likely to report this type of injury to their general practitioner than to an accident and emergency department. It could be that the pilot study missed a very important group, such as those reporting to general practitioners, chiropractors, physiotherapists etc... It is possible that by recruiting hospital patients who have recently been injured, there has not been enough time elapsed for injury signs to develop; for example, a haematoma typically takes twenty four hours to appear and therefore patients may be assessed too soon and give negative results.

Patients reporting to accident and emergency with an early onset of pain may be subjected to a different injury mechanism than those patients who develop pain later on. It is necessary to investigate whiplash patients from a variety of backgrounds and the co-ordinator will be responsible for actively involving other groups into the study. Collaboration with insurance companies may mean the project will have access to claimants for whiplash injuries.

The ideal situation is to have a before and after picture of a patient in order to define what is pathology caused by the accident and what was pre-existing; this investigation is clearly not possible; the exception being to subject volunteers to crash tests. A slightly less drastic measure may be to assess volunteers both pre and post participation of banger racing or bumper cars as these activities are said to produce similar forces and may provide further insight. Without creating injury simulation, examination of a large sample may allow identification of similar whiplash injury indicators; or give a normal range of injury dimensions, and once these have been identified; regular assessment of these pathologies may be made. If resolution of the pathology is found to correlate with resolution of symptoms (e.g. pain decrease and mobility increase) these findings may provide an indication of the pathoanatomy of whiplash.

A recommended sample size can not be suggested, as in the whiplash clinic a variety of injury mechanisms are being considered; these should be grouped accordingly and power analysis equations calculated on these pilot groups to ascertain the sample size needed.

When recruiting patients to the study, the injury mechanism should be considered. For the purpose of the thesis, only patients subjected to a rear-end impact were included due to the different effects of accident impact (*see Chapter 2*). The mechanism of the whiplash injury causes different muscle responses, it is possible that an impact from a specific direction could be more injurious or result in different injuries. A consideration for future studies is to include victims of a variety of injury mechanisms but define these in groups and compare outcomes.

The criterion for patients eligible for the whiplash clinic is that:

- the patient has been involved in a whiplash accident
- there are no time scale restrictions between accident and scan
- if the patient is recruited from a hospital visit, the treatment given by the hospital must be complete and the patient discharged before they may participate in the whiplash clinic

### *Equipment*

The assessment of different models of ultrasound equipment should be considered, the one used in this study was a basic unit and technology has moved on since the start of this study. The capabilities of different models of ultrasound equipment vary and it would be useful to see how they compare to enable verification of the universal application of this technique. Advanced systems have improved image quality but come at a higher cost. Although the newest systems are compact, many of the advanced systems are bulky and not readily portable.

### *Running the new clinic*

A successful study needs good patient recruitment and commitment and the continued support and interest of all parties involved. The first instance is to hold a meeting with all the relevant staff; porters, receptionists, nurses, doctors and consultants making them aware of the study, the procedures and the commitment required of them. Posters should be clearly displayed and contact details made clear. For many members of staff, participation in a research project of this type is additional work beyond their job description; and it is essential to make them aware how valuable their help and assistance is and that it is very much appreciated. New government guidelines have been implemented for patient turnaround time (Frank Coffey personal communication 2004) and this means that the study needs to take place efficiently. The time commitment required from patients in the pilot study was twenty to thirty minutes, however with the addition of questionnaires this time could take nearer fifty minutes; and it could be that a longer period could detract patients from participating. It must be remembered that often the patient has already been waiting in accident and emergency for two to four hours (Frank Coffey personal communication 2004). It may be possible to create incentives by offering monetary rewards to patients, although from experience most patients are uncomfortable and want to go home.

The requirement for patients to return for follow-up assessment relies on the patients 'good will'. In the pilot study, the patient was not compensated for their time or expenditures and maybe this is something that should be revised. It could be expected that patients who feel they have recovered are less likely to return than those still suffering with discomfort and are seeking treatment; and this may skew the results of the study. It is important that a large sample of patients are recruited to the study and that they return for follow-up as this gives the study validity and allows the documentation of the effect of recovery time.

### *Consideration of the existing pilot study protocol*

The protocol used in the pilot study proved successful in terms of the information acquired and time management. Modifications that could further improve the operation have been considered. Ethical approval has already been applied for and granted for the extension of the pilot study. Patients may now participate in follow-up assessments. When patients volunteer to participate in the study, it should be explained that they will be invited to return at three and six months for a follow-up visit and a letter will be sent arranging this time. The follow-up visits would comprise of repeating the initial assessment. It should be made clear that participation in the initial assessment would put them under no obligation to return for the follow-up assessments. The patient should also be made aware that they may leave the assessment at any point and do not have to give a reason for leaving.

### *Additional history and assessment questions*

For the purpose of the whiplash clinic, additional questions should be included. It is important to find out if the patient is litigating, as there is a possibility that litigation is linked to a patient's perception of injury. Patients should be asked to identify their dominant hand, which allow any correlation between this and the injury site to be established. A whiplash grading scale as advised by the Quebec Task Force group (Spitzer *et al.*, 1995) should be included for the clinician to assess the patients' injury according to this scale.

### *Functional outcome measures*

A collection of questionnaires is already included in the assessment of patients submitted to the spine ward. These questionnaires ascertain the patient's mental health, the patient's perception of their injury and their ability to carry out everyday functions. These questionnaires should be introduced to the study as a means of assessing the patients perceived state of health; this information can be assessed along with recovery. It is important that these questionnaires do not take up too much of the study time, and to complete all of these questionnaires is a lengthy task, therefore it may be possible to shortlist the questionnaires described. Patients may need assistance filling in questionnaires due to discomfort or for the explanation of questions.

Questionnaires to include (*see Appendix H*):

*Neck Assessment Form* - Queen's Medical Centre Spinal Unit Department in house questionnaire; used to collect patient history. Includes a diagram of the body so the patient may record where they are experiencing discomfort and to what extent.

*Neck Disability Index Questionnaire* - This ten item scaled questionnaire is used to assess disability caused by musculoskeletal pain by the assessment of the effect the condition has on the activities of daily living (Vernon and Moir 1991).

*Modified Somatic Perception Questionnaire (MSPQ)* - This questionnaire provides a scale to measure somatic and autonomic perception (Main 1983). It is a twenty two item four-point self-reporting scale, that when used in conjunction with measures for depressive symptoms would seem to be of considerable promise in the understanding of the sequelae of backache and is much more sensitive than traditional measures of personality structure (Main 1983).

*Modified Zung Index* - This test assesses clinical depression (Zung 1965). It is a self-rating depression scale consisting of twenty three items; covering positive and negative symptoms. When using the scale, the patients are asked to rate each of the twenty three items as to how it applied to them at the time of testing, in four quantitative terms: a little of the time, some of the time, a large part of the time, and most of the time. In scoring the test, a value of between one and four is assigned to a response, depending on whether the item was worded positively or negatively. The total score provides an indication of depression.

*Health Status Profile SF-36* - This health survey questionnaire measures health perception. This questionnaire is used to measure the effect of the 'problem' (in this case whiplash injury) on the health related quality of life (HRQOL) (Ware and Sherbourne 1992). The SF-36 contains thirty six items covering eight dimensions or subscales of perceived health: physical functioning, role limitations because of physical problems, bodily pain, general health perceptions, vitality, social functioning, role limitations because of emotional problems, and mental health. On all dimensions and scores, the possible range is 0-100, and higher scores reflect a higher HRQOL.

### *Scanning technique*

A systematic examination of the neck should be carried out. The subject should be seated with their head and cervical spine in a neutral anatomical position, facing forwards with a straight spine. The C7 spinous process can be used as a palpable reference point. The superior limit is represented by the palpable occipital process. The neck is then imaged systematically based on the anatomical triangles. The neck should be examined for signs of injury, such as haematoma, muscle tear and swelling. Images should be captured if a musculoskeletal pathology is identified otherwise images should be taken from the site of pain determined by the patient. Contralateral images should be acquired to facilitate comparison of the injury with an allegedly injury free side. On completing the scan, patient's should grade the level of comfort they felt during the scanning process on a scale from 0 (no discomfort) to 5 (intolerable). Grading should be carried out in private, as asking the patient directly may not reflect their true opinion. It must be noted if any radiography has been conducted on the patient, this information could be used to obtain further information about the injury and compared to ultrasound scans.

### *Assessment of subject stature*

The impact of stature on the quality of ultrasound images is significant. Measurements should be made of the patient's height and weight to assess the effect of Body Mass Index (BMI) on scanning feasibility, image quality, structure identification, measurement and clinical outcomes. A consideration to assessing BMI is it provides an average calculation, it does not account for muscle or fat bulk in specific areas. Measurements of muscle and fat thickness should be made using the ultrasound machines callipers and this approach may yield results that are more representative.

### *Method to record injury site: quantification and documentation*

It is important to be able to document the extent of injury so this may be monitored at follow-up. Ideas suggesting how injury can be recorded and quantified have been put forward in the quantification section (*see Chapter* 2). These ideas should now be put into practise and if they prove suitable, they should be used as a standard. When put into practice in the study, it may be found that a different approach is needed to record and monitor pathological changes in patients, and that a different method of quantification needs to be developed. It is recommended that a reference system be used to record the site scanned at the initial assessment, dimension measurements are taken and recorded so that objective reviews at subsequent assessments can be made. The external acoustic meatus (ear hole) provides a readily identifiable consistent landmark that may be used as a reference point. A grid reference measurement of where the transducer was positioned in relation to the external acoustic meatus can be recorded, e.g. 12cm below the ear, 3cm to the left edge of the transducer.

Investigation should be conducted into how the skill of the operator affects assessment and if the assessment can be simplified to a level where only basic skills are required. If it is established that it is a simple assessment, perhaps nurses could do this as a first line approach and thus save time and the cost of using techniques that are more expensive. The minimal time needed for this initial assessment could help meet government turn around times.

### *Funding*

Collaboration with insurance companies could provide a source of funding for this project and interest from major insurance providers has been shown since the publication of the pilot study results. Insurance companies participating in the study may provide another source of subjects for the study.

### *Time considerations*

On average five patients a day report to accident and emergency with injuries relating to whiplash. This figure is based on an audit of the accident and emergency department's database of reasons for patients attending. The time scale for assessment of patients has been considered (*see Table 9*). It is feasible that seven patients could be assessed each day based on a seven hour day.

**Table 9: Assessment time scale**

| Task | Time |
|---|---|
| Introduction to the project | 10 min |
| History and physical assessment | 10 min |
| Ultrasound assessment | 10 min |
| Questionnaires | 15 min |
| Debrief | 5 min |
| TOTAL | 50 min |

### *Equipment consideration*

#### *Advances in technology*

The ultrasound machine used for this study represented a basic ultrasound device. Other ultrasound devices have greater technologies and their implementation to this study should be considered. Advanced devices have the ability to perform spatial compounding. Spatial compounding averages the frames that view anatomy from different angles. An electronic beam steers the transducer array to acquire rapidly several (e.g. three to nine) overlapping scans of an object from different view angles (Entrekin *et al.*, 2001). These single-angle scans are averaged to form a multi-angle compound image that is updated in real time with each subsequent scan. Real-time spatial compound imaging reinforces real structural information and reduces inherent ultrasound artefacts e.g. speckle and acoustic drop out from anisotropic specular structures. This leads to improved visualisation of pathology such as partial thickness tears, small fluid collections and inflammation that may otherwise appear ambiguous with conventional ultrasound. This would enhance the operator's ability to view any soft tissue injuries produced from a whiplash injury. To overcome the limitations of imaging people of a large stature, a machine with harmonic imaging capabilities could be employed. Harmonic imaging is a signal processing technique that minimises noise and improves signal to noise ratio having the effect of reducing artefact.

*Equipment calibration*

It is important that ultrasound equipment is calibrated to ensure reliable and accurate quantification and diagnosis. This is especially important in a study that focuses on quantification. Regular calibration checks of the equipment should be made using an ultrasound phantom.

## *10.3 Chapter Discussion*

The work completed in the thesis to date has been of major interest to the public. This thesis has laid the foundation for the protocol for a diagnostic technique for whiplash using ultrasound; and it is important that this work is continued by assessing this technique on a larger sample. A suggestion has been made as to how a whiplash clinic may be organised based on the information from this thesis and experience of the author. The author has thoroughly enjoyed working on this project and they are excited by the promising results of this thesis. The author sincerely hopes that this research is continued and challenges researchers to develop a means to investigate further the pathoanatomy of whiplash and identify a diagnostic technique. It would be fantastic if this work goes some way to benefiting many of those individuals who are affected by whiplash injury.

## References

**Adriani E, Mariani PP, Maresca G, Santori N (1995)** Healing of the patellar tendon after harvesting of its mid-third for anterior cruciate ligament reconstruction and evolution of the unclosed donor site defect. *Knee Surgrey, Sports Traumatology, Arthroscopy.* 3(3):138-143

**Ahuja A and Ying M (2002)** An overview of neck node sonography. *Investigative Radiology.* 37(6): 333-342

**Aldman B (1986)** "An Analytical Approach to the Impact Biomechanics of Head and Neck", Proceedings of the 30th Annual AAAM Conference. pp 439-454

**Allen GM and Wilson DJ (2001)** Ultrasound of the shoulder. *European Journal of Ultrasound.* 14(1): 3-9

**American Institute of Ultrasound in Medicine (1994).** Medical ultrasound safety. Part one: bioeffects and biophysics; part two: prudent use; part three: implementing ALARA. USA.

**Baatenburg de Jong RJ, Rongen RJ, Laméris JS, Knegt P, Verwoerd CDA (1993)** Evaluation of branchiogenic cysts by ultrasound. *Journal for Otorhinolaryngology and its Related Specialities.* 55: 294-298

**Balint PV and Sturrock RD (2001)** Intraobserver repeatability and interobserver reproducibility in musculoskeletal ultrasound imaging measurements. *Clinical and Experimental Rheumatology.* 19: 89-92

**Barnsley L, Lord SM, Wallis BJ (1995)** The prevalence of chronic cervical zygapophyseal joint pain after whiplash. *Spine.* 20(1): 20-25

**Baum U, Greess H, Lell M, Nomayr A, Lenz M (2000)** Imaging of head and neck tumors - methods: CT, spiral-CT, multislice-spiral-CT. *European Journal of Radiology.* **33(3):** 153-160

**Bemben MG (2002)** Use of Diagnostic Ultrasound for Assessing Muscle Size. *The Journal of Strength and Conditioning Research.* **16(1):** 103-108

**Berg LC, Nielsen JV, Thoefner MB, Thomsen PD (2003)** Ultrasonography of the equine cervical region: a descriptive study in eight horses. *Equine Veterinary Journal.* **35(7):** 647-655

**Bertram S, Bodner G, Rudisch A, Brandlmaier I, Emshoff R (2003)** Effect of scanning level and muscle condition on ultrasonographic cross-sectional measurements of the anterior masseter muscle. *Journal of Oral Rehabilitation.* **30:** 430-435

**Bianchi S, Martinoli C, Sureda D, Rizzatto G (2001)** Ultrasound of the hand. *European Journal of Ultrasound.* **14(1):** 29-34

**Bianchi S, Martinoli C, Bianchi-Zamorani M, Valle M (2002)** Ultrasound of the joints. *European Radiology.* **12:** 56-61

**Birch HL, Bailey AJ, Goodship AE (1998)** Macroscopic 'degeneration' of equine superficial digital flexor tendon is accompanied by a change in extracellular matrix composition. *Equine Veterinary Journal.* **30:** 534-539

**Bleakney R, Maffulli N (2002)** Ultrasound changes to intramuscular architecture of the quadriceps following intramedullary nailing. *The Journal of Sports Medicine and Physical Fitness.* **42(1):** 120-125

**Boden SD, McCowin PR, Davis DO, Dina TS, Mark AS, Wiesel S (1990)** Abnormal magnetic-resonance scans of the cervical spine in asymptomatic subjects: a prospective investigation. *The Journal of Bone and Joint Surgery.* **72A(8):** 1178-1184

**Bogduk N (1986)** The anatomy and pathophysiology of whiplash. *Clinical Biomechanics.* 92-101

**Borchgrevink G, Smevik O, Haave I, Haraldseth O, Nordby A, Lereim I (1997)** MRI of cerebrum and cervical columna within two days after whiplash neck sprain injury. *Injury.* **28:** 331-335

**Brault JR., Siegmund GP, Wheeler JB (2000)** Cervical muscle response during whiplash: evidence of a lengthening muscle contraction. *Clinical Biomechanics.* 15: 426-435

**Cailliet R (1991)** Neck and Arm Pain. 3rd edition. Philadelphia: FA Davis.

**Chang CY, Wang SF, Chiou HJ, Ma HL, Sun YC, Wu HD (2002)** Comparison of shoulder ultrasound and MR imaging in diagnosing full-thickness rotator cuff tears. *Journal of Clinical Imaging.* **26(1):** 50-54

**Claudon M, Tranquart F, Evans DH, Lefèvre F, Correas JM (2002)** Advances in ultrasound. *European Radiology.* **12:** 7-18

**Clemens HJ, Burrow K** Experimental investigation on injury mechanisms of cervical spine at frontal and rear-front vehicle impacts. Proceedings of the Sixteenth Stapp Car Crash Conference, 1972; 76-104.

**Cloward RB (1959)** Cervical Diskography: A contribution to the Etiology and Mechanism of Neck, Shoulder and Arm Pain. *Annals of Surgery.* **150(6):** 1052-1064

**Coffey, Frank** personal communication 2003.

**Crass JR, van de Vegte GL, Harkavy LA (1988)** Tendon echogenicity: ex vivo study. *Radiology*. **167:** 499-501

**Crowe HE:** Injuries to the cervical spine. Paper presented at the meeting of the Western Orthopaedic Association, San Francisco, 1928.

**Curry TS, Dowdey JE, Murray RC Jr.** Christensen's Physics of Diagnostic Radiology, 4th edition. Philadelphia, Lea and Febiger, 1990.

**Davis SJ, Teresi LM, Bradley WG, Ziemba MA, Bloze AE (1991)** Cervical spine hyperextension injuries: MR findings. *Radiology*. **180:** 245-251

**Deans GT, McGalliard JN, Rutherford WH (1986)** Incidence and duration of neck pain among patients injured in car accidents. *British Medical Journal*. **292:** 94-95

**Deng YC and Goldsmith W (1987)** Response of a human head/neck/upper-torso replica to dynamic loading, I: physical model. *Journal of Biomechanics*. **20(5):** 471-486

**Deng B, Begeman PC, Yang KH, Tashman S, King AI (2000)** Kinematics of human cadaver cervical spine during low speed rear-end impacts. *Stapp Car Crash Journal*. **44:** 171-188

**Department for Transport** personal communication 2004.

**Devor ST and Faulkner JA (1999)** Regeneration of new fibers in muscles of old rats reduces contraction-induced injury. *Journal of Applied Physiology*. **87(2):** 750-756

**Duerinckx AJ, Yu WD, El-Saden S, Kim D, Wang JC, Sandhu HS (1999)** MR imaging of the cervical spine motion with HASTE. *Magnetic Resonance Imaging*. **17(3)**: 371-381

**Dunn EJ and Blazar S (1987)** Soft-tissue injuries of the lower cervical spine, instructional course lectures. Griffin PP, ed. *The Journal of the American Academy of Orthopaedic Surgeons*. **36**: 499-512

**El-Khoury GY, Kathol MH, Daniel WW (1995)** Imaging of acute injuries of the cervical spine: Value of plain radiography, CTR, and MR imaging. *American Journal of Roentgenology*. **164**: 43-50

**Emshoff R, Bertram S, Strobl H (1999)** Ultrasonographic cross-sectional characteristics of muscles of the head and neck. *Oral Surgery, Oral Medicine, Oral Pathology, Oral Radiology and Endodontics*. **87(1)**: 93-106

**Emshoff R, Emshoff I, Rudisch A, Bertram S (2003)** Reliability and temporal variation of masseter muscle thickness measurements utilizing ultrasonography. *Journal of Oral Rehabilitation*. **30**: 1168-1172

**Entrekin EE, Porter BA, Sillesen HH, Wong AD, Cooperberg PL, Fix CH (2001)** Real-time spatial compound imaging: application to breast, vascular, and musculoskeletal ultrasound. *Seminars in Ultrasound, CT, and MRI*. **22**: 50-64

**Fornage BD (1988)** Peripheral nerves of the extremities: imaging with US. *Radiology*. **167**: 179-182

**Foster, Stuart.** personal communication 2004.

**Galasko, Charles.** Personal communication 2004.

**Garcia T, Hornof WJ, Insana MF (2003)** On the ultrasonic properties of tendon. *Ultrasound in Medicine and Biology.* 29(12): 1787-1797

**Gillis C, Sharkey N, Stover SM, Pool RR, Meagher DM, Willits N (1995a)** Effect of maturation and aging on material and ultrasonographic properties of equines superficial digital flexor tendon. *American Journal of Veterinary Research.* 56(10): 1345-1350

**Gillis C, Sharkey N, Stover SM, Pool RR, Meagher DM, Willits N (1995b)** Ultrasonography as a method to determine tendon cross-sectional area. *American Journal of Veterinary Research.* 56(10): 1270-1274

**Goldthwaite JE (1911)** The lumbosacral articulation: an explanation of many cases of lumbago, sciatica and paraplegia. *The Boston Medical and Surgery Journal.* 164: 356-372

**Goodwin DW (2000)** Imaging of the Achilles' tendon. *Foot Ankle Clinics.* 5(1): 135-148

**Grassi W, Filippucci E, Farina A, Cervini C (2002)** Sonographic imaging of tendons. *Arthritis and Rheumatism.* 43(5): 969-976

**Griffiths H (1998)** The radiological aspects of whiplash. International Symposium: Whiplash '98, p21 Compendium of Abstracts.

**Hagen-Ansert SL.** Textbook of Diagnostic Ultrasonography, 3rd edition. St. Louis, CV Mosby, 1989.

**Haralick RM, Shanmugam K and Dinstein I (1973)** Textural features for image classification. *IEEE Transactions on Systems, Man, and Cybernetics.* Volume SMC 3, no 6.

**Healy JC (2002)** The value of ultrasound in sports medicine. *Hospital Medicine.* **63(10):** 593-597

**Heckmatt JZ and Dubowitz (1988)** Real-time ultrasound imaging of muscles. *Muscle and Nerve.* **11:** 56-65

**Henegar MM, Vollmer DG, Silbergeld DL (1996)** Intraoperative transligamentous ultrasound in the evaluation of thoracic intraspinal disease. *Technique Spine.* **21(1):** 124-127

**Hides JA, Richardson CA, Jull GA (1995)** Magnetic resonance imaging and ultrasonography of the lumbar multifidus muscle. Comparison of two different modalities. *Spine.* **20(1):** 54-58

**Hodgson DR, Rose RJ (1994)** The Athletic Horse: Principles and Practise of Equine Medicine. Chapter14B: Diagnostic imaging in the athletic horse: musculoskeletal ultrasonography pp297-326. Philadelphia: WB Saunders Company.

**Hollenberg GM, Adams MJ, Weinberg EP (2000)** Sonographic appearances of nonoperatively treated Achilles tendon ruptures. *Skeletal Radiology.* **29(5):** 259-264

**Howry DH and Bliss WR (1952)** Ultrasonic visualization of soft tissue structures of the body. *The Journal of Laboratory and Clinical Medicine.* **40:** 579-592

**Howry DH, Stott DA, Bliss WR (1954)** The ultrasonic visualization of carcinoma of the breast and other soft-tissue structures. *Cancer.* **7(2):** 354-358

**Hudson M (1998)** '*Sports Therapy: A Practical Approach*' Stanley Thornes Ltd. Pp28-39

**Jacobson JA and van Holsbeeck MT (1998)** Musculoskeletal ultrasonography. *The Orthopedic Clinics of North America.* **29:** 135-167

**Jacobson JA (1999)** Musculoskeletal sonography and MR imaging: a role for both imaging methods. *Radiologic Clinics of North America.* **37:** 713-735

**Jeffreys E and McSweeney T (1980)** Disorders of the Cervical Spine. London: Butterworth.

**Johnson G (1996)** Hyperextension soft tissue injuries of the cervical spine: A review. *Journal of Accident and Emergency Medicine.* **13:** 3-8

**Jones DA, Newham DJ, Round JM, Tolfree SEJ (1986)** Experimental human muscle damage: morphological changes in relation to other indicies of damage. *Journal of Physiology.* **375:** 435-448

**Jones, Rhodri** personal communication 2004.

**Jónsson H Jr, Bring G, Rauschning W, Sahlstedt B (1991)** Hidden cervical spine injuries in traffic accident victims with skull fractures. *Journal of Spinal Disorders.* 4(3): 251-263

**Kaneoka K, Ono K, Inami S, Hayashi K (1999)** Motion analysis of cervical vertebrae during whiplash loading. *Spine.* **24:** 763-770

**Kaariainen M, Kaariainen J, Jarvinen TL, Nissinen L, Heino J, Jarvinen M, Kalimo H (2000)** Integrin and dystrophin associated adhesion protein complexes during regeneration of shearing-type muscle injury. *Neuromuscular Disorders.* **10(2):** 121-132

**Kaempffe FA and Lerner RM (1996)** Ultrasound diagnosis of triceps tendon rupture. A report of 2 cases. *Clinical Orthopaedics and Related Research.* **332:** 138-142

**Kendall BE.** Chapter 55: Neuroradiology of the spine. In: Sutton D. Textbook of Radiology and Imaging, vol 2. New York: Churchill Livingstone, 1998:1489-1526

**Kerslake, Robert** personal communication 2004.

**Kim HJ, Ryu KN, Sung DW, Park YK (2002)** Correlation between sonographic and pathologic findings in muscle injury: experimental study in the rabbit. *Journal of Ultrasound in Medicine.* 21: 1113-1119

**Kirsch GA and Poirier V** *Ultrasound valuable in detecting whiplash and low back pain.* International Neurosonology '97. August 16th 1997.

**Klauser A, Stadlbauer KH, Frauscher F, Herold M, Klima G, Schirmer and zur Nedden (2004)** Value of transducer positions in the measurement of finger flexor tendon thickness by sonography. *Journal of Ultrasound in Medicine.* 23: 331-337

**Kneeland J (1997)** MR imaging of muscle and tendon injury. *European Journal of Radiology.* 25: 199-208

**Krakenes J, Kaale BR, Moen G, Nordli H, Gilhus NE and Rorvik J (2002)** MRI assessment of the alar ligaments in the late stage of whiplash injury - a study of structural abnormalities and observer agreement. *Neuroradiology.* 44(7): 617-624

**Kremkau FW.** Diagnostic Ultrasound: Principles and Instruments, 4th edition. Philadelphia, WB Saunders, 1993.

**Kremkau FW.** Diagnostic Ultrasound: Principles and Instruments, 6th edition. Philadelphia, WB Saunders, 2002.

**Kristjansson E (2004)** Reliability of ultrasonography for the cervical multifidus muscle in asymptomatic and symptomatic subjects. *Manual Therapy.* 9(2): 83-88

**Küllmer K, Sievers KW, Rompe JD, Nägele M, Harland U (1997)** Sonography and MRI of experimental muscle injuries. *Archives in Orthopaedic and Trauma Surgery.* **116:** 357-361

**Kumar S, Narayan Y, Amell T (2002)** An electromyographic study of low-velocity rear-end impacts. *Spine.* **27:** 1044-1055

**Kumar S, Ferrari R, Narayan Y (2004a)** Cervical muscle response to right posterolateral impacts. *Clinical Biomechanics.* **19:** 543-550

**Kumar S, Ferrari R, Narayan Y (2004b)** Cervical muscle response to posterolateral impacts - effect of head rotation. *Clinical Biomechanics.* **19:** 899-905

**LaBan MM (1990)** Whiplash: Its evaluation and treatment. *Physical Medicine and Rehabilitation: State of the Art Reviews.* **4(2):** 293-307

**Lam WWM, Ai V, Wong V, Lui W, Chan F, Leong L (2004)** Ultrasound measurement of lumbosacral spine in children. *Pediatric Neurology.* **30(2):** 115-121

**Laméris JS (1993)** Color-flow imaging of the head and neck region. *Journal for Otorhinolaryngology and its Related Specialities.* **55(5):** 281-283

**Ledsome JR, Lessoway V, Susak LE, Gagnon FA, Gagnon R, Wing PC (1996)** Diurnal changes in lumbar intervertebral distance, measured using ultrasound. *Spine.* **21(14):** 1671-1675

**Lee D and Bouffard A (2001)** Ultrasound of the knee. *European Journal of Ultrasound.* **14(1):** 57-71

**Lehto M and Alanen A (1987)** Healing of a muscle trauma: correlation of sonographical and histological findings in an experimental study in rats. *Journal of Ultrasound in Medicine.* **6:** 425-429

**Lin J, Fessell DP, Jacobson JA, Weadock WJ, Hayes CW (2000)** An illustrated tutorial of musculoskeletal sonography: Part 1, Introduction and general principles. *American Journal of Roentgenology.* **175:** 637-645

**Lindequist S, Larsen C, Daa Schrøder H (1990)** Ultrasound guided needle biopsy of skeletal muscle in neuromuscular disease. *Acta Radiologica.* **31(4):** 411-413

**Luan F, Yang KH, Deng B, Begeman PC, Tashman S, King AI (2000)** Qualitative analysis of neck kinematics during low-speed rear end impact. *Clinical Biomechanics.* **15:** 649-657

**Maag U, Desjardins D, Bourbeau R, Laberge-Nadeau C (1990)** In: Seat belts and neck injuries. Program of the International Research Committee on the Biomechanics of Impacts; Bron, France; 1990: 1-13.

**Macnab I (1964)** Acceleration injuries of the cervical spine. *Journal of Bone and Joint Surgery America.* **46:** 1797-1799

**MacNab, I. (1965)** "Whiplash Injuries Of The Neck" American Association for Automotive Medicine.

**MacNab I (1971)** The "whiplash syndrome". *Orthopedic Clinics of North America.* **2(2):** 389-403

**Main CJ (1983)** The Modified Somatic Perception Questionnaire (MSPQ). Journal of *Psychosomatic Research.* **27(6):** 503-14

**Marr CM, McMillan I, Boyd JS, Wright NG, Murray M (1993)** Ultrasonographic and histopathological findings in equine superficial digital flexor tendon injury. *Equine Veterinary Journal.* 25(1): 23-29

**Martinez JL and Garcia DJ (1968)** A model for whiplash. *Journal of Biomechanics.* 1: 23-32

**Martino F, Ettorre GC, Cafaro E, Macarini L, Bancale R, Sion E (1992)** L'ecografia muscolo-tendinea nei trauma distorsivi acuti del collo. *La Radiologia Medica.* 83: 211-215

**Martinoli C, Derchi LE, Pastorino C, Bertolotto M, Silvestri E (1993)** Analysis of echotexture of tendons with US. *Radiology.* 186: 839-843

**Martinoli C, Bianchi S, Zamorani MP, Zunzunegui JL, Derchi LE (2001)** Ultrasound of the elbow. *European Journal of Ultrasound.* 14(1): 21-27

**Martinoli C, Bianchi S, Dahmane M, Pugliese F, Bianchi-Zamorani M, Valle M (2002)** Ultrasound of tendons and nerves. *European Radiology.* 12: 44-55

**Mattoon JS, Tod Dorst W, Grguric MR, Auld DM, Reed SM (2004)** Technique for equine cervical articular process joint injection. *Veterinary Radiology and Ultrasound.* 45(3): 238-240

**Maurits NM, Bollen AE, Windhausen A, De Jager AEJ, Van Der Hoeven JH (2003)** Muscle ultrasound analysis: normal values and differentiation between myopathies and neuropathies. *Ultrasound in Medicine and Biology.* 29(2): 215-225

**McDicken WM (1991)** Diagnostic Ultrasonics: Principles and use of instruments. 3rd edition. Chapter 12: Performance of real-time B-scan instruments p139-p152. Churchill Livingstone, Medical Division of Longman Group UK Limited.

**McIvor NP, Freeman JL, Salem S (1993)** Ultrasonography of the thyroid and parathyroid glands. *Journal for Otorhinolaryngology and its Related Specialities.* **55(5):** 303-308

**McNally DS, Naish C, Halliwell M (2000)** Intervertebral disc structure: observation by a novel use of ultrasound imaging. *Ultrasound in Medicine and Biology.* **26(5):** 751-758

**McNally EG (2002)** Musculoskeletal ultrasound. *Current Orthopaedics.* **16:** 49-56

**Micklethwaite L, Wood AKW, Sehgal CM, Polansky M, Dowling BA, Dart AJ, Rose RJ, Hodgson DR (2001)** Use of quantitative analysis of sonographic brightness for detection of early healing of tendon injury in horses. *American Journal of Veterinary Research.* **62(8):** 1320-1327

**Möller M, Kälebo P, Tidebrant G, Movin T, Karlsson J (2002)** The ultrasonographic appearance of the ruptured Achilles tendon during healing: a longitudinal evaluation of surgical and nonsurgical treatment, with comparisons to MRI appearance. *Knee Surgery, Sports Traumatology, Arthroscopy.* **10(1):** 49-56

**Murphy MJ and Lieponis JV.** Nonoperative treatment of cervical spine pain. In: Sherk HH, Dunn EJ, Eismont FJ, Fielding JW, Long DM, Ono K, Penning L, Raynor R, eds. The Cervical Spine (2nd Ed). Philadelphia: JB Lippincott Company, 1989:670-677.

**Nagele M, Kock W, Woll B, Reiser M (1992)** Dynamic functional MR of the cervical vertebral column. *RöFo: Fortschritte auf dem Gebiete der Rontgenstrahlen und der Nuklearmedizin.* **157:** 222-228

**Naish C, Mitchell R, Innes J, Halliwell M, McNally D (2003)** Ultrasound imaging of the intervertebral disc. *Spine.* **28(2):** 107-113

**Nazarian LN, Zegel HG, Gilbert KR, Edell SL, Bakst BL, Goldberg BB (1998)** Paraspinal Ultrasonography: Lack of Accuracy in Evaluating Patients with Cervical or Lumbar Back Pain. **17(2): 117-122**

**Nielsen JV, Berg LC, Thoefner MB, Thomson PD (2003)** Accuracy of ultrasound-guided intra-articular injection of cervical facet joints in horses: a cadaveric study. *Equine Veterinary Journal*. 35(7): 657-661

**Nordhoff LS (1996)** Motor Vehicle Collision Injuries: Mechanisms, Diagnosis, and Management. Aspen Publishers Inc. Gaithersburg, Maryland, USA.

**Olney DB, Marsen AK (1986)** The effect of head restraints and seat belts on the incidence of neck injury in car accidents. *Injury*. 17: 365-367

**Ono K, Kaneoka K, Wittek A, Kajzer J:** Cervical injury mechanism based on the analysis of human cervical vertebral motion and head-neck-torso kinematics during low speed rear impacts. Lake Buena Vista, FL, 41st Annual Stapp Car Crash Conference, Society of Automotive Engineers, paper no. 973340, November 1997.

**Otremski I, Marsh JL, Wilde BR, McLardy Smith PD, Newman RJ (1989)** Soft tissue cervical spinal injuries in motor vehicle accidents. *Injury*. 20: 349-351

**Panjabi MM (1998)** Cervical spine models for biomechanical research. *Spine*. 23: 2684-2700

**PartnerRe Ltd: technical author: Emil Bergundthal, Sara Thomas (November 2000)** "Whiplash Injury: A Growing Concern for Many Motor Liability Insurers" www.partnerre.com/pdf/whiplash.pdf

Peetrons P, Rasmussen OS, Creteur V, Chhem RK (2001) Ultrasound of the shoulder joint: non 'rotator cuff' lesions. *European Journal of Ultrasound.* 14(1): 11-19

Peetrons P (2002) Ultrasound of muscles. *European Radiology.* 12(1): 35-43

Pickersgill CH, Marr CM, Reid SWJ (2001) Repeatability of diagnostic ultrasonography in the assessment of the equine superficial digital flexor tendon. *Equine Veterinary Journal.* 33(1): 33-37

Porter RW, Hibbert C, Wellman P (1980) Backache and the lumber spinal canal. *Spine.* 5(2): 99-105

Pugh CR (1993) A simple method to document the location of ultrasonographically detected equine tendon lesions. *Veterinary Radiology and Ultrasound.* 34: 211-212

Raghavendra BN and Epstein FJ (1985) Sonography of the spine and spinal cord. *Radiologic Clinics of North America.* 23(1): 91-105

Raynor RB (1997) Intraoperative ultrasound for immediate evaluation of anterior cervical decompression and discectomy. *Spine.* 22(4): 389-395

Reimers K, Reimers CD, Wagner S, Paetzke I, Pongratz DE (1993) Skeletal muscle sonography: a correlative study of echogenicity and morphology. *Journal of Ultrasound in Medicine.* 2: 73-77

Revell J, Mirmehdi M and McNally D. Strain quantification in ultrasound sequences. In: 14th British Machine Vision Conference, pages 359-368. BMVA Press, September 2003.

**Revell J, Mirmehdi M and McNally D.** Computer Vision Elastography: Speckle adaptive motion estimation for elastography using ultrasound sequences. Accepted in IEEE Transactions in Medical Imaging, 2004. *In press*

**Ronnen HR, de Korte PJ, Brink PRG, van der Bijl HJ, Tonino AJ, Franke CL (1996)** Acute Whiplash Injury: Is There a Role for MR Imaging? - A Prospective Study of 100 Patients. *Radiology*. **201(1):** 93-96

**Severy DM, Mathewson JH, Bechtol CO (1955)** Controlled automobile rear-end collisions, an investigation of related engineering and medical phenomena. *Canadian Services Medical Journal*. **11:** 727-759

**Scholten RR, Pillen S, Verrips A, Zwarts MJ (2003)** Quantitative ultrasonography of skeletal muscles in children: normal values. *Muscle and Nerve*. **27:** 693-698

**Schwartz RG, Rohan J, Hayden F (1999)** Diagnostic paraspinal musculoskeletal ultrasonography. *Journal of Back and Musculoskeletal Rehabilitation*. **12:** 25-33

**Schwartz GF and Feig SA (2002)** Nonpalpable breast lesions: Biopsy methods and patient management. *Obstetrics and Gynecology Clinics of North America*. **29(1):** 137-157

**Silvestri E, Martinoli C, Derchi LE, Bertolotto M, Chiarmondia M, Rosenberg I (1995)** Echotexture of peripheral nerves: correlation between US and histologic findings and criteria to differentiate tendons. *Radiology*. **197:** 291-296

**Soltani AR, Kallinen M, Mälkiä E, Vihko V (1996)** Ultrasonography of the neck splenius capitis muscle. *Acta Radiologica*. **37:** 647-650

**Som PM (1997)** The present controversy over the imaging method of choice for evaluating the soft tissue of the neck. *American Journal of* Neuroradiology. **18(10):** 1869-1872

**Spitzer WO, Skovron ML, Salami LR, Cassidy JD, Duranceau J, Suissa S, Zeiss E (1995)** Scientific monograph of the Quebec Task Force on Whiplash-Associated Disorders: redefining "whiplash" and its management [see comments] [published erratum appears in Spine 20: 2372, 1995. Spine 20 (8 suppl): 1S-73S, 1995.

**Stauber WT and Smith CA (1998)** Cellular responses in exertion-induced skeletal muscle injury. *Molecular and Cellular Biochemistry.* **179:** 189-196

**Steindler A and Luck JV (1938)** Differential diagnosis of pain in the low back: allocation of the source of pain by procaine hydrochloride method. *The Journal of the American Medical Association.* **110:** 106-113

**Stipkovich LN (1994)** Musculoskeletal ultrasonographic examination of the cervical spine and surrounding tissue including normal lymph nodes. *Journal of the American Chiropractic Association.* **31:** 33-37

**Svensson MY, Aldman B, Hansson HA, Lövsund P, Seeman T, Suneson A, Öertengren T (1993)** Pressure effects in the Spinal Canal During Whiplash Extension Motion: A Possible Cause of Injury to the Cervical Spinal Ganglia. Proceedings of the IRCOBI Conference on the biomechanics of impacts. Eindhoven, Netherlands: 189-200.

**Teitz CC, Garrett WE, Miniachi A, Lee MH, Mann RA (1997)** Tendon problems in athletic individuals. *Journal of Bone and Joint Surgery.* **79A:** 138-152

**Tervonen O, Lahde S, Vanharanta H (1991)** Ultrasound diagnosis of lumbar disc degeneration: comparison with computed tomogramphy/discography. *Spine.* **16(8):** 951-954

**Tidball JG, Salem G, Zernicke R (1993)** Site and mechanical conditions for failure of skeletal muscle in experimental strain injuries. *Journal of Applied Physiology.* 74(3): 1280-1286

**Tsuchisashi M, Nishikawa S, Mii K (1981)** Road traffic accidents and the abbreviated injury scale (AIS) in Japan. *Accident, Analaysis and Prevention.* 13: 37-42

**Unterharnscheidt F (1986)** Pathological and neurological findings in rhesus monkeys subjected to -Gx and +Gx indirect impact acceleration. In: Sances A Jr, Thomas DJ, Ewing CL, et al., eds. Mechanisms of Head and Spine Trauma. Goshen, NY: Aloray Publisher; 1986; 565-663.

**Vernon H and Mior S (1991)** The neck disability index: A study of reliability and validity. *Journal of Manipulative and Physiological Therapeutics.* 14(7): 409-415

**Versteegen GJ, Kingma J, Meijler WJ, ten Duis HJ (2000)** Neck sprain after motor vehicle accidents in drivers and passenegers. *European Spine Journal.* 9: 547-552

**Volle E, Assheuer J, Hedde JP, Gustorf-Aeckerle R (1992)** Radicular avulsion resulting from spinal injury: Assessment of diagnostic modalities. *Neuroradiology.* 34: 235-240

**Voyvodic F, Dolinis J, Moore VM, Ryan GA, Slavotinek JP, Whyte AM, Hoile RD, Taylor GW (1997)** MRI of car occupants with whiplash injury. *Neuroradiology.* 39: 35-40

**Ware JJ and Sherbourne CD (1992)** The MOS 36-item short-form health survey (SF-36). I. Conceptual framework and item selection. *Medical Care.* 30: 473-83

**Watkin KL, Diouf I, Gallagher TM, Logemann JA, Rademaker AW, Ettema SL (2001)** Ultrasonic quantification of geniohyoid cross-sectional area and tissue composition: a preliminary study of age and radiation effects. *Head and Neck.* 23: 467-474

**Weiss GM (1996)** Spinal ultrasound: Clinical correlation of spinal ultrasound and MRI. *American Journal of Pain Management*. 6(4): 123-126

**Weng L, Tirumalai AP, Lowery CM, Nock LF, Gustafson DE, Von Behren PL, Kim JH (1997)** US extended-field-of-view imaging technology. *Radiology*. 203(3): 877-880

**Whittingham TA (1997)** New and future developments in ultrasonic imaging. *British Journal of Radiology*. 70: S119-S132

**Wild JJ (1950)** The use of ultrasonic pulses for the measurement of biologic tissues and the detection of tissue density changes. *Surgery*. 27:183-88

**Williams IF, Craig AS, Parry DAD, Goodship AE, Shah J, Silver IA (1985)** Development of collagen fibril organization and collagen crimp healing patterns during tendon healing. *International Journal of Biological Macromolecules*. 7: 275-282

**Wilmink JT and Patijn J (2001)** MR imaging of alar ligament in whiplash-associated disorders: an observer study. *Neuroradiology*. 43: 859-863

**Yang KH and Begeman PC (1996)** A Proposed Role for Facet Joints in Neck Pain in Low to Moderate Speed Rear End Impacts Part I: Biomechanics. 6th Injury Prevention Through Biomechanics Symposium: 59-63.

**Ying M, Yeung E, Li B, Li W, Lui M, Tsoi C (2003)** Sonographic evaluation of the size of Achilles tendon: the effect of exercise and dominance of the ankle. *Ultrasound in Medicine and Biology*. 29(5): 637-642

Yoganandan N, Pintar FA, Haffner M. Epidemiology and injury biomechanics of motor vehicle related trauma to the human spine. In: Proceedings of the 33rd Stapp Car Crash Conference, P-227, 892438, p223-242, Washington, DC, 1989, SAE.

Yoganandan N, Pintar FA, Cusick JF, Sun E, Eppinger R (1998) "Whiplash Injury Mechanisms", Whiplash '98 Symposium: p23.

Zung WWK (1965) A self rated depression scale. *Archives of General Psychiatry*. 32: 63-70

## *Figure References*

*Figures 1, 3, 5-9, 15 from:*

**Moore KL and Agur AMR (2002)** Essential Clinical Anatomy. 2nd edition. Lippincott Williams and Wilkins, Baltimore, USA.

*Figure 2, 10, 13, 14 from:*

**Lachmann SM and Jenner JR (1994)** Soft tissue injuries in sport. 2nd edition. Blackwell Science, Oxford, UK.

*Figure 4 from:*

**Seeley RR, Stephens TD, Tate P (1998)** Anatomy and Physiology. 4th edition. McGraw-Hill Publishing Company, USA

*Figure 85 and 86 from:*

**Waldman SD (2004)** Atlas of Interventional Pain Management. 2nd edition. Saunders, Philadelphia, USA.

# Appendix

Appendix A - Glossary

Appendix B - Muscle and ligament tables

Appendix C - Properties of ultrasound tables

Appendix D- Anticoagulants

Appendix E - Diasus technical specification

Appendix F -Cadaver preparation

Appendix G - Whiplash pilot study documents

Appendix H - Questionnaires

Appendix I - Journal publications

Appendix J - Media publications

## *Appendix A - Glossary*

abduction - a movement of a body part away from the midline of the body.

adduction - a movement of a body part towards the midline of the body.

aetiology - the cause of a disease.

anechoic - echo-free.

anterior - the front of the body.

atrophic - wasting away of tissue.

bifurcation - dividing of a structure.

cadaver - dead body.

contralateral - the opposite side.

echogenicity - characteristics of echoes.

extravascular - outside the blood vessels.

haemorrhage - bleeding.

histology - study of the structure of tissues.

hyperechoic - high echogenicity.

hypoechoic - low echogenicity.

interobserver - between observers.

intraobserver - within observers.

*in vitro* - outside the living body.

*in vivo* - inside the living body.

musculoskeletal - relating to the muscle and skeletal system.

musculotendinous junction - the point where muscle and tendon join.

myositis ossificans - where muscle tissue is replaced by bone.

oedema - fluid collection in the body.

palpable - able to be touched or felt.

paraspinal - near the spine.

pathoanatomy - disease of the anatomy.

pathology - study of diseases.

phantoms - systems that simulate biological situations.

posterior - to the back.

pulsatile - having a pulse.

## *Appendix B - Muscle and ligament tables*

*Muscles of the cervical region*

| Structure | Origin | Insertion | Nerve | Function | Comment |
|---|---|---|---|---|---|
| **Superficial and lateral cervical muscles** | | | | | |
| *Platysma* | skin over inferior border of mandible | fascia of deltoid and pectoralis major | facial nerve | depresses lower lip; wrinkles skin of neck and upper chest | can be absent on one or both sides |
| *Trapezius* | occipital protuberance, nuchal ligament, spinous processes of C7-T12 | clavicle, acromion process, and scapular | accessory nerve | abducts and extends head | |
| *Sternocleidomastoid* | mastoid process and superior nuchal line | manubrium and medial clavicle | accessory nerve | acting unilaterally - flexes and rotates head to opposite side; acting bilaterally - flex neck | |
| | | | | | |
| **Suprahyoid muscles** | | | | | |
| *Digastric* | anterior belly - mandible; posterior belly -mastoid notch | intermediate tendon to body and hyoid bone | anterior belly - mylohyoid nerve; posterior belly - facial nerve | depresses mandible, and elevates hyoid | |
| *Stylohyoid* | styloid process | hyoid bone | facial nerve | elevates and retracts hyoid | can be absent or double |
| *Mylohyoid* | body of mandible | hyoid bone | mylohyoid nerve | elevates hyoid bone and floor of mouth and tongue | |
| *Geniohyoid* | genu of mandible | body of hyoid bone | hypoglossal nerve | protracts hyoid bone | |

| Structure | Origin | Insertion | Nerve | Function | Comment |
|---|---|---|---|---|---|
| **Infrahyoid muscles** | | | | | |
| *Sternohyoid* | manubrium of sternum and clavical | hyoid bone | upper cervical through ansa cervicalis | depresses hyoid bone | may be absent or double |
| *Sternothyroid* | manubrium of sternum | thyroid cartilage | upper cervical through ansa cervicalis | depresses hyoid bone and larynx | |
| *Thyrohyoid* | thyroid cartilage | hyoid bone | upper cervical, passing with hypoglossal nerve | depresses hyoid bone and elevates larynx | |
| *Omohyoid* | superior border of scapula | hyoid bone | upper cervical through ansa cervicalis | depresses, retracts and steadies hyoid bone | may be absent or double |
| | | | | | |
| **Anterior vertebral muscles** | | | | | |
| *Longus colli* | C1-C6 | C3-T3 | anterior rami of C2-C6 spinal nerves | rotates and flexes neck | |
| *Longus capitis* | occipital bone | C3-C6 | anterior rami of C1-C3 spinal nerves | flexes head | |
| *Rectus capitis anterior* | occipital bone | C1 | C1-C2 spinal nerves | flexes head | |
| *Rectus capitis lateralis* | occipital bone | C1 | C1-C2 spinal nerves | flexes head and helps to stabilise it | |

| Structure | Origin | Insertion | Nerve | Function | Comment |
|---|---|---|---|---|---|
| **Lateral vertebral muscles** | | | | | |
| *Scalenus anterior* | C3-C7 | first rib | C4-C6 spinal nerves | laterally flexes and rotates neck, elevates first rib | |
| *Scalenus medius* | C3-C7 | first rib | anterior rami of cervical spinal nerves | flexes neck laterally, elevates first rib | |
| *Scalenus posterior* | C4-C6 | second rib | anterior rami of cervical spinal nerves C7 and C8 | flexes neck laterally, elevates second rib | can blend into scalenus medius |
| | | | | | |
| **Deep muscles of the back** | | | | | |
| *Splenius capitis* | inferior part of ligamentum nuchae, C7-T4 and supraspinous ligament | mastoid process and occipital bone | posterior rami of spinal nerves | acting unilaterally - laterally bend and rotate head; acting bilaterally - extends head and neck | |
| *Splenius cervicis* | T3-T6 | C1-C4 | posterior rami of spinal nerves | | |

| Structure | Origin | Insertion | Nerve | Function | Comment |
|---|---|---|---|---|---|
| *Erector spinae (divides into 3):* | | | | | |
| • *iliocostalis cervicis* | angles of 3-6 ribs | C4-C6 | posterior rami of spinal nerves | acting bilaterally - extend vertebral column and head; acting unilaterally - laterally bend vertebral column | |
| • *longissimus* | | | | | |
| o *cervicis* | T1-T5 | C2-C6 | posterior rami of spinal nerves | | |
| o *capitis* | T1-T5 and C4-C7 | mastoid process | posterior rami of spinal nerves | | |
| • *spinalis* | | | | | |
| o *cervicis* | C7-T2 | C2-C4 | posterior rami of spinal nerves | | often absent |
| o *capitis* | blends with semispinalis capitis but can be mophologically separate | | | | |
| *Transversospinalis (divides into 3):* | | | | | |
| • *Semispinalis* | | | | | |
| o *cervicis* | transverse processes of C4-T12 | occipital bone and spinous processes of C2-C5 | posterior rami of spinal nerves | extends neck, and rotates contralaterally | |

| **Structure** | **Origin** | **Insertion** | **Nerve** | **Function** | **Comment** |
|---|---|---|---|---|---|
| • *multifidus* | transverse processes of vertebrae C4-C7 | spinous processes of next superior vertebrae | posterior rami of spinal nerves | stabalise vertebrae during local movements of the vertebral column | |
| • *rotators* | most developed in thoracis region, in this region represented by irregular and variable muscle bundles | adjacent vertebrae | posterior rami of spinal nerves | stabilise vertebrae and assist with local extension and rotary movements of vertebral column | |
| | | | | | |
| **Minor deep muscles of the back** | | | | | |
| *interspinales* | spinous process of vertebrae | spinous process of adjacent vertebrae | posterior rami of spinal nerves | aid in extension and rotation of vertebral column | |
| *intertransversarii* | transverse process of vertebrae | transverse process of adjacent vertebrae | posterior and anterior rami of spinal nerves | aid in lateral bending of vertebral column, acting bilaterally they stabilise the vertebral column | |
| | | | | | |
| **Suboccipital muscles** | | | | | |
| *Rectus capitis posterior major* | C2 | nuchal line | posterior ramus of C1 | unilaterally - rotate head to same side; bilaterally - extend head | |

| **Structure** | **Origin** | **Insertion** | **Nerve** | **Function** | **Comment** |
|---|---|---|---|---|---|
| *Rectus capitis posterior minor* | C1 | nuchal line | posterior ramus of C1 | unilaterally - rotate head to same side; bilaterally - extend head | |
| *Obliquus capitis inferior* | C2 | C1 | posterior ramus of C1 | unilaterally - rotate head to same side; bilaterally - extend head | |
| *Obliquus capitis superior* | C1 | occipital bone (inferior nuchal line) | posterior ramus of C1 | unilaterally - rotate head to same side; bilaterally - extend head | |
| | | | | | |
| **Muscles connecting the upper limb with the vertebral column** | | | | | |
| *Trapezius (see above)* | | | | | |
| *Rhomboideus major* | T2-T5 | medial border of scapula | dorsal scapular nerve | retracts, rotates and fixes scapula | |
| *Rhomboideus minor* | ligamentum nuchae and C1-T1 | medial border of scapula | dorsal scapular nerve | retracts, rotates and fixes scapula | |
| *Levator scapulae* | C1-C4 | superior part of medial border of scapula | dorsal scapular and cervical nerves | elevates and rotates scapula | |

*Ligaments of the cervical region*

| Ligament | Distribution |
|---|---|
| *Supraspinous ligament* | strong fibrous cord, connects apices of the spinous processes from the external occipital protuberance to the sacrum. |
| *Ligamentum nuchae* | the segment of supraspinous ligament which extends from the spinous process of C7 to the external occipital protuberance. A fibrous membrane penetrates from the ligamentum nuchae deep into the neck to attach onto the spinous process of the cervical segments, thereby forming a septum between the muscles on each side of the neck. |
| *Interspinous ligaments* | are thin membranous structures which connect adjacent spinous processes. They extend from the base to the tip of each spinous process. |
| *Thin loose capsules* | of the facet joint attach the margins of the articular surfaces of the adjacent vertebrae. |
| *Ligamentum flava* | thick, dense, broad structures that connect the laminae of adjacent vertebrae. Ligaments arise from ventral surface of the lamina above and pass inferiorly to attach to the dorsal surface of the lamina below where the lamina fuse to form the base of the spinous process. |
| *Posterior longitudinal ligament* | extends from axis to sacrum. A dense broad ligament lying within the ventral surface of the spinal canal, closely adherent to the posterior surface of the vertebral bodies and discs. |
| *Intervertebral discs* | classified as a ligament, discussed previously. |
| *Anterior longitudinal ligament* | dense and strong extends from anterior surface of axis (C2) to the sacrum. Closely adherent to intervertebral discs and the prominent margins of the vertebrae, but is not tightly adherent to the concavity of the anterior surfaces of the vertebral bodies. |

## *Appendix C - Properties of ultrasound tables*

**Propagation speed of ultrasound in tissue**

| *Tissue* | *Propagation speed (mm/s)* |
|---|---|
| Fat | 1.44 |
| Brain | 1.51 |
| Liver | 1.56 |
| Kidney | 1.56 |
| Muscle | 1.57 |
| Soft-tissue average | 1.54 |

*Adapted from Kremkau FW: Diagnostic Ultrasound: Principles and Instruments, 4th edition. Philadelphia, WB Saunders, 1993.*

**Acoustic impedance of tissue**

| *Tissue* | *Acoustic impedance** |
|---|---|
| Air | 0.0004 |
| Fat | 1.38 |
| Water (50°C) | 1.54 |
| Brain | 1.58 |
| Blood | 1.61 |
| Kidney | 1.62 |
| Liver | 1.65 |
| Muscle | 1.70 |
| Lens | 1.84 |
| Bone | 7.8 |

* Acoustic impedance (Z) = x $10^6$kg/$m^2$ sec

*Adapted from Curry TS, Dowdey JE, Murray RC Jr: Christensen's Physics of Diagnostic Radiology, 4th edition. Philadelphia, Lea and Febiger, 1990.*

**Reflection of ultrasound at tissue interfaces**

| *Interface* | *Reflection (%)* |
|---|---|
| Blood-brain | 0.3 |
| Kidney-liver | 0.6 |
| Blood-kidney | 0.7 |
| Liver-muscle | 1.8 |
| Blood-fat | 7.9 |
| Liver-fat | 10.0 |
| Muscle-fat | 10.0 |
| Muscle-bone | 64.6 |
| Brain-bone | 66.1 |
| Water-bone | 68.4 |
| Soft tissue-gas | 99.0 |

*Adapted from Hagen-Ansert SL: Textbook of Diagnostic Ultrasonography, 3rd edition. St. Louis, CV Mosby, 1989.*

**Typical imaging depth and axial resolution (two-cycle pulse) in tissue**

| *Frequency (MHz)* | *Imaging depth (cm)* | *Axial resolution (mm)* |
|---|---|---|
| 2.0 | 30 | 0.77 |
| 3.5 | 17 | 0.44 |
| 5.0 | 12 | 0.31 |
| 7.5 | 8 | 0.20 |
| 10.0 | 6 | 0.15 |
| 15.0 | 4 | 0.10 |

*Adapted from Kremkau FW: Diagnostic Ultrasound: Principles and Instruments, 6th edition. Philadelphia, WB Saunders, 2002.*

## *Appendix D - Anticoagulants*

Anti-coagulant Dextrose (ACD)

1.3 litre pot of blood needs 150ml ACD

2.5% tri-sodium citrate

1.5% citric acid

2% glucose

For a glass test tube of 20ml capacity:

5g sodium citrate

3g citric acid

4g glucose D(+) (dextrose)

Sodium Citrate

294.1g to 1 litre makes a 1mol solution

0.109M = 32.06g

1.603g sodium citrate to 50ml

EDTA (disodium salt)

1.5 (±25) mg/ml

For a 10ml sample of blood, add 0.5ml solution to the blood

## *Appendix E - Diasus technical specification*

Diasus technical specification supplied by Dynamic Imaging.

| **Diasus Technical Specification** | | |
|---|---|---|
| *Transducer types* | Ultra Wideband Electronic Linear Array | |
| *Transducer frequencies* | 5-10MHz, 40mm active length<br>8-16MHz, 26mm active length<br>10-22MHz, 26mm active length | |
| *Scan modes* | B-Mode | |
| *Screen format* | Single/Dual image | |
| *Resolution* | 640 x 440 pixels, 8 bits | |
| *External interface* | Seven slide potentiometer gain controls<br>2 rotary potentiometers controlling Transmit Power and Overall Gain<br>86 key QWERTY keyboard and 29 dedicated function keys<br>Trackerball for measurements and text positioning<br>15" Digital Autoscan Colour Monitor, high resolution, flicker free, low emission MPR-II compliance, screen resolution 800x600<br>Standard PC communications ports | |
| *B-Mode features* | Depth of view | 100mm max |
| | Frame rate | 30fps max |
| | Magnification | 6 step zoom |
| | Inversion | black-white/white-black, left-right/right-left |
| *Signal processing* | 4.0-26.0MHz bandwidth, swept frequency, 4 post processing curves (gamma correction), 2D filtering, frame averaging, selectable multiple transmit focus positions | |
| *Display information* | Patient ID, Hospital ID, Clinician ID, measurement mode, post processing status, current scale, frame averaging status, transpose status, frozen status, time and date, transmit focus indicators, body mark, text annotation | |
| *Software package* | Distance (4) traced or ellipse area (2) curved line length (2) | |

| | | |
|---|---|---|
| *Power* | Input | 115V AC/60Hz, 230V AC/50Hz, rated power 300VA max |
| | Output | 230V AC, 50/60Hz, 230VA max for additional accessories |
| *Operating conditions* | Temperature | +10°C to +40°C |
| | Relative humidity | 30% to 80% |
| *Storage/transport* | Temperature | -10°C to +60°C |
| | Relative humidity | 30% to 90% (non condensing) |
| *Physical* | Weight | 65kg approx |
| | Dimensions | 537 x 1285 x 765mm (WxHxD) |
| *Standards* | Electrical safety | EN60601-1-1, UL2601-1, Class 1, Type BF |
| | EMC | EN60601-1-2 |
| | Acoustic power | EN61157, on screen indication in accordance with Acoustic Output Display Standard |
| | Quality | Dynamic Imaging is committed to a Total Quality Culture and has been assessed and registered as meeting the requirements of BS EN46001, the application of BS EN ISo 9001 to the manufacture of medical devices, under Annex II of EC Council Directive 93/42/EEC, the Medical Device Directive |
| | CE0120 | Diasus is identified with this CE Mark in compliance with EC Directive 93/42/EEC (Medical Devices Directive) Dynamic Imaging is registered as complying with EN46001, the internationally recognised quality system standard for medical devices. |
| *Accessories* | Video printers, needle guide attachments | |
| *Consumables* | Gel, video printer paper, needle guides | |

## *Appendix F - Cadaver preparation*

UNIVERSITY OF NOTTINGHAM
SCHOOL OF BIOMEDICAL SCIENCES
EMBALMING METHOD
(March 2004)

The method of embalming used in the School of Biomedical Sciences at the University of Nottingham Medical School has been applied successfully for over 25 years, and has been adopted for use in Australia, Egypt and Malaysia, amongst other places.

The fluid itself is a traditional mixture of:-

800 ml Methanal (formalin, 40%)
700 ml Liquid phenol
1.5L Glycerol - made up to 20 litres with industrial alcohol 17L (ethanol)

A small quantity of eosin may be added to colour the fluid if desired.

For the infusion, the femoral artery is found by dissection, the incision being made about a third of the way down the thigh, medial to the sartorius. The artery is cut transversely in two places, about 1cm apart, to take cannulae of suitable size for the lumen; one cannula, larger if possible, is positioned up towards the aorta, and a smaller cannula is positioned down the limb. These are clamped in place.

An initial per-embalming fluid of approximately 1 molar saline is pumped via the cannulae into the arterial system - 500 ml is usually sufficient - which washes blood away for the perfusion site. Without this initial stage, the embalming fluid will coagulate blood in the artery close to the cannulae, thus blocking them. It may be that due to arterial disease or thrombi, the pre-wash will enter the arteries only slowly, or not at all. It may be decided at this point to use a second cannulation site - perhaps the upper brachial artery or the common carotid - rather than continue with the femoral site.

The embalming fluid is pumped up to an aspirator some 2.5 metres above floor level. This should provide sufficient pressure for a thorough perfusion. The fluid is run into the arterial system via a flexible tube, preferably of silicone rubber as this best resists the hardening effect of the fluid. This is allowed to continue over night. It then remains to 'top-up' any poorly perfused areas with a repeating syringe using a long wide-bore needle.

It has been found useful to ensure fixation of the brain within the skull by passing this needle into the cranial cavity, going medial to the eye to pass through the superior orbital fissure. Some 20 ml of 40% methanal (formalin) may be pumped into each cerebral hemisphere.

The cadaver is then left to drain of surplus fluid. After 2-3 days, the cadaver is placed inside a 1000 gauge polythene bag to be stored at room temperature/or at 40°F in the summer months.

## COMPOSITION OF EMBALMING FLUID: "NOTTINGHAM FORMULATION"

(ready prepared and obtained from Vickers Laboratories)

Each 20 Litres comprises:

- 7.5% - 1.5L Glycerol
- 3.5% - 700ml Methanal (Formaldehyde 40%) - [we have increased this to 800 ml]
- 3.5% - 700ml Phenol
- 84.5% - 16.9L Methanol
- "Pinch" (few grains) Eosin Colourant

## STANDARD OPERATING PROCEDURES IN THE ANATOMY DISSECTING ROOM

## PROCEDURE FOR EMBALMING CADAVERIC MATERIAL

- Place cadaver in recumbent position on embalming table. Inform Secretariat of receipt and number codes.
- Remove all clothing, needles, catheters and tags and place them in a yellow clinical waste bag.
- Wash down and sterilise cadaver with a solution of 1% Trigene disinfectant in water.
- Shave head hair with electric razor - into clinical waste bag.
- Position (and fix if necessary) head, upper and lower limbs in anatomical position before embalming.
- Locate femoral triangle of one limb and femoral artery (halfway between thumb and middle finger of embalmer's hand placed upon pubic symphysis and anterior superior iliac spine, respectively.
- Approximately 4cm from thigh crease, incise skin inferomedially for 5 cm with scalpel.
- Deepen incision carefully, layer by layer, until deep fascia overlying adductor longus muscle exposed.
- Employ retractors to keep tissue flaps apart while digitally palpating between exposed muscles for firm femoral sheath.
- Gently incise sheath to expose femoral artery and mobilise away with forceps or other blunt instrument from femoral vein.
- With scalpel carefully incise 2 transverse cuts, 1 cm apart and 3 mm in length, transversely on the anterior arterial wall.
- Carefully insert two angled metal catheters into the artery through the cuts, in superior and inferior directions and clamp firmly into position with metal clamps.
- Infuse 500 ml of a 1N warm saline solution with electric pump into artery via the catheters.
- Gravity feed 20L of embalming fluid into the artery via the two catheters overnight.

- Wash away any fluid which has leaked from the cadaver.
- Check cadaver for areas of non-fixation and inject local embalming fluid with electric pump and needle.
- Pump additional embalming fluid into cavities - chest, abdomen, hands, fingers, feet, toes etc (directly through body wall), cranial cavity (through upper eyelid and superior orbital fissure) with pump and needle. (For cranial cavity, increase formaldehyde concentration in embalming fluid from 4% to 7.5%.
- Rinse cadaver down with water and place in transparent plastic cadaver bag and evacuate air by suction for storage at room temperature/or 40°F in summer months.
- Check cadaver periodically (3 months, 6 months) for fixation.
- Minimal time for satisfactory fixation is 6 months.

# *Appendix G - Whiplash pilot study documents*

## Form 1: Patient information sheet

### The Use of Ultrasound Scanning of the Tissues of the Neck in Assessment of Whiplash Associated Disorders

*Researchers:*

Andrew Clarke, Clinical Research Fellow, Spinal Unit, QMC

Amanda Roshier, PhD Student, Institute of Biomechanics, University of Nottingham

You are being invited to take part in a research study. Before you decide it is important for you to understand why the research is being done and what it will involve. Please take time to read the following information carefully and discuss it with friends and relatives if you wish. Ask us if there is anything that is not clear or if you would like more information. Take time to decide whether or not you wish to take part.

Purpose of Study

Whiplash was first described in 1928 at a Research Meeting. Ever since, controversy has reigned as to the physical basis for the condition. The actual mechanism of a whiplash injury has been well documented, but the resultant 'damage' to body structures which cause the pain has yet to be agreed upon. Therefore, by performing ultrasonic assessments of the tissues of the neck in people who have suffered an acute whiplash, we aim to identify the site(s) of injury.

Why Have I Been Chosen ?

You are attending the Accident and Emergency Department because of a whiplash injury.

Do I Have To Take Part ?

It is up to you to decide whether or not to take part. If you do decide to take part you will be given this information sheet to keep and be asked to sign a consent form. If you decide to take part you are still free to withdraw at any time and without giving a reason. This will not affect the standard of care you receive.

What Do I Have To Do ?

- Contact Mr Andrew Clarke / Ms A Roshier
- Arrange a time that is convenient for you (ideally during your visit to A&E)
- Attend QMC for Assessment, which includes:
- A Clinical History of the Injury
- A Clinical Examination
- An Ultrasound Examination of the Neck
- The assessment will take approximately 20-30mins

What Is The Procedure That Is Being Tested ?

The ability of Ultrasound to identify tissue injuries in the neck following a whiplash injury.

What Are The Side Effects Of Taking Part ?

You may experience mild discomfort during the ultrasound scan.

What Are The Possible Disadvantages And Risks Of Taking Part ?
There are no disadvantages to taking part

What If Something Goes Wrong ?
It is very unlikely that any adverse effects will occur. If you are harmed by taking part in this research project, there are no special compensation arrangements. If you are harmed due to someone's negligence, then you may have grounds for a legal action but you may have to pay for it. Regardless of this, if you wish to complain about any aspect of the way you have been approached or treated during the course of this study, the normal National Health Service complaints mechanisms will be available to you. Trust complaints officer: Naomi Broughton 0115 924 9924 (x36098).

What Will Happen To The Results Of The Research Study ?
All information which is collected about you during the course of the research will be kept strictly confidential. Any information about you which leaves the hospital/surgery will have your name and address removed so that you cannot be recognised from it. This study is being carried out for research purposes and will not directly benefit your treatment.

Who Is Organising And Funding The Research ?
- Institute of Biomechanics (University of Nottingham)
- Centre for Spinal Studies and Surgery (Queen's Medical Centre)

Who Has Reviewed The Study ?
- Mr M P Grevitt Consultant Spinal Surgeon Queen's Medical Centre
- Mr L Neumann Consultant Orthopaedic Surgeon City Hospital, Nottingham

Contact For Further Information
- Mr Andrew Clarke / Ms Amanda Roshier
- Ask the A&E staff to help or you can contact us
- Via Queen's Medical Centre Switchboard (0115 924 9924) ask for Bleep 1702 (between 0800-1700 hrs)
- On e-mail, whiplashstudy@hotmail.com (please send your name and contact details)

Thank you for your participation

Andrew Clarke, Research Fellow, Centre for Spinal Studies and Surgery, QMC
Amanda Roshier, PhD Student, Institute of Biomechanics, University of Nottingham

## Form 2: Patient consent form

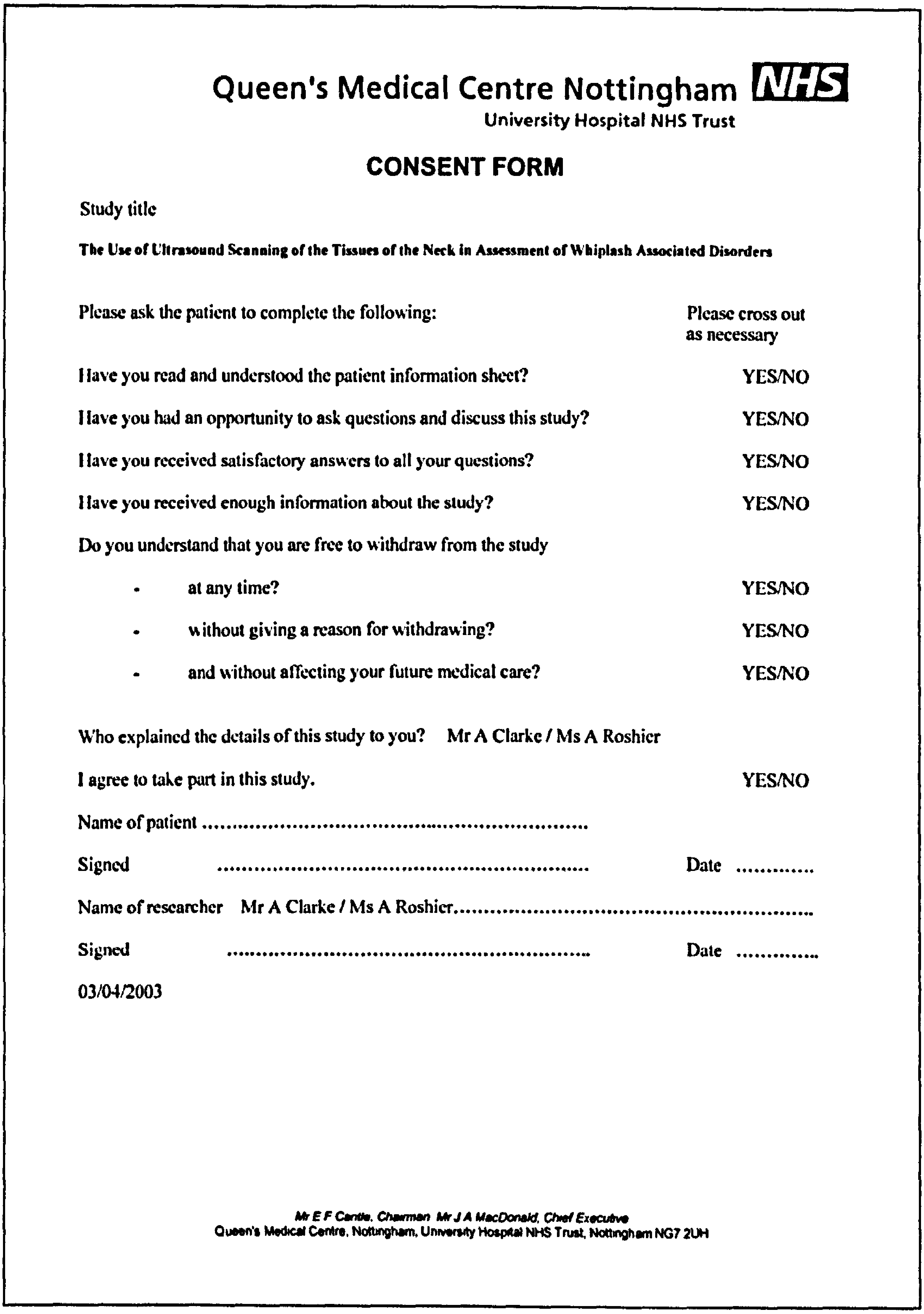

Queen's Medical Centre Nottingham NHS
University Hospital NHS Trust

### CONSENT FORM

Study title

**The Use of Ultrasound Scanning of the Tissues of the Neck in Assessment of Whiplash Associated Disorders**

| Please ask the patient to complete the following: | Please cross out as necessary |
|---|---|
| Have you read and understood the patient information sheet? | YES/NO |
| Have you had an opportunity to ask questions and discuss this study? | YES/NO |
| Have you received satisfactory answers to all your questions? | YES/NO |
| Have you received enough information about the study? | YES/NO |
| Do you understand that you are free to withdraw from the study | |
| - at any time? | YES/NO |
| - without giving a reason for withdrawing? | YES/NO |
| - and without affecting your future medical care? | YES/NO |

Who explained the details of this study to you? Mr A Clarke / Ms A Roshier

| | |
|---|---|
| I agree to take part in this study. | YES/NO |

Name of patient ..............................................................

Signed .............................................................. Date .............

Name of researcher Mr A Clarke / Ms A Roshier..........................................................

Signed .............................................................. Date ..............

03/04/2003

*Mr E F Cantle, Chairman Mr J A MacDonald, Chief Executive*
Queen's Medical Centre, Nottingham, University Hospital NHS Trust, Nottingham NG7 2UH

## Form 3: Patient assessment form

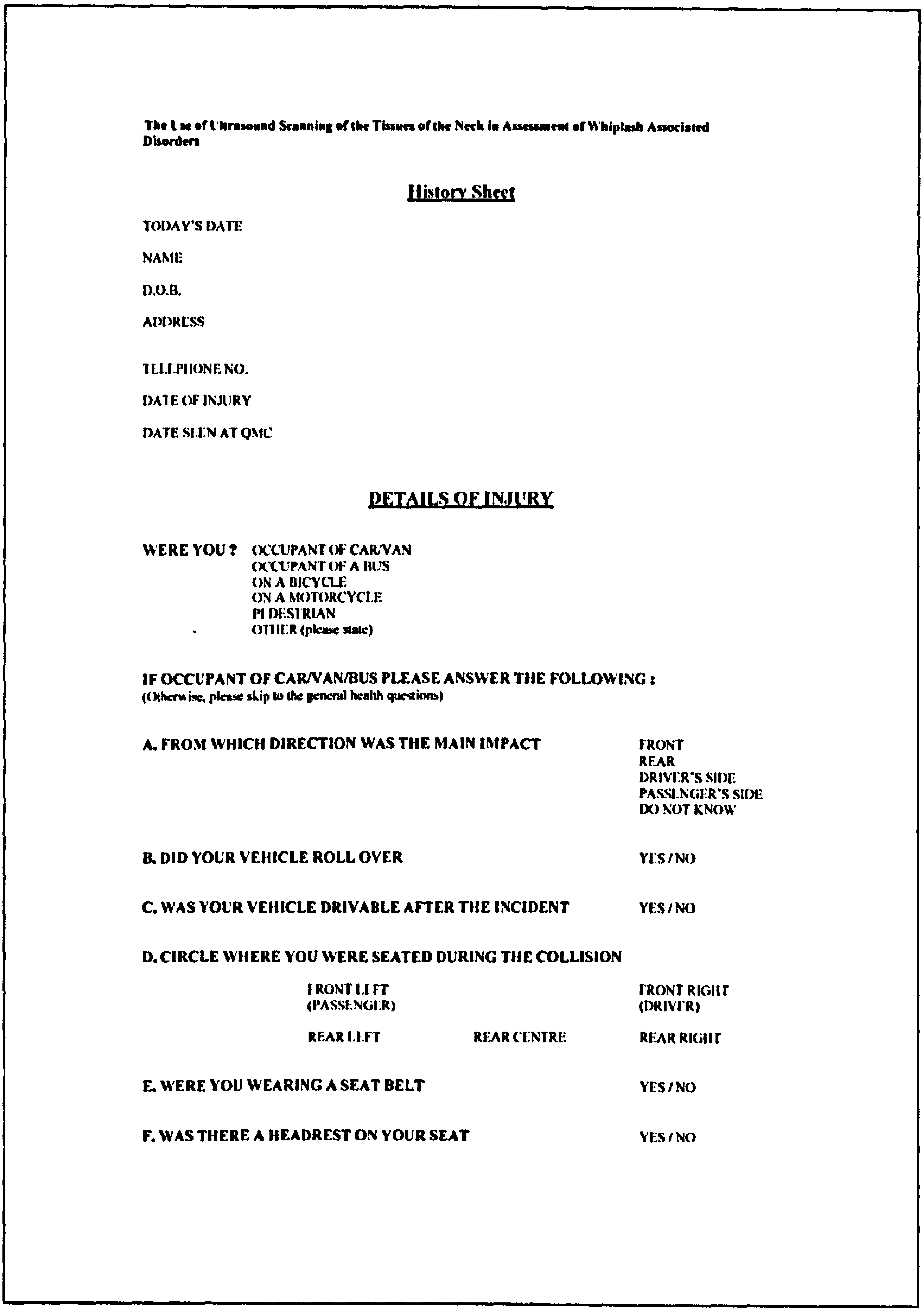

**The Use of Ultrasound Scanning of the Tissues of the Neck in Assessment of Whiplash Associated Disorders**

### History Sheet

TODAY'S DATE

NAME

D.O.B.

ADDRESS

TELEPHONE NO.

DATE OF INJURY

DATE SEEN AT QMC

### DETAILS OF INJURY

**WERE YOU ?**
- OCCUPANT OF CAR/VAN
- OCCUPANT OF A BUS
- ON A BICYCLE
- ON A MOTORCYCLE
- PEDESTRIAN
- OTHER (please state)

**IF OCCUPANT OF CAR/VAN/BUS PLEASE ANSWER THE FOLLOWING :**
(Otherwise, please skip to the general health questions)

| | |
|---|---|
| **A. FROM WHICH DIRECTION WAS THE MAIN IMPACT** | FRONT<br>REAR<br>DRIVER'S SIDE<br>PASSENGER'S SIDE<br>DO NOT KNOW |
| **B. DID YOUR VEHICLE ROLL OVER** | YES / NO |
| **C. WAS YOUR VEHICLE DRIVABLE AFTER THE INCIDENT** | YES / NO |

**D. CIRCLE WHERE YOU WERE SEATED DURING THE COLLISION**

| | | |
|---|---|---|
| FRONT LEFT<br>(PASSENGER) | | FRONT RIGHT<br>(DRIVER) |
| REAR LEFT | REAR CENTRE | REAR RIGHT |

| | |
|---|---|
| **E. WERE YOU WEARING A SEAT BELT** | YES / NO |
| **F. WAS THERE A HEADREST ON YOUR SEAT** | YES / NO |

## GENERAL HEALTH QUESTIONS

| | |
|---|---|
| HOW WAS YOUR HEALTH BEFORE THE INJURY | EXCELLENT<br>VERY GOOD<br>FAIR<br>POOR |
| BEFORE THE COLLISION DID YOU SUFFER WITH | HEADACHE<br>ACHE/PAIN IN LOW BACK<br>ACHE/PAIN IN NECK REGION |
| HAVE YOU HAD A SIMILAR INJURY IN THE PAST | YES / NO (please give date) |
| IF YES, WHAT DID YOU INJURE (please state) | |

## DURING THIS INJURY

| | |
|---|---|
| DID YOU LOSE CONCIOUSNESS | YES / NO |
| DID YOU HIT YOUR HEAD | YES / NO |
| DID YOU BREAK ANY BONES | YES / NO |

## CURRENT SYMPTOMS

| SYMPTOMS | NO | YES | DAY 1 | DAY 1-4 | DAY 5 + | UNSURE | MILD | MODERATE | SEVERE |
|---|---|---|---|---|---|---|---|---|---|
| NECK / SHOULDER PAIN | | | | | | | | | |
| REDUCED / PAINFUL NECK MOVEMENTS | | | | | | | | | |
| NUMBNESS / TINGLING IN ARMS/HANDS | | | | | | | | | |
| NUMBNESS / TINGLING IN LEGS / FEET | | | | | | | | | |
| DIZZINESS / UNSTEADY | | | | | | | | | |
| NAUSEA/ VOMITING | | | | | | | | | |
| RINGING IN EARS | | | | | | | | | |
| MEMORY / CONCENTRATION PROBLEMS | | | | | | | | | |
| VISUAL DISTURBANCE | | | | | | | | | |
| LOW BACK PAIN | | | | | | | | | |

## CLINICAL EXAMINATION

**CERVICAL SPINE**

**ANY TENDERNESS ON PALPATION** YES / NO

**PLEASE DOCUMENT LOCATION**

**SHOULDER**

**ANY TENDERNESS ON PALPATION** YES/NO

**PLEASE DOCUMENT LOCATION**

## CERVICAL SPINE MOVEMENTS

| MOVEMENT | PAIN FREE | PAINFUL | LIMITATION |
|---|---|---|---|
| FLEXION | | | |
| EXTENSION | | | |
| RIGHT ROTATION | | | |
| LEFT ROTATION | | | |
| RIGHT LAT FLEX | | | |
| LEFT LAT FLEX | | | |

## SHOULDER MOVEMENTS

| MOVEMENT | RIGHT | LEFT |
|---|---|---|
| FORWARD FLEXION | | |
| ABDUCTION | | |
| INTERNAL ROTATION | | |
| EXTERNAL ROTATION | | |

## NEUROLOGICAL EXAMINATION

**NORMAL** YES / NO

**(IF NO, PLEASE COMPLETE TABLE)**

| LEVEL | SENSORY RIGHT | SENSORY LEFT | MOTOR RIGHT | MOTOR LEFT | REFLEX RIGHT | REFLEX LEFT |
|---|---|---|---|---|---|---|
| C5 | | | | | | |
| C6 | | | | | | |
| C7 | | | | | | |
| C8 | | | | | | |
| T1 | | | | | | |

## DIAGNOSTIC TESTS

**PLAIN RADIOGRAPHS** YES / NO

**(PLEASE DOCUMENT FINDINGS)**

## ULTRASOUND FINDINGS

## Study Poster

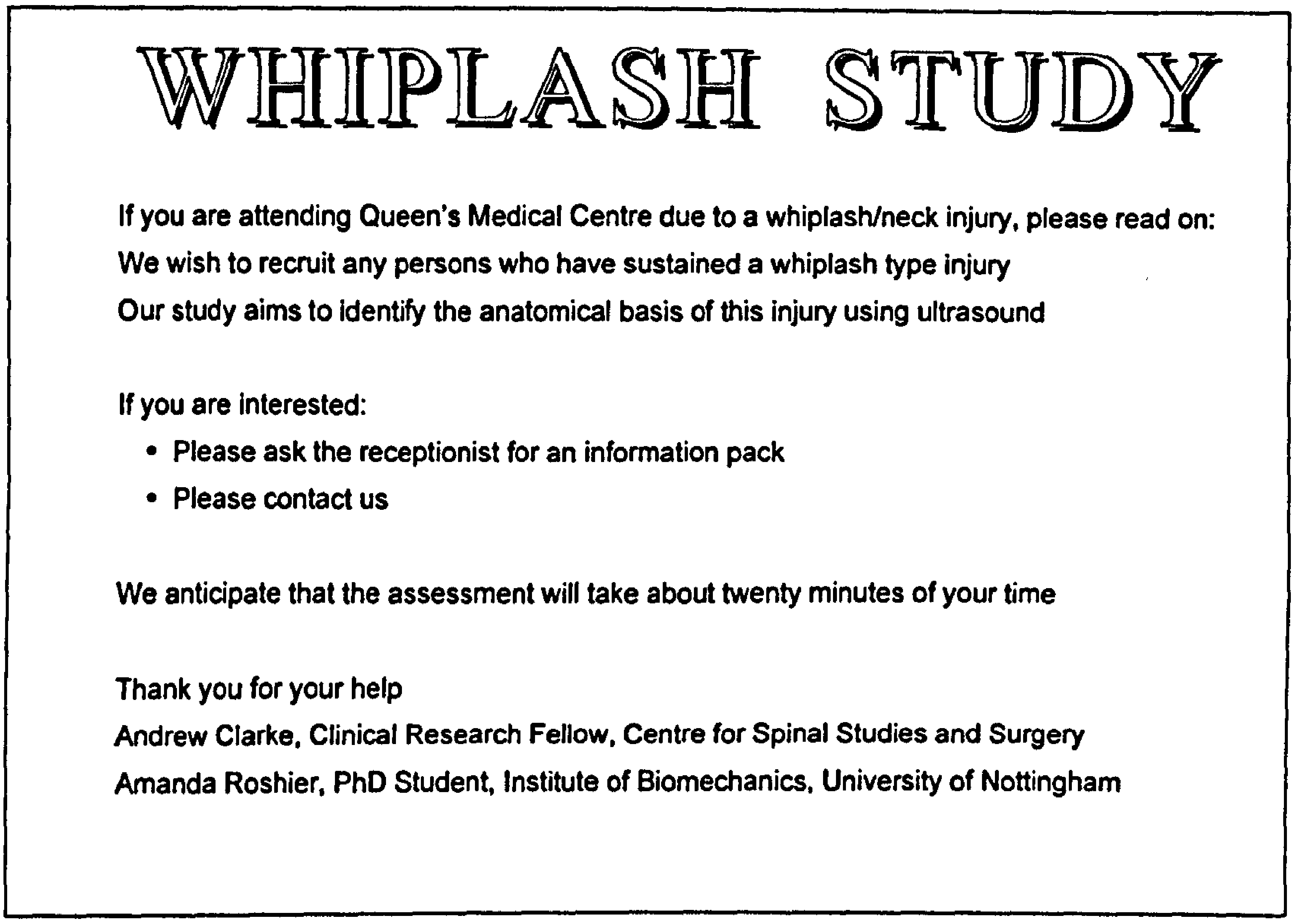

# WHIPLASH STUDY

If you are attending Queen's Medical Centre due to a whiplash/neck injury, please read on:
We wish to recruit any persons who have sustained a whiplash type injury
Our study aims to identify the anatomical basis of this injury using ultrasound

If you are interested:

- Please ask the receptionist for an information pack
- Please contact us

We anticipate that the assessment will take about twenty minutes of your time

Thank you for your help
Andrew Clarke, Clinical Research Fellow, Centre for Spinal Studies and Surgery
Amanda Roshier, PhD Student, Institute of Biomechanics, University of Nottingham

## Appendix H - Questionnaires

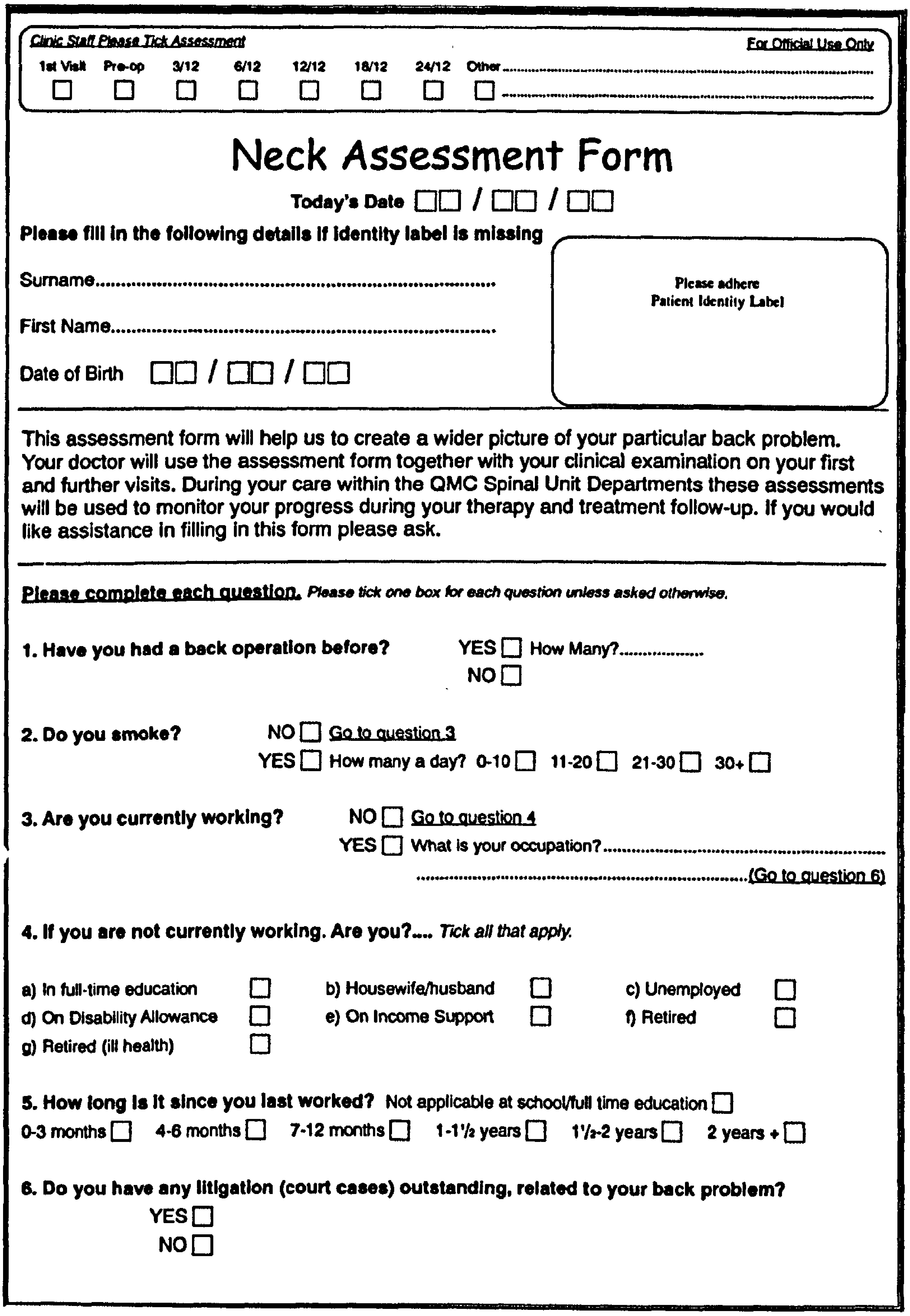

Clinic Staff Please Tick Assessment

For Official Use Only

| | | | | | | | |
|---|---|---|---|---|---|---|---|
| 1st Visit | Pre-op | 3/12 | 6/12 | 12/12 | 18/12 | 24/12 | Other.................................................. |
| ☐ | ☐ | ☐ | ☐ | ☐ | ☐ | ☐ | ☐.................................................. |

# Neck Assessment Form

**Today's Date** ☐☐ / ☐☐ / ☐☐

**Please fill in the following details if identity label is missing**

Please adhere
Patient Identity Label

Surname..............................................................................

First Name..........................................................................

Date of Birth ☐☐ / ☐☐ / ☐☐

This assessment form will help us to create a wider picture of your particular back problem. Your doctor will use the assessment form together with your clinical examination on your first and further visits. During your care within the QMC Spinal Unit Departments these assessments will be used to monitor your progress during your therapy and treatment follow-up. If you would like assistance in filling in this form please ask.

**Please complete each question.** *Please tick one box for each question unless asked otherwise.*

**1. Have you had a back operation before?** YES ☐ How Many?..................
NO ☐

**2. Do you smoke?** NO ☐ Go to question 3
YES ☐ How many a day? 0-10 ☐ 11-20 ☐ 21-30 ☐ 30+ ☐

**3. Are you currently working?** NO ☐ Go to question 4
YES ☐ What is your occupation?.............................................................
..............................................................................(Go to question 6)

**4. If you are not currently working. Are you?....** *Tick all that apply.*

| | | | | | |
|---|---|---|---|---|---|
| a) In full-time education | ☐ | b) Housewife/husband | ☐ | c) Unemployed | ☐ |
| d) On Disability Allowance | ☐ | e) On Income Support | ☐ | f) Retired | ☐ |
| g) Retired (ill health) | ☐ | | | | |

**5. How long is it since you last worked?** Not applicable at school/full time education ☐
0-3 months ☐ 4-6 months ☐ 7-12 months ☐ 1-1½ years ☐ 1½-2 years ☐ 2 years + ☐

**6. Do you have any litigation (court cases) outstanding, related to your back problem?**
YES ☐
NO ☐

**6. What caused your back problem(s)?** *Tick all that apply.*

a) Accident at work ☐
b) Accident elsewhere ☐
c) Road Vehicle Accident ☐
d) Lifting ☐
e) Fall ☐
f) Other ☐ please specify……………………………………………………………………………

---

The following diagram will help us to measure the level and whereabouts of your pain. Each of the three lines relates to the main areas of your body where you may be experiencing pain. Please draw a cross (X) on the relevant lines to the level of pain you have today.
'0' = no pain and '10' = the most severe pain imaginable.

No pain Most Severe Pain

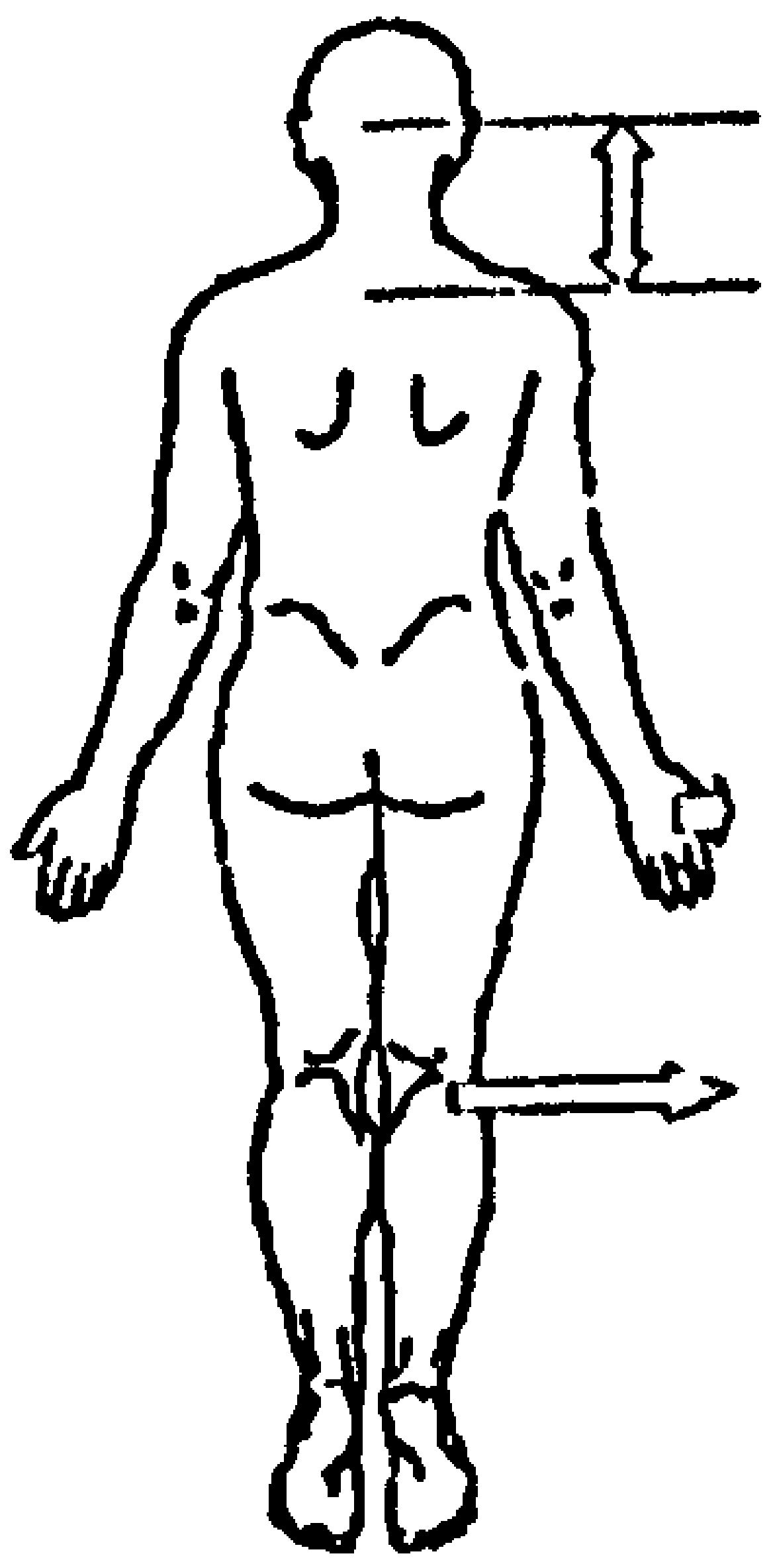

Neck 0 1 2 3 4 5 6 7 8 9 10

Arms 0 1 2 3 4 5 6 7 8 9 10

Legs 0 1 2 3 4 5 6 7 8 9 10

# THE NECK DISABILITY INDEX

**Please answer all 10 sections. In each category, tick only one that best applies to your current condition.**

**1. PAIN INTENSITY**
- ☐ I have no pain at the moment.
- ☐ The pain is very mild at the moment.
- ☐ The pain is moderate at the moment.
- ☐ The pain is fairly severe at the moment.
- ☐ The pain is very severe at the moment.
- ☐ The pain is the worst imaginable at the moment.

**2. PERSONAL CARE**
**(Washing, Dressing, etc.)**
- ☐ I can look after myself normally, without causing extra pain.
- ☐ I can look after myself normally, but it causes extra pain.
- ☐ It is painful to look after myself and I am slow and careful.
- ☐ I need some help, but manage most of my personal care.
- ☐ I need help every day in most aspects of self care.
- ☐ I do not get dressed; I wash with difficulty and stay in bed.

**3. LIFTING**
- ☐ I can lift heavy weights without extra pain.
- ☐ I can lift heavy weights, but it gives extra pain.
- ☐ Pain prevents me from lifting heavy weights off the floor, but I can manage if they are conveniently positioned, for example, on a table.
- ☐ Pain prevents me from lifting heavy weights off the floor, but I can manage light to medium weights if they are conveniently positioned.
- ☐ I can lift very light weights.
- ☐ I cannot lift or carry anything at all.

**4. READING**
- ☐ I can read as much as I want to, with no pain in my neck.
- ☐ I can read as much as I want to, with slight pain in my neck.
- ☐ I can read as much as I want to, with moderate pain in my neck.
- ☐ I can't read as much as I want, because of moderate pain in my neck.
- ☐ I can hardly read at all, because of severe pain in my neck.
- ☐ I cannot read at all.

**5. HEADACHES**
- ☐ I have no headaches at all.
- ☐ I have slight headaches that come infrequently.
- ☐ I have moderate headaches that come infrequently.
- ☐ I have moderate headaches that come frequently.
- ☐ I have severe headaches that come frequently.
- ☐ I have headaches almost all the time.

**6. CONCENTRATION**
- ☐ I can concentrate fully when I want to, with no difficulty.
- ☐ I can concentrate fully when I want to, with slight difficulty.
- ☐ I have a fair degree of difficulty in concentrating when I want to.
- ☐ I have a lot of difficulty in concentrating when I want to.
- ☐ I have a great deal of difficulty in concentrating when I want to.
- ☐ I cannot concentrate at all.

**7. WORK**
- ☐ I can do as much work as I want to.
- ☐ I can do my usual work, but no more.
- ☐ I can do most of my usual work, but no more.
- ☐ I cannot do my usual work.
- ☐ I can hardly do any work at all.
- ☐ I can't do any work at all.

**8. DRIVING**
- ☐ I can drive my car without any neck pain.
- ☐ I can drive my car as long as I want, with slight pain in my neck.
- ☐ I can drive my car as long as I want, with moderate pain in my neck.
- ☐ I can't drive my car as long as I want, because of moderate pain in my neck.
- ☐ I can hardly drive at all, because of severe pain in my neck.
- ☐ I can't drive my car at all.

**9. SLEEPING**
- ☐ I have no trouble sleeping.
- ☐ My sleep is slightly disturbed (less than 1 hr sleepless).
- ☐ My sleep is mildly disturbed (1-2 hrs sleepless).
- ☐ My sleep is moderately disturbed (2-3 hrs sleepless).
- ☐ My sleep is greatly disturbed (3-5 hrs sleepless).
- ☐ My sleep is completely disturbed (5-7 hrs sleepless).

**10. RECREATION**
- ☐ I am able to engage in all my recreation activities, with no neck pain at all.
- ☐ I am able to engage in all my recreation activities, with some neck pain.
- ☐ I am able to engage in most, but not all, of my usual recreation activities, because of pain in my neck.
- ☐ I am able to engage in few of my recreation activities, because of pain in my neck.
- ☐ I can hardly do any recreation activities, because of pain in my neck.
- ☐ I can't do any recreation activities at all.

© Vernon and Mior Neck Disability Index

Official use only..............................(Points)/........................(Questions answered) = ................................(Score)

# Health Status Profile SF-36

For office use ☐☐☐☐

This survey asks for your views about your health. This information will help keep track of how you feel and how well you are able to do your usual activities.

Answer every question by marking in the appropriate boxes with ☒. If you are unsure about how to answer a question, please give the best answer you can.

Q1 In general, would you say your health is:

☐ Excellent ☐ Very good ☐ Good ☐ Fair ☐ Poor

Q2 **Compared with one year ago,** how would you rate your health in general **now**?

☐ Much better now than one year ago
☐ Somewhat better now than one year ago
☐ About the same as one year ago
☐ Somewhat worse now than one year ago
☐ Much worse now than one year ago

The following questions are about activities you might do during a typical day. **Does your health now limit you in these activities? If so, how much?** (Mark one box on each line)

| | **Yes, limited a lot** | **Yes, limited a little** | **No, not limited at all** |
|---|---|---|---|
| Q3 **Vigorous activities,** such as running, lifting heavy objects, participating in strenuous sports | ☐ | ☐ | ☐ |
| Q4 **Moderate activities,** such as moving a table, pushing a vacuum cleaner, bowling, or playing golf | ☐ | ☐ | ☐ |
| Q5 Lifting or carrying groceries | ☐ | ☐ | ☐ |
| Q6 Climbing **several** flights of stairs | ☐ | ☐ | ☐ |
| Q7 Climbing **one** flight of stairs | ☐ | ☐ | ☐ |
| Q8 Bending, kneeling or stooping | ☐ | ☐ | ☐ |
| Q9 Walking **more than a mile** | ☐ | ☐ | ☐ |
| Q10 Walking **half a mile** | ☐ | ☐ | ☐ |
| Q11 Walking **one hundred yards** | ☐ | ☐ | ☐ |
| Q12 Bathing or dressing yourself | ☐ | ☐ | ☐ |

During the **past 4 weeks,** have you had any of the following problems with your work or other regular daily activities **as a result of your physical health?** (Mark one box on each line)

Q13 Cut down on the **amount of time** you spent on work or other activities Yes ☐ ☐ No

Q14 **Accomplished less** than you would like Yes ☐ ☐ No

Q15 Were limited in the **kind** of work or other activities Yes ☐ ☐ No

Q16 Had **difficulty** in performing work or other activities (for example, it took extra effort) Yes ☐ ☐ No

During the past 4 weeks, have you had any of the following problems with your work or other regular daily activities **as a result of any emotional problems** (such as feeling depressed or anxious)? (Mark one box on each line)

Q17 Cut down on the **amount of time** you spent on work or other activities Yes ☐ ☐ No

Q18 **Accomplished less** than you would like Yes ☐ ☐ No

Q19 Didn't do work or other activities as **carefully** as usual Yes ☐ ☐ No

Q20 During the **past 4 weeks,** to what extent has your physical health or emotional problems interfered with your normal social activities with family, friends, neighbours or groups? (Mark one box)

☐ Not at all ☐ Slightly ☐ Moderately
☐ Quite a bit ☐ Extremely

Q21 How much **bodily** pain have you had during the **past 4 weeks**? (Mark one box)

☐ None ☐ Very mild ☐ Mild
☐ Moderate ☐ Severe ☐ Very severe

Q22 During the **past 4 weeks,** how much did pain interfere with your normal work (including both work outside the home and housework)?

☐ Not at all ☐ A little bit ☐ Moderately
☐ Quite a bit ☐ Extremely

These questions are about how you feel and about how things have been with you **during the past 4 weeks**. For each question, please give the one answer that comes closest to the way you have been feeling. (Mark one box on each line).

| How much time during the **past 4 weeks...** | All of the time | Most of the time | A good bit of the time | Some of the time | A little of the time | None of the time |
|---|---|---|---|---|---|---|
| Q23 Did you feel full of life? | ☐ | ☐ | ☐ | ☐ | ☐ | ☐ |
| Q24 Have you been a very nervous person? | ☐ | ☐ | ☐ | ☐ | ☐ | ☐ |
| Q25 Have you felt so down in the dumps that nothing could cheer you up? | ☐ | ☐ | ☐ | ☐ | ☐ | ☐ |
| Q26 Have you felt calm and peaceful? | ☐ | ☐ | ☐ | ☐ | ☐ | ☐ |
| Q27 Did you have a lot of energy? | ☐ | ☐ | ☐ | ☐ | ☐ | ☐ |
| Q28 Have you felt downhearted and low? | ☐ | ☐ | ☐ | ☐ | ☐ | ☐ |

Continued... These questions are about how you feel and about how things have been with you **during the past 4 weeks**. For each question, please give the one answer that comes closest to the way you have been feeling. (Mark one box on each line).

| How much time during the **past 4 weeks...** | All of the time | Most of the time | A good bit of the time | Some of the time | A little of the time | None of the time |
|---|---|---|---|---|---|---|
| Q29 Did you feel worn out? | ☐ | ☐ | ☐ | ☐ | ☐ | ☐ |
| Q30 Have you been a happy person? | ☐ | ☐ | ☐ | ☐ | ☐ | ☐ |
| Q31 Did you feel tired? | ☐ | ☐ | ☐ | ☐ | ☐ | ☐ |

Q32 During the **past 4 weeks,** how much of the time has your **physical health or emotional problems** interfered with your social activities (like visiting friends, relatives, etc)? (Mark one box)

☐ All of the time ☐ Most of the time ☐ Some of the time
☐ A little of the time ☐ None of the time

How TRUE or FALSE is **each** of the following statements for you? (Mark one box on each line)

| | Definitely true | Mostly true | Don't know | Mostly false | Definitely false |
|---|---|---|---|---|---|
| Q33 I seem to get ill more often than other people | ☐ | ☐ | ☐ | ☐ | ☐ |
| Q34 I am as healthy as anybody I know | ☐ | ☐ | ☐ | ☐ | ☐ |
| Q35 I expect my health to get worse | ☐ | ☐ | ☐ | ☐ | ☐ |
| Q36 My health is excellent | ☐ | ☐ | ☐ | ☐ | ☐ |

## MODIFIED SOMATIC PERCEPTION QUESTIONNAIRE

Please describe how you have felt during the PAST WEEK by marking a cross (X) in the appropriate box. In each row place only one cross. Please answer all questions. Do not think too long before answering.

| | | **Not at all** | **A little, slightly** | **A great deal, quite a bit** | **Extremely, could not have been worse** |
|---|---|---|---|---|---|
| 1 | **Heart rate increase** | | | | |
| 2 | Feeling hot all over | | | | |
| 3 | **Sweating all over** | | | | |
| 4 | Sweating in a particular part of the body | | | | |
| 5 | **Pulse in neck** | | | | |
| 6 | Pounding in head | | | | |
| 7 | **Dizziness** | | | | |
| 8 | Blurring of vision | | | | |
| 9 | **Feeling faint** | | | | |
| 10 | Everything appearing unreal | | | | |
| 11 | **Nausea** | | | | |
| 12 | Butterflies in stomach | | | | |
| 13 | **Pain or ache in stomach** | | | | |
| 14 | Stomach churning | | | | |
| 15 | **Desire to pass water** | | | | |
| 16 | Mouth becoming dry | | | | |
| 17 | **Difficulty swallowing** | | | | |
| 18 | Muscles in neck aching | | | | |
| 19 | **Legs feeling weak** | | | | |
| 20 | Muscles twitching or jumping | | | | |
| 21 | **Tense feeling across forehead** | | | | |
| 22 | Tense feeling in jaw muscles | | | | |

Official use only Score = ...............................

## MODIFIED ZUNG INDEX

Please indicate for each of these questions which answer best describes how you have been feeling recently by marking a cross (X) in the appropriate box. In each row place only one cross. Please answer all questions. Do not think too long before answering.

| | | Rarely or none of the time (less than 1 day per week) | Some or little of the time (1 - 2 days per week) | A moderate amount of time (3-4 days per week) | Most of the time (5-7 days per week) |
|---|---|---|---|---|---|
| 1 | I feel downhearted and sad | | | | |
| 2 | **Morning is when I feel best** | | | | |
| 3 | I have crying spells or feel like it | | | | |
| 4 | **I have trouble getting to sleep at night** | | | | |
| 5 | I feel that nobody cares | | | | |
| 6 | **I eat as much as I used to** | | | | |
| 7 | I still enjoy sex | | | | |
| 8 | **I notice I am losing weight** | | | | |
| 9 | I have trouble with constipation | | | | |
| 10 | **My heart beats faster than usual** | | | | |
| 11 | I get tired for no reason | | | | |
| 12 | **My mind is as clear as it used to be** | | | | |
| 13 | I tend to wake up too early | | | | |
| 14 | **I find it easy to do the things I used to** | | | | |
| 15 | I am restless and I can't keep still | | | | |
| 16 | **I feel hopeful about the future** | | | | |
| 17 | I am more irritable than usual | | | | |
| 18 | **I find it easy to make a decision** | | | | |
| 19 | I feel quite guilty | | | | |
| 20 | **I feel that I am useful and needed** | | | | |
| 21 | My life is pretty full | | | | |
| 22 | **I feel that others would be better off if I were dead** | | | | |
| 23 | I am still able to enjoy the things I used to | | | | |

Official use only Score = ..............................

Thank You for taking the time to fill in this form

# *Appendix I - Journal publications*

PAGE/PAGES
EXCLUDED
UNDER
INSTRUCTION
FROM
UNIVERSITY

# Appendix J – Media publications (includes CD)

NOT COPIED ON INSTRUCTION FROM THE UNIVERSITY