



Remnant, J.G. and Lea, Richard G. and Allen, Ceri E. and Huxley, J.N. and Robinson, Robert S. and Brower, A. (2014) Novel gonadal characteristics in an aged bovine freemartin. *Animal Reproduction Science*, 146 (1-2). pp. 1-4. ISSN 1873-2232

**Access from the University of Nottingham repository:**

<http://eprints.nottingham.ac.uk/34519/7/bovine%20freemartin.pdf>

**Copyright and reuse:**


The Nottingham ePrints service makes this work by researchers of the University of Nottingham available open access under the following conditions.

This article is made available under the Creative Commons Attribution Non-commercial Share Alike licence and may be reused according to the conditions of the licence. For more details see: <http://creativecommons.org/licenses/by-nc-sa/2.5/>

**A note on versions:**

The version presented here may differ from the published version or from the version of record. If you wish to cite this item you are advised to consult the publisher's version. Please see the repository url above for details on accessing the published version and note that access may require a subscription.

For more information, please contact [eprints@nottingham.ac.uk](mailto:eprints@nottingham.ac.uk)



## Novel gonadal characteristics in an aged bovine freemartin



J.G. Remnant\*, R.G. Lea, C.E. Allen, J.N. Huxley, R.S. Robinson, A.I. Brower

School of Veterinary Medicine and Science, University of Nottingham, Sutton Bonington Campus, Loughborough, Leicestershire LE12 5RD, United Kingdom

### ARTICLE INFO

#### Article history:

Received 28 September 2013

Received in revised form 7 February 2014

Accepted 15 February 2014

Available online 1 March 2014

#### Keywords:

Anti-mullerian hormone (AMH)

Bovine

CYP17A1

Freemartin

Gonad

### ABSTRACT

The gonads from a five-year-old freemartin Holstein animal were subjected to morphological analysis and to immunohistochemistry using antibodies against developmental and functional markers. We demonstrate, for the first time, the retention of anti-mullerian hormone (AMH) producing intratubular cells (Sertoli cells) in the context of abundant steroidogenic interstitial cells, and structures consistent with clusters of luteal cells. This novel report describes the clinical, gross and histological findings accompanying this newly described gonadal immunophenotype, and its implication in the understanding of freemartin development.

© 2014 The Authors. Published by Elsevier B.V. Open access under [CC BY-NC-SA license](https://creativecommons.org/licenses/by-nc-sa/4.0/).

### 1. Introduction

Freemartinism is the most common cause of intersexuality in cattle (Padula, 2005). During bovine fetal development, the male gonad begins to differentiate at an earlier stage of gestation than the female gonad and therefore becomes steroidogenically active earlier than the female (Short et al., 1970). Freemartinism occurs when fusion of placental blood vessels in cattle with twin pregnancies permits male gonad derived hormones (anti-mullerian hormone (AMH) and testosterone) to transfer to a female twin embryo, which in turn inhibits female reproductive tract development. The result is varying degrees of female reproductive tract suppression (AMH) with stimulation of the male tract (testosterone) (Long, 1990). Shared foetal blood supply also allows transfer of

haematopoietic stem cells between embryos, enabling confirmation of freemartinism through detection of both XX and XY chromosomes in lymphocytes. Varying degrees of masculinisation of the reproductive tract have been described (Peretti et al., 2008) including a freemartin with a rudimentary penis (Buyse, 1936). The present study builds on previous morphologic descriptions of freemartin gonads by characterizing structures present in mature freemartin gonads using immunohistochemistry for developmental and functional markers. A suspected freemartin was donated to the University of Nottingham (School of Veterinary Medicine and Science) shortly after birth. On examination the calf had grossly abnormal external genitalia and urinated in an upward trajectory from the dorsal aspect of the vulva. Karyotyping was carried out on a jugular blood sample and confirmed the calf to be an XX/XY chimaera, confirming a diagnosis of freemartinism (Herschler et al., 1966). The calf remained phenotypically female and behaviourally 'bull like', exhibiting unprovoked aggression towards handlers that necessitated euthanasia at five years of age.

\* Corresponding author. Tel.: +44 0115 951 6116; fax: +44 0115 951 6415.

E-mail address: [john.remnant@nottingham.ac.uk](mailto:john.remnant@nottingham.ac.uk) (J.G. Remnant).

Previous studies have described features of gonads of immature freemartin cattle (Cabanca et al., 2007; Harikae et al., 2012; Khan and Foley, 1994), but to the best of the authors' knowledge this is the first study to provide immunohistochemical characterization of the gonads of a mature bovine freemartin. Previous studies have also described a loss of AMH by the freemartin fetal gonad before puberty, and suggested this coincides with rising testosterone levels (Rota et al., 2002). In the current study, AMH immunoreactivity was investigated in a bovine intersex gonad years past puberty.

## 2. Materials and methods

A complete post-mortem examination was performed and tissue samples, fixed in 10% buffered neutral formalin for 2 days, were paraffin embedded, routinely sectioned (5  $\mu$ m), and stained with haematoxylin and eosin (HE). Immunohistochemistry was performed on sections of gonad using primary antibodies specific for myeloid cell leukaemia sequence, MCL1 (rabbit polyclonal; 2  $\mu$ g/ml; S-19, Santa Cruz, CA) (a marker of oocytes, Fowler et al., 2008); cytochrome P450, family 17, subfamily A, polypeptide 1 [CYP17A1] (rabbit polyclonal; 6.25 ng/ml: kindly provided by Professor Ian Mason, University of Edinburgh) and AMH (goat polyclonal; 0.12  $\mu$ g/ml: Santa Cruz). Positive control tissues were sheep foetal ovary (MCL1) and sheep foetal testis (CYP17A1, AMH). Antigen retrieval procedures were necessary for exposure of all epitopes. Sections were heated in 0.01 M citrate buffer pH 6.0 for 20 min and antibody labelling visualised using a peroxidase/DAB detection system (Bond Autostainer and reagents: Leica Microsystems UK Ltd, Milton Keynes, UK). Negative controls comprised sections incubated with non-specific rabbit or goat IgG at the same concentration as the primary antibody. All sections were counterstained with haematoxylin, dehydrated, cleared in xylene and mounted with DPX.

## 3. Results

Gross post-mortem findings included a coiled, muscular, penis-like structure with a volume of approximately 80 cm<sup>3</sup>, lying underneath the vestibule with a central, blind ending, mucosa lined lumen that was continuous with the urethra. The urethral orifice was found directly dorsal to the clitoris. The gonads were mobile, externally palpable subcutaneous masses located in the inguinal region. The gonadal structures included pampiniform plexi adjacent to the epididymis. Spermatic cord-like structures extended through the inguinal rings that included vas deferens, blood supply and cremaster muscle. On gross examination of the fresh, sectioned gonad, tissue architecture identifiable as the body of the testis or as ovary was not identified, rather, the gonads were composed of bulging, pink-red parenchyma that included multiple, variably sized, tan-orange structures resembling ovarian corpora lutea (Fig. 1), which were surrounded by fibrous pale or soft brown interstitium.

On histological examination, the penile structure located beneath the vestibule was histologically well

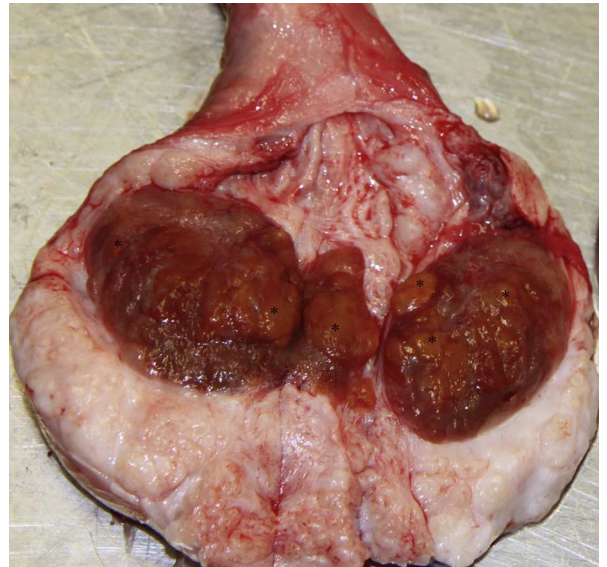


Fig. 1. Mature freemartin gonad showing multiple corpora lutea-like structures (CL) throughout (examples identified with \*).

developed with the lumen lined by pseudostratified epithelium. In the gonad, tubular structures lined by elongate epithelial cells (consistent with the appearance of seminiferous tubules), were present. In addition, well-demarcated clusters of large, round cells with abundant vacuolated cytoplasm, and elongate cells in a vascular stroma were evident (Fig. 2).

Gonadal cells interpreted as intra-tubular Sertoli-cells on HE examination were immunohistochemically positive for AMH, with pockets of tubules having strong positive labelling (Figs. 2 and 3). Areas of steroidogenesis, identified through positive labelling for CYP17A1, were localised to

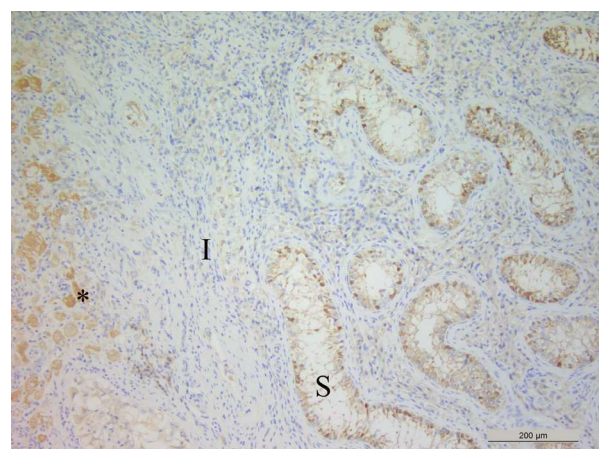
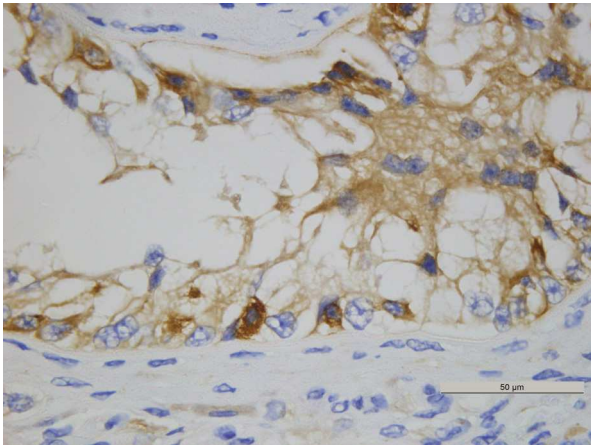
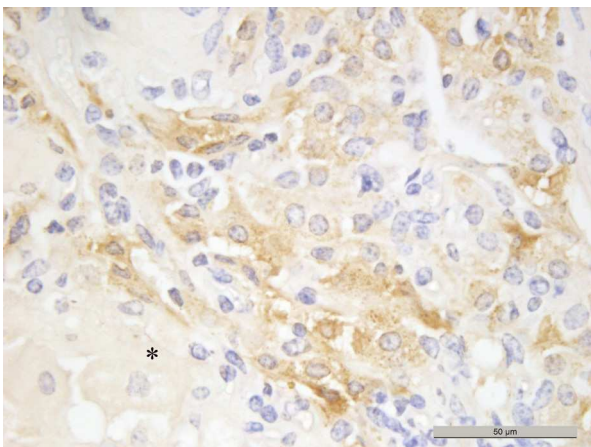


Fig. 2. Immunohistochemically labelled section of mature freemartin gonad showing the margin of a CL like structure (\*), a band of interstitial cells (I), and a cluster of seminiferous cord like structures (S). Dark brown labelling depicts specific AMH immunoreactivity of cells lining the cords and there was some pale brown non-specific labelling of the CL like structure. (For interpretation of the references to colour in this figure legend, the reader is referred to the web version of the article.)



**Fig. 3.** Localisation of AMH protein in the freemartin gonad. Positive labelling indicates AMH positive Sertoli-like cells in the seminiferous cords.

the described elongate cells within the interstitium of the gonad (Fig. 4). Cells, seen macroscopically to form orange nodules and histologically resembling ovarian luteal tissue, did not label with AMH or CYP17A1 antibodies, and showed non-specific binding when using either of these antibodies (Figs. 2 and 4) and when treated with goat IgG on negative control slides (see supplementary material). Follicular structures were not identified grossly or in standard HE stained sections of the gonad, nor were oocytes observed following immunohistochemical labelling for the oocyte marker MCL1 (data not shown). Positive control sections for AMH, CYP17A1 and MCL1 exhibited strong positive labelling in expected regions (see Supplementary material).



**Fig. 4.** Localisation of CYP17A1 protein in the mature freemartin gonad. Dark brown, granular staining depicts specific CYP17A1 immunoreactivity of elongate interstitial cells and pale brown non-specific binding is present in an adjacent CL like structure (\*). (For interpretation of the references to colour in this figure legend, the reader is referred to the web version of the article.)

#### 4. Discussion

Immunohistochemical characterization of the gonads from a highly masculinised, mature freemartin revealed a previously unrecognised gonadal phenotype. The gonad consisted of developed seminiferous tubules containing Sertoli cells that were continuing to express AMH. Areas of steroidogenesis were also identified; the positive CYP17A1 labelling of these areas combined with the morphology and interstitial location of these cells is consistent with testicular Leydig cells or ovarian theca cells. Structures identified as corpora lutea were also evident but in the absence of any follicular structures.

There are sporadic reports of AMH expression in fetal and immature freemartin gonads, from developed seminiferous tubules and small islands of tissue separate from seminiferous tubules (Cabanca et al., 2007; Harikae et al., 2012; Vigier et al., 1984). Rota et al. (2002) measured circulating AMH in male, female, and freemartin calves. In freemartins, levels fell to that of normal female calves within 5 weeks of birth and in male calves they fell to normal female levels by 5 months of age. Prior to the present study, AMH had not been detected in mature freemartin gonads (Cabanca et al., 2007; Harikae et al., 2012), but one study did conclude that in cases of extreme gonadal masculinisation, AMH may persist for several months after birth (Rota et al., 2002). The same authors found that in these cases the decline in circulating AMH in freemartins was accompanied by increased testosterone production at puberty. In the present study, populations of both AMH positive and androgen positive cells were present in the adult bovine freemartin. Studies of male intersex and cryptorchid stallions have identified AMH expression in mature (three to four years old) testis (Ball et al., 2008), and suggest that the inguinal position of the ovo-testis may have contributed to the persistence of AMH expressing tissue. Although, to the best of our knowledge, there have been no studies of AMH in bovine cryptorchid testes, circulating AMH has been used as an indicator of functional cryptorchidism in calves (Kitahara et al., 2012). However, no investigations on mature animals were carried out, and no significant difference was found between circulating AMH levels in normal entire calves and cryptorchid calves.

The clusters of round cells identified in this study, suggestive of corpora lutea, have been described prior to the routine use of immunohistochemistry as “luteal or interstitial cell masses” (McEntee, 1990). A similar structure was also shown in a report by Khan and Foley (1994), with a figure legend describing abundant interstitial cells, cysts, and degenerate granulosa cells of a follicle. In the same report, follicles were described in many immature freemartin gonads. In contrast, in the mature freemartin gonad reported here, follicles or ova were not observed but there were numerous corpora lutea-like structures. Consistent with the findings of Rodgers et al. (1986), the structures previously ambiguously referred to as interstitial or luteal cell masses (Khan and Foley, 1994; McEntee, 1990) and interpreted as corpora lutea in our study, did not label with CYP17A1. The presence of these structures in an aged freemartin, coupled with the apparent frequency of follicular structures reported in immature freemartin

gonads, raises the possibility that these structures represent the end stage of follicular development in the absence of ovulation, similar to a luteinised follicular cyst in an adult dairy cow (Garverick, 1997). It seems unlikely that spontaneous prostaglandin release and luteolysis would have occurred in this animal in the absence of an identifiable uterus. Though these cells have abundant vacuolated cytoplasm, immunohistochemical labelling suggests that they are incapable of producing estrogens and androgens. In contrast, the elongated interstitial cell population, found in close proximity, were CYP17A1 (androgen) positive, and may be of Leydig or theca origin, or a mixture of the two cell types. The presence of androgenic cells and aggressive behaviour suggest that testosterone was being produced in this animal, but further studies are needed to elucidate the interplay between the hypothalamic pituitary axis, circulating hormones and the cellular composition of the gonad in the freemartin.

In conclusion, we have characterized an aged bovine freemartin gonad as having persistent AMH production in Sertoli cells and confirmed androgen production from cells located in the interstitium. We also identified structures suggestive of corpora lutea in the absence of visible follicles or oocytes. These findings were not anticipated based on earlier reports indicative of a decline in AMH production in very early in life and abundant follicles in freemartin gonads (Khan and Foley, 1994). The detection of AMH, androgen producing cells and numerous structures that appear to be luteal raises a number of questions about the interplay of AMH and testosterone and the effects of these hormones on female ovarian structures in the intersex gonad. Hormone assays of adult bovine freemartins matched to gonadal histologic examination as we have described could be a valuable next step in our understanding of intersex conditions.

### Conflicts of interest

The authors confirm that they have no conflict of interest to declare. The work was funded by the University of Nottingham.

### Acknowledgment

The authors would like to thank Pat Fisher, University of Nottingham, for carrying out the karyotyping and Max Wood, a final year veterinary student at the University of Nottingham who assisted with the post mortem examination.

### Appendix A. Supplementary data

Supplementary material related to this article can be found, in the online version, at <http://dx.doi.org/10.1016/j.anireprosci.2014.02.011>.

### References

- Ball, B.A., Conley, A.J., Grundy, S.A., Sabeur, K., Liu, I.K.M., 2008. Expression of anti-Müllerian hormone (AMH) in the equine testis. *Theriogenology* 69, 624–631.
- Buyse, A., 1936. A case of extreme sex-modification in an adult bovine freemartin. *The Anatomical Record*, 43–58.
- Cabianca, G., Rota, A., Cozzi, B., Ballarin, C., 2007. Expression of AMH in female fetal intersex gonads in the bovine. *Anatomia, Histologia, Embryologia* 36, 24–26.
- Fowler, P.A., et al., 2008. In utero exposure to low doses of environmental pollutants disrupts fetal ovarian development in sheep. *Molecular Human Reproduction* 14, 269–280.
- Garverick, H.A., 1997. Ovarian follicular cysts in dairy cows. *Journal of Dairy Science* 80, 995–1004.
- Harikae, K., et al., 2012. Evidence for almost complete sex-reversal in bovine freemartin gonads: formation of seminiferous tubule-like structures and transdifferentiation into typical testicular cell types. *Journal of Reproduction and Development* 58, 654–660.
- Herschler, M.S., Fechtmeier, N.S., Gilmore, L.O., 1966. Identification of freemartins by chromosomal analysis. *Journal of Dairy Science* 49, 113–114.
- Khan, M.Z., Foley, G.L., 1994. Retrospective studies on the measurements, karyotyping and pathology of reproductive organs of bovine freemartins. *Journal of Comparative Pathology* 110, 25–36.
- Kitahara, G., et al., 2012. Anti-Müllerian hormone (AMH) profiles as a novel biomarker to evaluate the existence of a functional cryptorchid testis in Japanese Black calves. *Journal of Reproduction and Development* 58, 310–315.
- Long, S.E., 1990. Development and diagnosis of freemartinism in cattle. *In Practice*, 208–210.
- McEntee, K., 1990. *Reproductive Pathology of Domestic Mammals*. Academic Press, San Diego.
- Padula, A.M., 2005. The freemartin syndrome: an update. *Animal Reproduction Science* 87, 93–109.
- Peretti, V.C.F., Albarella, S., Paciello, O., Dario, C., Barbieri, V., Iannuzzi, L., 2008. XX/XY chimerism in cattle: clinical and cytogenetic studies. *Sexual Development*, 24–30.
- Rodgers, R.J., Waterman, M.R., Simpson, E.R., 1986. Cytochromes P-450<sub>sc</sub>, P-450(17)<sub>α</sub>, adrenodoxin, and reduced nicotinamide adenine dinucleotide phosphate-cytochrome P-450 reductase in bovine follicles and corpora lutea. Changes in specific contents during the ovarian cycle. *Endocrinology* 118, 1366–1374.
- Rota, A., Ballarin, C., Vigier, B., Cozzi, B., Rey, R., 2002. Age dependent changes in plasma anti-Müllerian hormone concentrations in the bovine male, female, and freemartin from birth to puberty: relationship between testosterone production and influence on sex differentiation. *General and Comparative Endocrinology* 129, 39–44.
- Short, R.V., Jost, A., Harris, G.W., Ford, C.E., 1970. The bovine freemartin: a new look at an old problem [and discussion]. *Philosophical Transactions of the Royal Society of London. B, Biological Sciences* 259, 141–147.
- Vigier, B., Tran, D., Legeai, L., Bezaud, J., Josso, N., 1984. Origin of anti-Müllerian hormone in bovine freemartin fetuses. *Journal of Reproduction and Fertility* 70, 473–479.