

**A Patient-Friendly Web Resource for Vascular Anomalies:
Establishing a Connection between Patients and Clinicians**

by
ELEANOR LOUISE BAILEY

A thesis submitted to Johns Hopkins University
in conformity with the requirements for
the degree of Master of Arts

Baltimore, Maryland
March, 2017

© 2017 *Eleanor Louise Bailey*
All Rights Reserved

ABSTRACT

Patient education is fundamental to patient-centered care which emphasizes shared decision-making between patients and clinicians. Patients and families must have a sufficient understanding of health information to participate in health decision-making, and this understanding is garnered from accurate, reliable, and readable health resources accompanied by helpful visuals. With 84% of Americans accessing health information online, the importance of ensuring these resources are comprehended by consumers must be emphasized. If health care providers wish to communicate with the general public, they must ensure health information is written at a level understandable to the average American.

A 2016 study of online resources about vascular anomalies, including those from Boston Children's Hospital, Cincinnati Children's Hospital, and Johns Hopkins Hospital, revealed none of these resources are readable by the average American. The language and sentence structure are complex, commensurate with the reading level of high school or college graduates, while the average American reads at the seventh grade level. Additionally, few visual aids about vascular anomalies exist, and the primary visual representations shown are graphic patient photographs.

The lack of understandable resources about vascular anomalies hinders a shared decision-making process between patients or families and clinicians. By utilizing a combination of readability tests as well as the first standardized index of quality health information, known as DISCERN, a comprehensive and readable source of health information about vascular anomalies was developed. The diagnostic and treatment information was gathered from several experts in the field and vetted by the specialists at Johns Hopkins Hospital. This web resource contains text that is understandable to the average American and illustrations that show the condition without frightening patients.

A disparity exists between how patients and clinicians approach health information; this is apparent in how web-based patient resources are currently presented. To establish a connection between patients and clinicians through web-based patient education, the principles of design governing traditional visual communication must be applied in the virtual world and amended to include accessibility, readability, and organization in virtual space.

Eleanor Bailey

CHAIRPERSONS OF THE SUPERVISORY COMMITTEE

Clifford R. Weiss, M.D.

Associate Professor of Radiology, Surgery, and Biomedical Engineering

The Johns Hopkins University School of Medicine

Medical Director, Johns Hopkins CBID

Director, Interventional Radiology Research

The Johns Hopkins Hospital

Katherine Brown Püttgen, M.D.

Assistant Professor of Dermatology

The Johns Hopkins University School of Medicine

Division Chief, Pediatric Dermatology

The Johns Hopkins Hospital

Gary P. Lees, M.S., C.M.I., F.A.M.I.

Professor and Chair, Department of Art as Applied to Medicine

The Johns Hopkins University School of Medicine

ACKNOWLEDGEMENTS

This project is the culmination of several great minds. Their knowledge, support, and guidance have shaped this thesis and by extension, my education. I would like to offer my thanks to the following people.

Dr. Clifford Weiss, Associate Professor of Radiology, Surgery, and Biomedical Engineering at the Johns Hopkins University School of Medicine. His passion for the field of vascular anomalies and his dedication to his patients inspired my interest in patient education. Dr. Weiss was instrumental in ensuring the accuracy of information about diagnostic and treatment methods produced through this project.

Dr. Katherine Brown Püttgen, Assistant Professor of Dermatology at the Johns Hopkins University School of Medicine. She introduced me to new approaches to patient education, giving me a broad perspective of how I can contribute to this field. Her willingness to make time for me and teach me about hemangiomas and their impact on families makes me appreciate the relationship medical illustrators have with clinicians.

Gary Lees, my departmental advisor and Chair of the Department of Art as Applied to Medicine at the Johns Hopkins University School of Medicine. He gave me the encouragement I needed to persevere, and he allowed me to work independently, developing my skills as a project manager.

Aline Lin, Link Studios. She provided instrumental feedback on the layout and design of the web resource created through this thesis project. Her input has improved my proficiency in design and optimizing user experience.

Michael Linkenhoker, Link Studios, Adjunct Assistant Professor at the Department of Art as Applied to Medicine at the Johns Hopkins University School of Medicine. He

sparked my interest in interactive design and helped to cultivate my understanding of digital communication.

Dacia Balch, Academic Program Administrator, Department of Art as Applied to Medicine, the Johns Hopkins University School of Medicine. Dacia has been an advocate, resource, office assistant, coach, and friend throughout this process. She always encouraged me to see new perspectives, and for that I am grateful.

Corinne Sandone, Associate Professor, Director of Graduate Program, Department of Art as Applied to Medicine, the Johns Hopkins University School of Medicine. She provided me with the resources I needed to make this project happen.

My classmates in the Graduating Class of 2017: Katie Bergdale, Nicholas Reback, Daniel Hermansen, Julia Lerner, Li Yao, and Sarah Chen. They have been a talented, fun, hard-working group of people who encouraged me and kept me sane.

The Class of 2018. These ladies made every day interesting and full of laughter.

My Family: Dad and Lisa, who endlessly supported me. Mom, for her encouragement, sense of humor, and willingness to listen. Brady, for making me smile and always being proud of me. Bo, Josie and Mark, Charles and Morgan, and Angus and Aly, for reminding me that I have family everywhere and getting me through the tough times.

My Friends: Amir Heravi, Lucas Muñiz, Erik Antonio, Danae Carlson, Mica Hardwick, Anna Grace Mills, Jacob Opdahl. I am grateful to have known each of you. Thank you for teaching me to chase my dreams.

TABLE OF CONTENTS

ABSTRACT.....	ii
ACKNOWLEDGEMENTS.....	iv
TABLE INDEX.....	viii
FIGURE INDEX.....	ix
INTRODUCTION	
Patient Education and the Internet.....	1
Readability.....	2
Vascular Anomalies Online Resources.....	3
The Logical Next Step.....	4
Vascular Anomalies Background	5
Current State of the Field.....	5
MATERIALS AND METHODS	
Research and Planning.....	10
Illustration Process.....	17
Website Development.....	24
Review of Resource using DISCERN.....	29
Transfer of Content to Hopkins Website.....	32
RESULTS AND DISCUSSION	
CONCLUSION	
Impact of Organization	36
Disease-Specific Centers: A Patient’s Approach.....	36
Establishing a Connection.....	37
Asset Referral Information.....	38
APPENDIX A.....	40
APPENDIX B.....	44

APPENDIX C.....	63
CITED REFERENCES.....	64
GENERAL REFERENCES.....	65
VITA.....	66

TABLE INDEX

<i>Table 1.</i> Results of the National Assessment of Adult Literacy. The assessment was performed in 2003 and tested over 19,000 adults, age sixteen and older, in national and state-level assessments (America's Health Literacy, 2008).	2
<i>Table 2.</i> ISSVA Classification of Vascular Anomalies ©2014 International Society for the Study of Vascular Anomalies Available at "issva.org/classification" Accessed March 1, 2017.	5
<i>Table 3.</i> Excerpt from the venous malformation plain language table. The full table can be found in Appendix B.	16
<i>Table 4.</i> DISCERN questions and rating scale.	31
<i>Table 5.</i> Assessment of the readability of each page. The Glossary page and the "What do they look like?" page have been excluded because they do not contain sufficient text.	35
<i>Table 6.</i> Vascular Anomalies Research.	62

FIGURE INDEX

<i>Figure 1.</i> (a) Screen capture of Seattle Children’s Hospital web page about VAs. Text not intended to be read.	6
<i>Figure 2.</i> Patient images of VAs, taken from the top results of a Google image search of the term “Vascular Anomaly”	9
<i>Figure 3.</i> Overview Map. This map image is used as one form of navigation in the site.	10
<i>Figure 4.</i> This chart describes how a user may click through the website.	12
<i>Figure 5.</i> This site map shows where pages will be located (nested) within each other.	13
<i>Figure 6.</i> A screen capture of a tooltip that appears when a cursor hovers over the phrase “Vascular Anomalies.	14
<i>Figure 7.</i> Blocking in the model for illustrations A (left) and B (right).	20
<i>Figure 8.</i> Lights and darks added to establish form for illustrations A (left) and B (right).	20
<i>Figure 9.</i> Adding detail to illustrations A (left) and B (right).	21
<i>Figure 10.</i> Adding the original sketch of the model on top of the painted layers for illustrations A (left) and B (right).	21
<i>Figure 11.</i> Adding a venous malformation to the girl’s cheek in illustration A.	22
<i>Figure 12.</i> Final layout and details for illustrations A (top) and B (bottom).	23
<i>Figure 13.</i> Initial look of website with Salt theme. Text not intended to be read.	25
<i>Figure 14.</i> Enfold theme with demo medical content. Not all text is intended to be read.	26
<i>Figure 15.</i> Avada theme with some VA content uploaded. Not all text is intended to be read.	26
<i>Figure 16.</i> Color scheme exploration. Not all text is intended to be read.	27
<i>Figure 17.</i> Logo and final color scheme with normal color vision (left) and with Deuteranopia color vision (right).	27
<i>Figure 18.</i> The initial design of the Venous Malformation page. Not all text is intended to be read.	28
<i>Figure 19.</i> Adjustments to the Venous Malformation page were made to improve use of space and reduce page length. Not all text is intended to be read.	29

Figure 20. Screen capture of the Johns Hopkins Hospital website with new readable content and illustrations. Not all text is intended to be read.33

Figure 21. Screen capture of the Vascular Anomalies homepage. Not all text is intended to be read.39

Figure 22. Screen capture of the Overview page. Not all text is intended to be read.40

Figure 23. Screen capture of the Vascular Malformations page. Not all text is intended to be read.41

Figure 24. Screen capture of the Venous Malformation page (footer cropped). Not all text is intended to be read.42

INTRODUCTION

Patient Education and the Internet

The phrase “patient-centered care” was coined to convey a clinician’s duty to understand the experience of illness and address a patient’s needs within an increasingly complex and fragmented health care delivery system (Barry et al. 2012). The National Academy of Medicine defines this approach as one where patients’ values guide all clinical decisions. Educating patients is fundamental to patient-centered care. For patients and families to participate in decision-making, they must have sufficient understanding of health information. This understanding is garnered from accurate, reliable, and readable health resources that are accompanied by helpful visuals.

The Internet is an expanding information network that is accessible to most Americans. From 2000 to 2015, the percentage of Americans who use the Internet jumped from 52% to 84% with most users being between ages 18 to 29 (Perrin et al., 2015). In 2012, 72% of internet users said they looked for online health information in the past year, and half of health information searches were on behalf of someone else (Fox et al., 2013). Parents and allies of patients are utilizing the Internet to find information on diagnoses, treatments, and other health resources; many of these adults are expected to make healthcare-related decisions on behalf of a child or minor.

Understanding health information requires health literacy, the ability to understand and process health information and services. Inadequate levels of parent health literacy have been linked to higher rates of emergency department visits among their children, poor adherence to medication dosing and treatment plans, and difficulty understanding healthcare-related tools such as growth-charts (Davis et al., 2016). With 84% of Americans having access to online health information, ensuring consumer comprehension of these resources is vital to patient-centered care.

Readability

The results of the most recent National Assessment of Adult Literacy show that only 12% of adults are considered proficient, meaning they are able to comprehend existing health resources and make decisions based on those resources (America's Health Literacy, 2008) (Table 1). According to the United States Department of Health and Human Services, the average American's reading level is seventh grade. If healthcare providers aim to communicate with the general public, they must ensure that health information is written at a seventh grade reading level.

Health Literacy Level	Task Examples	Percentage
Proficient	Using a table, calculate an employee's share of health insurance costs for a year	12%
Intermediate	Read instructions on a prescription label, and determine what time a person can take the medication.	53%
Basic	Read a pamphlet, and give two reasons a person with no symptoms should be tested for a disease.	21%
Below Basic	Read a set of short instructions, and identify what is permissible to drink before a medical test.	14%

Table 1. Results of the National Assessment of Adult Literacy. The assessment was performed in 2003 and tested over 19,000 adults, age sixteen and older, in national and state-level assessments (America's Health Literacy, 2008).

Several tools have been developed to assess readability. The Flesch-Kincaid Grade Level test (FKGL) and Flesch Reading Ease Score (FRES) measure how difficult content is to understand; their formulas evaluate number of words per sentence and the number of syllables per word. Another aspect of readability is the number of complex words, which is evaluated by the Gunning Fog Index. The SMOG, which is an acronym for Simple Measure of Gobbledygook and is a variation of the Gunning Fox Index, estimates the years of education needed to comprehend a text.

By utilizing a combination of these tests, content can be altered to match a desired reading level. However, to reach the 88% of Americans who are not proficient in health literacy, resources should be evaluated not only for readability, but for quality of information. DISCERN is the first standardized index of quality health information. This tool was developed through the analysis of a random sample of consumer health information providing varying levels of evidence for the treatment choices they advertised. From this analysis, a set of guidelines was developed. DISCERN consists of fifteen questions that are answered with a rating from one (bad) to five (good). The questions are split into three categories to address: 1) the clarity of the resource's aim, 2) the degree to which the resource achieves its aims, and 3) the relevance of the information (British Library and the University of Oxford 1997).

Vascular Anomalies Online Resources

Vascular anomalies (VAs) are disorders of blood and lymphatic vessels. VAs affect approximately 5.5% of the population (Greene, 2013). Because VAs are present at birth and usually become apparent within the first few years of life, parents often are searching for information about VAs, including diagnostic and treatment resources. A 2016 study of online resources about vascular anomalies evaluated the top 30 websites based on a Google search of the terms “hemangioma”, “vascular malformation”, and “vascular anomalies”. The study revealed none of these resources are accessible to the average American. The average DISCERN score for all websites was 2.97, or a partially valid source of information on a one to five scale. The average reading level measured by FKGL was 12; only one website scored lower than 9th grade. The FRES is recommended to be 65/100 or above for health information. Yet, all of these websites scored below 60 with the average score being 40.43. According to this review, an increase in quality of information, measured by DISCERN score, correlated with an increase in FKGL and a decrease in

FRES (Davis et al., 2016). Resources with high quality information are written at a high grade level, and score poorly on readability tests. Thus, most websites with high quality information about vascular anomalies are not understandable by the average American.

The Logical Next Step

The lack of understandable resources about vascular anomalies hinders a shared decision-making process between patients or families and clinicians. To improve this process, an accurate and readable source of information about vascular anomalies must be developed. To reach the largest audience, this resource should be web-based.

The main objective of this project is to develop an online resource with readability in mind. The enabling objectives of this project are:

- 1) to provide users with accurate information regarding description, diagnostic process, and treatment options of vascular anomalies.
- 2) to write all text content at or below a 7th grade reading level according to the FKGL test, and below an 8th grade reading level according to the average of the Flesch-Kincaid Grade Level (FKGL), Gunning-Fog Score, Coleman-Liau Index, SMOG Index, and Automated Readability Index. Additionally, text content will earn a score of 65 or above according to the FRES.
- 3) to ensure the resource earns an average score of 4 or above when evaluated by the DISCERN instrument for its clarity of aim, achievement of aim, and relevance of information.

Vascular Anomalies Background

Vascular anomalies (VAs) are disorders of the endothelium of veins, arteries, capillaries, or lymphatics (Greene, 2013). Endothelium is the type of tissue that lines these vessels. Instead of forming a smooth vessel, the endothelium forms pockets, bubbles, tortuous vessels, or shunts. Pooling blood can lead to pain and hemorrhage. Shunting vessels put stress on the heart. VAs can occur anywhere in the body but often affect the head or neck. In 1996, the International Society for the Study of Vascular Anomalies (ISSVA) created the following table delineating the proper classification scheme of VAs (Table 1). However, the terminology surrounding VAs is inconsistent due to the perpetuation of obsolete classification schemes.

VASCULAR ANOMALIES				
Vascular Tumors			Vascular Malformations	
Benign	Locally Aggressive	Malignant	Simple	Combined
Infantile Hemangioma	Kaposiform heman-gioendothelioma	Anngiosarcoma	Capillary Malformation (C)	CVM, CLM
Congenital Hemangioma	Retiform hemangioen-dothelioma	Epithelioid heman-gioendothelioma	Lymphatic Malformation (LM)	LVM, CLVM
Tufted Hemangioma	PILA, Dabska tumor		Venous Malformation (VM)	CAVM
Spindle-cell Hemangioma	Composite hemangio-endothelioma		Arteriovenous Malforma-tion (AVM)	CLAVM
Epithelioid Hemangioma	Kaposi Sarcoma		Arteriovenous Fistula	
Pyogenic Granuloma				

Table 2. ISSVA Classification of Vascular Anomalies ©2014 International Society for the Study of Vascular Anomalies Available at "issva.org/classification" Accessed March 1, 2017.

Current State of the Field

Clinical study of VAs has been hindered by the use of incorrect terminology in literature, heterogeneity within a single category of lesions, and lack of large data pools of patients with these relatively rare conditions (Greene, 2013). The major hospitals and

centers that have overcome these issues and are performing clinical studies are also the ones that have made an effort to reach the general public through websites. These websites (Fig. 1), produced by hospitals such as Boston Children’s Hospital, Seattle Children’s Hospital, Cincinnati Children’s Hospital, and Johns Hopkins Hospital, provide general VA information that is not readable to the average American. Much of the text is dedicated to advertising for the specific clinic instead of educating about the condition, diagnosis, and treatment. Additionally, the websites created by three of the aforementioned hospitals contain no images of VAs. Aesthetically, these pages are just blocks of text.

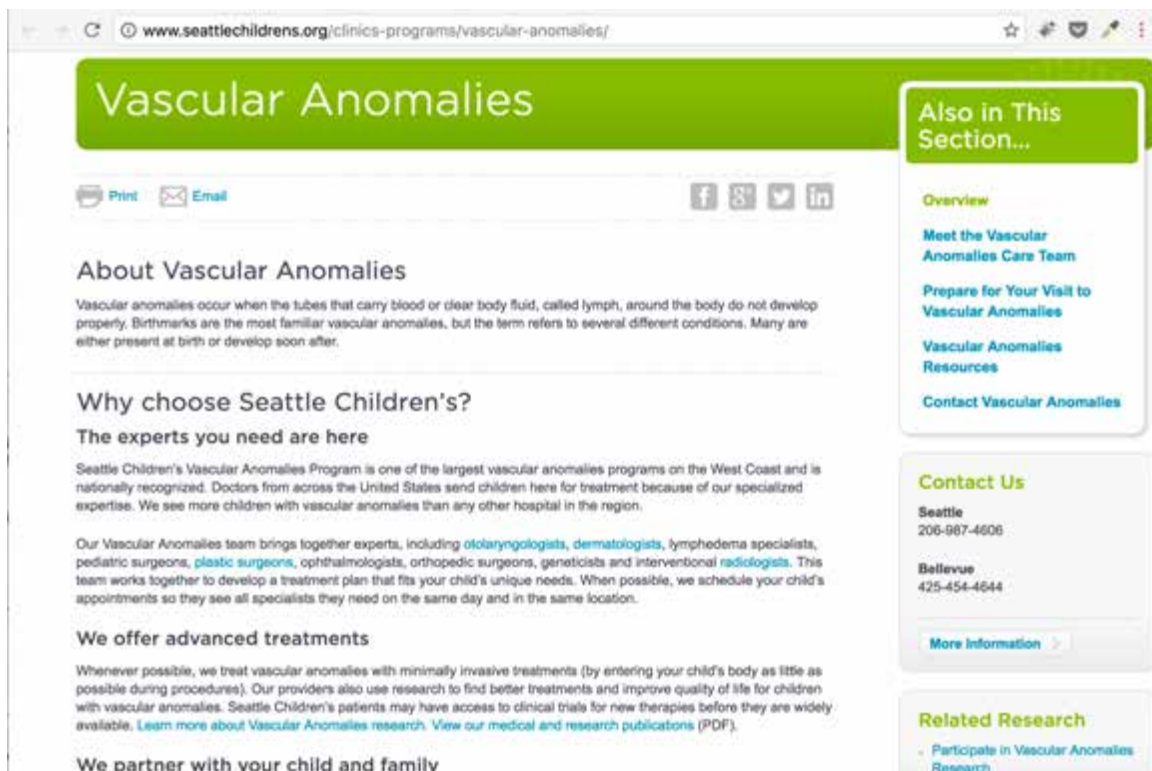


Figure 1. (a) Screen capture of Seattle Children’s Hospital web page about VAs. Text not intended to be read.

Vascular Anomalies Center | What are Vascular Anomalies?

Overview
Meet our Team
What Are Vascular Anomalies?
Programs and Services
For Patients and Families
Patient Stories
Clinician Resources
Research and Innovation
Contact Us
Conditions and Treatments
Videos
In the News
Find Us

Vascular anomalies are composed of blood vessels that have developed abnormally. These blood vessels include arteries, veins, lymphatic vessels and/or capillaries.

Boston Children's Hospital's Vascular Anomalies Center classifies vascular anomalies into two categories:

- vascular malformations
- vascular tumors

Both categories refer to a variety of non-cancerous **birthmarks** and lesions. Although lesions in these two groups can often look quite similar, they are biologically very different and, therefore, require different treatment. How vascular anomalies manifest themselves can vary greatly from patient to patient, from single "stand-alone" anomalies to complex conditions or syndromes that combine more than one anomaly or affect multiple parts of the body.

Vascular malformations

- Vascular malformations are benign (non-cancerous) lesions.
- They are present at birth, but may not become visible for weeks or months.
- Unlike hemangiomas, vascular malformations do not have a growth cycle and tend to grow slowly throughout a child's life.
- Vascular malformations are usually sporadic (occurring by chance), although some are inherited within families.
- There are several types of vascular malformations:
 - **Capillary (port wine stains)** are always present at birth as pink or purple skin patches.
 - **Venous malformations** are often confused with hemangiomas. They are soft to the touch and the color

Contact the Vascular Anomalies Center
617-355-5226
International: +1-617-355-5209
vascular@childrens.harvard.edu

Hemangioma and Vascular Malformation Center

HOME / SERVICES / H / HEMANGIOMA AND VASCULAR MALFORMATION CENTER

Recommend Email Print

Hemangioma and Vascular Malformation Center

Conditions Treated
Diagnosis and Treatment
Research
Clinical Trials
Related Resources
Meet the Team
Contact / Refer

Our Teamwork Makes Us Special in Treating Complex Vascular Anomalies

The Hemangioma and Vascular Malformation Center at Cincinnati Children's is one of the largest multidisciplinary centers in the country for vascular anomalies (blood vessels that have developed abnormally). We follow over 5,000 patients and see about 600 new patients each year. Both national and international cases as well as children and adults of all ages are treated in the clinic.

The program is a partnership between the Cincinnati Children's [Department of Surgery](#) and the [Division of Hematology / Oncology](#). Our multidisciplinary team specializes in establishing an accurate diagnosis, which can be challenging in these complex conditions but is essential to developing the most effective treatment plan possible.

Once a diagnosis is established, physicians from a variety of disciplines work closely to treat the vascular anomaly. This team may include surgeons, cardiologists, dermatologists, pathologists and interventional radiologists, depending on the diagnosis and location of the anomaly. Each specialist has an in-depth understanding of the complex problems associated with these conditions, and the team is known for its highly collaborative efforts – an important factor in successful treatment. The team comes together each week to discuss treatment options, patient history and imaging, and conducts a total of six interdisciplinary clinics each month (four at the Burnet Campus and two at the Liberty Campus).

The program offers treatment options not widely available at other centers. We are a leader in developing new [clinical trials](#) to improve the standard of care for the most difficult conditions. In fact, we are one of only a few programs in the nation to offer new treatments through clinical trials for patients with vascular anomalies.

In addition to offering accurate diagnosis and effective treatment, we follow short- and long-term outcomes to improve care over time. We are part of the Disease Specific

Cancer and Blood Diseases Institute

BEST CHILDREN'S HOSPITALS
US News
CANCER 2016-17

Read an overview about the Cancer and Blood Diseases Institute at Cincinnati Children's, including the related centers and programs that work together in a multidisciplinary approach.

Contact Us / Refer

Contact the Hemangioma and Vascular Malformation Center to make an appointment or refer a patient.

Figure 1. (continued). (b) A screen capture of the Boston Children's Hospital web page about VAs (top) and a screen capture of the Cincinnati Children's Hospital web page about VAs (bottom). Text not intended to be read.

www.hopkinsmedicine.org/interventional-radiology/conditions/malformations/

Conditions & Treatments

- Overview
- Vascular
 - Vascular Malformations
 - Treatment of Vascular Malformations
 - Hereditary Hemorrhagic Telangiectasia / HHT
- Oncology / Interventional Oncology
- Pediatric
- Women's Health
- Men's Health
- Infertility
- Our Experts
- Appointments & Locations
- Fellowship
- HHT Center
- About Interventional Radiology

FONT SIZE PRINT THIS PAGE

Treatment of Vascular Malformations

Vascular Malformation Treatment Seminar

Watch Sally Mitchell and Clifford Weiss discuss treatment of a Vascular Malformation at the Johns Hopkins Hospital.

What is a vascular malformation?

Vascular Malformation is a general term that includes congenital vascular anomalies of only veins, only lymph vessels, both veins and lymph vessels, or both Arteries and Veins:

- Only veins: Venous Malformations (VM)
- Only lymph vessels: Lymphatic Malformations (LM)
- Both veins and lymph vessels: Venolymphatic Malformations (VLM)
- Arteries connected directly to veins without any capillaries in between: Arteriovenous Malformations (AVM)

Why do these vascular malformations occur?

These are all present at birth, and become apparent at different ages. We are just beginning to understand how malformations occur. The pulmonary arteriovenous malformation, when associated with Hereditary Hemorrhagic Telangiectasia, is inherited genetically. There is currently much work being done on the possible genetics of other malformations. Most are only known as something that occurs during development of the arteries, veins, and/or lymph vessels, but without specific cause.

What are the symptoms of a vascular malformation?

These vascular malformations can cause a variety of symptoms, depending on the location in the body:

Venous malformations (VMs) may cause pain where ever they are located. Venous and lymphatic malformations may cause a lump under the skin. There may be an overlying birthmark on the skin. Bleeding or lymph fluid leaking may occur from skin lesions. Lymphatic malformations tend to become infected, requiring repeated antibiotic treatments. Venous and lymphatic malformations may be associated with a syndrome called Klippel-Trenaunay Syndrome.

Arteriovenous malformations (AVMs) may cause pain. They are also more stressful on the heart because of the rapid shunting of blood from arteries to veins. Depending on their location, they may also result in bleeding (for example from the bowels, from the uterus, from the bladder).

Figure 1. (continued). (c) A screen capture of the Johns Hopkins Hospital web page about VAs. Text not intended to be read.

These websites intend to reach the general public, which includes those with hearing, movement, and sight disability. The Internet removes barriers to communication and interaction that many people face in the physical world. However, when websites are poorly designed, they can create barriers that exclude people from using the Internet. The World Wide Web Consortium (W3C) develops Web standards that aim to make websites accessible to everyone. Their Web Content Accessibility Guidelines dictate that the visual presentation of text and images of text has a contrast ratio of at least 4.5:1 or in the case of large text, a ratio of at least 3:1. Several of the existing website resources for VAs do not follow these guidelines. Those with visual disabilities may not be able to properly navigate through these websites.

These websites represent the top results patients and families will see when using the Internet to search for information about vascular anomalies. However, vascular anomalies are primarily diagnosed because of their presentation on the skin surface, it is understandable that patients and families will be searching for images of this condition. The lack of imagery on these prominent websites may prompt patients and families to search Google images. The resulting images are almost entirely patient photographs (Fig. 2). There are two illustrations depicting vascular malformations; these are from the Johns Hopkins Hospital website.

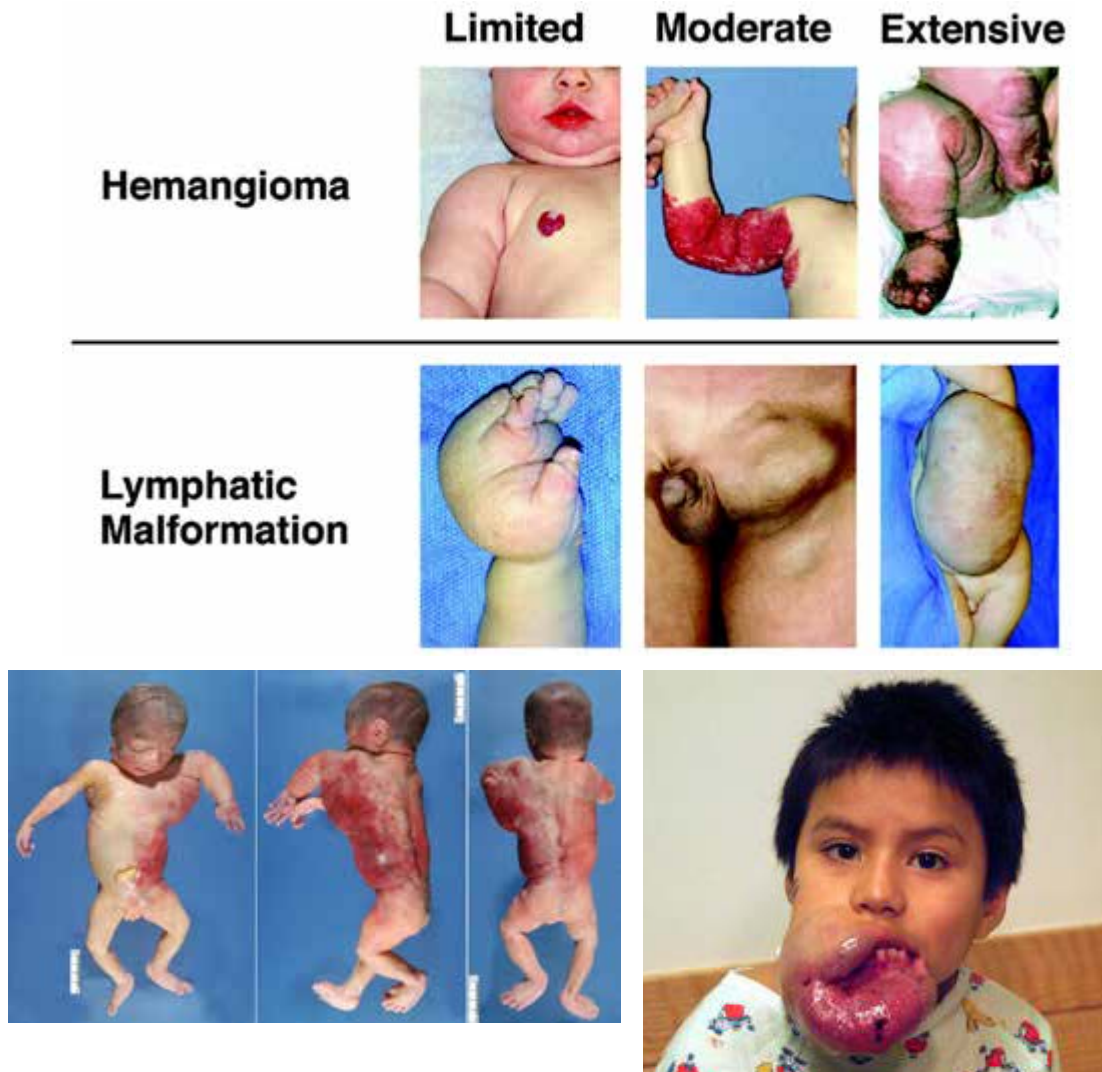


Figure 2. Patient images of VAs, taken from the top results of a Google image search of the term “Vascular Anomaly”

MATERIALS AND METHODS

Research and Planning

On December 3, 2016, a paper titled “What might parents read: Sorting webs of online information on vascular anomalies” (Davis et al., 2016) was published defining the problem this thesis intends to remedy. This paper was reviewed to establish a plan of action. Information about VAs would be gathered, translated into plain language using grade level and readability tests, and organized in a website utilizing web design principles to optimize usability. This website would be reviewed using DISCERN and populated with illustrations to increase accessibility and audience.

The table from ISSVA delineating correct classification of vascular anomalies (Table 2) was taken and adapted for use on the site. The site’s version was referred to as the Overview Map (Fig. 3).

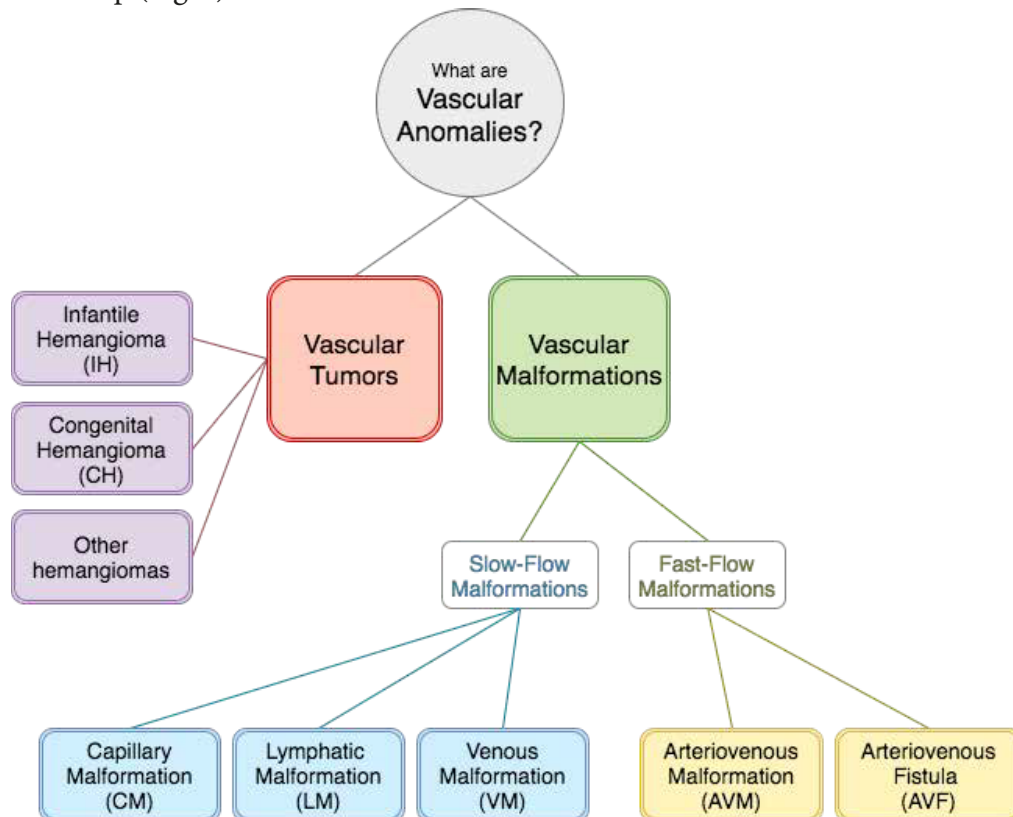


Figure 3. Overview Map. This map image is used as one form of navigation in the site.

From the Overview Map, a site map was created in which location of information on the web page would mimic the classification scheme (Fig. 4). A flowchart was created to illustrate users' navigation pathways through the site (Fig. 5). To optimize usability, two main pathways for accessing information were developed based on the users' level of knowledge upon initially accessing the resource. The user could proceed through an explanation of vascular anomalies, the differences between tumors and malformations, and then navigate to a specific VA. As an alternative, the user could use the Overview Map to navigate directly to a specific VA.

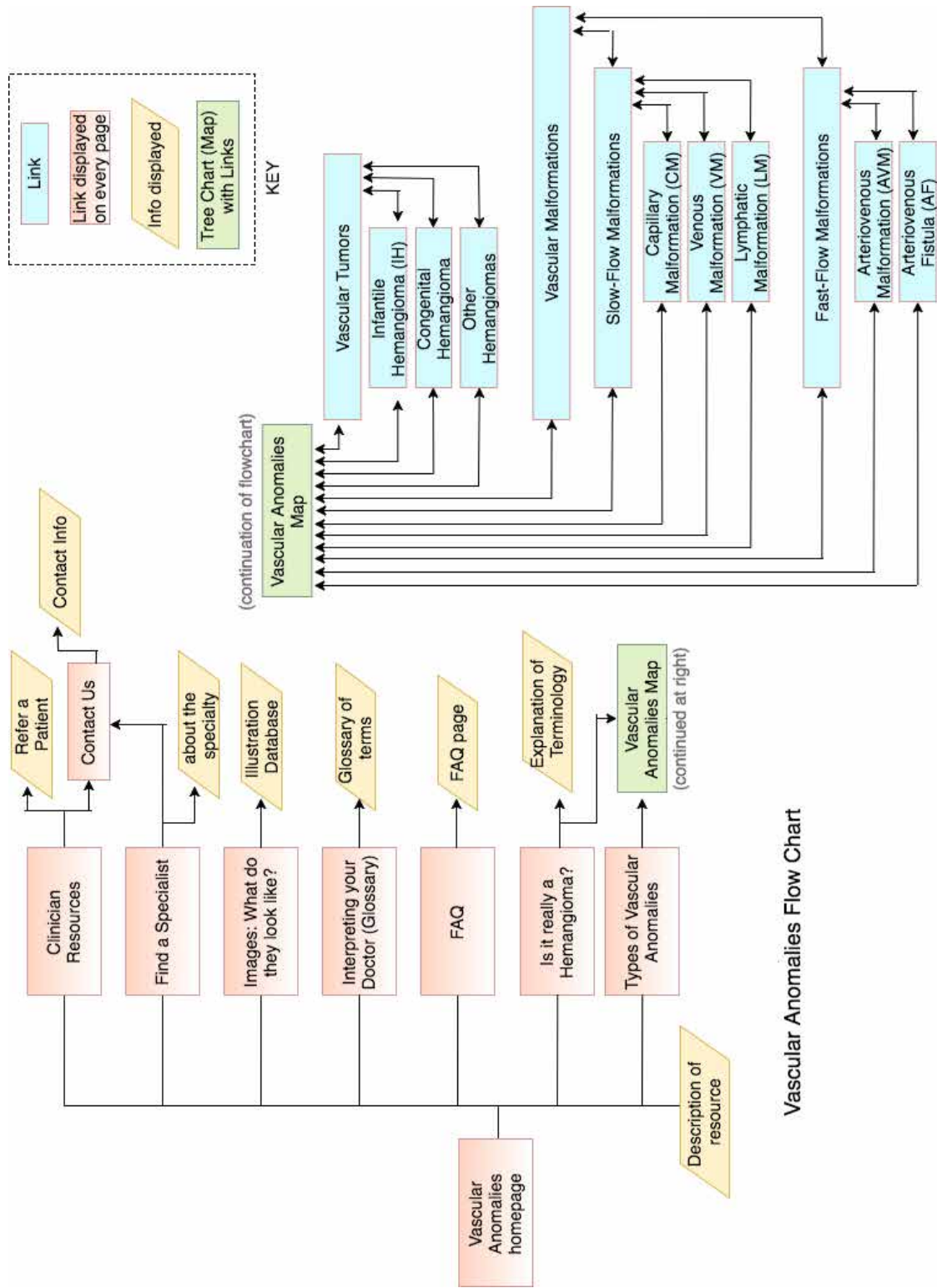


Figure 4. This chart describes how a user may click through the website.

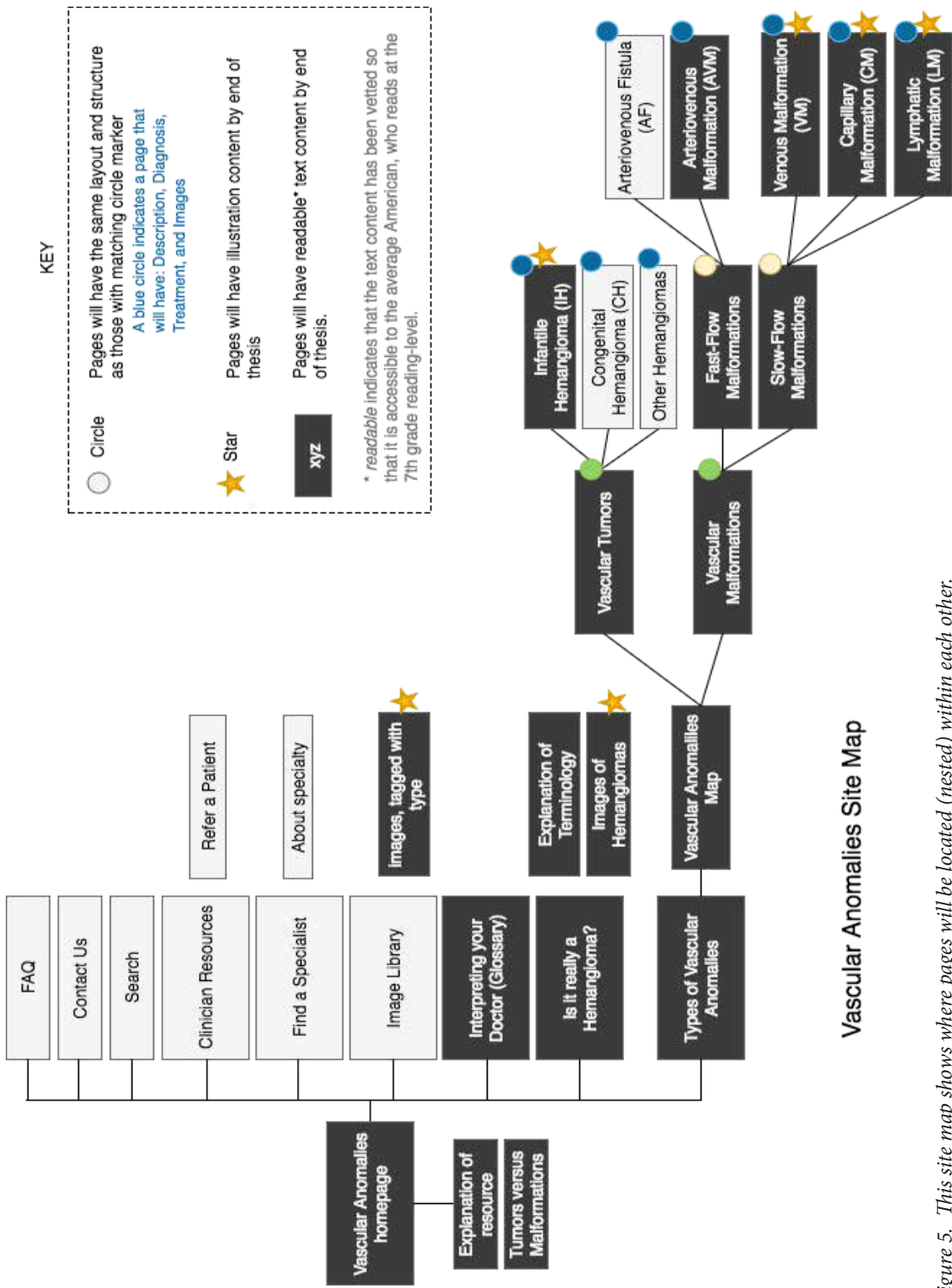


Figure 5. This site map shows where pages will be located (nested) within each other.

Due to the specificity of the information being conveyed, not all words could be shortened or changed to plain language. As a result, complex words were equipped with a tooltip. A tooltip is a message, in this case—a definition, that appears when a cursor is positioned over a word (Fig. 6).

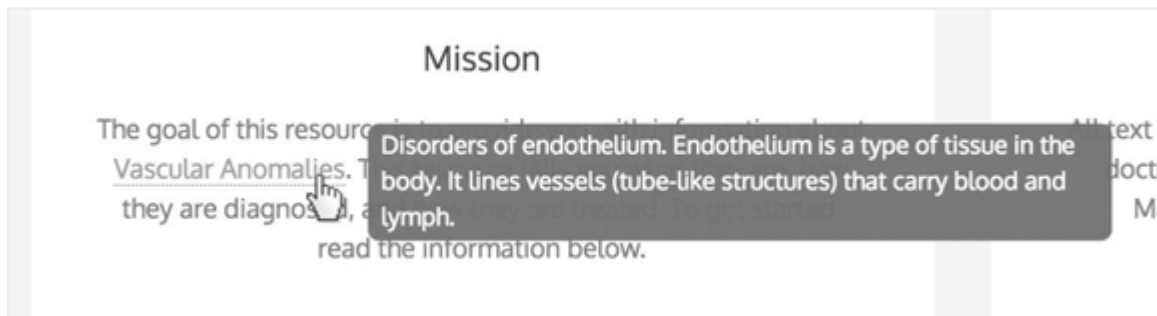


Figure 6. A screen capture of a tooltip that appears when a cursor hovers over the phrase “Vascular Anomalies.”

From the tooltip words, a glossary page was made. The list of words included can be viewed in Appendix C. A user would be able to access this page as a comprehensive searchable database of words relating to VAs. This glossary would be useful for a user who is trying to understand other information sources not presented in plain language, including the other 30 websites found via Google search, and resources gathered directly from clinicians and VA specialists.

Existing websites containing information about VAs were reviewed, including those from Boston Children’s Hospital Vascular Anomalies Center, Cincinnati Children’s Hospital Hemangioma and Vascular Malformation Center, Seattle Children’s Hospital Vascular Anomalies page, and Johns Hopkins Medicine Vascular and Interventional Radiology Treatment of Vascular Malformations. Screen captures of these pages can be referred to in Figure 1. The readability of these pages was assessed by Davis et al. Their usability and layout were compared qualitatively from a new user’s perspective.

Research papers were gathered from widespread authors in the field including Dr. Arin K. Greene of the Vascular Anomalies Center of Boston Children's Hospital, Drs. Sally Mitchell and Clifford Weiss of the Department of Interventional Radiology at Johns Hopkins Hospital, and Dr. Katherine Püttgen of the Department of Pediatric Dermatology at Johns Hopkins Hospital. Using these resources, a table was created with one column containing common questions and general information a patient or family member would require regarding a specific vascular anomaly. These questions were divided into three categories: general information, diagnosis, and treatment. In a second column, any information corresponding to these questions was gathered from research. A third column was created which contained the plain language translation of the research information. The plain language text was then sent to Dr. Clifford Weiss or Dr. Katherine Püttgen for review. They made any necessary changes and checked the accuracy of the information. Due to the time constraints of this thesis, the process described above was performed for only a portion of all VAs, including venous malformations, lymphatic malformations, capillary malformations, arteriovenous malformations, and infantile hemangiomas. The tables for each of these VAs are located in Appendix B, and an excerpt from the venous malformation table can be seen in Table 3.

Venous Malformation		
	Notes from Resources•	Plain Language
DESCRIPTION		
Physical Appearance	<ul style="list-style-type: none"> • Blue, soft, and compressible. Hard, palpable phleboliths may be palpable • Range from small, localized skin lesions to diffuse malformations involving multiple tissue planes. • Usually occur on the head or neck, but can occur anywhere on the body. • Usually greater than 5 cm and single occurrence. • Because they affect the skin and cause a deformity, the primary morbidity of a venous malformation is psychosocial. • Head or neck venous malformations can present with mucosal bleeding or progressive distortion, leading to airway or orbital compromise 	<ul style="list-style-type: none"> • A venous malformation (VM) can look like a bruise on the skin or a growth under the skin. For most people, a VM is bigger than 5 centimeters (the size of a plum). • You can press down on a VM and it will shrink, like a balloon losing air. Once you stop pressing down, it will fill back up, like a balloon filling with air. You might feel round, hard pieces when you press the VM. These are called Phleboliths (look like small pearls). • VMs can happen anywhere in the body, but they are commonly found on the head or neck. • A VM on an arm, hand, leg, or foot can cause pain, or make that body part difficult to use.

Table 3. Excerpt from the venous malformation plain language table. The full table can be found in Appendix B.

To achieve a seventh grade level of readability, research was done on tools that will measure the readability of content. For time-management, a tool which measured readability using several methods at once was necessary. Readable.io is a website that measures the readability of text, URL, or uploaded file. It scores the readability grade level using FKGL, Gunning-Fog score, Coleman-Liau index, SMOG index, Automated Readability Index, and also provides an average of all these scores. All text for this resource aimed to score at or below a sixth grade reading level according to FKGL, and at or below seventh grade overall. Additionally, this tool measures FRES, which needed to be at or above 65/100. Readable.io is a premium tool and, as a result, required a small fee of three dollars to access all features. A premium account provided unlimited number of text scores, 50 URL scores per day, ten file scores per day, and fifty alerts which could be synced to automatically monitor the readability, keyword density and even sentiment of selected web pages.

Although proper grammar rules of the English language denote there is no reason to capitalize many of the conditions described on this resource, a decision was made to utilize capitalization to improve readability. Capitalization was used for emphasis to draw the user's attention to the phrase and maintain its appearance regardless of location within a sentence. Additionally, repeated occurrences of treatment, procedure, or condition names were replaced with acronyms once they were defined in the text. To encourage acronym association, these acronyms were defined in each section (description, diagnosis, and treatment) in which they were used. Replacing some of these complex names with acronyms reduced the number of letters and syllables used. Sentences were shortened, making them more readable according to the tests performed. For example, utilizing acronyms in this sentence about venous malformations—"If a patient has a deep or large VM, a doctor will want to take an MRI to make sure"—reduces the syllable count from 34 to 25 and reduces the number of letters from 97 to 63. Both acronyms, VM and MRI, were defined previously in the text. To a reader, the resulting sentence is much more approachable.

Illustration Process

Several patients and families were consulted during the illustration process. The majority of these patients were adolescents and adults, all already receiving treatment at Johns Hopkins Hospital. The patients and families explained their timeline from discovery of the vascular anomaly to diagnosis and treatment.

One patient, in his forties, was accompanied by his wife. He explained that he had a vascular malformation in his knee that had become apparent when he was an adolescent. This patient lived with the vascular malformation for many years without a diagnosis. He led a life with some discomfort, but largely unaffected by the condition. As

it grew, the vascular malformation eventually hampered his ability to walk. At the time, he was told it was a hemangioma, a vascular tumor, and he had it surgically removed. However, because the condition was a malformation and not a tumor, it could not be completely excised and underwent subsequent regrowth. His resulting condition was worse than it had been before surgical intervention. Finally, this patient was referred to Johns Hopkins Hospital where his vascular malformation was correctly diagnosed, and sclerotherapy treatment was begun. Both he and his wife recognized the lack of resources about VAs. They reflected that a finding an online readable resource with illustrations would have caused them to seek a VA specialist and improved his chances of getting the correct diagnosis and treatment sooner.

An adolescent patient was attending a consultation appointment with her mother. This patient had a vascular malformation in her right arm. The malformation became irritated on occasion and hindered her ability to use her arm. Her vascular malformation was deep and did not leave any physical discoloration or mark on the skin surface. She said that because of this, her school teachers disregarded her disability and thought she was lying. None of her teachers or friends had heard of vascular anomalies, and her mother conveyed concern that this lack of support might be causing psychological distress to her daughter and harming her academic performance. They asserted that educating people about VAs ultimately would improve both the psychological and physical health of those affected.

Many patients and families expressed the frustration and discouragement they felt after suffering for years without a diagnosis due to a lack of education about the condition. Some patients underwent surgeries to remove a misdiagnosed VA because they relied on the knowledge level of one physician instead of seeking the services of a specialist for a second opinion. After explaining the goal of this thesis, both patients and families

supported the need for readable resources explaining the correct classification of VAs, the process of diagnosis, and the different options for treatment. This information would improve their knowledge and participation in shared decision-making with clinicians.

Following these conversations, each patient agreed to be photographed as a reference for the illustrations that would populate the website. The process of discussing their stories was an essential prelude to the photography session as it ensured that the patients were confident that their images would improve the education of others. They signed model release forms and were photographed, and the resulting reference photos were transferred to an iPad Pro where they would be used to create illustrations. All illustrations were digitally painted using the Procreate application. In some cases, illustrations were created from a combination of photo references. If a photograph was exceptional in showing the vascular anomaly and the individual patient was not recognizable, then a separate model photo was used.

Painting in the Procreate application was done in four or five main layers. First, a few colors were used to block in the model (Fig. 7). By filling in the figure, this layer's contents could be selected using a pixel selection tool, ensuring that subsequent layers would be painted within this space and thereby keeping the entire painting organized.



Figure 7. Blocking in the model for illustrations A (left) and B (right).

Second, a layer of lights and darks was added to establish form (Fig. 8).

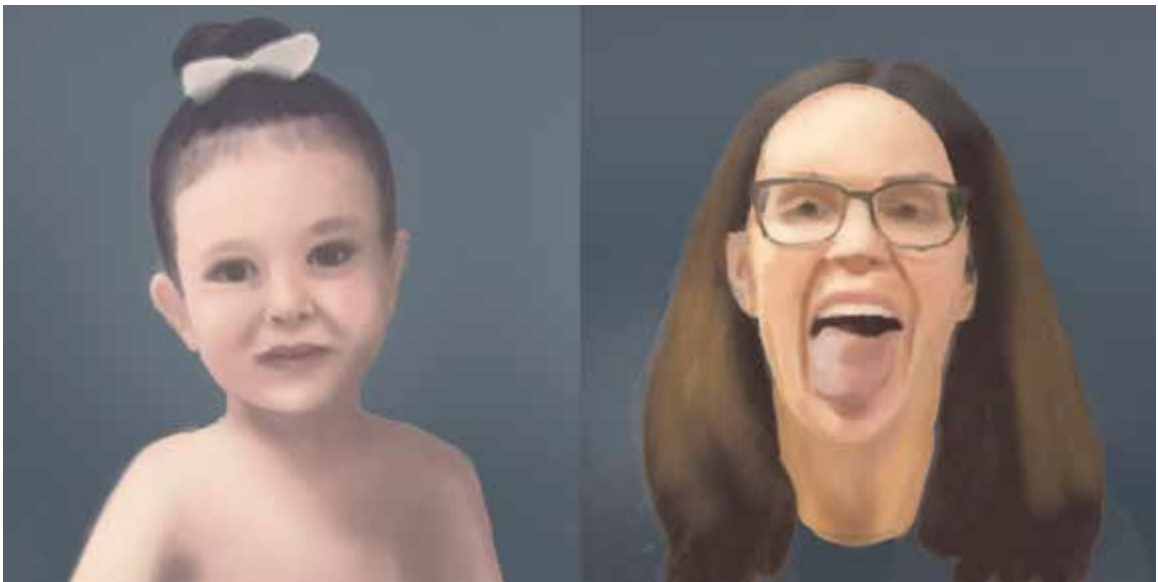

Figure 8. Lights and darks added to establish form for illustrations A (left) and B (right).

Third, a layer of details and subtle color shifts was painted until the figure was recognizable (Fig. 9).



Figure 9. Adding detail to illustrations A (left) and B (right).

Fourth, a layer of sketched outlines was placed on top to add a purely illustrative element, making the image and subject matter more approachable (Fig. 10).



Figure 10. Adding the original sketch of the model on top of the painted layers for illustrations A (left) and B (right).

If the illustration was being created from multiple references, a fifth layer containing just the vascular anomaly was painted and shaped until it merged appropriately with the model (Fig. 11).

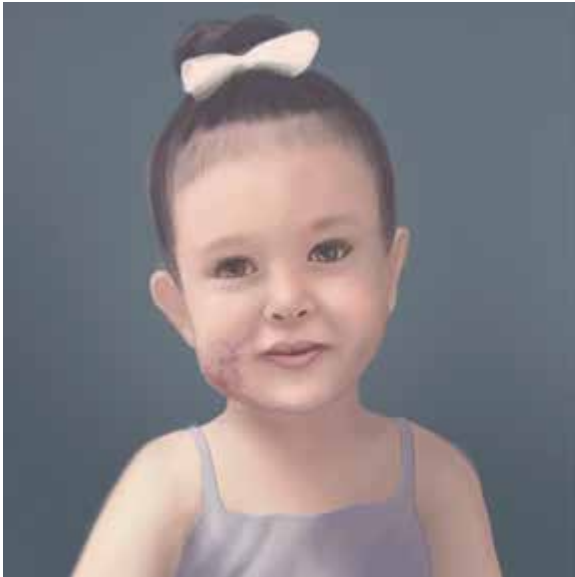

Figure 11. Adding a venous malformation to the girl's cheek in illustration A.

The final illustrations were prepared for presentation on the website. This involved changing the background to match the website's theme colors, and creating additional details of the vascular malformations themselves. Two final illustrations for the venous malformation page can be seen in Figure 12.

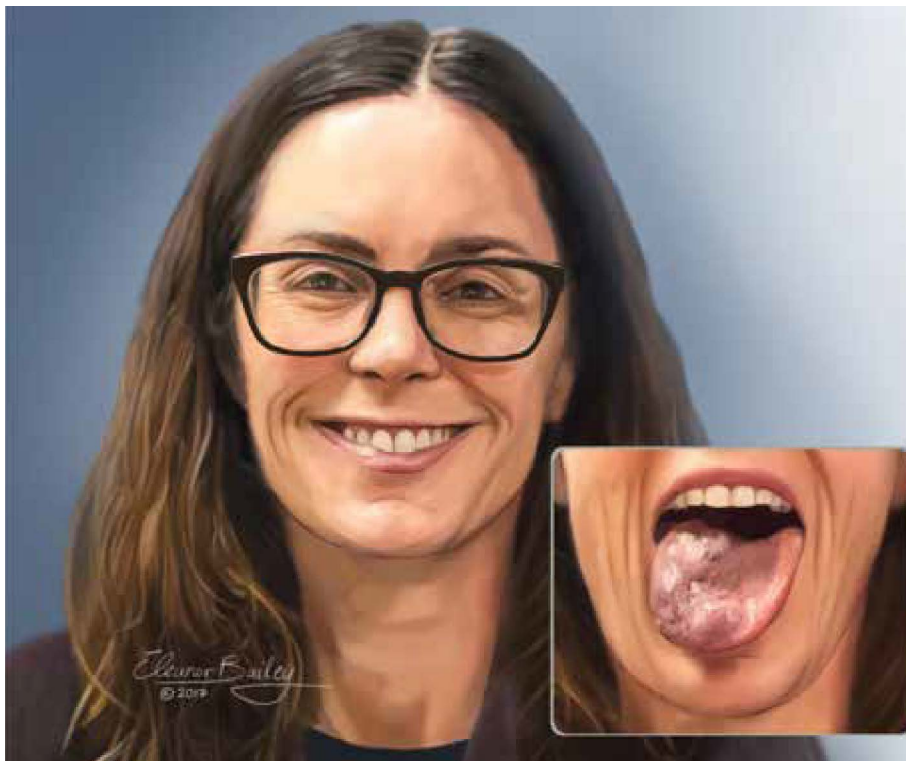
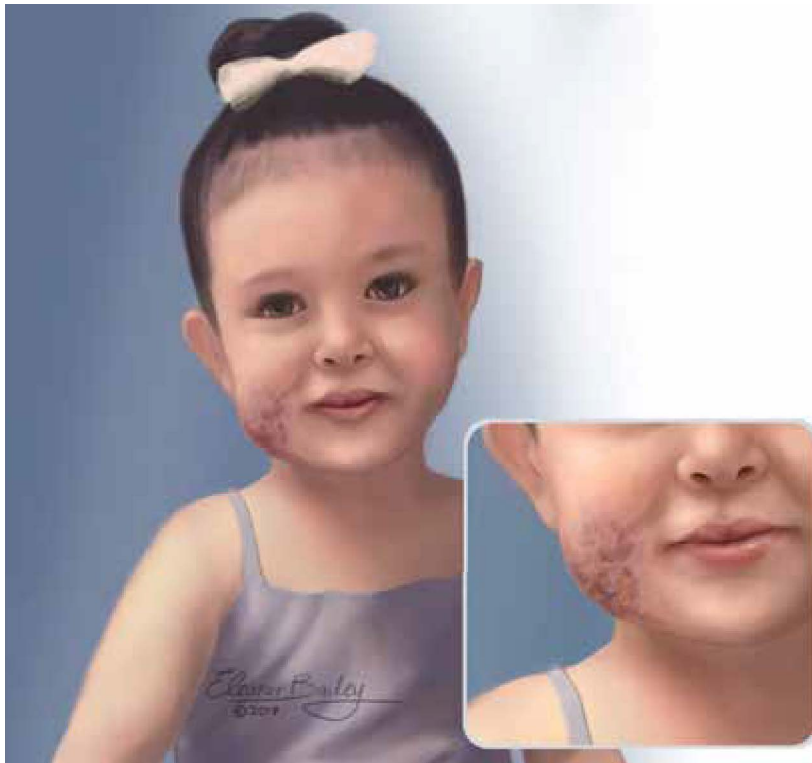

Figure 12. Final layout and details for illustrations A (top) and B (bottom).

Website Development

The vascular anomalies website was created on Wordpress as a subdomain of eleanorbaileyillustration.com. Wordpress, an open-source tool used for website creation and management, caters to beginner designers by offering themes. A theme is a collection of templates from which pages can be customized by changing the content and reorganizing elements. These templates have a predefined, often customizable, color scheme and font family. Together, these templates produce a unified graphical interface. Only responsive themes were considered during the creation of this resource in order to reach the largest possible audience. Responsive themes are those that adjust automatically to fit a device's screen size, such as a phone or tablet, as well as being usable on a desktop computer. The original theme for the VAs website was copied over from eleanorbaileyillustration.com to allow for initial exploration of site setup and navigation. This theme, called Salt, offered a modern layout with bold blocks of color (Fig. 13). However, due to issues with customizability, a new theme was selected. The new theme, called Enfold, received a customer rating of 4.85 average out of 5 based on 7864 ratings and featured more than 100 demo pages. It was equipped with filler content (pictures and text) illustrating the theme's adaptability to several fields, including a medical profession. This filler content was uploaded to preview the website's possible appearance (Fig. 14), and although it provided usability and layout options, customizability features were still lacking. Enfold used its own layout builder that prevented the theme user from altering the CSS files which produced the pages. Certain design elements could not be customized.

After consulting Mr. Michael Linkinhoker and Ms. Aline Lin of Link Studio, a visual communications company that specializes in both website design and medical illustration, a third theme was selected from their recommendation. This theme, called Avada (Fig. 15), was both customizable and allowed manipulation of its code. Content for

the venous malformation page was uploaded to test layout and usability.

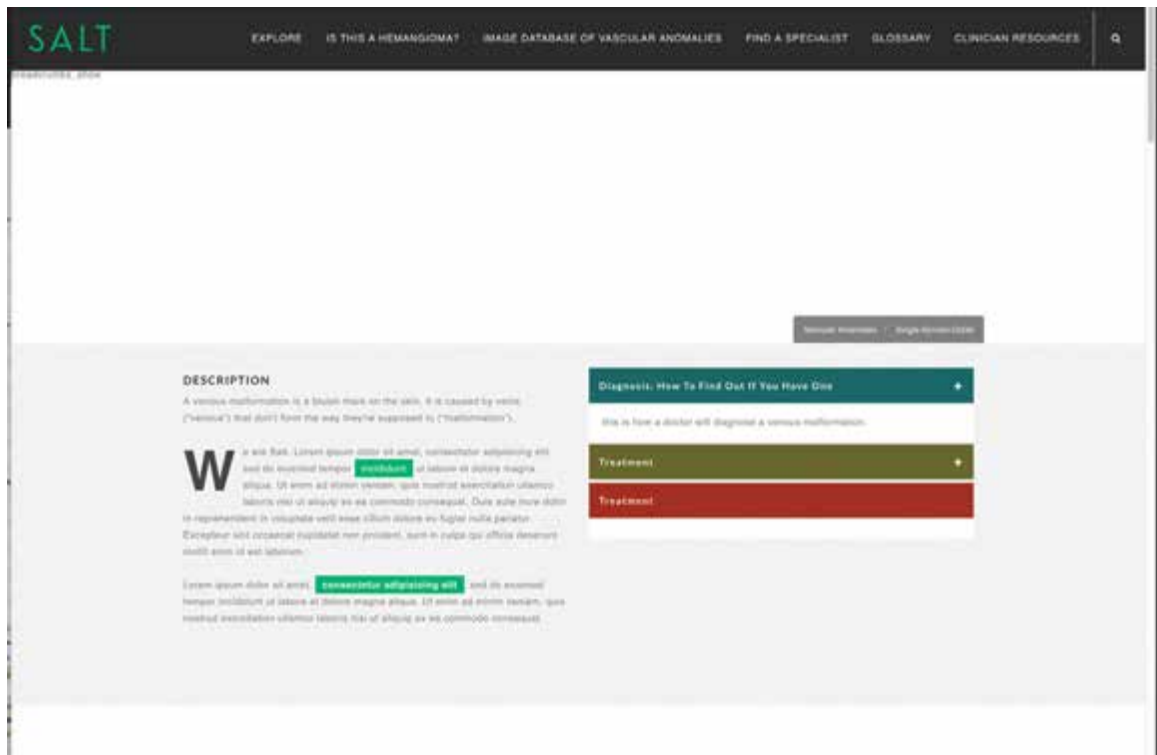


Figure 13. Initial look of website with Salt theme. Text not intended to be read.

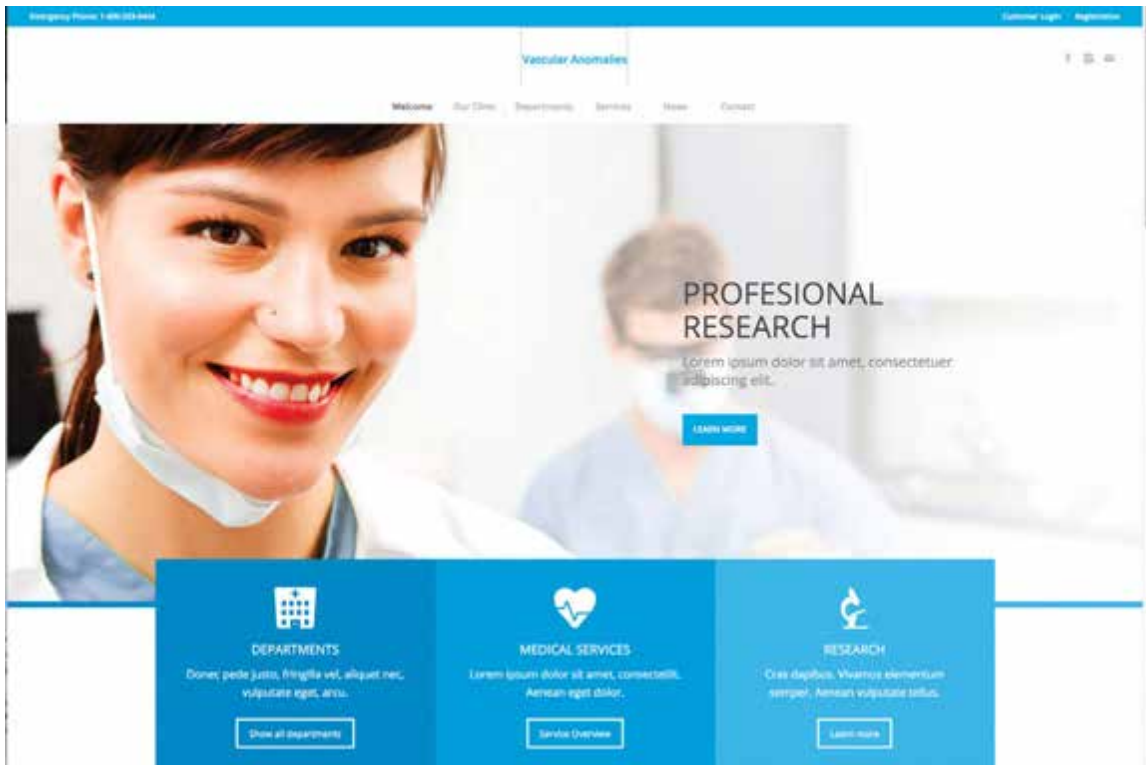


Figure 14. Enfold theme with demo medical content. Not all text is intended to be read.

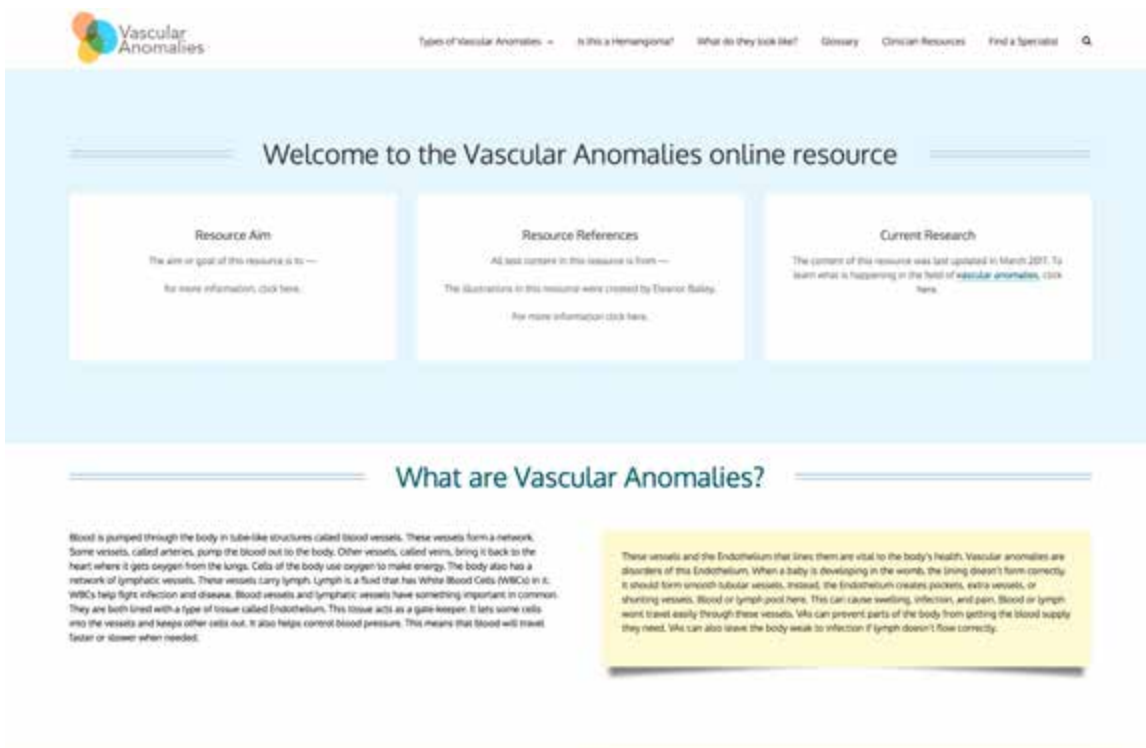


Figure 15. Avada theme with some VA content uploaded. Not all text is intended to be read.

Accessibility was the foremost concern in choosing a color scheme (Fig. 16). To ensure that all text content would be legible for those with sight disabilities, W3C’s Web Content Accessibility Guidelines 2.0 were considered when choosing background colors and foreground text colors. Color-value scales were made using a colorblind filter to ensure that text would be legible to colorblind users. Red-green schemes were avoided. The final logo and color scheme were tested in Adobe Photoshop’s Deuteranopia colorblind mode (Fig. 17).




Figure 16. Color scheme exploration. Not all text is intended to be read.

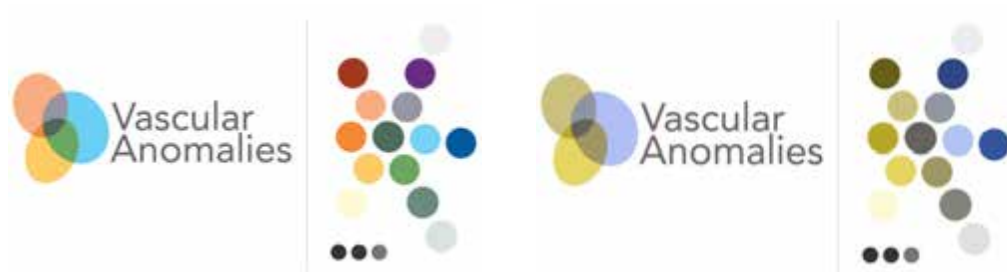

Figure 17. Logo and final color scheme with normal color vision (left) and with Deuteranopia color vision (right).

To improve usability of the website, consistency was prioritized. This was achieved by first developing the venous malformation page (Fig. 18) and then reproducing its layout for all other specific vascular anomaly pages. Additionally, language was kept consistent throughout the website. For example, on the Overview Map, the button that says “Venous Malformation (VM)” leads to the venous malformation page that is titled “Venous Malformation (VM)”.

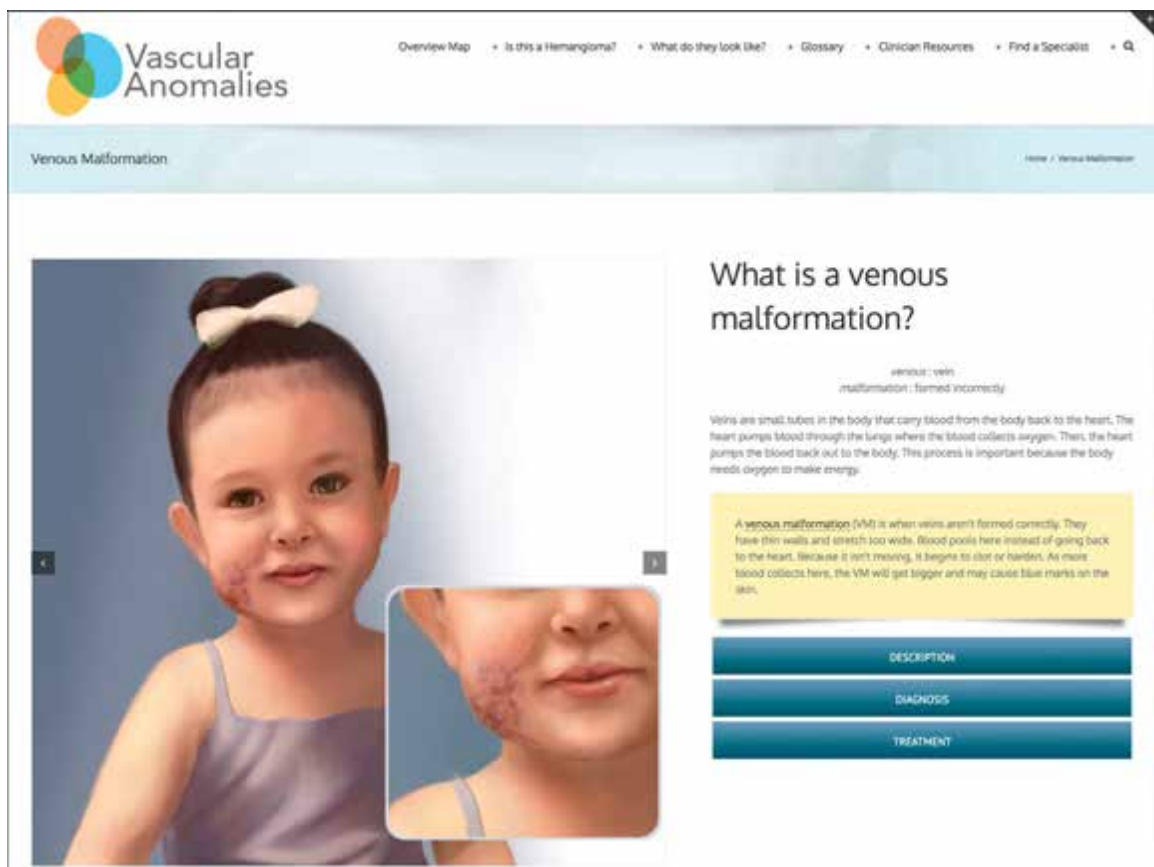


Figure 18. The initial design of the Venous Malformation page. Not all text is intended to be read.

After the illustrations and text were uploaded to the venous malformation page, the layout and usability were reviewed with Ms. Lin of Link Studio. She noted that improvements could be made to the use of space within a page. This is especially important in a responsive website because when a site is viewed on a mobile device

instead of a desktop computer, the screen size is more narrow. The page width is reduced, and a multi-column layout will shift to form a single column greatly increasing the length of a page. The designer must be aware of how much a user needs to scroll before reaching content. With this consideration, changes were implemented including reducing logo size by 30%, removing the redundant title bar, and reducing the size of buttons that link to areas further down the page (the “Description”, “Diagnosis”, and “Treatment” buttons) (Fig. 19).

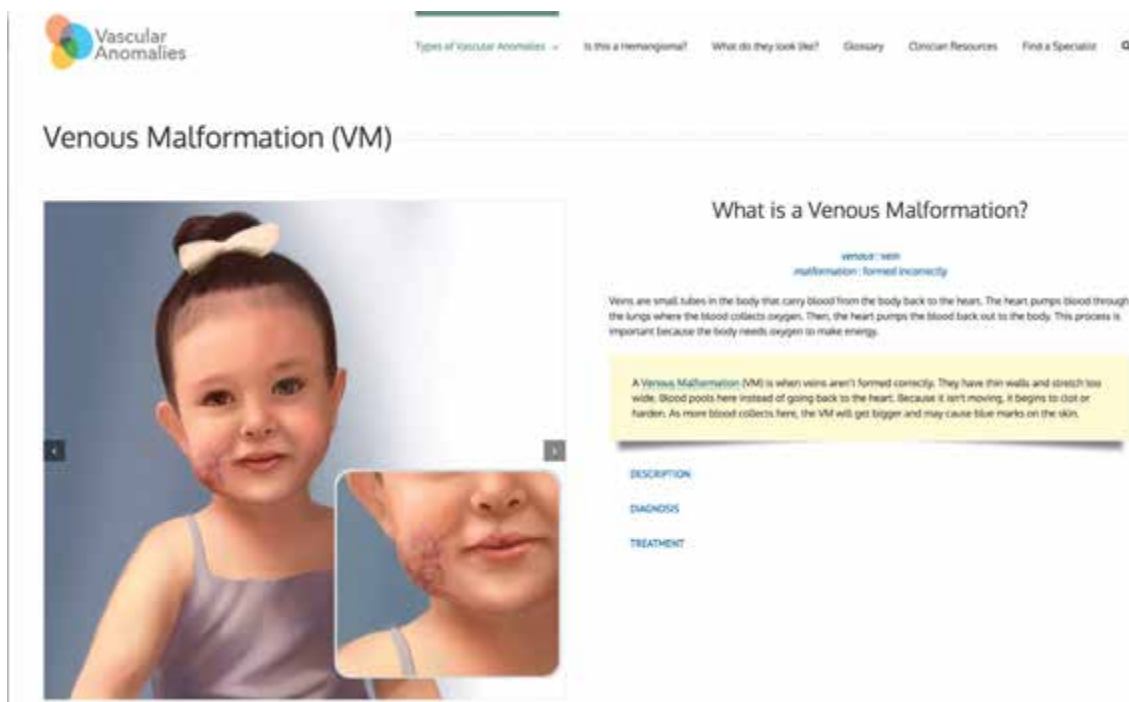


Figure 19. Adjustments to the Venous Malformation page were made to improve use of space and reduce page length. Not all text is intended to be read.

Review of Resource using DISCERN

Throughout the process of research and page population, DISCERN was utilized to ensure the quality of the resource. As a reminder, DISCERN is an instrument and handbook designed to help consumers judge the quality of health information. It was

accessed through the DISCERN on the Internet project which was funded by the National Health Service Executive Research and Development Programme. This fifteen-question evaluation form can be seen in Table 3. Upon completion of the site's layout, homepage, and population of several specific anomaly pages including lymphatic malformation, venous malformation, infantile hemangioma, and arteriovenous malformation, patient allies and members of the general public were consulted about how well the resource met the guidelines put forth by DISCERN. This is an ongoing process, and their feedback will continue to be implemented to improve the quality of resource.

Section 1. Is the publication reliable?					
	No		Partially		Yes
1. Are the aims clear?	1	2	3	4	5
2. Does it achieve its aims?	1	2	3	4	5
3. Is it relevant?	1	2	3	4	5
4. Is it clear what sources of information were used to compile the publication (other than the author or producer)?	1	2	3	4	5
5. Is it clear when the information used or reported in the publication was produced?	1	2	3	4	5
6. Is it balanced and unbiased?	1	2	3	4	5
7. Does it provide details of additional sources of support?	1	2	3	4	5
8. Does it refer to areas of uncertainty?	1	2	3	4	5
Section 2. How good is the quality of information on treatment choices?					
9. Does it describe how each treatment works?	1	2	3	4	5
10. Does it describe the benefits of treatment?	1	2	3	4	5
11. Does it describe the risks of treatment?	1	2	3	4	5
12. Does it describe what would happen if no treatment is used?	1	2	3	4	5
13. Does it describe how the treatment choices affect overall quality of life?	1	2	3	4	5
14. Is it clear that there may be more than one possible treatment choice?	1	2	3	4	5
15. Does it provide support for shared decision-making?	1	2	3	4	5

Table 4. DISCERN questions and rating scale.

Section 3. Overall Rating of the Publication					
	Low		Moderate		High
	Serious or extensive shortcomings		Potentially important but not serious shortcomings		Minimal shortcomings
16. Based on the answers to all of the above questions, rate the overall quality of the publication as a source of information about treatment choices.	1	2	3	4	5

Table 4. (continued) DISCERN questions and rating scale.

Transfer of Content to Hopkins Website

During the development of this website and content, it was decided that the content would be copied over to the existing departmental pages on the Johns Hopkins Hospital website (Fig. 20). Due to the high volume of traffic experienced by this site, the content created through this thesis would reach the largest possible audience. However, the original site was still maintained with all original content.

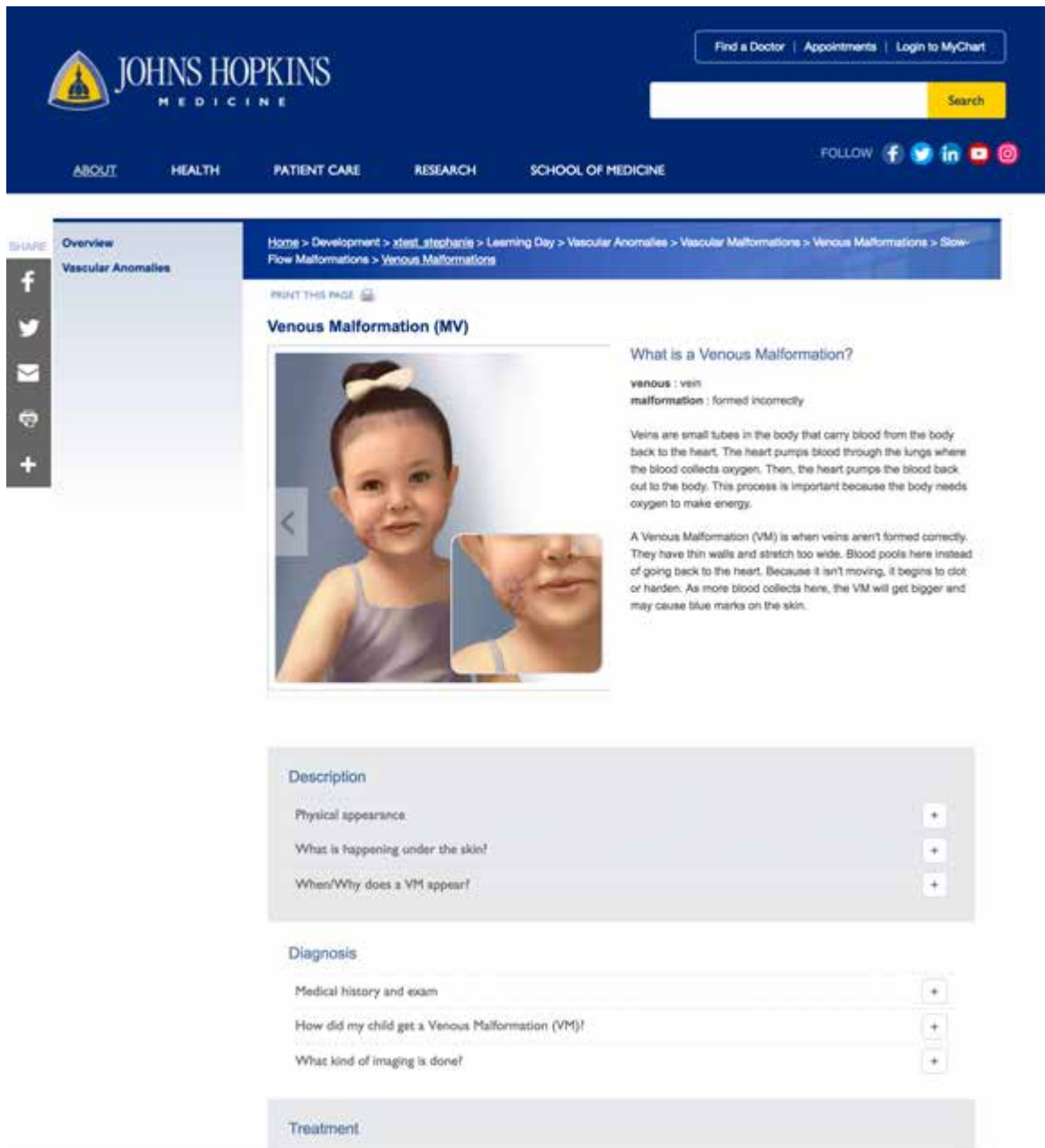


Figure 20. Screen capture of the Johns Hopkins Hospital website with new readable content and illustrations. Not all text is intended to be read.

RESULTS AND DISCUSSION

This thesis produced a website of information about vascular anomalies. The specific pages that have been populated with information during the course of this thesis are the Vascular Anomalies homepage, Overview of Vascular Anomalies, What do they look like?, Glossary, Vascular Malformations, Venous Malformation (VM), Lymphatic Malformation (LM), and Infantile Hemangioma (IH). Screen captures of these pages are located in Appendix A.

The readability of the information has been reviewed by FKGL, and by a combination of FKGL, Gunning-Fog score, Coleman-Liau index, SMOG index, and Automated Readability index (Table 5). Based on this assessment, this resource is readable to most Americans. By reviewing the DISCERN tool prior to and following resource creation, quality of the resource has been optimized. The information is organized with the patient in mind, utilizing layout and design elements to mimic the patient's approach to their condition by starting at the broadest category of information (vascular anomaly) and working toward the most specific condition. The information is accompanied by illustrations that differ vastly from the current visual resources, which consist of patient photos with censor bars over the subject's eyes, or pixelation blur over the subject's face. Patient photos are detached and jarring, while these illustrations show an aesthetically pleasing approach to this condition.

Page within Resource	Readability	
	FKGL	Combined
Vascular Anomalies homepage	6	8.2
Overview of Vascular Anomalies	6.9	9.2
Vascular Malformations	7.4	10
Venous Malformation (VM)	5.4	7.2
Lymphatic Malformation	6.1	7.8
Infantile Hemangioma	5.5	7.3

Table 5. Assessment of the readability of each page. The Glossary page and the "What do they look like?" page have been excluded because they do not contain sufficient text.

CONCLUSION

Impact of Organization

A medical professional primarily knows and communicates about the conditions he or she treats. This approach to health information often translates to the organization of health information in the virtual world. On a hospital's website, information about vascular malformations would be on the web page of an interventional radiologist, while information about vascular tumors would be on the web page of a pediatric dermatologist, and information about both may be on the web page of a plastic surgeon. This organization is centered on the provider. However, from a patient's perspective, the condition itself is paramount. A patient may seek the services of a pediatric dermatologist, an interventional radiologist, and a plastic surgeon throughout the process of diagnosis and treatment of their vascular anomaly. When health information is organized according to a clinician's perspective, a patient is forced to traverse the hospital's site, searching for and collecting fragments of information. If patient-centered care is the goal, then hospitals and medical professionals are failing with this approach.

Disease-Specific Centers: A Patient's Approach

Successful patient education considers how a patient will search for information about his or her condition. One solution that has been adopted by several successful hospitals is the creation of disease-specific centers. These centers employ the expertise of a variety of specialties with the unified intent to treat one overarching condition. This intent is reflected in their web-based patient education. The condition is the primary focus, while the specific providers are secondary. A health resource user starts with information about his or her condition and then is led to the services of different specialists. While the website created in this thesis utilizes this approach, the Johns Hopkins Hospital website and the pages onto which this health information was transferred could benefit from reorganization.

Establishing a Connection

A disparity exists between how patients and clinicians approach patient education. The majority of health resources are being produced at a level beyond what is understandable to the average American. These resources are produced by people in the health professions, jobs that require a college degree, often a master's or doctorate. Doctors have been immersed in academic language and specialty-specific terminology because this is the language they were taught and how they communicate with one another. Medical professionals create health resources with the intent to reach the general public. However, there is a discrepancy between the reading levels of those who hold the information, medical professionals, and those searching for information, the general public.

All patient education, whether web-based or printed, has the same goal: to provide patients with health information to improve health behaviors. Successful patient education communicates complex ideas through a variety of methods, reaching the audience through illustrations, animation, and text. The recent findings on the inadequacy of online health resources have provided an expansion to the field of medical illustration. To establish a connection between patients and clinicians through web-based patient education, the principles of design governing traditional visual communication must be applied in the virtual world and amended to include accessibility, readability, and organization in virtual space.

Asset Referral Information

The vascular anomalies web resource as well as all illustrations and text content created during this thesis can be viewed at:

www.vascularanomalies.eleanorbaileyillustration.com.

Some of the content has been adapted and can be viewed on the Johns Hopkins Medicine website. A copy of this thesis and all its assets is located in the Johns Hopkins University Department of Art as Applied to Medicine.

APPENDIX A

Vascular Anomalies

Types of Vascular Anomalies - Is this a Hemangioma? What do they look like? Glossary Clinician Resources Find a Specialist

Image Gallery >>>

Welcome to the Vascular Anomalies online resource

Mission
The goal of this resource is to provide you with information about **Vascular Anomalies**. This resource tells you what they are, how they are diagnosed, and how they are treated. To get started, read the information below.

Resources
All text content in this resource has been collected from current doctors in the field. This resource was created as part of a Master's thesis at Johns Hopkins University. For more information on specific sources, click here.

Current Research
The content of this resource was last updated in March 2017. For other current resources in the field of Vascular Anomalies, click here.

What are Vascular Anomalies?

Blood Vessels
Blood is pumped through the body in tube-like structures called blood vessels. These vessels form a network. Some vessels, called arteries, pump the blood out to the body. Other vessels, called veins, bring it back to the heart where it gets oxygen from the lungs. Cells of the body use oxygen to make energy.

Lymphatic Vessels
The body also has a network of lymphatic vessels. These vessels carry lymph. Lymph is a fluid that has White Blood Cells (WBCs) in it. WBCs help fight infection and disease.

Endothelium
Blood vessels and lymphatic vessels have something important in common. They are both lined with a type of tissue called Endothelium. This tissue acts as a gate-keeper. It lets some cells into the vessels and keeps other cells out. It also helps control blood pressure. This means that blood will travel faster or slower when needed.

These vessels and the Endothelium that lines them are vital to the body's health. Vascular Anomalies (VAs) are disorders of this Endothelium.

When a baby is developing in the womb, the lining doesn't form correctly. It should form smooth tubular vessels. Instead, the Endothelium creates pockets, extra vessels, or shunting vessels. Blood or lymph pool here. This can cause swelling, infection, and pain. Blood or lymph won't travel easily through these vessels. VAs can prevent parts of the body from getting the blood supply they need. VAs can also leave the body weak to infection if lymph doesn't flow correctly.


To learn more about the organization of Vascular Anomalies, click the image below:

SEARCH THIS RESOURCE:

PRODUCED BY:
Eleanor Bailey
Department of An Applied to Medicine,
The School of Medicine, University of Alberta

© 2017 Eleanor Bailey. All content, text, and illustrations on this site are copyright (c) 2017 Eleanor Bailey and cannot be copied, reproduced, altered, or used in any way without written permission by Eleanor Bailey. Please visit www.vascularanomalies.com for more information about the author.

Figure 21. Screen capture of the Vascular Anomalies homepage. Not all text is intended to be read.

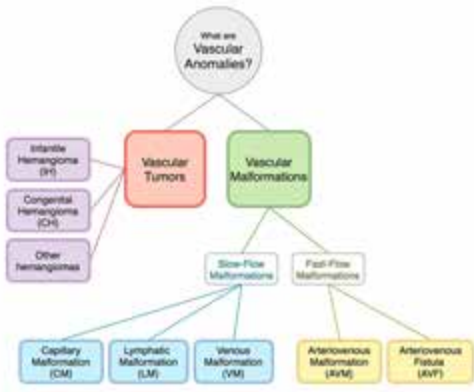


[Types of Vascular Anomalies](#) |
 [Is this a Hemangioma?](#) |
 [What do they look like?](#) |
 [Glossary](#) |
 [Clinical Resources](#) |
 [Find a Specialist](#)

Overview of Vascular Anomalies

Know what you're here for?

This map shows how Vascular Anomalies (VA) are organized. If you know which VA you're looking for, click it on the map to go to that page.



Vascular Tumors and Vascular Malformations: What's the difference?

Vascular Tumors

While a baby is developing in the womb, the cells that line blood vessels multiply more than is normal. After birth, the cells keep increasing. These extra cells form a complex mass. As the heart pumps blood out to the body, the spaces within the mass fill with blood.

Vascular Tumors have a growth cycle. They get bigger until they reach maximum size. Then, they slowly shrink. Often, they resolve on their own.

Some Vascular Tumors don't need treatment. They are managed until they heal. Some are treated with oral medication or eye drops. After the tumor shrinks, surgery can be done to remove any remaining mark.

[LEARN MORE](#)

Vascular Malformations

While a baby is in the womb, abnormal clusters of blood or lymphatic vessels form. These abnormal vessels can cause fluid to pool. Sometimes, they are painful and can affect nearby structures.

As the baby grows up, the Vascular Malformation will grow too, and might become problematic. Unlike Vascular Tumors, Vascular Malformations don't have a growth cycle. They won't resolve on their own.

Vascular Malformations can be managed with some medications, and new drugs are being developed. Sclerotherapy is an effective treatment for Vascular Malformations. Surgery can be done to get rid of any mark or growth left on the skin after Sclerotherapy treatment.

[LEARN MORE](#)

Vascular Malformations and Vascular Tumors are both benign. This means that neither condition is cancer. They are present at birth. However, you might not see a Tumor or Malformation right away. These two types of VA can look similar, but they have different causes and, therefore, different treatments.

Vascular Tumors and Vascular Malformations are both manageable conditions. New treatments are constantly being developed by clinics around the world.

SEARCH THIS RESOURCE:

PRODUCED BY:

Elisavet Bailey
Department of Art as Applied to Medicine
The Johns Hopkins University School of Medicine

© 2017 Elisavet Bailey. All content, text, and illustrations on this site are copyright (C) 2017 Elisavet Bailey and cannot be copied, reproduced, altered, or used in any way without written permission by Elisavet Bailey. Please visit elisavetbaileyillustration.com for more information about the author.

Figure 22. Screen capture of the Overview page. Not all text is intended to be read.

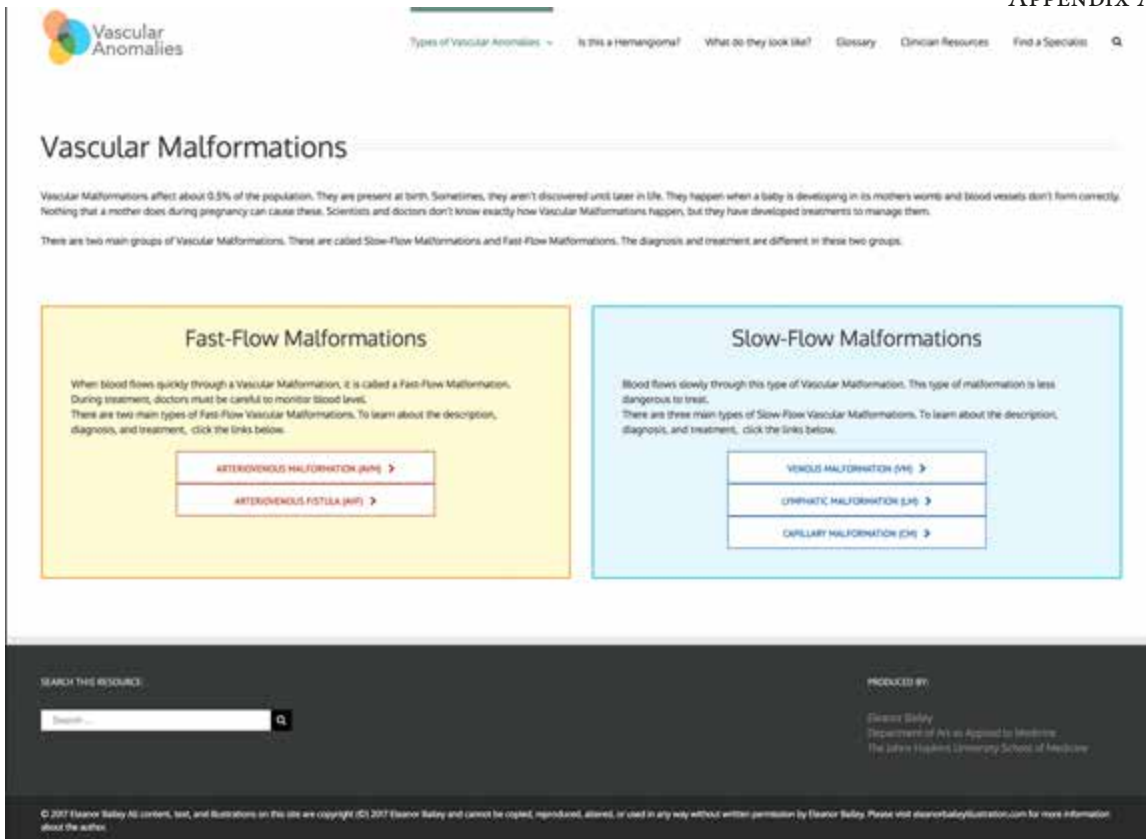
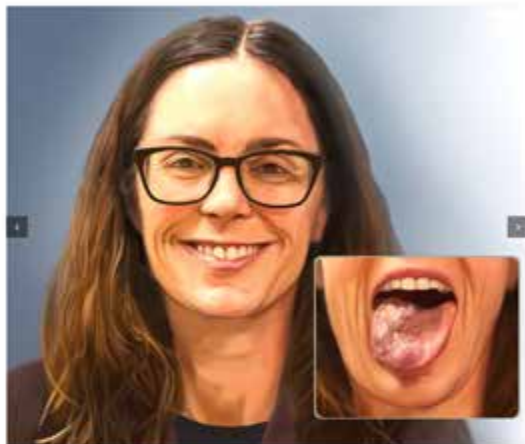

Figure 23. Screen capture of the Vascular Malformations page. Not all text is intended to be read.

Venous Malformation (VM)



VENOSA: VMP
malformation: formed incorrectly

Veins are small tubes in the body that carry blood from the body back to the heart. The heart pumps blood through the lungs where the blood collects oxygen. Then, the heart pumps the blood back out to the body. This process is important because the body needs oxygen to make energy.

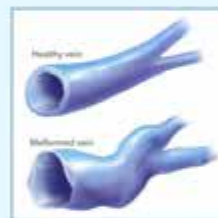What is a Venous Malformation?

A Venous Malformation (VM) is when veins aren't formed correctly. They have thin walls and stretch too wide. Blood pools here instead of going back to the heart. Because it isn't moving, it begins to clot or harden. As more blood collects here, the VM will get bigger and may cause blue marks on the skin.

- DESCRIPTION
- DIAGNOSIS
- TREATMENT

Description

- Physical Appearance
- What is happening under the skin?
- When/Why does a VM appear?



Diagnosis

- Medical History and Exam
- How did my child get a Venous Malformation (VM)?
- What kind of imaging is done?



Treatment

- What kind of doctors are involved?
- When should you get treatment?
- Sclerotherapy
- Surgery

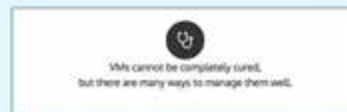

Figure 24. Screen capture of the Venous Malformation page (footer cropped). Not all text is intended to be read.

APPENDIX B

Lymphatic Malformation (LM)	
DESCRIPTION	Plain Language
<p>Other names</p> <p>Physical Appearance</p> <p>What is happening under the skin?</p>	<p>Notes from Resources•</p> <p>Cystic hygroma, lymphangioma, cavernous lymphangioma, cystic lymphangioma, and lymphangioma circumscriptum.</p> <ul style="list-style-type: none"> • LMs are soft and compressible. The overlying skin may be normal, have a bluish hue, or contain pink vesicles that can appear similar to a capillary malformation. • LMs are present at birth, but may not become apparent until childhood or adolescence. • The most commonly affected sites are the head, neck, and axilla. • Because the lymphatic and venous systems share a common embryonic origin, lymphatic malformations may be associated with venous phlebectasia (veins becoming varicose, which means they're tortuous and dilated) <p>• LM causes three primary problems: 1) psychosocial morbidity, because lesions typically involve the integument and cause a deformity, 2) infection, and 3) bleeding. Swelling from bleeding, infection, or viral illness may obstruct vital structures. Infection occurs because malformed lymphatic are unable to normally clear foreign material and contribute to antibody production, and protein across fluids and blood in the cysts favor bacterial growth.</p> <ul style="list-style-type: none"> • The body's immune system protects it from infection. When you get sick, your immune system fights the sickness in your body to make you healthy again. The Lymphatic System is part of the immune system. Lymph is a fluid that contains White Blood Cells. These cells fight infection and disease. Lymph vessels are tubes in the body that carry lymph from the parts of the body to the blood stream. Lymph nodes are small bean-shaped glands in the body. They help to filter lymph to remove viruses and bacteria. • A Lymphatic Malformation (LM) is when lymph vessels didn't form the way they should.

<p>What is happening under the skin? (continued)</p>	<ul style="list-style-type: none"> • 71% of lesions become infected, and sepsis can occur rapidly. Poor dental hygiene predisposes cervicofacial malformations to infection, and buttock or pelvic lesions may become infected by gut flora. • Intralesional bleeding affects approximately one third of lymphatic malformations and causes bluish discoloration, pain, and/or swelling. Bleeding results from abnormal venous channels in the malformation or from small arteries in the septations. • Lymphatic malformations can cause site-specific morbidity depending on the extent and location of the lesion. (Wherever its located, that limb might be hard to use, blood and lymphatic aren't working in that area) 	<ul style="list-style-type: none"> • 71% of LMs become infected. Bleeding affects one third of LMs. Both of these can cause swelling. If the LM is on an arm or leg, this swelling could make that limb hard to use.
<p>Why/When do they appear?</p>		<ul style="list-style-type: none"> • Because an LM develops when a baby is in the womb, it is something the baby is born with. Yet, a patient or parent might not see it at first. LMs can appear after an accident or as a child grows into an adult (during puberty).
<p>DIAGNOSING</p>		
<p>History and physical exam</p>	<ul style="list-style-type: none"> • 90% of lymphatic malformations are diagnosed by history and physical examination • patients and/or family members are queried about a family history of similar lesions. • The primary differential diagnosis is venous malformation 	<ul style="list-style-type: none"> • When a baby is in the womb, its blood and lymph vessels develop from the same tissue. This means that an if you have an LM, the doctor may want to check your blood vessels too. • Doctors can discover 90% of LMs by looking at the affected area and going over the patient's history. • In general LMs are not passed on from parent to child. Nothing that a mother does during pregnancy can cause these.
<p>What kind of imaging is done?</p>	<ul style="list-style-type: none"> • large or deep lymphatic malformations are evaluated by MRI to confirm the diagnosis, define the extent of the malformation, and plan treatment. 	<ul style="list-style-type: none"> • If a patient has a deep or large LM, a doctor will want to take an MRI. MRI stands for Magnetic Resonance Imaging. An MRI is a scan or picture of the inside of a patient's body. The MRI will help the doctor see the size and location of the LM. Also, MRI will help doctors to see what other important things are near the LM, that may be affected by treatment.

<p>What kind of imaging is done? (continued)</p>	<ul style="list-style-type: none"> • Ultrasonography is not as informative as MRI, but sedation in children is not required for ultrasound. • CT scans are occasionally indicated to delineate osseous involvement 	<ul style="list-style-type: none"> • The doctor could do an Ultrasound to see the LM. This is a good method for young children because it doesn't require a child to lie very still. However, Ultrasound is not as detailed as MRI. • Occasionally a doctor may do a CT scan to see if the LM is affecting a bone. CT stands for Computed Tomography. A CT is like an MRI, except it uses x-rays instead of magnets.
TREATING		
<p>General</p>	<ul style="list-style-type: none"> • Patients with more than three infections in a year are given daily prophylactic antibiotic therapy. 	<ul style="list-style-type: none"> • The Lymphatic System keeps the body healthy by fighting infection and disease. An LM might cause problems with this, so some patients need to take antibiotics to help fight infections. • An LM grows as the patient grows. It can also grow after trauma or puberty. A patient will likely need to keep getting treated throughout his/her life. Treatment is focused on managing the LM.
<p>Doctors Involved</p>	<p>Interventional Radiologist</p>	<ul style="list-style-type: none"> • A team of doctors will work together to treat an LM. An Interventional Radiologist is a doctor that can read pictures and scans of the body and use these images to treat the LM. This doctor will play a role in both diagnosing and treating your LM.
<p>When should you get treatment?</p>	<ul style="list-style-type: none"> • Intervention for lymphatic malformation is reserved for symptomatic lesions. • Occasionally, a lymphatic malformation involving an anatomically sensitive area or causing a significant deformity necessitates management as early as infancy. If possible, intervention should be postponed until after 12 months of age, when the risks associated with anesthesia are lower. • Therapy for lesions causing a visible deformity should be considered before 4 years of age to limit psychological morbidity. At this time long-term memory and self-esteem begin to form. 	<ul style="list-style-type: none"> • Lymphatic Malformation (LM) is benign, which means it's not cancer. If an LM isn't causing problems (pain or loss of function) for the patient, then doctor will just check on it every year. However, LMs can slowly expand over time. Once an LM starts causing problems, doctors will start treatment. • If an LM is in a sensitive or dangerous area, or if it becomes infected often, doctors may want to treat it right away. • Even if you aren't ready for treatment, the patient should see a specialist doctor before age 4. This is when long-term memory and self-esteem begin to form. Deformity can lead to psychological problems. Doctors will make sure patients feel good about the treatment timeline.

<p>Pharmacotherapy?</p>	<p>Sirolimus</p>	<p>Many doctors are working on new treatments for LMs. A new drug called Sirolimus has worked for some patients. For most vascular anomalies, a combination of treatment methods is best. Your doctor will help you decide where to start.</p>
<p>Sclerotherapy?</p>	<p>Sclerotherapy is the first-line mode of treatment for a large or problematic lymphatic malformation.</p> <ul style="list-style-type: none"> • Sclerotherapy involves aspiration of the cysts, followed by the injection of a sclerosant into the lymphatic malformation, which causes scarring of the cyst walls. • Generally is safer and more effective than resection. • A variety of fluids could be used for Sclerotherapy. The fluid that is injected is called a Sclerosant. The possible Sclerosants are Doxycycline, Ethanol, Bleomycin, and OD-432 • Dr. Arin Greene of Boston Children's Hospital uses Doxycycline. • Sclerotherapy provides good to excellent results in 75% to 90% of patients, reducing the size of the malformation and/or alleviating symptoms. • often multiple treatments are required, spaced 6 weeks apart. • The most common complication is ulceration (in less than 5% of cases). Ulcerations are managed with local wound care and are allowed to heal secondarily. Extravasation of the sclerosant outside the lesion can cause injury to adjacent structures. 	<p>Sclerotherapy is a great treatment for Lymphatic Malformations (LMs). Sclerotherapy means injecting the LM with special fluid. This fluid destroys the lymph vessels and causes scars to form inside. Less lymph will flow through the area. An LM is like a balloon filling up with liquid. Sclerotherapy blocks the opening of the balloon so it doesn't fill. This will cause the LM to shrink.</p> <ul style="list-style-type: none"> • Sclerotherapy is done a little bit at a time with treatments at least 6 weeks apart. Each vessel that is part of the LM is filled. • During sclerotherapy the LM is drained, and partially refilled with the Sclerosant. • What Sclerosants may be used should be discussed with the LM specialist. Your doctor will advise you about which Sclerosant is best for your LM. He/She will prepare you for what happens normally after the procedure and for potential problems. • For comfort, most patients are put to sleep during Sclerotherapy. The doctors who do this are called Anesthesiologists. Some patients get to go home the day of the procedure and some stay overnight in the hospital to recover. • Right after treatment, there could be swelling, irritation on the skin, and bruising at the site of the LM. • The most common complication of Sclerotherapy is ulceration. This means that a sore or wound develops on the skin over the LM. The sore is called an Ulcer. Ulceration happens in less than 5% of cases. Your doctor will help you manage an ulcer until it heals. • Sclerotherapy makes the LM get smaller, but LMs can re-expand over time. LMs are not curable, instead they are managed throughout life. Many patients get multiple rounds of treatment throughout their lifetime. The goal is to make symptoms go away as much as possible.

<p>Radiofrequency Ablation (RFA)</p>	<ul style="list-style-type: none"> • Radiofrequency ablation (RFA) is a treatment for LMs inside the mouth. It destroys the LM without damaging nearby structures. RFA doesn't cause much swelling, which means it's less likely to block the patient's airway. 	<ul style="list-style-type: none"> • Radiofrequency ablation (RFA) is a treatment for LMs inside the mouth. It destroys the LM without damaging nearby structures. RFA doesn't cause much swelling, which means it's less likely to block the patient's airway.
<p>Surgery?</p>	<ul style="list-style-type: none"> • Resection is less favorable than sclerotherapy because the entire lesion can rarely be removed. Excision may cause a worse deformity than the malformation. Recurrence is likely, since abnormal channels adjacent to the lesion are not treated. The risk of blood loss and iatrogenic injury is high. 	<ul style="list-style-type: none"> • Sclerotherapy can reduce the size of an LM and make symptoms go away. Yet, it can't make the LM go away completely. Patients sometimes may get surgery after Sclerotherapy. This could remove a mass, extra skin, or visible mark left by the LM. However, the LM will often return after surgery. • Surgery to remove an LM can result in blood loss. It can also cause a worse deformity than the LM. It is nearly impossible to surgically remove an entire LM.

Venous Malformation (VM)		
	Notes from Resources•	Plain Language
DESCRIPTION		
Other names		
Physical Appearance	<ul style="list-style-type: none"> • Blue, soft, and compressible. Hard, palpable phleboliths may be palpable • Range from small, localized skin lesions to diffuse malformations involving multiple tissue planes. • Usually occur on the head or neck, but can occur anywhere on the body. • Usually greater than 5 cm and single occurrence. • Because they affect the skin and cause a deformity, the primary morbidity of a venous malformation is psychosocial. • Head or neck venous malformations can present with mucosal bleeding or progressive distortion, leading to airway or orbital compromise • Extremity venous malformations can cause a leg-length discrepancy, hypoplasia as a result of disuse atrophy, pathologic fracture, hemarthrosis, and degenerative arthritis. • Venous malformations involving muscle may result in fibrosis, pain, and disability.) 	<ul style="list-style-type: none"> • A venous malformation (VM) can look like a bruise on the skin or a growth under the skin. For most people, a VM is bigger than 5 centimeters (the size of a plum). • You can press down on a VM and it will shrink, like a balloon losing air. Once you stop pressing down, it will fill back up, like a balloon filling with air. You might feel round, hard pieces when you press the VM. These are called Phleboliths (look like small pearls). • VMs can happen anywhere in the body, but they are commonly found on the head or neck. • A VM on an arm, hand, leg, or foot can cause pain, or make that body part difficult to use. • A VM near a joint, like an elbow or knee, can cause that joint to function badly. • A side effect of VM is that a person who has a VM on their skin might be embarrassed or self-conscious. This is bad for children who may be teased by classmates.
What is happening under the skin?	<ul style="list-style-type: none"> • Venous malformations result from an error in vascular morphogenesis. Veins have decreased smooth muscle cells that are arranged in clumps rather than concentrically. • Possible causes for enlargement of a venous malformation over time include dilation of veins, angiogenesis, or vasculogenesis 	<ul style="list-style-type: none"> • Veins carry blood from the body back to the heart. The heart pumps the blood through the lungs so that it can pick up oxygen. The body uses oxygen to make energy. When a baby develops in the womb, a vein can form wrong. This is a Venous Malformation (VM).

<p>Why/When do they appear?</p>	<ul style="list-style-type: none"> • A VM is present at birth, but sometimes doesn't become apparent until prompted (hormonal changes, adolescence, trauma). • Most VMs, even if asymptomatic, will ultimately will require intervention. • Because lesions have a higher risk of progression during puberty, adolescent hormones might stimulate venous malformations. 	<ul style="list-style-type: none"> • Because a VM develops when a baby is in the womb, it is something the baby is born with. Yet, a patient or parent might not see it at first. VMs can appear after an accident or as a child grows into an adult (during puberty).
<p>DIAGNOSING</p>		
<p>History and physical exam</p>	<ul style="list-style-type: none"> • 90% of venous malformations are diagnosed by history and physical examination • Patients and/or family members are queried about a family history of similar lesions, especially if a glomerve-nous malformation or cutaneous venous malformation is suspected • Dependent positioning of the affected area will cause a venous malformation to enlarge 	<ul style="list-style-type: none"> • Doctors can discover 90% of VMs by looking at the affected area and going over the patient's history. The doctor will ask if this has happened to a family member. • Some rare kinds of VMs are genetic. This means they are in the family's DNA and can happen to other family members. • In general, VMs are not passed on from parent to child. Nothing that a mother does during pregnancy can cause these.
<p>What kind of imaging is done?</p>	<ul style="list-style-type: none"> • Large or deep venous malformations are evaluated by MRI to confirm the diagnosis, define the extent of the malformation, and plan treatment. • MRI sequences are obtained with fat suppression and contrast. Phleboliths demonstrate a low-intensity signal on both T1 and T2 images. Contrast helps delineate a venous malformation from a lymphatic malformation, because venous lesions enhance uniformly following gadolinium administration. Venous malformations can appear less intense after treatment because of scar tissue. Morphologically, venous malformation is often circumscribed, lobulated, and isolated to an anatomical structure (usually muscle). In contrast, a lymphatic malformation is more likely to infiltrate through several tissue planes. 	<ul style="list-style-type: none"> • If a patient has a deep or large VM, a doctor will want to take an MRI to make sure. MRI stands for Magnetic Resonance Imaging. An MRI is a scan or picture of the inside of a patient's body. The MRI will help the doctor see the size and location of the VM. Also, MRI will help doctors see what other important things are near the VM, that may be affected by treatment.

<p>What kind of imaging is done? (continued)</p>	<ul style="list-style-type: none"> • MR venography is occasionally indicated to show the deep venous system in lesions affecting an extremity. • Ultrasonography can be used instead of MRI for imaging of some localized venous malformations and does not require sedation in young children. • Phlebectasia is initially imaged with ultrasound to demonstrate the dilated, incomplete veins and large perforators. • Computed tomography is occasionally indicated to assess an osseous venous malformation. • Intralosomal venography is not needed to confirm the diagnosis of a venous malformation. It is performed during sclerotherapy before sclerosant is injected. 	<ul style="list-style-type: none"> • An MRV is a specific type of MRI that shows blood vessels. MRV stands for Magnetic Resonance Venography. Sometimes, the doctor will do an MRV to see the system of veins connecting to the VM. • An MRA is a specific type of MRI that shows blood vessels. MRA stands for Magnetic Resonance Angiography. Sometimes, the doctor will do an MRV to see if there are any arteries connecting to the VM. • MRI/MRV/MRA does not expose a patient to radiation. • For small VMs, the doctor could do an Ultrasound to see the VM. This is a good method for young children because it doesn't require sedation. Ultrasound can also be used to see Phleboliths. • A doctor could do a CT scan to see if the VM is affecting a bone. CT stands for Computed Tomography. A CT is like an MRI, except it uses x-rays instead of magnets. In general, CTs are not the best way to look for VM.
<p>TREATING</p>	<p>Venous malformations can be managed in different ways, but will not be 100% cured.</p> <ul style="list-style-type: none"> • Because venous malformation is at greatest risk for expansion during adolescence, pubertal hormones may be involved in its pathogenesis. Consequently, women are advised to avoid estrogen-containing oral contraceptives, because estrogen has more potent proangiogenic activity than progesterone. 	<p>VMs cannot be completely cured, but there are many ways to manage them well.</p>
<p>Doctors Involved</p>	<p>Children with an extensive venous malformation are evaluated by a hematologist. Large lesions are at risk for coagulation of stagnant blood, stimulation of thrombin, and conversion of fibrinogen to fibrin. Fibrinolysis results in localized intravascular coagulopathy. The chronic consumptive coagulopathy can cause either thrombosis (phleboliths) or bleeding (hemarthrosis, hematoma, or intraoperative blood loss).</p>	<p>A team of doctors will work together to treat a VM. An Interventional Radiologist is a doctor that can read pictures and scans of the body and use these images to treat the VM. This doctor will play a role in both diagnosing and treating your VM. Patients with large VMs may also see a hematologist. This is because large VMs can lead to problems with blood clotting. A hematologist is a doctor who treats blood diseases. If you are getting treatment for a large VM the hematologist will make sure your blood is clotting properly, before, during and after the procedure.</p>

<p>When should you get treatment?</p>	<ul style="list-style-type: none"> • Venous malformation is a benign condition, and non-problematic lesions can be observed. • Intervention for venous malformation is reserved for symptomatic lesions that cause pain, deformity, or threaten vital structures, or for asymptomatic phlebectatic areas at risk of thromboembolism. • Many children do not require treatment at the time of diagnosis. Because venous malformations can slowly expand, patients may become symptomatic and seek intervention during late childhood or adolescence. • Occasionally, a venous malformation involving an anatomically sensitive area or causing a significant deformity necessitates management as early as infancy. If possible, intervention should be postponed until after 12 months of age, when the risks associated with anesthesia are lower. • Therapy for lesions causing a visible deformity should be considered before 4 years of age to limit psychological morbidity. At this time long-term memory and self-esteem begin to form. • Some parents elect to wait until the child is older and able to make the decision to proceed with operative intervention, especially if the deformity is minor. However, if the venous malformation enlarges over time, it can become more difficult to treat. 	<ul style="list-style-type: none"> • Venous Malformation (VM) is benign, which means it's not cancer. If a VM isn't causing problems (pain, or loss of function) for the patient, then doctor will just check on it every year. However, VMs can slowly expand over time. Once a VM starts causing problems, doctors will start treatment. • If a VM is in a sensitive or dangerous area, doctors may want to treat it right away. • Whether a VM needs treatment right away or not, the patient should see a specialist doctor before age 4. This is when long-term memory and self-esteem begin to form. Deformity can lead to psychological problems. Doctors will make sure patients and families feel good about the treatment timeline.
<p>Pharmacotherapy?</p>	<p>Sirolimus</p> <ul style="list-style-type: none"> • Individuals with recurrent discomfort are given low-dose prophylactic daily aspirin to prevent phlebothrombosis 	<p>Many doctors are working on new treatments for VMs. A new drug called Sirolimus has worked for some patients. For most vascular anomalies, a combination of treatment methods is best. Your doctor will help you decide where to start.</p>

<p>Sclerotherapy?</p>	<ul style="list-style-type: none"> • Sclerotherapy involves the injection of a sclerosant into the venous malformation, which causes cellular destruction, thrombosis, and intense inflammation. Scarring leads to shrinkage of the lesion. • The first-line treatment for a problematic venous malformation is sclerotherapy, which generally is safer and more effective than resection. Exceptions to this rule include: Small, well-localized lesions that can be easily excised for cure. Glomovenous malformations which respond less-favorably to sclerotherapy. Venous malformations involving the palmar aspect of the hand or adjacent to an important nerve such as the facial nerve. • Sclerotherapy provides good to excellent results in 75% to 90% of patients, reducing the size of the malformation and/or alleviating symptoms. • Sclerotherapy is continued until symptoms are resolved and/or spaces are no longer available to inject, because the venous malformation has become fibrotic. • Often multiple treatments are required, spaced 6 weeks apart. • Ultrasonography is used to assess the response to treatment and to determine whether residual spaces are amenable to further injections. • Possible sclerosants include sodium tetradecyl sulfate, ethanol, polidocanol, alcohol solution of zein, bleomycin, sodium morrhuate, or ethanolamine oleate. • Boston Children's Hospital prefers sodium tetradecyl sulfate (10 ml of 3% solution mixed with 2 ml of ethiodized oil [Ethiodol] and 10 cc of air). The solution is then forced back and forth between two syringes attached to a three-way stopcock to create a foaming mixture, which increases the efficacy of the solution. 	<ul style="list-style-type: none"> • Sclerotherapy is a great treatment for venous malformations (VMs). Sclerotherapy means injecting the VM with a fluid. This fluid destroys the veins, can clot the blood, and helps the VM to scar down. The goal is that less or no blood will flow through the VM. This will cause the VM to shrink. • Sclerotherapy is done a little bit at a time with treatments at least 6 weeks apart. Each vein that is part of the VM is filled. • During a Sclerotherapy treatment, a doctor will use Ultrasound to target the VM, and x-ray imaging to help control the treatment. • A variety of fluids could be used for Sclerotherapy. The fluid that is injected is called a Sclerosant. • A variety of fluids could be used for Sclerotherapy. The fluid that is injected is called a Sclerosant. The possible Sclerosants are Sodium tetradecyl sulfate (STS) Ethanol Polidocanol Alcohol solution of zein Bleomycin Sodium morrhuate Ethanol oleate • What Sclerosants may be used should be discussed with the VM specialist. Your doctor will advise you about which Sclerosant is best for your VM. He/She will prepare you for what happens normally after the procedure and for potential problems.
-----------------------	---	--

<p>Sclerotherapy? (continued)</p>	<ul style="list-style-type: none"> Ethanol may be more destructive to a venous malformation than sodium tetradecyl sulfate, but it has to be carefully used because of its potential for causing local and systemic complications. It should be used with caution when injected adjacent to important structures such as the facial nerve. Most patients, especially children, are managed under general anesthesia with ultrasound and/or fluoroscopic guidance. A Foley catheter is placed to monitor urine output if a large venous malformation is treated. The malformation is cannulated using ultrasound, and contrast is injected under fluoroscopy to determine the anatomy of the lesion. Typically, a contrast agent (Ethiodol) or air/carbon dioxide is mixed with the sclerosant to allow fluoroscopic or sonographic monitoring. Multiple injections into different portions of the venous malformation are often needed. Except for high-risk individuals, most patients are discharged home the day of the procedure. Small lesions in adolescents and adults may be treated in the office without image guidance. The early response to sclerotherapy is swelling, irritation of the overlying skin, and bruising. The most common complication is ulceration (in less than 5% of cases), which is more likely to occur if the venous malformation involves the skin or if ethanol is used. Ulcerations are managed with local wound care and are allowed to heal secondarily. Extravasation of the sclerosant outside the lesion can cause injury to adjacent structures. Post treatment swelling may necessitate close monitoring. Patients with airway lesions are admitted to the intensive care unit, and occasionally prolonged intubation or tracheostomy is required. 	<ul style="list-style-type: none"> For comfort, most patients are put to sleep during Sclerotherapy. The doctors who do this are called Anesthesiologist. Some patients get to go home the day of the procedure, and some stay overnight in the hospital to recover. Right after treatment, there could be swelling, irritation on the skin, and bruising at the site of the VM.
---------------------------------------	--	--

<p>Sclerotherapy? (continued)</p>	<ul style="list-style-type: none"> • Orbital injections can cause orbital compartment syndrome, and patients are examined by an ophthalmologist before and after the procedure. Treatment of deep extremity lesions below the muscle fascia can cause compartment syndrome. • Systemic adverse events from sclerotherapy can occur if a significant volume of sclerosant is used: hemolysis, hemoglobinuria, and oliguria. Ethanol can cause central nervous system depression, pulmonary hypertension, hemolysis, thromboembolism, and arrhythmias. • To prevent renal injury, D5W with 75 mEq/L of sodium bicarbonate is used to alkaline the urine. Maintenance fluid is double for the first 4 hours after treatment. Oliguria is treated with one small dose of a diuretic. • Patients with low fibrinogen levels who are at risk for thromboembolism may be given low-molecular-weight heparin (0.5 mg/kg/dose every 12 hours) for 14 days before and after the procedure (maximum 30 mg). • Venous malformations usually reexpand after sclerotherapy; thus patients often require additional interventions over the course of their lifetime. For example, 6 months after treatment with sodium tetradecyl sulfate, 45% of patients have partial recanalization. • Although sclerotherapy effectively reduces the size of venous malformations and improves symptoms, it does not remove the malformation. Consequently, patients can continue to have a mass or visible deformity after treatment that may be improved by resection. 	<ul style="list-style-type: none"> • The most common complication of Sclerotherapy is Ulceration. This means that a sore or wound develops on the skin over the VM. The sore is called an Ulcer. Ulceration happens in less than 5% of cases. Your doctor will help you manage an ulcer until it heals. • Sclerotherapy makes the VM get smaller, but VMs can re-expand over time. VMs are not curable, instead they are managed throughout life. Many patients get multiple rounds of treatment throughout their lifetime. The goal is to make symptoms go away as much as possible.
<p>Surgery?</p>	<ul style="list-style-type: none"> • Resection is less favorable than sclerotherapy because the entire lesion can rarely be removed. Excision may cause a worse deformity than the malformation. Recurrence is likely, since abnormal channels adjacent to the lesion are not treated. The risk of blood loss and iatrogenic injury is high. 	<p>Sclerotherapy can reduce the size of a VM and make symptoms go away. Yet, it can't make the VM go away completely. Patients sometimes can get surgery after Sclerotherapy. This could remove a mass or visible mark left by the VM. However, the VM will often return after surgery. Surgery to remove a VM can result in major blood loss. It could also cause a worse deformity than the VM. It is nearly impossible to surgically remove an entire VM.</p>

Infantile Hemangioma (IH)		
	Notes from Resources•	Plain Language
DESCRIPTION		
Other names		
Physical Appearance	<ul style="list-style-type: none"> • Infantile Hemangioma (IH) is the most common tumor of infancy; affecting 4% to 5% of white individuals. • Females (4:1) are affected more frequently than males. • Children born prematurely are more likely to develop an IH. • 80% involve the integument and are bright red (superficial infantile hemangioma). • 20% are underneath the skin and may appear bluish or have no overlying skin discoloration (deep infantile hemangioma) • 50% are noted at birth by a telangiectatic stain/ecchymotic area, although the median age of presentation is 2 weeks after birth. 	<ul style="list-style-type: none"> • Infantile Hemangioma (IH) is the most common tumor that affects babies. • IH is at least twice as common in girls and are more common in Caucasians. • Babies who are born early are more likely to have an IH. • IH usually appears on the skin surface and is bright red. This is called Superficial IH. Sometimes IH happens deep under the skin. This is called Deep IH. Sometimes an IH will be on the surface and deep. This is called Mixed IH. • Many IH show some mark or color change on the skin at birth or within the first 2 weeks of a baby's life.
What is happening under the skin?	<ul style="list-style-type: none"> • Infantile hemangioma may arise from vasculogenesis (formation of blood vessels from progenitor cells). • Hemangioma endothelial cells (HemECs) are clonal, and thus a somatic mutation in a precursor cell may cause the lesion. • The precursor cell for infantile hemangioma might be a multi-potent hemangioma-derived-stem cell (HemSC) that has been isolated. Although it has been postulated that the precursor cell for infantile hemangioma may have embolized from the placenta, genetic studies have shown that HemECs are derived from the child, not the mother. • Several mechanisms could contribute to the rapid growth of infantile hemangioma. • The mechanism by which infantile hemangioma involutes is unknown. 	<ul style="list-style-type: none"> • The exact cause of IH is not fully understood. We know that blood vessels in the IH come from types of cells called Stem Cells. These Stem Cells send signals to form new blood vessels. Some of the vessels also form from the normal vessels that are already there. Different signals tell the cells in the IH to grow more than they should.

<p>Why/When do they appear?</p>	<ul style="list-style-type: none"> • 50% are noted at birth by a telangiectatic stain/ecchymotic area, although the median age of presentation is 2 weeks after birth. • During the first 9 months of life, infantile hemangioma grows rapidly (proliferating phase); 80% of its size is achieved by the time the infant is 3.2 months of age. • Between 9 and 12 months of age, the lesion begins to slowly shrink (involuting phase); the color fades and the lesion flattens. The appearance improves until 3.5 years of age. • After 3.5 years of age, an infantile hemangioma will no longer be visible in 50% of children. Others will have a permanent deformity: residual telangiectasias, anetoderma from loss of elastic fibers, scarring, fibrofatty residuum, redundant skin, and/or destroyed anatomic structures. 	<ul style="list-style-type: none"> • IH usually appears within 2 weeks of birth. • During a baby's first 9 months, an IH will grow quickly. This time is called the Proliferative Phase. • By about 3 months of age, the IH will be at 80% of its maximum size. By 5 months of age about 80% of IHs will have completed their growth. Some types of IH can grow longer. • Usually by the time a baby is 1 year old, the IH will start to shrink and begin to flatten. • Most Hemangiomas will decrease to their smallest possible size between 3 ½ and 4 years of age. For some children, the IH will no longer be there at all. Up to half of children may have some extra blood vessels on the skin (telangiectasias) or some scar tissue.
<p>DIAGNOSING</p>		
<p>History and physical exam</p>	<ul style="list-style-type: none"> • 90% or more of infantile hemangiomas are diagnosed by history and physical examination based on the tumor's appearance and unique growth cycle. • Deeper lesions are more difficult to diagnose, because they are noted later than superficial tumors and may not have significant overlying skin changes. A lesion beneath the integument might not be appreciated until 3 or 4 months of age, when it has grown large enough to cause a visible deformity. • Diagnosis of deep or equivocal lesions is facilitated using a hand-held Doppler audio device, which shows fast-flow. 	<ul style="list-style-type: none"> • Doctors can diagnose over 90% of Infantile Hemangiomas (IH) by examining the area and talking with the parents about the baby's birth and growth. • If the IH is deep under skin, it can be harder to diagnose in the first few months of life. It may not be seen until 3 or 4 months of age.

<p>What kind of imaging is done?</p>	<ul style="list-style-type: none"> • Ultrasonography is the first-line confirmatory study for a soft tissue infantile hemangioma if history, physical examination, and handheld Doppler findings are equivocal. Ultrasonound is also used to identify hepatic lesions. Infantile hemangioma appears as a well-circumscribed hypervascular soft tissue mass. Low-resistance arterial waveforms indicate decreased arterial resistance and increased venous drainage. • MRI is rarely indicated and requires sedation. It is necessary if a visceral lesion (for example, in the brain or lung) is suspected, or occasionally if the diagnosis remains unclear following ultrasonography. 	<ul style="list-style-type: none"> • In cases where a history and exam are not enough, the doctor may order an Ultrasound to see under the skin. • Usually, IH only happens in the skin and soft tissue, but sometimes IH can occur inside the body or be associated with changes in the heart and brain. In these cases, an Echocardiogram (an Ultrasound of the heart) or an MRI/MRA may be needed. MRI stands for Magnetic Resonance Imaging. An MRI is a scan or picture of the inside of a patient's body. MRA stands for Magnetic Resonance Angiography. An MRA shows the blood vessels.
<p>PHACE</p>	<ul style="list-style-type: none"> • This condition consists of a plaque-like infantile hemangioma in a "segmental" or trigeminal nerve distribution of the face with one or more of the following anomalies: posterior fossa brain malformation, hemangioma, arterial cerebrovascular anomalies, coarctation of the aorta and cardiac defects, eye/endocrine abnormalities, sternal clefting/supraumbilical raphe. • PHACES affects 2.3% of children with infantile hemangioma; 90% are female. 	<ul style="list-style-type: none"> • IH can rarely be part of a syndrome called PHACE. This affects about 2% of children with Hemangiomas. Each letter stands for a condition. The conditions are: P - brain malformation H - hemangioma A- abnormal arteries C- heart problems E - eye malformation <p>In PHACE, a large Hemangioma – that usually covers a wide 'geographic' area – is on the head or, less often, the upper body. This occurs with one of the conditions in the brain, heart, or eye. If your doctor suspects PHACE, an MRI/MRA, echocardiogram, and an eye exam will be done.</p>

<p>TREATING</p>	<p>General</p> <ul style="list-style-type: none"> • Most children with infantile hemangioma are observed, because 90% of lesions are small, localized, and do not involve important areas. • Infants are followed monthly during the proliferative phase if the tumor has potential to become problematic (for example, may cause obstruction or destruction of important structures). • During involution, patients are followed annually if intervention may be necessary in childhood to improve a deformity. • 16% of infantile hemangiomas will ulcerate at a median age of 4 months. Lip, neck, and anogenital tumors are most likely to ulcerate. • To reduce risk of ulceration, tumors are covered with a hydrated petroleum to minimize desiccation and protect against shearing of the skin. • If an ulceration develops, the wound is washed with soap and water at least twice daily. Small, superficial areas are managed with topical antibiotic ointment. • To minimize discomfort, a small amount of topical lidocaine may be applied, no more than 4 times daily to avoid toxicity. • Almost all ulcerations will heal with local wound care. 	<ul style="list-style-type: none"> • Most children with Infantile Hemangioma (IH) don't need treatment. 90% of IHs are small and don't cause problems. • Before age 1, the IH will be growing. During this time, your pediatrician or a specialist, usually a dermatologist, will check up on it regularly. If the IH starts causing problems, a doctor will recommend treatment. • Between age 1 and age 3.5, the tumor will be shrinking. The patient should see a doctor at least once a year. • Ulceration is the most common complication with IH. An ulcer is a sore or wound on the IH. Your doctor will help the ulcer to heal with wound care, medicine, lasers or, rarely, surgery.
<p>Doctors Involved</p>	<p>Pediatric Dermatologist</p>	<ul style="list-style-type: none"> • Infantile Hemangioma (IH) is a condition that affects babies. A doctor who specializes in child health is called a Pediatrician. A Pediatrician who treats skin problems in children is called a Pediatric Dermatologist. This type of doctor will be able to diagnose an IH.

<p>When should you get treatment?</p>	<ul style="list-style-type: none"> • Intervention for lymphatic malformation is reserved for symptomatic lesions. • Occasionally, a lymphatic malformation involving an anatomically sensitive area or causing a significant deformity necessitates management as early as infancy. If possible, intervention should be postponed until after 12 months of age, when the risks associated with anesthesia are lower. • Therapy for lesions causing a visible deformity should be considered before 4 years of age to limit psychological morbidity. At this time long-term memory and self-esteem begin to form. 	<ul style="list-style-type: none"> • Lymphatic Malformation (LM) is benign, which means it's not cancer. If an LM isn't causing problems (pain or loss of function) for the patient, then doctor will just check on it every year. However, LMs can slowly expand over time. Once an LM starts causing problems, doctors will start treatment. • If an LM is in a sensitive or dangerous area, or if it becomes infected often, doctors may want to treat it right away. • Even if you aren't ready for treatment, the patient should see a specialist doctor before age 4. This is when long-term memory and self-esteem begin to form. Deformity can lead to psychological problems. Doctors will make sure patients feel good about the treatment timeline.
<p>Drugs?</p>	<ul style="list-style-type: none"> • Oral propranolol is now approved by the US Food and Drug Administration (FDA) for treating IHs that involve intervention (Puttgen et al., 2016). • With clinical use, propranolol has been found to be rapidly effective for IH, well tolerated, and better than previous therapies at inducing regression (Drolet et al., 2013). • Before the initiation of [oral propranolol] therapy, the potential risks of adverse effects are carefully considered and weighed against the benefits of intervention. A medical team with expertise in both the management of IH and the use of oral propranolol in infant provides the most optimal care to patients in need of systemic therapy with propranolol. (Drolet et al., 2013). 	<ul style="list-style-type: none"> • A drug called Propranolol is now approved by the US Food and Drug Administration (FDA) for treating IH. Propranolol is a drug taken by mouth. It has been used for many years to treat abnormal heart beat, high blood pressure and other conditions. It has been proven to cause Hemangiomas to shrink. • You and your doctor should consider the risks and benefits of Propranolol before starting treatment. A medical team with experience in treating IHs with Propranolol will provide the best care. • Timolol is an eye drop that can be used to treat small, thin Hemangiomas. This drug only treats the skin surface.

<p>Drugs? (continued)</p>	<ul style="list-style-type: none"> • Topical timolol may be effective for small, superficial infantile hemangiomas in unfavorable locations, such as the periorbital area, lip, or nose. The drug does not penetrate through the dermis, and thus deep tumors are not affected. • Timolol 0.5% gel-forming solution may prevent proliferation and cause accelerated regression. • Asthma, apnea, and bradycardia have occurred following ophthalmological use of timolol as a result of systemic absorption of the drug. Although these complications have not been reported when used for infantile hemangioma, patients should be screened for pulmonary or cardiac disease before topical timolol is used. • Dermatologic side effects include alopecia, rash, and urticarial. 	<ul style="list-style-type: none"> • Timolol is an eye drop that can be used to treat small, thin Hemangiomas. This drug only treats the skin surface.
<p>Surgery?</p>	<ul style="list-style-type: none"> • Operative intervention is rarely indicated during infancy (proliferative phase), because problematic lesions can be successfully managed with intralesional or systemic pharmacotherapy. • The tumor is highly vascular during this period, and the patient is at risk for blood loss and inferior aesthetic outcome, compared with resection after the tumor has regressed. • Operative intervention after 3 years of age (involuting phase) is much safer than excision during the proliferative phase, because the lesion is smaller and less vascular. • 50% of infantile hemangiomas leave a permanent deformity once they have finished involuting: postulceration scarring, alopecia, anetodermo, expanded skin, fibrofatty residuum, and destroyed structures, such as the nose, ear, or lip. 	<ul style="list-style-type: none"> • Most patients don't need surgery during infancy to treat an Infantile Hemangioma (IH). If the IH needs treatment, it can almost always be treated with medication. • After 3 years old, when the IH has gotten smaller, surgery is much safer. • 50% of IHs leave a permanent mark or scar. This will sometimes be removed with surgery.

<p>Surgery? (continued)</p>	<ul style="list-style-type: none"> • Because the lesion has been allowed to shrink maximally, the extent of the excision and reconstruction is reduced, and thus the aesthetic outcome is superior. • It is preferable to intervene surgically between 3 and 4 years of age. During this period, the infantile hemangioma will no longer improve significantly, and the procedure is performed before the child's long term memory and self-esteem begin to form at about 4 years of age. Some parents may elect to wait until the child is older and able to make the decision to proceed with operative intervention, especially if the deformity is minor. • Because the tumor acts as a tissue expander, there is usually adequate skin to allow primary, linear closure of the wound. 	<ul style="list-style-type: none"> • Surgery is usually done between ages 3 and 5. This is after the IH has gotten smaller, and before the child's long-term memory and self-esteem begin to form. Some parents choose to wait until the child is old enough to decide whether to have surgery. • Hemangiomas sometimes leave behind extra skin. This can help a surgeon to close the wound after removing the IH.
-----------------------------	---	--

Table 6. Vascular Anomalies Research. The research in this table has been gathered from Vascular Anomalies: Classification, Diagnosis, & Management by Arin K. Greene, from Abrams' Angiography: Interventional Radiology, 3rd Edition, and from the input of Drs. Clifford Weiss and Katherine Puttgen of the Johns Hopkins University School of Medicine. The text in the "Notes from Resources" column is the copyright of the original publishers. The text in the "Plain Language" column is copyright of Eleanor Bailey.

APPENDIX C

List of Glossary Terms Defined in the Resource:

Arteriovenous Malformation

benign

cardiologist

clinical trial

dermatologist

Hemangioma

hematologist

lymph

lymphatic vessels

pathologist

radiologist

Sclerotherapy

Ulceration

Vascular Anomalies

Venous Malformation

CITED REFERENCES

- America's Health Literacy: Why We Need Accessible Health Information. (2008). Retrieved February 3, 2017, from <https://health.gov/communication/literacy/issuebrief/>
- Barry, M. J., and Edgman-Levitan, S. (2012). Shared Decision Making — The Pinnacle of Patient-Centered Care. *New England Journal of Medicine*, 366(9), 780-781. doi:10.1056/nejmp1109283
- Davis, K. S., McCormick, A. A., and Jabbour, N. (2017). What might parents read: Sorting webs of online information on vascular anomalies. *International Journal of Pediatric Otorhinolaryngology*, 93, 63-67. doi:10.1016/j.ijporl.2016.12.004
- Fox, S., and Duggan, M. (2013). Health Online 2013. Retrieved February 1, 2017, from <http://www.pewinternet.org/2013/01/15/health-online-2013/>
- Greene, A. K. (2013). *Vascular Anomalies: Classification, Diagnosis, & Management*. St. Louis, MO: Quality Medical Publishing.
- Perrin, A., and Duggan, M. (2015). Americans' Internet Access: 2000-2015. Retrieved February 2, 2017, from <http://www.pewinternet.org/2015/06/26/americans-internet-access-2000-2015/>
- The DISCERN Instrument. (1997). British Library and the University of Oxford. Retrieved October 4, 2016, from http://www.discern.org.uk/discern_instrument.php

GENERAL REFERENCES

- Tekes, A., Mitchell, S. E., Puttgen, K. B., Redett, R. J., Hsu, S. L., and Weiss, C. R. (2014). Vascular Anomalies: Hemangiomas and Vascular Malformations. In *Abrams' Angiography: interventional radiology* (Third ed., pp. 306-336). Philadelphia, PA: Lippincott Williams & Wilkins, a Wolters Kluwer business.
- Duckett, J. (2015). *HTML & CSS: design and build websites*. Indianapolis, IN: John Wiley & Sons, Inc.
- Greene, A. K. (2012). Current Concepts of Vascular Anomalies. *Journal of Craniofacial Surgery*, 23(1), 220-224. doi:10.1097/scs.0b013e318241b8cc
- Behraves, S., Yakes, W., Gupta, N., Naidu, S., Chong, B. W., Khademhosseini, A., and Oklu, R. (2016). Venous malformations: clinical diagnosis and treatment. *Cardiovascular Diagnosis and Therapy*, 6(6), 557-569. doi:10.21037/cdt.2016.11.10
- Tollefson, M. M., & Frieden, I. J. (2012). Early Growth of Infantile Hemangiomas: What Parents' Photographs Tell Us. *Pediatrics*, 130(2), E314-E320. doi:10.1542/peds.2011-3683d

VITA

Eleanor Bailey was born in Livingston, Montana on September 9, 1992. She grew up in the foothills of the Cascades in Carnation, Washington. After graduating high school, she attended Mississippi State University. It was here that she cultivated her love of art and biology, graduating *summa cum laude* with a Bachelor of Fine Arts in Drawing while maintaining a research practice in the Stewart Biology Laboratory.

In August of 2015, Eleanor moved to Baltimore, Maryland to join the Department of Art as Applied to Medicine at the Johns Hopkins University School of Medicine. She has worked with veterinarians, researchers, surgeons, clinicians, and educators to communicate complex subject matter in innovative ways. She will receive her Master of Arts in Medical and Biological Illustration in May 2017.