



## Case Report

## Micro-CT for the examination of paediatric rib injuries: A case series

Waltraud Baier\*, Danielle G. Norman, Mark A. Williams

WMG, International Manufacturing Centre, University of Warwick Coventry, CV4 7AL, UK



## ARTICLE INFO

## Article history:

Received 24 October 2020

Received in revised form 17 March 2021

Accepted 7 April 2021

Available online 15 April 2021

## Keywords:

Paediatric rib fractures

Non-accidental injuries

Child abuse

Child homicide

Micro Computed Tomography (Micro-CT)

## ABSTRACT

Cases of child abuse and homicide are amongst the biggest challenges investigators face, with complex evidence bases often strongly contested and reliant on specialist interpretation of the medical evidence. In many cases, this medical evidence includes examination of the deceased's skeleton using different macroscopic and microscopic imaging methods. Rib fractures are a common concern when examining suspicious cases and much research has been conducted on their causes. The role of CPR in particular has been controversial and therefore a clear assessment of the fracture distribution is crucial. Recent studies have shown the benefit of imaging techniques such as Computed Tomography, although the gold standard remains histology. This paper presents three cases of suspected non-accidental rib fractures of infants which had been examined using micro-CT and histology. Micro-CT has been shown to be superior to medical CT as it achieves a greater resolution, making it effective for paediatric post-mortem imaging. Micro-CT observations were compared retrospectively to the histology, which demonstrated that micro-CT found 69% of the fractures identified histologically as well as an additional 22% not identified through histology. As well as complimenting histological analysis, the extent to which micro-CT can enhance the overall examination of paediatric non-accidental injuries is also discussed.

© 2021 The Authors. Published by Elsevier B.V.  
CC BY-NC-ND 4.0

## 1. Introduction

Physical injuries suggestive of child abuse and their precise cause can be a contentious issue in both medical and legal communities [1,2] and consequently have been at the centre of some of strongly contested court cases [3]. The term Non-Accidental Injury (NAI) describes this type of trauma in a more neutral way. Investigating NAI's poses significant challenges as the suspects often are the child's parents or primary carers and often there are additional concerns regarding the welfare of any siblings and subsequent social care issues if the injuries were non-fatal. When a child presents at hospital with injuries for which no plausible explanation is provided, standard protocol is to raise the case as suspicious which then may lead to a criminal investigation [4]. Even when there is a reasonable suspicion that the injuries were inflicted by a third party, proving this is complicated since individual injuries are not pathognomonic of abuse [5]. The topic has become a focus of attention in medical and academic studies with increased societal awareness of the problem. This has led to an increased knowledge base and it is now widely accepted that fractures in certain areas such as the metaphyses of the limb bones or the posterior ribs are highly indicative of non-accidental trauma. Skull fractures have

less indicative value as they are often the result of high-impact accidents but complex or bilateral skull fractures have been shown occur in abuse [5,6]. With the distribution of injuries being a crucial aspect of the diagnosis, it becomes clear that complete and accurate documentation is paramount. Once each injury has been identified and described, it must be interpreted with regard to the fracture mechanics involved. Rib fractures are often cited as strongly linked to inflicted trauma [7,8], however, there is some controversy regarding the role of cardiopulmonary resuscitation (CPR) when used as justification for rib fractures [9]. Numerous studies have aimed to clarify the issue and it appears that while CPR-related rib fractures are rare, they do sometimes occur [10–12]. The consensus appears to be that while anterior rib fractures can be caused by both CPR and abuse and are therefore less diagnostic, posterior fractures are usually regarded as having a strong diagnostic specificity of being inflicted [10,12]. However, there is some indication that the CPR method (two-fingers versus two-thumbs encircling) is an important factor to consider as they involve different forces acting upon the ribcage [13–15].

In order to address the problem of distinguishing CPR-related injuries from true trauma, ageing the injuries correctly is crucial to determine the sequence of events. In fatal cases, histology is currently the current gold standard for wound identification and ageing [16,17]. In recent years, more and more post-mortem (PM) imaging methods have been considered for this purpose to augment the lengthy histology

\* Corresponding author.

E-mail address: [val.baier@warwick.ac.uk](mailto:val.baier@warwick.ac.uk) (W. Baier).

process and to be used in cases where the injured child has survived. A range of technologies have been employed: traditional radiographs, Magnetic Resonance Imaging (MRI), Ultrasound, Computed Tomography (CT), and occasionally Micro-CT [18,19]. Each of these imaging solutions has advantages and disadvantages regarding their area of application, their sensitivity, and their availability with micro-CT entirely limited to post-mortem imaging due to the high dose of radiation emitted. MRI and ultrasound, on the other hand, are radiation-free and therefore better suited to scan children who have survived their injuries [18]. However, both methods are less available and less effective for detecting bone fractures [20] which are most commonly imaged using 2D radiographs, which poses another problem, namely that of superimposition of three-dimensional structures, thus obscuring potential trauma [21]. CT therefore appears to be the most promising imaging technology for rib fractures [21], and micro-CT offers even higher spatial resolution than standard medical CT which has been exploited in an increasing number of forensic applications [22]. The small size of paediatric bones therefore lends itself to be imaged in this way and it has been noted by Raynor et al. [16] that this method increasingly precedes histopathological examination in such cases. They proceed to state that “A careful comparative study of PM micro-CT and histology is awaited”, which is the aim that the present study begins to address. For this purpose, a case series consisting of three cases of infants with rib fractures was micro-CT scanned as part of the medico-legal investigation. The study further aims to assess the suitability of micro-CT imaging by comparison to histology and post-mortem examination findings. Finally, it will discuss how the micro-CT images can serve to support court testimony.

**2. Materials and methods**

Three infant ribcages (including the spine) were micro-CT scanned following the forensic post-mortem examination which had in all three cases identified one or more unexplained rib fractures. None of them were found to have any underlying conditions affecting bone susceptibility to fracture. The specimens were secured onto a bed of foam using surgical thread and placed inside a plastic specimen container for scanning. Each ribcage was scanned at the highest permissible resolution given the overall specimen size and interpreted by a research anthropologist with 5 years experience in reading micro-CT images. The ribcages were subsequently examined by a histopathologist with over 25 years experience. In case 1 the micro-CT results were not available to the histopathologist prior to their examination, in cases 2 and 3 they were in form of an illustrated report; the raw image data were not consulted. The histology examination followed established procedures based primarily on macroscopic inspection and specimen radiography. The histology reports were retrospectively compared to the micro-CT findings by the micro-CT examiner in order to establish the injury detection rate of micro-CT, relative to histology, and to identify any additional fractures revealed through the micro-CT inspection (Table 1). Fractures were noted according to their exact location in each

**Table 1**  
Summary of all fractures observed. Matches in the “healing” column include 9 identified as acute on micro-CT but confirmed to be healing on histology. The “Possible” matches describe possible fractures confirmed through the other method (2 possible histology fractures and 7 possible micro-CT fractures).

	Acute	Healing	Possible	Total
<b>Match</b>	8 (12.7%)	17 (27.0%)	9 (14.3%)	34 (54.0%)
<b>Histology only</b>	1 (1.6%)	12 (19.0%)	2 (3.2%)	15 (23.8%)
<b>Micro-CT only</b>	8 (12.7%)	5 (7.9%)	1 (1.6%)	14 (22.2%)

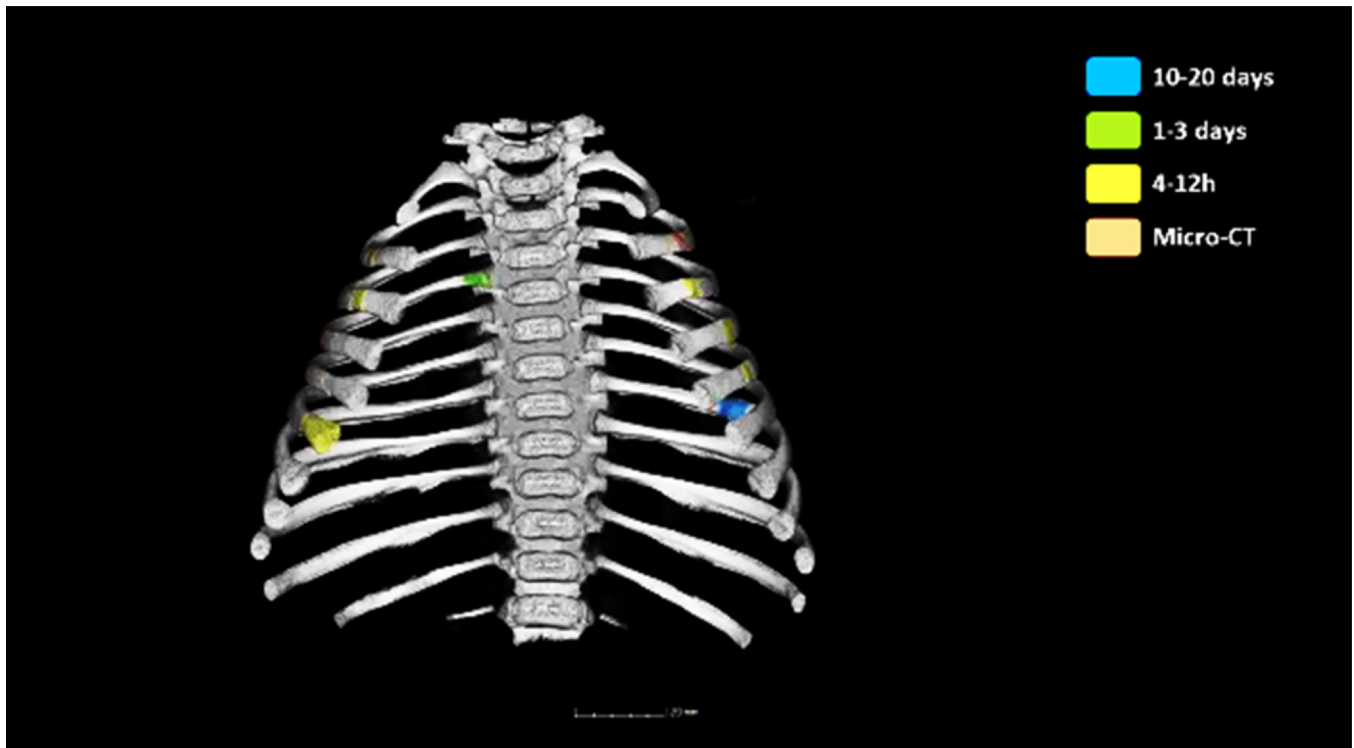
**Table 2**  
Distribution of fractures as identified using micro-CT and histology. A = Acute fracture, H = Healing fracture, P = Possible fracture, L = Left, R = Right.

Rib	Anterior		Lateral		Posterior	
	Micro-CT	Histology	Micro-CT	Histology	Micro-CT	Histology
<b>Case 1</b>						
L7	A	A			H	
		H				
L9					A	
					H	
L10	A		A	A		
			H	H		
L11					H	
R5		A				
R6					A	
R8					H	
R9	H	H			H	H
R10		H			A	A
					H	H
R11	A		A		A	A
						H
R12					H	
<b>Case 2</b>						
L2	A	P				
L3	A	A				
L4	A	A				
L5	A	A				
L7			H	H		P
R2	A	P				
R3	A	A				
R4	A					H
R5	A					
R6		P				
<b>Case 3</b>						
L3					P	H
L4					P	H
L5	P	H				
L6	A	H			P	H
L7		H				H
L8	A	H				H
L9	A	H				
L10	A	H				
L11		H				H
R2	A	H	A			H
R3					P	H
R5	P	H			P	
R6	A	H				H
R7	A	H			P	H
R8	A	H				
R9	A	H				
		H				
R10	H	H				
R11	H	H				H

examination report and were grouped as posterior, lateral, and anterior for the purpose of this study (see Table 2). Corresponding locations referred to here reflect precise localisation correspondence. Fractures were identified on micro-CT using the volume rendering and transverse sections showing cortical disruption in sequential slices. They were considered “healing” if periosteal reaction (seen as higher grey values than soft tissue, more similar to those of bone) was observed around the fracture. Histologically, a fracture was considered as healing if it occurred > 12 h prior to death.

No inter- and intra-observer studies were conducted due to the retrospective nature of this study which also prevents it from being fully blinded.

In addition, short video clips were created from the 3D views of the ribcages showing each injury (as identified histologically)



**Fig. 1.** Still image from the presentation delivered during court trial of case 2. The ribcage was shown as animated three-dimensional model with injury locations highlighted in different colours according to their age (based on the histology results). The micro-CT category refers to an injury only observed on micro-CT. (For interpretation of the references to color in this figure legend, the reader is referred to the web version of this article.)

colour-coded according to its age in support of the expert witness testimony during the court trial (see Fig. 1).

The cases:

	Case 1	Case 2	Case 3
<b>Age</b>	18 months	2 months	36 months
<b>Cause of death as determined by the forensic pathologist</b>	Cardiac arrest	Asphyxia	Abdominal injuries
<b>Scan parameters</b>			
<i>Scanner</i>	Nikon XT	Nikon XT	Nikon XT
	L 225	L 225	L 225
<i>Voltage</i>	120 kV	140 kV	120 kV
<i>Power</i>	7 W	9 W	26 W
<i>Exposure</i>	1400 ms	500 ms	500 ms
<i>Filtration</i>	None	0.125 mm tin	None
<i>Projections</i>	3141	3141	3141
<i>Spatial resolution</i>	95.7 µm	81.8 µm	126.7 µm

### 3. Results

Across the three cases, there were 8 fresh and 8 healing fractures that were identified by both micro-CT and histology independently (Fig. 2a and b). Nine further fractures were identified by both methods but considered acute on micro-CT and healing (early stages) on histology (Fig. 3d).

Eight acute (Fig. 3a), 5 healing, and 1 possible fractures were identified only by micro-CT. The acute ones were predominantly found anteriorly (n=4) whereas the healing ones were located posteriorly (n=5). One acute (Fig. 2c), 12 healing, and 2 possible fractures were identified only by histology. The majority of these healing fractures were located posteriorly (n=8), followed by anteriorly (n=4), the complete distribution is shown in Table 2.

7 possible fractures seen on micro-CT were verified by histology (Fig. 3c) and 2 seen histologically were verified using micro-CT

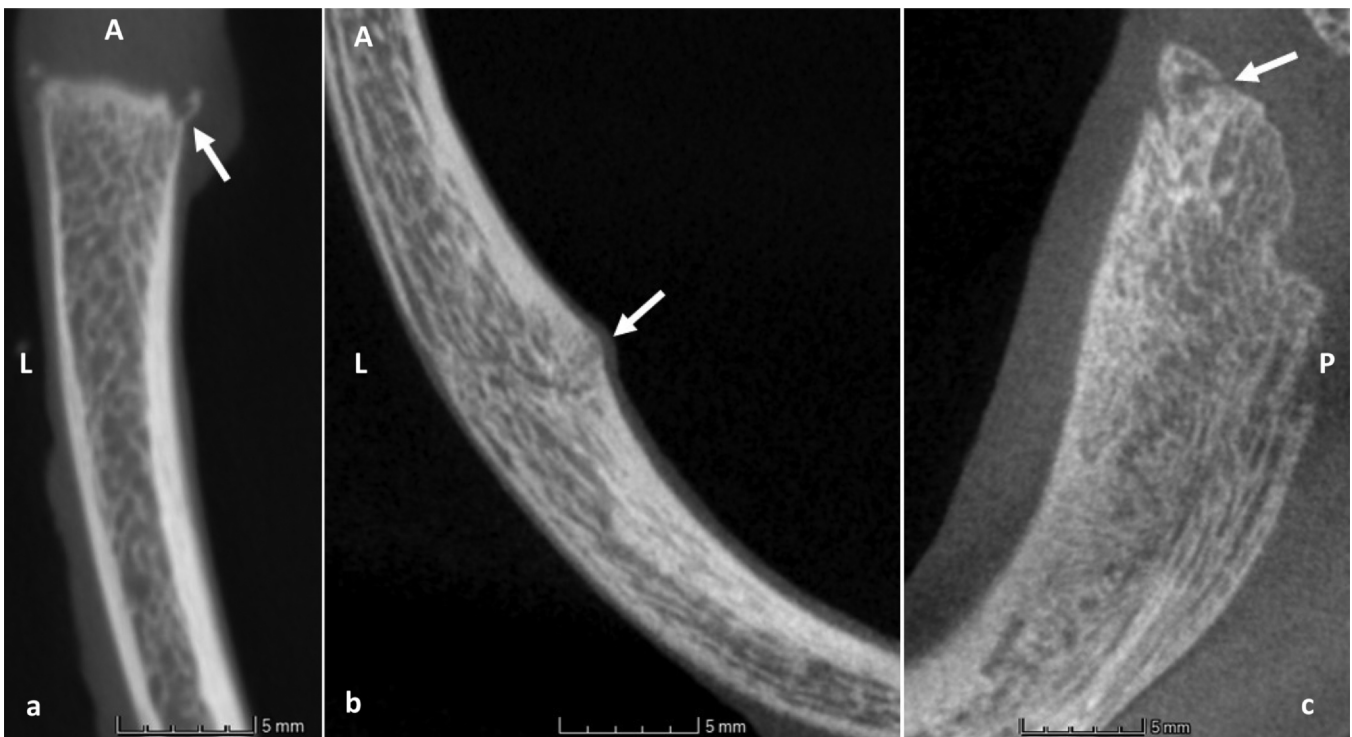(Fig. 3b). Altogether, there was no significant difference in the number of fractures identified through micro-CT compared to histology. Note that the histo-pathologist was unable to revisit and examine the fractures identified only through micro-CT examination the implications of which are considered in the discussion.

### 4. Discussion

This study retrospectively examined three cases of suspected NAI rib fractures of infants where micro-CT and histology were employed. The aim was to compare micro-CT observations of rib fractures to those identified through histology and to assess the extent that micro-CT imaging could complement the histology. Observations from micro-CT images resulted in the identification of 69% of fractures described independently through histological analysis, plus an additional 14 fractures (22% of the grand total) not seen histologically. This suggests that micro-CT imaging can complement histology when examining non-accidental rib fractures of infants.

#### 4.1. Injury age

The different age assigned to some of the injuries depending on the method used highlights the challenges of radiological fracture ageing. Radiologically, bone healing is only visible once a periosteal bone reaction begins to form, usually from around ten days onwards although it has been observed as early as four days [23,24]. Histology is therefore crucial for a more precise injury dating, being able to detect even the earliest cell responses to trauma which is potentially relevant to the distinction between fractures caused by (unsuccessful) CPR and NAIs. Research into callus ageing based on micro-CT on fractured mouse femurs has shown some promising results [25] but is still in its early stages and it remains debatable whether the findings are directly transferrable to human bone. This case series provides an initial basis to refine current micro-CT



**Fig. 2.** Transverse sections through some of the injuries encountered in this study, indicated by the arrows. (a) Case 3, Anterior left 10th rib, acute fracture identified by both methods; (b) Case 2, Lateral left 7th rib, healed fracture identified by both methods; (c) Case 1, Posterior 10th rib, healed fracture identified by both methods but acute re-fracture missed on micro-CT. All sections are shown in superior view, anterior is towards the image top. L = Left, A = Anterior, P = Posterior.

sensitivity for determining fracture age using the histological assessment. However, one challenge thereby is that each scan has a slightly different resolution and was performed using slightly different scan parameters (in order to optimise the image quality) which might affect the appearance of the more subtle changes.

The fracture age can also affect the likelihood of an injury being detected in the first place. Hong et al. [21] noted that acute fractures were most commonly missed on imaging, an observation reinforced by Raynor et al. [16] who noted that re-fractures through existing older ones were missed on the skeletal survey and contact radiology in all instances. While two re-fractures were also missed on micro-CT in the present study, four were identified correctly. A comparison is however difficult due to the classification of healing and acute in this study.

The earliest fracture identified on micro-CT as healing in the present study dated to 7–14 days prior to death (case 1, L10) whereas fractures dating to 5–14 days prior to death (case 3, R8 and R9) were described as fresh, demonstrating the complexity of this task.

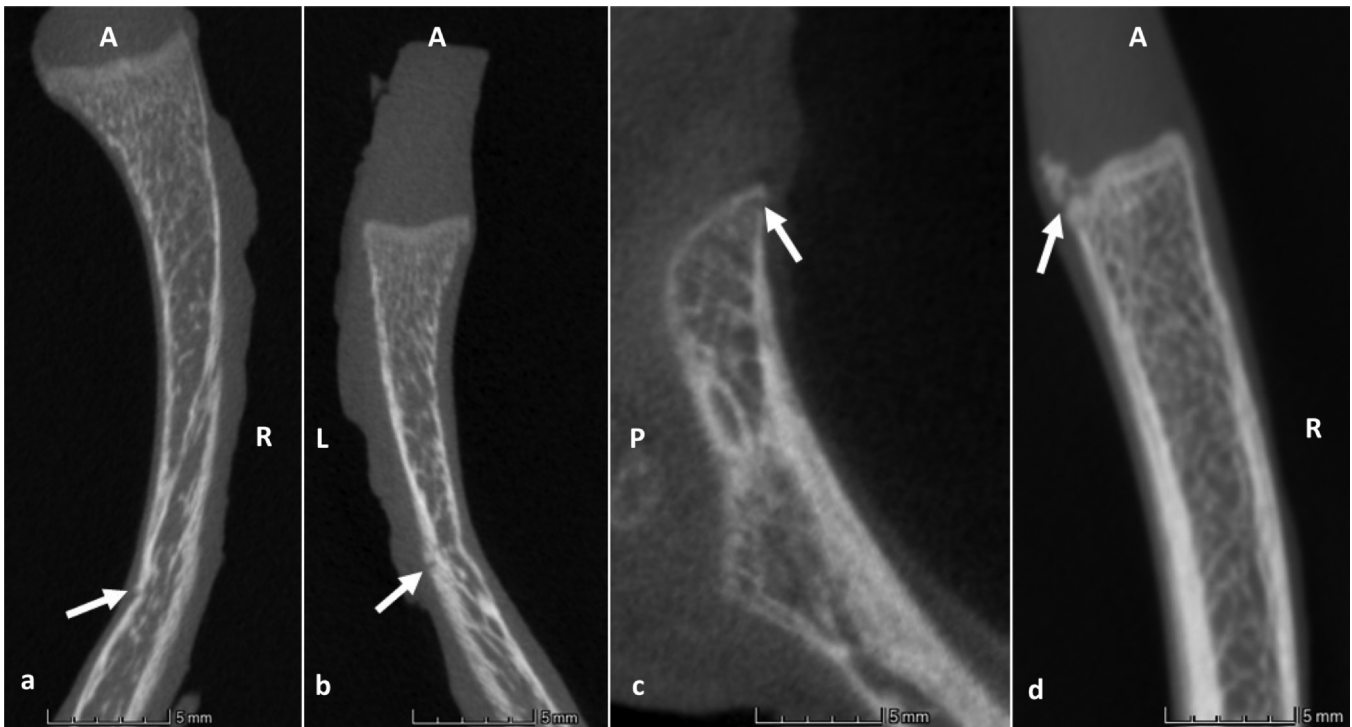#### 4.2. Micro-CT sensitivity/specificity

Due to the retrospective nature and practical limitations of conducting this study, the histopathologist was unable to re-examine the fractures identified exclusively using the micro-CT data. The features identified exclusively on micro-CT (i.e. not seen in the histology) potentially represent false negatives for the histological examination. During the preparation phase when the histopathologist is planning where to take the sections, they typically rely on radiographs and visual inspection of the specimen. Clearly, when compared to the micro-CT examination where all data is digitally captured and explored in 3D through multiple planes simultaneously, the histopathologist has access to significantly less

information for the initial identification of the fractures. Understandably then, it is difficult for the histopathologist to identify all subtle features particularly when they are not apparent macroscopically or from traditional radiographs. Indeed it would be too impractical for the histologist to examine the entire ribcage and there is inevitable loss of material as the process is destructive. The alternative of course is that features were misidentified as fractures during micro-CT examination. The authors suggest that this is unlikely given (i) that micro-CT allows for complete 3-dimensional capture of the whole specimen; (ii) the additional flexibility for the examiner to digitally explore microscopic data from any desired plane/view; (iii) the extensive experience of the micro-CT examiner with 5 years' experience in analysing micro-CT images in both research and over a hundred forensic cases. However, further research could be helpful here to variety the reason for the discrepancies such as allowing the histopathologist to re-examine the specimens following examination of the micro-CT data.

The spatial resolution of the micro-CT scans differed between the three cases (96  $\mu\text{m}$ , 82  $\mu\text{m}$ , and 127  $\mu\text{m}$ ), warranting caution when comparing them to each other. The case with the highest number of injuries missed on micro-CT coincided with having the lowest resolution (case 3, 127  $\mu\text{m}$ ). However, this was also the case with the highest number of fractures overall. Case 1 had the second lowest resolution but was the case with the highest number of fractures (10/22) identified on micro-CT alone and as discussed above the case where the histopathologist did not have access to the micro-CT findings. Given these variations and the small sample size it is difficult to assess the true impact of spatial resolution on fracture detection as this is also directly influenced by the size of the feature in question.

Similar studies have also observed the benefit of complementing histology with skeletal surveys and contact radiology [16]. The



**Fig. 3.** Transverse sections through further rib injuries examined in this study, indicated by the arrows. (a) Case 2, Anterior right 5th rib, acute fracture identified on micro-CT but not on histology; (b) Case 2, Anterior left 2nd rib, possible fracture identified histologically and confirmed on micro-CT; (c) Case 3, Posterior right 5th rib, possible micro-CT fracture confirmed histologically; (d) Case 2, Anterior 8th rib, fracture identified with both methods but classified as healing (5–14 days prior to death) using histology. R = Right, L = Left, A = Anterior, P = Posterior.

authors of that study emphasise that the results from these methods and the macroscopic examination are an essential prerequisite to direct the histopathologist to the relevant areas, and without them the histopathological process would be “almost impossible” [16].

#### 4.3. Court

Micro-CT being a non-destructive imaging technique provides helpful contextual images of the histopathological findings. Histology slides consist of thin, two-dimensional sections of only a portion of the overall specimen which makes them unsuitable to show certain features in relation to other injuries or general anatomical structures. This leads to histopathological expert witness testimony in court being largely verbal which makes it more difficult to follow and comprehend, especially for lay audience such as the jury [26]. Using imagery from the micro-CT scans contributed to support the expert testimony in court. In all three cases, the court presentation showed the entire ribcage as volume-rendering (sometimes called the 3D view although it is not fully three-dimensional) so it could be viewed from all angles. Each injury was highlighted as a region of interest (ROI) with different colour-coding for different fracture ages (Fig. 1). The information was directly based on the histopathology report and was used during trial to illustrate the oral expert witness testimony. This immediately showed how different injury sites relate to each other and gave an impression of the sequence of events. In two out of the three cases, there were fractures identified only on the micro-CT scans. They were included in the court presentation as a separate category highlighting the complementary nature of the two methods. This acknowledgement that no single method is perfect and that examining a specimen from different perspectives increases the accuracy of the overall results was an important step in educating the court about the value of different scientific examinations. While the benefit of three-dimensional models for understanding evidence has been realised by

several researchers [27,28], it is crucial to understand their potential biasing influence that comes with such a level of realism (Schofield 2007). The balance between benefits and bias is delicate and not fully understood yet, it is therefore important that such models are accompanied by suitable expert testimony.

#### 4.4. Further research

Overall, micro-CT has proven highly sensitive for detecting fractures. However, rib fractures can have many causes, including underlying conditions that affect the susceptibility of bone to damage, such as osteogenesis imperfecta or rickets [29]. Currently, histology is recommended for distinguishing between rachitic fractures and NAIs [30] but future research could use the added three-dimensional view of the bone structure to study these conditions, as has been the case for osteoporosis [31]. Another area of great research potential is the ageing of fractures using micro-CT. This assessment is currently also limited to histology but initial research into fracture ageing using radiology in general [32] and micro-CT in particular [25,33] has shown promising results. The scan data from the current study could form the basis for future work comparing the micro-CT appearance of differently dated injuries.

### 5. Conclusion

The comparison of the mini case series presented here has shown that micro-CT is highly sensitive in detecting paediatric rib fractures. While histology remains the gold standard, there is a strong indication from this analysis that the two methods, used in conjunction, can increase the overall fracture detection rate (by 22% in this study). This is because the examination of micro-CT scans has certain advantages over histological analysis namely the flexibility to non-destructively examine the complete 3D specimen microscopically at any necessary plane or view point. Further research would be

required to determine the reason for the histology false negatives. Given the importance of a complete and detailed fracture distribution, this observation is likely to carry a lasting impact in the forensic examination of paediatric suspected non-accidental injuries. Using the 3D views has also shown to be a helpful addition to the delivery of the expert witness testimony during the court trial in all three cases. Larger case series will be required to study a timeline for fracture healing and typical fracture patterns.

### CRedit authorship contribution statement

**Waltraud Baier:** Conceptualization, Methodology, Data acquisition, Data analysis, Writing, Editing. **Danielle G. Norman:** Methodology, Data analysis, Editing. **Mark A. Williams:** Conceptualization, Project administration, Editing.

### Declarations of interest

None.

### Acknowledgements

We would like to express our gratitude to Assistant Chief Constable Mark Payne and Ms Michelle Painter, both West Midlands Police, for their continuous support for this research project.

### References

- [1] C. Skellern, T. Donald, Suspicious childhood injury: formation of forensic opinion, *J. Paediatr. Child Health* 47 (2011) 771–775.
- [2] S. Betts, A Critical Analysis of Medical Opinion Evidence in Child Homicide Cases (Ph.D. thesis), University of New South Wales, 2013.
- [3] J. Robertson, Understanding how forensic science may contribute to miscarriages of justice, *Aust. J. Forensic Sci.* 45 (2) (2013) 109–112.
- [4] J.Y.Q. Mok, Non-accidental injury in children – an update, *Injury* 39 (2008) 978–985.
- [5] P. Jayakumar, M. Barry, M. Ramachandran, Orthopaedic aspects of paediatric non-accidental injury, *J. Bone Jt. Surg.* 92 (2) (2010) 189–195.
- [6] A.M. Kemp, F. Dunstan, S. Harrison, S. Morris, M. Mann, K. Rolfe, S. Datta, D. Thomas, J.R. Sibert, S. Maguire, Patterns of skeletal fractures in child abuse: systematic review, *Br. Med. J.* 367 (2008) 859–862.
- [7] S.P. Cadzow, K.L. Armstrong, Rib fractures in infants: red alert! The clinical features, investigations and child protection outcomes, *J. Paediatr. Child Health* 36 (2000) 322–326.
- [8] I. Barber, J.M. Perez-Rossello, C.R. Wilson, P.K. Kleinman, The yield of high-detail radiographic skeletal survey in suspected infant abuse, *Paediatr. Radiol.* 45 (2015) 69–80.
- [9] R.A. Bilo, S.G. Robben, R.R. van Rijn, *Forensic Aspects of Pediatric Fractures: Differentiating Accidental Trauma from Child Abuse*, Springer, Heidelberg, 2010.
- [10] S. Maguire, M. Mann, N. John, B. Ellaway, J.R. Sibert, A.M. Kemp, Does cardiopulmonary resuscitation cause rib fractures in children? A systematic review, *Child Abuse Negl.* 30 (2006) 739–751.
- [11] B. Stöver, Bildgebende Diagnostik der Kindesmisshandlung, *Der Radiol.* 47 (11) (2007) 1037–1050.
- [12] M.A. Weber, R.A. Risdon, A.C. Offiah, M. Malone, N.J. Sebire, Rib fracture identified at post-mortem examination in sudden unexpected deaths in infancy (SUDI), *Forensic Sci. Int.* 189 (2009) 75–81.
- [13] M.J. Worn, M.D. Jones, Rib fractures in infancy: establishing the mechanisms of cause from the injuries – a literature review, *Med. Sci. Law* 47 (3) (2007) 200–212.
- [14] E. Matshes, E. Lew, Two-handed cardiopulmonary resuscitation can cause rib fractures in infants, *Am. J. Forensic Med. Pathol.* 31 (4) (2010) 303–307.
- [15] J.A. Reyes, G.A. Somers, G.P. Taylor, D.A. Chiasson, Increased incidence of CPR-related rib fractures in infants—is it related to changes in CPR technique? *Resuscitation* 82 (2011) 545–548.
- [16] E. Raynor, P. Konala, A. Freemont, The detection of significant fractures in suspected infant abuse, *J. Forensic Leg. Med.* 60 (2018) 9–14.
- [17] W. Baier, C. Mangham, J.M. Warnett, M. Payne, M. Painter, M.A. Williams, Using histology to validate micro-CT findings of trauma in three post-mortem samples – first steps towards method validation, *Forensic Sci. Int.* 297 (2019) 27–34.
- [18] O.J. Arthurs, A.D. Calder, L. Kihō, A.M. Taylor, N.J. Sebire, Routine perinatal and paediatric post-mortem radiography: detection rates and implications for practice, *Paediatr. Radiol.* 44 (2014) 252–257.
- [19] J.C. Hutchinson, O.J. Arthurs, N.J. Sebire, Postmortem research: innovations and future directions for the perinatal and paediatric autopsy, *Arch. Dis. Child.: Educ. Pract.* 101 (2016) 54–56.
- [20] G. Pärtan, P. Pamberger, E. Blab, W. Hruby, Common tasks and problems in paediatric trauma radiology, *Eur. J. Radiol.* 48 (2003) 103–124.
- [21] T.S. Hong, J.A. Reyes, R. Moineddin, D.A. Chiasson, W.E. Berdon, P.S. Babyn, Value of postmortem thoracic CT over radiography in imaging pediatric rib fractures, *Pediatr. Radiol.* 41 (6) (2011) 736–748.
- [22] A.M. Christensen, M.A. Smith, D.S. Gleiber, D.L. Cunningham, D.J. Wescott, The use of X-ray computed tomography technologies in forensic anthropology, *Forensic Anthropol.* 1 (2) (2018) 124–140.
- [23] I. Prosser, S. Maguire, S.K. Harrison, M. Mann, J.R. Sibert, A.M. Kemp, How old is this fracture? Radiologic dating of fractures in children: a systematic review, *Am. J. Roentgenol.* 184 (4) (2005) 1282–1286.
- [24] D.L. Messer, B.H. Adler, F.W. Brink, H. Xiang, A.M. Agnew, Radiographic timelines for pediatric healing fractures: a systematic review, *Pediatr. Radiol.* 50 (2020) 1041–1048.
- [25] E.F. Morgan, Z.D. Mason, K.B. Chien, A.J. Pfeiffer, G.L. Barnes, T.A. Einhorn, L.C. Gerstenfeld, Micro-computed tomography assessment of fracture healing: relationships among callus structure, composition, and mechanical function, *Bone* 44 (2) (2009) 335–344.
- [26] M. Findlay, Juror comprehension and complexity, *Br. J. Criminol.* 41 (1) (2001) 56–76.
- [27] D. Errickson, T.J.U. Thompson, B.W.J. Rankin, The application of 3D visualization of osteological trauma for the courtroom: a critical review, *J. Forensic Radiol. Imaging* 2 (2014) 132–137.
- [28] S. Blau, E. Phillips, C. O'Donnell, G. Markowsky, Evaluating the impact of different formats in the presentation of trauma evidence in court: a pilot study, *Aust. J. Forensic Sci.* 51 (6) (2019) 695–704.
- [29] A. Sprigg, Radiological features of non-accidental skeletal injury, *Paediatr. Child Health* 18 (12) (2008) 554–560.
- [30] C. Kepron, M.S. Pollanen, Rickets or abuse? A histological comparison of rickets and child abuse-related fractures, *Forensic Sci. Med. Pathol.* 11 (2015) 78–87.
- [31] S. Körmendi, B. Vecsei, K. Orhan, C. Dobó-Nagy, Micro-CT in osteoporosis research, in: K. Orhan (Ed.), *Micro-computed Tomography (micro-CT) in Medicine and Engineering* (E-book), Springer, 2020, [https://doi.org/10.1007/978-3-030-16641-0\\_7](https://doi.org/10.1007/978-3-030-16641-0_7)
- [32] T.A. Pickett, The challenges of accurately estimating time of long bone injury in children, *J. Forensic Leg. Med.* 33 (2015) 105–110.
- [33] E. Wehrle, D.C. Tourolle, G.A. Kuhn, A.C. Scheuren, S. Hofmann, R. Müller, Evaluation of longitudinal time-lapsed in vivo micro-CT for monitoring fracture healing in mouse femur defect models, *Sci. Rep.* 7 (2019) 17445, <https://doi.org/10.1038/s41598-019-53822-x>