

Rho-Associated Kinase Inhibitor Eye Drop (Ripasudil) Transiently Alters the Morphology of Corneal Endothelial Cells

Naoki Okumura,¹ Yugo Okazaki,¹ Ryota Inoue,¹ Shinichiro Nakano,¹ Nigel J. Fullwood,² Shigeru Kinoshita,³ and Noriko Koizumi¹

¹Department of Biomedical Engineering, Faculty of Life and Medical Sciences, Doshisha University, Kyotanabe, Japan

²Biomedical and Life Sciences, School of Health and Medicine, Lancaster University, Lancaster, United Kingdom

³Department of Frontier Medical Science and Technology for Ophthalmology, Kyoto Prefectural University of Medicine, Kyoto, Japan

Correspondence: Noriko Koizumi, Department of Biomedical Engineering, Faculty of Life and Medical Sciences, Doshisha University, Kyotanabe 610-0321, Japan; nkoizumi@mail.doshisha.ac.jp.

Submitted: August 5, 2015

Accepted: October 28, 2015

Citation: Okumura N, Okazaki Y, Inoue R, et al. Rho-associated kinase inhibitor eye drop (ripasudil) transiently alters the morphology of corneal endothelial cells. *Invest Ophthalmol Vis Sci*. 2015;56:7560-7567. DOI:10.1167/iovs.15-17887

PURPOSE. Ripasudil (Glanatec), a selective Rho-associated coiled coil-containing protein kinase (ROCK) inhibitor, was approved in Japan in September 2014 for the treatment of glaucoma and ocular hypertension. The purpose of this study was to investigate the effect of ripasudil eye drops on corneal endothelial morphology, as ROCK signaling is known to modulate the actin cytoskeleton.

METHODS. Morphological changes in the corneal endothelium were evaluated in human subjects by specular and slit-lamp microscopy, following topical administration of ripasudil. We also used a rabbit model to evaluate the effect of ripasudil on clinical parameters of the corneal endothelium. Twenty-four hours after ripasudil application, corneal specimens were evaluated by phalloidin staining, immunohistochemical analysis, and electron microscopy.

RESULTS. Specular microscopy revealed morphological changes in human eyes, and slit-lamp microscopy showed guttae-like findings. The rabbit model showed morphological changes similar to those seen in human eyes after ripasudil administration. Electron microscopy demonstrated that these alterations are due to the formation of protrusions along the cell-cell borders, but this formation is transient. Expression of corneal endothelial function-related markers was not disrupted; corneal thickness and corneal volume were not changed; and no cell death was observed following ripasudil administration.

CONCLUSIONS. Ripasudil induces transient guttae-like findings in humans, most likely due to protrusion formation along intracellular borders caused by the reduction in actomyosin contractility of the corneal endothelial cells. No severe adverse effects were observed. Physicians should be aware that ROCK inhibitors can cause these guttae-like findings, to avoid misdiagnosing patients as having Fuchs endothelial corneal dystrophy. (www.umin.ac.jp/ctr number, UMIN000018340.)

Keywords: ROCK inhibitor, ripasudil, corneal endothelial cells

Glaucoma, a progressive optic neuropathy, causes visual field loss and is one of the major causes of secondary blindness.^{1,2} Research confirms that the progression of visual field loss due to glaucomatous optic neuropathy is suppressed by reducing intraocular pressure (IOP); consequently, the main goal of glaucoma treatment is to reduce IOP.^{3,4} A number of pharmaceutical agents, such as prostaglandin analogues, β -blockers, carbonic anhydrase inhibitors, and α 2-agonists, are used in clinical settings, but IOP is not well controlled by the currently available drugs in a certain number of patients.⁴ Development of new therapeutic agents therefore remains eagerly anticipated.

Rho-associated coiled coil-containing protein kinase (ROCK) inhibitors and other drugs that modulate the actin cytoskeleton are reported to reduce IOP by promoting aqueous humor outflow through the trabecular meshwork.⁵⁻¹² A selective ROCK inhibitor, Y27632, altered the distribution of actin stress fibers and cell-substrate adhesion of cultured trabecular

meshwork and Schlemm's canal cells.^{8,10,13} Topical administration of ROCK inhibitor eye drops also reduced IOP in rabbit and monkey models by increasing the outflow capacity,^{8,14} a unique mechanism among conventional IOP-lowering drugs.^{8,9,15} In addition, a clinical study demonstrated that the ROCK inhibitors SNJ-1656 (Y39983)^{16,17} and AR-12286¹⁸ reduced IOP in healthy volunteers, as well as in patients with glaucoma and ocular hypertension.

Ripasudil (GLANATEC), a selective ROCK inhibitor, was approved in Japan in September 2014 for the treatment of glaucoma and ocular hypertension.¹⁵ Ripasudil exhibited IOP-lowering effects in rabbits and monkeys,¹⁹ and phase 1 clinical trials showed that ripasudil reduced IOP in healthy adult volunteers.²⁰ In addition, randomized clinical studies showed that 0.4% ripasudil reduced IOP in patients with primary open-angle glaucoma and ocular hypertension.²¹

Wato et al.²² observed morphological changes in the corneal endothelium by noncontact specular microscopy following

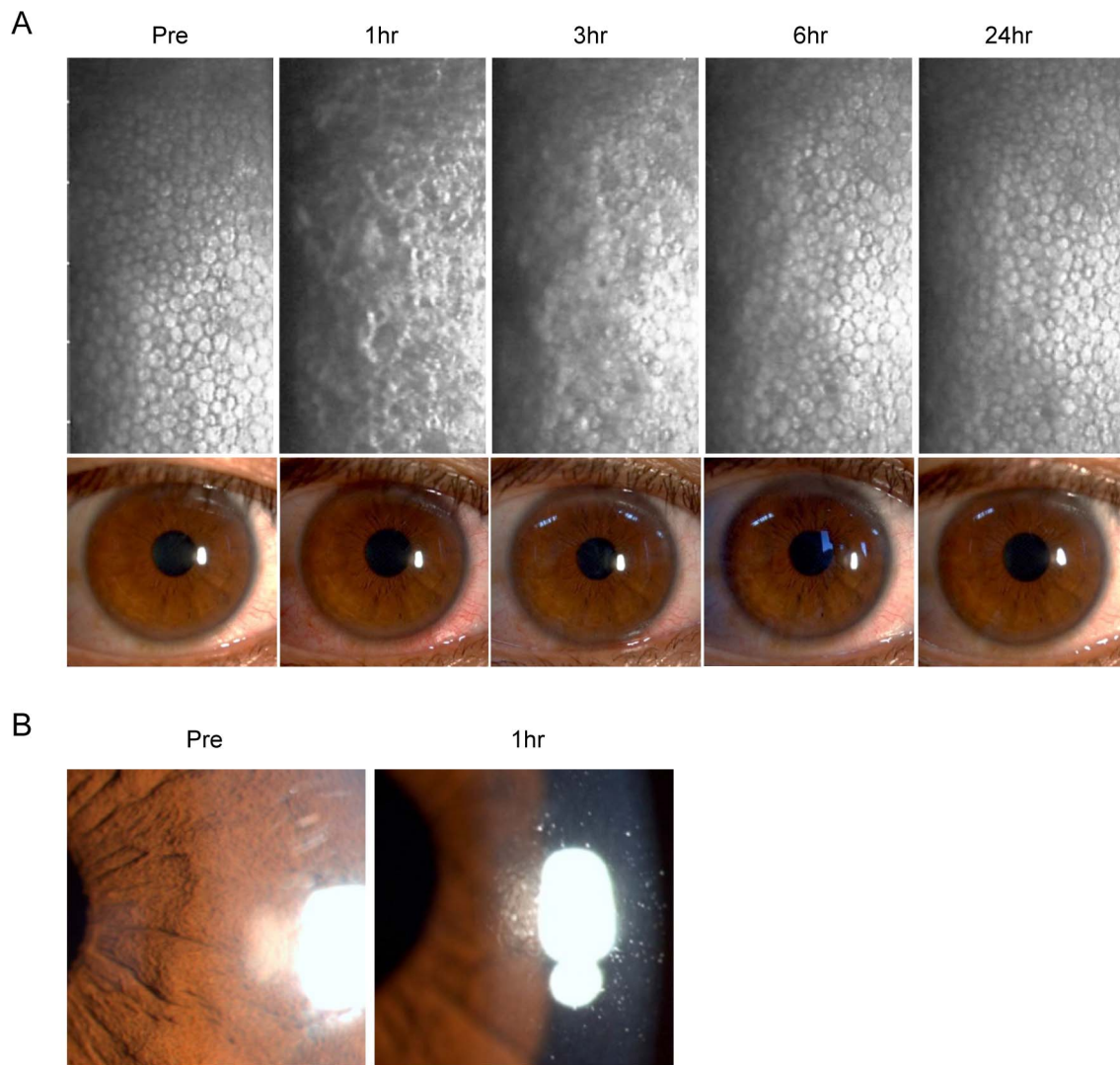


FIGURE 1. Pseudo guttae-like morphological changes in human corneal endothelium induced by ripasudil eye drops. **(A)** Noncontact specular microscopy image and slit-lamp photograph of a healthy subject administered one drop of 0.4% ripasudil. **(B)** Slit-lamp photograph demonstrating pseudo guttae of healthy subject 1 hour after topical administration of 0.4% ripasudil.

instillation of ripasudil in cynomolgus monkeys; however, the reasons for these changes are not yet well elucidated. The corneal endothelium is a nonregenerative tissue, and severe damage can cause vision loss due to corneal edema.²³ Therefore, further investigation is required to evaluate this effect of ripasudil eye drops on the corneal endothelium. The aim of the current study was to perform a pathological investigation of corneal endothelial cells (CECs) to elucidate how ripasudil administration induces the observed morphological changes in the corneal endothelium.

MATERIALS AND METHODS

Ethics Statement

Animals were housed and treated in accordance with the ARVO Statement for the Use of Animals in Ophthalmic and Vision Research. The rabbit experiments were performed at Doshisha University (Kyoto, Japan), according to the protocol approved by that university's Animal Care and Use Committee (Approval No. 0831). The human data were obtained in accordance with the tenets set forth in the Declaration of Helsinki.

Ripasudil Administration in Human Subjects

The effect of ripasudil eye drops (GLANATEC ophthalmic solution 0.4%; Kowa Company, Ltd., Nagoya, Japan) on corneal endothelium was examined in two human subjects (46-year-old female and 38-year-old male) who had no corneal diseases. Each was administered one drop of ripasudil to the right eye, and the corneal endothelium was observed by noncontact specular microscopy and slit-lamp microscopy at specific time points: before administration and 1, 3, 6, and 24 hours after a single dose of ripasudil. This study was performed according to a protocol approved by the Institutional Review Board of Doshisha University. Clinical trial registration was obtained from UMIN UMIN000018340 (<http://www.umin.ac.jp/english/>).

Ripasudil Administration in a Rabbit Model

A single dose of ripasudil was administered into the right eyes of nine rabbits. Anterior segments and corneal endothelium were evaluated by slit-lamp microscopy and contact specular microscope (Konan scanning slit specular microscope; Konan Medical, Nishinomiya, Japan) for 24 hours. Corneal thickness,

corneal volume, and corneal refractive power were evaluated with a Pentacam (OCULUS Optikgeräte GmbH, Wetzlar, Germany). Intraocular pressure was determined with a Tonovet (icare Finland, Vantaa, Finland) ($n = 5$). Corneal specimens obtained from four rabbits were used for analysis by scanning electron microscopy and transmission electron microscopy. For repeated-dose administration, ripasudil was administered into the right eye of three rabbits twice daily for 7 days, and the corneal endothelium was evaluated by contact specular microscopy and histological analysis.

Fluorescent Staining

Rabbit corneal specimens were fixed in 4% formaldehyde and incubated for 30 minutes at room temperature in 1% bovine serum albumin (BSA) to block nonspecific binding. The actin fibers were evaluated by examining the corneas after actin staining with a 1:400 dilution of Alexa Fluor 488-conjugated phalloidin (Life Technologies Corp., Carlsbad, CA, USA). The effect on function-related proteins was investigated by immunohistochemical analyses of ZO-1, N-cadherin, and Na^+/K^+ -ATPase using primary antibodies against Zona Occludens 1 (ZO-1; 1:200; Zymed Laboratories, South San Francisco, CA, USA), N-cadherin (1:200, Zymed Laboratories), and Na^+/K^+ -ATPase (1:200; Upstate Biotechnology, Lake Placid, NY, USA). Alexa Fluor 488-conjugated goat anti-mouse (Life Technologies Corp.) was used as a secondary antibody at a 1:1000 dilution.

The effect of ripasudil on cell death was examined in corneas obtained from five rabbits 24 hours after administration of ripasudil. The specimens were stained with annexin V and propidium iodide (PI) by incubating with annexin V-fluorescein isothiocyanate (FITC; 1:200; Zymed Laboratories) and PI (1:200, Zymed Laboratories) for 30 minutes at 37°C, followed by fixation in 4% formaldehyde. As a positive control, 10 μM staurosporine was injected into anterior chamber in two rabbits and corneas were recovered after 24 hours. Nuclei were stained with 4',6-diamidino-2-phenylindole (DAPI) (Vector Laboratories, Burlingame, CA, USA). The slides were examined with a fluorescence microscope (TCS SP2 AOBS; Leica Microsystems, Wetzlar, Germany).

Scanning Electron Microscopy

The effect of ripasudil on corneal endothelial morphology was evaluated in corneal specimens obtained from four rabbits at 1, 3, and 24 hours after a single dose of ripasudil or control. Excised corneas were fixed in 2.5% glutaraldehyde and 2% paraformaldehyde in 0.1 M Sørensen buffer (pH 7.2–7.4) for at least 3 hours at room temperature. The samples were washed in the buffer, postfixed with 1% aqueous osmium tetroxide, dehydrated through an ascending ethanol series, and transferred to hexamethyldisilazane (HMDS) (Agar Scientific, Stansted, UK), which was allowed to sublimate off. The samples were mounted on stubs, sputter-coated with gold, and examined by scanning electron microscopy (model 5600; JEOL Ltd., Tokyo, Japan).

Transmission Electron Microscopy

Corneal specimens were obtained from four rabbits at 1, 3, and 24 hours after a single dose of ripasudil or control. The samples were washed in 0.1 M Sørensen buffer, fixed with 2.5% glutaraldehyde and 2% paraformaldehyde in 0.1 M Sørensen buffer, and postfixed with 1% osmium tetroxide. After dehydration in an ascending ethanol series and acetone, the samples were infiltrated and embedded in epoxy resin. Ultrathin sections were collected on uncoated copper grids and double stained with uranyl acetate and lead. Sections were

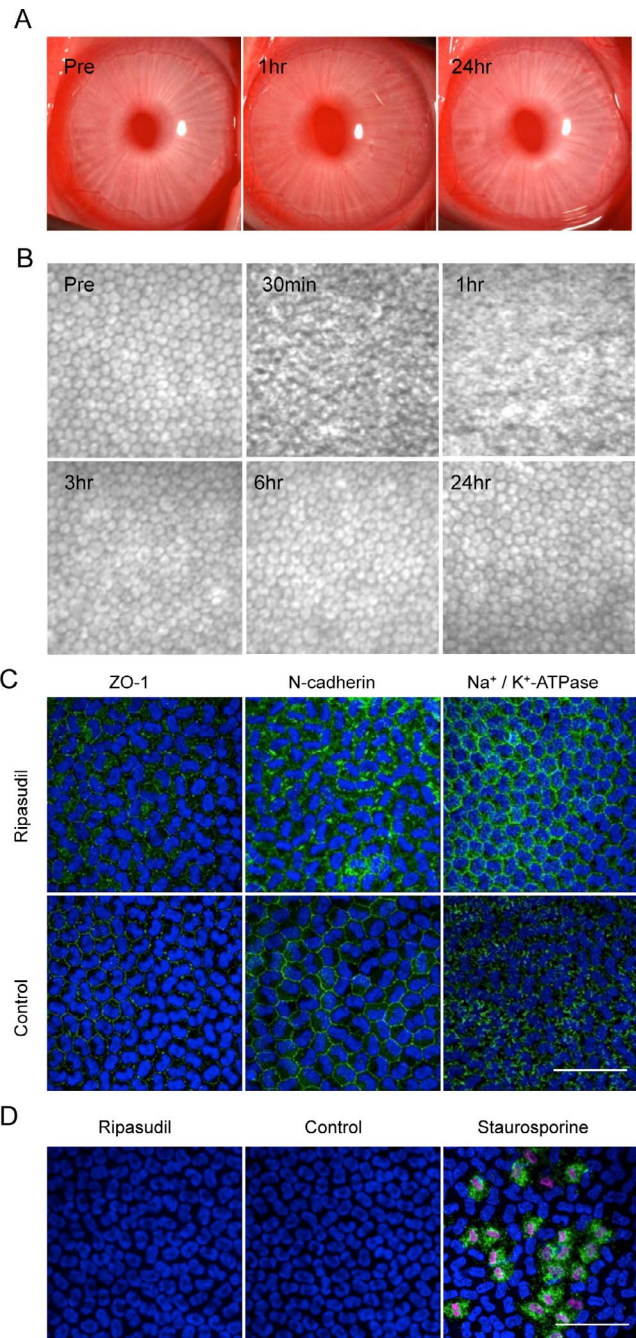


FIGURE 2. Slit-lamp microscopy, contact specular microscopy, and histological evaluation of rabbit corneal endothelium after single-dose administration of ripasudil eye drops. (A) 0.4% ripasudil was administered topically as an eye drop in five rabbits, followed by slit-lamp microscopy evaluation. (B) Endothelial morphology was evaluated by contact specular microscopy after administration of 0.4% ripasudil. Representative images obtained from five independent rabbits are shown. (C) Corneas recovered from five rabbits 24 hours after administration of 0.4% ripasudil were stained with phalloidin. Expression of the function-related proteins ZO-1, N-cadherin, and Na^+/K^+ -ATPase was also evaluated by immunofluorescence staining. Nuclei were stained with DAPI. Scale bar: 50 μm . (D) To evaluate the effect of ripasudil, corneas from five rabbits recovered 24 hours after administration of 0.4% ripasudil were stained with annexin V and PI. Staurosporine was injected into the anterior chamber to induce apoptosis as a positive control. Nuclei were stained with DAPI. Scale bar: 50 μm .

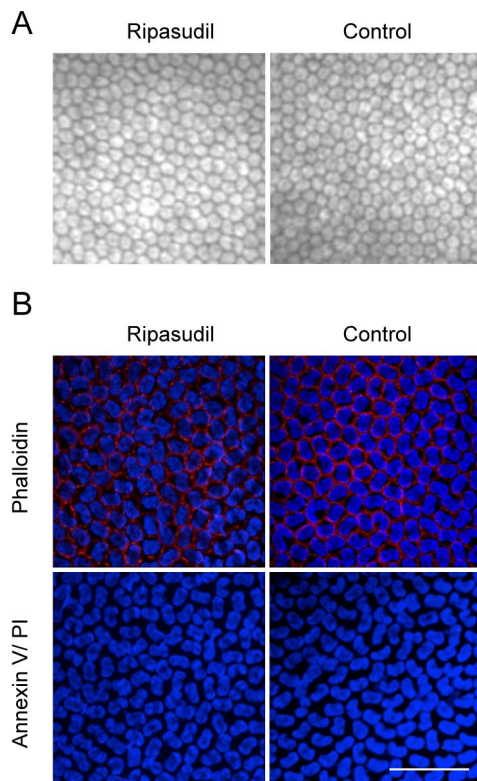


FIGURE 3. The effect of repeated-dose administration of 0.4% ripasudil on rabbit corneal endothelium. (A) For repeated-dose administration, 0.4% ripasudil was administered twice daily for 7 days in three rabbits, and the corneal endothelium was examined by contact specular microscopy. (B) To evaluate cell morphology, the corneal endothelium was stained with phalloidin. Annexin V and PI staining was performed to evaluate the effect of ripasudil on corneal endothelial cell death. Nuclei were stained with DAPI. Scale bar: 50 μ m.

examined with a transmission electron microscope (JEM-1400Plus; JEOL Ltd.) equipped with a charge-coupled device camera.

Statistical Analysis

The Student's *t*-test was used to determine statistical significance (*P* value) of differences between mean values of the two-sample comparison. Results are expressed as mean \pm SEM.

RESULTS

Effect of Ripasudil Eye Drops on Corneal Endothelium in Human Subjects

Noncontact specular microscopy demonstrated an indistinct cell border after 1 hour. The cell border was still slightly indistinct after 3 hours and was distinct once again by 6 hours; no pathological changes, such as distinct cell borders and cell loss, were observed at 24 hours after administration (Fig. 1A). Conjunctival injection, which was previously reported as a possible adverse effect of ROCK inhibitors, was observed coincident to the morphological changes in the corneal endothelium at 3 hours (Fig. 1A). A guttae-like appearance of the cornea was observed by slit-lamp microscopy after 1 to 3 hours of treatment, but this resolved within 24 hours (Fig. 1B). These changes were observed similarly in both human subjects.

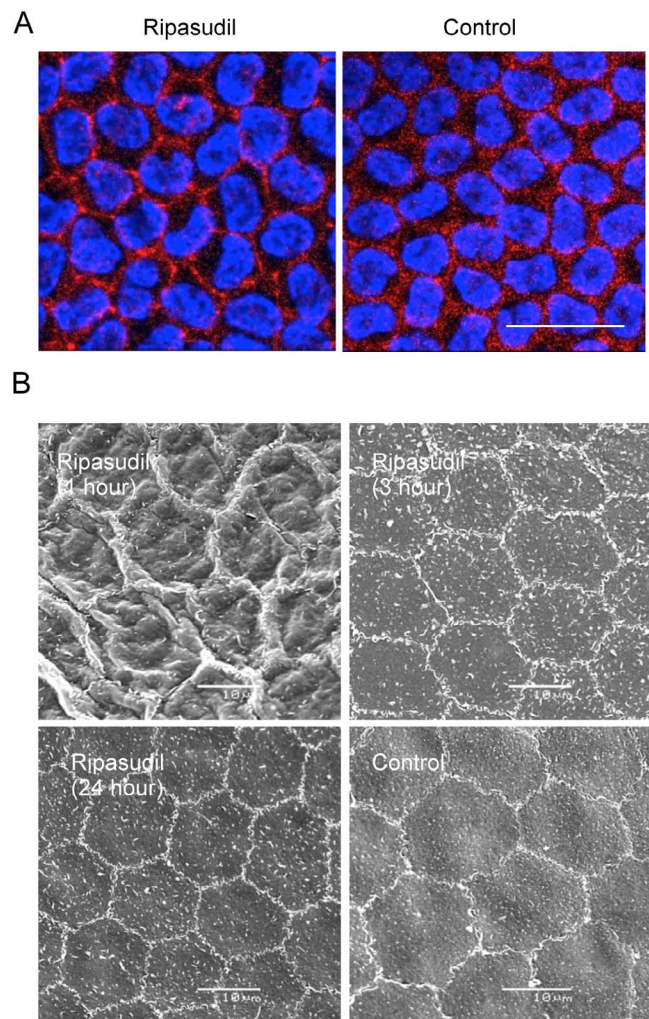


FIGURE 4. Morphological evaluation of rabbit corneal endothelium after treatment with ripasudil eye drops. (A) 0.4% ripasudil was topically administered to the rabbit eye, and 1 hour after treatment the cornea and control cornea were recovered. Actin fibers were stained by phalloidin. Scale bar: 50 μ m. (B) Corneas were recovered from rabbits 1, 3, and 24 hours after administering a single dose of 0.4% ripasudil. Rabbit corneal endothelium was evaluated by scanning electron microscopy. Images were representative of two independent rabbits for every time point. Scale bar: 10 μ m.

Effect of Ripasudil Eye Drops on Rabbit Corneal Endothelium

A histological analysis of corneal endothelium following treatment with ripasudil was conducted on a rabbit model. Slit-lamp microscopy showed no severe adverse corneal effects such as corneal edema, but contact specular microscopy showed that the cell border of the corneal endothelium became indistinct by 30 minutes to 1 hour after dosing (Figs. 2A, 2B). Similar to the finding in human subjects, it recovered within 3 to 6 hours, and no morphological changes or cell losses were observed 24 hours after administration. At 24 hours after administration, the expression of the function-related proteins ZO-1 (tight junction), N-cadherin (adherence junction), and Na⁺/K⁺-ATPase (pump function) was well preserved in the normal phenotypes (Fig. 2C). Annexin V and PI staining showed no induction of apoptosis or cell death by ripasudil administration (Fig. 2D). Ripasudil administration twice daily for 7 days in the rabbit model caused no

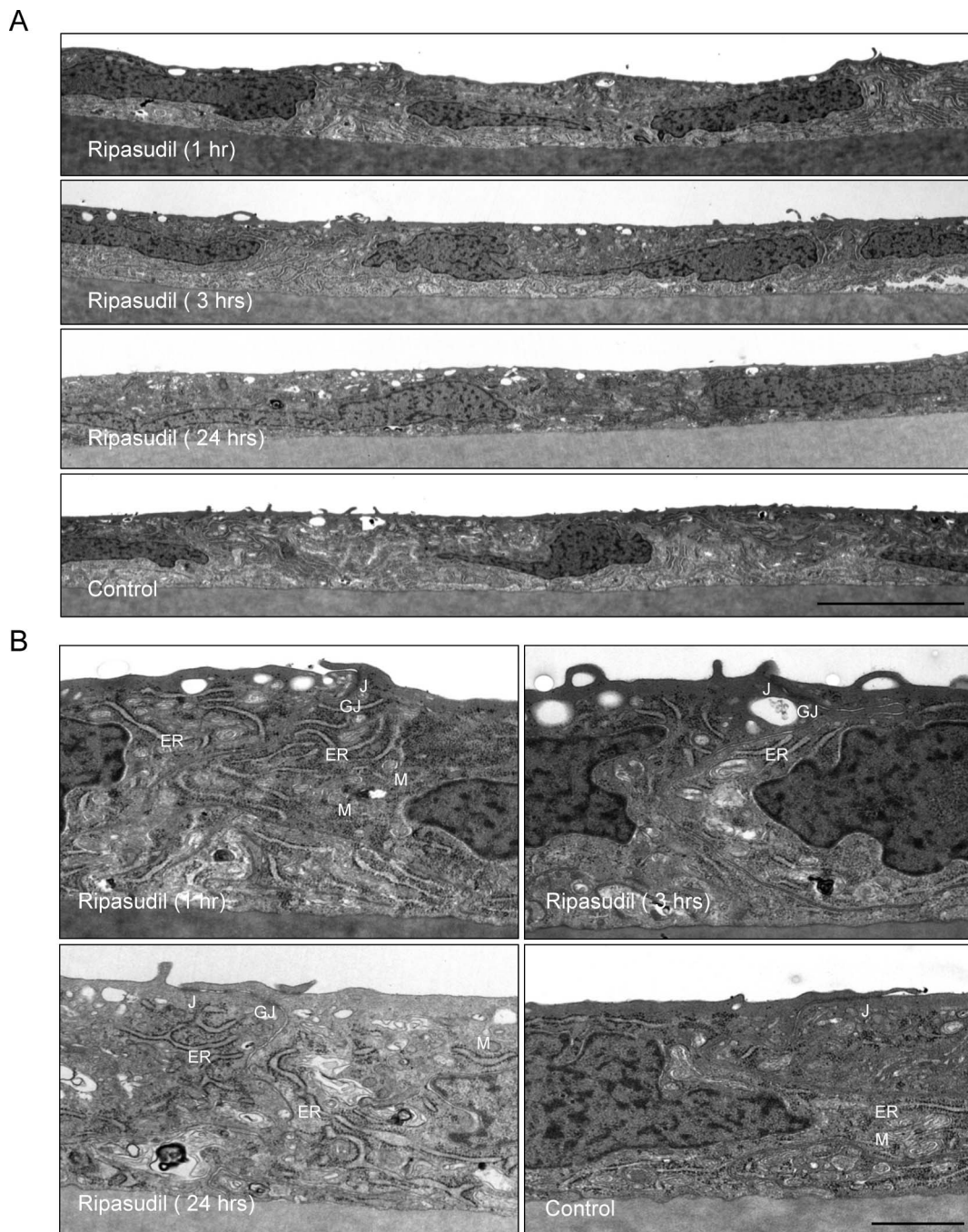


FIGURE 5. Transmission electron microscopy of rabbit corneal endothelium after treatment with ripasudil eye drops. (**A**, **B**) Corneas administered ripasudil were recovered after 1, 3, and 24 hours. Rabbit corneal endothelium was then evaluated by transmission electron microscopy. Images are representative of two independent rabbits for every time point. J, intact junctional complexes (tight junction and adherens junction); GJ, gap junction; M, mitochondria; ER, endoplasmic reticulum. Scale bars: 5 μ m (**A**); 1 μ m (**B**).

morphological changes, as determined by contact specular microscopy (Fig. 3A) and phalloidin staining (Fig. 3B). In addition, no annexin V- and PI-positive cells were observed (Fig. 3B).

The ROCK inhibitors regulate the actin cytoskeleton, so we next examined the expression pattern of actin in the corneal endothelium. Phalloidin staining revealed a distribution of actin fibers at the cell cortex in both ripasudil-treated and control eyes, and no obvious differences were observed 24 hours after administration (Fig. 4A). However, scanning electron microscopy demonstrated the formation of protrusions along the cell

borders, which recovered by 3 hours (Fig. 4B). Transmission electron microscopy also revealed the formation of protrusions at the cell border of the corneal endothelium, which also reverted to the control level within 24 hours (Fig. 5A). Tight junctions, adherence junctions, and gap junctions were present, even at 1 hour when specular microscopy revealed indistinct cell borders, and retention of adhesion on Descemet's membrane was unchanged (Fig. 5B). Organelles such as mitochondria and endoplasmic reticulum were unaltered morphologically by ripasudil administration throughout the 24-hour study.

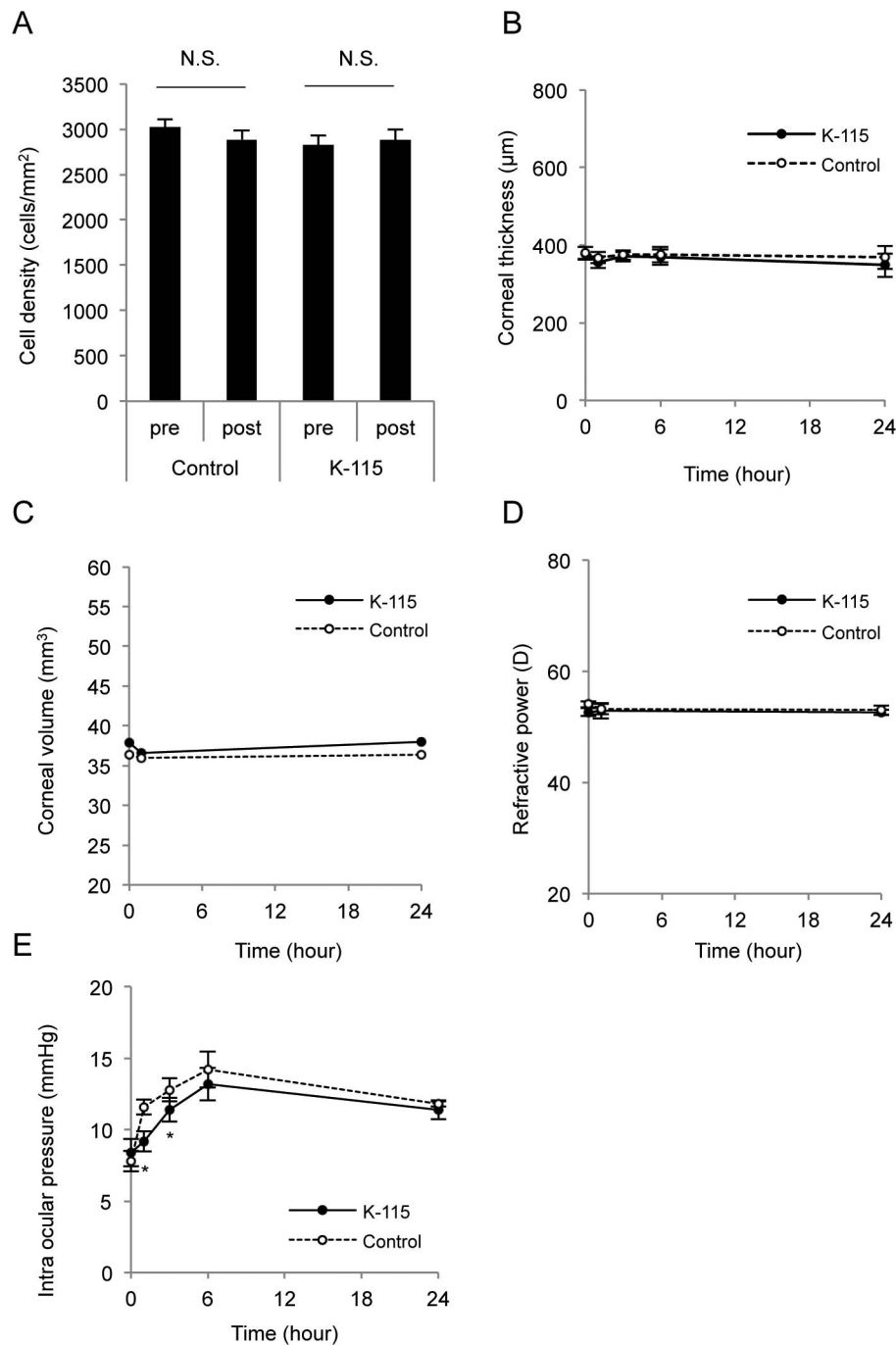


FIGURE 6. Evaluation of rabbit clinical parameters after treatment with ripasudil eye drops. (A) 0.4% ripasudil was administered topically as an eye drop in the right eyes of five rabbits, and corneal endothelial cell density was evaluated by contact specular microscopy after 24 hours. (B) Corneal thickness of rabbit after ripasudil administration was evaluated with an ultrasound pachymeter. (C, D) The effect of ripasudil on corneal volume and refractive power was evaluated by Pentacam. (E) Intraocular pressure of rabbits was measured by Tonovet after treatment with 0.4% ripasudil. * $P < 0.01$.

We next evaluated the clinical parameters in the rabbit model that undergo changes if corneal endothelial function is damaged. Corneal endothelial cell density, determined by contact specular microscopy, was not decreased by ripasudil (Fig. 6A). Corneal thickness and corneal volume, which are maintained by the barrier and pump functions of the corneal endothelium, were not significantly changed by ripasudil (Figs. 6B, 6C). The lack of any significant changes in refractive power also demonstrated that corneal shape was preserved, despite the formation of protrusions at the cell border (Fig. 6D). The

IOP was significantly lower at 1 and 3 hours after treatment, showing the effect of ripasudil against glaucoma (Fig. 6E).

DISCUSSION

The ROCK isoforms ROCK1 and ROCK2 were originally discovered as a target of the small Guanosine-5'-triphosphate (GTP)-binding protein RhoA.²⁴ The Rho-binding domain within the coiled-coil region of ROCK was identified, but subsequent

research revealed that several molecules activate or inhibit ROCK via multiple contact points.²⁵⁻²⁸ ROCK mediates various important cellular functions, such as cell shape, motility, adhesion, and proliferation.²⁴ Active Rho-GTP binds to ROCK and increases the phosphorylation of a number of downstream target proteins, such as myosin light chain (MLC), Lin-11/Isl-1/Mec-3 kinase (LIMK), and MLC phosphatase complex of type 1 (MYPT1). This is followed by stabilization of filamentous actin and an increase in the actin-myosin contractile force.^{24,29} ROCK has attracted the interest of researchers as a potential therapeutic target for various diseases, such as cancer, neuronal degenerative disease, asthma, cardiovascular disease, and hypertension, as well as glaucoma.^{28,30} In fact, fasudil was approved in Japan and China for the treatment of cerebral vasospasm in 1995.²⁸ To our knowledge, ripasudil is the first approved ROCK inhibitor eye drop for the treatment of glaucoma and ocular hypertension.¹⁵

Ripasudil is anticipated to alter cytoskeletal contraction of the trabecular meshwork and Schlemm's canal cells to increase outflow of aqueous humor^{15,16,19}; therefore, several types of ocular cells can be affected. For instance, the high occurrence of hyperemia is a common symptom after topical administration of ROCK inhibitors.^{14,16,18} Coincidentally, slight to mild conjunctival hyperemia was observed in more than half of the participants in ripasudil clinical trials.^{20,21} This hyperemia is thought to arise because of conjunctival vessel dilation due to alteration of vascular endothelial cells.¹⁶ However, the hyperemia was transient, and no conjunctival hemorrhage, which occurred in animal experiments,¹⁴ was observed in the clinical studies, suggesting the safety of ripasudil eye drops.³¹

In this study, we showed that ripasudil eye drops caused morphological changes in the corneal endothelium as observed by noncontact specular microscopy. Of importance, this change was also recognized as guttae-like findings by slit-lamp microscopy. Guttae are collagenous excrescences of the corneal endothelial basement membrane (Descemet's membrane) and are observed in as many as 5% of the population aged over 40.³² They are also typical features of Fuchs endothelial corneal dystrophy.³³ To avoid misdiagnosing a patient as having Fuchs endothelial corneal dystrophy, physicians should be aware that guttae-like findings can be caused by ROCK inhibitor eye drops.

We investigated these guttae-like findings further using the rabbit model and demonstrated that they are induced by the formation of mild protrusions along the cell-cell borders. Protrusion formation is considered an effect of ripasudil, because ROCK inhibitors modulate the actin cytoskeleton in various types of cells. We have also reported that ROCK inhibitors alter the cell morphology of cultured CECs.³⁴ A pharmacodynamics study revealed that ripasudil has high intraocular permeability and that it penetrates into all eye tissues except the lens,¹⁹ suggesting that ripasudil affects the corneal endothelium. Tian and his colleagues⁷ reported that intracameral infusion of H-7 to monkey eyes induced morphological change in the corneal endothelium, observed by specular microscopy, and membrane ruffling along the intracellular borders, as observed by SEM.⁷ H-7 is a serine-threonine kinase inhibitor that inhibits actomyosin contractility and eventually produces cellular relaxation.^{5-7,35} Taken together, alteration of corneal endothelium borders by ripasudil and other actin cytoskeleton-modulating drugs is suggested to be a common feature of these drugs.

The corneal endothelium is essential for maintaining corneal clarity via its barrier function that suppresses the overflow of aqueous humor into the corneal stroma. Transmission electron microscopy demonstrated that tight junctions, adherence junctions, and gap junctions were present 1 hour after ripasudil administration, and the corneal thickness

and volume were unchanged. This suggests that the barrier function of the corneal endothelium was not disrupted. ROCK inhibitors can change the localization of junctional proteins and increase the permeability of Schlemm's canal,¹¹ but this difference may be explained by the fact that the effects of ROCK inhibitors depend on the cell types.²⁸ One remaining question is the effect of long-term use of ripasudil eye drops on the corneal endothelium in clinical settings. We have shown that morphological changes are transient in this animal model, but careful evaluation in human patients is needed.

In conclusion, we have demonstrated that ripasudil induces transient guttae-like findings in humans, most likely due to protrusion formation along intracellular borders caused by the reduction in actomyosin contractility of the CECs. Physicians should appreciate that ROCK inhibitors can cause these guttae-like findings in order to avoid misdiagnosing patients as having Fuchs endothelial corneal dystrophy.

Acknowledgments

The authors thank Masato Asahiyama and Keisuke Itagaki for technical support for transmission electron microscopy.

Supported by Program for the Strategic Research Foundation at Private Universities from MEXT (NK, NO).

Disclosure: **N. Okumura**, None; **Y. Okazaki**, None; **R. Inoue**, None; **S. Nakano**, None; **N.J. Fullwood**, None; **S. Kinoshita**, None; **N. Koizumi**, None

References

1. Quigley HA, Broman AT. The number of people with glaucoma worldwide in 2010 and 2020. *Br J Ophthalmol*. 2006;90:262-267.
2. Tham YC, Li X, Wong TY, Quigley HA, Aung T, Cheng CY. Global prevalence of glaucoma and projections of glaucoma burden through 2040: a systematic review and meta-analysis. *Ophthalmology*. 2014;121:2081-2090.
3. The Advanced Glaucoma Intervention Study (AGIS): 7. The relationship between control of intraocular pressure and visual field deterioration. The AGIS Investigators. *Am J Ophthalmol*. 2000;130:429-440.
4. Kass MA, Heuer DK, Higginbotham EJ, et al. The Ocular Hypertension Treatment Study: a randomized trial determines that topical ocular hypotensive medication delays or prevents the onset of primary open-angle glaucoma. *Arch Ophthalmol*. 2002;120:701-713, discussion 829-830.
5. Tian B, Kaufman PL, Volberg T, Gabelt BT, Geiger B. H-7 disrupts the actin cytoskeleton and increases outflow facility. *Arch Ophthalmol*. 1998;116:633-643.
6. Tian B, Gabelt BT, Peterson JA, Kiland JA, Kaufman PL. H-7 increases trabecular facility and facility after ciliary muscle disinsertion in monkeys. *Invest Ophthalmol Vis Sci*. 1999;40:239-242.
7. Tian B, Sabanay I, Peterson JA, Hubbard WC, Geiger B, Kaufman PL. Acute effects of H-7 on ciliary epithelium and corneal endothelium in monkey eyes. *Curr Eye Res*. 2001;22:109-120.
8. Honjo M, Tanihara H, Inatani M, et al. Effects of rho-associated protein kinase inhibitor Y27632 on intraocular pressure and outflow facility. *Invest Ophthalmol Vis Sci*. 2001;42:137-144.
9. Rao PV, Deng P, Sasaki Y, Epstein DL. Regulation of myosin light chain phosphorylation in the trabecular meshwork: role in aqueous humour outflow facility. *Exp Eye Res*. 2005;80:197-206.
10. Koga T, Koga T, Awai M, Tsutsui J, Yue BY, Tanihara H. Rho-associated protein kinase inhibitor, Y27632, induces alterations in adhesion, contraction and motility in cultured human trabecular meshwork cells. *Exp Eye Res*. 2006;82:362-370.

11. Kameda T, Inoue T, Inatani M, et al. The effect of Rho-associated protein kinase inhibitor on monkey Schlemm's canal endothelial cells. *Invest Ophthalmol Vis Sci.* 2012;53:3092-3103.
12. Inoue T, Tanihara H. Rho-associated kinase inhibitors: a novel glaucoma therapy. *Prog Retin Eye Res.* 2013;37:1-12.
13. Rao PV, Deng PF, Kumar J, Epstein DL. Modulation of aqueous humor outflow facility by the Rho kinase-specific inhibitor Y-27632. *Invest Ophthalmol Vis Sci.* 2001;42:1029-1037.
14. Tokushige H, Inatani M, Nemoto S, et al. Effects of topical administration of y-39983, a selective rho-associated protein kinase inhibitor, on ocular tissues in rabbits and monkeys. *Invest Ophthalmol Vis Sci.* 2007;48:3216-3222.
15. Garnock-Jones KP. Ripasudil: first global approval. *Drugs.* 2014;74:2211-2215.
16. Tanihara H, Inatani M, Honjo M, Tokushige H, Azuma J, Araie M. Intraocular pressure-lowering effects and safety of topical administration of a selective ROCK inhibitor, SNJ-1656, in healthy volunteers. *Arch Ophthalmol.* 2008;126:309-315.
17. Inoue T, Tanihara H, Tokushige H, Araie M. Efficacy and safety of SNJ-1656 in primary open-angle glaucoma or ocular hypertension. *Acta Ophthalmol.* 2015;93:e393-e395.
18. Williams RD, Novack GD, van Haarlem T, Kocpozynski C. Ocular hypotensive effect of the Rho kinase inhibitor AR-12286 in patients with glaucoma and ocular hypertension. *Am J Ophthalmol.* 2011;152:834-841, e831.
19. Isobe T, Mizuno K, Kaneko Y, Ohta M, Koide T, Tanabe S. Effects of K-115, a rho-kinase inhibitor, on aqueous humor dynamics in rabbits. *Curr Eye Res.* 2014;39:813-822.
20. Tanihara H, Inoue T, Yamamoto T, Kuwayama Y, Abe H, Araie M. Phase 1 clinical trials of a selective Rho kinase inhibitor, K-115. *JAMA Ophthalmol.* 2013;131:1288-1295.
21. Tanihara H, Inoue T, Yamamoto T, Kuwayama Y, Abe H, Araie M. Phase 2 randomized clinical study of a Rho kinase inhibitor, K-115, in primary open-angle glaucoma and ocular hypertension. *Am J Ophthalmol.* 2013;156:731-736.
22. Wato E, Omichi K, Yoneyama S, Tanaka M, Kagawa M, Amano Y. Safety evaluation of morphological changes in corneal endothelial cells induced by K-115 in cynomolgus monkeys. *Fundam Toxicol Sci.* 2014;1:39-47.
23. Tan DT, Dart JK, Holland EJ, Kinoshita S. Corneal transplantation. *Lancet.* 2012;379:1749-1761.
24. Riento K, Ridley AJ. Rocks: multifunctional kinases in cell behaviour. *Nat Rev Mol Cell Biol.* 2003;4:446-456.
25. Sebbagh M, Renvoize C, Hamelin J, Riche N, Bertoglio J, Breard J. Caspase-3-mediated cleavage of ROCK I induces MLC phosphorylation and apoptotic membrane blebbing. *Nat Cell Biol.* 2001;3:346-352.
26. Coleman ML, Sahai EA, Yeo M, Bosch M, Dewar A, Olson MF. Membrane blebbing during apoptosis results from caspase-mediated activation of ROCK I. *Nat Cell Biol.* 2001;3:339-345.
27. Blumenstein L, Ahmadian MR. Models of the cooperative mechanism for Rho effector recognition: implications for RhoA-mediated effector activation. *J Biol Chem.* 2004;279:53419-53426.
28. Olson MF. Applications for ROCK kinase inhibition. *Curr Opin Cell Biol.* 2008;20:242-248.
29. Scott RW, Olson MF. LIM kinases: function, regulation and association with human disease. *J Mol Med (Berl).* 2007;85:555-568.
30. Liao JK, Seto M, Noma K. Rho kinase (ROCK) inhibitors. *J Cardiovasc Pharmacol.* 2007;50:17-24.
31. Tanihara H, Inoue T, Yamamoto T, et al. Intra-ocular pressure-lowering effects of a Rho kinase inhibitor, ripasudil (K-115), over 24 hours in primary open-angle glaucoma and ocular hypertension: a randomized, open-label, crossover study. *Acta Ophthalmol.* 2015;93:e254-e260.
32. Lorenzetti DW, Uotila MH, Parikh N, Kaufman HE. Central cornea guttata. Incidence in the general population. *Am J Ophthalmol.* 1967;64:1155-1158.
33. Zhang J, Patel DV. The pathophysiology of Fuchs' endothelial dystrophy—a review of molecular and cellular insights. *Exp Eye Res.* 2015;130:97-105.
34. Okumura N, Ueno M, Koizumi N, et al. Enhancement on primate corneal endothelial cell survival in vitro by a ROCK inhibitor. *Invest Ophthalmol Vis Sci.* 2009;50:3680-3687.
35. Birrell GB, Hedberg KK, Hablison DL, Griffith OH. Protein kinase C inhibitor H-7 alters the actin cytoskeleton of cultured cells. *J Cell Physiol.* 1989;141:74-84.