

---

# Innovation in prediction planning for anterior open bite correction

Mohammed Almuzian, Anas Almukhtar, Michael O'Neil, Philip Benington, Thamer Al Anezi and Ashraf Ayoub

University of Glasgow, MVLS College, Glasgow Dental Hospital & School, Glasgow, UK

*Abstract:* This study applies recent advances in 3D virtual imaging for application in the prediction planning of dentofacial deformities. Stereo-photogrammetry has been used to create virtual and physical models, which are creatively combined in planning the surgical correction of anterior open bite. The application of these novel methods is demonstrated through the surgical correction of a case.

(Aust Orthod J 2015; 31: XXXX)

Received for publication: June 2014

Accepted: April 2015

Mohammed Almuzian: dr\_muzian@hotmail.com; Anas Almukhtar: ans.1900@yahoo.com; Michael O'Neil: mikeyglasgow7@hotmail.co.uk; Philip Benington: philip.benington@ggc.scot.nhs.uk; Thamer Al Anezi: elthmry-dr@hotmail.com; Ashraf Ayoub: ashraf.ayoub@glasgow.ac.uk


## Introduction

A variety of methods are available for the treatment of mild to moderate anterior open bite in an adult patient. Among these options are Kim mechanics<sup>1</sup> or its modified version,<sup>2</sup> the use of repelling magnets<sup>3</sup> or skeletal anchorage devices that aid in intruding posterior teeth.<sup>4</sup> Mini-implant supported molar intrusion has shown better stability compared with conventional methods that involve the extrusion of anterior teeth.<sup>5</sup> However, the treatment of a high angle Class II malocclusion that is associated with a significant anterior open bite (AOB) usually involves a Le Fort I osteotomy, which facilitates auto-rotation of the mandible as a response to posterior maxillary impaction. Any associated change in vertical height of the anterior maxilla depends on the appropriateness of incisor display at rest and on maximum smiling. The maxilla can be surgically moved either in one piece or segmentally, depending on the severity of the curve of Spee. If a one piece procedure is indicated, pre-surgical orthodontic treatment involves continuous archwire mechanics aimed at partial or complete levelling of the upper dental arch. A disadvantage of this approach is the potential extrusion of the upper incisors, which can lead to post-surgical relapse of the AOB. Levelling

of the dental arch, through a segmental osteotomy using sectional mechanics, is an alternative procedure that eliminates incisor extrusion and the risk of open bite relapse.

The surgical correction of AOB in long-faced patients tends to produce complex soft tissue changes. Traditionally, these have been predicted from the profile view using photo-cephalometric planning techniques, which involved the superimposition of 1:1 photographic and radiographic images. The osteotomy segments and the covering soft tissue were cut and replaced according to the known ratios of expected soft tissue changes in response to underlying hard tissue movements.<sup>6</sup> More recently, software packages have offered a computerised prediction of the facial profile following orthognathic surgery,<sup>7</sup> which has subsequently been incorporated into the informed consent process. Current evidence supports the effectiveness of prediction planning in improving patient satisfaction with treatment outcomes.<sup>8,9</sup>

Whichever technique is employed, profile planning remains limited and offers poor reliability. Uncertain soft tissue changes away from the facial midline are well documented in orthognathic patients, particularly in relation to a Le Fort I osteotomy, and patients are



**Figure 1.** Pretreatment facial views. Frontal view with lips (A) at rest and (B) on smiling. (C) Profile view with lips at rest.

rarely able to view themselves in profile. In asymmetric cases, profile planning is inadequate.<sup>10,11</sup>

Swennen et al.<sup>12</sup> described a method for three-dimensional (3D) virtual planning that included the prediction of soft tissue changes, as well as the 3D printing of individualised surgical wafers. The hard and soft tissue structures of the face were acquired using cone beam computed tomography (CBCT) and stereo-photogrammetry, which were superimposed onto each other to produce a virtual face. The CBCT image of the dentition was magnified and distorted due to streak artefacts that were produced by the metallic restorations and the orthodontic appliances. These problems rendered the teeth inaccurate for planning the post-surgical occlusion. A 'triple scan' method, as described by Swennen et al., involved capturing the dentition accurately from a scanned impression of the teeth.<sup>13</sup> This image was substituted for the distorted dentition of the CBCT. However, the method required radiographic scanning of the patient's head twice, which is undesirable.

Due to the absence of collision detection and haptic feedback, the major disadvantage associated with the virtual planning model was the lack of tactile sensation when manipulating the 3D occlusal images on a screen. Therefore, physical model surgery planning remains the standard approach in most surgical centres around the world. Conventional model surgery, carried out on dental casts that are mounted on dental articulators, is still widely used to determine the required jaw movements to achieve the final planned occlusion. An accurate recording of the position of the maxillary dentition relative to the mandibular condyles and the cranial base is essential for accurate

model surgery planning. This is commonly recorded using a face bow transfer, but orientating the maxillary occlusal plane on the articulator is prone to errors.<sup>14,15</sup> The conventional dental articulators are not designed for planning of the surgical correction of facial asymmetries or complex orthognathic planning. With the advent of rapid prototyping from CBCT data, it has become possible to produce a physical model of the patient's skull at relatively low cost. The dentition is subject to the same distortion due to radiographic magnification and streak artefacts produced as a result of metallic restorations and dental appliances. The printed, distorted dentition requires replacement with an accurate physical substitute prior to model surgery planning. This was successfully achieved by O'Neil,<sup>16</sup> who produced an anatomically accurate physical 3D skeletal and dental model of the skull, jaw bones and teeth. The present paper reports the use of this technology in the management of an AOB case, coupled with the use of a virtual model for soft tissue prediction.

## Case summary

A 23-year-old man presented to the inter-disciplinary orthognathic clinic with a chief complaint of an inability to incise food, due to a lack of contact between his anterior teeth. His medical history was clear, apart from mild asthma.

## Facial assessment (Figure 1)

### *Anteroposterior features*

The patient showed a mild degree of maxillary deficiency with some paranasal flattening. The malar

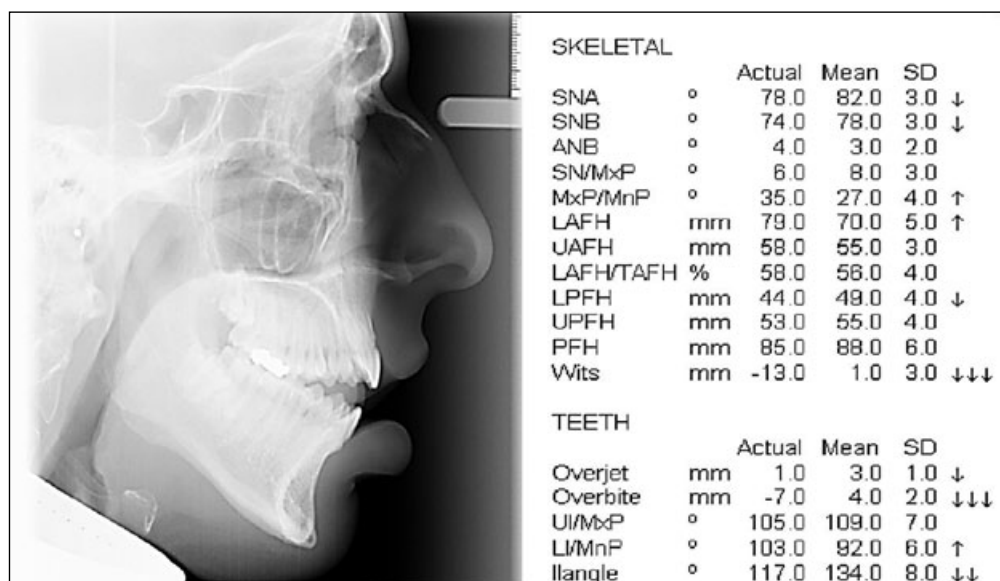


Figure 2. Pretreatment lateral cephalometric radiograph and analysis.

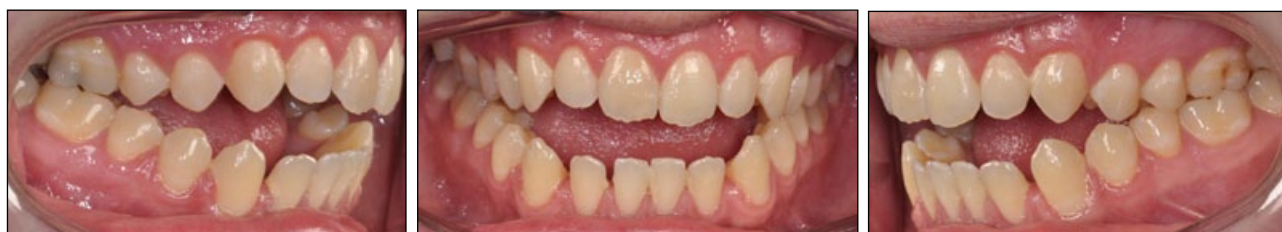

Figure 3. Pretreatment intra-oral views.

regions appeared mildly deficient; the nasal tip and columella were angled downwards. The maxillary incisors were set back from their ideal position in the face, with a resulting lack of support for the upper lip, despite the naso-labial angle being within the normal range. The jaw relationship was Class II, with a convex profile, due to backward rotation of the mandible and retrogenia.

#### *Vertical features*

The lower anterior face height was increased and the lips were incompetent. The vertical display of the upper incisors was within normal limits both at rest (3–4 mm) and on smiling (11 mm) and the length of the upper lip was within normal limits. The angle of the mandibular plane to the Frankfort horizontal was increased, as was the percentage of the lower anterior face height. At rest, there was a lack of labial seal. The curvature of the mento-labial fold was normal, but became flattened when the patient postured the lips together. The lateral cephalometric assessment confirmed the clinical findings (Figure 2).

#### *Transverse features*

There was mild asymmetry of the mandible, as the chin point had shifted to the right. The upper dental centreline was coincident with the facial midline, but the lower centreline was displaced to the right by approximately 2 mm. The alar base width was slightly reduced.

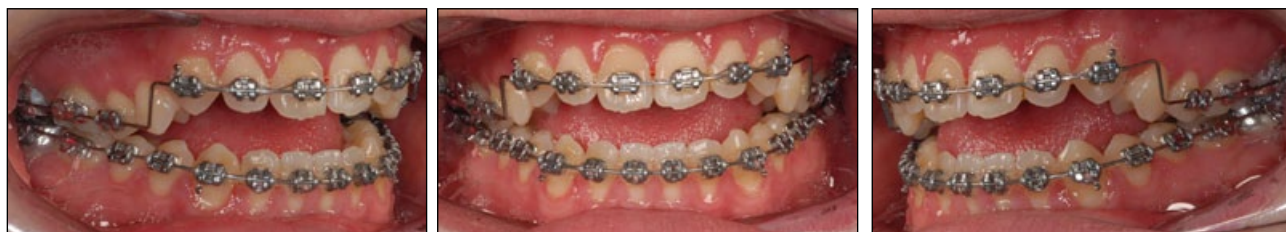#### *Intra-oral assessment (Figure 3)*

##### *Dental arches*

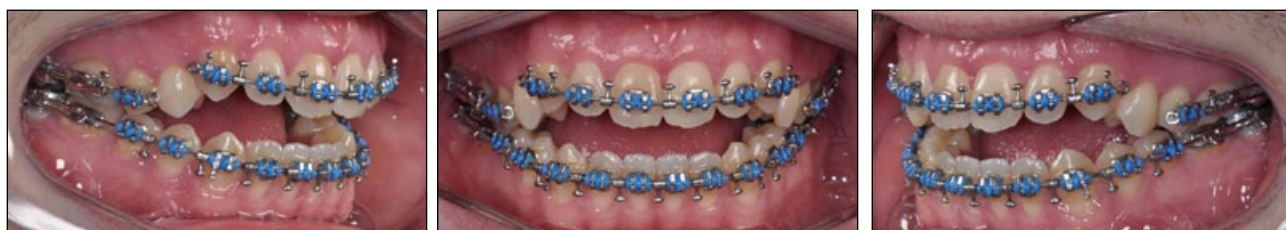The permanent dentition was complete except for the impacted third molars. The upper and lower arches were well aligned and there was mild spacing of the lower anterior teeth. The lower occlusal plane was flat, but the upper arch showed a pronounced curvature. The lower incisors were proclined but the upper anterior teeth were mildly retroclined.

##### *Occlusion*

The overjet was reduced and the buccal segment relationships were Angle Class II. An AOB was present



**Figure 4.** Pre-surgical orthodontic treatment showing the stepped archwire mechanics in the maxillary arch. The upper first premolars have been bypassed because of their planned extraction. Appliances used were pre-adjusted edgewise (0.022 x 0.028 inch slot with MBT® prescription).



**Figure 5.** Upper archwire was sectioned immediately before surgery to allow intra-operative extraction of upper first premolars at the time of surgery.

that extended from the upper right second premolar to upper left second premolar and measured 6 mm maximum between the central incisors. There was a tendency towards a cross-bite in the buccal segments, with the upper posterior teeth in a bilateral cusp-to-cusp relationship.

### ***Treatment plan***

Based on the clinical assessment and the analysis of photographs, radiographs and dental study models, the following treatment plan was agreed between the members of the inter-disciplinary team and the patient:

#### ***Envisaged soft tissue and aesthetic changes***

- Correction of the paranasal hollowing.
- Advancement of the maxillary incisors but with no vertical change.
- Reduction in lower anterior face height and in the steepness of the mandibular plane angle.
- Improvement in the competency of the lips.
- Advancement of the mandible and improvement in the lower lip contour.
- Correction of the chin point to the midline.

#### ***Dentoskeletal movements required to produce the required aesthetic changes***

- Advancement of maxilla by approximately 4 mm.
- Impaction of the posterior part of the maxilla.

- Auto-rotation and advancement of the mandible, secondary to posterior maxillary impaction to close the AOB and achieve optimal occlusion.
- Advancement and lateral sliding genioplasty to address the retrogenia and associated asymmetry.

### ***Pre-surgical orthodontic plan***

- Sectional levelling of the maxillary dental arch to avoid upper incisor extrusion.
- Extraction of upper first premolars at the time of surgery.
- Transverse arch-coordination, allowing for the upper first molars to finish in a full unit Class II occlusion.

### ***Pre-surgical orthodontic treatment***

Segmental mechanics were applied to the maxillary arch and aimed to actively intrude the upper incisors, to compensate for potential surgical relapse. A continuous archwire was used in the lower arch (Figure 4). The maxillary archwire was sectioned immediately before surgery to facilitate a segmental Le Fort I maxillary osteotomy (Figure 5).

### ***Virtual 3D skeletal and soft tissue prediction planning***

Following completion of pre-surgical orthodontics, a 22 cm CBCT scan was captured using an iCAT® machine (Imaging Sciences International, PA, USA). The DICOM (Digital Imaging



Communication in Medicine) data set produced was loaded into Maxilim® software (Medicim-Medical Image Computing, Mechelen, Belgium) and the soft and hard tissue models were segmented using the recommended Hounsfield Unit values for each tissue type. The CBCT scan produced a non-textured soft tissue surface, which is not ideal for patient communication, and so texture was added using a special tool built into Maxilim® software for that purpose. The required 3D photo-realistic image was obtained using the DI3D® stereo-photogrammetry system (Dimensional Imaging, Glasgow, UK). Soft tissue simulation and texture mapping were then carried out to produce the virtual photo-realistic 3D integrated hard and soft tissue model.

A standardised Maxilim® cephalometric analysis for maxillary osteotomy was used to assist with the planning process. It enabled the operator to monitor the Frankfort, maxillary and mandibular planes, the condylar axes, and the sagittal, coronal and axial planes, as well as orientating the model to mimic natural head position.

Following virtual segmentation at the site of the first premolar, the anterior and posterior parts of the maxilla were selected separately to develop a surgical plan (Figure 6). The segments were advanced in accordance with the provisional surgical plan and the posterior segment was impacted to allow auto-rotation of the mandible, which assisted closure of the AOB. With the lower incisors in their final anteroposterior position, the maxillary segments were finely adjusted to produce the final occlusion. The adjustments were done within the limitations of the distorted dentition and the lack of collision detection. The predicted effect on the soft tissues was subsequently assessed and included a review of the position of the chin in all three planes of space. The final virtual plan involved the following surgical movements:

- Anterior maxillary advancement of 3 mm.
- Posterior maxillary advancement of 8 mm (due to the loss of the first premolars) and an impaction of 4 mm.
- Mandibular auto-rotation of 7 degrees.
- Genioplasty was carried out to advance the chin by 4 mm and reposition to the left by 2 mm.

This plan was discussed with the maxillofacial technologist who proceeded with the physical 3D model surgery planning of the skeletal bases and the dental occlusion.

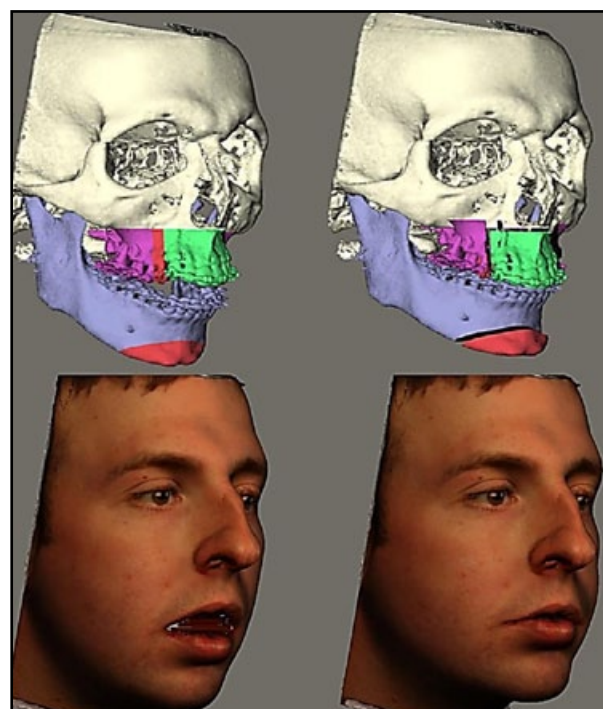


Figure 6. Final virtual 3D combined skeletal and soft tissue prediction plan.

### ***Physical 3D skeletal and dental model surgery planning***

The DICOM data file from the patient's existing iCAT scan was converted into a STL (Standard Tessellation Language) file format using Mimics® software (Materialise, Leuven, Belgium) (Figure 7). A rapid prototyping machine (Object 30, Tri-Tech 3D, Staffordshire, England) was used to build a 3D physical model of the skull using 0.028 mm thick layers (Figure 8).

The dentition component of the physical model was distorted as a result of magnification errors and streak artefacts during CBCT scan. So the distorted dentition was sectioned, removed from the physical model and replaced by a new plaster dentition (Shera Hard-Rock, John-Winters, Halifax, UK), which was poured from direct alginate impressions of the patient's dentition (xantALGIN® select, Heraeus, Germany). The replacement of the dentition was performed using a polyvinyl splint and a transfer jig replication technique as described by O'Neil et al.<sup>16</sup> The skull was mounted on a simulation device and oriented according to the patient's natural head position.<sup>17</sup>

The measurements of the surgical movements anticipated in the final virtual plan were given to the

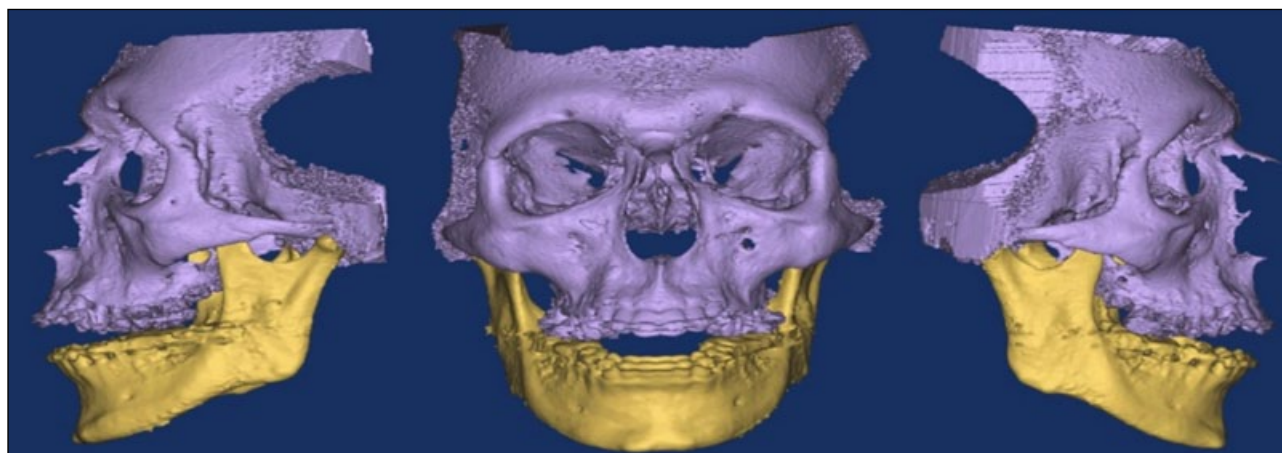


Figure 7. Virtual skull with inaccurate dentition derived from CBCT scan. Note the streak artefacts.

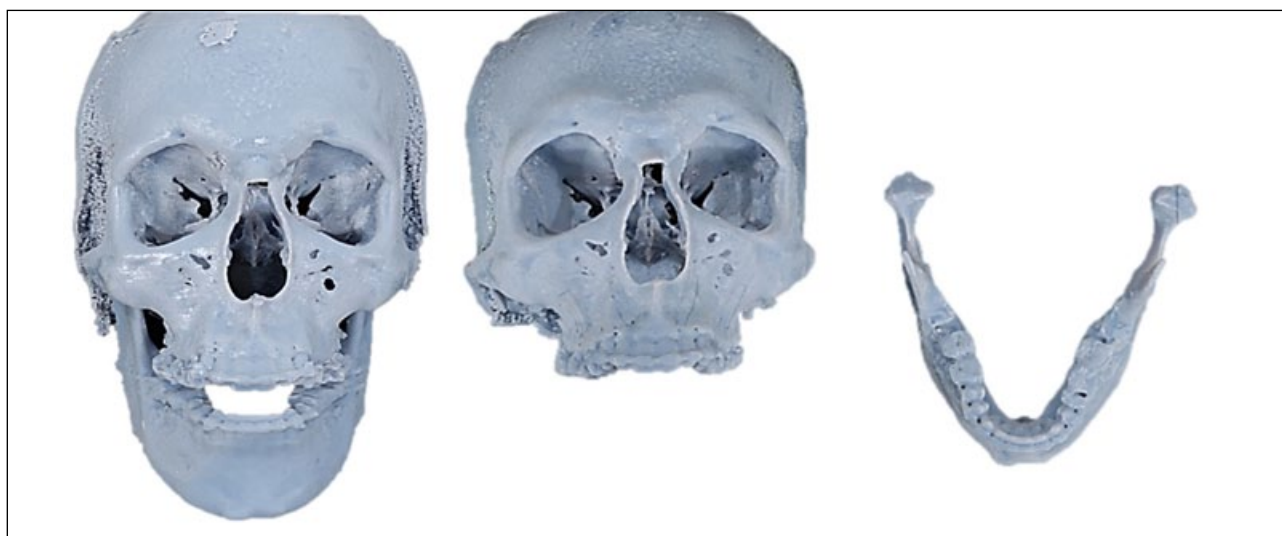


Figure 8. 3D physical skull printing and reproduction with inaccurate dentition and streak artefacts derived from CBCT scan of the patient.

maxillofacial laboratory technician, who proceeded to duplicate these movements onto the physical model. Following simulated mandibular auto-rotation, the maxillary segments were adjusted to achieve the optimal occlusion (Figure 9). The greater accuracy of occlusal interdigitation achievable on a physical model may result in minor changes to the skeletal movements, which were planned on the virtual model. Corresponding adjustments to the virtual plan might be required in which the magnitude of jaw movement performed on the physical model is virtually replicated to obtain the final predicted outcomes.

### ***Surgery and post-surgical management***

Surgery was carried out, guided by the manufactured occlusal wafer, and the maxillary segments were

accurately placed in the predetermined position (Figure 10).

Post-surgical orthodontic treatment was carried out to achieve the best possible occlusion over a six month period. Following fixed appliance removal (Figure 11), a lower wire retainer was bonded from canine to canine and supported by night-time wear of a vacuum-formed retainer. In the upper arch, a Hawley retainer was provided for night-time use in order to maintain arch form.

### ***Assessment of treatment outcome***

A CBCT scan and stereo-photogrammetry were captured approximately six months after treatment to assess the achieved surgical changes and the final soft tissue appearance. Colour-coded superimpositions of

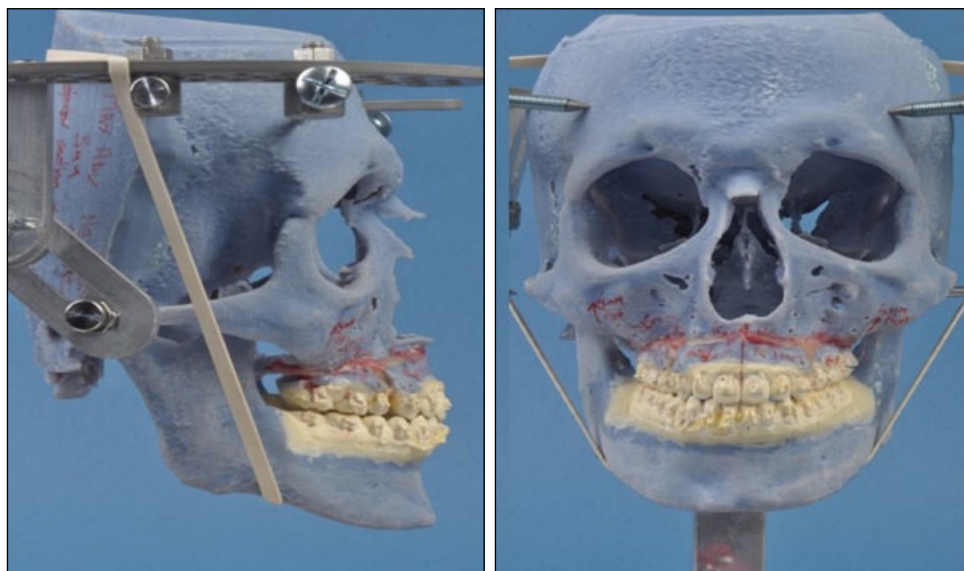


Figure 9. Final physical skeletal and dental plan with accurate replaced dentition.

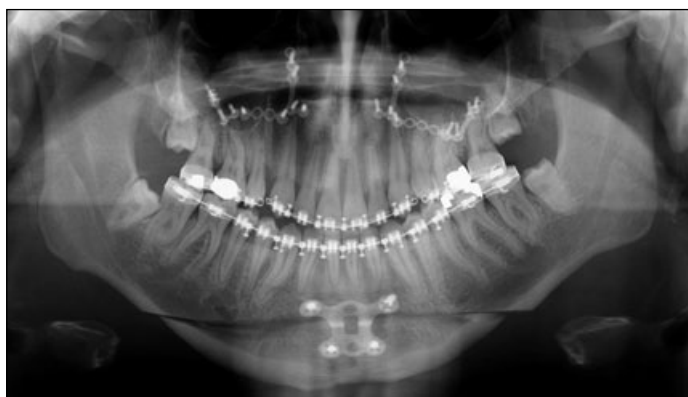

Figure 10. Post-surgical OPT.

the pre- and post-surgery CBCT images, using the forehead as a stable reference surface, displayed the areas of maximum skeletal and soft tissue changes in red (Figure 12).

## Discussion

The present case has demonstrated the value of modern technology and innovation, including 3D virtual and physical prediction planning to improve the precision of surgical movements of bone segments and to achieve the best possible soft tissue harmony.

In general, one of the main goals of orthognathic surgery is to improve the harmony of soft tissue appearance and obtain the best possible occlusion. The traditional 2D profile planning lacks the ability to predict soft tissue changes from the frontal view, so 3D virtual model planning has been introduced to address this deficiency. The closure of the AOB in

the presented case was achieved by mandibular auto-rotation, following posterior maxillary impaction. This is difficult to predict using a conventional dental articulator. The production of an anatomically accurate 3D physical model of the skull, jaw bones and dentition is a positive step to improve the accuracy of predicting mandibular auto-rotation. Inaccurate prediction of the magnitude of posterior maxillary impaction required to achieve the appropriate amount of mandibular auto-rotation could lead to a poor outcome and may necessitate further surgical and/or orthodontic intervention.

The tactile feel of occlusal interdigitation is one of the main advantages of using physical models for prediction planning. However, while tactile feel is absent, virtual 3D prediction planning provides necessary information regarding soft tissue changes in response to surgery. It further provides a unique opportunity for the patient to foresee the likely



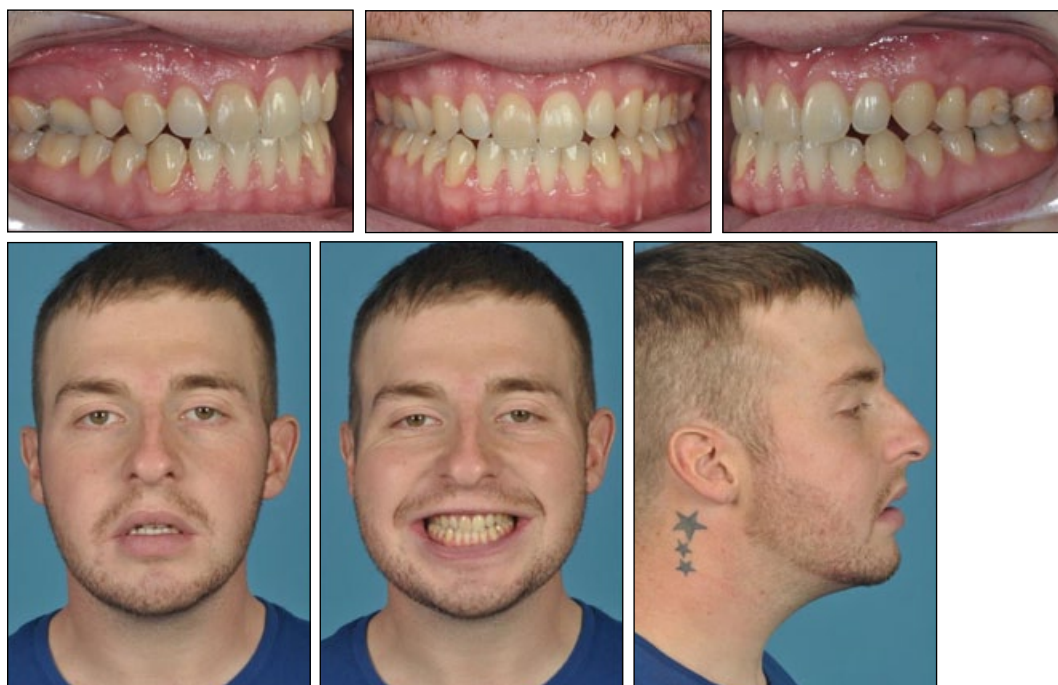

Figure 11. End of treatment Intra-oral and facial views.

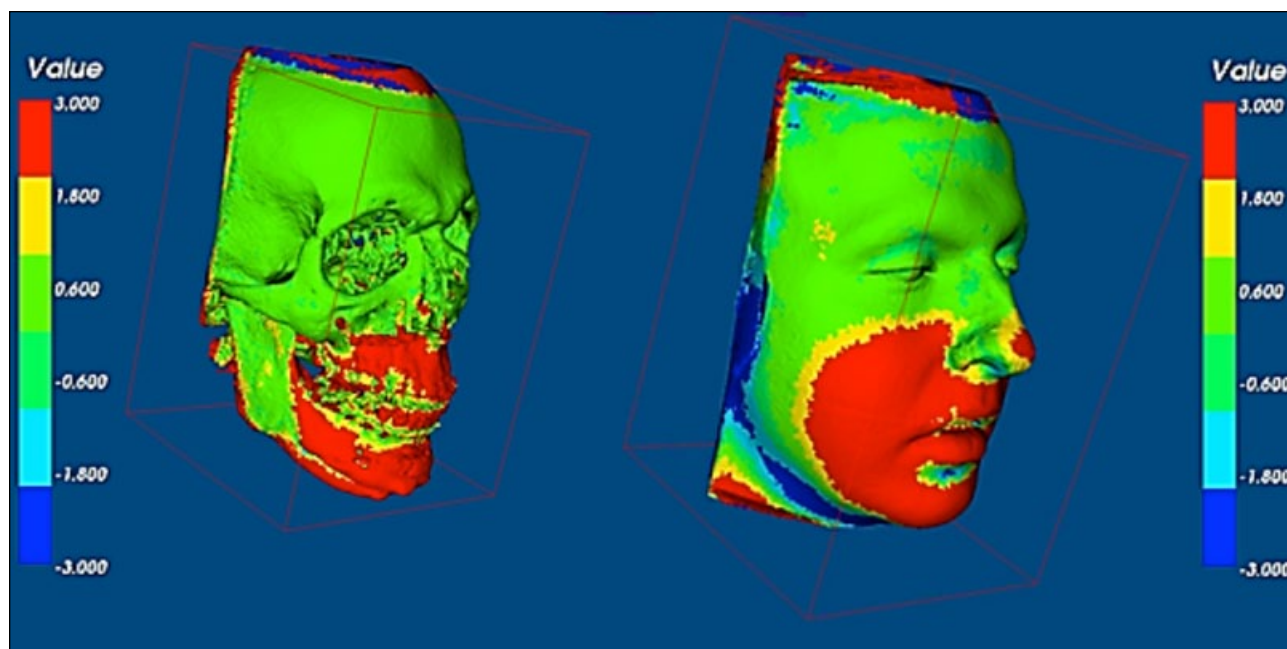


Figure 12. Colour-coded 3D superimposition of the pre- and post-surgery CBCT scans showing skeletal and soft tissue changes. Red indicates a change of >3mm.

changes following surgery. Several software packages are available for prediction planning, and their accuracy has been reported in systematic reviews by De Vos et al. in 2009 and Plooiij et al. in 2011.<sup>18,19</sup> The introduction of haptic-based manipulation of 3D digital images appears promising. Once accuracy has been validated, the process could be readily applied to virtual orthognathic surgical planning and provide

the operator with the ability to detect collision and consequently choose the most appropriate dental occlusion. Once this has been achieved, the application of CAD/CAM systems would be possible to produce occlusal wafers that are based on accurate occlusal surfaces to guide the surgical correction of dentofacial deformities.



## Corresponding author

Mohammed Almuzian  
University of Glasgow  
MVLS College, Glasgow Dental Hospital & School  
378 Sauchiehall Street  
Glasgow G2 3JZ  
UK

Email: dr\_muzian@hotmail.com

## References

1. Kim YH. Anterior openbite and its treatment with multiloop edgewise archwire. *Angle Orthod* 1987;57:290-321.
2. Enacar A, Ugur T, Toroglu S. A method for correction of open bite. *J clin orthod* 1996;30:43-8.
3. Kiliaridis S, Egermark I, Thilander B. Anterior open bite treatment with magnets. *Eur J Orthod* 1990;12:447-57.
4. Park YC, Lee HA, Choi NC, Kim DH. Open bite correction by intrusion of posterior teeth with miniscrews. *Angle Orthod* 2008;78:699-710.
5. Sugawara J, Baik UB, Umemori M, Takahashi I, Nagasaka H, Kawamura H et al. Treatment and posttreatment dentoalveolar changes following intrusion of mandibular molars with application of a skeletal anchorage system (SAS) for open bite correction. *Int J Adult Orthodon Orthognath Surg* 2002;17:243-53.
6. Bailey LJ, Collie FM, White RP Jr. Long-term soft tissue changes after orthognathic surgery. *Int J Adult Orthodon Orthognath Surg* 1996;11:7-18.
7. Konstantos KA, O'Reilly MT, Close J. The validity of the prediction of soft tissue profile changes after LeFort I osteotomy using the dentofacial planner (computer software). *Am J Orthod Dentofacial Orthop* 1994;105:241-9.
8. Eckhardt CE, Cunningham SJ. How predictable is orthognathic surgery? *Eur J Orthod* 2004;26:303-9.
9. Smith JD, Thomas PM, Proffit WR. A comparison of current prediction imaging programs. *Am J Orthod Dentofacial Orthop* 2004;125:527-36.
10. Pospisil OA. Reliability and feasibility of prediction tracing in orthognathic surgery. *J Craniomaxillofac Surg* 1987;15:79-83.
11. Kolokitha OE, Topouzelis N. Cephalometric methods of prediction in orthognathic surgery. *J Maxillofac Oral Surg* 2011;10:236-45.
12. Swennen GR, Mollemans W, Schutyser F. Three-dimensional treatment planning of orthognathic surgery in the era of virtual imaging. *J Oral Maxillofac Surg* 2009;67:2080-92.
13. Swennen GR, Mollemans W, De Clercq C, Abeloos J, Lamoral P, Lippens F et al. A cone-beam computed tomography triple scan procedure to obtain a three-dimensional augmented virtual skull model appropriate for orthognathic surgery planning. *J Craniofac Surg* 2009;20:297-307.
14. Walker F, Ayoub AF, Moos KF, Barbenel J. Face bow and articulator for planning orthognathic surgery: 1 face bow. *B J Oral Maxillofac Surg* 2008;46:567-72.
15. O'Malley AM, Milosevic A. Comparison of three facebow/semi-adjustable articulator systems for planning orthognathic surgery. *B J Oral Maxillofac Surg* 2000;38:185-90.
16. O'Neil M, Khambay B, Bowman A, Moos KF, Barbenel J, Walker F et al. Validation of a new method for building a three-dimensional physical model of the skull and dentition. *B J Oral Maxillofac Surg* 2012;50:49-54.
17. Lundström A, Lundström F, Le Bret LM, Moorrees CF. Natural head position and natural head orientation: basic considerations in cephalometric analysis and research. *Eur J Orthod* 1995;17:111-20.
18. De Vos W, Casselman J, Swennen GR. Cone-beam computerized tomography (CBCT) imaging of the oral and maxillofacial region: a systematic review of the literature. *Int J Oral Maxillofac Surg* 2009;38:609-25.
19. Plooi JM, Maal TJ, Haers P, Borstlap WA, Kuijpers-Jagtman AM, Bergé SJ. Digital three-dimensional image fusion processes for planning and evaluating orthodontics and orthognathic surgery. A systematic review. *Int J Oral Maxillofac Surg* 2011;40:341-52.