

RESEARCH ARTICLE

Assessment of bone marrow fat fractions in the mandibular condyle head using the iterative decomposition of water and fat with echo asymmetry and least-squares estimation (IDEAL-IQ) method

Kug Jin Jeon, Chena Lee, Yoon Joo Choi , Sang-Sun Han *

Department of Oral and Maxillofacial Radiology, Yonsei University College of Dentistry, Seoul, Republic of Korea

* sshan@yuhs.ac OPEN ACCESS

Citation: Jeon KJ, Lee C, Choi YJ, Han S-S (2021) Assessment of bone marrow fat fractions in the mandibular condyle head using the iterative decomposition of water and fat with echo asymmetry and least-squares estimation (IDEAL-IQ) method. PLoS ONE 16(2): e0246596. <https://doi.org/10.1371/journal.pone.0246596>

Editor: Essam Al-Moraissi, Tamar University, Faculty of Dentistry, YEMEN

Received: November 5, 2020

Accepted: January 22, 2021

Published: February 26, 2021

Copyright: © 2021 Jeon et al. This is an open access article distributed under the terms of the [Creative Commons Attribution License](https://creativecommons.org/licenses/by/4.0/), which permits unrestricted use, distribution, and reproduction in any medium, provided the original author and source are credited.

Data Availability Statement: All relevant data are within the manuscript and its [Supporting Information](#) files.

Funding: This study was supported by the Yonsei University College of Dentistry (6-2020-0027). There was no additional external funding received for this study.

Competing interests: The authors have declared that no competing interests exist.

Abstract

The prevalence of temporomandibular joint disorder (TMD) is gradually increasing, and magnetic resonance imaging (MRI) is becoming increasingly common as a modality used to diagnose TMD. Edema and osteonecrosis in the bone marrow of the mandibular condyle have been considered to be precursors of osteoarthritis, but these changes are not evaluated accurately and quantitatively on routine MRI. The iterative decomposition of water and fat with echo asymmetry and least-squares estimation (IDEAL-IQ) method, as a cutting-edge MRI technique, can separate fat and water using three asymmetric echo times and the three-point Dixon method. The purpose of this study was to analyze the quantitative fat fraction (FF) in the mandibular condyle head using the IDEAL-IQ method. Seventy-nine people who underwent MRI using IDEAL-IQ were investigated and divided into 1) the control group, without TMD symptoms, and 2) the TMD group, with unilateral temporomandibular joint (TMJ) pain. In both groups, the FF of the condyle head in the TMJ was analyzed by two oral and maxillofacial radiologists. In the TMD group, 29 people underwent cone-beam computed tomography (CBCT) and the presence or absence of bony changes in the condylar head was evaluated. The FF measurements of the condyle head using IDEAL-IQ showed excellent inter-observer and intra-observer agreement. The average FF of the TMD group was significantly lower than that of the control group ($p < 0.05$). In the TMD group, the average FF values of joints with pain and joints with bony changes were significantly lower than those of joints without pain or bony changes, respectively ($p < 0.05$). The FF using IDEAL-IQ in the TMJ can be helpful for the quantitative diagnosis of TMD.

Introduction

The prevalence of temporomandibular joint disorder (TMD) is gradually increasing, and cone-beam computed tomography (CBCT), computed tomography (CT) and magnetic resonance imaging (MRI) are becoming increasingly common as modalities used to diagnose TMD.

CT is an excellent imaging modality for evaluating bony changes of the temporomandibular joint (TMJ) and can be expressed by quantifying the density of tissue using Hounsfield units (HU), which are relatively set based on the value of -1000 for air and 0 for water. MRI is excellent for evaluating soft tissue. It shows the soft tissue, including the disc of the TMJ and its attachment, as well as joint effusion and the bone marrow signal of the condylar head [1]. MRI does not use radiation, and new advanced techniques for diagnosis are being developed, including higher magnetic field strength, improved coil design, and other technical improvements [2], resulting in increasing demand for MRI. Various MRI techniques have been tried in recent years, and for the TMJ, studies have been conducted using dynamic MRI [3], real-time MRI [4, 5], zero-TE technique [6], and T2 mapping [7]. The bone marrow consists of water, fat, and protein, and its proportion is thought to be related to the remodeling capacity of the bone [8]. In previous studies, edema and osteonecrosis in the bone marrow of the mandibular condyle were considered to be a precursor to osteoarthritis, but these changes were not evaluated accurately and quantitatively on routine MRI [5, 9–11]. One of the latest MRI techniques is the iterative decomposition of water and fat with echo asymmetry and least-squares estimation (IDEAL-IQ) method, which can separate fat and water using three asymmetric echo times and the three-point Dixon method [12]. IDEAL-IQ has been studied for the liver [13–16], pancreas [17], femur [8], and salivary glands [18], as well as for the diagnosis of osteoporosis [8] and metabolic diseases such as diabetes mellitus [19, 20] through changes in the fat fraction (FF). Yoo et al. [21] reported that malignant lesions replaced normal bone marrow fat with cancer cells, resulting in a reduced percentage of fat. However, the utility of IDEAL-IQ for the TMJ has not yet been assessed.

This study quantitatively measured the FF in the condyle head of the TMJ using the IDEAL-IQ method and statistically compared the control and TMD groups. Further, the FF was compared within the TMD group according to the presence of pain and bony changes to assess its utility in the accurate diagnosis of TMD.

Materials and methods

Subject classification

Seventy-nine patients who underwent MRI examinations including a TMJ IDEAL-IQ sequence from April 2019 to June 2020 at Yonsei University Dental Hospital were retrospectively selected.

We classified patients without any TMD symptoms into the control group and those with TMD symptoms into the TMD group. Symptoms were defined as pain, sound (click, crepitus, or popping), and limitation of mouth opening (assisted opening < 40 mm) according to the Diagnostic Criteria for Temporomandibular Disorders (DC/TMD) [22]. The TMD group included only patients with unilateral TMJ pain.

The control group consisted of 34 people (68 joints) (15 male and 19 female; age range, 35–79 years; mean age, 59.44 years). Forty-five people (90 joints) with TMD symptoms were classified into the TMD group (13 male and 32 female; age range, 32–76 years; mean age, 48.40 years).

Quantitative analysis of MRI

MRI of the TMJ was acquired using a 3.0 T scanner (Pioneer; GE Healthcare, Waukesha, WI, USA) with 16-channel flex large coil. Images of the 3D coronal IDEAL-IQ sequence

were acquired using the following parameters: echo time, 9.9 ms; repetition time, 6.5 ms; bandwidth, 111.11 kHz; NEX, 1.0; field of view, 240 × 240 mm; slice thickness, 2.0 mm; scan time, 1 min. The FF of the TMJ as determined using IDEAL-IQ was analyzed in the control group and TMD group. Regions of interest were drawn along the inner surface of the cortical layer to the condylar neck on the coronal image where the condylar head was most visible (Fig 1). Oral and maxillofacial radiologists with 20 years of experience analyzed of FF twice at 1 month intervals. The average values of two measurements were used for the statistical analysis. To assess reliability, 20 MRI images (40 joints) were randomly selected and oral and maxillofacial radiologists with 12 years of experience analyzed of FF twice at 1 month intervals.

Bony change evaluation of the TMD group on CBCT images

In the TMD group, 29 people underwent both MRI and CBCT examinations within 2 months (10 male and 19 female; age range, 36–74 years; mean age, 47.69 years). Two oral and maxillofacial radiologist assessed bony changes in the mandibular condyle. Bony change was defined as the presence of erosion (an interruption or absence of the cortical lining) or an osteophyte (marginal hypertrophic bone formation) according to the criteria proposed by Shigeno et al. [7]. The presence or absence of bony changes was defined by the consensus of two radiologists.

Statistical analysis

The intra- and inter-observer agreement of the two radiologists was assessed using kappa analysis. The FF between the control group and the TMD group was compared using the unpaired t-test. In the TMD group with unilateral joint pain, the FF between the painful joint and the painless joint were compared using the paired t-test, and the FF between joints with and without bony changes were compared using the unpaired t-test. Statistical analyses were performed using GraphPad Prism version 8.0 (GraphPad Software, La Jolla, CA, USA).

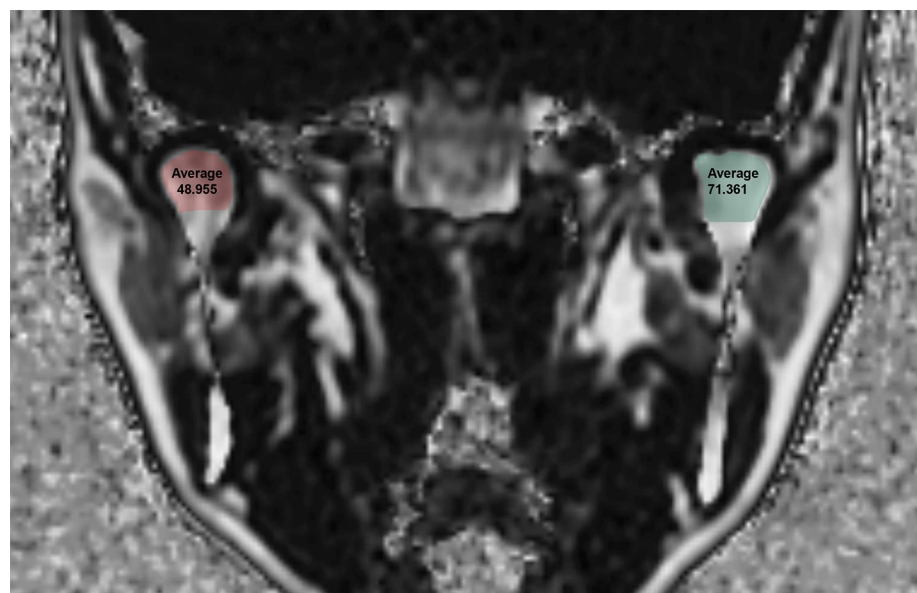


Fig 1. Fat Fraction (FF) using the IDEAL-IQ sequence in a 43-year-old female patient with temporomandibular joint disorder.

<https://doi.org/10.1371/journal.pone.0246596.g001>

Ethics approval

The study was approved by the Institutional Review Board of Yonsei University Dental Hospital (IRB no. 2-2020-0014) and was performed in accordance with all relevant guidelines and regulations. The requirement for patient consent was waived because of the retrospective nature of the study.

Results

The kappa coefficients for intra-observer agreement were 0.898 (95% confidence interval [CI], 0.807–0.946) and 0.993 (95% CI, 0.987–0.996), respectively. The inter-observer agreement of the two observers was 0.960 (95% CI, 0.924–0.979) (Table 1).

The average FF value of the TMD group was 60.56%, which was statistically significantly lower than that of the control group (p -value < 0.0001) (Table 2 and Fig 2). Detailed FF values for the control and TMD groups are shown in S1 and S2 Tables.

Within the TMD group, the average FF value of painful joints was 55.98%, which was statistically significantly lower than that of painless joints (p -value = 0.0012), and the average FF value of joints with bony changes was 50.54%, which was statistically significantly lower than that of joints without bony changes (p -value = 0.0019) (Table 3 and Fig 3).

Discussion

TMD is a chronic disease, in which patients can undergo cycles of symptom improvement and exacerbation. It would be very helpful if imaging provided indicators that could predict a patient's future prognosis beyond just showing the current status of bony changes or disc condition.

Edema and osteonecrosis may occur in the marrow of the mandibular condyle. Osteoarthritis may be secondary to osteonecrosis in the TMJ, and edema may be a precursor to osteonecrosis or a sign of worsening of symptoms [9]. It is known that osteonecrosis manifests as low signal intensity on T1-weighted MRI, while edema is displayed as high signal intensity on T2-weighted images [23, 24], but these signal changes are subjectively judged by visual inspection. Thus, an objective and quantifiable evaluation method is needed.

The red (hematopoietic) marrow is composed of 40% fat, 40% water, and 20% protein, and the yellow (fatty) marrow in adults is composed of approximately 80% fat, 15% water, and 5% protein [25]. The proportion of both types of marrow appears to be related to the remodeling capacity of bone. Therefore, it is thought that changes of the FF in the condylar bone marrow may help predict the progression of TMD.

Several MRI techniques can be used to quantify FF. MR spectroscopy can accurately measure fat-water content [26, 27], but due to its long scan time, small image range, and post-processing, it has limitations in clinical applications [13, 28]. The latest IDEAL-IQ technique can obtain FF images without post-processing, and can automatically calculate the FF with shorter scan and measuring time [8, 29]. Meisamy et al. [14] reported the accuracy of IDEAL-IQ in the liver and Aoki et al. [8] reported its reproducibility in pelvic imaging through 10 repeated

Table 1. Intra- and inter-observer agreement for two radiologists: Kappa index (95% CI).

	Radiologist 1	Radiologist 2
Intra-observer agreement	0.898 (0.807–0.946)	0.993(0.987–0.996)
Inter-observer agreement	0.960 (0.924–0.979)	

CI, confidence interval.

<https://doi.org/10.1371/journal.pone.0246596.t001>

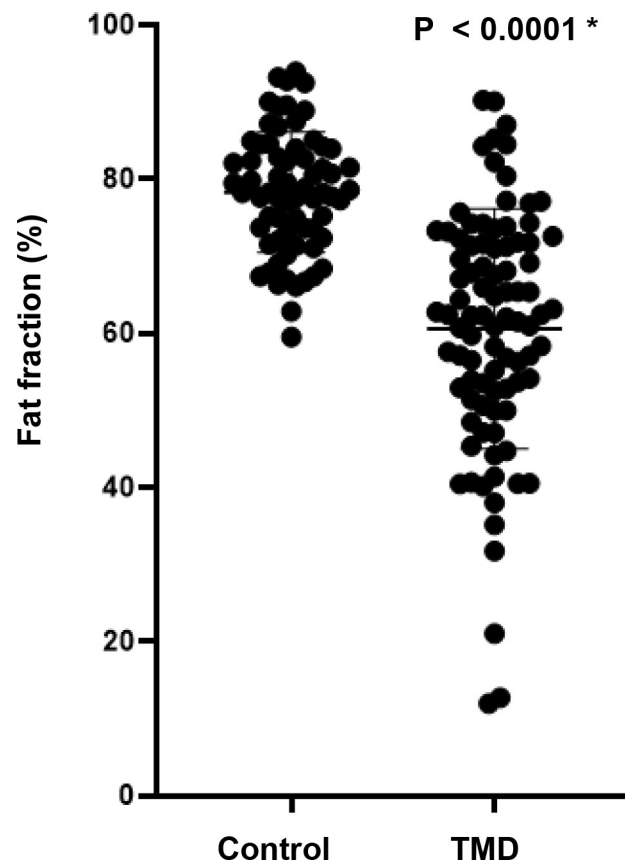
Table 2. Fat fraction (%) between the control group and Temporomandibular Joint Disorder (TMD) group.

Control group (n = 68 joints)	TMD group (n = 90 joints)	Difference (95% CI)	p-value
78.30	60.56	17.73 ± 2.07 (13.66–21.81)	< 0.0001 *

CI, confidence interval; unpaired t-test, * $p < 0.05$.

<https://doi.org/10.1371/journal.pone.0246596.t002>

evaluations. Aoki et al. [8] also reported that the FF significantly increased with age and that the FF of postmenopausal women was significantly higher than that of premenopausal women in the lumbar vertebral bodies, ilium, and intertrochanteric region of the femur. Hu et al. [19] reported that IDEAL-IQ findings were highly associated with increasing vertebral fat deposition and that IDEAL-IQ could be used to quantitatively evaluate changes in fat deposition in alloxan-induced diabetic rabbits. Chen et al. [20] reported that pancreatic fat infiltration was associated with diabetes and that IDEAL-IQ could be used to accurately and reproducibly quantify pancreatic fat content in 7 pigs with diabetes and 6 control pigs. In the intervertebral disc of the vertebra, the signal intensity of the focal lesion was evaluated by visual assessment in T1-weighted images to distinguish normal hematopoietic marrow and infiltrative pathology [30, 31]. A report suggested that malignant lesions of the spine have lower FF than benign lesions, and that the FF could therefore be useful for distinguishing between benign and malignant causes of focal bone marrow abnormalities [21]. It is also thought that in TMD, the TMJ

**Fig 2. Fat fraction (%) between the control group and Temporomandibular Joint Disorder (TMD) group.**

<https://doi.org/10.1371/journal.pone.0246596.g002>

Table 3. Fat fraction (%) according to the presence of pain and bony changes in the TMD group.

	Yes	No	Difference (95% CI)	p-value
Pain	55.98	64.49	8.58 ± 16.67 (3.58–13.59)	0.0012 *
	(n = 45 joints)	(n = 45 joints)		
Bony changes	50.54	64.62	14.08 ± 4.32 (5.43–22.73)	0.0019 *
	(n = 20 joints)	(n = 38 joints)		

CI, confidence interval; pain, paired t-test, **p*<0.05; bony changes, unpaired t-test, **p*<0.05.

<https://doi.org/10.1371/journal.pone.0246596.t003>

has FF changes, but to the best of our knowledge, no studies have yet investigated the application of IDEAL-IQ in TMJ.

In this study, the FF measurements of the condyle head using IDEAL-IQ showed excellent intra- and inter-observer agreement. The FF was statistically significantly lower in the TMD group than in the control group. In patients with TMD, the FF is thought to decrease due to the loss of normal bone marrow fat, increased serum protein exudate, and edema fluid [9]. According to the three-way histologic classification of core biopsies of the mandibular condyle by Larheim et al. [9], normal samples show a normal marrow architecture in which the hematopoietic marrow is maintained, while samples with edema show preservation of the hematopoietic bone marrow and production of serum protein exudate and edema fluid within the marrow interstitium. Finally, samples with osteonecrosis display loss of the hematopoietic marrow, the normal marrow stroma, and marrow fat, as well as gradual reticulin fibrosis.

Fat content in the TMD group was statistically significantly lower in the joints with pain and bony changes than those without pain or bony changes. TMJ pain can have a variety of sources, including inflammatory changes in the posterior disc attachment [32], the presence of inflammatory mediators in the synovial fluid [33], excessive joint effusion [34, 35], and bone marrow edema [9, 35–41]. It has been reported that the risk and degree of pain in TMJs with an abnormal bone marrow signal were significantly higher than those in TMJs with a normal bone marrow signal on MRI [37, 42]. If there are bony changes, the bone marrow may be lost

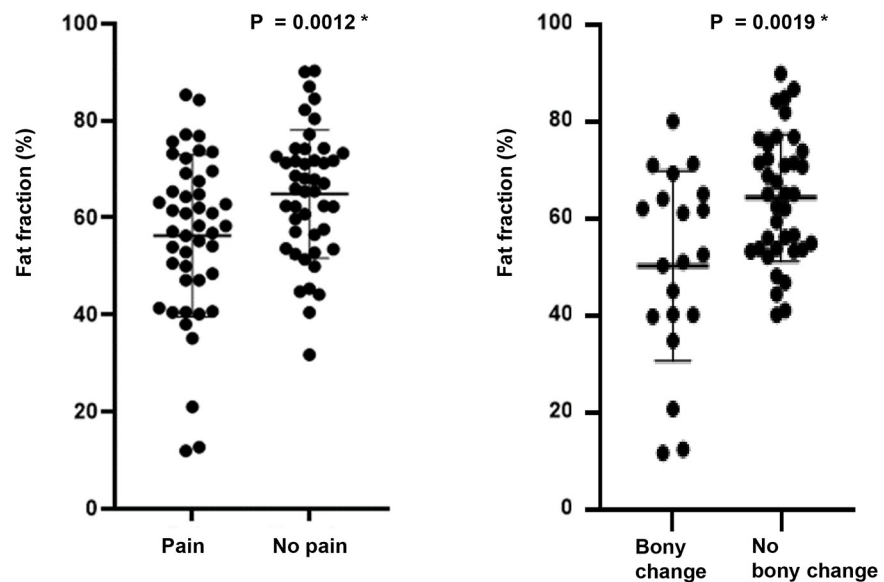


Fig 3. Fat fraction (%) according to the presence of pain and bony changes within the TMD group.

<https://doi.org/10.1371/journal.pone.0246596.g003>

in addition to the cortical bone, which may be accompanied by edema and osteonecrosis; therefore, the fat content decreases. In light of the observed difference in the FF value between the TMD group and the control group, it is noteworthy that a recent study showed the same tendency in the sacroiliac joint. The mean FF of normal sacroiliac joints was $52.0 \pm 10.4\%$ and $50.5 \pm 10.1\%$ on the left and right sides, respectively, whereas active inflammatory fat deposition in the patients with spondyloarthritis led to a much lower FF: $15.8 \pm 5.9\%$ and $13.5 \pm 6.7\%$ on the left and right sides, respectively. However, post-inflammatory FF indicating chronicity was higher than normal [43]. In TMJ, further studies are needed according to the stage of the disease.

The FF of the bone marrow can have different values depending on age, sex, and body mass index (BMI). Previous studies have shown that FF tends to increase gradually with age in the parotid glands, submandibular glands, and sacroiliac joints [18, 44]. At birth, the mandible only contains red marrow, but with age, conversion of red marrow to yellow marrow begins anteriorly, and by age 30, only yellow marrow is found in the normal mandible [45]. Therefore, this study targeted people over the age of 30. The TMD group and the control group were designed to include patients in similar age groups to minimize the effect of age. Previous studies showed no statistically significant differences between male and female [18, 43]. The reported relationship between FF and BMI has varied across studies, with the salivary gland being related, but the sacroiliac joint not [18, 43]. Further studies on the FF of the mandibular condyle according to age, sex, and BMI are needed. In addition, since the mandibular condyle is a site that is loaded by occlusion, further studies on the relationship with occlusal force are also required.

The main limitation of this study is the number of samples, and since bony changes only included erosion and osteophytes, further studies on minor bony changes such as sclerosis, flattening, and subchondral cyst are needed. Further research is also needed on the relationship between intensity of pain and FF values. Finally, we did not consider systemic conditions such as drug treatment, radiation treatment, and metabolic disorders.

In conclusion, the FF, assessed quantitatively using IDEAL-IQ in the TMJ, was lower in patients with TMD than in the control group, and there were significant differences depending on the presence or absence of pain and bony changes in the TMD group. IDEAL-IQ could be used to diagnose TMD on MRI based on a quantitative assessment of the FF of the condylar bone marrow.

Supporting information

S1 Table. Control group.

(DOCX)

S2 Table. TMD group.

(DOCX)

Author Contributions

Conceptualization: Kug Jin Jeon, Chena Lee, Sang-Sun Han.

Data curation: Kug Jin Jeon, Yoon Joo Choi.

Formal analysis: Kug Jin Jeon, Yoon Joo Choi.

Funding acquisition: Kug Jin Jeon.

Investigation: Kug Jin Jeon, Yoon Joo Choi.

Methodology: Kug Jin Jeon, Chena Lee, Sang-Sun Han.

Project administration: Kug Jin Jeon, Sang-Sun Han.

Resources: Kug Jin Jeon.

Supervision: Sang-Sun Han.

Validation: Kug Jin Jeon, Chena Lee, Yoon Joo Choi, Sang-Sun Han.

Writing – original draft: Kug Jin Jeon, Sang-Sun Han.

Writing – review & editing: Kug Jin Jeon, Chena Lee, Yoon Joo Choi, Sang-Sun Han.

References

1. Tamimi D, Kocasarac HD, Mardini S. Imaging of the Temporomandibular Joint. *Semin Roentgenol*. 2019; 54: 282–301. <https://doi.org/10.1053/j.ro.2019.03.007> PMID: 31376868
2. Martín Noguero T, Luna Alcalá A, Beltrán LS, Gómez Cabrera M, Broncano Cabrero J, Vilanova JC. Advanced MR Imaging techniques for differentiation of neuropathic arthropathy and osteomyelitis in the diabetic foot. *Radiographics*. 2017; 37: 1161–1180. <https://doi.org/10.1148/rg.2017160101> PMID: 28696850
3. Hopfgartner AJ, Tymofiyeva O, Ehses P, Rottner K, Boldt J, Richter EJ, et al. Dynamic MRI of the TMJ under physical load. *Dentomaxillofac Radiol*. 2013; 42: 20120436. <https://doi.org/10.1259/dmfr.20120436> PMID: 23975114
4. Krohn S, Gersdorff N, Wassmann T, Merboldt KD, Joseph AA, Buegers R, et al. Real-time MRI of the temporomandibular joint at 15 frames per second-A feasibility study. *Eur J Radiol*. 2016; 85: 2225–2230. <https://doi.org/10.1016/j.ejrad.2016.10.020> PMID: 27842671
5. Krohn S, Joseph AA, Voit D, Michaelis T, Merboldt KD, Buegers R, et al. Multi-slice real-time MRI of temporomandibular joint dynamics. *Dentomaxillofac Radiol*. 2019; 48: 20180162. <https://doi.org/10.1259/dmfr.20180162> PMID: 30028188
6. Lee C, Jeon KJ, Han SS, Kim YH, Choi YJ, Lee A, et al. CT-like MRI using the zero-TE technique for osseous changes of the TMJ. *Dentomaxillofac Radiol*. 2020; 49: 20190272. <https://doi.org/10.1259/dmfr.20190272> PMID: 31670578
7. Shigeno K, Sasaki Y, Otonari-Yamamoto M, Ohata H, Shibahara T. Evaluating the mandibular condyles of patients with osteoarthritis for bone marrow abnormalities using magnetic resonance T2 mapping. *Oral Radiol*. 2019; 35: 272–279. <https://doi.org/10.1007/s11282-018-0357-5> PMID: 30484208
8. Aoki T, Yamaguchi S, Kinoshita S, Hayashida Y, Korogi Y. Quantification of bone marrow fat content using iterative decomposition of water and fat with echo asymmetry and least-squares estimation (IDEAL): reproducibility, site variation and correlation with age and menopause. *Br J Radiol*. 2016; 89 (1065): 20150538. <https://doi.org/10.1259/bjr.20150538> PMID: 27356277
9. Larheim TA, Westesson PL, Hicks DG, et al. Osteonecrosis of the temporomandibular joint: correlation of magnetic resonance imaging and histology. *J Oral Maxillofac Surg*. 1999; 57: 888–898. [https://doi.org/10.1016/s0278-2391\(99\)90001-0](https://doi.org/10.1016/s0278-2391(99)90001-0) PMID: 10437715
10. Sano T, Westesson PL, Larheim TA, Rubin SJ, Tallents RH. Osteoarthritis and abnormal bone marrow of the mandibular condyle. *Oral Surg Oral Med Oral Pathol Oral Radiol Endod*. 1999; 87: 243–252. [https://doi.org/10.1016/s1079-2104\(99\)70280-5](https://doi.org/10.1016/s1079-2104(99)70280-5) PMID: 10052383
11. Emshoff R, Brandlmaier I, Schmid C, Bertram S, Rudisch A. Bone marrow edema of the mandibular condyle related to internal derangement, osteoarthritis, and joint effusion. *J Oral Maxillofac Surg*. 2003; 61: 35–40. <https://doi.org/10.1053/joms.2003.50006> PMID: 12524605
12. Reeder SB, Pelc NJ, Alley MT, Gold GA. Multi-coil Dixon chemical species separation with an iterative least squares method. *Magn Reson Med*. 2004; 51: 34–45.
13. Kim H, Taksali SE, Dufour S, Befroy D, Goodman TR, Petersen KF, et al. Comparative MR study of hepatic fat quantification using single-voxel proton spectroscopy, two-point Dixon and three-point IDEAL. *Magn Reson Med*. 2008; 59: 521–527. <https://doi.org/10.1002/mrm.21561> PMID: 18306404
14. Meisamy S, Hines CD, Hamilton G, Sirlin CB, McKenzie CA, Yu H, et al. Quantification of hepatic steatosis with T1-independent, T2-corrected MR imaging with spectral modeling of fat: blinded comparison with MR spectroscopy. *Radiology*. 2011; 258: 767–775. <https://doi.org/10.1148/radiol.10100708> PMID: 21248233
15. Eskreis-Winkler S, Corrias G, Monti S, Zheng J, Capanu M, Krebs S, et al. IDEAL-IQ in an oncologic population: meeting the challenge of concomitant liver fat and liver iron. *Cancer Imaging*. 2018; 12: 18 (1):51. <https://doi.org/10.1186/s40644-018-0167-3> PMID: 30541635

16. Corrias G, Krebs S, Eskreis-Winkler S, Ryan D, Zheng J, Capanu M, et al. MRI liver fat quantification in an oncologic population: the added value of complex chemical shift-encoded MRI. *Clin Imaging*. 2018; 52: 193–199. <https://doi.org/10.1016/j.clinimag.2018.08.002> PMID: 30103108
17. Fukui H, Hori M, Fukuda Y, Onishi H, Nakamoto A, Ota T, et al. Evaluation of fatty pancreas by proton density fat fraction using 3-T magnetic resonance imaging and its association with pancreatic cancer. *Eur J Radiol*. 2019; 118: 25–31. <https://doi.org/10.1016/j.ejrad.2019.06.024> PMID: 31439250
18. Su GY, Wang CB, Hu H, Liu J, Ding HY, Xu XQ, et al. Effect of laterality, gender, age and body mass index on the fat fraction of salivary glands in healthy volunteers: assessed using iterative decomposition of water and fat with echo asymmetry and least-squares estimation method. *Dentomaxillofac Radiol*. 2019; 48: 20180263. <https://doi.org/10.1259/dmfr.20180263> PMID: 30306806
19. Hu L, Zha YF, Wang L, Li L, Xing D, Gong W, et al. Quantitative evaluation of vertebral microvascular permeability and fat fraction in alloxan-induced diabetic rabbits. *Radiology*. 2018; 287: 128–136. <https://doi.org/10.1148/radiol.2017170760> PMID: 29156149
20. Chen Y, Long L, Jiang Z, Zhang L, Zhong D, Huang X. Quantification of pancreatic proton density fat fraction in diabetic pigs using MR imaging and IDEAL-IQ sequence. *BMC Med Imaging*. 2019; 14: 19: 38. <https://doi.org/10.1186/s12880-019-0336-2> PMID: 31088378
21. Yoo HJ, Hong SH, Kim DH, et al. Measurement of fat content in vertebral marrow using a modified dixon sequence to differentiate benign from malignant processes. *J Magn Reson Imaging*. 2017; 45: 1534–1544. <https://doi.org/10.1002/jmri.25496> PMID: 27690264
22. Schiffman E, Ohrbach R, Truelove E, Look J, Anderson G, Goulet JP, et al. Diagnostic Criteria for Temporomandibular Disorders (DC/TMD) for clinical and research applications: recommendations of the International RDC/TMD Consortium Network* and Orofacial Pain Special Interest Group. *J Oral Facial Pain Headache*. 2014; 28: 6–27. <https://doi.org/10.11607/jop.1151> PMID: 24482784
23. Schellhas KP, Wilkes CH, Fritts HM, et al. MR of osteochondritis dissecans and avascular necrosis of the mandibular condyle. *Am J Neuroradiol*. 1989; 10: 3–12. <https://doi.org/10.2214/ajr.152.3.551> PMID: 2783809
24. Schellhas KP, Wilkes CH. Temporomandibular joint inflammation: comparison of MR fast scanning with T1- and T2-weighted imaging techniques. *Am J Roentgenol*. 1989; 153: 93–98. <https://doi.org/10.2214/ajr.153.1.93> PMID: 2735304
25. Vogler JB 3rd, Murphy WA. Bone marrow imaging. *Radiology*. 1988; 168: 679–693. <https://doi.org/10.1148/radiology.168.3.3043546> PMID: 3043546
26. Hamilton G, Yokoo T, Bydder M, Cruite I, Schroeder ME, Sirlin CB, et al. In vivo characterization of the liver fat 1HMR spectrum. *NMR Biomed*. 2011; 24: 784–90. <https://doi.org/10.1002/nbm.1622> PMID: 21834002
27. Karampinos DC, Ruschke S, Dieckmeyer M, Diefenbach M, Franz D, Gersing AS, et al. Quantitative MRI and spectroscopy of bone marrow. *J Magn Reson Imaging*. 2018; 47: 332–353. <https://doi.org/10.1002/jmri.25769> PMID: 28570033
28. Bernard CP, Liney GP, Manton DJ, Turnbull LW, Langton CM. Comparison of fat quantification methods: a phantom study at 3.0T. *J Magn Reson Imaging*. 2008; 27: 192–197. <https://doi.org/10.1002/jmri.21201> PMID: 18064714
29. Kise Y, Chikui T, Yamashita Y, Kobayashi K, Yoshiura K. Clinical usefulness of the mDIXON Quant the method for estimation of the salivary gland fat fraction: comparison with MR spectroscopy. *Br J Radiol*. 2017; 90: 20160704. <https://doi.org/10.1259/bjr.20160704> PMID: 28707990
30. Disler D, McCauley T, Ratner L, Kesack C, Cooper J. In-phase and out-of-phase MR imaging of bone marrow: prediction of neoplasia based on the detection of coexistent fat and water. *Am J Roentgenol*. 1997; 169: 1439–1447. <https://doi.org/10.2214/ajr.169.5.9353477> PMID: 9353477
31. Zajick DC Jr, Morrison WB, Schweitzer ME, Parellada JA, Carrino JA. Benign and malignant processes: normal values and differentiation with chemical shift MR imaging in vertebral marrow. *Radiology*. 2005; 237: 590–596. <https://doi.org/10.1148/radiol.2372040990> PMID: 16244268
32. Suenaga S, Hamamoto S, Kawano K, Higashida Y, Norikura T. Dynamic MR imaging of the temporomandibular joint in patients with arthrosis: relationship between contrast enhancement of the posterior disk attachment and joint pain. *Am J Roentgenol*. 1996; 166: 1475–1481. <https://doi.org/10.2214/ajr.166.6.8633468> PMID: 8633468
33. Takahasi T, Nagai H, Seki H, Fukuda M. Relationship between joint effusion, joint pain, and protein levels in joint lavage fluid of patients with internal derangement and osteoarthritis of the temporomandibular joint. *J Oral Maxillofac Surg*. 1999; 57: 1187–1193. [https://doi.org/10.1016/s0278-2391\(99\)90483-4](https://doi.org/10.1016/s0278-2391(99)90483-4) PMID: 10513864
34. Westesson P-L, Brooks SL. Temporomandibular joint: relationship between MR evidence of effusion and the presence of pain and disk displacement. *Am J Roentgenol*. 1992; 159: 559–563. <https://doi.org/10.2214/ajr.159.3.1503025> PMID: 1503025

35. Larheim TA, Katzberg RW, Westesson P-L, Tallents RH, Moss ME. MR evidence of temporomandibular joint fluid and condyle marrow alterations: occurrence in asymptomatic volunteers and symptomatic patients. *Int J Oral Maxillofac Surg.* 2001; 30: 113–117. <https://doi.org/10.1054/ijom.2000.0018> PMID: 11405445
36. Sano T. Recent developments in understanding temporomandibular joint disorders. Part1: bone marrow abnormalities of the mandibular condyle. *Dentomaxillofac Radiol.* 2000; 29: 7–10. <https://doi.org/10.1038/sj/dmfr/4600492> PMID: 10654030
37. Sano T, Westesson PL, Larheim TA, Takagi R. The association of temporomandibular joint pain with abnormal bone marrow in the mandibular condyle. *J Oral Maxillofac Surg.* 2000; 58: 254–257. [https://doi.org/10.1016/s0278-2391\(00\)90141-1](https://doi.org/10.1016/s0278-2391(00)90141-1) PMID: 10716105
38. Emshoff R, Brandlmaier I, Bertram S, Rudisch A. Relative odds of temporomandibular joint pain as a function of magnetic resonance imaging findings of internal derangement, osteoarthritis, effusion, and bone marrow edema. *Oral Surg Oral Med Oral Pathol Oral Radiol Endod.* 2003; 95: 437–445. <https://doi.org/10.1067/moe.2003.95> PMID: 12686927.
39. Sano T, Westesson PL, Yamamoto M, Okano T. Differences in temporomandibular joint pain and age distribution between marrow edema and osteonecrosis in the mandibular condyle. *Cranio.* 2004; 22: 283–288. <https://doi.org/10.1179/crn.2004.035> PMID: 15532312.
40. Chiba M, Kumagai M, Fukui N, Echigo S. The relationship of bone marrow edema pattern in the mandibular condyle with joint pain in patients with temporomandibular joint disorders: longitudinal study with MR imaging. *Int J Oral Maxillofac Surg.* 2006; 35: 55–59. <https://doi.org/10.1016/j.ijom.2005.04.020> PMID: 15964172
41. Wahaj A, Hafeez K, Zafar MS. Association of bone marrow edema with temporomandibular joint (TMJ) osteoarthritis and internal derangements. *Cranio.* 2017; 35: 4–9. <https://doi.org/10.1080/08869634.2016.1156282> PMID: 27077262
42. Larheim TA, Westesson PL, Sano T. MR grading of temporomandibular joint fluid: association with disk displacement categories, condyle marrow abnormalities and pain. *Int J Oral Maxillofac Surg.* 2001; 30: 104–112. <https://doi.org/10.1054/ijom.2000.0017> PMID: 11405444
43. Koo BS, Song Y, Shin JH, Lee S, Kim TH. Evaluation of disease chronicity by bone marrow fat fraction using sacroiliac joint magnetic resonance imaging in patients with spondyloarthritis: A retrospective study. *Int J Rheum Dis.* 2019; 22(4):734–741. <https://doi.org/10.1111/1756-185X.13485> PMID: 30740910.
44. Ning Q, Fan T, Tang J, Han S, Wang W, Ren H, et al. Preliminary analysis of interaction of the fat fraction in the sacroiliac joint among sex, age, and body mass index in a normal Chinese population. *J Int Med Res.* 2020; 48(7): 300060520931281. <https://doi.org/10.1177/0300060520931281> PMID: 32723110.
45. Kaneda T, Minami M, Ozawa K, Akimoto Y, Okada H, Yamamoto H, et al. Magnetic resonance appearance of bone marrow in the mandible at different ages. *Oral Surg Oral Med Oral Pathol Oral Radiol Endod* 1996; 82: 229–233. [https://doi.org/10.1016/s1079-2104\(96\)80262-9](https://doi.org/10.1016/s1079-2104(96)80262-9) PMID: 8863315.