

University of Massachusetts Medical School  
**eScholarship@UMMS**

---

Radiology Publications

Radiology

---

2021-03-15


## Pivotal trial of the Neuroform Atlas stent for treatment of posterior circulation aneurysms: one-year outcomes

Brian T. Jankowitz  
*Cooper University Hospital*

*Et al.*

Let us know how access to this document benefits you.

Follow this and additional works at: [https://escholarship.umassmed.edu/radiology\\_pubs](https://escholarship.umassmed.edu/radiology_pubs)

 Part of the [Cardiovascular Diseases Commons](#), [Neurology Commons](#), [Neurosurgery Commons](#), and the [Radiology Commons](#)

---

### Repository Citation

Jankowitz BT, Puri AS. (2021). Pivotal trial of the Neuroform Atlas stent for treatment of posterior circulation aneurysms: one-year outcomes. Radiology Publications. <https://doi.org/10.1136/neurintsurg-2020-017115>. Retrieved from [https://escholarship.umassmed.edu/radiology\\_pubs/610](https://escholarship.umassmed.edu/radiology_pubs/610)

Creative Commons License



This work is licensed under a [Creative Commons Attribution-NonCommercial 4.0 License](https://creativecommons.org/licenses/by-nc/4.0/)  
This material is brought to you by eScholarship@UMMS. It has been accepted for inclusion in Radiology Publications by an authorized administrator of eScholarship@UMMS. For more information, please contact [Lisa.Palmer@umassmed.edu](mailto:Lisa.Palmer@umassmed.edu).



OPEN ACCESS

Original research

# Pivotal trial of the Neuroform Atlas stent for treatment of posterior circulation aneurysms: one-year outcomes

Brian T Jankowitz,<sup>1</sup> Ashutosh P Jadhav,<sup>2</sup> Bradley Gross,<sup>3</sup> Tudor G Jovin,<sup>4</sup> Abdunnasser A Alhajeri,<sup>5</sup> Justin F Fraser ,<sup>6</sup> Ricardo A Hanel ,<sup>7</sup> Eric Sauvageau,<sup>8</sup> Amin Aghaebrahim ,<sup>9</sup> Donald Frei ,<sup>10</sup> Richard Bellon,<sup>10</sup> David Loy,<sup>11</sup> Ajit S Puri,<sup>12</sup> Adel M Malek ,<sup>13</sup> Ajith Thomas ,<sup>14</sup> Gabor Toth ,<sup>15</sup> Demetrius Klee Lopes ,<sup>16</sup> R Webster Crowley,<sup>17</sup> Adam S Arthur ,<sup>18,19</sup> John Reavey-Cantwell,<sup>20</sup> Eugene Lin,<sup>21</sup> Adnan H Siddiqui,<sup>22</sup> Michael J Alexander ,<sup>23</sup> Ahmad Khaldi,<sup>24</sup> Geoffrey P Colby ,<sup>25</sup> Justin M Caplan ,<sup>26</sup> Sudhakar R Satti,<sup>27</sup> Aquilla S Turk,<sup>28</sup> Alejandro M Spiotta,<sup>29</sup> Richard Klucznik,<sup>30</sup> Danial K Hallam,<sup>31</sup> David Kung ,<sup>32</sup> Michael T Froehler,<sup>33</sup> R Charles Callison,<sup>34</sup> Peter Kan ,<sup>35</sup> Steven W Hetts ,<sup>36</sup> Osama O Zaidat

► Prepublication history and additional material are published online only. To view please visit the journal online (<http://dx.doi.org/10.1136/neurintsurg-2020-017115>).

For numbered affiliations see end of article.

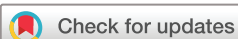## Correspondence to

Dr Brian T Jankowitz, Cooper Neurological Institute, Cooper University Hospital, Camden, NJ 08103, USA; [jankowitz-brian@cooperhealth.edu](mailto:jankowitz-brian@cooperhealth.edu)

Received 19 November 2020

Revised 15 February 2021

Accepted 19 February 2021



© Author(s) (or their employer(s)) 2021. Re-use permitted under CC BY-NC. No commercial re-use. See rights and permissions. Published by BMJ.

**To cite:** Jankowitz BT, Jadhav AP, Gross B, *et al.* *J NeuroIntervent Surg* Epub ahead of print: [please include Day Month Year]. doi:10.1136/neurintsurg-2020-017115

## ABSTRACT

**Background** Stent-assisted coiling of wide-necked intracranial aneurysms (IAs) using the Neuroform Atlas Stent System (Atlas) has shown promising results.

**Objective** To present the primary efficacy and safety results of the ATLAS Investigational Device Exemption (IDE) trial in a cohort of patients with posterior circulation IAs.

**Methods** The ATLAS trial is a prospective, multicenter, single-arm, open-label study of unruptured, wide-necked, IAs treated with the Atlas stent and adjunctive coiling. This study reports the results of patients with posterior circulation IAs. The primary efficacy endpoint was complete aneurysm occlusion (Raymond-Roy (RR) class I) on 12-month angiography, in the absence of re-treatment or parent artery stenosis >50%. The primary safety endpoint was any major ipsilateral stroke or neurological death within 12 months. Adjudication of the primary endpoints was performed by an imaging core laboratory and a Clinical Events Committee.

**Results** The ATLAS trial enrolled and treated 116 patients at 25 medical centers with unruptured, wide-necked, posterior circulation IAs (mean age 60.2±10.5 years, 81.0% (94/116) female). Stents were placed in all patients with 100% technical success rate. A total of 95/116 (81.9%) patients had complete angiographic follow-up at 12 months, of whom 81 (85.3%) had complete aneurysm occlusion (RR class I). The primary effectiveness outcome was achieved in 76.7% (95% CI 67.0% to 86.5%) of patients. Overall, major ipsilateral stroke and secondary persistent neurological deficit occurred in 4.3% (5/116) and 1.7% (2/116) of patients, respectively.

**Conclusions** In the ATLAS IDE posterior circulation cohort, the Neuroform Atlas Stent System with adjunctive coiling demonstrated high rates of technical and safety performance.

**Trial registration number** <https://clinicaltrials.gov/ct2/show/NCT02340585>.

## INTRODUCTION

Wide-necked intracranial aneurysms (IAs) (neck ≥4 mm, dome-to-neck ratio <2) constitute at least 40% of all IAs,<sup>1–3</sup> and are difficult to treat with endovascular coiling alone given the propensity for coils to herniate into the parent artery.<sup>4,5</sup> Stent-assisted coiling (SAC) is a well-established endovascular treatment,<sup>6–9</sup> which reconstructs the aneurysm neck, prevents coil herniation into the parent artery, and theoretically expedites aneurysm healing by creating a scaffold for endothelial coverage.<sup>5,10</sup>

The Neuroform stent system (Stryker Neurovascular, Fremont, California, USA) was first approved by the United States Food and Drug Administration (FDA) in 2002. Since then, newer stent iterations, such as Neuroform EX and EZ3, have been approved. The Neuroform Atlas Stent System (Atlas) is the newest generation.<sup>9,11–13</sup> The device was designed to scaffold the aneurysm neck and support the placement of detachable, intrasaccular coils. Significant design advances include improved trackability and a smaller cell size, which provides better coil retention within the aneurysm. The Atlas stent design also allows for its delivery via a lower profile, 0.0165 inch (internal diameter) microcatheter as compared with the 0.027 inch microcatheter required for the original Neuroform stent. Finally, the new hybrid cell design, with closed cells at the proximal end, improves recrossing and enhances stability within the vessel, while the classic central open-cell design provides excellent wall apposition, conformability, and flexibility.

In a previous prospective Neuroform Atlas investigational device exemption (IDE) study of 182 patients with anterior circulation IAs, SAC via the Atlas stent demonstrated high rates of complete occlusion at the 12-month angiographic follow-up,<sup>14,15</sup> as well as promising safety profiles in the anterior cerebral circulation.<sup>11</sup> In this study,

we present the primary efficacy and safety results of the ATLAS IDE trial in a cohort of patients with posterior circulation IAs.

## METHODS

### Study design

The ATLAS IDE trial is a prospective, multicenter, open-label, non-randomized, two-cohort, single-arm study that enrolled patients with wide-necked intracranial saccular aneurysms to be treated with SAC using the Atlas stent at 25 medical centers in the USA. Safety and efficacy endpoints were evaluated in a modified intention-to-treat cohort of patients who signed the informed consent form and in whom the investigational device entered the body. An imaging core laboratory and an independent Clinical Events Committee (CEC) adjudicated the primary efficacy and safety endpoints, respectively, to ensure consistency and accuracy of the data and minimize bias.

The institutional review board at each enrollment center approved the study protocol. Each patient completed a written informed consent prior to participation in the trial. All data were entered into a Health Insurance Portability and Accountability Act (HIPAA)-compliant electronic data capture system and monitored by the sponsor and a contract research organization. The data used to support the conclusions of this trial will be furnished, on reasonable requests, by the corresponding author.

### Patient enrollment

Enrollment for patients with posterior circulation IAs (including vertebral, basilar, and posterior cerebral arteries) took place between June 2015 and December 2017. Clinical investigators and designated research staff at each center managed patient identification, recruitment, and enrollment. Patients were considered enrolled in the study once the site investigator determined that they met all trial inclusion/exclusion criteria and provided the signed informed consent form. The full study enrollment criteria are provided in online supplemental table 1). Briefly, patients were included if they were 18–80 years old and had a documented, wide-necked (neck  $\geq 4$  mm or dome-to-neck ratio  $< 2$ ), intracranial, saccular aneurysm arising from a parent vessel with a diameter of 2.0–4.5 mm. The following criteria were used to determine study exclusion: multiple untreated IAs requiring treatment, acute target aneurysm rupture  $< 14$  days prior to study treatment, modified Rankin Scale (mRS) score of  $\geq 4$  or Hunt and Hess scale score  $\geq 3$ , intracranial mass or cerebral vascular malformation, a target aneurysm in the anterior circulation proximal to the superior hypophyseal internal carotid artery, previous treatment with SAC embolization, a known absolute contraindication to angiography or antiplatelet therapy, Moyamoya disease, or underlying parent artery atherosclerosis.

### Procedure description

The procedure was previously described in detail in the primary results of the ATLAS humanitarian device exemption study.<sup>16</sup> In brief, all patients undergoing treatment were premedicated with dual antiplatelet therapy (aspirin and clopidogrel) for at least 5 days. Platelet reactivity testing was not mandated. All procedures were performed under general anesthesia, and anticoagulation was managed according to each study site standard of care with a recommended activated clotting time of 250–300 s during the procedure. Atlas was deployed using an Excelsior SL-10 or XT-17 (Stryker Neurovascular, Fremont, California, USA) microcatheter via a transfemoral, radial, or brachial percutaneous approach. Dual antiplatelet therapy was maintained for at least 3 months following stent implantation.

### Follow-up evaluation

After the implant procedure, all treated patients had follow-up evaluations within 72 hours of the procedure, prior to hospital discharge, and at 2, 6, and 12 months. Data were collected to assess primary and secondary endpoints. Data consisted of neurological assessments (National Institutes of Health Stroke Scale (NIHSS), mRS), antiplatelet medication, and quality-of-life assessment (EQ-5D-3L)). Hunt and Hess scores were recorded for patients who had evidence of aneurysm rupture and subarachnoid hemorrhage (SAH). Digital subtraction angiography (DSA) was performed at 12 months to evaluate the grade of aneurysm occlusion and parent vessel stenosis.

### Primary efficacy outcome

The primary efficacy endpoint was complete aneurysm occlusion (defined as 100% occlusion of the aneurysm or Raymond-Roy (RR) class I)<sup>14,15</sup> at 12-month follow-up DSA, in the absence of re-treatment or parent artery stenosis ( $> 50\%$ ). Angiographic occlusion was assessed by an independent imaging core laboratory, blinded to assessments made by the clinical sites, to avoid bias. The University of California San Francisco (UCSF) interventional radiology core laboratory provided angiographic evaluation of anonymized patients in the ATLAS trial. For this specific project, the angiogram reader was SWH, who has over 15 years' experience in the interpretation of cerebral angiograms and the endovascular treatment of brain aneurysms.

### Primary safety outcome

The primary safety endpoint was any incidence of major ipsilateral stroke, defined as an ipsilateral stroke with an increase of four or more points on the NIHSS assessment at 24 hours after symptoms' onset, or neurological death within 12 months postprocedure. An independent CEC adjudicated prespecified primary endpoint events and serious device-related events. The threshold for the primary safety endpoint event rate was set at  $< 25\%$  for the posterior circulation cohort in the ATLAS trial, which was established after reviewing data extracted from the MAPS trial<sup>3</sup> wide-necked aneurysm patient cohort as well as published rates of procedural and long-term morbidity and mortality.

### Secondary outcomes

Secondary efficacy endpoints were assessed after the index procedure through 12 months, and included procedural technical success (defined as the proportion of patients in whom the Atlas stent was successfully delivered and deployed at the target location), rates of target aneurysm occlusion across RR classes, re-treatment, recanalization, progressive occlusion of the target aneurysm, incidence of parent artery stenosis ( $> 50\%$  stenosis), and stent migration.

Secondary safety endpoints were any serious adverse events (SAEs) through 12 months following the procedure, including any incidence of new or worsening major ipsilateral stroke as measured by the NIHSS, device-related SAE, target aneurysm rupture, and SAH.

### Statistical analysis

Descriptive statistics were compiled for baseline variables, procedural characteristics, and endpoints. Continuous and ordinal variables are summarized as mean (SD), median, and IQR. Median and interquartile range are reported when distribution of a variable is visually skewed from normal distribution.

**Table 1** Baseline characteristics of the ATLAS trial posterior circulation cohort

Characteristics	Summary statistics (n=116)
<b>Demographics</b>	
Age	60.2±10.5
Female	81.0% (94)
White	91.4% (106)
<b>Target aneurysm characteristics (site-reported)</b>	
Aneurysm neck width (mm)	4.7±1.7
Aneurysm size (mm)	7.1±3.0
Dome:neck ratio	1.2±0.3
Parent vessel diameter proximal to the aneurysm neck (mm)	2.9±0.6
Parent vessel diameter distal to the aneurysm neck (mm)	2.4±0.5
<b>Target aneurysm location</b>	
Arising from the mid aspect of the PComA	1 (0.9%)
Basilar apex	88 (75.9%)
Basilar trunk	7 (6.0%)
Superior cerebellar artery	5 (4.3%)
Posterior inferior cerebellar artery	5 (4.3%)
Vertebral artery	5 (4.3%)
Vertebrobasilar junction	2 (1.7%)
Other*	3 (2.6%)

Data are mean±SD, or n (%).

\*Persistent trigeminal artery, fetal posterior cerebral artery, and posterior cerebral artery.

ATLAS, Assessment of Treatment with Lisinopril and Survival; PComA, posterior communicating artery.

Percentages and numerators, denominators are presented for categorical and binary variables.

The proportion of patients who met the primary endpoints were compared with performance goals using the one-sided Fisher's exact test with a significance level of  $\alpha=0.025$ . The performance goals were determined a priori based on a meta-analysis as well as regulatory and medical considerations. Analyses for posterior circulation cohorts were performed by constructing two-sided, 95% confidence intervals about the estimates of the percentage of patients with complete aneurysm occlusion and the percentage of patients experiencing a major ipsilateral stroke or neurological death using the exact binomial (Clopper-Pearson) method. Success in the posterior circulation cohort occurred when the lower bound of the efficacy endpoint was above 50% and the upper bound of the safety endpoint was below 25%. Missing values are imputed. All analyses were performed using SAS software, version 9.4 (SAS Institute Inc., Cary, North Carolina, USA).

## RESULTS

A total of 124 patients with posterior circulation IAs were initially enrolled across 25 US centers. The modified intention-to-treat cohort included 93.5% (116/124) after the exclusion of eight patients (online supplemental figure 1). Mean patient age was 60.2±10.5 years, 81.0% (94/116) were female, and 91.4% (106/116) were Caucasian (table 1). The most frequent comorbidities were hypertension (67.2%; 78/116) and hyperlipidemia (49.1%; 57/116). The majority of patients were either current smokers (40.5%; 47/116) or past smokers (38.8%; 45/116). A history of previous hemorrhagic stroke or multiple aneurysms

was reported by 17.2% (20/116) and 17.2% (20/116) of patients, respectively. A total of 113 patients (97.4%) had a baseline mRS score  $\leq 2$ . Thirteen patients (11.2%) had experienced previous rupture of their target aneurysms, of whom 10 were treated with coiling only, while two were treated with balloon-assisted coiling. The other patient with a previously ruptured target aneurysm was untreated. The mean and median time from aneurysm rupture to stent placement was 800 and 189 days, respectively.

Target aneurysm characteristics are summarized in table 1.

## Intraprocedural and postprocedural results

All procedures were technically successful (100.0%; 116/116). Patients were implanted with one (65.5%; 76/116) or two (34.5%; 40/116) Atlas stents. Multi-stent constructs were preplanned. Stents were implanted successfully in 94.5% (156/165) of attempts. Nine device failures occurred among five patients. All cases involved inadvertent deployment in the catheter hub (seven) or the feeling of excess friction as the stent was advanced in the microcatheter requiring removal of the catheter. None of these stents was actually deployed in a patient and all cases were successfully completed with additional devices. The median procedure duration first puncture to wound closure was 109.0 min (IQR 85.0–140.0). Immediately postprocedure, complete occlusion (RR I) was achieved in 77.6% (90/116) of patients, residual aneurysm neck filling (RR II) in 19.0% (22/116), and residual aneurysm dome filling (RR III) in 3.4% (4/116).

## Primary endpoints

Of the 116 patients who completed the 12-month follow-up, 95 patients had DSA results available (table 2). The primary efficacy endpoint was achieved in 76.7% (95% CI 67.0% to 86.5%) of patients ( $p<0.001$  vs performance goal, missing values handled with multiple imputation). The rate of complete occlusion, according to the imaging core laboratory, was 85.3% (81/95, 95% CI 76.5% to 91.7%), while parent artery stenosis  $>50\%$  occurred in 2.1% (2/95, 95% CI 0.3% to 7.4%) of patients. The rate of re-treatment was 7.8% (9/116, 95% CI 3.6% to 14.2%). Of the nine patients who underwent re-treatment, 2.6% (3/116) had complete occlusion postprocedure but recanalized, 0.9% (1/116) had preplanned staged procedures (achieved complete occlusion after stage 2 operation), 2.6% (3/116) had residual neck, and 1.7% (2/116) had residual aneurysm that persisted on follow-up imaging.

The incidence of the primary safety endpoint (major ipsilateral stroke and/or neurological death) for all 116 patients was 4.3% (5/116, 95% CI 1.4% to 9.8%,  $p<0.001$ ; table 2). Major

**Table 2** Primary safety and efficacy endpoint rate through 12-month follow-up (CEC adjudicated)

Endpoint	Summary statistics (n=116)	95% CI	Performance goal	P value*
Primary efficacy endpoint†	76.7%	(67.0% to 86.5%)	50%	<0.001
Primary safety endpoint	5 (4.3%)	(1.4% to 9.8%)	25%	<0.001
Major ipsilateral stroke	4 (3.4%)	(0.9% to 8.6%)		
Neurologic death	1 (0.9%)	(0.0% to 4.7%)		

\*One-sided binomial exact test of success against the performance goal at 12 months ( $\alpha=0.025$ ).

†Multiple imputation for missing data.  
CEC, Clinical Events Committee.

## Hemorrhagic stroke

ipsilateral stroke occurred in 3.4% (4/116, 95% CI 0.9% to 8.6%) of patients, while neurological death occurred in 0.9% (1/116, 95% CI 0.0% to 4.7%) of patients. This neurological death was the result of subdural hematoma and related severe pneumonia aspiration after experiencing a fall 75 days post-procedure. Of the five patients who experienced unfavorable primary safety outcomes, 1.7% (2/116) recovered with no residual deficit on subsequent follow-up,

### Secondary efficacy endpoints

Secondary endpoints were evaluated at the 12-month follow-up DSA (table 3). The majority of the 95 patients with available DSA results had RR I occlusion of the target aneurysm at a rate of 85.3% (81/95, 95% CI 76.5% to 91.7%). The rate of RR II occlusion of the target aneurysm was 9.5% (9/95, 95% CI 4.4% to 17.2%), and for RR III was 5.3% (5/95, 95% CI 1.7% to 11.9%). Ninety of the 95 subjects had combined RR I and II (94.7%, 95% CI 88.1% to 98.3%).

Most patients had the same (71.6%; 68/95, 95% CI 61.4% to 80.4%) or improved (17.9%; 17/95, 95% CI 10.8% to 27.1%) occlusion status of their target aneurysms compared with immediate postprocedure RR scores. Only 10.5% (10/95, 95% CI 5.2% to 18.5%) of patients had worse occlusion status compared with immediate postprocedure RR scores. For clinical outcome at 12 months' follow-up, 93.1% (95/102) of patients had an mRS score of 0–1, while 96.1% (98/102) had an mRS score of 0–2. There was no reported occurrence of stent migration (0.0%; 0/95, 95% CI 0.0% to 3.8%).

### Secondary safety endpoints

According to CEC adjudication, four patients experienced new or worsening major ipsilateral stroke (table 4), and these four patients were the same subjects who experienced the primary

**Table 4** Secondary safety endpoints through 12-month follow-up

Secondary safety endpoint	Summary statistics	
	(n=116)	95% CI
New or worsening major ipsilateral stroke (CEC-adjudicated)	4 (3.4%)	(0.9% to 8.6%)
Subarachnoid hemorrhage (CEC-adjudicated)*	2 (1.7%)	(0.2% to 6.1%)
Aneurysm rupture (CEC-adjudicated)*	1 (0.9%)	(0.0% to 4.7%)
Device-related serious adverse event (site-reported)	11 (9.5%)	(4.8% to 16.3%)

Data are n (%).

\*One subject experienced a serious adverse effect (SAE) on postoperative day 1 that was site-reported as 'vessel dissection related to subarachnoid hemorrhage (SAH)' and possibly related to the device and was CEC-adjudicated as a major ipsilateral stroke, aneurysm rupture, and SAH'. This single event is therefore captured in four separate secondary endpoint categories (ie, new or worsening ipsilateral stroke, SAH, aneurysm rupture, and device-related SAE). CEC, Clinical Events Committee.

safety endpoint of major ipsilateral stroke. Two patients experienced SAH: one patient experienced only SAH, while the other experienced both SAH and aneurysm rupture, although neither were related to stent placement. The patient who had both SAH and aneurysm rupture also had major ipsilateral stroke and was one of the patients who experienced the primary safety endpoint of major ipsilateral stroke. Clinically, the two patients who experienced either SAH alone or both SAH and aneurysm rupture returned for their 12-month visit and their mRS score was 0. All SAEs that were site-reported as 'possibly', 'probably', or 'related' to the study device were classified as 'site-reported device-related SAEs'. This included 12 SAEs in 11 subjects. For two subjects, the events were also CEC-adjudicated as primary safety endpoint events (ie, major ipsilateral stroke). Four of the 11 subjects experienced site-reported device-related SAEs that were CEC-adjudicated as minor ischemic strokes. All four subjects had excellent long-term outcomes with mRS scores of 0 or 1 and NIHSS scores of 0 at their 6- and 12-month follow-up visits. Five of the 11 subjects experienced site-reported device-related SAEs that were CEC-adjudicated as not strokes (of any type), SAH, or aneurysm rupture. Three of these patients had target aneurysm re-treatment based on asymptomatic recanalization detected on routine follow-up imaging. Two of the five subjects had transient ischemic attacks, which occurred on postoperative days 45 and 113, respectively.

### DISCUSSION

The ATLAS IDE study included a cohort of 116 patients with wide-necked IAs located in the posterior circulation, making it the largest study using Atlas stents for this particular cohort of patients. In this study, SAC using Atlas was associated with excellent technical success and safety profile rates. Atlas SAC embolization provided a high rate of 12-month complete occlusion without stenosis or re-treatment in the majority of patients, with low incidence of safety endpoints. Therefore, Atlas SAC embolization successfully met both the efficacy and safety endpoints of the trial, indicating that Atlas represents an efficacious and safe treatment option for SAC embolization of wide-necked IAs in the posterior cerebral circulation. Based on these results, the FDA awarded specific approval for use of Atlas stents in the posterior circulation on July 30, 2020, making it the only adjunctive stent in the USA that has shown safety and effectiveness in the posterior neurovasculature.

Several meta-analyses of patients with wide-necked aneurysms who underwent SAC treatment in the anterior or posterior

**Table 3** Secondary efficacy endpoints at 12-month follow-up

Endpoint	Summary statistics	
	(n=116)	95% CI
Procedural technical success (per patient)	116/116 (100.0%)	
Subjects with one stent implanted	76/116 (65.5%)	
Subjects with two stents implanted	40/116 (34.5%)	
Raymond-Roy class (core laboratory)		
I	81/95 (85.3%)	(76.5% to 91.7%)
II	9/95 (9.5%)	(4.4% to 17.2%)
III	5/95 (5.3%)	(1.7% to 11.9%)
1 and 2 combined	90/95 (94.7%)	(88.1% to 98.3%)
Recanalization (1)	9/97 (9.3%)	(4.3% to 16.9%)
Any Raymond-Roy class change over time (core laboratory)		
Same	68/95 (71.6%)	(61.4% to 80.4%)
Better	17/95 (17.9%)	(10.8% to 27.1%)
Worse	10/95 (10.5%)	(5.2% to 18.5%)
Parent artery stenosis >50% (core laboratory)	2/95 (2.1%)	(0.3% to 7.4%)
Incidence of stent migration (core laboratory)	0/95 (0.0%)	(0.0% to 3.8%)
Incidence of re-treatment (site-reported)	9/116 (7.8%)	(3.6% to 14.2%)

Data are n (%).

\*Recanalization is defined as Raymond score of 3 at 12 month visit or retreatment due to recanalization.

circulation have been published.<sup>17–19</sup> The results of these studies suggest that stenting wide-necked aneurysms with earlier generation stents can result in RR I occlusion rates in the range of 69–73%, with mortality rates less than 2.5%. Recanalization rates ranged from 9% to 13%, and one analysis reported an aggregate re-treatment rate of 5.7%.<sup>19</sup> The results of our study demonstrate that treatment of wide-necked aneurysms with the Atlas stent results in comparable or improved outcomes compared with earlier generation stents.

Few studies have assessed efficacy and safety outcomes specific to the Atlas stent in wide-necked IAs. A recent retrospective analysis of a prospectively maintained database of 113 patients with wide-necked IAs in the anterior and posterior circulation reported a technical success rate of 100%.<sup>20</sup> Complete occlusion (RR I) was achieved in 88% and 82% of patients immediately postprocedure and at the 12-month follow-up, respectively. At the 6-month follow-up, 96.5% (109/113) of patients had an mRS score of 0–1, with a mortality rate of 2.7% (3/113) mostly due to SAH, and a morbidity rate of 0.85%.<sup>20</sup> Another retrospective study of 37 patients at three centers using the Atlas stent also demonstrated a technical success rate of 100%. Complete occlusion (RR I) was achieved in 83.8% (31/37) and 80.8% (21/26) immediately postprocedure and at the 6-month follow-up, respectively, while neurological morbidity was reported in 2.7% (1/37) of patients at the 6-month follow-up.<sup>13</sup> Tsai *et al* reported their 1-year results using Atlas stent-assisted coil embolization, which examined the efficacy and safety outcomes at discharge of 58 patients with 76 Atlas stents. In that retrospective study, 40 patients were treated with a single stent, 15 with a Y-stent, and three with an X-stent configuration.<sup>21</sup> The immediate RR I occlusion rate was 70.7% (41/58), with no neurological morbidity and an mRS score of 0 (IQR 0–1).<sup>21</sup> These studies were retrospective in nature, used low to moderate numbers of patients,<sup>13 21 22</sup> did not collect long-term follow-up data,<sup>21</sup> and included heterogeneous IAs with respect to status, size, and location. The ATLAS IDE of wide-necked IAs in the posterior circulation has examined many of these limitations, and the results are specific to the posterior circulation.

The Low-profile Visualized Intraluminal Support (LVIS and LVIS Jr) stents (MicroVention, Aliso Viejo, California, USA) were the first neurovascular stents approved for SAC embolization of anterior circulation IAs in the USA. The efficacy and safety results for the Atlas stent were similar to those of the US LVIS pivotal multicenter trial of 153 patients with wide-necked IAs in the anterior and posterior circulation at 12 months.<sup>23</sup> Direct comparisons are difficult, but a recent study compared Atlas (37 patients) and LVIS Jr (27 patients) stent-assisted aneurysm coiling, after controlling for location, size, coiling technique, and coil packing density.<sup>12</sup> That study observed greater rates of complete occlusion (RR I) with Atlas than with LVIS Jr (57% vs 41%), and this difference remained at follow-up (12.7 months; 100% vs 81% (17/21)). The study also detected a significantly lower rate of in-stent restenosis with Atlas (0% vs 19% (4/21)) along with similar re-treatment rates (0%).<sup>12</sup>

### Limitations

The main limitation of ATLAS IDE is the single-arm nature of the study; thus, there was no direct comparative analysis with another aneurysm treatment device. However, this study had a relatively large sample size, and the study characteristics, including the independent core laboratory, CEC, and prospective study design, were all meant to mitigate potential bias.

### SUMMARY

In the ATLAS IDE posterior circulation study, Atlas SAC embolization demonstrated excellent technical success as well as promising efficacy and safety profiles in patients with wide-necked IAs in the posterior circulation. This was shown by the high rates of angiographic

complete occlusion of IAs at 12 months and the low rates of serious neurological events and mortality. Therefore, the Neuroform Atlas Stent System is an effective and safe treatment option for patients with wide-necked, posterior circulation IAs.

### Author affiliations

- <sup>1</sup>Cooper Neurological Institute, Cooper University Hospital, Camden, New Jersey, USA
- <sup>2</sup>Barrow Neurological Institute, Phoenix, Arizona, USA
- <sup>3</sup>Department of Neurosurgery, University of Pittsburgh Medical Center, Pittsburgh, PA, USA
- <sup>4</sup>Department of Neurology, Cooper University Hospital, Camden, New Jersey, USA
- <sup>5</sup>Department of Diagnostic Radiology, Riverside Radiology and Interventional Associates Inc, Columbus, Ohio, USA
- <sup>6</sup>Department of Neurological Surgery, University of Kentucky, Lexington, Kentucky, USA
- <sup>7</sup>Baptist Health System Jacksonville, Jacksonville, Florida, USA
- <sup>8</sup>Lyerly Neurosurgery, Baptist Neurological Institute, Jacksonville, Florida, USA
- <sup>9</sup>Neurological Institute, Lyerly Neurosurgery, Baptist Medical Center Jacksonville, Jacksonville, Florida, USA
- <sup>10</sup>Department of Interventional Neuroradiology, Radiology Imaging Associates, Englewood, Colorado, USA
- <sup>11</sup>Department of Radiology, University of Virginia Medical Center, Charlottesville, Virginia, USA
- <sup>12</sup>Department of Radiology, University of Massachusetts, Worcester, Massachusetts, USA
- <sup>13</sup>Department of Neurosurgery, Tufts Medical Center, Boston, Massachusetts, USA
- <sup>14</sup>Department of Surgery, Division of Neurosurgery, Beth Israel Deaconess Medical Center, Boston, Massachusetts, USA
- <sup>15</sup>Cerebrovascular Center, Cleveland Clinic, Cleveland, OH, USA
- <sup>16</sup>Brain and Spine Institute, Advocate Aurora Health, Park Ridge, Illinois, USA
- <sup>17</sup>Rush University, Chicago, Illinois, USA
- <sup>18</sup>Semmes-Murphey Neurologic and Spine Institute, Memphis, Tennessee, USA
- <sup>19</sup>Department of Neurosurgery, University of Tennessee Health Science Center, Memphis, Tennessee, USA
- <sup>20</sup>Virginia Commonwealth University, Richmond, Virginia, USA
- <sup>21</sup>Neuroscience Department, Mercy Health St Vincent Medical Center Department of Internal Medicine, Toledo, Ohio, USA
- <sup>22</sup>Department of Neurosurgery, University at Buffalo, Buffalo, New York, USA
- <sup>23</sup>Department of Neurosurgery, Cedars-Sinai Medical Center, Los Angeles, California, USA
- <sup>24</sup>Department of Neurosurgery, Wellstar Health System, Marietta, Georgia, USA
- <sup>25</sup>Department of Neurosurgery, University of California Los Angeles, Los Angeles, California, USA
- <sup>26</sup>Department of Neurosurgery, Johns Hopkins University School of Medicine, Baltimore, Maryland, USA
- <sup>27</sup>Department of Neurointerventional Surgery, CCHS, Newark, Delaware, USA
- <sup>28</sup>Department of Neuroradiology, Prisma Helath, Greenville, South Carolina, USA
- <sup>29</sup>Department of Neurosurgery, Medical University of South Carolina, Charleston, South Carolina, USA
- <sup>30</sup>Division of Interventional Neuroradiology, Houston Methodist Hospital, Houston, Texas, USA
- <sup>31</sup>Department of Radiology, University of Washington, Seattle, Washington, USA
- <sup>32</sup>Department of Neurosurgery, University of Pennsylvania, Philadelphia, Pennsylvania, USA
- <sup>33</sup>Cerebrovascular Program, Vanderbilt University, Nashville, Tennessee, USA
- <sup>34</sup>Department of Interventional Neurology, Lawnwood Regional Medical Center and Heart Institute, Fort Pierce, Florida, USA
- <sup>35</sup>Department of Neurosurgery, Baylor College of Medicine, Houston, Texas, USA
- <sup>36</sup>Department of Radiology, UCSF, San Francisco, California, USA
- <sup>37</sup>Department of Neuroscience, St Vincent Mercy Hospital, Toledo, Ohio, USA

**Twitter** Amin Aghaebrahim @drnimajax, Donald Frei @donfreimd, Gabor Toth @GaborTothMD, Demetrius Klee Lopes @cure4stroke, Adam S Arthur @AdamArthurMD and Peter Kan @PeterKa80460001

**Acknowledgements** The authors acknowledge Superior Medical Experts for editing and technical writing assistance.

**Contributors** All authors made substantial contributions to the conception and design, analysis, and interpretation of data; drafted or critically revised the article; and gave final approval of the version to be published.

**Funding** The ATLAS trial (Safety and Effectiveness of the Treatment of Wide Necked, Saccular Intracranial Aneurysms with the Neuroform Atlas Stent System) was funded by Stryker Neurovascular.

**Competing interests** BTJ: consultant for Stryker and a consultant/proctor for

Medtronic. Ooz: research grant from Stryker, Medtronic, Cerenovus, Penumbra, and Genentech; consultant and speaker for Cerenovus, Stryker, Penumbra, and Medtronic; has ownership interest in Galaxy Therapeutics LLC; and serves on the endovascular committee as co-chair for National Institutes of Health StrokeNet Consortium and has served as an expert witness. SWH: Core Laboratory Services for Stryker and MicroVention Terumo (money paid to UCSF, over \$5k); consulting for Microvention Terumo (money paid to SWH, under \$5k). APJ: reports no conflicts. BG: consultant for Medtronic and Microvention. TGJ: consultant at Cerenovus (steering committee/DSMB—modest), Stryker Neurovascular (PI DAWN (DWI or CTP Assessment with Clinical Mismatch in the Triage of Wake-Up and Late Presenting Strokes Undergoing Neurointervention With Trevo)—unpaid); holds Stock at Anaconda, Blockade Medical, Route 92, Corindus, FreeOx Biotech, Viz.ai, Silk Road. JFF: equity - Fawkes Biotechnology, Cerelux, LLC; consultant: Medtronic, Penumbra, Stream Biomedical. RAH: research Grant: Medtronic, Stryker, Microvention, Cerenovus; consultant: Stryker, Medtronic, Cerenovus, Microvention; stockholder: Neurvana, Elum, EndoStream, Three Rivers Medical Inc, Rist, Cerebrotech, InNeuroCo; Scientific Advisor: MIVI, Elum, Three Rivers Medical Inc, Shape Medical. ES: reports a speakers' agreement with Stryker. AA: reports no conflicts. DF: consultant/speakers bureau for Stryker; consultant/speakers bureau for Siemens, Penumbra, Philips, Genentech, Viz.AI; Scientific Advisory Board for Shape Memory Medical. AMM: consulting fees/honoraria: Microvention-Terumo Inc., Stryker Inc; major stock shareholder/equity: Cerevasc LLC; ownership/founder: Cerevasc LLC; intellectual property rights: Cerevasc LLC, Tufts Medical Center. AT: SCENT data safety monitoring board, funds paid to the institution. GT: consultant to Dynamed, Medtronic, and Microvention. DKL: consultant for Stryker Neurovascular. MJA: consultant for Stryker Neurovascular. AHS: financial interest/investor/stock options/ownership for Amnis Therapeutics, Boston Scientific (for acquisition of Claret Medical), Buffalo Technology Partners, Inc., Cognition Medical, Endostream Medical, Ltd, Imperative Care, International Medical Distribution Partners, Q'Apel Medical, Inc, Rebound Therapeutics Corp., Rist Neurovascular, Inc, Serenity Medical, Inc, Silk Road Medical, Spinnaker Medical, Inc, Synchron; consultant/advisory board for Amnis Therapeutics, Boston Scientific, Cerenovus, Endostream Medical, Ltd, Imperative Care, Integra LifeSciences Corp., Medtronic, MicroVention, Penumbra, Q'Apel Medical, Inc., Rapid Medical, Rebound Therapeutics Corp, Serenity Medical, Inc, Silk Road Medical, Stryker, W.L. Gore & Associates National PI/Steering Committees: Cerenovus LARGE Trial and ARISE II Trial, mal Medtronic SWIFT PRIME and SWIFT DIRECT Trials; MicroVention FRED Trial and CONFIDENCE Study; MUSC POSITIVE Trial; Penumbra 3D Separator Trial, COMPASS Trial, INVEST Trial. PK: consultant for Stryker and Cerenovus; stockholder of InNeuroCo. MTF: grant funding from NIH, Medtronic, Microvention, Stryker, and Genentech; consultant for Medtronic, Stryker, Balt USA, Viz.ai, Genentech, Cerenovus, Corindus, and EndoPhys. AMS: research support from Stryker, Medtronic, and Penumbra; consulting for Stryker, Terumo, Penumbra, and Siemens. ASA: consultant for Johnson and Johnson, Medtronic, Microvention, Penumbra, Scientia, Siemens, Stryker; research support from Balt, Cerenovus, Medtronic, Microvention, Penumbra, Siemens, and Stryker; shareholder in Bendit, Cerebrotech, Endostream, Magneto, Marblehead, Mentice, Neurogami, Serenity, Synchron, Triad Medical. RWC: proctor for Medtronic and Cerenovus. SRS: consultant for Balt, Cerenovus, Cordis, Medtronic, Microvention, Terumo, Stryker. GPC: consultant and proctor for Stryker, MicroVention, and Medtronic. JMC: reports no disclosures. AAA: reports no disclosures. JRC: reports no disclosures. AK: reports no disclosures. RCC: consulting for Stryker. EL: reports no disclosures. AST: reports no disclosures. DL: reports no disclosures. DK: reports no disclosures. DKH: reports no disclosures. ASP: reports no disclosures. No CEC/DSMB members are from participating sites of the study. UCSF is not a participating site. RB and RK declare none.

**Patient consent for publication** Not required.

**Ethics approval** The study was performed in compliance with the World Medical Association's Declaration of Helsinki. The study protocol was approved by the local ethics committee or institutional review board.

**Provenance and peer review** Not commissioned; externally peer reviewed.

**Data availability statement** Data are available upon reasonable request. For inquiries, please contact: Brian T. Jankowitz, Associate Professor Neurosurgery Cooper University Hospital Camden, NJ 08103. Email: jankowitz-brian@CooperHealth.edu

**Open access** This is an open access article distributed in accordance with the Creative Commons Attribution Non Commercial (CC BY-NC 4.0) license, which permits others to distribute, remix, adapt, build upon this work non-commercially, and license their derivative works on different terms, provided the original work is properly cited, appropriate credit is given, any changes made indicated, and the use is non-commercial. See: <http://creativecommons.org/licenses/by-nc/4.0/>.

#### ORCID iDs

Justin F Fraser <http://orcid.org/0000-0002-5980-3989>  
Ricardo A Hanel <http://orcid.org/0000-0001-7195-5806>  
Amin Aghaebrahim <http://orcid.org/0000-0002-9126-2932>  
Donald Frei <http://orcid.org/0000-0002-7811-5030>

Adel M Malek <http://orcid.org/0000-0002-0642-7609>  
Ajith Thomas <http://orcid.org/0000-0003-4412-3152>  
Gabor Toth <http://orcid.org/0000-0002-3646-3635>  
Demetrius Klee Lopes <http://orcid.org/0000-0002-6280-0113>  
Adam S Arthur <http://orcid.org/0000-0002-1536-1613>  
Michael J Alexander <http://orcid.org/0000-0003-0280-809X>  
Geoffrey P Colby <http://orcid.org/0000-0002-3376-0933>  
Justin M Caplan <http://orcid.org/0000-0002-0289-3661>  
David Kung <http://orcid.org/0000-0002-1387-6082>  
Peter Kan <http://orcid.org/0000-0001-6649-4128>  
Steven W Hetts <http://orcid.org/0000-0001-5885-7259>  
Osama O Zaidat <http://orcid.org/0000-0003-4881-4698>

#### REFERENCES

- Murayama Y, Nien YL, Duckwiler G, et al. Guglielmi detachable coil embolization of cerebral aneurysms: 11 years' experience. *J Neurosurg* 2003;98:959–66.
- Imamura H, Sakai N, Sakai C, et al. Endovascular treatment of aneurysmal subarachnoid hemorrhage in Japanese Registry of Neuroendovascular Therapy (JR-NET) 1 and 2. *Neurol Med Chir* 2014;54:81–90.
- McDouglall CG, Johnston SC, Gholkar A, et al. Bioactive versus bare platinum coils in the treatment of intracranial aneurysms: the MAPS (Matrix and Platinum Science) trial. *AJNR Am J Neuroradiol* 2014;35:935–42.
- Chalouhi N, Jabbour P, Singhal S, et al. Stent-assisted coiling of intracranial aneurysms: predictors of complications, recanalization, and outcome in 508 cases. *Stroke* 2013;44:1348–53.
- Piotin M, Blanc R, Spelle L, et al. Stent-assisted coiling of intracranial aneurysms: clinical and angiographic results in 216 consecutive aneurysms. *Stroke* 2010;41:110–5.
- Mokin M, Primiani CT, Ren Z, et al. Stent-assisted coiling of cerebral aneurysms: multicenter analysis of radiographic and clinical outcomes in 659 patients. *J Neurointerv Surg* 2020;12:289–97.
- Ghinda D, Dos Santos MP, Sabri A, et al. Clinical and angiographic outcomes of stent-assisted coiling of intracranial aneurysms. *Interv Neuroradiol* 2015;21:146–54.
- Phan K, Huo YR, Jia F, et al. Meta-analysis of stent-assisted coiling versus coiling-only for the treatment of intracranial aneurysms. *J Clin Neurosci* 2016;31:15–22.
- Hetts SW, Turk A, English JD, et al. Stent-assisted coiling versus coiling alone in unruptured intracranial aneurysms in the matrix and platinum science trial: safety, efficacy, and mid-term outcomes. *AJNR Am J Neuroradiol* 2014;35:698–705.
- Wanke I, Forsting M. Stents for intracranial wide-necked aneurysms: more than mechanical protection. *Neuroradiology* 2008;50:991–8.
- Zaidat OO, Hanel RA, Sauvageau EA, et al. Pivotal trial of the Neuroform Atlas stent for treatment of anterior circulation aneurysms: one-year outcomes. *Stroke* 2020;51:2087–94.
- Gross BA, Ares WJ, Ducruet AF, et al. A clinical comparison of Atlas and LVIS Jr stent-assisted aneurysm coiling. *J Neurointerv Surg* 2019;11:171–4.
- Goertz L, Dorn F, Siebert E, et al. Safety and efficacy of the Neuroform Atlas for stent-assisted coiling of intracranial aneurysms: a multicenter experience. *J Clin Neurosci* 2019;68:86–91.
- Roy D, Milot G, Raymond J. Endovascular treatment of unruptured aneurysms. *Stroke* 2001;32:1998–2004.
- Raymond J, Guilbert F, Weill A, et al. Long-term angiographic recurrences after selective endovascular treatment of aneurysms with detachable coils. *Stroke* 2003;34:1398–403.
- Jankowitz BT, Hanel R, Jadhav AP, et al. Neuroform Atlas stent system for the treatment of intracranial aneurysm: primary results of the atlas humanitarian device exemption cohort. *J Neurointerv Surg* 2019;11:801–6.
- King B, Vaziri S, Singla A, et al. Clinical and angiographic outcomes after stent-assisted coiling of cerebral aneurysms with enterprise and Neuroform stents: a comparative analysis of the literature. *J Neurointerv Surg* 2015;7:905–9.
- McLaughlin N, McArthur DL, Martin NA. Use of stent-assisted coil embolization for the treatment of wide-necked aneurysms: a systematic review. *Surg Neurol Int* 2013;4:43.
- Zhao B, Yin R, Lanzino G, et al. Endovascular coiling of wide-neck and wide-neck bifurcation aneurysms: a systematic review and meta-analysis. *AJNR Am J Neuroradiol* 2016;37:1700–5.
- Caragliano AA, Papa R, Pitrone A, et al. The low-profile Neuroform Atlas stent in the treatment of wide-necked intracranial aneurysms - immediate and midterm results: an Italian multicenter registry. *J Neuroradiol* 2020;47:421–7.
- Tsai JP, Hardman J, Moore NZ, et al. Early post-humanitarian device exemption experience with the Neuroform Atlas stent. *J Neurointerv Surg* 2019;11:1141–4.
- Kim CH, Kim YH, Sung SK, et al. Clinical safety and effectiveness of atent-assisted coil embolization with Neuroform Atlas stent in intracranial aneurysm. *J Korean Neurosurg Soc* 2020;63:80–8.
- Fiorella D, Boulos A, Turk AS, et al. The safety and effectiveness of the LVIS stent system for the treatment of wide-necked cerebral aneurysms: final results of the pivotal US LVIS trial. *J Neurointerv Surg* 2019;11:357–61.