

Tilburg University

## Improvement of small fiber neuropathy in a sarcoidosis patient after treatment with infliximab

Hoitsma, E.; Faber, C.G.; van Santen-Hoeufft, M.; de Vries, J.; Reulen, J.P.H.; Drent, M.

*Published in:*  
Sarcoidosis Vasculitis and Diffuse Lung Diseases

*Publication date:*  
2006

*Document Version*  
Publisher's PDF, also known as Version of record

[Link to publication in Tilburg University Research Portal](#)

*Citation for published version (APA):*  
Hoitsma, E., Faber, C. G., van Santen-Hoeufft, M., de Vries, J., Reulen, J. P. H., & Drent, M. (2006). Improvement of small fiber neuropathy in a sarcoidosis patient after treatment with infliximab. *Sarcoidosis Vasculitis and Diffuse Lung Diseases*, 23(1), 73-77.

### General rights

Copyright and moral rights for the publications made accessible in the public portal are retained by the authors and/or other copyright owners and it is a condition of accessing publications that users recognise and abide by the legal requirements associated with these rights.

- Users may download and print one copy of any publication from the public portal for the purpose of private study or research.
- You may not further distribute the material or use it for any profit-making activity or commercial gain
- You may freely distribute the URL identifying the publication in the public portal

### Take down policy

If you believe that this document breaches copyright please contact us providing details, and we will remove access to the work immediately and investigate your claim.

## Improvement of small fiber neuropathy in a sarcoidosis patient after treatment with infliximab

Elske Hoitsma<sup>1, 5</sup>, Carin G. Faber<sup>1, 5</sup>, Marijke van Santen-Hoeyff<sup>2, 5</sup>, Jolanda De Vries<sup>5, 6</sup>, Jos P. H. Reulen<sup>4</sup>, Marjolein Drent<sup>3, 5</sup>

<sup>1</sup>Dept of Neurology, <sup>2</sup>Internal Medicine, <sup>3</sup>Respiratory Medicine, <sup>4</sup>Clinical Neurophysiology and <sup>5</sup>Sarcoidosis Management Center, University Hospital Maastricht, The Netherlands, <sup>6</sup>Department of Psychology and Health, Tilburg University and Research Institute Psychology and Health, Tilburg, The Netherlands

**Abstract.** We describe a patient with severe small fiber neuropathy (SFN) accompanied by autonomic involvement, who was experimentally treated with infliximab, an anti-tumour necrosis factor- $\alpha$  (TNF- $\alpha$ ) therapy. Six months after this treatment was started his symptoms completely resolved. Until now they did not return. Repeated temperature threshold testing (TTT) as well as cardiovascular autonomic function test clearly improved after one year therapy. This case reveals two important issues. First, it shows that SFN seems not an irreversible disorder, even in severe cases. Second, TNF- $\alpha$  may be a crucial cytokine in the pathogenesis of SFN in sarcoidosis and eventually also in other immune mediated inflammatory diseases. (*Sarcoidosis Vasc Diffuse Lung Dis* 2006, 23: 73-77)

**Key Words.** Small fiber neuropathy. Infliximab. Sarcoidosis.

Sarcoidosis is a multi-organ inflammatory disorder of unknown origin, characterized by T-lymphocyte and mononuclear phagocyte infiltration in the affected organs, granuloma formation, and distortion of the normal micro-architecture, which is probably antigen-driven [1]. The inflammatory process may be accelerated by the release of tumour necrosis factor- $\alpha$  (TNF- $\alpha$ ) from resident macrophages, resulting in further recruitment of inflammatory cells [2]. The

clinical manifestations of sarcoidosis are largely non-specific, dependent on the intensity of the inflammation and organ systems affected, of which the lung is the most prominent. Besides pulmonary symptoms many patients suffer from fatigue, pain and vegetative symptoms [3-5]. Recently, we found that small fiber neuropathy (SFN) is rather common in sarcoidosis patients [6].

While treatment of systemic sarcoidosis usually includes corticosteroids or other immunosuppressants such as methotrexate, treatment of SFN is unknown so far. In our experience corticosteroids and methotrexate are not beneficial in SFN related to sarcoidosis [7]. Therefore, symptoms of SFN become usually chronic, devastating and one of the major problems in sarcoidosis.

Infliximab is a chimeric IgG monoclonal antibody directed against TNF- $\alpha$  which binds both the

Received: September 28, 2005

Accepted after Revision: October 20, 2005

Correspondence: Marjolein Drent, M.D.

Department of Respiratory Medicine

University Hospital Maastricht

PO Box 5800

6202 AZ Maastricht

The Netherlands

Tel.: + 31 43 3877043

Fax: + 31 43 3875051

E-mail: m.drent@lung.azm.nl

soluble and transmembrane form of TNF- $\alpha$  [8]. It has proved useful in treating active rheumatoid arthritis and Crohn's disease [9, 10]. Because TNF- $\alpha$  may be a crucial cytokine in sarcoidosis, and infliximab has proved successful in treating other chronic inflammatory diseases, there is a rationale for treating refractory sarcoidosis with infliximab too [8, 11]. We describe a case of multi-organ sarcoidosis with severe SFN who improved spectacularly after treatment with infliximab.

## Case report

In May 2001, this 39 year-old Caucasian man was suffering from dyspnoea and wheezing. A chest X-ray demonstrated hilar lymph adenopathy suggestive of sarcoidosis without pulmonary infiltrates. His medical history revealed hypertension, hypercholesterolemia and morbid obesitas since 1985 treated with perindopril and orlistat. Since May 2000 he was known with diabetes type II, for which he was successfully treated with metformine and glimepiride. Up to now his glycaemic controls remained perfectly stable (HBA1C between 6.3 and 6.9%) and he did not develop retinopathy. At that time no additional medical treatment was initiated for his pulmonary symptoms. However, in December 2001 his fatigue and dyspnoea increased and he complained of progressive burning sensations in both feet and hands, accompanied by profuse sweating, diarrhoea, erectile dysfunction, dizziness while upright, and sicca syndrome, all suggestive of SFN with autonomic involvement. He also reported sleeplessness and a depressive mood. Furthermore, he suffered from arthralgia in shoulders and knees and developed subcutaneous nodules of 1 to 2 cm diameter located on his lower arms and legs. Due to his clinical deterioration he was unable to work. Physical examination revealed dyspnoea and distal dysesthesia with loss of temperature sensation, and red, wet palms and soles. Further physical and neurological examination including reflexes remained normal, besides the subcutaneous nodules. Chest X-ray again showed mediastinal and hilar lymph adenopathy. Biopsies of a mediastinal lymph node and subcutaneous nodule were performed, showing non-caseating granulomas consistent with the diagnosis of sarcoidosis. For assessment of polyneuropathy and central proprioceptive sensory pathways he underwent electromyography (EMG), nerve conduction studies and somatosensory evoked potentials (SSEP), which were all normal. Evaluation of small nerve fiber function was performed by temperature threshold testing (TTT), using the method of levels and method of limitis [4, 12]. Severely abnormal warm and cold sensation thresholds were found in both hands and feet compatible with severe small fiber neuropathy (Table 1). The results of TTT revealed in most cases a warm sensation threshold exceeding 50 °C and a cold sensation threshold below 0 °C (50 °C and 0 °C being the maximal and minimal temperature limit of our equipment). Cardiovascular autonomic function was assessed using the tests recommended by the San Antonio Consensus Meeting [13] which showed three tests out of five that were abnormal, indicating autonomic dysfunction (Table 1 and Fig. 1). By the end of December 2001

he started with prednison 40 mg daily, which was without benefit however and tapered. Glycaemic controls remained stable during therapy. In February 2002 methotrexate 7,5 mg weekly was added to the 10 mg prednison daily. As this appeared to be ineffective, the dose of methotrexate was increased up to 20 mg weekly. Despite this, his fatigue, neuropathic pain, autonomic dysfunction, and arthralgia deteriorated and the subcutaneous noduli enlarged. Initiated neuropathic pain treatment with gabapentin, opioids, carbamazepin and amitriptylin achieved no improvement. At the end of 2002 he was admitted to a dermatologist because of severe skin lesions on both hands (Fig. 2). The lesions were diagnosed as burns due to insensitivity for heat. This insensitivity was attributable to the SFN. Therefore, to avoid these burning lesions in the future, thermostats at the warm water taps were advised.

In May 2003 infliximab was started. A dosage of 3 mg/kg of infliximab (500 mg) was given and repeated at week 2, 6 and 12 with spectacular reduction of his symptoms. Remarkably, in a schedule of therapy every 6 weeks symptoms reoccurred after 4 weeks and he demonstrated a 'rebound' reaction. To try to avoid this reaction the dosage interval was shortened in once every 4 weeks and the dosage tapered to 400 mg. This appeared to be successful. First his arthralgias, fatigue and lung function tests as well as inflammatory parameters improved (Table 1). Thereafter, his subcutaneous noduli disappeared and at last, after almost half a year, the neuropathic pain symptoms, as well as symptoms of autonomic dysfunction disappeared. Temperature threshold testing and cardiovascular autonomic function testing were repeated in July 2004. Both showed spectacular improvement (Fig. 1 and Table 1). Although cardiovascular autonomic function testing was still judged abnormal (2 two out of the 5 tests were abnormal), the degree of abnormality was remarkably reduced. After therapy both systolic and diastolic blood pressure showed a more flat response after rising from supine to an upright position and he reported no dizziness anymore. At present he is stable on infliximab once every 4.5 weeks. His quality of life improved substantially, his fatigue became within normal limits (see Table 1), he is enjoying life again and even restarted working successfully.

## Discussion

Our patient suffered from diabetes type II and multi-organ sarcoidosis with severe small fiber neuropathy. The intriguing question whether the SFN in this case was related to sarcoidosis together with diabetes or one of these disorders alone will stay unanswered. In our opinion the facts that glucose levels were stable in our patient despite severe SFN, other organ damage due to diabetes such as retinopathy or nephropathy were absent and the reversibility of SFN that went parallel with reversibility of sarcoidosis symptoms, make sarcoidosis a rather more likely cause of SFN than diabetes in this case.

SFN is a neuropathy selectively involving small diameter myelinated and unmyelinated nerve fibers

**Table I**  
**Temperature threshold testing and cardiovascular autonomic function tests (CAFT) before and after one year treatment with infliximab**

<i>TTT</i>	<i>Before treatment (°C)</i>	<i>After treatment (°C)</i>	<i>Normative value (°C)</i>
<i>Warm sensation</i>			
R hand	<u>49.0</u>	<u>35.8</u>	< 35.3*
L hand	<u>≥ 50</u>	32.5	“
R foot	<u>≥ 50</u>	<u>45.5</u>	< 45.1*
L foot	<u>≥ 50</u>	<u>46.2</u>	“
<i>Cold sensation</i>			
R hand	<u>≤ 0</u>	29.0	> 28.1*
L hand	<u>≤ 0</u>	30.9	“
R foot	<u>≤ 0</u>	26.2	> 24.5*
L foot	<u>≤ 0</u>	<u>20.6</u>	“
<i>CAFT</i>			
<i>In rest, supine</i>			
Mean HR (beats/minute)	74	68	
CV (%)	<u>1.3</u>	<u>1.7</u>	> 2.5
<i>In rest, upright</i>			
Mean HR (beats/minute)	78	74	
CV (%)	1.9	2.6	
<i>From supine to upright</i>			
Delta HR (beats)	<u>13.9</u>	20.2	> 16.3
30/15 ratio	<u>1.05</u>	1.13	> 1.12
<i>Deep breathing</i>			
I-E (beats)	14.8	11.8	> 10.5
<i>Valsalva manoeuvre</i>			
HR <sub>max</sub> /HR <sub>min</sub>	<u>1.1</u>	<u>1.3</u>	> 1.5
<i>Laboratory tests</i>			
sACE (U/l)	22	9	9-25
sIL2R (kU/l)	725	325	214-846
<i>Lung function tests</i>			
FEV1,% of predicted	<u>66</u>	82	> 80%
FVC,% of predicted	<u>74</u>	86	> 80%
DLCO,% of predicted	<u>95</u>	125	> 80%
<i>Symptom scores</i>			
FAS (fatigue)	<u>45</u>	20	< 22
WHOQOL-100 (quality of life)	<u>4</u>	16	> 15.9
SFNSL-score	<u>77</u>	31	< 48

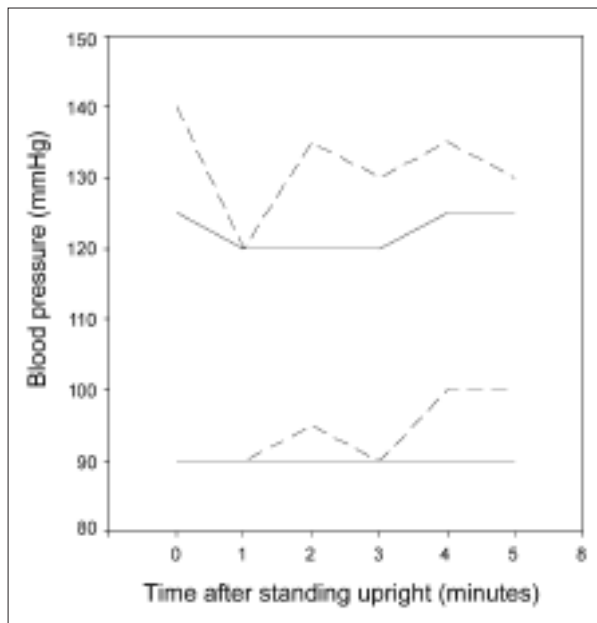
Abnormal data are presented underlined/bold;

\* 99% cut off value according to Yarnitsky and Sprecher [12].

TTT = temperature threshold testing using method of limits (data are presented in °C; starting temperature in all tests 32 °C). CAFT = cardiovascular autonomic function testing. HR = heart rate. CV = coefficient of variation. Delta HR = initial maximal increase in heart rate after standing upright. 30/15 ratio = heart rate 30 seconds after standing upright divided by heart rate 15 seconds after standing upright. I-E = successive maximum inspiration minus minimum expiration heart rate while deep breathing. sACE = serum angiotensin converting enzyme. sIL2R = soluble interleukin-2-receptor. FEV1 = forced expiratory volume in one second. FVC = forced vital capacity. DLCO = diffusing capacity for carbon monoxide. FAS = fatigue assessment scale [27]. WHOQOL-100 = quality of life questionnaire of the World Health Organisation (overall quality of life and general health facet) [5]. SFNSL = small fiber neuropathy screening list.

[14]. Interest in this disorder has considerably increased during the past few years. Patients typically present with peripheral pain and/or symptoms of autonomic dysfunction [15-17]. Diagnosis is made on the

basis of the clinical features, normal nerve conduction studies, and abnormal specialized tests of small nerve fibers. Among others, these tests include TTT for sensory fibers and cardiovascular autonomic testing for

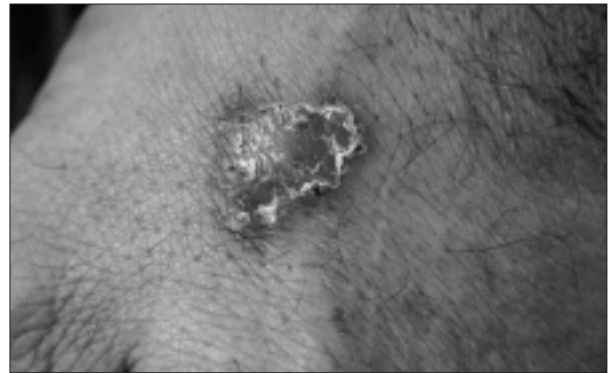


**Fig. 1.** Blood pressure response after standing in upright position before and after one year infliximab treatment.

X-axis: t = 0 = baseline measurement while supine; t = 1 = one minute after standing upright; t = 2 = two minutes after standing upright; etc. Scattered line: systolic and diastolic blood pressure before treatment with infliximab. Patient reported dizziness after standing upright.

autonomic fibers [18]. The pathophysiology of SFN is unknown. However, it appears to be frequent in several immune mediated diseases such as Guillain-Barré syndrome, Sjögren's disease, vasculitis, SLE, rheumatoid arthritis and sarcoidosis [14, 18]. The latter relation has been appreciated just recently [6]. Furthermore, SFN is frequent in diabetes [19]. So far, no proper treatment for SFN is available. Treatment is usually directed towards alleviation of neuropathic pain and often stays problematic [14]. Prognostic studies are lacking, but in our experience SFN in sarcoidosis is usually chronic and devastating. In diabetes patients SFN is usually progressive, with eventually involvement of large nerve fibers [19].

Infliximab was an attractive therapeutic option in our patient for several reasons. Treatment with corticosteroids and methotrexate had not been successful. Moreover, corticosteroids caused severe side-effects and were not well tolerated. He still was severely disabled. Furthermore, increasing evidence has demonstrated that TNF- $\alpha$  is a crucial cytokine in the pathogenesis of sarcoidosis and recently, refractory sarcoidosis has been treated successfully with



**Fig. 2.** Burns on the hand of the sarcoidosis patient with severe small fiber neuropathy.

Infliximab [8, 11]. However, at present no data are available of the effect of anti-TNF- $\alpha$  therapy on SFN, while in our patient SFN was the most devastating problem. Remarkably, severe SFN appeared to be reversible after treatment with Infliximab in this case.

Theoretical support for the effect of anti-TNF- $\alpha$  therapy on SFN may be found in the following. First, it has been appreciated recently that proinflammatory cytokines including TNF- $\alpha$  contribute to the development of inflammatory and neuropathic pain as well as hyperalgesia [20]. Second, TNF- $\alpha$  plays an important role in neuropathies such as Guillain-Barré syndrome and in Guillain-Barré syndrome small nerve fibers are also involved. Elevated serum concentration of TNF- $\alpha$  shows a positive correlation with neuropathy severity in patients with Guillain-Barré syndrome [21, 22]. Furthermore, the decrease in serum TNF- $\alpha$  and increase in serum soluble TNF receptors shows a positive correlation with neuropathy recovery following treatment in those patients. Finally, the presence of SFN in several immune mediated diseases suggests a common final pathway in the pathogenesis of the disorder that may be related to the ongoing inflammatory process. Similarity might be related to cytokine release in immune mediated diseases. Support for the hypothesis that SFN in immune mediated diseases is related to cytokine release is found in pharmacological and physiological studies. These studies report that pro-inflammatory cytokines such as TNF- $\alpha$  are strongly involved in the generation and maintenance of neuropathic pain [20, 23-27]. Therefore, it is tempting to speculate that anti-TNF- $\alpha$  therapy might be beneficial in SFN.

## Conclusion

This case once again stresses that infliximab might be considered as a promising alternative in the treatment of refractory multi-organ sarcoidosis. The case presented suffering from sarcoidosis, diabetes and SFN responded very successful. Our patient reveals two new and important issues. First, severe SFN appeared to be reversible in this case. Second, TNF- $\alpha$  may be a crucial cytokine in the pathogenesis of SFN related to sarcoidosis and possibly in other immune mediated inflammatory diseases and diabetes as well. The successful reaction to anti-TNF- $\alpha$  therapy is very promising and this observation opens a window for new therapeutic and pathogenetic studies.

## References

- Baughman RP, Lower EE, du Bois RM: Sarcoidosis. *Lancet* 2003; 361: 1111-8.
- Ziegenhagen MW, Benner UK, Zissel G, Zabel P, Schlaak M, Muller-Quernheim J: Sarcoidosis: TNF-alpha release from alveolar macrophages and serum level of sIL-2R are prognostic markers. *Am J Respir Crit Care Med* 1997; 156: 1586-92.
- Hoitsma E, De Vries J, van Santen-Hoeufft M, Faber CG, Drent M: Impact of pain in a Dutch sarcoidosis patient population. *Sarcoidosis Vasc Diffuse Lung Dis* 2003; 20: 33-9.
- Hoitsma E, Drent M, Verstraete E, et al: Abnormal warm and cold sensation thresholds suggestive of small-fibre neuropathy in sarcoidosis. *Clin Neurophysiol* 2003; 114: 2326-33.
- Wirnsberger RM, de Vries J, Breteler MH, van Heck GL, Wouters EF, Drent M: Evaluation of quality of life in sarcoidosis patients. *Respir Med* 1998; 92: 750-6.
- Hoitsma E, Marziniak M, Faber CG, et al: Small fiber neuropathy in sarcoidosis. *Lancet* 2002; 359: 2085-6.
- Hoitsma E, Faber CG, Drent M, Sharma OP: Neurosarcoidosis: a clinical dilemma. *Lancet Neurol* 2004; 3: 397-407.
- Baughman RP, Lower EE: Infliximab for refractory sarcoidosis. *Sarcoidosis Vasc Diffuse Lung Dis* 2001; 18: 70-4.
- Maini R, St Clair EW, Breedveld F, et al: Infliximab (chimeric anti-tumour necrosis factor alpha monoclonal antibody) versus placebo in rheumatoid arthritis patients receiving concomitant methotrexate: a randomised phase III trial. ATTRACT Study Group. *Lancet* 1999; 354: 1932-9.
- Heller T, James SP, Drachenberg C, Hernandez C, Darwin PE: Treatment of severe esophageal Crohn's disease with infliximab. *Inflamm Bowel Dis* 1999; 5: 279-82.
- Yee AM, Pochapin MB: Treatment of complicated sarcoidosis with infliximab anti-tumor necrosis factor-alpha therapy. *Ann Intern Med* 2001; 135: 27-31.
- Yarnitsky D, Sprecher E: Thermal testing: normative data and repeatability for various test algorithms. *J Neurol Sci* 1994; 125: 39-45.
- Consensus statement: Report and recommendations of the San Antonio conference on diabetic neuropathy. American Diabetes Association American Academy of Neurology. *Diabetes Care* 1988; 11: 592-7.
- Hoitsma E, Reulen JPH, de Baets M, Drent M, Spaans F, Faber CG: Small fiber neuropathy: a common and important clinical disorder. *J Neurol Sci* 2004; 227: 119-30.
- Verbraeckken J, Hoitsma E, van der Grinten CPM, Cobben NAM, Wouters EFM, Drent M: Sleep efficiency associated with periodic leg movements in chronic sarcoidosis patients. *Sarcoidosis, Vasc Diffuse Lung Dis* 2004; 21: 137-46.
- Hoitsma E, Faber CG, van Kroonenburgh MJPG, et al: Association of small fiber neuropathy with cardiac sympathetic dysfunction in sarcoidosis. *Sarcoidosis Vasc Diffuse Lung Dis* 2005; 22: 43-50.
- De Vries J, Rothkrantz-Kos S, van Diejen-Visser MP, Drent M: The relationship between fatigue and clinical parameters in pulmonary sarcoidosis. *Sarcoidosis Vasc Diffuse Lung Dis* 2004; 21: 127-36.
- Lacomis D: Small-fiber neuropathy. *Muscle Nerve* 2002; 26: 173-88.
- Simmons Z, Feldman EL: Update on diabetic neuropathy. *Curr Opin Neurol* 2002; 15: 595-603.
- Oprea A, Kress M: Involvement of the proinflammatory cytokines tumor necrosis factor-alpha, IL-1 beta, and IL-6 but not IL-8 in the development of heat hyperalgesia: effects on heat-evoked calcitonin gene-related peptide release from rat skin. *J Neurosci* 2000; 20: 6289-93.
- Radhakrishnan VV, Sumi MG, Reuben S, Mathai A, Nair MD: Serum tumour necrosis factor-alpha and soluble tumour necrosis factor receptors levels in patients with Guillain-Barre syndrome. *Acta Neurol Scand* 2004; 109: 71-4.
- Creange A, Belec L, Clair B, Raphael JC, Gherardi RK: Circulating tumor necrosis factor (TNF)-alpha and soluble TNF-alpha receptors in patients with Guillain-Barre syndrome. *J Neuroimmunol* 1996; 68: 95-9.
- Sommer C, Marziniak M, Myers RR: The effect of thalidomide treatment on vascular pathology and hyperalgesia caused by chronic constriction injury of rat nerve. *Pain* 1998; 74: 83-91.
- Sommer C, Schafers M: Painful mononeuropathy in C57BL/Wld mice with delayed wallerian degeneration: differential effects of cytokine production and nerve regeneration on thermal and mechanical hypersensitivity. *Brain Res* 1998; 784: 154-62.
- Schafers M, Geis C, Brors D, Yaksh TL, Sommer C: Anterograde transport of tumor necrosis factor-alpha in the intact and injured rat sciatic nerve. *J Neurosci* 2002; 22: 536-45.
- Empl M, Renaud S, Erne B, et al: TNF-alpha expression in painful and nonpainful neuropathies. *Neurology* 2001; 56: 1371-7.
- Cunha FQ, Poole S, Lorenzetti BB, Ferreira SH: The pivotal role of tumour necrosis factor alpha in the development of inflammatory hyperalgesia. *Br J Pharmacol* 1992; 107: 660-4.