



Title	Anemia in a neonate with placental mesenchymal dysplasia
Author(s)	Ishikawa, Satoshi; Morikawa, Mamoru; Umazume, Takeshi; Yamada, Takahiro; Kanno, Hiromi; Takakuwa, Emi; Minakami, Hisanori
Citation	Clinical case reports, 4(5), 463-465 <a href="https://doi.org/10.1002/ccr3.543">https://doi.org/10.1002/ccr3.543</a>
Issue Date	2016-05
Doc URL	<a href="http://hdl.handle.net/2115/62283">http://hdl.handle.net/2115/62283</a>
Rights(URL)	<a href="https://creativecommons.org/licenses/by-nc-nd/4.0/">https://creativecommons.org/licenses/by-nc-nd/4.0/</a>
Type	article
File Information	Ishikawa_et_al-2016-Clinical_Case_Reports.pdf



[Instructions for use](#)

## CASE REPORT

## Anemia in a neonate with placental mesenchymal dysplasia

Satoshi Ishikawa<sup>1</sup>, Mamoru Morikawa<sup>1</sup>, Takeshi Umazume<sup>1</sup>, Takahiro Yamada<sup>1</sup>, Hiromi Kanno<sup>2</sup>, Emi Takakuwa<sup>2</sup> & Hisanori Minakami<sup>1</sup>

<sup>1</sup>Department of Obstetrics, Hokkaido University Graduate School of Medicine, Sapporo, Japan

<sup>2</sup>Department of Pathology, Hokkaido University Hospital, Sapporo, Japan

### Correspondence

Takahiro Yamada, Department of Obstetrics, Hokkaido University Graduate School of Medicine, N15W7, Kita-ku, Sapporo, 060-8638, Japan. Tel: +81 11 706 5941; Fax: +81 11 706 7711; E-mail: taka0197@med.hokudai.ac.jp

### Funding Information

No sources of funding were declared for this study

Received: 26 June 2015; Revised: 25 December 2015; Accepted: 28 February 2016

*Clinical Case Reports* 2016; 4(5): 463–465

doi: 10.1002/ccr3.543

### Introduction

Although placental mesenchymal dysplasia (PMD) can coexist with a completely normal fetus, a review of 82 cases indicated that approximately 40% of fetuses with PMD die in utero [1]. However, the cause of intrauterine fetal death (IUFD) is uncertain in most PMD cases. Abrupt worsening of fetal condition was documented within 1 day after confirming fetal well-being in at least two PMD cases [2, 3]. These reports prompted us to recommend early admission of a woman with PMD at gestational week (GW) 30 to our hospital for intensive monitoring of fetal well-being. This case suggested that the intensive monitoring of fetal well-being using ultrasound contributes to the avoidance of IUFD in some PMD cases. The Hokkaido University Hospital Institutional Review Board approved this study and the patient provided written informed consent.

### Case History

A 26-year-old nulliparous Japanese woman in GW 13 was referred to our hospital for suspected partial hydatidiform

### Key Clinical Message

Causes of intrauterine fetal death (IUFD) are uncertain in most placental mesenchymal dysplasia (PMD) cases. Our case showed high  $\alpha$ -fetoprotein levels in the maternal circulation, markedly dilated subchorionic vessels, and neonatal hemoglobin concentration of 8.4 g/dL, suggesting that fetal anemia may explain some adverse outcomes in PMD pregnancies.

### Keywords

Alpha fetoprotein elevation, fetal death, placental mesenchymal, placental pathology, placental transfer.

mole. Blood flow in the mole-like placental cysts on color Doppler ultrasound study suggested PMD [4] in this patient. The fetal middle cerebral artery peak systolic velocity (MCA-PSV) was 23.6 cm/sec (0.59 multiple of the median [MoM]) (Fig. 1), and multiple subchorionic vesicles ~2.0 cm in diameter (Fig. 2A) and unremarkable fetal heart rate trace were seen on the day of prophylactic admission at GW 30<sup>-0/7</sup>. The normal serum  $\alpha$ -fetoprotein (AFP) level of 160 ng/mL (corresponding to 1.0 MoM) at GW 23 increased markedly to 7261 ng/mL (22 MoM) on the next day of admission (Fig. 1). The MCA-PSV increased to 56.9 cm/sec (1.42 MoM), while the vesicle diameter remained 2.3 cm 3 days later at GW 30<sup>-3/7</sup>. However, the vesicle size increased markedly to 3.3 cm in diameter and an emergent cesarean section was performed at GW 30<sup>-5/7</sup>. A premature but otherwise healthy female infant weighing 1550 g was born with 1- and 5-min Apgar scores of 6 and 8, respectively.

### Investigations

The hemoglobin concentrations were 8.3 g/dL and 8.4 g/dL in the cord and neonatal blood, respectively. Histolog-

ical examination of the placenta weighing 575 g revealed that the vesicle was dilated but vessels were unruptured (Fig. 2B). A further increase in maternal serum AFP level to 10,786 ng/mL (33 MoM) was observed on the day of delivery (Fig. 1), but a normal hemoglobin F level (0.5%) as well as a decreased AFP level (to 4990 ng/mL) was confirmed on postpartum day 3 in this patient.

### Outcome and Follow-Up

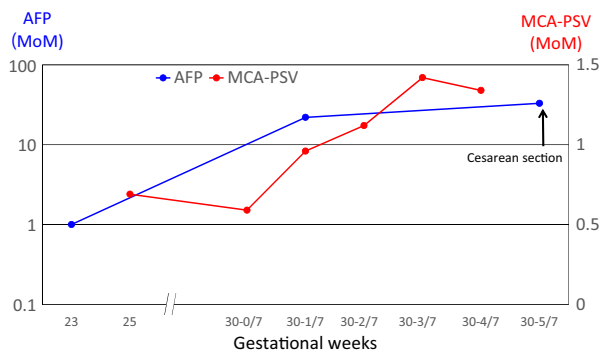
The neonate with transient tachypnea of the newborn did not require tracheal intubation, and left hospital at age 104 days after exhibiting normal findings on brain magnetic resonance imaging (MRI) at the age of 93 days.

### Discussion

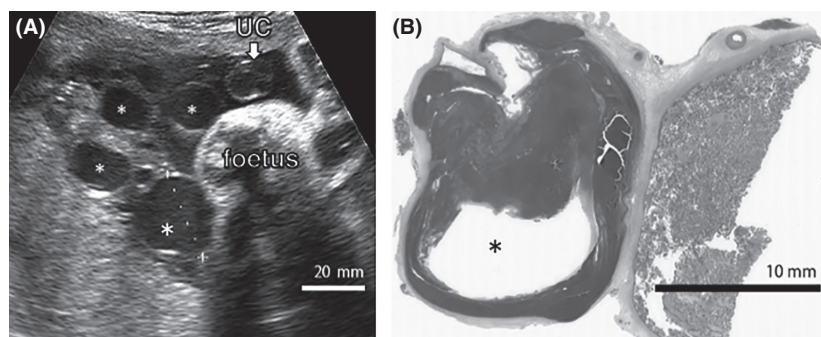
Sudden IUFD was a concern in this patient based on our previous experience [5] and a previous review by Pham et al. [1]. An acute increase in diameter of the vesicle in 2 days from 2.3 cm to 3.3 cm in our case prompted us to perform cesarean section at GW 30 with concerns regard-

ing imminent vessel rupture. Although the vessel was not ruptured histologically in the present case, the neonate indeed had anemia. In addition, the present case had very high AFP levels of 22 MoM and 33 MoM on admission and the day of delivery, respectively. Even in the absence of PMD, approximately 10% of fetuses carried by women with a persisting elevated AFP level  $\geq 2.5$  MoM die in utero [6]. In our previous PMD case with AFP of 2.7 MoM [5], subchorionic vessels dilated to 2.5 cm in diameter were seen on ultrasound performed 1 week prior to IUFD occurring at GW 36 when the patient visited our hospital on an outpatient-basis due to decreased fetal movement. This case of IUFD was considered to be due to hypovolemia caused by the rupture of cirroid chorionic vessels [5]. A similar case of IUFD at GW 28 was documented with a dilated chorionic vessel 3.5 cm in diameter [7]. Among 11 new cases reported by Pham et al. [1], one was documented to have severe anemia at birth.

Placental mesenchymal dysplasia is characterized by stem villous cystic dilation and vesicle formation, placentomegaly, and vascular abnormalities [8]. Large dilated (to varying degrees) and tortuous vessels seen on the chorionic plate of PMD placentas have endothelial damage showing hemorrhage into the vessel wall and fibroblastic organization [1, 9, 10]. Increased serum level of AFP was seen in the present case and in women with PMD [5, 11] even in the presence of normal AFP level in the amniotic fluid [11]. This implied that AFP moved extraordinarily from the fetal circulation to the maternal circulation and may suggest an increased permeability of placental vessels derived from vascular abnormalities, allowing AFP to enter the maternal circulation. In addition, the large dilated and tortuous vessels with placentomegaly may cause increase in vascular bed. If fetal erythropoiesis was insufficient for the increase of vascular bed, fetal anemia would occur even in the absence of vessel rupture. These scenarios may explain fetal anemia and



**Figure 1.** Changes in maternal serum  $\alpha$ -fetoprotein (AFP) and fetal middle cerebral artery peak systolic velocity (MCA-PSV). MoM, multiple of the median.



**Figure 2.** Ultrasound study of the surface of the placenta (A) and photomicrographs of the dilated but unruptured vessel (B). UC, umbilical cord; \*, cirroid chorionic vessels.

elevated AFP levels in the maternal circulation in this case and adverse outcomes, such as fetal growth restriction, hydrops fetalis, and IUFD in some of PMD pregnancies. Intensive monitoring of the placenta and MCA-PSV using ultrasound may be helpful to avoid IUFD in some PMD pregnancies.

## Acknowledgment

This study was supported by Grants-in-Aid for Scientific Research from the Ministry of Education, Science, Sports, and Culture of Japan (No. 25462546 and 26462468).

## Conflict of Interest

None declared.

## References

1. Pham, T., J. Steele, C. Stayboldt, L. Chan, and K. Benirschke. 2006. Placental mesenchymal dysplasia is associated with high rates of intrauterine growth restriction and fetal demise: a report of 11 new cases and a review of the literature. *Am. J. Clin. Pathol.* 126:67–78.
2. Tortoledo, M., A. Galindo, and C. Ibarrola. 2010. Placental mesenchymal dysplasia associated with hepatic and pulmonary hamartoma. *Fetal Pediatr. Pathol.* 29:261–270.
3. Ventura, F., M. Rutigliani, C. Bellini, A. Bonsignore, and E. Fulcheri. 2013. Clinical difficulties and forensic diagnosis: histopathological pitfalls of villus mesenchymal dysplasia in the third trimester causing foetal death. *Forensic Sci. Int.* 229:e35–e41.
4. Kuwata, T., H. Takahashi, and S. Matsubara. 2014. ‘Stained-glass’ sign for placental mesenchymal dysplasia. *Ultrasound Obstet. Gynecol.* 43:355.
5. Umazume, T., S. Kataoka, K. Kamamuta, F. Tanuma, A. Sumie, T. Shirogane, et al. 2011. Placental mesenchymal dysplasia, a case of intrauterine sudden death of fetus with rupture of cirroid periumbilical chorionic vessels. *Diagn. Pathol.* 6:38.
6. Spaggiari, E. M., S. Dreux, A. S. Valat, I. Czerkiewicz, F. Guimiot, T. Schmitz, et al. 2013. Management strategy in pregnancies with elevated second-trimester maternal serum alpha-fetoprotein based on a second assay. *Am. J. Obstet. Gynecol.* 208:303.e1–7.
7. Sheeja, S., P. Usha, M. P. Shiny, and T. Renu. 2013. Placental mesenchymal dysplasia: a report of two cases with review of literature. *Indian J. Pathol. Microbiol.* 56:57–59.
8. Pawoo, N., and D. S. Heller. 2014. Placental mesenchymal dysplasia. *Arch. Pathol. Lab. Med.* 138:1247–1249.
9. Parveen, Z., J. E. Tongson-Ignacio, C. R. Fraser, J. L. Killeen, and K. S. Thompson. 2007. Placental mesenchymal dysplasia. *Arch. Pathol. Lab. Med.* 131:131–137.
10. Zeng, X., M. F. Chen, Y. A. Bureau, and R. Brown. 2012. Placental mesenchymal dysplasia and an estimation of the population incidence. *Acta Obstet. Gynecol. Scand.* 91:754–757.
11. Aviram, R., D. Kidron, S. Silverstein, I. Lerer, D. Abeliovich, R. Tepper, et al. 2008. Placental mesenchymal dysplasia associated with transient neonatal diabetes mellitus and paternal UPD6. *Placenta* 29:646–649.