



Case Report

Pulmonary cavitary *Mycobacterium kyorinense* (*M. kyorinense*) infection in an Australian woman



Sanjeevan Muruganandan^a, Lata Jayaram^b, Jenny Siaw Jin Wong^c, Stephen Guy^{d,*}

^a Respiratory and Sleep Medicine, Western Health, Australia

^b Respiratory and Sleep Medicine, Western Health, University of Melbourne, Australia

^c Microbiology Department, Dorevitch Pathology, Western Hospital, Australia

^d Infectious Diseases, Western Health, University of Melbourne, Australia

ARTICLE INFO

Article history:

Received 29 January 2015

Accepted 1 February 2015

Keywords:

Mycobacterium kyorinense

M. kyorinense

Non-tuberculous mycobacterium

Pulmonary cavitation

Pulmonary infection

ABSTRACT

We describe a patient with pulmonary cavitary pneumonia from whom we serially isolated *Mycobacterium kyorinense*, an organism not previously reported in Australia, or associated with cavitary disease. We discuss the clinical presentation, the isolation of the organism on several specimens and initial management. *M. kyorinense* is a recently characterized species, which has previously only been described in Japan and Brazil [1].

© 2015 The Authors. Published by Elsevier Ltd. This is an open access article under the CC BY-NC-ND license (<http://creativecommons.org/licenses/by-nc-nd/4.0/>).

Introduction

Mycobacterium kyorinense is a non-pigmented slow growing mycobacterium that was first described in Japan. The species was first isolated in 2007 [1] and subsequently characterized as a novel species in 2009 [2]. *M. kyorinense* is similar to *Mycobacterium celatum* and *Mycobacterium branderi* however gene sequences of 16S rRNA, hsp65 and rpoB differentiate it as a separate species [2]. To date, 12 patients with *M. kyorinense* infection have been described in the literature; 11 in Japan and a single case in Brazil [1–5].

Previously described cases have been mostly immune-competent adults with predominantly pulmonary infections, although single case reports describe lymph node and joint infections [4]. No published cases have described cavitation as part of pulmonary infection. Six of the 12 reported cases have died, with progressive infection causing most of these deaths [3]. However all patients who died received antimicrobials which likely were ineffective against this organism, and their deaths preceded identification of this novel species as a human pathogen. Most patients who

survived the infection received a combination of macrolide and quinolone therapy [1].

The purpose of this article is to report the first isolation of *M. kyorinense* in Australia, and to the best of our knowledge the first report of pulmonary cavitation associated with this infection.

Case presentation

A 46-year-old Caucasian female was referred to our institution in December 2012 following a CT-pulmonary angiogram performed to investigate left sided pleuritic chest pain, which revealed a large apical cavity with surrounding consolidation (Fig. 1). The patient reported daily cough productive of brown sputum. There was no associated dyspnoea, malaise or fatigue and no anorexia or weight loss. The patient was Australian born and worked as a computer programmer. Her only overseas travel was to Malta and United Kingdom 30 years prior. She smokes cigarettes and had a past history significant for bilateral pleurodesis for recurrent pneumothoraces as well as an anxiety disorder, for which she took paroxetine. She did not report recurrent infections through childhood or exposure to *M. tuberculosis*. A chest radiograph 6 years prior to presentation showed 'fibrocalcific lesions in both lung apices'.

Physical examination revealed a thin woman (BMI 19.6 kg/m²) with normal vital signs. There was no clubbing or palpable

* Corresponding author at: Infectious Diseases Department, Western Health, Footscray, Victoria 3011, Australia. Tel.: +61 412281269.

E-mail addresses: sanjeevan10@gmail.com (S. Muruganandan), stephen.guy@wh.org.au (S. Guy).

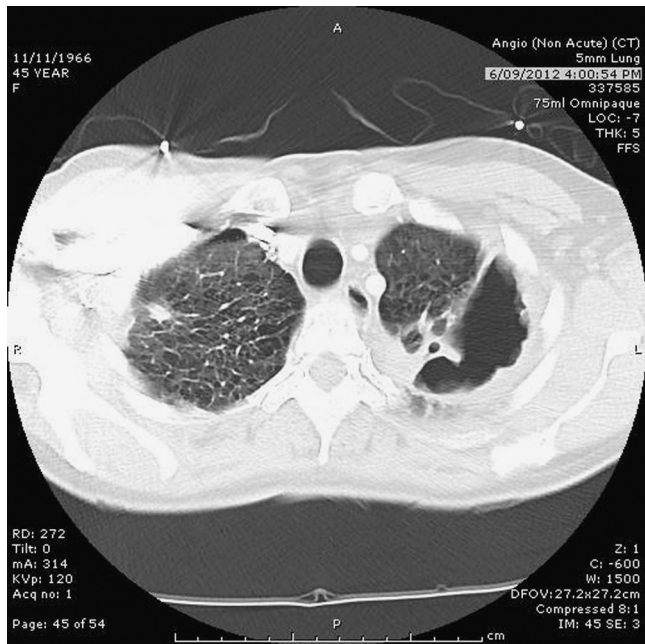

Fig. 1. CT chest at presentation showing a left upper lobe cavity with areas of consolidation and background changes of centrilobular emphysema.

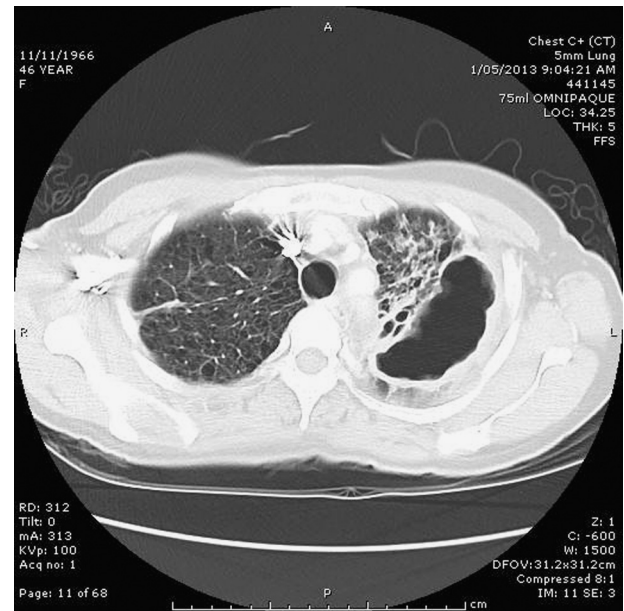


Fig. 2. Expansion of the left upper lobe cavity and progression of the consolidation.

lymphadenopathy. Respiratory examination revealed coarse breath sounds in the left upper zone upon auscultation. Examination was otherwise unremarkable.

Blood work revealed normal electrolytes, renal function and liver function tests. Complete blood picture showed mild thrombocytosis only. C-reactive protein and ESR were normal. Quantiferon-gold, serum *Aspergillus* precipitins and HIV antibody were negative. Serum immune-globulins revealed a mild increase in IgA (5.73 g/dL, range 0.85–3.50), but were otherwise normal and alpha-1-antitrypsin was normal. Pulmonary function testing revealed a mild obstructive ventilatory defect and moderately reduced diffusion capacity. The patient underwent a bronchoscopy, which revealed inflamed left lingular segment airways with no endobronchial lesions seen. Cytological analysis of the bronchial specimens did not show any evidence of malignancy. A non-tuberculous mycobacterium was isolated on culture of bronchial washings, which subsequently identified as *M. kyorinense*.

Between 20 December 2012 and 7 November 2013, seven pulmonary specimens were collected for analysis (two bronchoscopy and five sputum). Small numbers of acid fast bacilli not resembling *M. tuberculosis* were seen on direct smear from the first bronchial wash specimen. All specimens grew in Bactec MGIT 960 at an average of 13 days (range 7–30 days). MPT 64 TB antigen (BD MGIT™ Tbc Identification Test) testing was negative on the first isolate and all positive broth culture isolates were submitted to Mycobacterial Reference Laboratory, Victorian Infectious Diseases and Reference Laboratories for further testing (MRL, VIDRL). The MRL identified the non-tuberculous mycobacterium as *M. kyorinense* by 16S ribosomal RNA gene sequencing. The MRL was unable to perform sensitivity testing of the isolate.

Smoking cessation was encouraged however no anti-mycobacterial treatment was instituted initially due to uncertainty about the significance of the *M. kyorinense* isolate, and the patient's symptoms deteriorated over the following 3 months. Repeat CT chest showed an increase in the size of the cavity as well as the development of widespread tree-in bud opacities in the left and right upper lobes (Fig. 2). A second bronchoscopy was performed which once again yielded *M. kyorinense*. Clarithromycin, ethambutol and moxifloxacin

were commenced empirically and consideration was given to initiating an injectable aminoglycoside given the extensive cavitation present [1].

Follow up after 7 months of therapy was completed although the patient had continued to smoke and her adherence with medication was uncertain. The patient continued to cough and *M. kyorinense* was repeatedly isolated from the expectorated sputum. Repeat CT imaging performed at 7 months showed partial improvement of the lung infiltrates but persistence of the cavity.

Discussion

We believe that our patient fulfils the proposed ATS/IDSA criteria for non-tuberculous mycobacterial pulmonary infection, due to *M. kyorinense* [6]. This is only the 13th reported case, the second case outside Japan and the first to report cavitation of the lung parenchyma. This case adds to the emerging evidence that *M. kyorinense* may be a pathogenic non-tuberculous mycobacterium in humans, and, given this patient's extended recent residence in Australia, suggests the organism may have a wider geographical distribution than previously described.

Since only 12 cases of pulmonary *M. kyorinense* disease have previously been reported, it is difficult to characterize specific clinical findings of patients with this disease. It is not clear from previously published cases of *M. kyorinense* infection whether these patients were smokers, however at least three of the reported cases have 'COPD' listed as a co-morbidity. Otherwise there appears to be no other consistently reported co-morbid condition predisposing to *M. kyorinense* infection [1]. Our patient had no overt immune compromising conditions, however her history of cigarette smoking, findings on her pulmonary function test as well as her imaging findings support a diagnosis of GOLD stage 1 COPD [9]. Additionally, her recurrent pneumothoraces and pleurodesis, as well as the historical reported apical changes on chest radiograph, suggest possible structural lung disease. Indeed many other non-tuberculous mycobacterial pulmonary infections occur in patients with documented structural lung conditions or a history of cigarette smoking [6].

Sensitivity testing of *M. kyorinense* isolates described in the literature has revealed for most strains the MICs of rifampin, ethambutol, and isoniazid were relatively high, and MICs of macrolides, aminoglycosides, and quinolones were relatively low [4]. Several patients subsequently determined to have *M. kyorinense* infection appear to have received first line *M. tuberculosis* therapy empirically with little success [1]. Fluroquinolones in combination with a macrolide seem to have been the most successful therapy described [4]. Injectable aminoglycoside may also have a role in management of *M. kyorinense* [1] and other non-tuberculous mycobacteria [6–8]. Given the uncertainties regarding patient's adherence with medication, it is difficult to assess treatment response accurately, and whether the incomplete response after 6 months of therapy constitutes true treatment failure.

Conclusion

We describe the first case of *M. kyorinense* pulmonary infection in Australia, and the first to be associated with cavitary lung disease. This organism has gathering evidence for its role as a pathogen in humans and further reports will inform specific risk factors and therapies are appropriate for infections it causes.

Conflict of interest

None declared.

Acknowledgements

We thank staff of the MRL (Dr David Leslie, Janet Fyfe and Maria Globan), Victorian Infectious Diseases Reference Laboratory for providing definitive identification of the isolate.

References

- [1] Ohnishi H, Yonetani S, Matsushima S, Wada H, Takeshita K, Kuramochi D, et al. *Mycobacterium kyorinense* infection. Emerg Infect Dis 2013. <http://dx.doi.org/10.3201/eid1903.120591>.
- [2] Okazaki M, Ohkusu K, Hata H, Ohnishi H, Sugahara K, Kawamura C. *Mycobacterium kyorinense* sp. nov., a novel, slow-growing species, related to *Mycobacterium celatum*, isolated from human clinical specimens. Int J Syst Evol Microbiol 2009;59:1336–41.
- [3] Campos CED, Caldas PCS, Ohnishi H, Watanabe T, Ohtsuka K, Matsushima S, et al. First isolation of *Mycobacterium kyorinense* from clinical specimens in Brazil. J Clin Microbiol 2012;50:2477–8.
- [4] Kobashi Y, Mouri K, Obase Y, Kato S, Oka M. Pulmonary *Mycobacterium kyorinense* disease showed clinical improvement following combined therapy with clarithromycin and levofloxacin. Intern Med 2012;51:1923–6.
- [5] Wada H, Yamamoto M, Okazaki M, Watanabe T, Goto H. Isolation of *Mycobacterium kyorinense* in a patient with respiratory failure. Adv Intern Med 2009;150:568–70.
- [6] Griffith DE, Aksamit T, Brown-Elliott BA, et al. An official ATS/IDSA statement: diagnosis, treatment, and prevention of non-tuberculous mycobacterial diseases. Am J Respir Crit Care Med 2007;175:367–416.
- [7] Thomson RM, Yew WW. When and how to treat pulmonary non-tuberculous mycobacterial diseases. Respirology 2009;14:12–26.
- [8] Kobashi YMT, Oka M. A double-blind randomized study of aminoglycoside infusion with combined therapy for pulmonary *Mycobacterium avium* complex disease. Respir Med 2007;101:130–8.
- [9] The Global Strategy for the Diagnosis, Management and Prevention of COPD, Global Initiative for Chronic Obstructive Lung Disease (GOLD); 2013, Available at: <http://www.goldcopd.org/>.



Minerva Access is the Institutional Repository of The University of Melbourne

Author/s:

Muruganandan, S; Jayaram, L; Wong, JSJ; Guy, S

Title:

Pulmonary cavitary Mycobacterium kyorinense (M. kyorinense) infection in an Australian woman

Date:

2015-01-01

Citation:

Muruganandan, S., Jayaram, L., Wong, J. S. J. & Guy, S. (2015). Pulmonary cavitary Mycobacterium kyorinense (M. kyorinense) infection in an Australian woman. IDCASES, 2 (2), pp.37-39. <https://doi.org/10.1016/j.idcr.2015.02.001>.

Persistent Link:

<http://hdl.handle.net/11343/270608>

File Description:

Published version

License:

CC BY-NC-ND