

## Surgical implications of 3D vs 2D endoscopic ear surgery: a case-control study

### 3D vs 2D EES: a case-control study

Giulia Molinari, MD<sup>1,2</sup>, Talisa Ragonesi<sup>1</sup>, Sara-Lynn Hool, MD<sup>1</sup>, Georgios Mantokoudis, MD, PhD<sup>1</sup>, Livio Presutti, MD<sup>2</sup>, Marco Caversaccio, MD<sup>1</sup>, Lukas Anschuetz, MD<sup>1</sup>

<sup>1</sup> Department of Otolaryngology Head and Neck Surgery, Inselspital, University Hospital and University of Bern, Switzerland

<sup>2</sup> Department of Otolaryngology Head and Neck Surgery, University Hospital of Modena, Italy

#### Corresponding Author

Giulia Molinari, MD

Department of Otolaryngology Head and Neck Surgery, Inselspital, University Hospital and University of Bern, Freiburgstrasse 15, CH-3010 Bern, Switzerland

Fax: +41316324872

Phone: +41316322654

Email: [dr.giuliamolinari@gmail.com](mailto:dr.giuliamolinari@gmail.com)

#### Abstract

**Purpose:** To compare 3D to 2D technology in endoscopic ear surgery (EES); to report surgeons' feedback on the use of 3D in EES; to describe the operative setting for 3D EES.

**Methods:** A case-control study on EES was performed at a tertiary university center. All consecutive cases of 3D EES (case group) were matched to a control group operated with

the standard 2D technique. Data on surgical approach, type of surgery, operative time, outcomes and complications was compared between the two groups. After each surgery, the operating surgeons were asked to give a feedback on the use of 3D endoscopy, filling in a questionnaire based on 5-point Likert scales.

**Results:** None of the 3D procedures was switched to 2D. Nor intraoperative or long-term complications were recorded. The operative time was similar in both groups. Post-operative hearing function did not show any statistically significant difference between 3D and 2D patients. Ninety-six per cent of participants agreed or strongly agreed on better views of anatomy and pathology with the 3D technique. Discomfort induced by 3D vision was rarely reported.

**Conclusion:** Surgical and functional results from EES respectively performed with 3D and 2D systems are overall similar, suggesting that both techniques are safe and effective.

According to the surgeons' feedback, 3D provides better depth perception and improved view of anatomy and pathology. Several surgeons are willing to use the 3D system for future EES. To guarantee the best 3D EES experience, the setting in the operating room plays a crucial role.

**Keywords:** endoscopic ear surgery; 3D endoscopy; stereoscopic view; operative setting; visual discomfort.

#### **Declarations**

**Funding:** None

**Conflicts of interest/Competing interests:** The authors declare that they have no conflict of interest.

**Availability of data and material:** The datasets analysed during the study are available from the corresponding author on reasonable request.

**Code availability:** Not applicable

**Authors' contributions:** All authors contributed to the study conception and design.

Material preparation, data collection and analysis were performed by Giulia Molinari, Talisa Ragonesi, Sara-Lynn Hool, and Lukas Anschuetz. The first draft of the manuscript was written by Giulia Molinari and Lukas Anschuetz and all authors commented on previous versions of the manuscript. All authors read and approved the final manuscript.

**Ethics approval:** This study was performed in line with the principles of the Declaration of Helsinki. Approval was granted by the Ethics Committee of University of Bern (Kantonale Ethikkommission Bern, KEK-BE Nr. 2019-00555)

## **Introduction**

Endoscopic ear surgery (EES) has gained importance worldwide in the last decades and has brought new anatomical, pathophysiological and surgical concepts to the field of otology.[1–3] As indicated by the constantly growing body of literature on this topic, EES is recognized as a feasible and effective way to treat a variety of middle ear pathologies. Such spread and versatility of the endoscope is mainly due to the advantages inherent to the endoscopic technique, such as the panoramic field of view and the use of angled scopes inside the middle ear.[4,5] Therefore a minimal-invasive and functional approach by preserving healthy mastoid and middle ear mucosa can be adopted.[6]

However, the endoscopic approach is characterized by some intrinsic technical limitations such as the lack of depth perception.[7] Recently, this shortcoming has been addressed by new technological developments, resulting in the application of three-dimensional (3D) systems to EES. 3D technology has already been proposed in different endoscopic

settings (e.g. endoscopic sinus surgery, laparoscopic surgery, gastro-intestinal endoscopy), successfully providing endoscopic views more adherent to reality.[8–10] Hitherto, clinical application of 3D endoscopy to middle ear surgery is at its infancy, being limited by the size of the endoscopes commercially available and the narrow diameter of the external auditory canal (EAC).

A clinical pilot study on eight patients from Bernardeschi et al. (2018)[11] and a small case series by Chen et al. (2018)[12] are currently reported in the literature. A comparison on intraoperative conditions, outcomes and surgeons' preferences between 3D and conventional two-dimensional (2D) EES has not been investigated yet. On this topic, a comparative study has been performed on a cadaveric model.[13] According to it, 3D EES is feasible, despite being burdened by a higher incidence of eyestrain. Interestingly, the results from this study also indicated that 3D EES is suitable especially for inexperienced surgeons, whose mental EES setting is not yet long established, if compared to expert 2D EES surgeons.

In order to further investigate the value of 3D endoscopy on EES, we performed a case-control study comparing the 3D to 2D technology in a clinical setting. Our aim was to assess the surgical and functional outcomes on patients as well as to collect the surgeons' feedback on their experience with 3D EES. Furthermore, a detailed description of the operative setting for 3D endoscopy in this kind of surgery is reported to facilitate the implementation of 3D technology among new users.

## **Patients and Methods**

### *Ethical considerations*

Our institutional review board (Kantonale Ethikkommission Bern) granted approval to perform the present study (KEK-BE Nr. 2019-00555). This study was performed according to the Declaration of Helsinki.

#### *Patients and surgical outcome assessment*

All consecutive cases of 3D EES were enrolled in the present study (case group) and matched to a control group operated with the standard 2D technique during the same period (between December 2017 and May 2019). The two groups were individually matched for diagnosis, preoperative hearing function (mean bone-conduction and air-conduction pure tone average and mean air-bone gap), operating surgeon, type and extent of surgery, and secondarily, for age and sex of patients when possible. Matching was performed by fourth-year medical student (T.R.), who was blinded to intraoperative course and postoperative outcomes.

Data from patients' electronic records were retrospectively collected and summarized in a database. Information on diagnosis, preoperative hearing function, surgical approach, type of surgery, operative time, and intraoperative complications was collected. Similarly, data regarding the post-operative period (in terms of surgical outcomes and complications), were included in the database according to the follow-up visits at 2 weeks, 4 weeks and 3 months after surgery. The audiometric test was performed preoperatively and at last follow-up. Pure tone average (PTA) was calculated for both bone conduction (BC) and air conduction (AC), from preoperative and post-operative pure tone audiometry, considering 0.5, 1, 2, 4 kHz frequencies. Preoperative hearing function was similar between the two groups (p-value for mean BC-PTA, mean AC-PTA and mean air-bone gap (ABG) not statistically significant between 3D and 2D groups).

Mean ABG was reported as the difference between AC-PTA and BC-PTA, while air-bone gap closure was calculated as the difference between preoperative ABG and postoperative ABG. The AC gain (preoperative AC-PTA – postoperative AC-PTA) was also measured.

### *Surgical setting and instrumentation*

For the 2D setup, a 3-chip HD camera was connected to a 3-mm diameter, 14 cm length rigid endoscope with 0° or 45° view (Karl Storz, Tuttlingen, Germany). The 3D system was composed by the TIPCAM 1 S 3D ORL 4 mm diameter and 18 cm length video endoscope in 0° and 45° view (Karl Storz, Tuttlingen Germany), with the surgeon wearing passive polarization glasses, as shown in **Figure 1**. For both techniques, the endoscopic images were projected on a 32" 4K/3D monitor (Karl Storz, Tuttlingen, Germany). To allow ideal 3D image visibility, the monitor is positioned on the opposite side of the surgical table. As illustrated in **Figure 2**, important is a direct and perpendicular line of the monitor to the operating surgeon, in a distance of around 2 meters, with the superior border of the screen aligned with the level of his/her eyes. The standard instrument set for endoscopic middle ear surgery was used in all cases. The 3D technology employed in this study has self-regulating light source intensity and the camera is provided with autofocus system, thus the surgical view is automatically on focus, despite the distance from the structures.

The visualization modalities of the SPIES (Storz Professional Image Enhancement System), such as Clara, Chroma, Spectra A and B, are available in both 2D and 3D systems. While Clara provides additional illumination for exploration of darker areas, the enhancement algorithms of Chroma, Spectra A and B facilitate the evaluation of the mucosal surface and the subepithelial vascularization. Their combination could be of

particular interest in cholesteatoma surgery, as they may help in distinguishing cholesteatoma matrix from granulation tissue or normal mucosa.

#### *Surgeons' feedback and scrub nurses' point of view*

The operating surgeons were asked to give a feedback on the use of 3D endoscopy after each surgery, filling in a questionnaire based on 5-point Likert scales. The questionnaire consisted of two parts: one relative to the easiness of 3D endoscopy and the comparison between 3D and 2D system (rating from 1= strongly disagree to 5=strongly agree), and one for the perception of discomfort during or after 3D endoscopic surgery (from 1=never to 5=very often). Space for free text was also available for personal comments. None of the participants received financial support. If more than one surgeon was involved in the procedure, all surgeons filled in the questionnaire.

Additionally, the scrub nurses were interviewed after the 3D procedures to allow direct qualitative feedback from the non-surgical perspective.

#### *Statistical analysis*

Statistical analysis on selected surgical and functional data was performed through GraphPad Prism 8. Comparisons between groups were performed using chi square test for categorical variables, while t-test or Mann-Whitney U-test for normally and non-normally distributed continuous variables, respectively. Alpha coefficient was set at 0.05.

## **Results**

#### *Patients and surgical outcomes*

Overall, 34 patients were enrolled in the present study, 17 in each group. Twenty-two males and 12 females were included. In both groups, 15 patients were operated through

exclusive transcanal EES, while 2 through combined endoscopic and microscopic technique (both canal-wall up procedures for cholesteatoma). In none of the 3D procedures a switch to 2D view was needed. The details regarding patients' general information and surgical procedures are summarized in **Table 1**. Regarding cholesteatoma surgery, in both groups 3 atticotomies with disease removal, 2 canal-wall-up tympanoplasties and 1 second-look procedure were included respectively. Mean operative time was 99 minutes in the 3D group and 85 minutes in the 2D one; the difference was not significant (p value=0.38).

No intraoperative complications were recorded. In the immediate post-operative period 2 patients from the 3D group suffered from transient vertigo, both after revision tympano-ossiculoplasty for chronic otitis media. Then, in the first 4 weeks after operation, 2 patients (one per group) reported transient and self-limited vertigo, associated to tinnitus in one of them. At three-month follow-up, none of the patient suffered from vertigo, tinnitus or facial palsy. Graft intake rate evaluated at last follow-up was 100% (17/17) in the 3D group and 88 % (15/17) in the 2D group (p value>0.9). One patient with cholesteatoma from the 3D group underwent a second-look surgery for PORP failure with persistent conductive hearing loss. Intraoperatively, abundant scarring was observed, without evidence for persistent cholesteatoma.

Audiometric data is summarized in **Table 2**. None of the patients experienced sensorineural hearing loss after the surgery (p value of preoperative vs postoperative mean BC-PTA = 0.401 and 0.247 and, in 3D and 2D group respectively).

Overall, the mean ABG improved in both groups, with an ABG closure of 6.8 dB in 3D group (p value = 0.06) and of 10.8 dB in 2D group (p value = 0.001).



The AC gain was 5.3 dB in the 3D group ( $p$  value = 0.08) and 9.4 dB in the 2D group ( $p$  value = 0.002). However, when comparing post-operative data between the 3D and 2D groups, no statistically significant difference was found, as reported in **Table 2**.

#### *Surgeons' feedback and scrub nurses' point of view*

The results from the questionnaires on the intraoperative 3D experience collected by all the surgeons involved in the study are summarized in **Figure 3** and **4**. Overall, 96% of surgeons agreed or strongly agreed that the 3D system guarantees better views of both anatomy and pathology. Eighty-three per cent of the participants agreed or strongly agreed that 3D EES improves depth perception. More variable opinions were reported on the surgical time with 3D system, as some of the interviewed disagree on 3D being faster than 2D. None of them, however, strongly disagree with the potential positive features of 3D.

Discomfort induced by the 3D view was rarely reported by the participants. The most common symptom was headache after surgery. Some declared that occasionally the new system was more exhausting compared to 2D. Less than one third of surgeons experienced vertigo during or after 3D surgery.

Comments written in the free-text space of the questionnaire are reported in **Figure 5**.

The interview with the scrub nurses revealed the following comments to be considered: (1) a sterile bag is not needed to cover the videoscope, as it is fully autoclavable; this speeds up the preparation of the operating setting and, at the same time, make the scope easier to handle; (2) working alongside the surgeon, the nurse cannot always have a perfect straight view on the 3D monitor. As a consequence, the quality of 3D imaging from their point of view could be tarnished and this occasionally determines eyestrain and headache. Therefore, they reported to prefer to remove the polarizing glasses and watch surgery on

the 2D assisting monitor. They also suggested that a larger screen or an additional 3D monitor to be placed in front of the scrub nurse could overcome this limitation.

## **Discussion**

This study analyses the role of 3D in the setting of endoscopic ear surgery. The comparison between patients operated with the new 3D system with those who underwent conventional 2D EES revealed overall similar surgical and functional outcomes. When investigating the surgeons' point of view on the suitability and specific operative features of 3D in EES, a general attitude in favour of the use of 3D was found.

With the introduction of 4 mm high-definition 3D videoscopes, the interest in the application of 3D to EES has recently risen. As suggested by pioneering papers on this very topic, 3D endoscopy is deemed appropriate for selected cases of ear surgeries.[11–13] Data from our series suggested that EES with 3D system is feasible and safe, and a switch to 2D was not needed in any case. Nevertheless, selection of candidates for 3D EES is fundamental since the non-existence of 3 mm diameter videoscopes contraindicates this type of surgery in pediatric patients and in adults with very narrow EAC. This drawback would be probably overcome in the future, considering that 3D endoscopy is awaited to be applied to pediatric populations or to dimensionally challenging fields in other surgical settings.[14–17]

So far the commercially available 3D endoscopes are also longer than the conventional ones for 2D EES (18 cm vs 14 cm). However, these technical differences in terms of diameter and length were not reported as limitations by our cohort of surgeons. Indeed, seventy-four per cent of them declared that the 3D system is easy to use.

Several studies have investigated the benefits of 3D surgery in head and neck surgery as well as other surgical specialties. [10,17,18]. First of all, enhanced depth perception and

better spatial orientation are largely cited as the main advantages of such technology. This has been confirmed by our study, as shown by the surgeons' feedback. Secondly, positive outcomes in terms of safety, shorter operative times, shorter hospital stays and lower number of complications have been reported mostly from 3D laparoscopy and urology studies.[19,20] In our case-control series, operative time and number of complications did not differ significantly between the two groups. This could be partially attributed to the low number of cases included. It could also be argued that the use of 3D did not require longer surgical time, since it is easy and intuitive to use for surgeons confident with EES.

When working inside the middle ear, the increased spatial orientation provided by the 3D system is helpful because the relationship of the structures located on a similar but not identical plane (such as the tympanic segment of the facial nerve, the tensor tympani muscle and tendon) can be directly appreciated on the 3D view. This is especially valuable for activities that demand a high degree of spatial and depth perception, such as in manipulations of the ossicular chain and particularly the stapes. Moreover, the 3D endoscopic view of ear anatomy could represent an effective teaching methodology for medical students and residents, who can share a more realistic view of the middle ear structures. [21]

As emerged also from the experience of 3D for recreational purposes, visual discomfort is among the major limitations of currently available 3D systems. Eyestrain and associated symptoms, such as fatigue, pain, blurred vision, headache, nausea and vertigo, during or after 3D viewing, have been related mostly to the excessive binocular disparity compared to the individual fusional capacity of the images. Other factors, such as the augmented accommodation-convergence linkage, the speed of local and global motion and occasional stereoscopic distortions, have been advocated as possible mechanisms.[22–25] According

to Wilhelm et al, the most modern 3D systems (displays, cameras, light technology, use of shutter goggles instead of polarizing glasses) have been able to minimize visual distortions.[26] Among the surgeons from our study, the perception of subjective discomfort (in the form of headache, vertigo and eyestrain) was overall limited. This could be related to the limited movements of instruments and the scope inside a small surgical field, such as the middle ear. On the other hand, scrub nurses pointed out that greater eyestrain and headache are experienced from their point of view, mostly because a completely straight view on the monitor was difficult to achieve. This underlines the relevance of the position of the viewer respect to the monitor, to lower visual discomfort during surgery. As already suggested by some authors, visual fatigue may be reduced by training and experience with the 3D system, even though specific studies are needed to address this.[23]

Another factor possibly impeding the 3D view is intraoperative bleeding.[23] Even a small amount of blood may lead to a rapidly blurred vision and the colour rendition is altered with an overall reddish image, where the structures are difficult to distinguish. Bleeding is a major concern in any endoscopic procedure, but it plays a crucial role in EES where the surgical field is tiny and the simultaneous use of instruments and blood suction is impossible.[27,28] However, it has been shown that various strategies and hemostatic agents could be applied during EES to successfully manage bleeding. Reasonably, the same bleeding control strategies should be applied in 3D EES, and frequent cleaning of the tip of the endoscope and use of anti-fogging solution are recommended as during conventional EES. Given the tendency of 3D view to easily deteriorate with bleeding, this issue could represent a limitation on the use of 3D system by novice surgeons, who are not yet familiar with bleeding management.

Interestingly, a recent paper suggested that inexperienced surgeons significantly benefit from 3D EES, compared to more expert surgeons: a tendency to shorter operative times with 3D was found in the residents' group, while consultants took longer to perform the same surgeries with 3D. Moreover, the fixation duration (how long the eyes of the surgeon stay still and focused on a specific area of the field) was shorter for experienced surgeons using 3D, while it was minimally influenced in the inexperienced group. These findings have been interpreted as the mental surgical setting of inexperienced surgeons not being well established yet; therefore they can benefit from the additional information provided by stereoscopic vision straightforwardly during surgery.[13] Further research is needed to investigate how these aspects have an impact on clinical situations.

Other factors important for the clinical adaptation are the small processing delay of the 3D imaging and the camera autofocus. During fast movements of the endoscope inside the tympanic cavity, the surgeon may have the sudden, short lasting impression that the image provided on the screen is not the one expected from the actual location of the tip. However, this has not determined a significantly longer operative time than 2D operations, suggesting that the slow and controlled maneuvering needed during 3D EES is similar to that applied in 2D surgeries. It could also mean that occasional processing lag of 3D is counterbalanced by the superiority of depth perception and stereoscopic vision. Overall, with previous manual focusing, the surgeon had a limited focus range to use and he/she had to change it turning a dedicated focus ring. In the modern 3D system, the focus is automatically guaranteed throughout the procedure, provided that the tip of the endoscope is maintained clear and defogged.

### *Strengths and limitations*

To the best of authors' knowledge, this is the first case-control study to systematically compare 3D vs 2D technology in EES.

Despite the limited number of patients included, the matching process was especially accurate on the diagnosis, type and extent of surgery, which are extremely relevant factors to consider in the analysis of surgical and functional outcomes. Any difference in this kind of results would possibly emerge from larger-scale multi-center studies.

Due to the retrospective nature of the study and given the actual availability of 3D systems patented for endoscopic ear surgery, longer, 4 mm 3D scopes were compared to 3 mm, shorter 2D scopes, creating a potential systematic bias in this study. However, a general positive attitude in favour of 3D was found among the participating surgeons and no specific technical limitations on 3D endoscopes were reported.

Compared to the work by Chen et al, where the observers in the operating room were asked to fill in the same questionnaires on 3D, the feedback on 3D from the operating surgeons was assessed with specific questionnaires and considered independently FROM scrub nurses' point of view for results interpretation. Therefore, data on 3D EES as reported in this study are representative of the direct experience of surgeons using this new technique.

## **Conclusions**

The surgical and functional outcomes of endoscopic ear surgeries respectively performed by the use of 3D and 2D systems are overall similar, suggesting that both techniques are safe and effective.

According to the surgeons' feedback, 3D provides better depth perception and improved view of anatomy and pathology of the middle and external ear, so that a considerable number of surgeons was more favourable to 3D and willing to use it in the future for EES.

To guarantee the best 3D EES experience, the setting of the 3D system in the operating room plays a crucial role and is described hereby.

Accepted manuscript

## References

- [1] Marchioni D, Alicandri-Ciufelli M, Pothier DD, et al (2015) The round window region and contiguous areas: endoscopic anatomy and surgical implications. *Eur Arch Otorhinolaryngol* 272(5):1103–12.
- [2] Anschuetz L, Presutti L, Marchioni D, et al (2018) Discovering Middle Ear Anatomy by Transcanal Endoscopic Ear Surgery: A Dissection Manual. *J Vis Exp* (131):1–7.
- [3] Marchioni D, Alicandri-Ciufelli M, Molteni G, et al. (2010) Selective epitympanic dysventilation syndrome. *Laryngoscope* 120(5):1028–33.
- [4] Alicandri-Ciufelli M, Fermi M, Bonali M, et al (2018) Facial sinus endoscopic evaluation, radiologic assessment, and classification. *Laryngoscope* 128(10):2397–402.
- [5] Marchioni D, Molteni G, Presutti L (2011) Endoscopic Anatomy of the Middle Ear. *Indian J Otolaryngol Head Neck Surg* 63(2):101–13.
- [6] Presutti L, Anschuetz L, Rubini A, et al (2018) The Impact of the Transcanal Endoscopic Approach and Mastoid Preservation on Recurrence of Primary Acquired Attic Cholesteatoma. *Otol Neurotol* 39(4):445–50.
- [7] Marchioni D, Rubini A, Gazzini L, et al (2018) Complications in endoscopic ear surgery. *Otol Neurotol*. 39(8):1012–7.
- [8] Gulati S, Patel M, Emmanuel A, et al (2019) The Future of Endoscopy: Advances in Endoscopic Image Innovations. *Dig Endosc*
- [9] Matsunaga R, Nishizawa Y, Saito N, et al (2017) Quantitative evaluation of 3D imaging in laparoscopic surgery. *Surg Today* 47(4):440–4.
- [10] Rampinelli V, Doglietto F, Mattavelli D, et al (2017) Two-Dimensional High Definition Versus Three-Dimensional Endoscopy in Endonasal Skull Base Surgery: A Comparative Preclinical Study. *World Neurosurg* 105:223–31.



- [11] Bernardeschi D, Lahlou G, De Seta D, et al (2018) 3D endoscopic ear surgery: a clinical pilot study. *Eur Arch Otorhinolaryngol* 275(2):379–84.
- [12] Chen CK, Hsieh LC, Hsu TH (2018) Novel three-dimensional image system for endoscopic ear surgery. *Eur Arch Otorhinolaryngol* 275(12):2933–9.
- [13] Anschuetz L, Niederhauser L, Wimmer W, et al (2019) Comparison of 3- vs 2-Dimensional Endoscopy Using Eye Tracking and Assessment of Cognitive Load Among Surgeons Performing Endoscopic Ear Surgery. *JAMA Otolaryngol Head Neck Surg* e191765. doi:10.1001/jamaoto.2019.1765
- [14] Wang Y, Chen W, Xia S, et al (2019) Three-Dimensional Versus Two-Dimensional Laparoscopic-Assisted Transanal Pull-Through for Hirschsprung's Disease in Children: Preliminary Results of a Prospective Cohort Study in a Tertiary Hospital. *J Laparoendosc Adv Surg Tech* 29(4):557–63.
- [15] Wasserzug O, Fishman G, Wengier A, et al (2018) Enhanced visualization of the surgical field in pediatric direct laryngoscopy using a three-dimensional endoscopic system. *Am J Otolaryngol* 39(5):628–30.
- [16] Delgado-Fernández J, Rivero-Garvía M, Márquez-Rivas J (2017) How I do it. 3D endoscopic treatment of metopic craniosynostosis through a single incision. *Acta Neurochir (Wien)* 159(11):2067–70.
- [17] Ali MJ, Naik MN (2017) First intraoperative experience with three-dimensional (3D) high-definition (HD) nasal endoscopy for lacrimal surgeries. *Eur Arch Otorhinolaryngol* 274(5):2161–4.
- [18] Albrecht T, Baumann I, Plinkert PK, et al (2016) Three-dimensional endoscopic visualization in functional endoscopic sinus surgery. *Eur Arch Otorhinolaryngol* 273(11):3753–8.
- [19] Dirie NI, Wang Q, Wang S (2018) Two-Dimensional Versus Three-Dimensional

Laparoscopic Systems in Urology: A Systematic Review and Meta-Analysis. *J Endourol* 32(9):781–90.

- [20] Cheng J, Gao J, Shuai X, et al (2016) Two-dimensional versus three-dimensional laparoscopy in surgical efficacy: A systematic review and meta-analysis. *Oncotarget* 7(43):70979–90.
- [21] Anschuetz L, Huwendiek S, Stricker D, et al (2018) Assessment of Middle Ear Anatomy Teaching Methodologies Using Microscopy versus Endoscopy: A Randomized Comparative Study. *Anat Sci Educ* 11:1–11.
- [22] Cho S, Kang H. (2012) An Assessment of Visual Discomfort Caused by Motion-in-Depth in Stereoscopic 3D Video 65.1-65.10.
- [23] Nomura K, Kikuchi D, Kaise M, et al. (2019) Comparison of 3D endoscopy and conventional 2D endoscopy in gastric endoscopic submucosal dissection: an ex vivo animal study. *Surg Endosc* 33(12):4164–2170.
- [24] Bang JW, Heo H, Choi JS, et al (2014) Assessment of eye fatigue caused by 3D displays based on multimodal measurements. *Sensors (Switzerland)* 14(9):16467–85.
- [25] Solimini AG, Mannocci A, Di Thiene D, et al (2012) A survey of visually induced symptoms and associated factors in spectators of three dimensional stereoscopic movies. *BMC Public Health* 12(1).
- [26] Wilhelm D, Reiser S, Kohn N, et al (2014) Comparative evaluation of HD 2D/3D laparoscopic monitors and benchmarking to a theoretically ideal 3D pseudodisplay: Even well-experienced laparoscopists perform better with 3D. *Surg Endosc* 28(8):2387–97.
- [27] Alicandri-Ciufelli M, Pingani L, Mariano D, et al (2019) Rating surgical field quality in endoscopic ear surgery: proposal and validation of the “Modena Bleeding Score.”

*Eur Arch Otorhinolaryngol* 276(2):383–8.

- [28] Anschuetz L, Bonali M, Guarino P, et al (2017) Management of Bleeding in Exclusive Endoscopic Ear Surgery: Pilot Clinical Experience. *Otolaryngol Head Neck Surg* 157(4):700–6.

**Table 1. Patients and surgical procedures in three-dimensional and two-dimensional endoscopic ear surgery groups.**

	3D EES	2D EES
<b>Mean age (range)</b>	39 (16-66)	41 (15-65)
<b>Side of surgery (R:L)</b>	12:5	9:8
<b>Surgical procedures</b>		
<u>Cholesteatoma surgery</u>	6	6
<u>Tympanoplasty Type I</u>	5	5
<u>Tympanoplasty Type IIIa/b</u>	4	4
<u>Canaloplasty</u>	2	2
<b>Graft for <u>tympanoplasty</u></b>		
Fascia	6	6
Cartilage	9	9
None	2	2
<b>Material for <u>ossiculoplasty</u></b>		
Cartilage	1	0
Incus	3	5
PORP	4	3

ACCEPT

TORP	1	2
None	8	7
<b>4 week-postoperative course</b>		
TM perforation	0	1
Infection	1	1
Tinnitus	1	0
Vertigo	1 (same patient with tinnitus)	1
Facial palsy	0	0
<b>3 month-postoperative course</b>		
Graft success rate	17/17	15/17
Tinnitus	0	0
Vertigo	0	0
Facial palsy	0	0

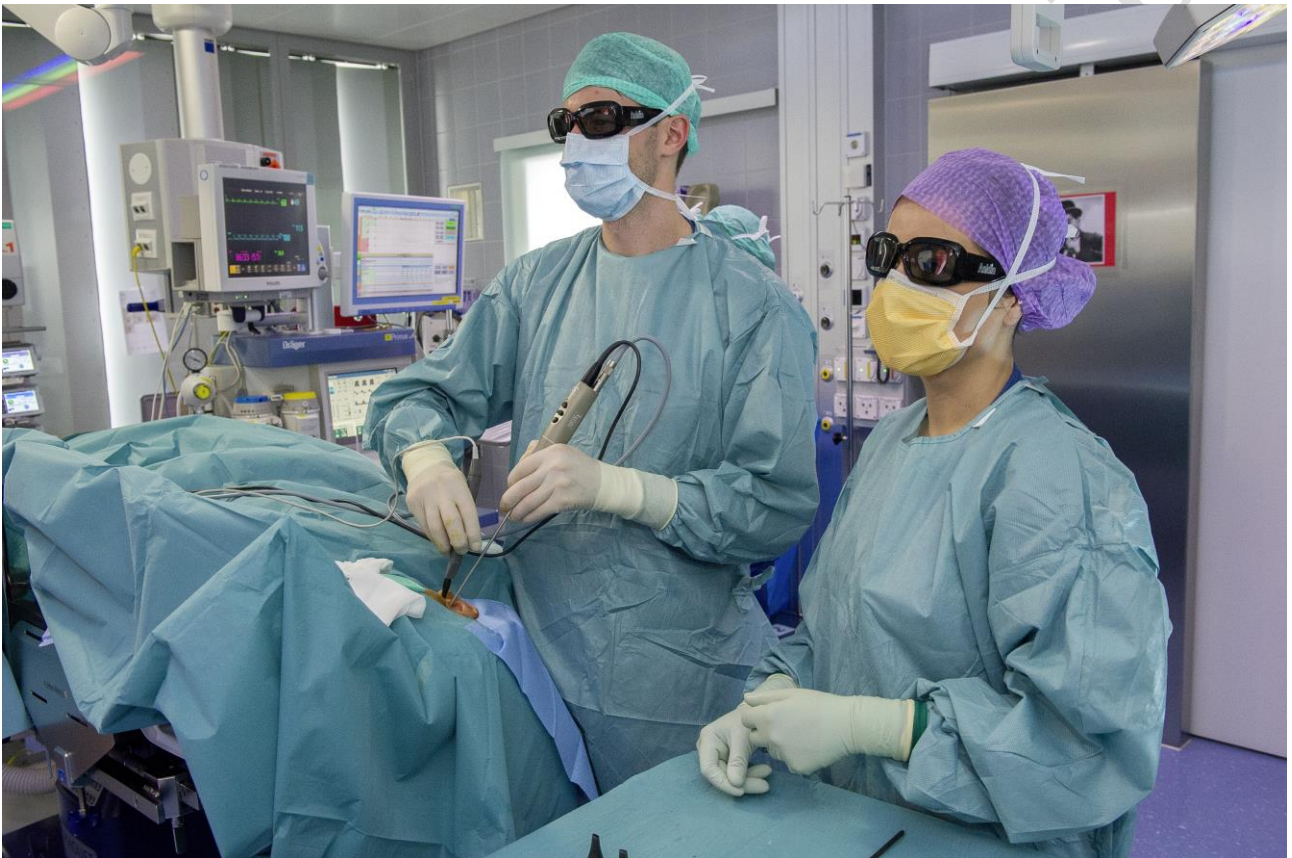M: male; F: female; R: right; L: left; PORP: partial ossiculoplasty replacement prosthesis;

TORP: total ossiculoplasty replacement prosthesis; TM: tympanic membrane

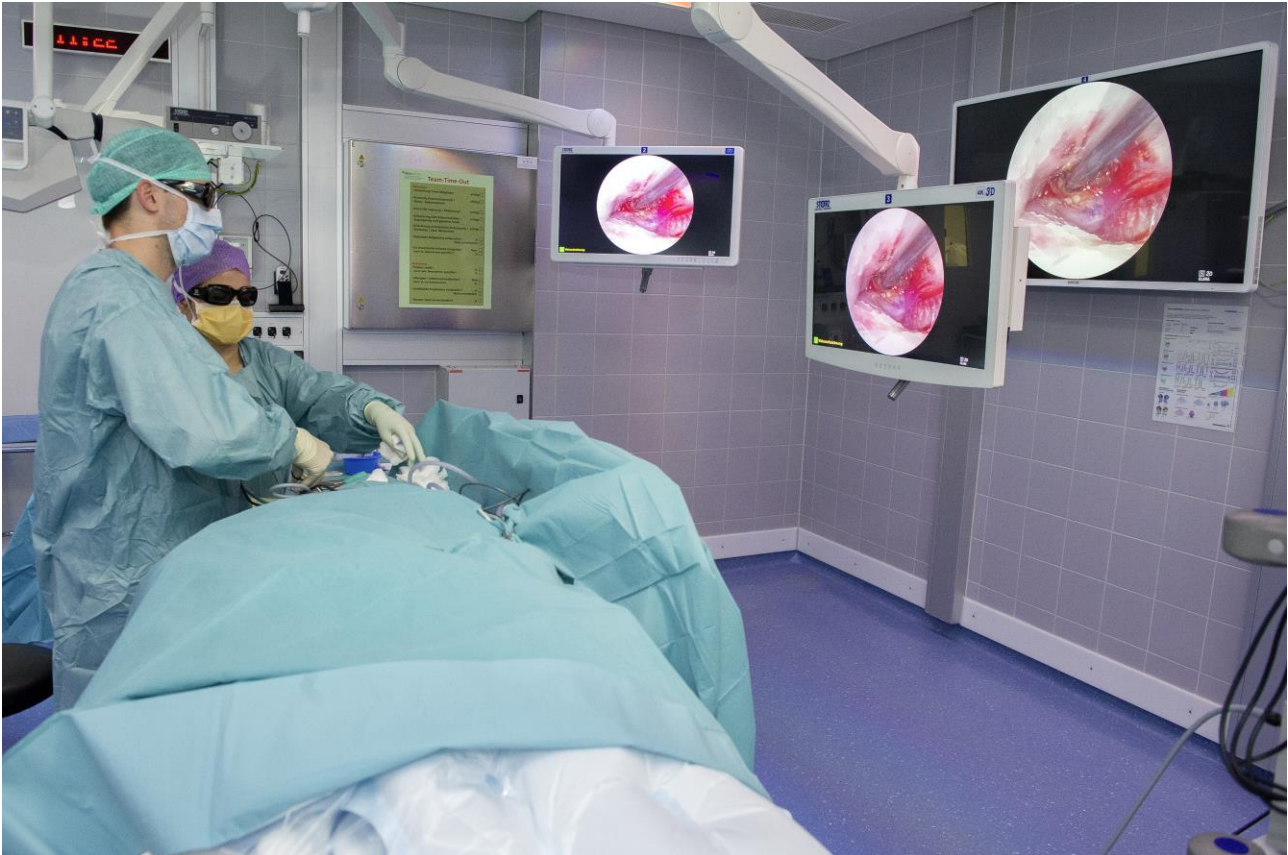Accepted manuscript

## Figure captions

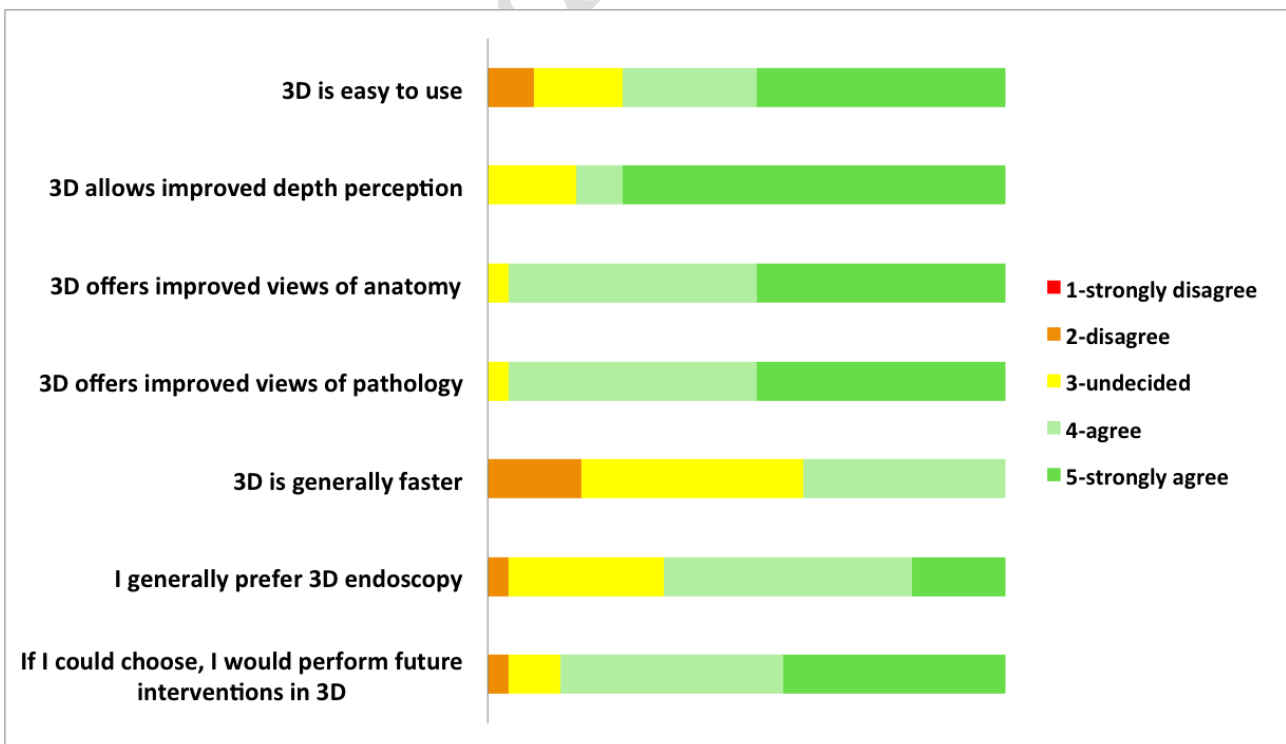
**Fig. 1:** Surgical setting for 3D endoscopic ear surgery on the right side. The surgeon holds the videoscope in the non-dominating hand and uses the surgical instruments with the opposite, as in conventional 2D surgery. Note that the videoscope is not wrapped in a sterile bag. The scrub nurse is alongside the surgeon, looking at the monitor in a straight direction as him. Both are wearing polarizing glasses for 3D view.



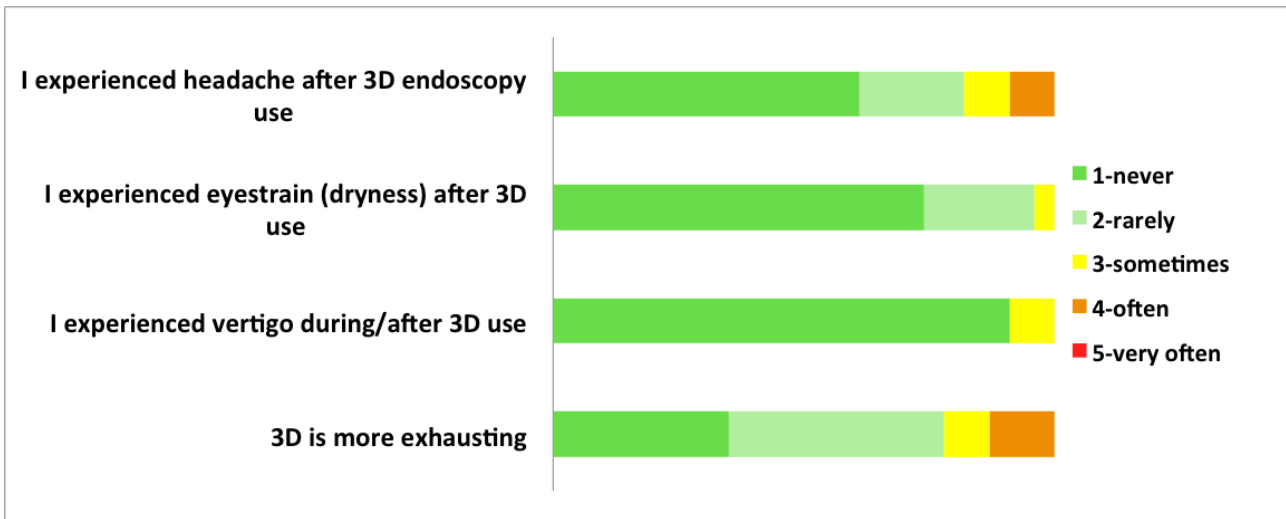
**Fig. 2:** Operating room during 3D endoscopic ear surgery. The 3D monitor is located in front of the surgeons, about 2 meters far from the surgical table. The upper margin of the screen is aligned with the surgeon's eyes. Additional screens provide 2D view.



**Fig. 3:** Surgeons' perception on the use of 3D endoscopic ear surgery on a Likert scale: easiness of use of 3D technique and comparison to conventional endoscopic ear surgery.



**Fig. 4:** Summary of feedback from surgeons on potential discomfort during 3D endoscopic ear surgery, according to a five-item Likert scale.



**Fig. 5:** Free comments from operating surgeons on the use of 3D technique during endoscopic middle ear surgery.

