

Case Report

Successful Treatment of Acute Promyelocytic Leukemia Complicated with Endometrial Cancer by Arsenic Trioxide

Hiroyuki Sugiura^a, Hisakazu Nishimori^{a*}, Hirofumi Matsuoka^b, Keiichiro Nakamura^b,
Keiko Fujii^a, Nobuharu Fujii^a, Ken-ichi Matsuoka^a, and Yoshinobu Maeda^a

Departments of ^aHematology and Oncology, ^bObstetrics and Gynecology, Okayama University Graduate School of Medicine, Dentistry and Pharmaceutical Sciences, Okayama 700-8558, Japan

Acute promyelocytic leukemia (APL) is a hematological emergency that requires urgent intervention because of the high incidence of early hemorrhagic death. When patients with APL experience a synchronous solid organ tumor, the tumor's treatment must also be done properly. Differentiation-inducing therapy using arsenic trioxide (ATO) has less hematological toxicity compared to cytotoxic chemotherapy and might be preferable for untreated APL patients with a synchronous solid organ tumor. Here we describe the first successful case of untreated APL and synchronous endometrial cancer (in an adult Japanese woman) treated with ATO consolidation therapy and the subsequent surgery and chemotherapy for endometrial cancer.

Key words: acute promyelocytic leukemia, endometrial cancer, arsenic trioxide, synchronous multiple primary malignant tumor, chemotherapy

Acute promyelocytic leukemia (APL) is a biologically and clinically distinct variant of acute myeloid leukemia. APL is currently classified as acute promyelocytic leukemia with t(15;17)(q24.1;q21.2); *PML-RARA* in the World Health Organization classification system [1]. APL presents a hematological emergency with a high rate of critical hemorrhage due to characteristic coagulopathy, and a patient with APL needs urgent intervention by differentiation-inducing therapy. APL has become a highly curable disease due to the introduction of differentiation-inducing therapy [2]. However, if a patient with APL has another solid organ tumor at the same time, treatment for the tumor should also be done properly. Synchronous multiple primary malignant tumor (sMPMT) is a condition in which more than one type of cancer is diagnosed in the same individual within 2 months [3].

A single-center study that analyzed hematological malignancy patients with sMPMT demonstrated that the presence of sMPMT was not a significant prognostic factor [4], suggesting that it will be important to appropriately treat both the hematological malignancy and the concomitant solid tumor. Differentiation-inducing therapy by all-trans retinoic acid (ATRA) is the main initial therapy for untreated APL, and arsenic trioxide (ATO) is used to treat refractory or relapsed APL as a more potent differentiation-inducing agent. The efficacy of ATRA+ATO therapy without cytotoxic chemotherapy has been reported as an initial treatment for untreated APL [5,6]. In these reports, cytotoxic chemotherapy was omitted through all phases of the initial treatment of untreated APL including induction, consolidation, and maintenance, and the event-free survival and overall survival rates were not inferior to those achieved with ATRA+cytotoxic chemotherapy. In addition,

Received May 8, 2020; accepted November 9, 2020.

*Corresponding author. Phone: +81-86-235-7227; Fax: +81-86-232-8226
E-mail: n-mori@md.okayama-u.ac.jp (H. Nishimori)

Conflict of Interest Disclosures: No potential conflict of interest relevant to this article was reported.

tion, the hematological toxicity and the risk of infections were significantly reduced in the ATRA+ATO therapy group.

Considering these reports, it appears that consolidation therapy using ATO instead of cytotoxic chemotherapy might be preferable for patients with both untreated APL and solid organ tumor complications because of its lesser hematological toxicity. In addition, there are several reports regarding the treatment of secondary APL after chemotherapy for a solid organ tumor [7,8], but to the best of our knowledge, there are no reports about the treatment of untreated APL together with a solid organ tumor. Here, we report the first case of untreated APL and synchronous endometrial cancer treated successfully with ATO consolidation therapy instead of cytotoxic chemotherapy. The patient then underwent surgery and weekly TC therapy: paclitaxel (PTX) plus carboplatin (CBDCA) for the treatment of endometrial cancer.

Case Description

A 67-year-old Japanese female (one normal vaginal delivery, menopause at 48 years old, body surface area 1.636 m² with abnormal uterine bleeding) was diag-

nosed with endometrial cancer, stage IIIc (T2N1M0). The pathological phenotype was serous adenocarcinoma. The patient simultaneously had pancytopenia and bleeding tendency. Bone marrow aspiration (BMA) revealed atypical promyelocytes with Auer rods which comprised 86% of nucleated cells. The G-banding karyotype was t(15; 17) (q22; q21), and fluorescence *in situ* hybridization showed *PML/RARA* fusion signal. The patient was diagnosed as having APL. Her white blood cell (WBC) and platelet counts were 410/ μ L and 3,100/ μ L, respectively and the risk of stratification, as defined by the PHETHEMA and GIMEMA cooperative groups, was intermediate [9]. The laboratory data, tumor marker and BMA findings are shown in Table 1. Images of the atypical promyelocytes in a BMA smear and the endometrial cancer shown by an enhanced computed tomography (CT) scan are provided in Fig. 1.

Because of its poor prognosis, the patient's APL was treated prior to her endometrial cancer. First, the patient received ATRA (45 mg/m² daily) as induction therapy, and the WBC count gradually increased. Idarubicin (IDR, 8 mg/m² daily, 3 days) and cytarabine (Ara-C, 100 mg/m² daily, 5 days) were added from day 13. After this cytotoxic chemotherapy, APL cells were not detected in peripheral blood, but the number of

Table 1

CBC		Biochemistry and tumor marker		BMA	
WBC	410 / μ L	TP	6.7 g/dL	NCC	85,000 / μ L
Neu	12 %	Alb	4.3 g/dL	APL cell	86 %
Lymph	82.5 %	T.Bil	0.6 mg/dL	G-banding	
Atypical Lymph	1 %	AST	17 U/L	46XX, t(15; 17)(q22; q12)	
APL cell	4.5 %	ALT	16 U/L	[19/20]	
RBC	280 \times 10 ⁶ / μ L	γ -GTP	16 U/L	FISH	
Hb	9.8 g/dL	Cre	0.52 mg/dL	<i>PML/RARA</i> fusion signal	99/100
Plt	3,100 / μ L	BUN	14 mg/dL		
		Na	141 mmol/L		
		K	4 mmol/L		
Coagulation test		Cl	108 mmol/L		
PT	11.7 sec	CEA	1.3 ng/mL		
APTT	28.9 sec	CA19-9	9.4 U/mL		
Fib	170 mg/dL	CA125	56 U/mL		
AT III	99 %				
FDP	47.5 μ g/mL				
D-dimer	18.6 μ g/mL				

CBC, complete blood count; RBC, red blood cell; WBC, white blood cell; Neu, neutrophil; Lymph, lymphocyte; APL, acute promyelocytic leukemia; Hb, hemoglobin; Plt, platelet; PT, prothrombin time; APTT, activated partial thromboplastin time; Fib, fibrinogen; FDP, fibrin degradation product; TP, total protein; Alb, albumin; T.Bil, total bilirubin; AST, aspartate aminotransferase; ALT, alanine aminotransferase; γ -GTP, γ -glutamyl transpeptidase; Cre, creatinine; BUN, blood urea nitrogen; CEA, carcinoembryonic antigen; CA-19-9, carbohydrate antigen 19-9; CA125, carbohydrate antigen 125; BMA, bone marrow aspiration; NCC, nucleated cell count; FISH, fluorescence *in situ* hybridization.

WBCs decreased. Pancytopenia recovery was on day 47 (from the induction of therapy), and the patient achieved complete cytogenetic remission on day 51 (Fig. 2).

After the induction therapy, ATO (0.15 mg/kg daily, on weekdays) was given as consolidation therapy instead of chemotherapy, and complete molecular remission was confirmed. Due to mild hematological toxicity, surgery for endometrial cancer (abdominal simple hysterectomy, bilateral appendectomy, pelvic and para-aortic lymph node dissection, and omentectomy) was conducted 10 days after the ATO administration. The bleeding volume was 510 g. Following the successful surgery, a second cycle of ATO (0.15 mg/kg daily,

on weekdays) was safely added. Complete molecular remission was obtained after the 2 courses of consolidation therapy (Fig. 3).

A CT scan of the patient's chest after consolidation therapy for APL at 142 days after her first admission revealed a single 8-mm-dia. lung metastasis of endometrial cancer. The patient had been treated with 18 cycles of weekly TC therapy: PTX (80 mg/m²) and CBDCA (area under the blood concentration-time curve=2) [10] instead of maintenance therapy with APL, resulting in a complete response to the lung metastasis (Fig. 4). Three months after the chemotherapy, endometrial cancer remained undetected, and APL had been under complete molecular remission.

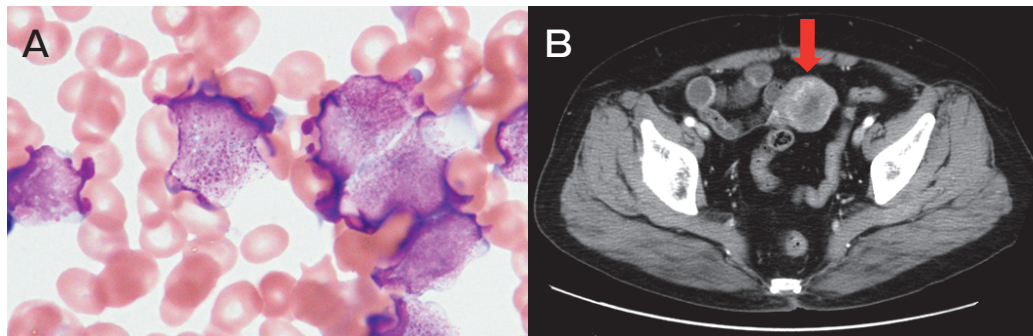


Fig. 1 Bone marrow aspiration smear image and contrast CT scan. **A**, BMA smear at the patient's first admission day (May-Giemsa stain, × 1000) showing granular atypical cells (APL cells); **B**, Contrast CT at 7 days before the first admission, revealing endometrial cancer (red arrow).

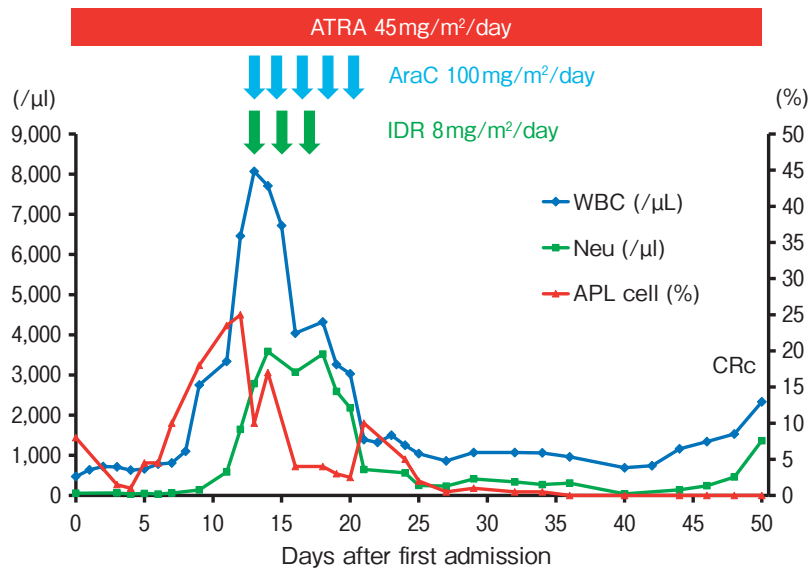


Fig. 2 Induction therapy for APL. The patient first received all-trans-retinoic acid (ATRA) only as induction therapy, but the number of leukocytes gradually increased. Cytotoxic chemotherapy was introduced from day 13, and a cytogenetic CR was achieved on day 51. APL, acute promyelocytic leukemia; AraC, cytarabine; ATRA, all trans-retinoic acid; CR, complete remission; CRc, complete cytogenetic remission; IDR, idarubicin; Neu, neutrophil; WBC, white blood cell.

The patient then started to receive tamibarotene (Am80, 6 mg/m² daily) as maintenance therapy for APL. Six months after the start of the Am80 maintenance therapy, the reappearance of lung metastasis and the enlargement of the para-aortic lymph node were

confirmed by CT scans. The patient was diagnosed with recurrent endometrial cancer and was administered 15 additional cycles of weekly TC therapy. A complete response was achieved again and maintained for 6 months with no recurrence of APL for 3 years.

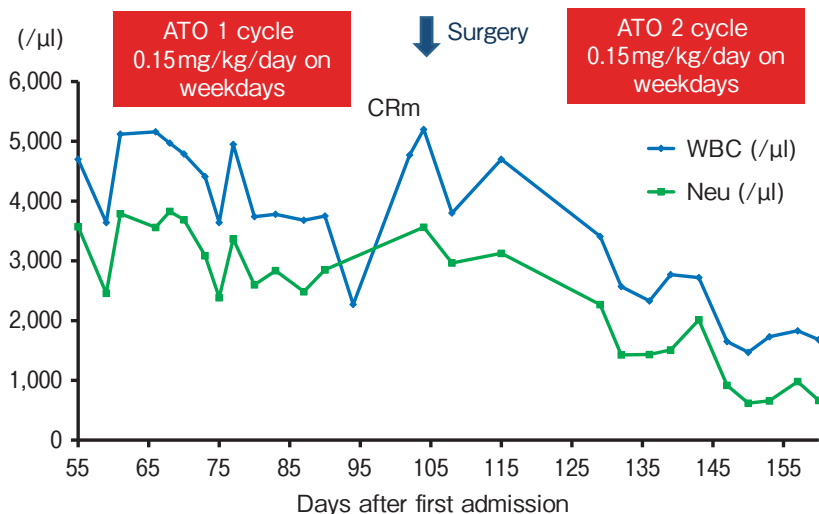


Fig. 3 Consolidation therapy for APL and surgery for endometrial cancer. ATO was given as consolidation therapy, and a CR was confirmed at the molecular level. Due to the presence of mild hematological toxicity, surgery was conducted for the patient's endometrial cancer soon after the ATO treatment. Following the successful surgery, a second cycle of ATO was also safely administered. The patient continued to show a CR after two courses of the consolidation therapy. ATO, arsenic trioxide; CR, complete remission; CRm, complete molecular remission; Neu, neutrophil.

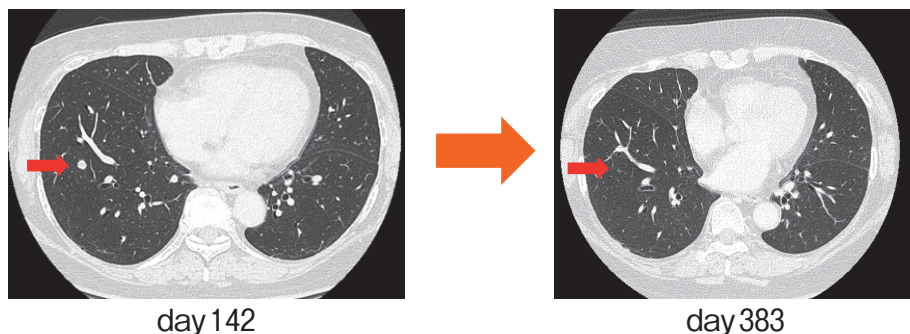
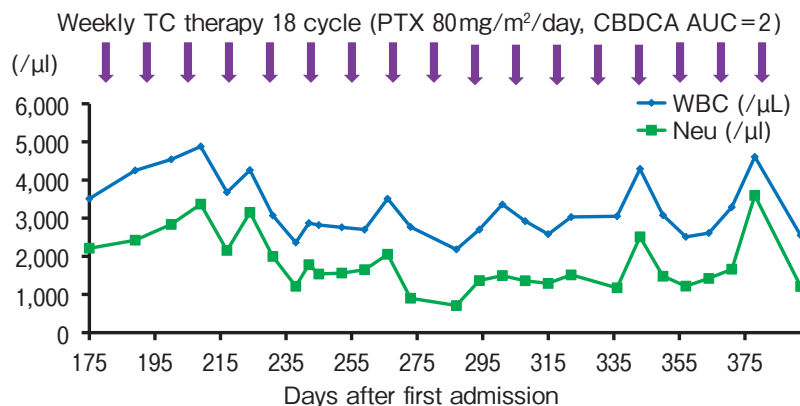


Fig. 4 Chemotherapy for metastatic endometrial cancer. After the second cycle of ATO therapy, the chest CT scan showed a single metastasis of endometrial cancer in the lung (red arrow). The patient had been treated with 18 cycles of weekly PTX and CBDCA instead of maintenance therapy for APL, resulting in a complete response to lung metastasis. APL, acute promyelocytic leukemia; ATO, arsenic trioxide; AUC, area under the blood concentration-time curve; CBDCA, carboplatin; PTX, paclitaxel.

Discussion

Prolonged cytopenia following the first course of chemotherapy for a hematologic malignancy can be challenging for the subsequent treatment of solid organ tumors. A relatively less cytotoxic therapy, such as ATO, seemed a reasonable option for a subsequent surgery or chemotherapy of a solid organ tumor. Here, we successfully treated both the patient's untreated APL and her endometrial cancer, using ATO as consolidation therapy for APL; the subsequent surgery and chemotherapy for endometrial cancer were conducted successfully due to the lesser hematological toxicity of ATO.

More recently, differentiation-inducing therapy using ATRA and ATO has been the trend of treatment for untreated APL. Nowadays this is preferred through all phases of treatment over the conventional use of ATRA combined with chemotherapy, especially for cases with low/intermediate-risk APL. Lococo *et al.* reported that the efficacy of ATRA+ATO therapy was not inferior to that of ATRA+cytotoxic chemotherapy for low/intermediate-risk APL, and the hematological toxicity and the risk of infections were increased in the patients who received ATRA+cytotoxic chemotherapy [5]. Moreover, Burnett *et al.* reported the efficacy and safety of the ATO+ATRA approach in multiple risk groups [6]. These 2 randomized trials also confirmed that ATO+ATRA was hematologically less toxic compared to ATRA-cytotoxic chemotherapy. Considering these 2 reports, ATO consolidation might be the preferred choice for the prompt subsequent treatment of patients with untreated APL and a solid organ tumor.

In addition, there is a case report that showed the efficacy of ATO in the treatment of platinum-resistant recurrent endometrial cancer [11]. However, because cytotoxic chemotherapy has played such an important role in as an option for untreated APL for many years, careful monitoring for recurrence should be done if cytotoxic chemotherapy was omitted.

A single-center study revealed that the presence of sMPMT was not a significant risk factor for newly diagnosed hematological patients, and it is important to provide adequate treatment for both hematological malignancies and solid tumors [4]. In that study, the order of treatment was not associated with the prognosis; rather, it was decided based on the prognosis of the combination of diseases and various other factors.

Untreated APL has had an extremely poor prognosis because of the risk of hemorrhagic death, and differentiation therapy should thus be performed promptly [2]. On the other hand, the treatment of our present patient's endometrial cancer was not urgent, as the reported 5-year survival of endometrial stage IIIc cancer was 65% [12]. Taken together, the above-mentioned findings led us to initiate the treatment for APL prior to that for endometrial cancer in our patient. There are few studies about the treatment of patients with a hematological malignancy and sMPMT, and further research is necessary to establish the optimal treatment.

In our patient's case, we conducted TC therapy for the recurrence of endometrial cancer. TC therapy has resulted in less peripheral neuropathy, and the non-inferiority of TC therapy to TAP therapy (*i.e.*, paclitaxel, doxorubicin, and cisplatin, which was the standard first-line therapy for recurrent endometrial cancer) was reported in an interim analysis of the GOG209 trial [13]. On the other hand, for the maintenance therapy of our patient's untreated APL, we used Am80 because the 7-year relapse-free survival rate was significantly higher in Am80 maintenance compared to that of ATRA in all-risk untreated APL patients [14].

In conclusion, we experienced a patient with untreated APL and synchronous endometrial cancer. Her APL was successfully treated with ATO consolidation therapy instead of cytotoxic chemotherapy, followed by surgery and chemotherapy for her endometrial cancer. Consolidation therapy by ATO might be preferable in such a case, because of its lesser hematological toxicity.

Acknowledgments. We thank all of the staff at Okayama University Hospital for their contribution to this study.

References

1. Arber DA, Orazi A, Hasserjian R, Thiele J, Borowitz MJ, Le Beau MM, Bloomfield CD, Cazzola M and Vardiman JW: The 2016 revision to the World Health Organization classification of myeloid neoplasms and acute leukemia. *Blood* (2016) 127: 2391–2405.
2. Coombs CC, Tavakkoli M and Tallman MS: Acute promyelocytic Leukemia: Where did we start, where are we now, and the future. *Blood Cancer J* (2015) 5: e304–309.
3. Vogt A, Schmid S, Heinemann K, Frick H, Herrmann C, Cerny T and Omlin A: Multiple primary tumours: Challenges and approaches, a review. *ESMO Open* (2017) 2: 1–11.
4. Nishiwaki S, Okuno S, Suzuki K, Kurahashi S and Sugiura I: Impact

- of Synchronous Multiple Primary Malignant Tumors on Newly Diagnosed Hematological Malignancies. *Clin Lymphoma Myeloma Leuk* (2017) 17: e79–85.
5. Lo-Coco F, Avvisati G, Vignetti M, Thiede C, Orlando SM, Iacobelli S, Ferrara F, Fazi P, Cicconi L, Di Bona E, Specchia G, Sica S, Divona M, Levis A, Fiedler W, Cerqui E, Breccia M, Fioritoni G, Salih HR, Cazzola M, Melillo L, Carella AM, Brandts CH, Morra E, von Lilienfeld-Toal M, Hertenstein B, Wattad M, Lübbert M, Hänel M, Schmitz N, Link H, Kropp MG, Rambaldi A, La Nasa G, Luppi M, Ciceri F, Finizio O, Venditti A, Fabbiano F, Döhner K, Sauer M, Ganser A, Amadori S, Mandelli F, Döhner H, Ehninger G, Schlenk RF, Platzbecker U for Gruppo Italiano Malattie Ematologiche dell'Adulto, the German-Austrian Acute Myeloid Leukemia Study Group and Study Alliance Leukemia: Retinoic Acid and Arsenic Trioxide for Acute Promyelocytic Leukemia. *N Engl J Med* (2013) 369: 111–121.
 6. Burnett AK, Russell NH, Hills RK, Bowen D, Kell J, Knapper S, Morgan YG, Lok J, Grech A, Jones G, Khwaja A, Friis L, McMullin MF, Hunter A, Clark RE, Grimwade D; and UK National Cancer Research Institute Acute Myeloid Leukaemia Working Group: Arsenic trioxide and all-trans retinoic acid treatment for acute promyelocytic leukaemia in all risk groups (AML17): results of a randomised, controlled, phase 3 trial. *Lancet Oncol* (2015) 16: 1295–1305.
 7. Zhang YC, Zhou YQ, Yan B, Shi J, Xiu LJ, Sun YW, Liu X, Qin ZF, Wei PK and Li YJ: Secondary acute promyelocytic leukemia following chemotherapy for gastric cancer: A case report. *World J Gastroenterol* (2015) 21: 4402–4407.
 8. Madabhavi I, Modi G, Panchal H, Patel A, Anand A and Parikh S: Treatment related acute promyelocytic leukemia (t-APML) in breast cancer survivor treated with anthracycline based chemotherapy: Rare case report. *Int J Hematol Oncol Stem Cell Res* (2015) 9: 215–217.
 9. Sanz MA, Lo Coco F, Martín G, Avvisati G, Rayón C, Barbui T, Díaz-Mediavilla J, Fioritoni G, González JD, Liso V, Esteve J, Ferrara F, Bolufer P, Bernasconi C, Gonzalez M, Rodeghiero F, Colomer D, Petti MC, Ribera JM and Mandelli F: Definition of relapse risk and role of nonanthracycline drugs for consolidation in patients with acute promyelocytic leukemia: a joint study of the PETHEMA and GIMEMA cooperative groups. *Blood* (2000) 96: 1247–1253.
 10. Vandenput I, Vergote I, Neven P and Frédéric A: Weekly paclitaxel-carboplatin regimen in patients with primary advanced or recurrent endometrial carcinoma. *Int J Gynecol Cancer* (2012) 22: 617–622.
 11. Cai H, Li X and Wang J: Arsenic trioxide in the treatment of platinum-resistant recurrent endometrial cancer: a case report and literature review. *J Obstet Gynaecol* (2020) 40: 137–138.
 12. Chapman BV, Swanick CW, Ning MS, Allen PK, Soliman PT, Westin SN, Pardeshi V, Broaddus RR, Lu KH, Jhingran A, Eifel PJ and Klopp AH: Adjuvant combined-modality therapy for stage IIIc endometrioid and non-endometrioid endometrial cancer. *Gynecol Oncol* (2019) 154: 22–28.
 13. Miller D, Filiaci V, Fleming G, Mannel R, Cohn D, Matsumoto T, Tewari K, DiSilvestro P, Pearl M and Zaino R: Randomized phase III noninferiority trial of first-line chemotherapy for metastatic or recurrent endometrial carcinoma: A Gynecologic Oncology Group study. *Gynecol Oncol* (2012) 125: 771–773.
 14. Takeshita A, Asou N, Atsuta Y, Sakura T, Ueda Y, Sawa M, Dobashi N, Taniguchi Y, Suzuki R, Nakagawa M, Tamaki S, Hagihara M, Fujimaki K, Furumaki H, Obata Y, Fujita H, Yanada M, Maeda Y, Usui N, Kobayashi Y, Kiyoi H, Ohtake S, Matsumura I, Naoe T, Miyazaki Y and the Japanese Adult Leukemia Study Group: Tamibarotene maintenance improved relapse-free survival of acute promyelocytic leukemia: a final result of prospective, randomized, JALSG-APL204 study. *Leukemia* (2019) 33: 358–370.