

Osteosynthesis for Geriatric Acetabular Fractures: An Epidemiological and Clinico-Radiological Study Related to Marginal or Roof Impaction

Madoka Inoue^{a,b}, Tomoyuki Noda^{c*}, Takenori Uehara^d, Tomonori Tetsunaga^b,
Kazuki Yamada^e, Taichi Saito^b, Yasunori Shimamura^f, Yasuaki Yamakawa^g, and Toshifumi Ozaki^b

Departments of ^aOrthopedic Surgery, ^bMusculoskeletal Traumatology, ^cEmergency Healthcare and Disaster Medicine, ^dMedical Materials for Musculoskeletal Reconstruction, and ^eMusculoskeletal Sports Medicine, Okayama University Graduate School of Medicine, Dentistry and Pharmaceutical Sciences, Okayama 700-8558, Japan, ^fDepartment of Orthopedic Surgery, Kochi Health Sciences Center, Kochi 781-8555, Japan

This retrospective study sought to elucidate the incidence rates of roof impaction (RI) and marginal impaction (MI) and radiological and clinical outcomes of open reduction and internal fixation (ORIF) for RI and MI in geriatric acetabular fractures. The cases of 68 patients aged ≥ 65 years (mean 71 years) treated with ORIF were analyzed. MI was present in 12 fractures (67%) and an RI of the weight-bearing surface was present in 24 (46%) of the potential fracture types. Regarding the reduction quality, 54% of the reductions were graded as anatomical, 37% as imperfect, and 9% as poor. In the clinical evaluations of the 45 patients who had >1-year follow-up (follow-up rate: 66.2%), 18% were graded as excellent, 53% as good, 16% as fair, and 13% as poor. An anatomic reduction was strongly associated with good or excellent clinical and radiological outcomes. CT was superior to radiographs for detecting the residual displacement postoperatively. Postoperative deep infection occurred in four patients. Three patients (6.7%) underwent a total hip arthroplasty conversion due to secondary osteoarthritis of the hip. We recommend ORIF as the preferred surgical treatment option for displaced acetabular fractures in elderly patients.

Key words: acetabular fracture, osteosynthesis, marginal impaction, roof impaction, elderly patient

Acetabular fracture is one of the most difficult fractures to treat. It should be treated in accordance with the general principle of treatment for intra-articular fractures. The treatment principle includes anatomical reduction and stable internal fixation. If the achievement of the anatomical restoration fails, favorable outcomes cannot be obtained. The number of geriatric acetabular fractures has been increasing in recent years with the aging of many populations [1], and a recent study reported that 14% of overall acetabular fractures occurred in the elderly [2]. Even among elderly patients with acetabular fractures,

the functional prognosis is better in those who underwent surgical intervention than those who did not [3,4]; therefore, surgery is desirable if possible. However, many authors reported that obtaining favorable reduction is more difficult in elderly patients than in young patients, due to the difficulty with fixation for osteoporotic bone. Tannast *et al.* [5] reported that anatomical reduction was obtained in only 44% of elderly patients, and they pointed out the difficulty of determining which indication is more appropriate: osteosynthesis or total hip arthroplasty (THA).

Ferguson *et al.* [6] reported that the prognosis after osteosynthesis can be predicted from images at injury

[1]. They identified the following as factors associated with a poor prognosis: roof impaction (RI), femoral head impaction, comminuted posterior wall fracture, dislocation at injury, and marginal impaction (MI). RI and MI in particular cause articular incongruity and instability of the joint. However, there are few reports of a detailed incidence rate of RI or MI in elderly patients, and there is no consensus about the outcomes of patients for whom adequate reduction and fixation were performed.

The objectives of the present study were to reveal the incidence rates of MI and RI by fracture type and to elucidate the outcomes of osteosynthesis combined with reduction and fixation for RI and MI in elderly (≥ 65 years) patients with acetabular fractures.

Patients and Methods

Of the 252 patients who underwent acetabular fracture surgery by the single surgeon at our Department of Orthopedics from 2005 to 2017, 68 (27%) the cases of the patients aged ≥ 65 years were retrospectively analyzed. Each patient routinely underwent plain radiography in three directions (anteroposterior, obturator oblique, and iliac oblique views) and computed tomography (CT) scans before and after acetabular fracture surgery. We analyzed the types of fractures according to the Judet and Letournel classification [7], the RI and MI incidence rates, the quality of reduction, and perioperative complications. The maximum displacement of the acetabulum in the three-direction radiographs was recorded, and the highest value was used to grade the quality of reduction according to Matta [8]. The following grades were used: 0-1 mm of displacement = anatomical, 2-3 mm = imperfect, and > 3 mm = poor [8].

In the 45 patients with > 1 year of follow-up post-surgery (follow-up rate: 66.2%), we also investigated the radiological and the clinical outcomes according to Matta's criteria [8] and postoperative complications. Regarding the radiographic Matta criteria, a grade of excellent indicates a normal appearance of the hip; a grade of good is given when mild changes, small osteophytes, moderate (1-mm) narrowing of the joint, and minimum sclerosis are observed; a grade of fair is given when intermediate changes, moderate osteophytes, moderate ($< 50\%$) narrowing of the joint, and moderate sclerosis are observed; and a grade of poor indicates advanced osteoarthritis changes. Herein, RI

was defined as the collapse of the superomedial dome, as described by Letournel and Judet [9] and Anglen *et al.* [10], and MI was defined as the collapse of the marginal region of the acetabulum caused by posterior dislocation.

The χ^2 -test was used to elucidate relationships between the quality of reduction and radiological or clinical outcomes. The statistical analyses were performed with the Statistical Package for the Social Sciences (SPSS), ver. 20.0. Statistical significance was set at $p < 0.05$. This study was approved by the Research Ethics Committee of Okayama University (study #1712-035), and all subjects signed consent forms.

Surgical methods.

1. The surgical treatment strategy for acetabular fractures in elderly patients at our hospital is to choose a single approach, even in associated fracture patterns. The aim is to keep the blood loss at $< 1,000$ ml and the operative time < 4 h in order to avoid an extensive surgical procedure.

2-a. The reduction and fixation of each MI accompanying a posterior wall bone fragment were performed under direct viewing at the fracture site. The key to the reduction is to reduce/elevate the MI fragment including the collapsed articular surface in an en bloc manner, using an instrument such as a chisel so that the subchondral bone is attached to as much cancellous bone as possible. If the femoral head is then subluxated, this procedure results in poor reduction. It is thus important to obtain a correct reduction position beforehand. Specifically, a Schanz pin is inserted into the femoral head from the greater trochanter, and then the femoral head is pushed to the intact surface of the anterior acetabular roof for correct reduction. After a complete reduction, there is no step-off or gap between the reduced and the intact articular surfaces.

2-b. The reduction and fixation of each RI were performed using one of the following methods, depending on the fracture pattern and the location of the RI:

- Flipping anterior wall fragment: This is indicated for patients with anterior wall fracture patterns. In this method, the anterior wall fragment is overturned forward while observing the hip joint from the front in order to reduce the RI fragment under direct visualization. Preparation of the second window of the ilioinguinal approach is therefore mandatory.

- Creating a cortical window to reduce the impacted fragment: This is applied for cases in which the access

from the fracture site to the RI is difficult. A cortical window located over the RI is created to reduce the articular surface, using an instrument such as a bone impactor through the window. The use of intraoperative CT and/or CT-based navigation is beneficial, if available.

- Direct reduction and fixation from a modified Stoppa window: This method, reported by Laflamme *et al.* [11], is particularly useful for cases in which severe displacement has occurred and the RI location is mainly at a weight-bearing surface of the posterior column. Since reduction for some associated fractures is performed before the anatomical reduction is accomplished, the stable reference fragment for reduction is unreliable. Therefore, the confirmation of accurate reduction is sometimes difficult in this method. Assessment with intraoperative CT is also helpful.

3. For bone defects that emerged after reduction, we have concomitantly used a bone graft substitute block represented by β -tricalcium phosphate (β -TCP), which is fixed with osteochondral support screws (Fig. 1). Infrapectineal buttress plating was applied for acetabular fractures involving the quadrilateral plate. All fractures were fixed with reconstruction plates and screws.

4. Patients were encouraged to sit up in bed on the first day after surgery, and after the removal of the drainage tube toe-touch weight-bearing was allowed. Partial weight-bearing exercise with crutches was started after 4 or 6 weeks. Full weight-bearing was allowed after 10 or 12 weeks.

Approaches. The surgical approach was determined according to the type and nature of acetabular fractures. The anterior approaches included the ilioinguinal (IL) approach [12], the lateral window of the IL approach, the modified Stoppa approach [13] combined with the lateral window of the IL approach, the modified ilioinguinal approach [14], and the Kloen approach [15] which is the modified Smith-Petersen approach [16]. The posterior approaches included the Kocher-Langenbeck (KL) approach [17] and the KL approach combined with trochanteric flip osteotomy [18]. The combined (anterior and posterior) approach was performed through the modified IL approach with the KL approach.

Results

Patient background. The cases of a total of 68 patients were analyzed. The mean age was 72 years (range 65-86 years); 78% (n=58) were male. The cause of the injury was a fall accident in 35 patients and a motor vehicle accident in the other 33 patients. The mean interval from the injury to the surgery was 9.6 days (3-21 days) (Table 1). The mean operative time was 3 h, 50 min (1 h, 30 min to 7 h, 40 min). The mean blood loss was 1,255 ml (173-5,000 ml). The mean follow-up period for the 45 patients (follow-up rate, 66.2%) who could be followed up for > 1 year after surgery was 35 months (16-68 months).

Patterns of fracture, incidence of MI and RI, and approaches. The fracture types according to the Judet and Letournel classification [7] were anterior wall (n=5), anterior column (n=7), posterior wall (n=12), posterior column (n=3), transverse (n=1), anterior column+posterior hemitransverse (n=6), transverse+posterior wall (n=2), T-shaped (n=4), and both columns (n=28) (Table 2). There was an MI in 12 fractures (67%) and an RI of the weight-bearing surface in 24 fractures (45%) of the potential fracture types. The characteristics of the fracture types and the incidence of both impactions in the potential fracture types are demonstrated in Table 2. The surgical approach for each fracture type is shown in Table 3.

Quality of reduction. According to the grading quality of reduction by Matta [8], 54% (n=37) were graded as anatomical, 37% (n=25) as imperfect, and 9% (n=6) as poor just after the osteosynthesis. Among the 45 (66.2%) patients who could be followed up for > 1 year postoperatively, 58% (n=26) were graded as anatomical, 33% (n=15) as imperfect, and 9% (n=4) as poor. Of these 45 patients, among the 41 (60.3%) who could be assessed by MPR-CT, 37% (n=15) were graded as anatomical, 49% (n=20) as imperfect, and 17% (n=7) as poor.

Outcomes. The outcomes assessed with the Matta radiological criteria [8] were excellent in 32 patients (71.1%), good in 5 (11%), fair in 2 (4%), and poor in 6 (13%). The outcomes assessed with the Matta clinical criteria [8] were excellent in eight patients (18%), good in 24 (53%), fair in 7 (16%), and poor in 6 (13%). The mean Matta score was 14.9 points (range 5-18 points).

Relationship between radiographs or CT assessment and clinical outcomes. Of the 26 patients with

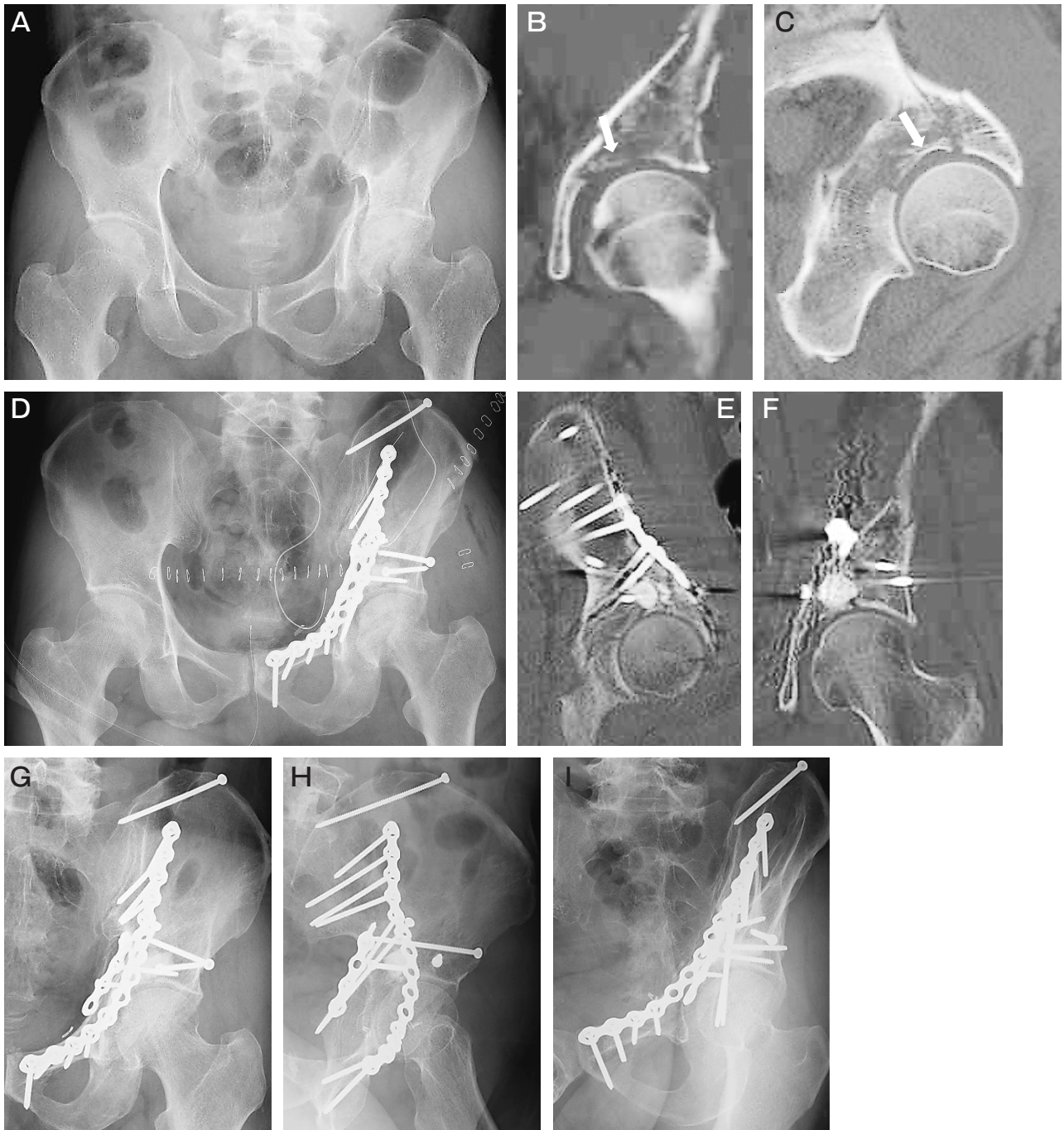


Fig. 1 Images of the clinical course in the left hip joint of a 70-year-old man who sustained a both column acetabular fracture. **A**, An anteroposterior radiograph at the injury; **B,C**, CT images at the injury showed a roof impaction (RI) fragment on the weight-bearing surface (*white arrow*); **D**, An anteroposterior radiograph after surgery showed a weight-bearing surface anatomically fixed using the modified Stoppa approach combined with the lateral-window of the ilioinguinal approach; **E,F**, CT images after surgery showed an anatomical reduction on the weight-bearing surface; **G-I**, Radiographs at 3 years post-surgery showed no sign of joint-space narrowing. The Matta clinical score was 18, and the outcome was graded as excellent.

Table 1 Patient characteristics (n = 68)

Patients (>65 years)	68
Mean age (years)	72 [65–86]
Sex	
Male	53 (78%)
Female	15 (22%)
Cause of injury	
Fall accident	35 (51%)
Motorcycle accident	33 (49%)
Mean time to surgery (days)	9.6 [3–21]

Data are presented as mean [range] or n (%).
Patient characteristics of this study.

anatomical reduction shown by radiographs, 26 (100%) had excellent or good radiological outcomes and 25 (96.2%) had excellent or good clinical outcomes. Of the 15 patients with imperfect reduction revealed by radiographs, 11 (73.3%) had excellent or good radiological outcomes and seven (46.7%) had excellent or good clinical outcomes. Of the four patients with poor reduction by radiographs, none had excellent or good radiological and clinical outcomes (Table 4).

Of the 14 patients with anatomical reduction visualized by MPR-CT, all had excellent or good radiological

Table 2 Characteristics of the fracture types and the incidence of both impactions in the potential fracture types

Fracture type	Patients	Number of patients with RI/total number of patients in each potential fracture type (%)	Number of patients with MI/total number of patients in each potential fracture type (%)
AW	5 (7.4%)	5/5 (100%)	–
AC	7 (10.3%)	1/7 (14.3%)	–
PW	12 (17.6%)	–	7/12 (58.3%)
PC	3 (4.4%)	–	–
TV	1 (1.5%)	0/1 (0%)	–
AC+PHTV	6 (8.8%)	5/6 (83%)	–
TV+PW	2 (2.9%)	0/2 (0%)	2/2 (100%)
T-shaped	4 (5.9%)	1/4 (25%)	1/4 (25.0%)
BC	28 (41.2%)	12/20 (60.0%)	2/8 (25%)
Total	68 (100%)	24/53 (45.3%)	12/18 (66.6%)

RI, roof impaction; MI, marginal impaction; AW, anterior wall; AC, anterior column; PW, posterior wall; PC, posterior column; TV, transverse; AC+PHTV, anterior column+posterior hemitransverse; TV+PW, transverse+posterior wall; BC, both column.

Table 3 Surgical approaches for each fracture type

Fracture type	Patients	Anterior approach					Posterior approach		Combined approach
		IL	LW	MS+LW	MIL	Kloen	KL	KL+TFO	MIL+KL
AW	5	1			2	2			
AC	7		4	3					
PW	12						8	4	
PC	3						3		
TV	1			1					
AC+PHTV	6			3	2				1
TV+PW	2						2		
T-shaped	4			1	2			1	
BC	28	2		18	5			2	1
Total	68 (100%)	3 (4.4%)	4 (5.9%)	26 (38.2%)	11 (16.2%)	2 (2.9%)	13 (19.1%)	7 (10.3%)	2 (2.9%)

IL, ilioinguinal; LW, Lateral window of IL; MS, Modified Stoppa; MIL, Modified IL; KL, Kocher-Langenbeck; TFO, trochanteric flip osteotomy. AW, anterior wall; AC, anterior column; PW, posterior wall; PC, posterior column; TV, transverse; AC+PHTV, anterior column+posterior hemitransverse; TV+PW, transverse+posterior wall; BC, both column.

Table 4 The relationships between the quality of reduction shown by radiographical assessment and radiological or clinical outcomes

Quality of reduction (n, %)	Radiological outcome (Matta criteria)		Clinical outcome (Matta criteria)	
	Excellent or good	Fair or poor	Excellent or good	Fair or poor
Anatomical (26, 57.8%)	26	0	25	1
Imperfect (15, 33.3%)	11	4	7	8
Poor (4, 8.9%)	0	4	0	4
Total (45, 100%)	37 (82.2%)	8 (17.8%)	32 (71.1%)	13 (28.9%)

Table 5 The relationships between the quality of reduction shown by MPR-CT assessment and radiological or clinical outcomes

Quality of reduction (n, %)	Radiological outcome (Matta criteria)		Clinical outcome (Matta criteria)	
	Excellent or good	Fair or poor	Excellent or good	Fair or poor
Anatomical (15, 36.6%)	14	0	14	0
Imperfect (20, 48.8%)	17	3	15	5
Poor (7, 17.1%)	4	3	1	6
Total (41, 100%)	35 (85.4%)	6 (14.6%)	30 (73.2%)	11 (26.8%)

Table 6 Early and late complications

Early complication (n = 68)	Patients, incidence (%)
Intraoperative vascular injury	2 (2.9%)
Postoperative arterial embolism	1 (1.5%)
Venous thromboembolism	1 (1.5%)
Sciatic nerve palsy	1 (1.5%)
Deep infection	4 (5.9%)
Postoperative redisplacement	2 (2.9%)
Late complication (n = 45)	4 (5.9%)
Heterotopic ossification (Brooker classification class III or IV)	2 (4.4%)
Avascular necrosis of the femoral head	1 (2.2%)
Posttraumatic arthrosis	8 (17.8%)

outcomes and all had excellent or good clinical outcomes. Of the 20 patients with imperfect reduction by MPR-CT, 17 (85.0%) had excellent or good radiological outcomes and 15 (75.0%) had excellent or good clinical outcomes. Of the seven patients with poor reduction by MPR-CT, 4 (57.1%) had excellent or good radiological outcomes and 1 (14.3%) had an excellent or good clinical outcome (Table 5).

The radiological and clinical outcomes were also parallel to the success of anatomical reduction confirmed by radiographs or CT assessment ($p < 0.05$). Compared with the radiographs, MPR-CT showed worse reduction in 14 patients (34%) and the same

reduction in 27 (66%).

Complications. The complications of the 68 patients at the early stage were intraoperative vascular injury (n = 2, 2.9%), postoperative arterial embolism (n = 1, 1.5%), venous thromboembolism (n = 1, 1.5%), sciatic nerve palsy (n = 1, 1.5%), deep infection (n = 4, 5.9%), and postoperative redisplacement (n = 2, 2.9%). The complications of the 45 patients at the late stage were heterotopic ossification graded as Brooker classification [19] class III or IV (n = 2, 4.4%), avascular necrosis of the femoral head (n = 1, 2.2%), and post-traumatic arthrosis (n = 8, 17.8%) (Table 6). Three (6.7%) of the 8 patients who developed osteoarthritis underwent total hip arthroplasty (THA).

Discussion

Displaced acetabular fractures in young patients are best treated with anatomical reduction and rigid internal fixation. The optimal management of elderly patients with displaced acetabular fractures remains controversial because of the patients' bone fragility, medical comorbidities, and/or certain poor prognostic factors revealed by radiography. Of the 5 poor-prognosis factors of acetabular fractures that can be observed after an injury, the gull sign (which indicates an RI), femoral head impaction, comminuted posterior wall fracture, and MI caused by posterior wall fracture are

more common in elderly patients [5]. At our hospital, we have speculated that favorable outcomes can be expected by reducing and fixing the impacted articular fragments such as MI and RI and maintaining the reduction position with stable fixation in cases of minor damage of both the acetabulum and femoral head. Consistent treatment has been performed following this strategy.

Ferguson *et al.* [6] analyzed the cases of 235 acetabular fractures in patients aged ≥ 60 years, and they reported a higher proportion of elementary fracture patterns (37.0% vs. 29.1%) and fractures involving displacement of the anterior column (63.8% vs. 43.1%) compared to the proportions in their group of young patients. The corresponding proportions in our present patient series are similar to those results: 41.1% of elementary fracture patterns and 67.6% of fractures involving the anterior column. Elementary fracture patterns and fractures characterized by displacement of the anterior column were more common in geriatric acetabular fractures.

Ferguson *et al.* [6] also reported a 38% incidence of MI among posterior wall fractures. Their assessments were based on only axial images of CT scans. The higher incidence of MI (67%) in the present study compared to their results suggests that the use of both multiplanar reconstruction (MPR) and three-dimensional (3D) CT may improve the detection accuracy of MI. We propose that especially in posterior wall fractures, performing imaging with a particular focus on MI is mandatory.

RI is more frequently diagnosed in fractures including the anterior components, with an incidence of 40% in the Ferguson *et al.* study [6]. For the identification of the RI region, multidirectional assessment by MPR and 3D-CT views are also useful. The sagittal images of CT-MPR were especially useful for the diagnosis (Figs. 1B, C and 2B, C). The key point in the diagnosis is determining the RI from the characteristic posterior wall fragment in both column fractures. The diagnosis should be made carefully based on continuous-slice MPR and 3D-CT images of the acetabular roof without the femoral head. The present analyses also revealed a high incidence rate of RI (45%) compared to the Ferguson *et al.* study [6]. The accurate diagnosis of both RI and MI would improve the reduction, which consequently leads to improved outcomes.

A single approach could be chosen in the present

series with the exception of two patients, even for the associated fracture patterns. The mean blood loss and operative time were acceptable, although in some cases it was difficult to control these values. Surgeons should take into account the tolerance of older patients and compromise on other treatment options, including a switch to a staged operation or percutaneous screwing.

Many studies have shown that the anatomic reduction of displaced acetabular fractures in young and old patients preserve the patient's own hip joint [3-8, 11, 12, 20-22]. The risk of failure and a poor result after osteosynthesis is greater in older patients. We have performed osteosynthesis consistently with improved CT assessment and surgical methods to control poor-prognosis factors.

The influence of an MI on the clinical outcome remains controversial. Boudissa *et al.* [3] and Ferguson *et al.* [6] reported that MI was a factor predicting a poor prognosis, whereas Herath *et al.* concluded that MI was not a poor-prognosis factor and was not a contraindication for osteosynthesis [4]. In contrast, Tannast *et al.* [5] reported that in cases with an MI, a favorable long-term prognosis was achieved with anatomic reduction.

Regarding RI, the gull sign described by Anglen *et al.*, which indicates that some type of RI has occurred, was 100% predictive for failure of reduction and/or fixation in elderly patients [10]. However, in cases in which the anatomical reduction and stable internal fixation were achieved by osteosynthesis, the osteoarthritis of the hip joint could be decreased [5]. Laflamme *et al.* suggested that good outcome could be obtained with the anatomical reduction of the RI [11].

In the present patient series, although there was an MI in 12 fractures (67%) and an RI of the weight-bearing surface in 24 (46%) of the potential fracture types, anatomical reduction assessed by radiography was obtained in 37 (54%) patients and imperfect reduction in 25 (37%). The incidences of MI and RI were both higher in this study compared to previous reports [8, 12, 20, 21], but improvement of the preoperative assessment and fixation technique enabled good clinical outcomes; 71% of the patients were graded as excellent or good.

Even in these elderly patients, the anatomical reduction shown by radiographs or MPR-CT was correlated with excellent or good radiological and clinical outcomes. An imperfect reduction shown by radiographs was not associated with excellent or good clinical

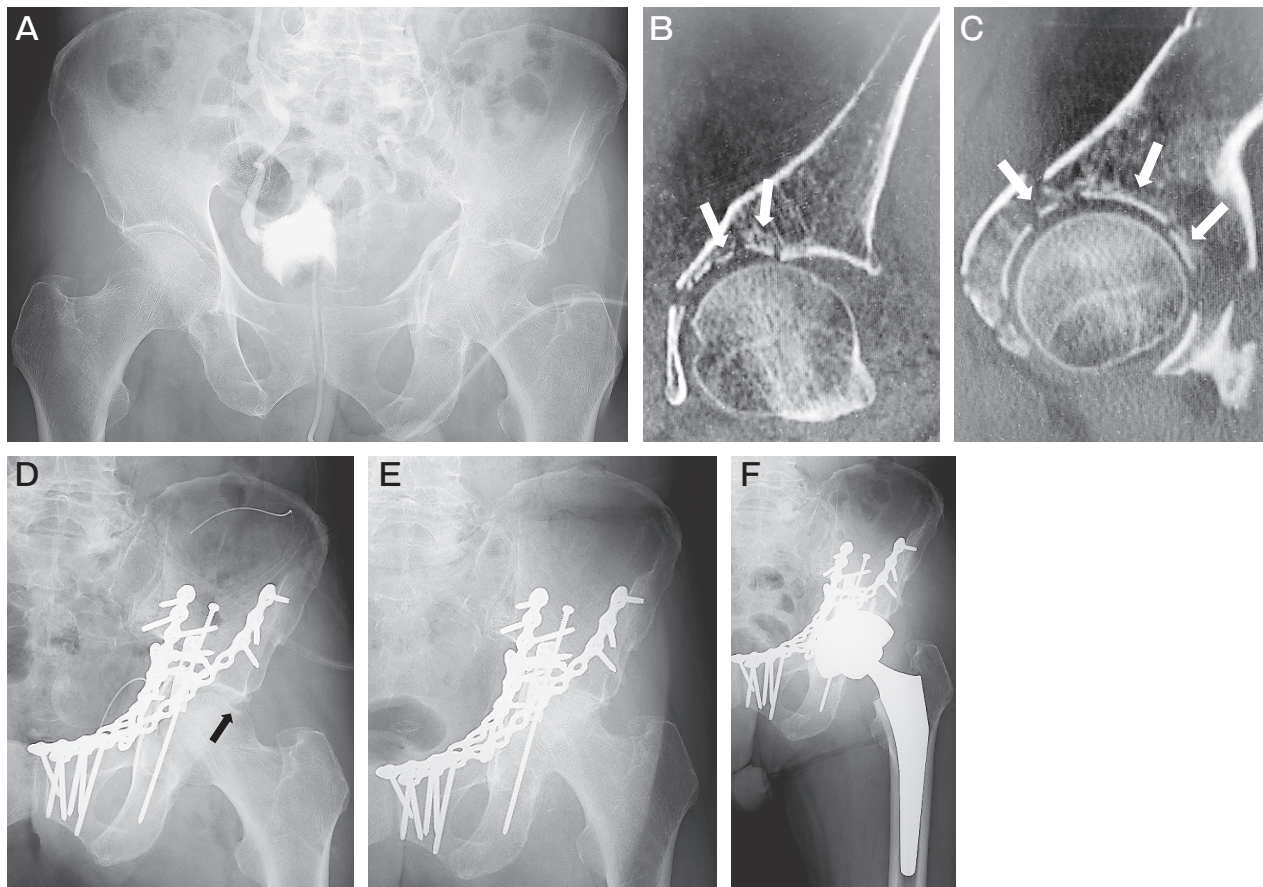


Fig. 2 Images of the clinical course in the left hip joint of a 66-year-old man who sustained a T-shaped acetabular fracture. **A**, An anteroposterior radiograph at the injury; **B,C**, CT images at the injury showed severely comminuted RI fragments on the weight-bearing surface (*white arrows*); **D**, An anteroposterior radiograph after surgery using the modified ilioinguinal approach. A femoral head injury was also observed (*black arrow*); **E**, An anteroposterior radiograph at 5 months post-surgery showed severe joint-space narrowing; **F**, An anteroposterior radiograph after the patient's total hip arthroplasty.

outcomes (7 of 15 cases, 46.7%). On the other hand, an imperfect reduction revealed by MPR-CT was associated with excellent or good clinical outcomes (15 of 20 cases, 75%). This result suggests that excellent or good reduction confirmed by MPR-CT assessment should be obtained intraoperatively.

Verbeek *et al.* [23] reported CT was superior to radiography for detecting residual displacement after acetabular fracture fixation, and the quality of reduction as assessed on CT was significantly associated with hip survival. The present analyses also demonstrated that MPR-CT showed worse reduction in 14 patients (34%) compared to the patients' radiographs. The postoperative assessment of the quality of reduction by MPR-CT provides valuable information about patients' prognoses

and the surgeons' skill level.

Concerning the complications examined herein, the incidences of sciatic nerve palsy (1.5%), deep infection (5.9%), heterotopic ossification graded as Brooker classification class III or IV (2.9%), and post-traumatic arthrosis (11.8%) were compatible to those in a meta-analysis of patients at all ages [20]. However, intraoperative vascular injury and postoperative arterial embolism occurred in three of the present cases (4.4%). It is important for surgeons to be aware of potential complications such as intraoperative vascular injury and thrombosis in geriatric patients, and to handle the vessels as gently as possible.

Regarding the THA conversion rate of osteosynthesis, a systematic review of postoperative outcomes in

patients with acetabular fractures aged ≥ 55 years showed a 19% mortality rate and the THA rate of 23.1% [24]. In the present study, we suspect that the improvement in the diagnostic accuracy of MI and RI and the surgical methods lowered the THA rate to 6.7%.

We acknowledge that it is difficult to reduce or fix the damaged and/or defected acetabular roof or femoral head. A fracture caused by severe osteoporosis leads to poor outcomes in the reduction and fixation of both MI and RI (Fig. 2A-D).

Several limitations are present in this study. The follow-up period was relatively short (the minimum follow-up was 1 year) and the follow-up rate was relatively low (66%). In addition, the sample size was small, the study design was retrospective, and this was a single-surgeon study, which may have influenced its external validity. A variety of CT scanners have been used over time, and the cases of 4 patients with incomplete postoperative CT images were included in the analyses.

In conclusion, osteosynthesis for displaced acetabular fractures in elderly patients yields good-to-excellent outcomes in the majority of patients. Despite the difficulties in the fixation of osteoporotic bone and the determination of indications for osteosynthesis and joint replacement, improved outcomes can be expected by reducing invasion based on the accurate diagnoses of RI and MI, the performance of appropriate reduction methods and approaches, and the use of fixation procedures such as the insertion of subchondral support screws to support subchondral bone, synthetic bone grafting, and quadrilateral surface buttress plating.

References

- Butterwick D, Papp S, Gofton W, Liew A and Beaulé PE: Acetabular fractures in the elderly: evaluation and management. *J Bone Joint Surg Am* (2015) 97-A: 758–768.
- Dyskin E, Hill BW, Torchia MT and Cole PA: A survey of high- and low-energy acetabular fractures in elderly patients. *Geriatr Orthop Surg Rehabil* (2019) 10: 2151459319870426.
- Boudissa M, Francony F, Drevet S, Kerschbaumer G, Ruatti S, Milaire M, Merloz P and Tonetti J: Operative versus non-operative treatment of displaced acetabular fractures in elderly patients. *Aging Clin Exp Res* (2020) 32: 571–577.
- Herath SC, Pott H, Rollmann MFR, Braun BJ, Holstein JH, Hoch A, Stuby FM and Pohlemann T: Geriatric acetabular surgery: Letournel's contraindications then and now—data from the German Pelvic Registry. *J Orthop Trauma* (2019) 33: S8–S13.
- Tannast M, Najibi S and Matta JM: Two to twenty-year survivorship of the hip in 810 patients with operatively treated acetabular fractures. *J Bone Joint Surg Am* (2012) 94-A: 1559–1567.
- Ferguson TA, Patel R, Bhandari M and Matta JM: Fractures of the acetabulum in patients aged 60 years and older: an epidemiological and radiological study. *J Bone Joint Surg Br* (2010) 92-B: 250–257.
- Judet R, Judet J and Letournel E: Fractures of the acetabulum: classification and surgical approaches for open reduction. *J Bone Joint Surg Am* (1964) 46-A: 1615–1646.
- Matta JM: Fractures of the acetabulum: accuracy of reduction and clinical results in patients managed operatively within 3 weeks after the injury. *J Bone Joint Surg Am* (1996) 78-A: 1632–1645.
- Letournel E and Judet R: *Fracture of the Acetabulum*. 2nd Ed, Springer, Heidelberg, Germany (1993): 64–314.
- Anglen JO, Burd TA, Hendricks KJ and Harrison P: The “gull sign”: a harbinger of failure for internal fixation of geriatric acetabular fractures. *J Orthop Trauma* (2003) 17: 625–634.
- Lafamme GY and Hebert-Davies J: Direct reduction technique for superomedial dome impaction in geriatric acetabular fractures. *J Orthop Trauma* (2014) 28: e39–e43.
- Letournel E: The treatment of acetabular fractures through the iliopsoas approach. *Clin Orthop Relat Res* (1993) 292: 62–76.
- Cole JD and Bolhofner BR: Acetabular fracture fixation via a modified Stoppa limited intrapelvic approach. *Clin Orthop Relat Res* (1994) 305: 112–123.
- Karunakar MA, Le TT and Bosse MJ: The modified ilioinguinal approach. *J Orthop Trauma* (2004) 18: 379–383.
- Kloen P, Siebenrock KA and Ganz R: Modification of the ilioinguinal approach. *J Orthop Trauma* (2002) 16: 586–593.
- Smith-Petersen MN: Approach to and exposure of the hip joint for mold arthroplasty. *J Bone Joint Surg Am* (1949) 31-A: 40–46.
- Letournel E and Judet R: *Fracture of the Acetabulum*. 2nd Ed, Springer, Heidelberg, Germany (1993): 363–373.
- Ganz R, Gill TJ, Gautier E, Ganz K, Krugel N and Berlemann U: Surgical dislocation of the adult hip a technique with full access to the femoral head and acetabulum without the risk of avascular necrosis. *J Bone Joint Surg Br* (2001) 83-B: 1119–1124.
- Brooker AF, Bowerman JW, Robinson RA and Riley LH: Ectopic ossification following total hip replacement. Incidence and a method of classification. *J Bone Joint Surg Am* (1973) 55-A: 1629–1632.
- Giannoudis PV, Grotz MRW, Papakostidis C and Dinopoulos H: Operative treatment of displaced fractures of the acetabulum: A meta-analysis. *J Bone Joint Surg Br* (2005) 87-B: 2–9.
- Petsatodis G, Antonarakos P, Chalidis B, Papadopoulos P, Christoforidis J and Pournaras J: Surgically treated acetabular fractures via a single posterior approach with a follow-up of 2–10 years. *Injury* (2007) 38: 334–343.
- Li YL and Tang YY: Displaced acetabular fractures in the elderly: results after open reduction and internal fixation. *Injury* (2014) 45: 1908–1913.
- Verbeek DO, van der List JP, Villa JC, Wellman DS and Helfet DL: Postoperative CT is superior for acetabular fracture reduction assessment and reliably predicts hip survivorship. *J Bone Jt Surg Am* (2017) 99: 1745–1752.
- Daurka JS, Pastides PS, Lewis A, Rickman M and Bircher MD: Acetabular fractures in patients aged > 55 years: a systematic review of the literature. *Bone Joint J* (2014) 96-B: 157–163.