University of Szeged

Faculty of Medicine

Department of Oto-Rhino-Laryngology and Head-Neck Surgery

Long-term hearing preservation in cochlear implant patients

Balázs Dimák MSc.

Ph. D. thesis

Supervisors:

János András Jarabin M.D. Ph.D.

József Géza Kiss Ph.D. habil. C.Sc.

Szeged

2021

PUBLICATIONS RELATOED TO THE THESIS

I. **Dimak Balazs**; Nagy Roland; Perenyi Adam; Jarabin Janos Andras; Schulcz Rebeka; Csanady Miklos; Jori Jozsef; Rovo Laszlo; Kiss Jozsef Geza: Review of Electrode Placement with the Slim Modiolar Electrode: Identification and Management
IDEGGYOGYASZATI SZEMLE / CLINICAL NEUROSCIENCE 73 : 1-2 pp. 53-59., 7 p. (2020)
IF: 0.337

II. Perenyi Ádám; Toth Ferenc; **Dimak Balazs**; Nagy Roland; Schoerg P; Jori Jozsef.; Kiss Jozsef Geza; Sprinzl Georg; Csanady Miklos; Rovo Laszlo: Electrophysiological measurements with electrode types of different perimodiolar properties and the same cochlear implant electronics – a retrospective comparison study
JOURNAL OF OTOLARYNGOLOGY-HEAD & NECK SURGERY 48 : 1 Paper: 46 (2019)
IF: 2.310

III. Nagy Roland; Jarabin Janos Andras; Perenyi Adam; **Dimak Balazs**; Toth Ferenc; Jori Jozsef; Kiss Jozsef Geza, Rovo Laszlo: Long-term Hearing Preservation with Slim Perimodiolar CI532® Cochlear Implant Array
AMERICAN JOURNAL OF OTOLARYNGOLOGY 1 : 4 Paper: 1019 (2018)

IV. Nagy Roland; Jarabin Janos Andras; **Dimak Balazs**; Perenyi Adam; Toth Ferenc; Szuts Viktória; Jori Jozsef; Kiss Jozsef Geza, Rovo Laszlo: A maradványhallás megőrzésének lehetőségei cochlearis implantáció során Nucleus CI532 Slim Modiolar elektródasorral
ORVOSI HETILAP 159 : 41 pp. 1680-1688. , 9 p. (2018)
IF: 0.534

V. Perenyi Adam; Nagy Roland; **Dimak Balazs**; Csanady Miklós; Jori Jozsef; Kiss Jozsef Geza, Rovo Laszlo: Cochlearis implantátumok különböző, előre görbített elektródasorainak elhelyezkedése a cochlea tengelyéhez viszonyítva. Radiológiai vizsgálat a perimodiolaritás mértékének megállapítására
ORVOSI HETILAP 160 : 31 pp. 1216-1222. , 7 p. (2019)
IF: 0.417

CONTENTS

ABBREVIATIONS

AHL	asymmetric hearing loss
AOS	advanced off stylet
AP	anterior-posterior projection
ASSR	auditory steady state response
BERA	brainstem evoked response audiometry
CG	common ground
CI	cochlear implant
CT	computer tomography
cu	current unit
CS	cochleostomy
dB	decibel
dB(HL)	decibel hearing level
DPOAE	distortion product otoacoustic emission
EAS	electric-acoustic stimulation
E-BERA	electrically evoked brainstem responses
ECAP	electrically evoked compound action potentials
ERW	extended round window
ESRT	electrical stapedius reflex threshold
HA	hearing aid
HP	hearing preserved
MRI	magnetic resonance imaging
NRT	neural response telemetry
RW	round window
SIT	standard insertion technique
SNHL	sensorineural hearing loss
SP	sound processor
SPE	slim perimodiolar electrode
SSD	single side deafness
THL	total hearing loss
T-NRT	neural response telemetry threshold

INTRODUCTION

Hearing loss

Hearing loss affects about 1.33 billion people (Global Burden of Disease) with around 466 million people (World Health Organization) worldwide with disabling hearing loss, and 124 million of these have moderate to severe disability [1]. Hungarian Central Statistical Office results (2020) show that 71600 people in Hungary live with severe hearing loss, 2000 are under the age of 14. Hearing loss is assessed at different frequencies (from 0.5kHz to 4kHz) and decibels (dB(HL)) (Table 1) using pure tone audiometry.

Table 1. The scale of hearing loss severity

Degrees	Range [dB(HL)]
Total Hearing Loss (Deafness)	N/A
Profound Hearing Loss (Residual Hearing)	>90
Severe Hearing Loss	81-90
Moderately Severe Hearing Loss	61-80
Moderate Hearing Loss	41-60
Mild Hearing Loss	26-40
Minimal Hearing Loss	>25

Severe hearing loss before the age of 3 can delay or even inhibit speech development and language acquisition. This may also lead to issues in learning, have a severe effect on classroom learning and socialisation [2]. Meanwhile, in adults disabled hearing can also have an impact on employment, confidence and it can also be linked to an increased risk of dementia [3]. It is also a potential cause for cognitive impairment and decline in socially isolated elderly patients [4].

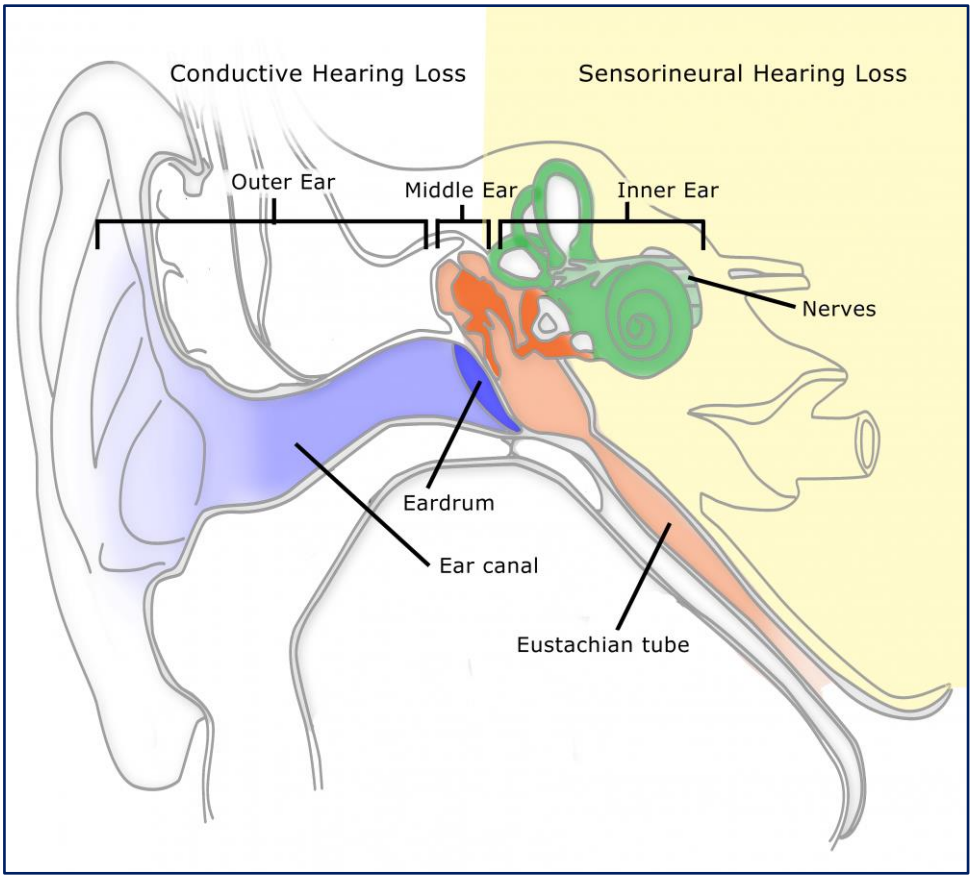

Figure 1. *The type of hearing loss a person has depends on where the problem is located within the auditory pathway. Hearing loss is classified as conductive if the problem is somewhere in the outer or middle ear pathway. If the problem is in the inner ear or affects the retrocochlear neuronal pathways, the hearing loss is classified as sensorineural. In some cases, problems may exist in both the outer/middle and inner ear pathways. This is called mixed hearing loss* [5].

There are three main causes of hearing loss: sensorineural, conductive and mixed (Figure 1.). Mixed hearing loss is the combination of sensorineural and conductive hearing loss where the bone conduction threshold is more than 20dB in hearing level and the air bone gap is >10dB. Conductive hearing loss is usually associated with issues in areas of sound conduction such as: the external auditory canal, the ear drum or the ossicles. This will lead to a decrease in the conduction of sound via air conduction, but bone conduction remains normal. This can be due to a hereditary or acquired occlusion of the external auditory canal (e.g. atresia, tumour), trauma, various types of middle ear infections or ossification of middle ear bones. Sensorineural hearing loss appears when the cochlear or retrocochlear neuronal structures have deteriorated. In sensorineural hearing loss the processing of the cochlear signal is impaired due to the reduction in cochlear receptor cells. This can be due to inner hair cell, outer hair cells or neural damage of the cochlear nerve. Consequently, the frequency processing capacity and auditory

mechanism are lessened. Sensorineural hearing loss can be due to aging, ototoxic medication, trauma, loud noise exposure, genetic diseases and cochlear malformations. In all three types of hearing loss the ear loses its normal sound sensing ability and can only detect sounds at a higher intensity level. Abnormalities which mainly affect the outer and middle ear; can be rehabilitated effectively with the use of hearing aids. For typical audiograms see Figure 2.

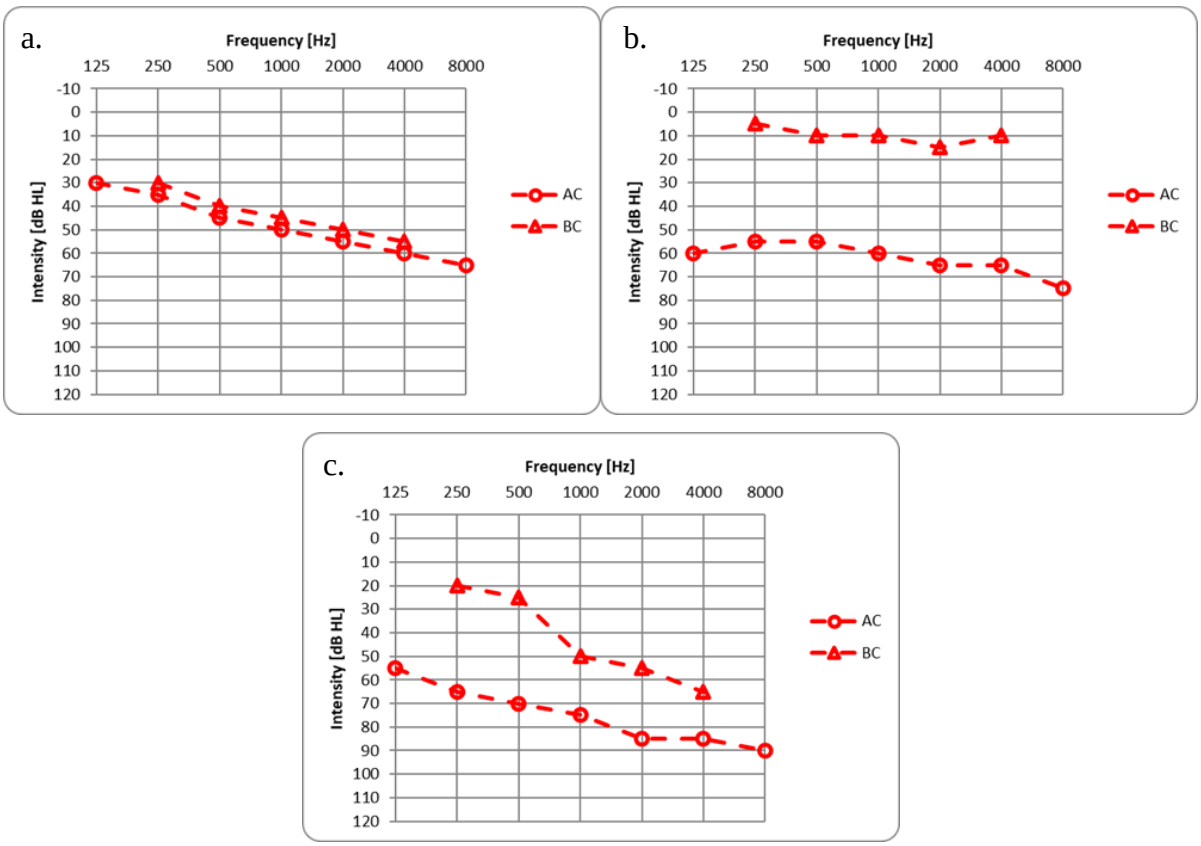

Figure 2. *Pure tone audiometry of the different types of hearing loss.* ***a.*** *A SNHL is present if there is less than a 15 dB(HL) difference between the air and bone conduction thresholds of a given ear, and the air and bone conduction thresholds are worse than 15 dB(HL).* ***b.*** *A conductive hearing loss is defined by bone conduction thresholds being 15 dB(HL) or better than the air conduction thresholds, and the bone conduction thresholds are 15 dB(HL) or less.* ***c.*** *Mixed loss will have both conductive and sensorineural components in the loss.*

Hearing loss rehabilitation using implantable hearing devices

The most common form of treatment for hearing loss is to provide the ear with a hearing aid. Hearing aids can be used in cases from minor hearing loss to the utilization of hearing loss. A special variant of hearing aids is the group of implantable hearing aids, in which the functional unit is implanted by a surgical procedure. The three groups of these implantable hearing aids

are middle ear implants (for moderate SNHL), bone conduction implants (for conductive hearing loss), and cochlear implants (CI) (for severe SNHL).

The first cochlear implant system was the House single-channel 3M device (USA) [6], to which the first speech processor appeared in 1972. From 1972 to the mid-80s, more than 1000 people with deaf and severe hearing loss (including hundreds of children) were implanted with this device. In many cases, it significantly improved lip-reading, and there were people who also understood words and sentences with the help of it.

Graeme Clark et al. created the first multi-channel implant (Nucleus Multi-Channel Cochlear Implant) in Australia, which became widely used clinically in 1984 [7]. These results were better and more encouraging than ever before. The first child was implanted with the device in 1989.

In the 1980s, the preconditions for cochlear implantation were also established at the Department of Oto-Rhino- Laryngology in Szeged. The first operation in Hungary was performed by Professor Ottó Ribári in 1985 in Budapest. In our clinic, the first cochlear implantation took place on September 29, 1995 [8].

A cochlear implant is an electronic medical device that replaces the function of the damaged inner ear [9].

Unlike hearing aids, which make sounds louder, cochlear implants replace the function of damaged parts in the inner ear (cochlea) to provide sound signals to the brain. The cochlea is the part of the inner ear that converts sound waves into nerve signals, which the brain processes as hearing. The apical region of the cochlea is responsible for detecting low-pitched sounds, while the basal region is responsible for detecting high-pithed sounds. The cochlea is lined with thousands of sensory cells, known as hair cells, which detect sound waves and send sound information as nerve signals through the auditory nerve to the brain. CI provides rehabilitation for individuals with severe to profound hearing loss in a uni, – or bilateral way. For people with this level of disability, most of their hair cells do not function normally and are not able to send the nerve signals properly. The CI (Figure 3.) system bypasses these non-functioning hair cells by using electrical pulses to send sound signals directly to the auditory nerve.

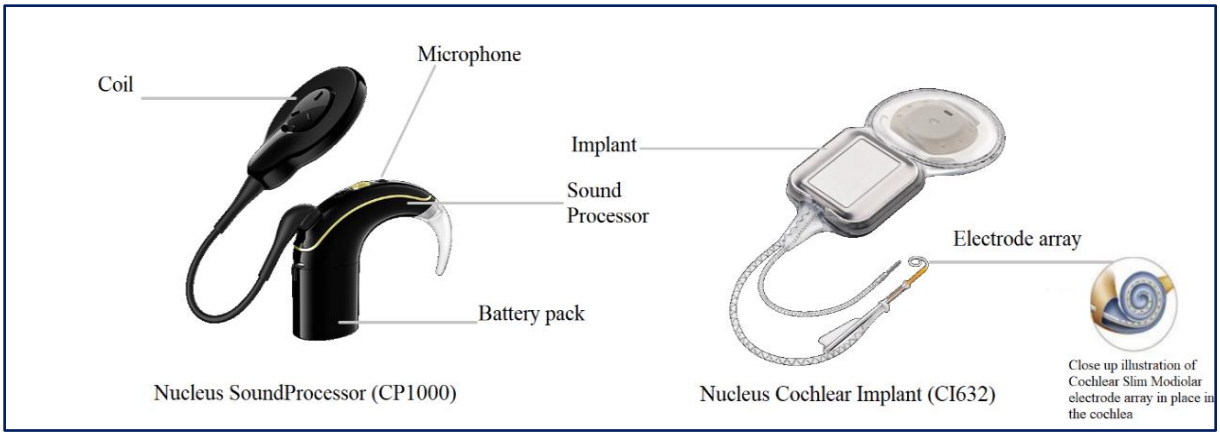

Figure 3. *Structure of a cochlear implant (Source: Cochlear database)*

A CI implant system has two parts: the sound processor and an implanted part. The external sound processor (SP) is worn behind the ear, the implant is surgically placed under the skin and attached to a flexible electrode array that is inserted into the cochlea. The sound processor detects environmental sounds and digitally converts them into coded electrical signals. A transmitter coil transfers these signals through the skin to the implant. The implant translates these coded signals into electrical pulses, which are transmitted along the electrode array to stimulate specific locations of the cochlea responsible for specific pitches. This targeted stimulation across the whole cochlea provides a more accurate pitch perception for better sound quality. By mimicking the natural function of hair cells, these pulses can deliver sound signals directly to the auditory nerve. Then these signals are transmitted by the auditory nerve to the brain, where they are interpreted as sound.

Every CI hardware and software components are subjects of continuous development over time to provide good speech perception. On the other hand, the applied surgical approach and technique may also substantially interfere with the functional outcome.

Different companies (Advanced Bionics, Cochlear, Med-El and Oticon, etc.) provide different types of receiver-stimulators, implant electrodes and speech processors. Multiple factors influence the postoperative outcome of the CI [10–13]. The various physical/technical parameters, surgical approaches and recipient-dependent factors may simultaneously affect the patients' quality of life [6]. There are several pros and cons when opting for an electrode profile (straight or perimodiolar), cochlear coverage (total or partial), receiver-stimulator (physical attributes) and speech processor (electric or electroacoustic stimulation), that meet the individual needs. There are other important factors of implant design such as: proximity to the

modiolus [14, 15], electrical current requirements [16], energy consumption, trauma to the cochlea [17] and combined electro-acoustic stimulation [18, 19]). One of the primary aims of cochlear implant system engineering is to promote atraumatic electrode insertion to maintain optimal postoperative hearing sensitivity by protecting and preserving the delicate inner ear structures.

Type of electrodes

CI512 (CA)

Although the height of the lateral aspect of scala tympani reduces significantly beyond 360° to 450°, the height of the medial aspect of scala tympani remains relatively consistent and up to twice the height of the lateral aspect [20, 21]. The insertion depth and diameter of the tip of perimodiolar electrodes are therefore not constrained as much by the reducing height of scala tympani, as is the case with lateral wall electrodes.

The difference in heights of the medial and lateral aspects of the scala tympani and the effect of the slope of the lateral wall on the rising force with the resulting proximity of a lateral wall electrode to the basilar membrane. In contrast, the perimodiolar electrode has much greater clearance in terms of the medial scala tympani height and much greater proximity to the spiral ganglion, as well as being much further from the functional structures of the basilar membrane and the organ of Corti.

The apical electrode diameter of current stylet-based perimodiolar electrodes is 0.5 mm (Contour Advance from Cochlear Ltd), which is a technical constraint created by the requirement of an internal stylet (Figure 4). Although a 0.5 mm apical electrode dimension is not dissimilar to the dimensions of contemporary lateral wall electrodes, space within the narrowing scala tympani is not the concern, but rather the ability to insert via round window. So, a separate cochleostomy has typically been required, which then exposes the risk of incorrect cochleostomy placement [22] and in many cases an anterior cochleostomy directly into scala vestibule or contributing to early translocation from scala tympani to scala vestibule [23].

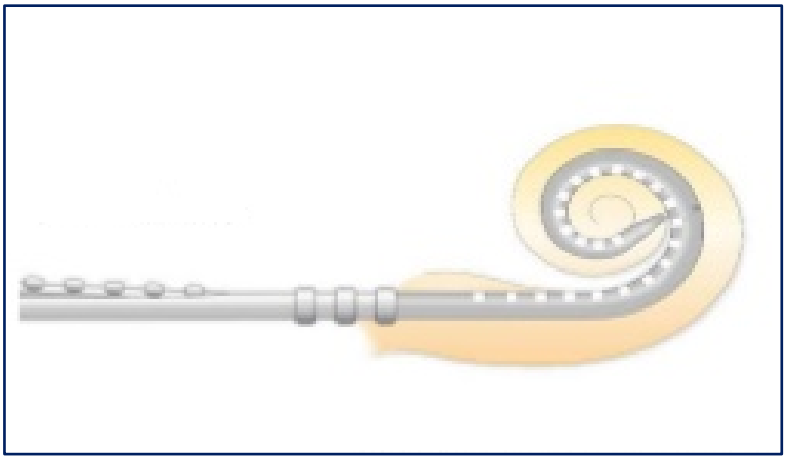

Figure 4. *Contour Advance electrode array Nucleus Contour technology provides extensive evidence of the efficacy and reliability of these electrodes which aim to bring the electrode contacts closer to the neural elements of the cochlea (Source: Cochlear database).*

CI532

The Slim Modiolar Electrode (CI532 implant) from Cochlear Ltd. introduced a new concept of a "sheath-based" perimodiolar electrode, as opposed to "stylet-based". This difference in approach to straighten and insert a pre-curved electrode is a significant advancement that addresses the two main challenges identified as contributing to the higher rates of trauma with stylet-based perimodiolar electrodes, being 1) variability or compliance with the AOS insertion technique, and 2) the ability to insert via the round window. The sheath-based design also allows for ease of reloading the electrode if required.

The sheath design ensures that the insertion technique results in the electrode being inserted only 5.5 mm into the basal turn initially, with no possibility of inserting further as with the standard insertion technique. This ensures that when the pre-curved electrode is advanced through the sheath, it avoids contact and trauma to lateral wall structures. When the sheath is removed, the electrode contacts remain in close proximity to the modiolus.

Hearing preservation following CI

Hearing preservation following CI particularly at the low frequencies can significantly improve hearing, speech reception, speech comprehension, accuracy in melody recognition, frequency discrimination and the localization of tone in patients in particularly challenging environments (e.g. prominent background noise) [24–27]. Therefore, preservation of endocochlear

microstructure during CI is one of the most significant goals for both the low-frequency hearing preservation and optimized electrical stimulation.

The physical parameters (curved vs. straight; short vs. long; with rounded vs. smoothened tip; with or without stylet, etc.), and the intrascalar position of the electrode configuration (perimodiolar, mid-scala, lateral wall) are well-known to have an impact on post-implant performance [14]. For example, imaging techniques (CT, X-ray) demonstrate an increased susceptibility of suboptimal intracochlear CI electrode array placement (i.e. the dislocations from scala tympani to the scala vestibuli) with the Contour than with the Contour Advance array (Figure 3.). The dislocation was significantly associated with lower speech recognition score for those individuals with the Contour array [15]. The applied surgical approach (Round Window (RW), Extended Round Window (ERW), Cochleostomy (CS)) and the implanted electrode profile mainly lead to immediate or short-term damage, while delayed alteration in cochlear function usually derives from the fibrous or bony remodelling of the endocochlear compartments. Iatrogenic intracochlear trauma during CI surgery is highly dependent on the type of fenestration (RW, ERW, CS) and the method of electrode insertion (standard vs. “soft”) [28, 29]. Further support could be provided through the administration of lubricants or drugs (e.g. intravenous or intrascalar corticosteroids) [30, 31]. The beneficial effects of glucocorticoids are thought to be mediated through several different pathways: the anti-inflammatory effects; the down-regulation of production of inducible nitric-oxide synthase; and direct inhibition of the MAP/JNK cell death signal cascade [32–35].

Furthermore, the possible disproportion between the physical dimensions of the electrode profile and the endocochlear compartments (diameter, shape, length of scala tympani) play a significant role in preserving inner ear structures and functions.

Bimodal, electric-acoustic stimulation (EAS) was one of the first concepts, where hearing preservation was crucial [18]. Multicentre clinical trials have proved EAS to be a safe and effective treatment option for adults with normal hearing to moderate SNHL. Additionally, EAS is also useful for patients who have severe-to-profound SNHL in the high frequencies, who otherwise do not benefit from conventional amplification [36–38].

As a consequence of EAS system’s implantation, the most prevalent adverse events are profound to total loss of residual hearing. Rates vary from 8/78 (11.0%) to 17/50 (34.0%) in different study populations with implanted EAS systems from two leading manufacturers

(MED-EL GmbH, Innsbruck, Austria and Cochlear Ltd., Sydney, Australia). Based on these multicentre studies [36, 37], those who did not have functional post-implant acoustic hearing a very small number of patients (0-5 subjects) chose to have revision surgery and re-implantation with full-length electrode array.

There are two typical electrode positions – Figure 5. – within the scala tympani: (1) perimodiolar, and (2) lateral wall, defined as the relative distance from the modiolus increases respectively.

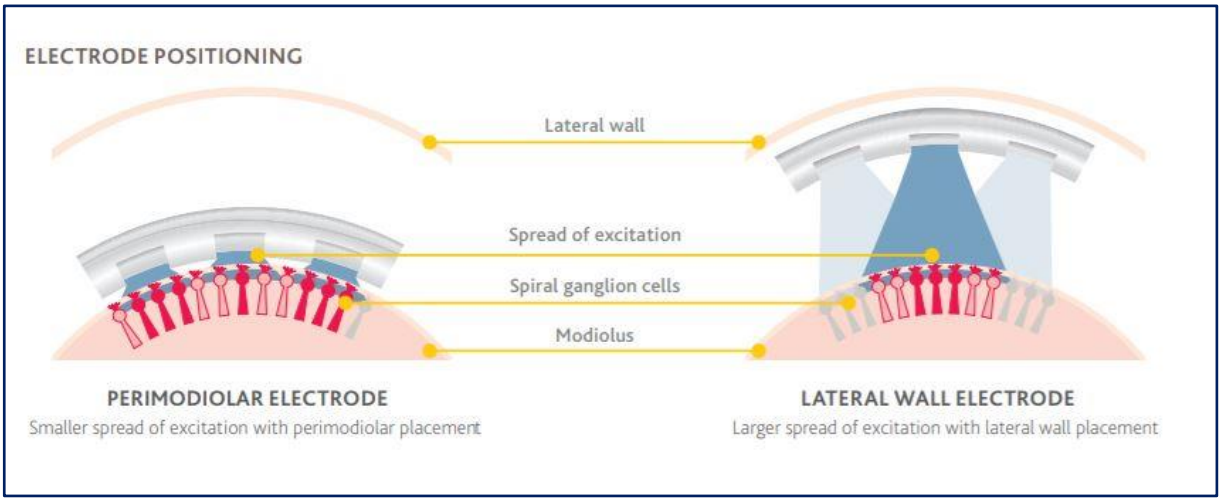

Figure 5. *Lateral wall straight vs perimodiolar electrode positioning. Perimodiolar placement of the electrode means better stimulation – closer to the spiral ganglion cells. (Source: Cochlear database)*

The effect of electrode design on hearing preservation still may appear puzzled. In a study by Mandy *et al*, the lateral wall electrode design was associated with short-term hearing preservation, while other factors, including age, were relevant for maintaining residual hearing in the long term [39]. On the other hand, our first results with the full-length Nucleus CI532 (Slim Modiolar®) electrode array were promising in terms of residual hearing preservation over a 1-year long follow-up period [33, 40].

Recent evidence suggests that speech discrimination is not improved by deep insertion, but it is significantly improved by perimodiolar position of the electrode [24]. With the perimodiolar electrode position, plenty of advantages are realized. As the distance from the modiolus is minimized and consistent modiolar proximity is maintained, limited adjacent current spread could be achieved with narrower stimulation width and reduced current demand,

that finally could relate to improved speech recognition. Applying this electrode profile residual hearing could be preserved on the long run [40] when it is inserted via ‘soft surgery’ [41] including ERW approach [42–44]. To incorporate the virtue of perimodiolar stimulation with reduced insertion trauma, a slim, pre-curved electrode profile (CI532) was recently released by Cochlear Ltd. (Sydney, Australia). This electrode array is held straight prior to insertion by an external polymer reloadable sheath that is removed after full electrode insertion [45].

However, by the broader application of perimodiolar electrodes various challenges have been brought to light [46]. One infrequent issue is that these thin and flexible electrode arrays are potentially more susceptible to tip fold-over, where the tip of the electrode is folding on itself as a ‘hairpin curve’ [47]. Various surgical complications (gusher, oozing, etc.), or anamnesis of previous diseases (meningitis, sclerosis of the cochlea) increase the risk of tip fold-over. We have detected three tip fold-over phenomena of the 143 cases (approx. 2%). This incidence corresponds to the published international data [48–51].

AIMS OF STUDY

Studies in implanted recipient groups using multiple implant types make it difficult to compare the influence of the implant electrode characteristics on outcomes in the presence of additional variables such as implant electronics, sound processors and speech coding paradigms. Hence, to reduce the number of variables, comparison of the influence of electrode designs on outcomes could be interpreted more effectively if a consistent receiver-stimulator design and a common sound processor are used. Recent publications [45, 47, 48, 51, 52] represent imaging and electrophysiological results with CI532.

Our centre's postoperative radiological comparative study demonstrated that the Slim Modiolar electrode array took a closer position to the modiolus than the Contour Advance electrode array [53].

We aimed to study long-term hearing preservation in a non-randomized, prospective clinical cohort with cochlear implant systems, limited to ones produced by Australian and Austrian leader companies, provided and fully financed by the Hungarian National Health Insurance.

Thus, here we report our subsequent results with a 3-year-long follow-up to investigate possible changes in residual hearing over time with Slim Modiolar electrode profile.

SUBJECTS AND METHODS

Study cohort

Out of the total number of cochlear implantees with slim perimodiolar implant system (n=143) – at the University of Szeged – our study population was recruited on the basis of the following criteria: (1) patient with good compliance; (2) measureable preoperative hearing threshold; (3) slim perimodiolar electrode array implant system; (4) minimum one-year follow-up period. Thirty consecutive subjects were enrolled into this prospective, non-randomized clinical study. Twenty females and ten males with mean age at implantation of 43.32 years, ranged between 10 years to 77 years. All subjects were implanted at the University of Szeged from 2015 until 2020. The postoperative follow-up duration lasted 1.72 years at average (ranged between 1.1 and 2.55 years). All subjects met the official indication criteria of CI. Anatomical / structural malformation was not revealed by the preoperative radiological examinations. For detailed patient data you can see Table 2.

Table 2. Population of patients with 1-year-follow up time.

No.	Gender	Age (year)	Implanted ear	Total Hearing Loss (THL) after implantation
1	Male	55	Left	No
2	Male	59	Left	Yes
3	Male	16	Right	No
4	Male	24	Right	No
5	Male	15	Left	Yes
6	Male	72	Right	No
7	Female	70	Right	No
8	Female	71	Left	No
9	Female	10	Right	Yes
10	Male	11	Right	No
11	Female	43	Left	Yes
12	Female	28	Right	No
13	Female	28	Left	No
14	Female	11	Right	No
15	Female	70	Right	No
16	Female	24	Right	No
17	Male	62	Right	No
18	Female	77	Right	No
19	Female	42	Right	No
20	Female	48	Right	Yes
21	Female	71	Left	No

22	Female	53	Right	Yes
23	Female	59	Right	No
24	Male	13	Right	No
25	Female	27	Right	No
26	Female	35	Left	Yes
27	Female	59	Left	No
28	Female	30	Right	No
29	Male	53	Right	No
30	Male	69	Right	Yes
Average	Male=10 Female=20	43.32 ± 24	Right=21 Left=9	THL=7

Firstly 30 consecutive subjects were enrolled into a prospective, non-randomized clinical study, based on similar inclusion criteria detailed below [33]. From that results cohort 9 patients (9/30=30%) showed up with total loss of residual hearing at every measured frequency following surgery. From patients who had preserved hearing (21/30=70%) we recruited those ones with 3-years long follow-up period into this present study. Finally, 11 patients with 13 implanted ears were subjects to this analysis (Table 3).

Table 3. Demographics of patients in the study.

No.	Gender	Etiology	Age (year)	Side	Approach	Contralateral hearing
1	Male	SNHL	55	left	RW	none
2	Female	SNHL	5	left	RW	CI
3	Male	SNHL	16	right	RW	HA
4	Male	SNHL	23	right	RW	HA
5	Male	SSD	72	right	RW	natural
6	Female	SNHL	70	left	RW	none
7	Female	SNHL	10	right	RW	HA
8	Male	SNHL	11	right	RW	HA
9	Female	SNHL	28	right	RW	CI
10	Female	SNHL	28	left	RW	CI
11	Female	SNHL	43	left	RW	none
12	Female	AHL	69	right	RW	none
13	Female	SNHL	70	left	RW	CI
Mean	Male=10 Female=20	SNHL=11 SSD = 1 AHL= 1	38,46 ± 24	Right=21 Left=9	RW=13	
SNHL: progressive sensorineural hearing loss of unknown origin; *AHL*: asymmetric hearing loss; *SSD*: single side deafness; *CI*: cochlear implant; *HA*: hearing aid; *RW*: round window approach. No. 9&10: simultaneous bilateral CI. No. 2&13: sequential bilateral CI.						

Inclusion criteria were as follows: (1) Nucleus CI 532 (Slim Perimodiolar®); (2) postlingual uni-, or bilateral SNHL; (3) normal middle ear function; (4) normal anatomy of the inner ear; (5) full-length electrode insertion.

All implantations were performed by two skilled surgeons (Professor Laszlo Rovo and Jozsef Jori). The approach of "soft surgery" was applied. Round window insertions were performed in all cases.

Implant configuration

The studied cochlear implant system provides full-length cochlear coverage with slim, perimodiolarly positioned electrode array (Figure 6. - Nucleus CI532 Slim Modiolar electrode (Cochlear Ltd., Sydney, Australia)). The thin implant body has no pedestal and it is designed to minimize bone excavation and skin protrusion. The side-by-side symmetrical shape makes the implantation easier for the surgeon. The titanium casing has been used for high impact resistance, and the smooth external geometry to minimize biofilm formation, that reduces the risk of infection. The total length of the electrode array is 98 mm, while the diameter is 0.35 × 0.4 mm at the tip and 0.45 × 0.5 mm at the base. At the last edge of the electrode array there are three white marker rings for controlling the insertion depth that are followed by 22 half-banded platinum electrode contacts. The insertion assistant reloadable sheath platform [54] and the physical attributes of the electrode array facilitate to proximate the modiolus and thus prevent the electrode from dislocation into the scalae media or vestibuli. These properties make this implant configuration easier to use with short incision and surgery time. [45, 51, 55]

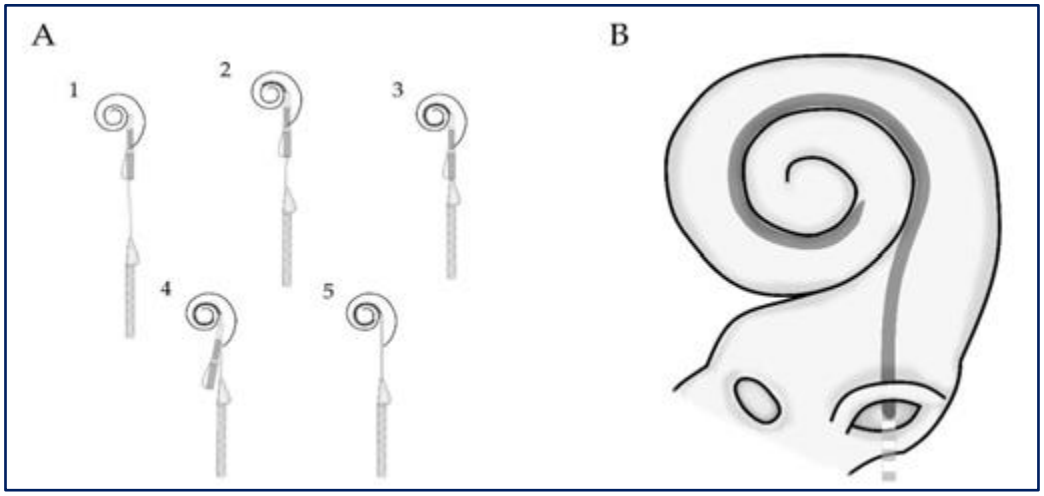

Figure 6. **a.** *Atraumatic electrode insertion in optimal position with the reloadable sheath.* ***b.*** *Slim, perimodiolar electrode configuration with total cochlear coverage.*

Soft surgery

The term soft surgery was introduced by Lehnhardt in 1993 and it provided basis for numerous publications [56, 57].

Preserving the residual hearing requires minimally invasive techniques of (1) cochlear fenestration, (2) management of endocochlear fluid compartments and (3) atraumatic electrode insertion, known as soft surgery. Thinner and atraumatic electrode arrays are also designed to accomplish these aims, as postoperative hearing performance can be maximized by minimizing the insertion trauma [33, 55, 56, 58, 59].

Several important factors contribute to intracochlear damage during implantation: (1) direct physical trauma, (2) pressure wave propagation in the perilymphatic fluid, (3) vibration and/ or heat trauma from drilling, (4) loss of perilymph, (5) changes in homeostasis/hydrodynamics of the endocochlear fluid compartments, (6) delayed fibrotic alteration and new bone formation within the cochlear lumen [28, 29, 33, 60–62].

The physical attributes (length and diameter) of the electrode array may each limit the postoperatively achieved residual hearing [63].

Comprehensive analysis of imaging diagnostics of the middle and inner ear provide indispensable information for planning the proper surgical access route and electrode [63, 64].

Our routinely applied minimally invasive surgical technique involved electrode insertion *via* the Round Window (RW). In order to reduce bleeding and to prevent blood from accessing the cochlea, we filled the tympanic cavity with adrenaline solution after having the posterior tympanotomy been completed. To prevent bone fragments entering the cochlea, the tympanic and mastoid cavity were flushed with abundant amount of saline. To remove the bony overhang of the round window, we used a 1 mm diamond burr at low speed (max. 350 rpm) in order to avoid noise and heat injury. We opened the RW membrane with a microscopic needle or hook. After opening the inner ear, suction was applied with care in order to avoid reducing the amount of perilymph. Furthermore, the scala tympani was left open for the shortest possible period, to prevent bone fragments, blood or other substances entering the inner ear, which might have been sources of primary and/or secondary injuries that finally would lead to loss of residual hearing. As a sort of prevention, after having opened the RW, we placed a piece of gel-foam soaked in corticosteroid solution into the RW niche.

The slim modiolar electrode of the CI532 implant was soaked into methylprednisolone solution (40 mg powder dissolved in 10 ml saline) and it was retracted into the insertion sheath. The

insertion sheath together with the electrode array was inserted into the scala tympani with the lowest possible force. Any minute resistance felt by the surgeon would have indicated physical contact of the electrode array to the basilar membrane or the lateral wall of the scala tympani or stria vascularis and possible injury of these structures. After the electrode had been inserted in full length, indicated by the 1st marker ring, the RW was immediately sealed with an autologous tissue (e.g. fascia or muscle) in order to prevent loss of perilymph [56].

Radiological validation

Radiography (skull AP and Stenver's view) was performed on the first postoperative day to confirm successful insertion of the active electrode into the cochlea (Figure 7.) and to rule out possible misplacement and tip fold-over [54].

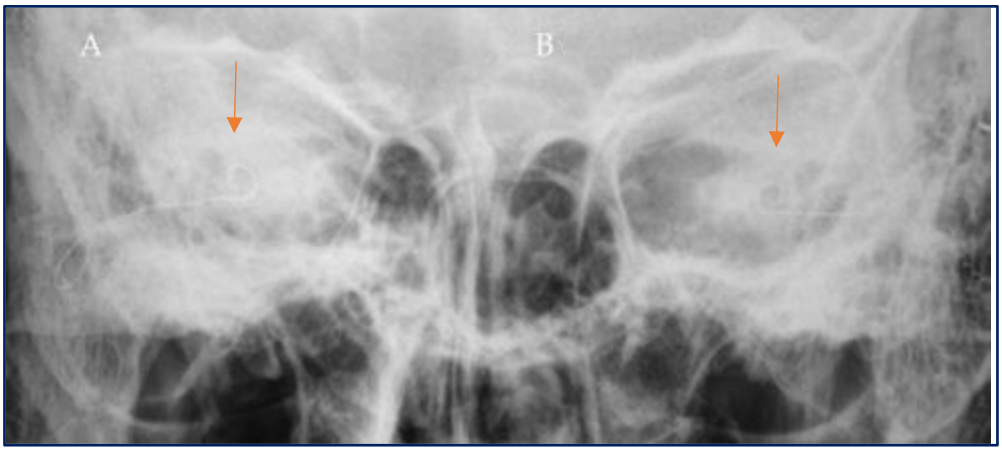

Figure 7. *Skull AP on the first postoperative day that confirms the proper in situ electrode position. The depicted subject (not included into the present study due to completely missing preoperative hearing) was chosen to interpret the differences between sequentially implanted systems (**a.** right ear: CI512 Contour Advanced; **b.** left ear: CI532 Slim Perimodiolar). A decreased electrode array curvature is seen with the slim perimodiolar system.*

Audiometric testing

Unaided pure-tone air-conduction thresholds were evaluated at frequencies ranging from 125 to 8000Hz preoperatively and at 1-year, 2-years and 3-years follow-up visits, by skilled audiologists using the Hughson-Westlake method. The audiometer (GSI 61 Clinical Audiometer; GrasonStadler, MN USA) was calibrated according to the standards of the International Organization for Standardization (ISO 389-1:2017). THD-50P (Telephonics

Corporation/Griffon Company, NY USA) headphone was used for air conduction hearing measurements.

Electrophysiological testing

Impedance

The evaluation of CI functioning is facilitated by various analysis tools, one of the most important is the electric impedance measurement. While it is impossible to directly assess impedance, its values can be obtained by measuring voltage, as provided by Ohm's law. In CIs, this measurement is performed by using a protocol known as "voltage telemetry" [65, 66].

Electrical stapedius reflex threshold (ESRT)

ESRTs are measured using the pod and Nucleus Custom Sound programming software. Stapedius muscle contractions are observed through the operating microscope after an adequate exposure has been achieved. The ESRT measurements are performed using the 22th, 18th, 14th, 12th, 8th and 4th electrodes of the Cochlear device. The charges on these electrodes are increased in 15% increments until a reflex is elicited. Thresholds are established by decreasing and increasing the charge levels in 3% increments around this level. The burst duration of the stimulus is set at 300 ms, with 1000-ms gaps between bursts [67].

Neural response telemetry (NRT)

The threshold levels in cochlear implant patients are well correlated to electrically evoked brainstem responses (E-BERA). The electrically evoked compound action potentials (ECAP) which are closely related to the E-BERA, would also show a similar correlation with behavioural threshold. In the modern cochlear implant systems bidirectional information flow is available. This creates the right conditions for not only stimulating in the cochlea but detecting different signals there. Using this telemetry system, we can perform impedance telemetry, compliance telemetry and neural response telemetry (NRT). The NRT system makes the measurement of compound action potential possible inside of the cochlea [68]. The ECAP from the auditory nerve is characterised by a large negative peak (N1) with a very short latency (within a fraction of a millisecond), followed by a positive peak (P1) as described by Killian et al. 1994 [69]. The peak-to-peak amplitude value (P1-N1) is usually measured.

The SP sets the appropriate electrode pair into action and stimulates the close spiral ganglion cells and generates action potentials in them. Then the summation action potential can be measured with another electrode pair. The signal returns to the SP and it can be averaged and analysed. With the adequate selection of electrodes the condition of neurons nearby each electrode can be mapped. The parameters of registered potentials can help in specifying the right programming modes in device fitting.

Impedance was measured for each electrode, the ESRT with 25 μs pulse width for every second electrode contact (No. 2, 4, 6 etc.) and neural response telemetry threshold (T-NRT) for 6 (No. 2, 6, 10, 14, 18 and 22) electrode contacts. A common sound processor (Nucleus CP910) was used.

The first fitting was performed 4 weeks after surgery in each case. In order to determine the electric threshold (T-levels), and comfort threshold (C-levels), the subjective fitting method was used in adults and the semi-objective NRT based fitting (based on the intraoperative T-NRT results) was applied in children [70, 71]. Default MAP parameters (25 μs pulse width, 900 Hz stimulation rate and 8 maxima) were used.

Statistical analysis

Statistical analysis with the Student's t-test ($P < 0.05$) and one-way repeated measures ANOVA test were performed with 95% confidence interval ($p < 0.05$). Before the calculation, tests for normality of data distribution were performed. Bonferroni correction was used as needed to consider multiple variables (e.g. comparison of all three implant groups). The comparison was made on each electrode and all of the electrodes (Grand average). The tests were performed with Microsoft Excel 2016 and SPSS for Windows.

RESULTS

Hearing preservation

Pre- and postoperative pure tone hearing threshold measurements were completed for all the 30 recruited subjects. Figure 8 frequency-dependently illustrates the number of patients pre- and postoperatively, where hearing sensitivity was measurable. It is well demonstrated that hearing is the most stable within the 250 to 1000 Hz range, and the least is beyond 4 kHz. This statement is true either pre-, or postoperatively.

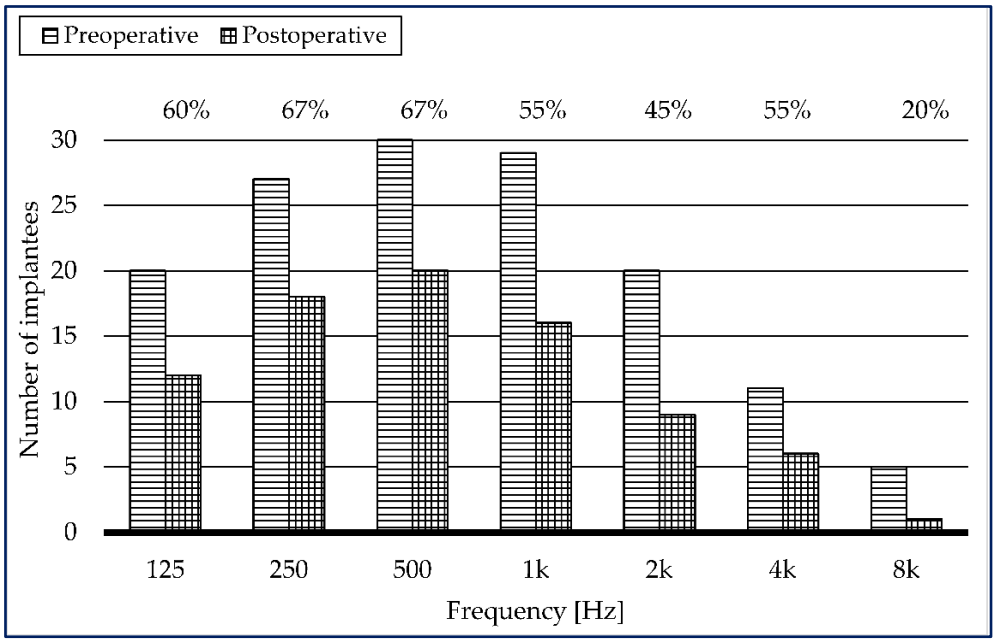

Figure 8. *Number of implantees with measurable hearing threshold at different frequencies. Preoperative (striped pattern columns); postoperative (checked pattern columns). On the top horizontal axis, the frequency-specific success rate of hearing preservation is showed in percentages.*

The average preoperative thresholds of the hearing within the lower frequency range were 61.75 dB(HL) at 125 Hz (no response from 10 patients); 78.52 dB(HL) at 250 Hz (no response from 3 patients). At the middle frequency range, mean values were 88.67 dB(HL) at 500 Hz (response from all patients); 97.07 dB(HL) at 1 kHz (no response from 1 patient) and 100.50 dB(HL) at 2 kHz (no response from 10 patients). At the higher frequencies, the average values were 91.36 dB(HL) at 4 kHz (no response from 19 patients) and 84.00 dB(HL) at 8 kHz (no response from 25 patients).

The difference in height between the striped and checked pattern columns represents the percentage of successful hearing preservation at specific frequencies.

One year postoperatively the average values of the hearing thresholds at the lower frequency range were: 93.89 dB(HL) at 125 Hz (no response from 17 patients); 87.86 dB(HL) at 250 Hz (no response from 10 patients). At the middle frequencies mean values were 102.86 dB(HL) at 500 Hz (no response from 10 patients); 111.61 dB(HL) at 1 kHz (no response from 14 patients) and 113.75 dB(HL) at 2 kHz (no response from 21 patients). At the higher frequencies, average values were 115.18 dB(HL) at 4 kHz (no response from 24 patients) and 99.29 dB(HL) at 8 kHz (no response from 29 patients).

Figure 9 illustrates the preoperative (striped pattern columns) and the postoperative (dotted pattern columns) hearing thresholds in dB(HL) at the measured frequencies. Decrease was detected at each examined frequency but the grade of it varied. The highest decrease was measured at 500 Hz with an average decrease of 14.19 dB(HL) and at 1000 Hz with an average decrease of 13.77 dB(HL). At the lower frequency range, hearing remained substantially stable. At 125 Hz only 3.06 dB(HL), while at 250 Hz only 7.19 dB(HL) loss was detected. At the high frequencies, from 2 to 8 kHz preoperative hearing sensitivity had been already proved to be rather poor, thus further loss had just little consequences.

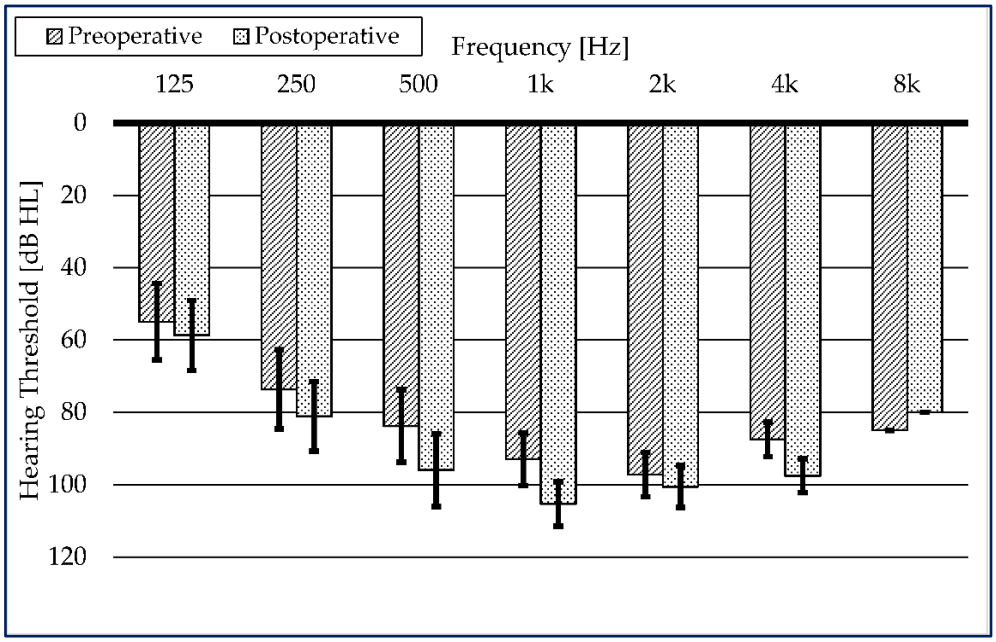

Figure 9. *Preoperative (striped pattern columns) and postoperative (dotted pattern columns) hearing thresholds in dB(HL) at the measured frequencies (*p<0.05).*

Figure 10 frequency-specifically demonstrates the degree of loss of acoustic sensitivity grouped into dB(HL) ranges, while exhibiting the number of implantees. It is clearly shown

that only minute threshold decay with less than 5 dB(HL) loss is the most frequently found one, while prominent postoperative loss of hearing appears less often.

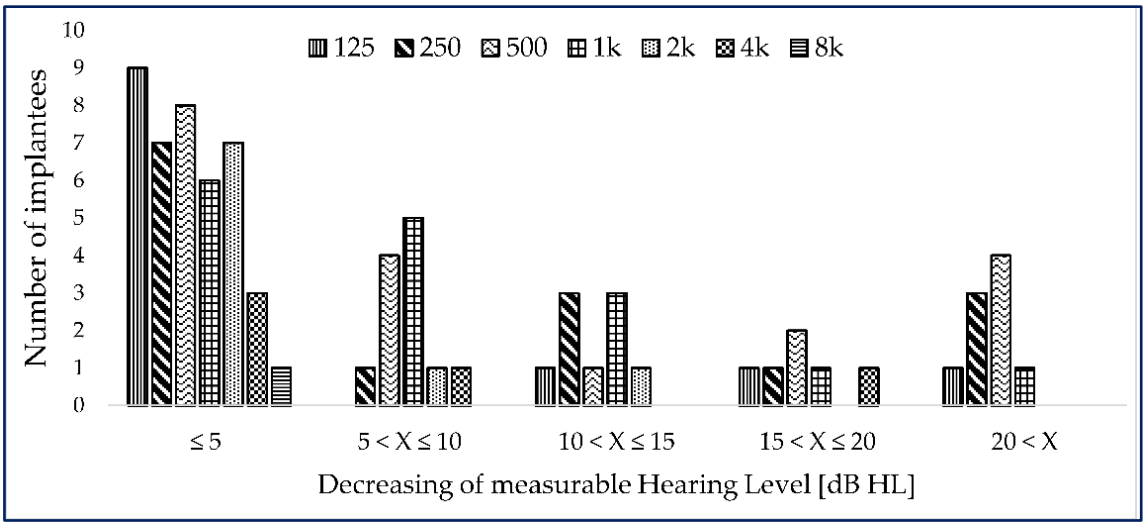

Figure 10. *Loss of acoustic sensitivity interpreted in dB(HL) ranges, while exhibiting the number of implantees frequency-specifically (with different patterns of columns).*

Nine implantees (9/30=30%) showed up with total loss of residual hearing at every measured frequency following surgery. Their preoperative hearing sensitivity is presented in Figure 11**.** It is clearly seen that within this subgroup of this cohort the measured average hearing threshold have been already poorer prior to surgery compared to those with preserved hearing. Genetic screening of the 30 recruited subjects revealed mutations in three cases in the background of hearing loss. All of these subjects suffered complete hearing loss postoperatively (3/3=100%), that genetic alteration may serve as a predictor when opting for an electro-acoustic/hybrid device, should be taken into consideration when indicating these systems [72].

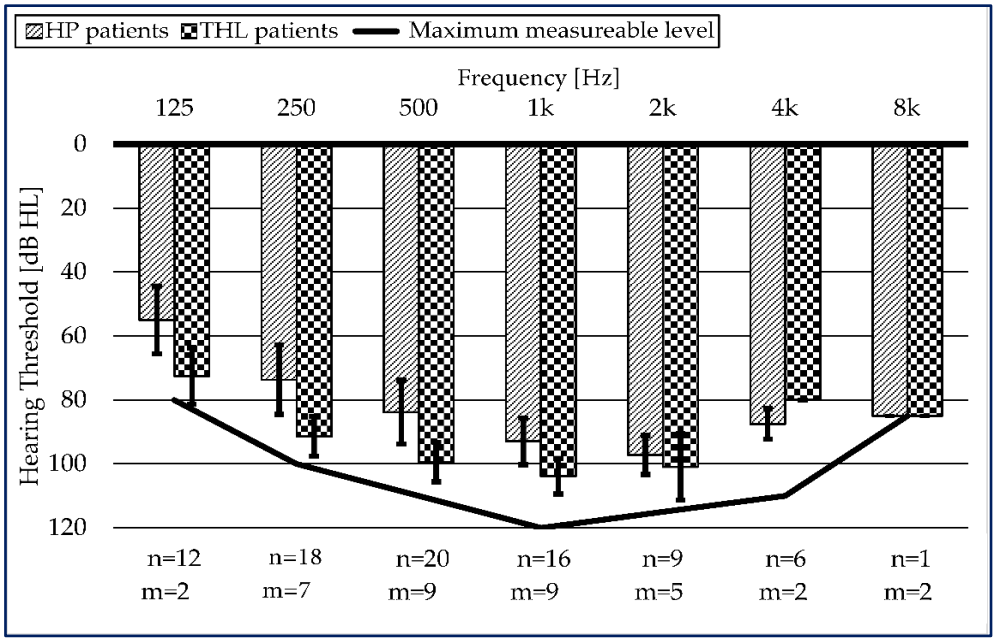

Figure 11. *Preoperative threshold of HP (striped pattern columns, n=number of patients) and THL (squared pattern columns, m=number of patients) patients (Continuous line measureable threshold level).*

Initial sound processor programming and activation was performed approximately one month after surgery.

The demographics of 11 patients with 13 implanted ears are summarised in Table 3 and show that the hearing loss is a result of: SNHL, single-sided deafness (SSD) or asymmetric hearing loss (AHL). The surgeries on all the 11 patients' 13 ears were performed using the principle of soft surgery applied to the RW method. All but one patient had damaged or no hearing on the contralateral ear.

Preoperative and 1-year, 2-year and 3-year post-operative pure tone hearing threshold measurements were completed for all patients (Figure 12 and 13).

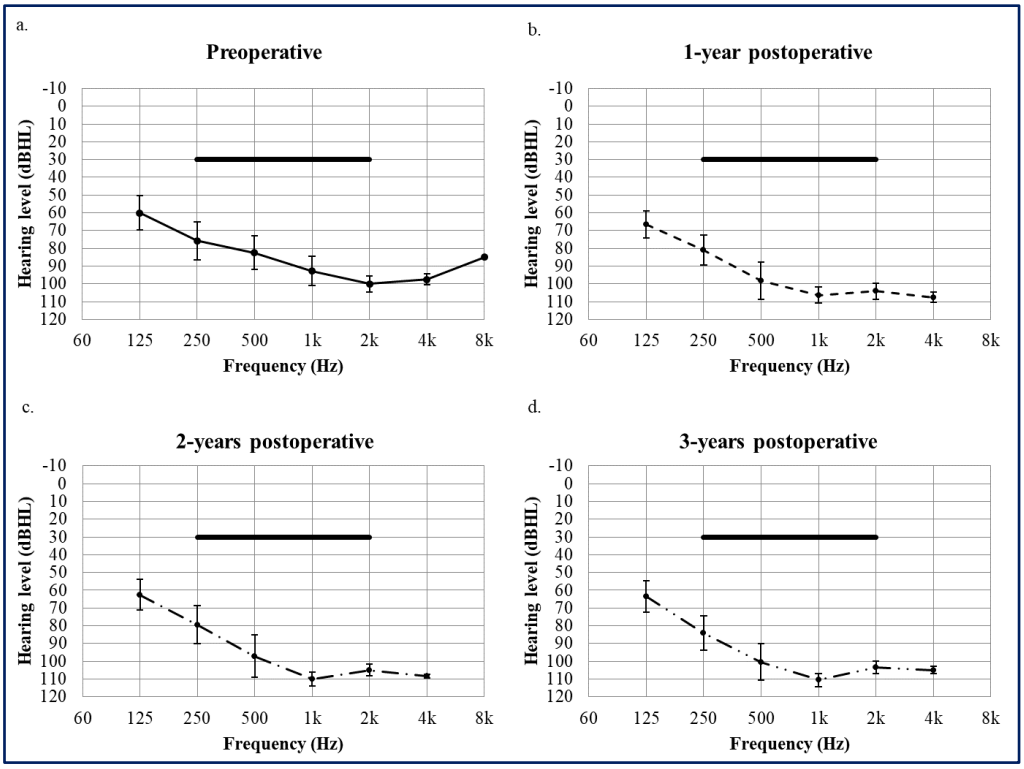

Figure 12. ***a.*** *Preoperative,* ***b.*** *1-year postoperative,* ***c.*** *2-year postoperative and* ***d.*** *3-year postoperative pure tone hearing thresholds in dB(HL) at the measured frequencies.*

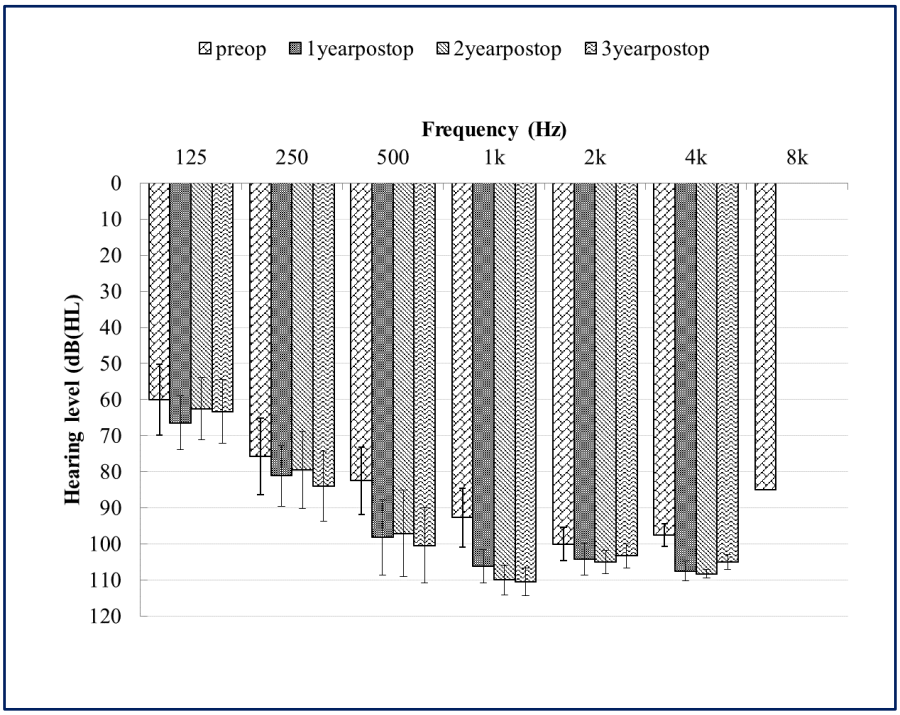

Figure 13. *Average hearing levels. Preoperative (brick pattern columns), 1-year postoperative (small dotted columns), 2-year postoperative (straight diagonal line columns) and 3-year postoperative (wavy line columns) hearing thresholds in dB(HL) at the measured frequencies.*

Average preoperative pure tone hearing thresholds for the 13 ears were 60–74.6–81.5–92.1–99.5–97.5–85.0 dB(HL) at the seven measured audiometric frequencies between 125 and 8000 Hz respectively.

The overall average change of 9.73 dB(HL) was recorded during pre and first year postoperative audiological examinations. The greatest change was observed in the mid frequency range with 16.64 dB(HL) at 500 Hz whilst 14.17 dB(HL) was recorded at 1 kHz. In the low (e.g. 125Hz – 250Hz) frequency range an average decrease of 6.5 dB(HL), while in the high (e.g. 2kHz – 4kHz) frequency range an average progression of 7.3 dB(HL) occurred. At the highest recorded frequency measured in this study (8 kHz) we only recorded in a single patient 85dB(HL) which was not observed at the measurement range in postoperative examinations. The second and third year postoperative data (9.5 and 10.2 dB(HL) respectively) showed were not statistically significant difference from the first year data.

The contralateral ears were fitted or either non-fitted (i.e. due to patient refusal) in a routine shown in Table 3.

Complications

Ninety-four (94) CI recipients with pre- and postoperative CT scans and detailed operative reports were available for review for the period from November 2015 to July 2018. Out of these 94 cases, the active electrode was inserted into the cochlea via the extended round window approach in 91 ears. Three electrodes were inserted via cochleostomy because the round window could not be identified. Fifty-seven percent of the cases – 54 out of 94 – were right-sided CI.

Tip fold-over was noted in three cases (3.19%) (Table 4) on radiography and will be discussed in more detail in the present study. Table 4 summarizes the demographic and clinical characteristics of these subjects.

Table 4. *Tip fold-over patients and electrode characteristics*

Patient #	Age	Sex	Side of CI	Approach	Company	CI System	Type of array	Location of Fold-over	Follow-up (m)
1	60	female	right	ERW	Cochlear	532	SPE	electrode 18	12
2	2	female	right	CS	Cochlear	532	SPE	electrode 18	13
3	4	male	left	ERW	Cochlear	532	SPE	electrode 18	6

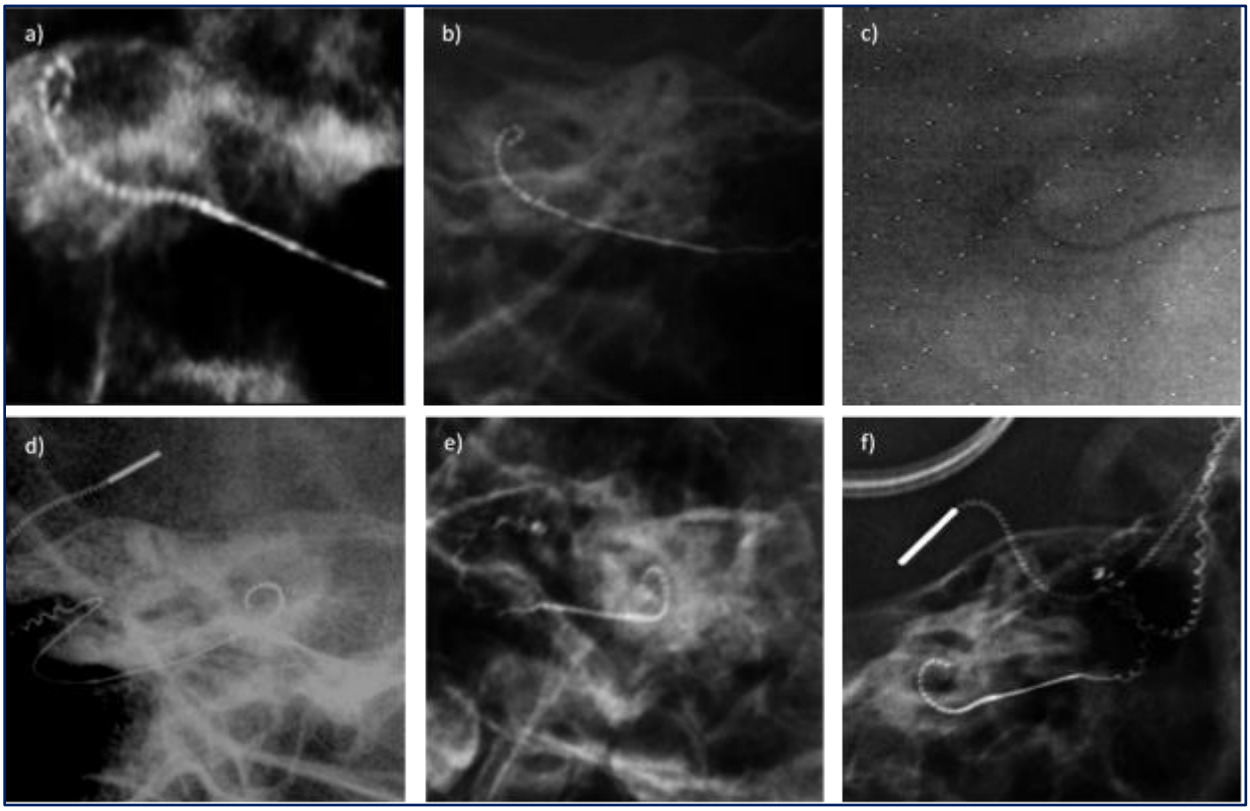

Figure 14. *Radiography of the three cases.* ***a.*** *Subject #1, postoperative radiography, Stenvers view.* ***b.*** *Subject #2, posteoperative radiography, Stenvers view.* ***c.*** *Subject #3, postoperative fluoroscopy, cochlear view,* ***d.*** *Subject #1, postoperative radiography after revision surgery, Stenvers view.* ***e.*** *Subject #2, postoperative radiography after revision surgery, Stenvers view.* ***f.*** *Subject #3, postoperative radiography after revision surgery, Stenvers view.*

Subject#1

A 60-year-old female subject with severe bilateral SNHL was referred for cochlear implantation of the right ear. The preoperative high-resolution CT scan and MRI revealed normal anatomy and no evidence of cochlear ossification or fibrosis. She had no history of meningitis. The round window niche was widened by drilling the bony rim over the round window to ensure good exposure of the membrane. There was no physical evidence during surgery to suggest the potential for intra-cochlear malposition of the electrode array and the intraoperative tests (impedance, ESRT and NRT examinations) did not show any abnormality (Figure15a, b). On the day after the implantation, a postoperative X-ray scan was performed (Figure 14a). With the help of the X-ray image, tip fold-over of the 18th electrode was detected. Unlike our standard protocol, the sound processor was programmed to the patient that day. The four apical electrodes that curved back were switched off so that the patient reported hearing sensations and the frequency discrimination was appropriate. The processor was programmed four weeks after the surgery again. At that time, the subject only reported whistling and beeping, but was unable to discriminate various frequencies. During the next two months, we were unable to produce a hearing experience for the patient. Hence, we decided to reimplant the patient with a contour advanced (CI512) electrode from the same implant family.

Subject#2

A 21-month-old girl with severe hair cell impairment - detected by brainstem evoked response audiometry (BERA), Auditory Steady State Response (ASSR) and distortion product otoacoustic emissions (DPOAEs), - was referred for bilateral cochlear implantation in June 2017. Genetic testing revealed mutation of the connexin 26 gene. Preoperative radiography and MRI scans revealed normal anatomy of the middle and inner ear. She had no history of bacterial meningitis. The round window was not detected on the right side; thus, cochleostomy insertion was performed. Unexpected oozing of the perilymph was noted. Accordingly, lower impedance (Figure 15c) and higher NRT values were measured during the intraoperative evaluations (Figure 15d). The ESRT, with the exception of electrode 5, could not be triggered. On the following day, a postoperative X-ray imaging (Figure 14b) revealed tip fold-over at the 18th electrode. Our team decided to perform a revision surgery.

Subject#3

A four-year-old male patient with severe bilateral SNHL was referred for sequential bilateral implantation. The first CI on the right side was performed without complication in September 2017; the surgery of the left side was performed in January 2018. Preoperative high-resolution CT and MRI scans showed regular anatomy of the middle and inner ear. He had no history of meningitis. The smooth contralateral insertion suggested the potential for a successful surgical insertion. The electrode array was gently inserted via the provided sheath through the round window using a soft-surgery technique. The surgeon reported some unusual resistance during the electrode insertion. The intraoperative tests did not show any abnormalities (Figure 15e, f). The following day, a tip fold-over was detected with X-ray imaging (Figure 14b).

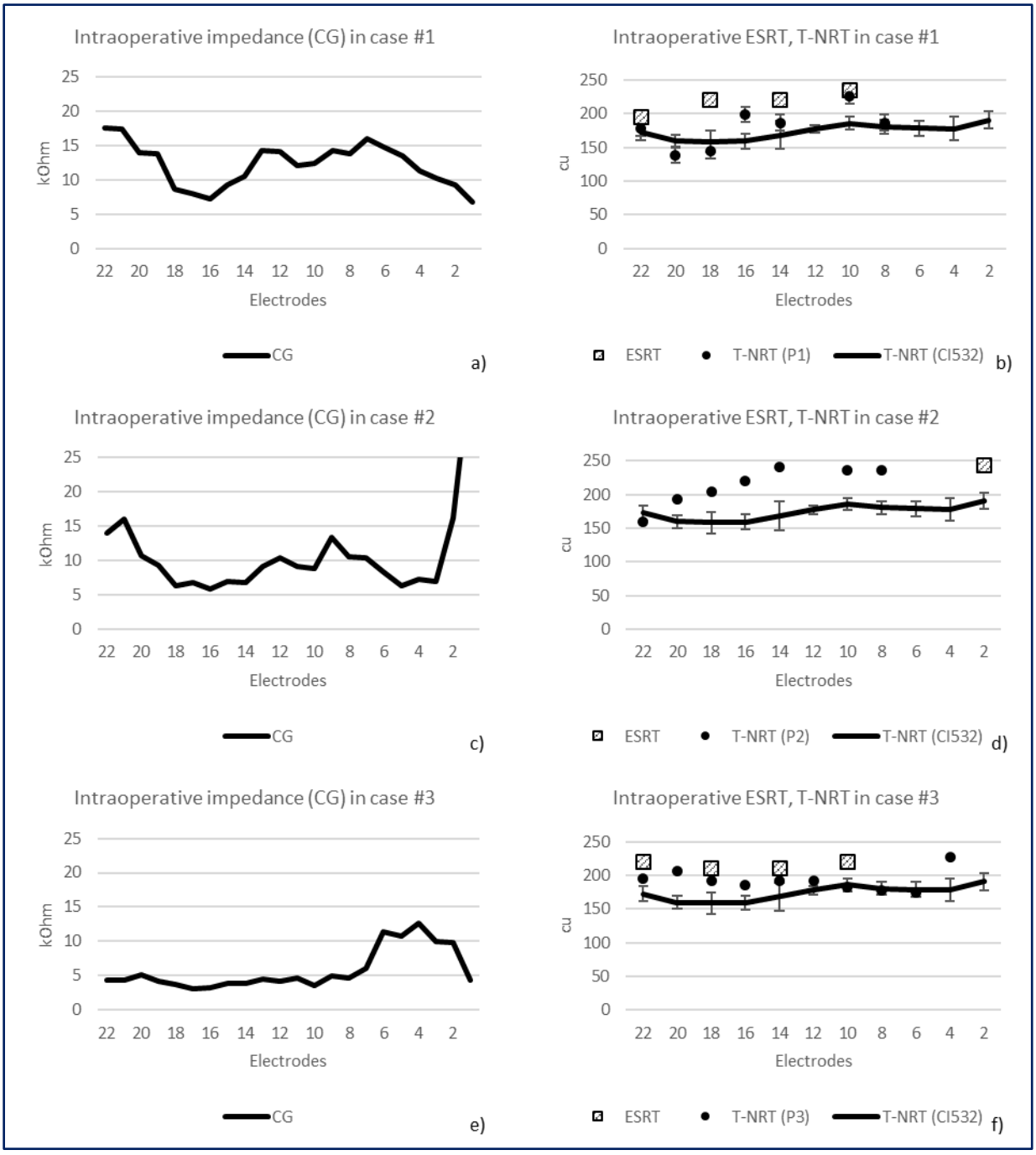

Figure 15. *Intraoperative tests.* ***a.*** *Intraoperative impedance telemetry in CG stimulation mode in Subject#1.* ***b.*** *Results of intraoperative stapedius reflex and nerve response telemetry in Subject#1. Based on clinical experience, none of the intraoperative studies showed any irregularities.* ***c.*** *Intraoperative impedance telemetry in CG stimulation mode in Subject#2.* ***d.*** *Results of intraoperative stapedius reflex and nerve response telemetry in Subject#2. With the exception of the fifth electrode, intraoperative stapedius reflex was not detected. NRT threshold (T-NRT) values were increased due to loss of the perilymph.* ***e.*** *Intraoperative impedance telemetry in CG stimulation mode in Subject#3.* ***f.*** *Results of intraoperative stapedius reflex and nerve response telemetry in Subject#3. Clinical results of intraoperative measurements showed no irregularities.*

Solutions

In the case of Subject #1, our team decided to implant a new device (CI512) with a more rigid and thicker electrode (Figure 14d) because tip fold-over of the slim perimodiolar electrode may have indicated an obstruction in the membranous labyrinth - which the preoperative CT scan did not reveal. The speech processor was reprogrammed four weeks after the reimplantation (Figure 16a). Instead of the whistling and unpleasant sounds, the patient reported a good sound experience. As of this report, she successfully differentiates the sound spectrum and hears sounds in a corresponding tone (Figure 16b).

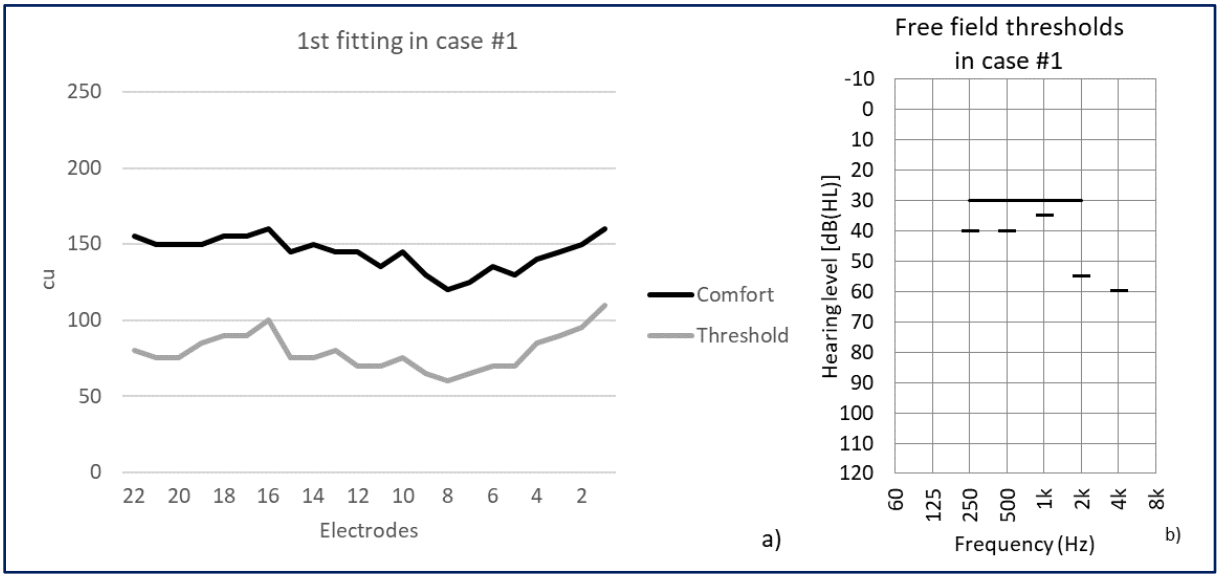

Figure 16. *Reimplantation results.* ***a.*** *First fitting comfort (black line) and threshold (grey line) levels.* ***b.*** *Free-field sound measurement results.*

In the second and third cases, early reimplantation was performed on the second postoperative day. The electrode array was gently removed from the cochlea and reinserted into a backup sheath (Figure 17) as used in our centre in these cases. Apart from its thin nature and proximity to the modiolus, another advantage of the slim perimodiolar electrode is that it can be reloaded into its external insertion sheath if necessary. Reinsertion was made in both paediatric cases. The intraoperative test results were normal (Figure 18a, b, c, d). The following day's postoperative X-ray images showed correct electrode location (Figure 14e, f). In both cases, we fitted the speech processor four weeks after the surgery. The paediatric patients also demonstrated good onset of speech perception with babbling and repetition of monosyllables. Speech development in Patient #2 successfully started consciously using disyllabic words one year later. Currently, her passive vocabulary is estimated at approximately 2-300 words. Patient

#3 is a perilingual child. Her vocalization has started and, for the time being, she has been producing lallation/unarticulated sounds. She uses her speech processor three hours a day on average. She had not used a hearing aid before, which could possibly cause her dislike towards the speech processor.

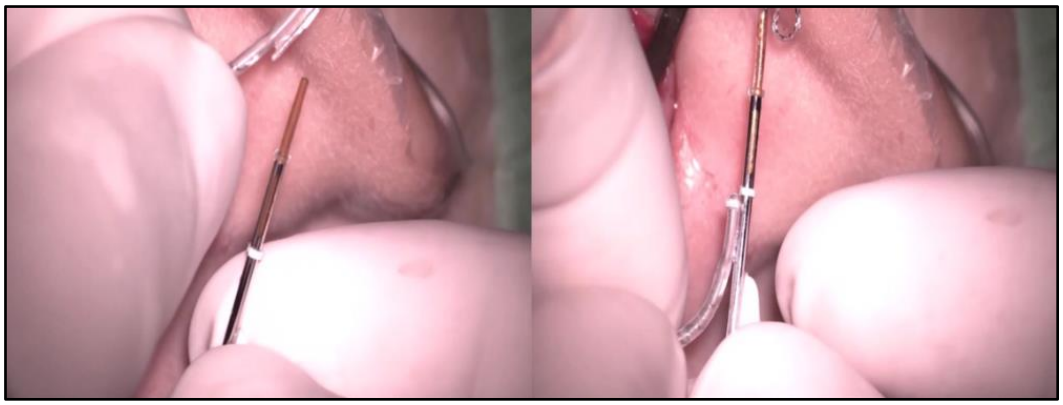

Figure 17. *Sheath re-loading in case #2 and #3 revision surgery*

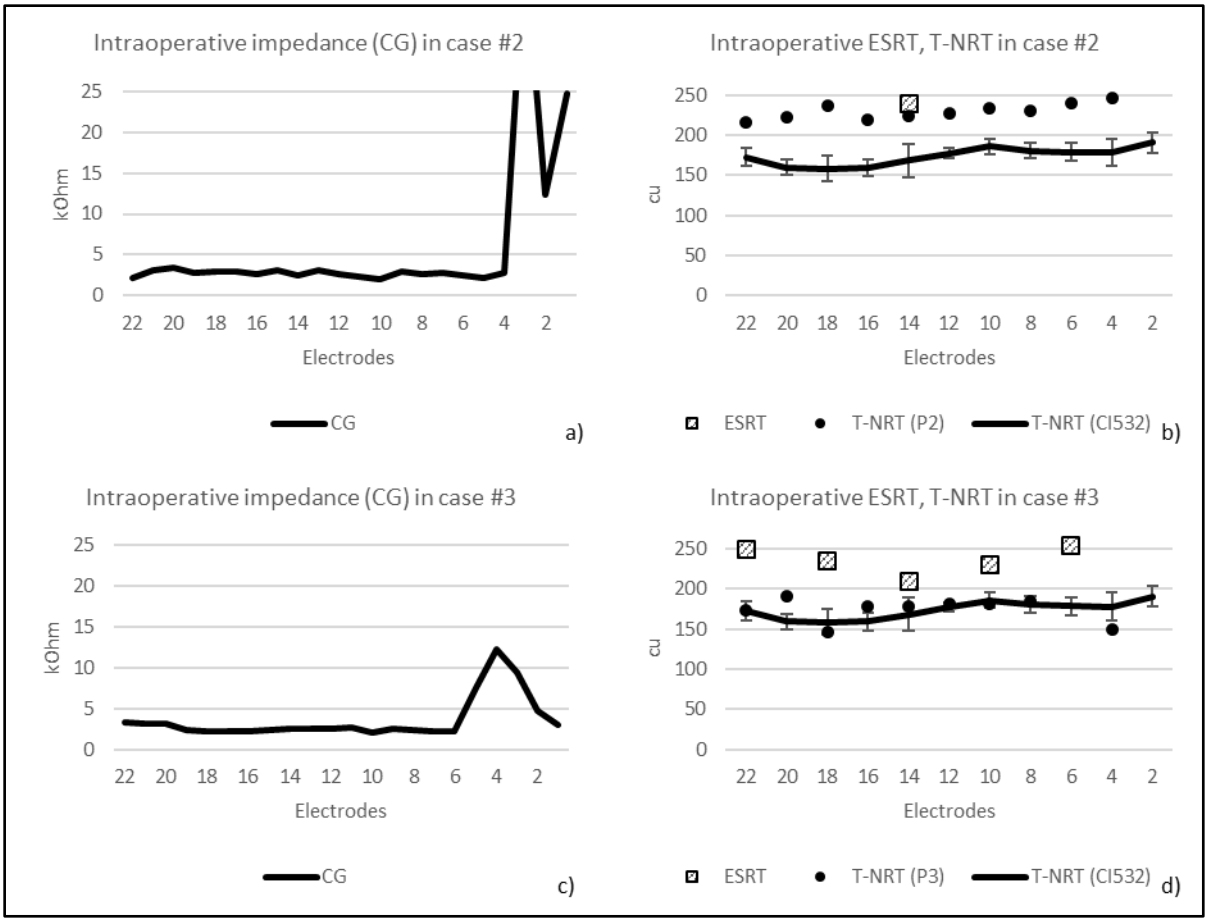

Figure 18. *Revision surgery's intraoperative tests in case #2 and case #3.* ***a*** *Intraoperative impedance telemetry in CG stimulation mode in case #2.* ***b*** *Subject#2: Results of intraoperative stapedius reflex and nerve response telemetry. With the exception of the 14th electrode, intraoperative stapedius reflex could not be triggered. Increased T-NRT values could be the result of oozing during the previous surgery.* ***c*** *Intraoperative impedance telemetry in CG stimulation mode in Subject#3.* ***d*** *Subject#3: Results of intraoperative stapedius reflex and nerve response telemetry. No irregularities occurred during the measurements.*

DISCUSSION

Preservation of acoustic hearing associated with cochlear implantation improves the postoperatively achievable periodicity and spectral resolution, which improves the patient's speech comprehension and the localization of the tone in particularly difficult conditions [73–78].

The effects of cochlear implantation on residual hearing have been discussed in several studies in which a number of surgical and technical factors have been identified [79]. There are some surgical techniques of approaching the scala tympani (*i.e.*, RW, ERW, CS) with varying risks of harming the fine structures of the cochlea with prompt or delayed onset [28]. Such late complications, like the appearance of endocochlear connective tissue or new bone formation, may lead to a gradual partial or complete loss of residual acoustic hearing [80]. This is most likely to be seen when the round window is extendedly exposed, where endothelial lesions trigger new tissue proliferation. The slightest is the tendency to harm the endocochlear structures when minimally invasive, soft surgery is applied [28].

Physical attributes of the electrode profile may also interfere with postoperative cochlear function. Theoretically, the endocochlear hydrodynamics may also be altered, as the vibration of the basilar membrane is restricted due to the presence of an electrode array. At this point, as the travelling waves to the apical region are modified, the basilar membrane would react to sounds differently, leading to an endocochlear “conductive” hearing loss [81, 82].

The new type of thin-diameter electrode arrays close to the modiolus are expected to have a lower hydrodynamic load, since the bony spiral lamina is attached from below, thus the basilar membrane vibrations remain unrestricted. However, the perimodiolar position of the electrode array allows the adjacent nerve elements of the spiral ganglion to be stimulated with a lower electrical intensity and through a smaller surface.

Cadaver experiments demonstrated that a force, applied to the basilar membrane with an average of 88 mN (42 mN to 122 mN) would be sufficient to accomplish the interscalar dislocation of the electrode, of which manual perceptibility is questionable [83]. Studies with large case numbers (n=100) have shown that the probability of the electrode line being located in the scala vestibuli significantly increased during CS, which also manifested itself in the absence of improvement in speech comprehension [84].

In a number of studies, intraoperatively performed electro-cochleography is used to track the electrode insertional trauma, furthermore to postoperative residual hearing follow-ups [85–87].

For the implementation of Electro-Acoustic (EAS) or hybrid speech processors the long-term preservation of residual acoustic hearing is inherently inevitable, thus application of atraumatic surgical techniques and electrode arrays is essential.

Our study cohort obviously demonstrates that by the application of appropriate soft surgery techniques and atraumatic electrodes are able to retain residual hearing on a long run. The positive experience gained with the new type of CI532 Slim Modiolar electrode predicts the possibility for the preservation of structural and functional integrity of all cochlear regions. Furthermore, a prompt, definitive solution could be provided for a possible late hearing loss progression, where only a psychophysical reprogramming of the implant would be enough.

On the basis of our results, if the acoustic hearing loss can be preserved with the assurance and efficacy of the initial experience, we will be able to provide sustained prominent hearing rehabilitation even in the indication of EAS that results in significant improvement in the life quality of many implantees.

In addition, long-term residual hearing loss may be of crucial importance in the subsequent feasibility of regenerative procedures and medical treatments [33, 45, 88, 89].

Intracochlear trauma due to electrode insertion may be as follows: (1) the trauma to the lateral wall tissues [17], (2) the translocation from scala tympani to scala vestibuli, (3) the basal fracture of the osseous spiral lamina [90] , etc. As for the lateral wall electrodes, many studies have been conducted with the stylet-based perimodiolar electrodes (e.g. Contour and Contour Advance (Cochlear Ltd., Sydney, Australia.)) to reveal their impact on cochlear microstructure and residual hearing [90, 91]. Lateral wall electrodes evidently contact lateral wall structures of the scala tympani, resulting in various degree of trauma to them. On the other hand, the impact of stylet-based perimodiolar electrodes varies, depending on the surgical technique applied (standard insertion technique vs advanced off stylet; SIT vs AOS). Perimodiolar electrodes implanted with SIT resulted in similar trauma profile to that with lateral wall electrodes; while with the AOS technique the lateral wall forces were minimized or negated such that they remain below the threshold for trauma or rupture of the intrascalar partition [92].

Up to date, only a few studies have been published with the sheath-based, slim-perimodiolar electrode and on its impact on cochlear microstructure and hearing preservation, that is object to this present study [33, 40].

Our results have proved the Nucleus CI532 Slim Perimodiolar® electrode array to be safe and effective in preserving residual hearing over three-years long follow-up period. This long-term

preservation of residual hearing refers to that the endocochlear trauma during electrode insertion is negligible or even absent.

There is always some risk of losing residual hearing due to cochlear implantation. In this study all of the subjects retained residual hearing within 9.73 dB(HL) in average at the measured 125-4000 Hz frequency range. These results are similar with a previous single-centre study outcome with the Hybrid L24 [93] where the median threshold increase was 10 dB(HL).

Electrical stimulation can be optimized by proper intrascalar positioning of the slim-perimodiolar electrode array in proximity to the neuronal structures of the cochlea [12, 24]. Due to this reduced distance the CI can deliver stimulation at a lower electrical intensity and through a smaller electrode surface, that has been proved to provide greater neural specificity [94–96], reduced stimulation levels [97–99], and improved hearing performance [24, 100].

There were no surgery-related complications, the slim perimodiolar electrode was suitable for round window approach in all case, that would improve the compliance of many surgeons.

A wide range of cochlear implants with different electrodes are available for rehabilitation of hearing impaired patients with severe to profound SNHL. Hearing rehabilitation outcomes may be influenced by optimizing device and electrode choice for the individual. Several comparative studies have been conducted including electrophysiological (ESRT, NRT) test methods to evaluate the influence of straight and perimodiolar electrode designs and their in-situ characteristics on clinical outcomes [14, 15, 67, 101–103]. Our study is unique in that it measured the influence of various electrode designs combined with a common receiver stimulator upon electrophysiological assessments for a relatively large routinely treated multicentre study cohort. As such, it is the first study to report on the influence of electrode design while using consistent implant receiver-stimulator electronics. The cooperation of the two clinics was established in 2017 with the aim to compare the perimodiolar and the straight electrode arrays. The study clinics followed a standard protocol enabled by the manufacturer's software, thus a conclusion from their individual results can be made. The results of Hey et al. from their multicentre study on CI532 are in good correlation with our results which proves that our methodology and results are reliable [52].

The Contour Electrode was the first perimodiolar electrode from Cochlear. As reported by researchers, some intracochlear trauma has been associated with its insertion, with a more reliable and less traumatic insertion achieved when deployed using the recommended advance

off-Stylet technique [14]. This is largely due to an inherent reduction in intracochlear outer wall force generation when using this technique for this electrode [14].

The Slim Modiolar Electrode is designed for insertion with minimal cochlear trauma. It has the advantage of taking 60% less volume in the scala tympani compared to the Contour Advance Electrode and is therefore placed in a position close to the modiolus. Perimodiolar proximity is an important clinical consideration as Holden et al. [24] concluded, observing that total insertion depth was not associated with better speech discrimination outcomes, however, the distance from the electrodes to the modiolus did indicate a significant influence. The Slim Modiolar electrode array takes a closer position to the modiolus than the Contour Advance electrode array as confirmed by a comparative radiological evaluation [53].

In this retrospective study the data from recipients with the three main types of electrode arrays used in each of the two author implant centres were included. Although the electrode of CI522 was known to take the lateral wall position within the cochlea, the authors' decided to enroll those subjects who were implanted with CI522 to gain a more detailed overview. Although results of two different implant centres were combined for evaluation, upon review, the authors considered the routine clinical practices employed and device parameters used at each site as sufficiently comparable.

Results from the objective intraoperative measurements indicated that the electrode contacts of the CI532 array were located closer to the modiolus than those of CI512. A previous study found that withdrawal of the stylet in the Contour Advance Electrode resulted in better NRT and ESRT responses, than with the stylet in place. They concluded that this is most probably due to a more favourable position of the electrode array towards the modiolus within the scala tympani once the stylet is removed [102].

In our study, although the mean ESRT was only slightly lower with CI532, the difference was statistically significant at the basal most electrodes tested. However, the mean T-NRT for CI532 was significantly lower than for CI512, especially in the apical-middle section, which is considered to be indicative of closer positioning towards the modiols. An expected rate of scalar dislocations could be 26% with precurved electrode (i.e. CI512) and 3% with straight electrode (i.e. CI522) with round window insertion technique [104] and this dislocation should have a significant impact on the NRT threshold in the apical part of the electrode. In order to minimize scalar dislocation, the extended round window insertion technique was used. Although the institutional protocols did not include postoperative computed tomography, the results from T-NRT and ESRT, both being constantly higher for CI512 when compared with CI532 and T-

NRT being constantly lower for CI512 when compared with CI522 are not indicative of significant dislocations between scalae tympani and vestibuli. The sizeable reduction in both T-NRT and ESRT observed in our study are considered sufficiently large to potentially influence differences in clinical outcomes as observed for subjective comfort level [102, 105].

The surface area of an electrode is inversely proportional with the resistance, thus current is proportional with the surface area. If the electrode with a smaller surface is capable of eliciting the same response it means that it is closer to the stimulated structure. The lower objective electrophysiological thresholds of CI532 suggest that the electrodes are capable of eliciting reflex responses with lower stimulation intensity, resulting from closer proximity to the modiolus.

In our experience the CI532 with its Slim Modiolar electrode profile provides a relatively easy and low trauma insertion procedure. However, implantation of this delicate electrode array was associated with tip fold-over at a rate of 3.19% that is comparable with the reported rates found in the literature [47–50, 106], but immediate intraoperative identification based on tactile feedback of the operating surgeon and standard intraoperative telemetry failed. Radiography definitively detected tip fold-over [107]. Based on our experience and measurement results, we are unable to determine the exact location of electrode array along its full length. International literature provides reference to the use of Spread of Excitation measurements [108] to detect tip-fold-over. However, our department has not had the availability to perform such measurements yet.

Based on our clinical protocol, X-ray imaging is performed the day after surgery. If the radiologist detects a suspected abnormality in the electrode position, fluoroscopy, cone-beam CT or low dose CT scans can be performed. Our recommendation is revision surgery, reloading the electrode array, if intact into a backup insertion sheath and reinsertion of the array. In an ideal situation, abnormalities of the electrode position would be detected in real time or shortly after insertion in order to spare a second procedure. Reliable electrophysiological methods or real-time imaging in the operating room (cone-beam CT, fluoroscopy or X-ray imaging) are encouraged. It is important to put special emphasis on preoperative imaging and 3D reconstruction. The more frequent use of fine and pre-curved electrodes necessitates rigorous routine postoperative radiological control of electrode array position.

ACKNOWLEDGEMENT

I would like to express sincere gratitude to my supervisor János András Jarabin MD PhD and József Géza Kiss PhD CSc habil. for involving me in the field of clinical and experimental audiology. They supported my research extensively.

I am grateful to Ferenc Tóth PhD. He let me working in the implantation team both as an audiologist and a physicist, offering me the possibility to see the true spectrum of hard of hearing patients' rehabilitation.

I would like to express my sincere gratitude to László Rovó MD PhD habil., now chair of the department of Otorhinolaryngology and Head-Neck Surgery for his continuous support and motivation in the broadening of my perspective both practical and theoretical ways.

I would like to thank to Roland Nagy PhD, Rebeka Schulcz, Alice Szamosközi, Fiona Molnár, Ádám Perényi MD PhD, Linda Szabó MD, Bálint Posta MD, and all my colleagues and co-authors for their work and collaboration.

I would like to thank all the assistants.

And now my heartfelt thanks to my family and my friends. They supported me all the time with unbounded love and patience, encouraging me to fulfil my duty.

REFERENCES

1. Olusanya BO, Neumann KJ, Saunders JE (2014) The global burden of disabling hearing impairment: a call to action. Bull World Health Organ 92:367–373. https://doi.org/10.2471/BLT.13.128728
2. Tendera A, Rispoli M, Senthilselvan A, Loucks TM (2019) Early Speech Rate Development: A Longitudinal Study. J Speech Lang Hear Res 62:4370–4381. https://doi.org/10.1044/2019_JSLHR-19-00145
3. Hubbard HI, Mamo SK, Hopper T (2018) Dementia and Hearing Loss: Interrelationships and Treatment Considerations. Semin Speech Lang 39:197–210. https://doi.org/10.1055/s-0038-1660779
4. Gates GA, Mills JH (2005) Presbycusis. Lancet (London, England) 366:1111–1120. https://doi.org/10.1016/S0140-6736(05)67423-5
5. Watson CS, Kidd GR, Miller JD, et al (2012) Telephone screening tests for functionally impaired hearing: current use in seven countries and development of a US version. J Am Acad Audiol 23:757–767. https://doi.org/10.3766/jaaa.23.10.2
6. House WF, Berliner KI (1986) Safety and efficacy of the House/3M cochlear implant in profoundly deaf adults. Otolaryngol Clin North Am 19:275–286
7. Clark G (2012) The multi-channel cochlear implant and the relief of severe-to-profound deafness. Cochlear Implants Int 13:69–85. https://doi.org/10.1179/1754762811Y.0000000019
8. Czigner J, Szilvássy J, Jóri J, Kiss JG (1997) Cochlear implantation in Szeged. A recently developed centre in South Hungary. Int J Artif Ogran 20:532
9. Farhood Z, Nguyen SA, Miller SC, et al (2017) Cochlear Implantation in Inner Ear Malformations: Systematic Review of Speech Perception Outcomes and Intraoperative Findings. Otolaryngol neck Surg Off J Am Acad Otolaryngol Neck Surg 156:783–793. https://doi.org/10.1177/0194599817696502
10. Finley CC, Skinner MW (2008) Role of electrode placement as a contributer. Otol Neurotol 29:920–928. https://doi.org/10.1097/MAO.0b013e318184f492.Role
11. Pfingst BE, Franck KH, Xu L, et al (2001) Effects of electrode configuration and place of stimulation on speech perception with cochlear prostheses. JARO - J Assoc Res Otolaryngol 2:87–103. https://doi.org/10.1007/s101620010065
12. Boyd PJ (2011) Potential benefits from deeply inserted cochlear implant electrodes. Ear Hear 32:411–427. https://doi.org/10.1097/AUD.0b013e3182064bda
13. Snels C, IntHout J, Mylanus E, et al (2019) Hearing Preservation in Cochlear Implant Surgery: A Meta-Analysis. Otol Neurotol 40:145–153. https://doi.org/10.1097/MAO.0000000000002083
14. Roland JTJ (2005) A model for cochlear implant electrode insertion and force evaluation: results with a new electrode design and insertion technique. Laryngoscope 115:1325–1339. https://doi.org/10.1097/01.mlg.0000167993.05007.35
15. Tykocinski M, Cohen LT, Pyman BC, et al (2000) Comparison of electrode position in the human cochlea using various perimodiolar electrode arrays. Am J Otol 21:205–211. https://doi.org/10.1016/s0196-0709(00)80010-1
16. Wackym PA, Firszt JB, Gaggl W, et al (2004) Electrophysiologic effects of placing cochlear implant electrodes in a perimodiolar position in young children. Laryngoscope

114:71–76. https://doi.org/10.1097/00005537-200401000-00012

17. Roland PS, Wright CG (2006) Surgical aspects of cochlear implantation: Mechanisms of insertional trauma. Adv Otorhinolaryngol 64:11–30. https://doi.org/10.1159/000094642

18. Von Ilberg C, Kiefer J, Tillein J, et al (1999) Electric-acoustic stimulation of the auditory system. New technology for severe hearing loss. Orl 61:334–340. https://doi.org/10.1159/000027695

19. Gantz BJ, Turner C, Gfeller KE, Lowder MW (2005) Preservation of hearing in cochlear implant surgery: advantages of combined electrical and acoustical speech processing. Laryngoscope 115:796–802. https://doi.org/10.1097/01.MLG.0000157695.07536.D2

20. Rebscher SJ, Hetherington A, Bonham B, et al (2008) Considerations for design of future cochlear implant electrode arrays: Electrode array stiffness, size, and depth of insertion. J Rehabil Res Dev 45:731–748. https://doi.org/10.1682/JRRD.2007.08.0119

21. Avci E, Nauwelaers T, Lenarz T, et al (2014) Variations in microanatomy of the human cochlea. J Comp Neurol 522:3245–3261. https://doi.org/10.1002/cne.23594

22. Adunka OF, Buchman CA (2007) Scala Tympani Cochleostomy I: Results of a Survey. Laryngoscope 117:2187–2194. https://doi.org/10.1097/MLG.0b013e3181453a6c

23. Fraysse B, Macías AR, Sterkers O, et al (2006) Residual hearing conservation and electroacoustic stimulation with the nucleus 24 contour advance cochlear implant. Otol Neurotol Off Publ Am Otol Soc Am Neurotol Soc [and] Eur Acad Otol Neurotol 27:624–633. https://doi.org/10.1097/01.mao.0000226289.04048.0f

24. Holden LK, Finley CC, Firszt JB, et al (2013) Factors affecting open-set word recognition in adults with cochlear implants. Ear Hear 34:342–360. https://doi.org/10.1097/AUD.0b013e3182741aa7

25. Büchner A, Schüssler M, Battmer RD, et al (2009) Impact of low-frequency hearing. Audiol Neurotol 14:8–13. https://doi.org/10.1159/000206490

26. Golub JS, Won JH, Drennan WR, et al (2012) Spectral and Temporal Measures in Hybrid Cochlear Implant Users. Otol Neurotol 33:147–153. https://doi.org/10.1097/mao.0b013e318241b6d3

27. Goehring T, Keshavarzi M, Carlyon RP, Moore BCJ (2019) Using recurrent neural networks to improve the perception of speech in non-stationary noise by people with cochlear implants. J Acoust Soc Am 146:705–718. https://doi.org/10.1121/1.5119226

28. Richard C, Fayad JN, Doherty J, Linthicum FH (2012) Round window versus cochleostomy technique in cochlear implantation: Histologic findings. Otol Neurotol 33:1181–1187. https://doi.org/10.1097/MAO.0b013e318263d56d

29. Jiam NT, Limb CJ (2016) The impact of round window vs cochleostomy surgical approaches on interscalar excursions in the cochlea: Preliminary results from a flat-panel computed tomography study. World J Otorhinolaryngol - Head Neck Surg 2:142–147. https://doi.org/10.1016/j.wjorl.2016.07.001

30. Haake SM, Dinh CT, Chen S, et al (2009) Dexamethasone protects auditory hair cells against TNFα-initiated apoptosis via activation of PI3K/Akt and NFκB signaling. Hear Res 255:22–32. https://doi.org/10.1016/j.heares.2009.05.003

31. Nagy I, Caelers A, Monge A, et al (2007) NF-kappaB-dependent apoptotic hair cell death in the auditory system. Audiol Neurotol 12:209–220. https://doi.org/10.1159/000101328

32. Jolly C, Garnham C, Mirzadeh H, et al (2009) Electrode features for hearing preservation and drug delivery strategies. Cochlear Implant Hear Preserv 67:28–42. https://doi.org/10.1159/000262594

33. Nagy R, Jarabin JA, Dimák B, et al (2018) Possibilities for residual hearing preservation with Nucleus CI532 Slim Modiolar electrode array: Case report. Orv Hetil 159:1680–1688. https://doi.org/10.1556/650.2018.31113

34. Lyu AR, Kim DH, Lee SH, et al (2018) Effects of dexamethasone on intracochlear inflammation and residual hearing after cochleostomy: A comparison of administration routes. PLoS One 13:1–15. https://doi.org/10.1371/journal.pone.0195230

35. Zine A, van de Water TR (2004) The MAPK/JNK signalling pathway offers potential therapeutic targets for the prevention of acquired deafness. Curr Drug Targets CNS Neurol Disord 3:325–332. https://doi.org/10.2174/1568007043337166

36. Pillsbury HC, DIllon MT, Buchman CA, et al (2018) Multicenter US Clinical Trial with an Electric-Acoustic Stimulation (EAS) System in Adults: Final Outcomes. Otol Neurotol 39:299–305. https://doi.org/10.1097/MAO.0000000000001691

37. Roland JT, Gantz BJ, Waltzman SB, Parkinson AJ (2016) United States multicenter clinical trial of the cochlear nucleus hybrid implant system. Laryngoscope 126:175–181. https://doi.org/10.1002/lary.25451

38. Lenarz T, James C, Cuda D, et al (2013) European multi-centre study of the Nucleus Hybrid L24 cochlear implant. Int J Audiol 52:838–848. https://doi.org/10.3109/14992027.2013.802032

39. Mady LJ, Sukato DC, Fruit J, et al (2017) Hearing Preservation: Does Electrode Choice Matter? Otolaryngol - Head Neck Surg (United States) 157:837–847. https://doi.org/10.1177/0194599817707167

40. Nagy R, Jarabin J, Perényi Á, et al (2018) Long-term Hearing Preservation with Slim Perimodiolar CI532® Cochlear Implant Array. Am J Otolaryngol 1:1019

41. Schieferbein V, Bredemann J, Schmitt R, et al (2019) Influence of patient-specific anatomy on medical computed tomography and risk evaluation of minimally invasive surgery at the otobasis. Eur Arch Oto-Rhino-Laryngology 276:375–382. https://doi.org/10.1007/s00405-018-5249-0

42. Jiam NT, Jiradejvong P, Pearl MS, Limb CJ (2016) The effect of round Window vs cochleostomy surgical approaches on cochlear implant electrode position a flat-panel computed tomography study. JAMA Otolaryngol - Head Neck Surg 142:873–880. https://doi.org/10.1001/jamaoto.2016.1512

43. Nada I, Abdelhamid AN, Negm A (2017) The utilization of round window membrane surface tension in facilitating slim electrodes insertion during cochlear implantation. Eur Arch Oto-Rhino-Laryngology 274:3327–3334. https://doi.org/10.1007/s00405-017-4652-2

44. Mirsalehi M, Rau TS, Harbach L, et al (2017) Insertion forces and intracochlear trauma in temporal bone specimens implanted with a straight atraumatic electrode array. Eur Arch Oto-Rhino-Laryngology 274:2131–2140. https://doi.org/10.1007/s00405-017-4485-z

45. Cuda D, Murri A (2017) Cochlear implantation with the nucleus slim modiolar electrode (CI532): a preliminary experience. Eur Arch Oto-Rhino-Laryngology 274:4141–4148. https://doi.org/10.1007/s00405-017-4774-6

46. Marx M, Risi F, Escude B, et al (2013) Reliability of cone beam computed tomography in scalar localization of the electrode array: A radio histological study

47. Ramos-Macias A, R De Miguel A, Falcon-González JC (2017) Mechanisms of electrode fold-over in cochlear implant surgery when using a flexible and slim perimodiolar electrode array. Acta Otolaryngol 137:1129–1135. https://doi.org/10.1080/00016489.2016.1271449

48. Aschendorff A, Briggs R, Brademann G, et al (2017) Clinical investigation of the nucleus slim modiolar electrode. Audiol Neurotol 22:169–179. https://doi.org/10.1159/000480345

49. Zuniga MG, Rivas A, Hedley-Williams A, et al (2017) Tip Fold-over in Cochlear Implantation. Otol Neurotol 38:199–206. https://doi.org/10.1097/MAO.0000000000001283

50. Sabban D, Parodi M, Blanchard M, et al (2018) Intra-cochlear electrode tip fold-over. Cochlear Implants Int 19:225–229. https://doi.org/10.1080/14670100.2018.1427823

51. McJunkin JL, Durakovic N, Herzog J, Buchman CA (2018) Early Outcomes with a Slim, Modiolar Cochlear Implant Electrode Array. Otol Neurotol 39:e28–e33. https://doi.org/10.1097/MAO.0000000000001652

52. Hey M, Wesarg T, Mewes A, et al (2019) Objective, audiological and quality of life measures with the CI532 slim modiolar electrode. Cochlear Implants Int 20:80–90. https://doi.org/10.1080/14670100.2018.1544684

53. Perényi Á, Jóri J, Csanády M, Rovó L (2019) Dimensions of the human temporal bone that are relevant to cochlear implantation surgery in infants and toddlers. A clinical-radiological study. Orv Hetil 160:936–943. https://doi.org/10.1556/650.2019.31389

54. Dimak B, Nagy R, Perenyi A, et al (2020) Review of electrode placement with the Slim Modiolar Electrode: identification and management. Ideggyogy Sz 73:53–59. https://doi.org/10.18071/isz.73.0053

55. Ramos-Macías A, Borkoski-Barreiro SA, Falcón-González JC, Ramos-De Miguel A (2018) Hearing Preservation with the Slim Modiolar Electrode Nucleus CI532® Cochlear Implant: A Preliminary Experience. Audiol Neurotol 22:317–325. https://doi.org/10.1159/000486409

56. Friedland DR, Runge-Samuelson C (2009) Soft Cochlear Implantation: Rationale for the Surgical Approach. Trends Amplif 13:124–138. https://doi.org/10.1177/1084713809336422

57. Lehnhardt E (1993) Intracochlear placement of cochlear implant electrodes in soft surgery technique. HNO 41:356–9

58. Cohen NL (1997) Cochlear implant soft surgery: Fact or fantasy? Otolaryngol - Head Neck Surg 117:214–216. https://doi.org/10.1016/S0194-5998(97)70176-1

59. Carlson ML, Driscoll CLW, Gifford RH, et al (2011) Implications of minimizing trauma during conventional cochlear implantation. Otol Neurotol 32:962–968. https://doi.org/10.1097/MAO.0b013e3182204526

60. Adunka O, Unkelbach MH, Mack M, et al (2004) Cochlear implantation via the round window membrane minimizes trauma to cochlear structures: A histologically controlled insertion study. Acta Otolaryngol 124:807–812. https://doi.org/10.1080/00016480410018179

61. Khater A, El-Anwar MW (2017) Methods of hearing preservation during cochlear

implantation. Int Arch Otorhinolaryngol 21:297–301. https://doi.org/10.1055/s-0036-1585094

62. Koch RW, Ladak HM, Elfarnawany M, Agrawal SK (2017) Measuring Cochlear Duct Length - A historical analysis of methods and results. J Otolaryngol - Head Neck Surg 46:1–11. https://doi.org/10.1186/s40463-017-0194-2

63. Karkas A, Champfleur NM de, Uziel A, et al (2018) Benefit of Preoperative Temporal Bone CT for Atraumatic Cochlear Implantation. Otol Neurotol Off Publ Am Otol Soc Am Neurotol Soc [and] Eur Acad Otol Neurotol 39:e186–e194. https://doi.org/10.1097/MAO.0000000000001692

64. Ádám P, Zsolt B, Zoltán B, et al (2016) Cone-Beam Komputertomográfi a Alkalmazása a Fül-Orr-Gégészeti Képalkotásban. Orv Hetil 157:52–58. https://doi.org/10.1556/650.2016.30334

65. Hughes ML, Vander Werff KR, Brown CJ, et al (2001) A longitudinal study of electrode impedance, the electrically evoked compound action potential, and behavioral measures in nucleus 24 cochlear implant users. Ear Hear 22:471–486. https://doi.org/10.1097/00003446-200112000-00004

66. Di Lella FA, Parreño M, Fernandez F, et al (2020) Measuring the Electrical Status of the Bionic Ear. Re-thinking the Impedance in Cochlear Implants. Front Bioeng Biotechnol 8:1–9. https://doi.org/10.3389/fbioe.2020.568690

67. Baysal E, Karatas E, Deniz M, et al (2012) Intra- and postoperative electrically evoked stapedius reflex thresholds in children with cochlear implants. Int J Pediatr Otorhinolaryngol 76:649–652. https://doi.org/10.1016/j.ijporl.2012.01.030

68. Brown CJ, Abbas PJ, Borland J, Bertschy MR (1996) Electrically evoked whole nerve action potentials in Ineraid cochlear implant users: responses to different stimulating electrode configurations and comparison to psychophysical responses. J Speech Hear Res 39:453–467. https://doi.org/10.1044/jshr.3903.453

69. Killian M, Klis S, Smoorenburg G (1994) Adaptation in the compound action potential response of the guinea pig VIII to electric stimulation. Hear Res 81:66–81

70. Kiss JG, Tóth F, Nagy AL, et al (2003) Neural response telemetry in cochlear implant users. Int Tinnitus J 9:59–60

71. Cafarelli Dees D, Dillier N, Lai WK, et al (2005) Normative findings of electrically evoked compound action potential measurements using the neural response telemetry of the Nucleus CI24M cochlear implant system. Audiol Neurootol 10:105–116. https://doi.org/10.1159/000083366

72. Szuts V, Jarabin JA, Nagy N, et al (2018) Altered Potassium Ion Homeostasis in Hearing Loss. Ion Channels Heal Sick. https://doi.org/10.5772/intechopen.77732

73. Dunn CC, Perreau A, Gantz B, Tyler RS (2010) Benefits of localization and speech perception with multiple noise sources in listeners with a short-electrode cochlear implant. J Am Acad Audiol 21:44–51. https://doi.org/10.3766/jaaa.21.1.6

74. Gifford RH, Dorman MF, Skarzynski H, et al (2013) Cochlear implantation with hearing preservation yields significant benefit for speech recognition in complex listening environments. Ear Hear 34:413–425. https://doi.org/10.1097/AUD.0b013e31827e8163

75. Gifford RH, Driscoll CLW, Davis TJ, et al (2015) A Within-Subject Comparison of Bimodal Hearing, Bilateral Cochlear Implantation, and Bilateral Cochlear Implantation with Bilateral Hearing Preservation: High-Performing Patients. Otol Neurotol 36:1331–

1337. https://doi.org/10.1097/MAO.0000000000000804

76. Gifford RH, Grantham DW, Sheffield SW, et al (2014) Localization and interaural time difference (ITD) thresholds for cochlear implant recipients with preserved acoustic hearing in the implanted ear. Hear Res 312:28–37. https://doi.org/10.1016/j.heares.2014.02.007

77. Loiselle LH, Dorman MF, Yost WA, Gifford RH (2015) Sound source localization by hearing preservation patients with and without symmetrical low-frequency acoustic hearing. Audiol Neurotol 20:166–171. https://doi.org/10.1159/000367883

78. Loiselle LH, Dorman MF, Yost WA, et al (2016) Using ILD or ITD Cues for Sound Source Localization and Speech Understanding in a Complex Listening Environment by Listeners With Bilateral and With Hearing-Preservation Cochlear Implants. J Speech Lang Hear Res 59:810–818. https://doi.org/10.1044/2015_JSLHR-H-14-0355

79. Sweeney AD, Hunter JB, Carlson ML, et al (2016) Durability of Hearing Preservation after Cochlear Implantation with Conventional-Length Electrodes and Scala Tympani Insertion. Otolaryngol - Head Neck Surg (United States) 154:907–913. https://doi.org/10.1177/0194599816630545

80. Fayad JN, Makarem AO, Linthicum FH (2009) Histopathologic assessment of fibrosis and new bone formation in implanted human temporal bones using 3D reconstruction. Otolaryngol - Head Neck Surg 141:247–252. https://doi.org/10.1016/j.otohns.2009.03.031

81. Banakis Hartl RM, Mattingly JK, Greene NT, et al (2016) A preliminary investigation of the air-bone gap: Changes in intracochlear sound pressure with air- and bone-conducted stimuli after cochlear implantation. Otol Neurotol 37:1291–1299. https://doi.org/10.1097/MAO.0000000000001184

82. Chole RA, Hullar TE, Potts LG (2014) Conductive Component After Cochlear Implantation in Patients With Residual Hearing Conservation. Am J Audiol 23:359–364. https://doi.org/10.1044/2014_AJA-14-0018

83. Schuster D, Kratchman LB, Labadie RF (2015) Characterization of intracochlear rupture forces in fresh human cadaveric cochleae. Otol Neurotol 36:657–661. https://doi.org/10.1097/MAO.0000000000000573

84. Wanna GB, Noble JH, Carlson ML, et al (2014) Impact of electrode design and surgical approach on scalar location and cochlear implant outcomes. Laryngoscope 124:S1–S7. https://doi.org/10.1002/lary.24728

85. O'Connell BP, Hunter JB, Wanna GB (2016) The importance of electrode location in cochlear implantation. Laryngoscope Investig Otolaryngol 1:169–174. https://doi.org/10.1002/lio2.42

86. Koka K, Litvak LM (2017) Feasibility of using electrocochleography for objective estimation of electro-acoustic interactions in cochlear implant recipients with residual hearing. Front Neurosci 11:1–9. https://doi.org/10.3389/fnins.2017.00337

87. Dalbert A, Pfiffner F, Hoesli M, et al (2018) Assessment of cochlear function during cochlear implantation by extra- and intracochlear electrocochleography. Front Neurosci 12:1–9. https://doi.org/10.3389/fnins.2018.00018

88. Plontke SK, Götze G, Rahne T, Liebau A (2017) Intracochlear drug delivery in combination with cochlear implants: Current aspects. HNO 65:19–28. https://doi.org/10.1007/s00106-016-0285-9

89. Mittal R, Nguyen D, Patel AP, et al (2017) Recent advancements in the regeneration of auditory hair cells and hearing restoration. Front Mol Neurosci 10:. https://doi.org/10.3389/fnmol.2017.00236

90. Adunka O, Gstoettner W, Hambek M, et al (2004) Preservation of basal inner ear structures in cochlear implantation. Orl 66:306–312. https://doi.org/10.1159/000081887

91. Brant JA, Ruckenstein MJ (2016) Electrode selection for hearing preservation in cochlear implantation: A review of the evidence. World J Otorhinolaryngol - Head Neck Surg 2:157–160. https://doi.org/10.1016/j.wjorl.2016.08.002

92. Risi F (2018) Considerations and rationale for cochlear implant electrode design-past, present and future. J Int Adv Otol 14:382–391. https://doi.org/10.5152/iao.2018.6372

93. Lenarz T, Stöver T, Buechner A, et al (2009) Hearing conservation surgery using the hybrid-L electrode: Results from the first clinical trial at the Medical University of Hannover. Audiol Neurotol 14:22–31. https://doi.org/10.1159/000206492

94. Xi X, Ji F, Han D, et al (2009) Electrode interaction in cochlear implant recipients: Comparison of straight and contour electrode arrays. Orl 71:228–237. https://doi.org/10.1159/000229303

95. Basta D, Todt I, Ernst A (2010) Audiological outcome of the pull-back technique in cochlear implantees. Laryngoscope 120:1391–1396. https://doi.org/10.1002/lary.20942

96. Hughes ML, Abbas PJ (2006) Electrophysiologic channel interaction, electrode pitch ranking, and behavioral threshold in straight versus perimodiolar cochlear implant electrode arrays. J Acoust Soc Am 119:1538–1547. https://doi.org/10.1121/1.2164969

97. Tykocinski M, Saunders E, Cohen LT, et al (2001) The Contour Electrode Array: Safety Study and Initial Patient Trials of a New Perimodiolar Design. Otol Neurotol 22:33–41. https://doi.org/10.1097/00129492-200101000-00007

98. Saunders E, Cohen L, Aschendorff A, et al (2002) Threshold, comfortable level and impedance changes as a function of electrode-modiolar distance. Ear Hear 23:28–40. https://doi.org/10.1097/00003446-200202001-00004

99. Parkinson AJ, Arcaroli J, Staller SJ, et al (2002) The Nucleus® 24 Contour™ cochlear implant system: Adult clinical trial results. Ear Hear 23:. https://doi.org/10.1097/00003446-200202001-00005

100. Dowell R (2012) Evidence about the effectiveness of cochlear implants for adults. Evidence based practice in audiology: evaluating interventions for children and adults with hearing impairment.

101. O'Connell BP, Hunter JB, Gifford RH, et al (2016) Electrode Location and Audiologic Performance After Cochlear Implantation: A Comparative Study Between Nucleus CI422 and CI512 Electrode Arrays. Otol Neurotol Off Publ Am Otol Soc Am Neurotol Soc [and] Eur Acad Otol Neurotol 37:1032–1035. https://doi.org/10.1097/MAO.0000000000001140

102. Rajati M, Ghassemi MM, Bakhshaee M, et al (2014) Effect of stylet removal on neural response telemetry and stapedial reflex thresholds during cochlear implantation. Auris Nasus Larynx 41:255–258. https://doi.org/10.1016/j.anl.2013.10.015

103. Müller A, Hocke T, Mir-Salim P (2015) Intraoperative findings on ECAP-measurement: normal or special case? Int J Audiol 54:257–264. https://doi.org/10.3109/14992027.2014.969410

104. Boyer E, Karkas A, Attye A, et al (2015) Scalar localization by cone-beam computed

tomography of cochlear implant carriers: a comparative study between straight and periomodiolar precurved electrode arrays. Otol Neurotol Off Publ Am Otol Soc Am Neurotol Soc [and] Eur Acad Otol Neurotol 36:422–429. https://doi.org/10.1097/MAO.0000000000000705

105. Mittmann P, Todt I, Ernst A, et al (2016) Electrophysiological detection of scalar changing perimodiolar cochlear electrode arrays: a long term follow-up study. Eur Arch oto-rhino-laryngology Off J Eur Fed Oto-Rhino-Laryngological Soc Affil with Ger Soc Oto-Rhino-Laryngology - Head Neck Surg 273:4251–4256. https://doi.org/10.1007/s00405-016-4175-2

106. Trakimas DR, Kozin ED, Ghanad I, et al (2018) Precurved Cochlear Implants and Tip Foldover: A Cadaveric Imaging Study. Otolaryngol - Head Neck Surg (United States) 158:343–349. https://doi.org/10.1177/0194599817738978

107. Ramos de Miguel Á, Argudo AA, Borkoski Barreiro SA, et al (2018) Imaging evaluation of electrode placement and effect on electrode discrimination on different cochlear implant electrode arrays. Eur Arch Oto-Rhino-Laryngology 275:1385–1394. https://doi.org/10.1007/s00405-018-4943-2

108. Grolman W, Maat A, Verdam F, et al (2009) Spread of excitation measurements for the detection of electrode array foldovers: A prospective study comparing 3-dimensional rotational x-ray and intraoperative spread of excitation measurements. Otol Neurotol 30:27–33. https://doi.org/10.1097/MAO.0b013e31818f57ab

SUPPLEMENTARY

I.

ESETISMERTETÉS

REVIEW OF ELECTRODE PLACEMENT WITH THE SLIM MODIOLAR ELECTRODE: IDENTIFICATION AND MANAGEMENT

Balazs DIMAK, Roland NAGY, Adam PERENYI, Janos Andras JARABIN, Rebeka SCHULCZ, Miklos CSANADY, Jozsef JORI, Laszlo ROVO, Jozsef Geza KISS

University of Szeged, Department of Oto-Rhino- Laryngology, Head and Neck Surgery, Szeged

PRINT | English | https://doi.org/10.18071/isz.73.0053 | www.elitmed.hu

Background – Several cochlear implant recipients experience functionality loss due to electrode array mal-positioning. The application of delicate perimodiolar electrodes has many electrophysiological advantages, however, these profiles may be more susceptible to tip fold-over.
Purpose – The prompt realization of such complication following electrode insertion would be auspicious, thus the electrode could be possibly repositioned during the same surgical procedure.
Methods – The authors present three tip fold-over cases, experienced throughout their work with Slim Modiolar Electrode implants. Implantations were performed through the round window approach, by a skilled surgeon. Standard intraoperative measurements (electric integrity, neural response telemetry, and electrical stapedial reflex threshold tests) were successfully completed. The electrode position was controlled by conventional radiography on the first postoperative day.
Results – Tip fold-over was not tactilely sensated by the surgeon. Our subjects revealed normal intraoperative telemetry measurements, only the postoperative imaging showed the tip fold-over. Due to the emerging adverse perception of constant beeping noise, the device was replaced by a CI512 implant after 6 months in one case. In the two remaining cases, the electrode array was reloaded into a back-up sheath, and reinserted into the scala tympani successfully through an extended round window approach.
Discussion – Future additional studies using the spread of excitation or electric field imaging may improve test reliability. As all of these measurements are still carried out following electrode insertion, real-time identification, unfortunately, remains questionable.

PERIMODIOLÁRIS TÍPUSÚ ELEKTRÓDA BEHELYEZÉSE: ÁTTEKINTÉS ÉS ESETTANULMÁNYOK

Dimak B; Nagy R; Perenyi A; Jarabin JA; Schulcz R; Csanady M; Jori J; Rovo L; Kiss JG
Ideggyogy Sz 2020;73(1–2):53–59.

Bevezetés – Számos, cochlearis implantáción átesett beteg tapasztalhat funkcionális veszteséget az elektródasor nem megfelelő elhelyezkedése miatt. A perimodioláris elektródák használata számos elektrofiziológiai előnnyel jár, azonban ezek az elektródatípusok hajlamosabbak lehetnek a visszahajlásra.
Célkitűzés – Az elektródasor behelyezését követően minél előbb felismerni az esetlegesen felmerülő tip fold-over jelenséget azért, hogy az elektródasor helyzetét még ugyanabban a műtéti eljárásban korrigálni lehessen.
Beteganyag és módszerek – Tanulmányunk három esetet mutat be, amelyek során a perimodioláris típusú elektróda behelyezése során tip fold-over-t tapasztaltunk. Az elektródasor behelyezése minden esetben a kerek ablakon keresztül történt. A beavatkozás során protokolláris intraoperatív méréseket (elektromos impedancia, idegi válasz telemetria és elektromos stapedius reflex küszöb teszt) végeztünk. Az elektróda helyzetét radiológiai vizsgálatokkal a műtét utáni első napon ellenőriztük.
Eredmények – Az elektródasor visszafordulását az operatőr nem érzékelte. Habár az intraoperatív mérések nem mutattak rendellenes eredményt, a műtét utáni képalkotó vizsgálatok tip fold-over jelenséget tártak fel. Az első esetben egy állandó sípoló zaj észlelése miatt az eszközt hat hónap elteltével CI512 implantátummal helyettesítettük. Két esetben az elektródasort visszahelyeztük az operációt követő napon egy új, steril vezetőbe, és a megnagyobbított kerek ablakon keresztül korrigáltuk az elektródasor helyzetét a scala tympaniba.
Megbeszélés – A nemzetközi szakirodalom alapján spread of excitation vizsgálatok elvégzését tervezzük. Mivel ezeket a méréseket is az elektróda behelyezése után végzik, a valós idejű azonosítás sajnos továbbra sem megoldott.

Correspondent: Balazs DIMAK, University of Szeged, Department of Oto-Rhino- Laryngology, Head and Neck Surgery; 6725 Szeged, Tisza Lajos blvd. 111.
Telephone: +3662341507, e-mail: dimak.balazs@med.u-szeged.hu
https://orcid.org/0000-0001-6546-6256

Érkezett: 2019. augusztus 29. Elfogadva: 2019. október 5.

Conclusion – Tip fold-over could be reliably identified by conventional X-ray imaging. By contrast, intraoperative electrophysiology was not sufficiently sensitive to reveal it.

Keywords: *cochlear implantation, cochlear implantation revision, perimodiolar electrode profile, tip fold-over*

Konklúzió – A tip fold-over megbízhatóan azonosítható hagyományos röntgenfelvétel segítségével. Ezzel szemben az intraoperatív elektrofiziológiai mérések nem bizonyulnak hatékony módszernek.

Kulcsszavak: *cochlearis implantáció, a cochlearis implantáció revíziója, perimodioláris elektródaprofil, tip fold-over*

Cochlear implant (CI) provides rehabilitation for uni- or bilateral severe to profound sensorineural hearing loss. Every CI hardware and software components are subjects of continuous development over time to provide good speech perception. On the other hand, the applied surgical approach and technique may also substantially interfere with the functional outcome.

In order to restore the best hearing functionality, different factors are needed to be considered, as follows: 1. electrode insertion depth and cochlear coverage, 2. matching neuro-tonotopicity, 3. atraumatic electrode insertion, and 4. applying the proper electrode array that matches the recipient's individual cochlear anatomy[1]. Therefore, several electrode concepts exist today that could represent some alternative solutions for successful implantation.

Serving as an 'interface', the electrode array is that the electric stimuli are transmitted to the neural structures through, thus its intra scalar-position has a fundamental influence on all aspects of stimulation. There are three typical electrode positions within the scala tympani: 1. perimodiolar, 2. mid-scala and 3. lateral wall, defined as the relative distance from the modiolus increases respectively.

With the perimodiolar electrode position, plenty of advantages are realized. As the distance from the modiolus is minimized and consistent modiolar proximity is maintained, limited adjacent current spread could be achieved with narrower stimulation width and reduced current demand, that finally could relate to improved speech recognition. Applying this electrode profile residual hearing could be preserved on the long run[2] when it is inserted via 'soft surgery'[3] including extended round window (ERW) approach[4–6]. To incorporate the virtue of perimodiolar stimulation with reduced insertion trauma, a slim, pre-curved electrode profile (CI532) was recently released by Cochlear Ltd. (Sydney, AUS). This electrode array is held straight prior to insertion by an external polymer reloadable sheath that is removed after full electrode insertion[7].

ABBREVIATIONS

ASSR: auditory steady-state response
BERA: brainstem evoked response audiometry
CG: common ground
CI: cochlear implant
CS: cochleostomy
CT: computer tomography
DPOAEs: distortion product otoacoustic emissions
eCAP: electrically-evoked compound action potential
ERW: extended round window
ESRT: electrically evoked stapedius reflex threshold
m: months
MRI: Magnetic Resonance Imaging
NRT: neural response telemetry
P: patient
SPE: slim perimodiolar electrode
T-NRT: neural response telemetry threshold

However, by the broader application of perimodiolar electrodes various challenges have been brought to light[8]. One infrequent issue is that these thin and flexible electrode arrays are potentially more susceptible to tip fold-over, where the tip of the electrode is folding on itself as a 'hairpin curve'[9].

Various surgical complications (gusher, oozing, etc.), or anamnesis of previous diseases (meningitis, sclerosis of the cochlea) increase the risk of tip fold-over.

In total, 94 slim perimodiolar electrode profile have been implanted in our tertiary referral center since November 2015. We detected three tip fold-over phenomena since then (approx. 3%). This incidence corresponds to the published international data[10–13].

This retrospective study aimed to unfold the challenging intra- and postoperative identification of tip fold-over and the possible management through three independent cases.

Table 1. *Tip fold-over patients and electrode characteristics*

Patient #	Age	Sex	Side of CI	Approach	Company	CI System	Type of array	Location of Fold-over	Follow-up (m)
1	60	female	right	ERW	Cochlear	532	SPE	electrode 18	12
2	2	female	right	CS	Cochlear	532	SPE	electrode 18	13
3	4	male	left	ERW	Cochlear	532	SPE	electrode 18	6

ERW: extended round window, CS: cochleostomy, SPE: slim perimodiolar electrode; (m) months

Material and methods

In accordance with our clinical protocol, all patients undergo neuroimaging assessment prior to surgery[14]. In standard cases, high-resolution (0.8 to 1.25 mm slice thickness) Computer Tomography (CT) scan of the temporal bone is applied, while in special cases, Magnetic Resonance Imaging (MRI)is performed[15]. If the history is indicative of bacterial meningitis or auditory nerve aplasia, MRI is the test of choice. Thus the course of the surgery could be planned in advance to get the most suitable electrode profile for the patient[16].

In our practice the primary aim is to preserve residual hearing by minimal invasive electrode insertion[17], using the thinnest electrode possible with an atraumatic electrode profile[18]. Standard posterior tympanotomy approach is applied for all cases. Intraoperative data is registered for impedance, electrically evoked stapedius reflex threshold (ESRT) level and neural response telemetry (NRT) values, with the software provided by the manufacturer (Custom Sound 5.0). The impedance level is measured in three stimulation modes [monopolar, bipolar, common ground (CG)]; thereafter, the stapedius reflex threshold on every fourth electrode

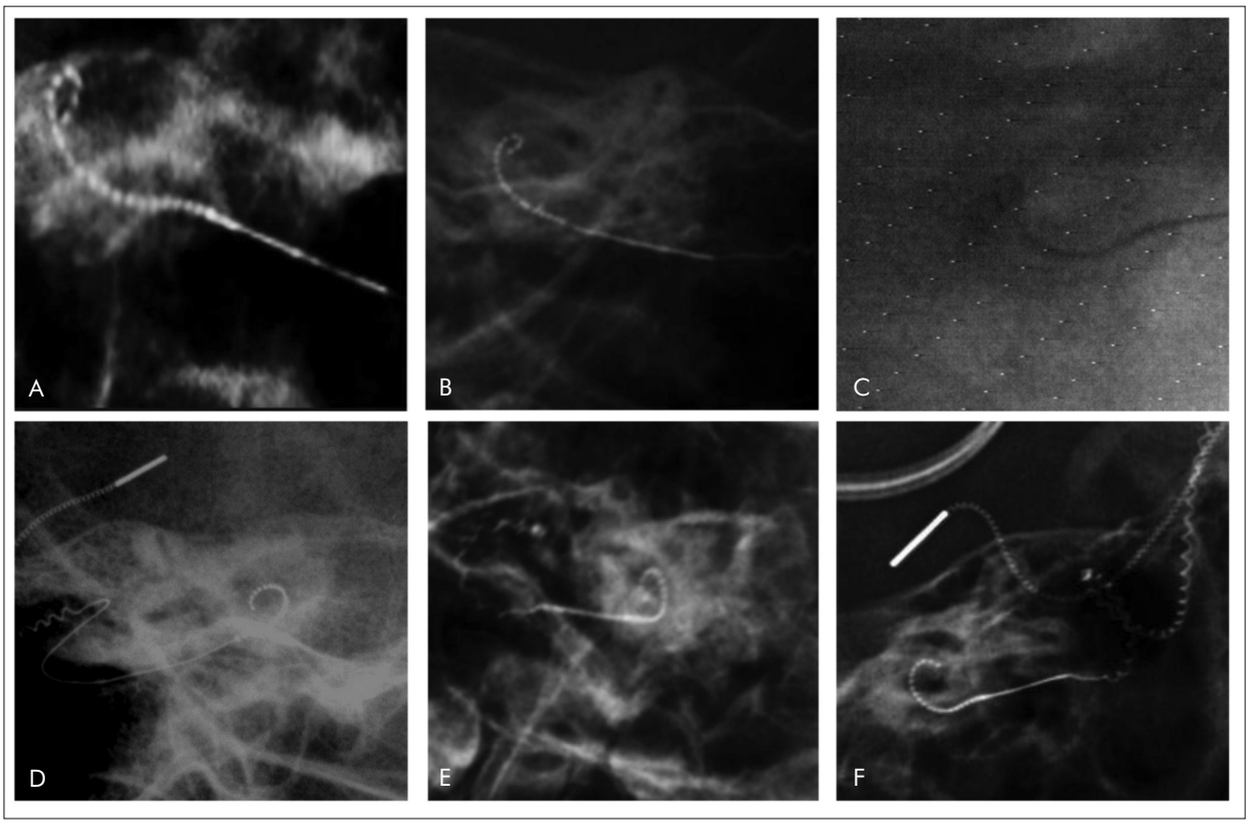

Figure 1. *Radiography of the three cases.* **A** *Subject #1, postoperative radiography, Stenvers view.* **B** *Subject #2, posteoperative radiography, Stenvers view.* **C** *Subject #3, postoperative fluoroscopy, cochlear view,* **D** *Subject #1, postoperative radiography after revision surgery, Stenvers view.* **E** *Subject #2, postoperative radiography after revision surgery, Stenvers view.* **F** *Subject #3, postoperative radiography after revision surgery, Stenvers view*

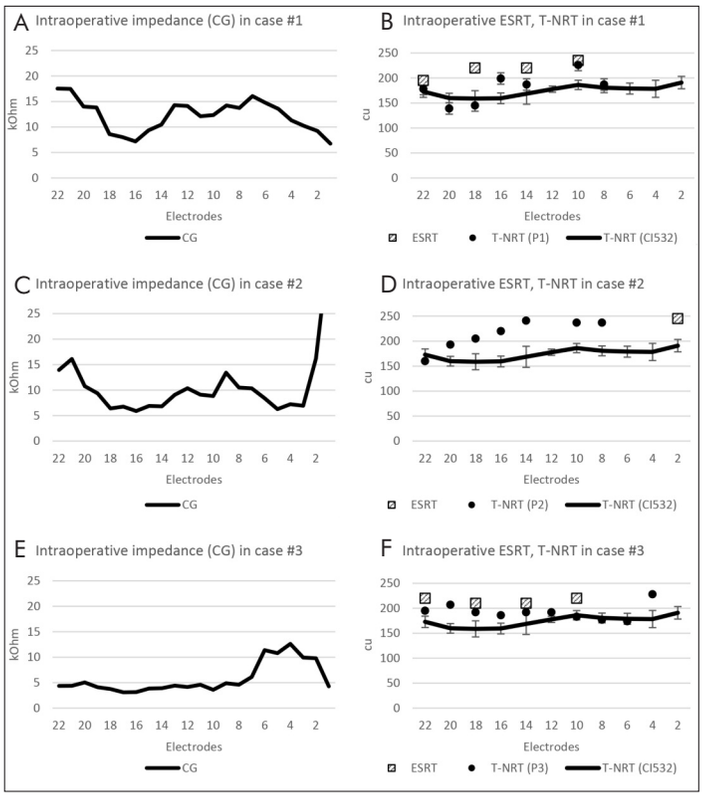

Figure 2. *Intraoperative tests.* **A** *Intraoperative impedance telemetry in CG stimulation mode in Subject#1.* **B** *Results of intraoperative stapedius reflex and nerve response telemetry in Subject#1. Based on clinical experience, none of the intraoperative studies showed any irregularities.* **C** *Intraoperative impedance telemetry in CG stimulation mode in Subject#2.* **D** *Results of intraoperative stapedius reflex and nerve response telemetry in Subject#2. With the exception of the fifth electrode, intraoperative stapedius reflex was not detected. NRT threshold (T-NRT) values were increased due to loss of the perilymph.* **E** *Intraoperative impedance telemetry in CG stimulation mode in Subject#3.* **F** *Results of intraoperative stapedial reflex and nerve response telemetry in Subject#3. Clinical results of intraoperative measurements showed no irregularities*

is tested. In this way, a properly sized current pulse strongly elicits the reflex. Following that, the current is reduced by 5 units until the stapedius reflex disappears. The threshold value is the last value where stapedius muscle contraction can still be visualized. The NRT is determined intraoperatively following insertion of the electrode array. To register the NRT values, the AutoNRT function of the software is used. The software sets – after manually entering patient-specific parameters – a start-up pulse level, raises it by 6 current units, triggers a clear nerve response and then decreases it automatically as long as the response is still a detectable electrically-evoked compound action potential (eCAP). Finally, on the first postoperative day, a standard radiographic examination of the head (antero-posterior and Stenvers view or fluoroscopy) is performed to document the electrode position.

Results

Ninety-four (94) CI recipients with pre- and postoperative CT scans and detailed operative reports were available for review for the period from November 2015 to July 2018. Out of these 94 cases, the active electrode was inserted into the cochlea via the extended round window approach in 91 ears. Three electrodes were inserted via cochleostomy because the round window could not be identified. Fifty-seven percent of the cases – 54 out of 94 – were right-sided CI.

Tip fold-over was noted in three cases (3.19%) **(Table 1)** on radiography, and will be discussed in more detail in the present study. **Table 1** summarizes the demographic and clinical characteristics of these subjects.

The postoperative radiography allowed identification of the electrode array within the cochlea **(Figure 1.D, 1.E, 1.F)**.

SUBJECT#1

A 60-year-old female subject with severe bilateral sensorineural hearing loss was referred for cochlear implantation of the right ear. The preoperative high-resolution CT scan and MRI revealed normal anatomy and no evidence of cochlear ossification or fibrosis. She had no history of meningitis. The round window niche was widened by drilling the bony rim over the round window to ensure good exposure of the membrane. There was no physical evidence during surgery to suggest the potential for intra-cochlear malposition of the electrode array, and the intraoperative tests (impedance, ESRT and NRT examinations) did not show any abnormality **(Figure 2.A, B)**. On the day after the implantation, a postoperative X-ray scan was performed **(Figure 1.A)**. With the help of the X-ray image, tip fold-over of the 18th electrode was detected. Unlike our standard protocol, the sound processor was programmed to the patient that day. The four apical electrodes that curved back were switched off so that the patient reported hearing sensations and the frequency discrimination was appropriate. The processor was programmed four weeks after the surgery again. At that time, the subject only reported whistling and beeping, but was unable to discriminate various frequencies. During the next two months, we were unable to produce a

hearing experience for the patient. Hence, we decided to reimplant the patient with a contour advanced (CI512) electrode from the same implant family.

SUBJECT#2

A 21-month-old girl with severe hair cell impairment - detected by distortion product brainstem evoked response audiometry (BERA), Auditory Steady State Response (ASSR) and otoacoustic emissions (DPOAEs), - was referred for bilateral cochlear implantation in June 2017. Genetic testing revealed mutation of the connexin 26 gene. Preoperative radiography and MRI scans revealed normal anatomy of the middle and inner ear. She had no history of bacterial meningitis. The round window was not detected on the right side; thus, cochleostomy insertion was performed. Unexpected oozing of the perilymph was noted. Accordingly, lower impedance **(Figure 2.C)** and higher NRT values were measured during the intraoperative evaluations **(Figure 2.D).** The ESRT, with the exception of electrode 5, could not be triggered. On the following day, a postoperative X-ray imaging **(Figure 1.B)** revealed tip fold-over at the 18th electrode. Our team decided to perform a revision surgery.

SUBJECT#3

A four-year-old male patient with severe bilateral sensorineural hearing loss was referred for sequential bilateral implantation. The first CI on the right side was performed without complication in September 2017; the surgery of the left side was performed in January 2018. Preoperative high-resolution CT and MRI scans showed regular anatomy of the middle and inner ear. He had no history of meningitis. The smooth contralateral insertion suggested the potential for a successful surgical insertion. The electrode array was gently inserted via the provided sheath through the round window using a soft-surgery technique. The surgeon reported some unusual resistance during the electrode insertion. The intraoperative tests did not show any abnormalities **(Figures 2.E, F)**. The following day, a tip fold-over was detected with X-ray imaging **(Figure 2.B)**.

SOLUTIONS

In the case of Subject #1, our team decided to implant a new device (CI512) with a more rigid and thicker electrode **(Figure 1.D)** because tip fold-over of the slim perimodiolar electrode may have indicated an obstruction in the membranous labyrinth - which the preoperative CT scan did not reveal. The speech processor was reprogrammed four weeks after the reimplantation **(Figure 3.A)**. Instead of the whistling and unpleasant sounds, the patient reported a good sound experience. As of this report, she successfully differentiates the sound spectrum and hears sounds in a corresponding tone **(Figure 3.B)**.

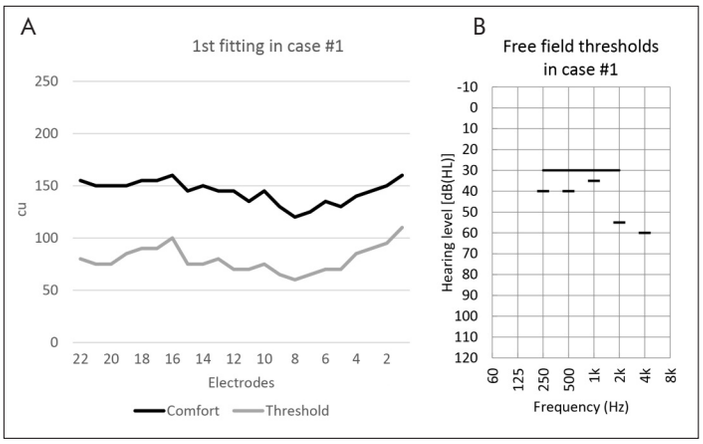

Figure 3. *Reimplantation results.* **A** *First fitting comfort (black line) and threshold (grey line) levels.* **B** *Free-field sound measurement results*

In the second and third cases, early reimplantation[19] was performed on the second postoperative day. The electrode array was gently removed from the cochlea and reinserted into a backup sheath **(Figure 4)** as used in our centre in these cases. Apart from its thin nature and proximity to the modiolus, another advantage of the slim perimodiolar electrode is that it can be reloaded into its external insertion sheath if necessary. Reinsertion was made in both pediatric cases. The intraoperative test results were normal **(Figure 5.A, B, C, D)**. The following day's postoperative X-ray images showed correct electrode location **(Figure 1.E, F)**. In both cases, we fitted the speech processor four weeks after the surgery. The pediatric patients also demonstrated good onset of speech perception with babbling and repetition of monosyllables. Speech development in Patient #2 successfully started con-

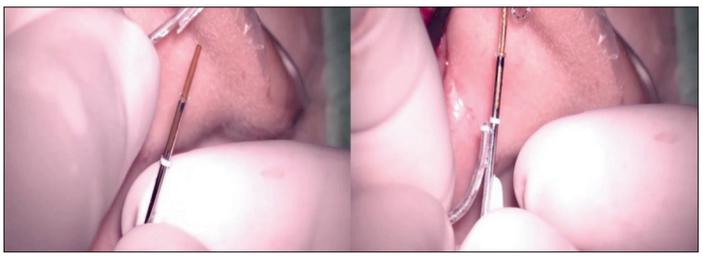

Figure 4. *Sheet re-loading in case #2 and revision surgery in case #3*

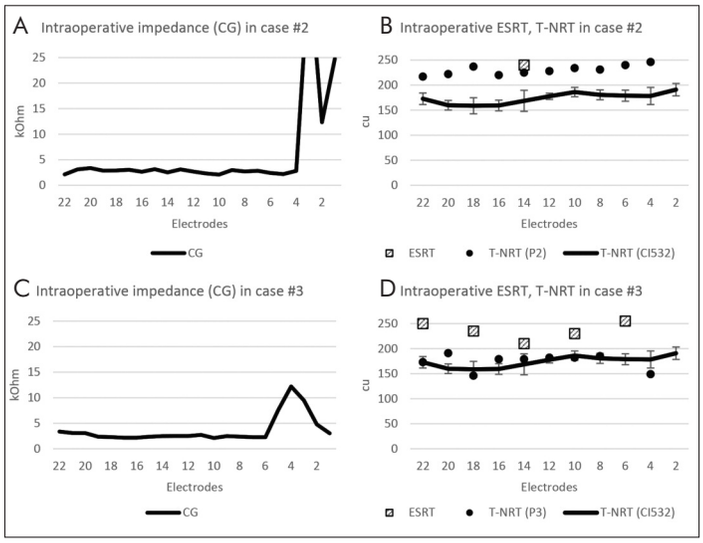

Figure 5. *Revision surgery's intraoperative tests in case #2 and case #3.* **A** *Intraoperative impedance telemetry in CG stimulation mode in case #2.* **B** *Subject#2: Results of intraoperative stapedius reflex and nerve response telemetry. With the exception of the 14th electrode, intraoperative stapedius reflex could not be triggered. Increased T-NRT values could be the result of oozing during the previous surgery.* **C** *Intraoperative impedance telemetry in CG stimulation mode in Subject#3.* **D** *Subject#3: Results of intraoperative stapedius reflex and nerve response telemetry. No irregularities occurred during the measurements*

sciously using disyllabic words one year later. Currently, her passive vocabulary is estimated at approximately 2-300 words. Patient #3 is a perilingual child. Her vocalization has started and, for the time being, she has been producing lallation/unarticulated sounds. She uses her speech processor three hours a day on average. She had not used a hearing aid before, which could possibly cause her dislike towards the speech processor.

Discussion

In our experience the CI532 with its Slim Modiolar electrode profile provides a relatively easy and low trauma insertion procedure. However, implantation of this delicate electrode array was associated with tip fold-over at a rate of 3.19% that is comparable with the reported rates found in the literature[9–12, 20], but immediate intraoperative identification based on tactile feedback of the operating surgeon and standard intraoperative telemetry failed. Radiography definitively detected tip fold-over[21]. Based on our experience and measurement results, we are unable to determine the exact location of electrode array along its full length. International literature provides reference to the use of Spread of Excitation measurements[22] to detect tip-fold-over. However, our department has not had the availability to perform such measurements yet.

Based on our clinical protocol, X-ray imaging is performed on the day after surgery. If the radiologist detects a suspected abnormality in the electrode position, fluoroscopy, cone-beam CT or low dose CT scans can be performed. Our recommendation is revision surgery, reloading the electrode array, if intact, into a backup insertion sheath and reinsertion of the array. In an ideal situation, abnormalities of the electrode position would be detected in real time or shortly after insertion in order to spare a second procedure. Reliable electrophysiological methods or real-time imaging in the operating room (cone-beam CT, fluoroscopy or X-ray imaging) are encouraged. It is important to put special emphasis on preoperative imaging and 3D reconstruction. The more frequent use of fine and pre-curved electrodes necessitates rigorous routine postoperative radiological control of electrode array position.

REFERENCES

1. *Dhanasingh A, Jolly C.* An overview of cochlear implant electrode array designs. Hear Res [Internet] 2017;356:93-103. https://doi.org/10.1016/j.heares.2017.10.005
2. *Nagy R.* Long-term Hearing Preservation with Slim Perimodiolar CI532® Cochlear Implant Array. Am J Otolaryngol Head Neck Surg [Internet] 2018;1(4):1019. https://doi.org/10.1016/j.otohns.2008.06.006
3. *Schieferbein V, Bredemann J, Schmitt R, Stenin I, Klenzner T, Schipper J, et al.* Influence of patient-specific anatomy on medical computed tomography and risk evaluation of minimally invasive surgery at the otobasis. Eur Arch Oto-Rhino-Laryngology [Internet] 2019;276(2):375-82. https://doi.org/10.1007/s00405-018-5249-0
4. *Jiam NT, Jiradejvong P, Pearl MS, Limb CJ.* The effect of round Windowvs cochleostomy surgical approaches on cochlear implant electrode position a flat-panel computed tomography study. JAMA Otolaryngol - Head Neck Surg 2016;142(9):873-80. https://doi.org/10.1001/jamaoto.2016.1512
5. *Nada I, Abdelhamid AN, Negm A.* The utilization of round window membrane surface tension in facilitating slim electrodes insertion during cochlear implantation. Eur Arch Oto-Rhino-Laryngology 2017;274(9):3327-34. https://doi.org/10.1007/s00405-017-4652-2
6. *Mirsalehi M, Rau TS, Harbach L, Hügl S, Mohebbi S, Lenarz T, et al.* Insertion forces and intracochlear trauma in temporal bone specimens implanted with a straight atraumatic electrode array. Eur Arch Oto-Rhino-Laryngology 2017;274(5):2131-40. https://doi.org/10.1007/s00405-017-4485-z

7. *Cuda D, Murri A*. Cochlear implantation with the nucleus slim modiolar electrode (CI532): a preliminary experience. Eur Arch Oto-Rhino-Laryngology [Internet] 2017;274(12): 4141-8. https://doi.org/10.1007/s00405-017-4774-6
8. *Marx M, Risi F, Escude B, Durmo I, James C, Lauwers F, et al*. Reliability of cone beam computed tomography in scalar localization of the electrode array: A radio histological study. Vol. 271, European archives of oto-rhino-laryngology: official journal of the European Federation of Oto-Rhino-Laryngological Societies (EUFOS): affiliated with the German Society for Oto-Rhino-Laryngology - Head and Neck Surgery 2013. https://doi.org/10.1007/s00405-013-2448-6
9. *Ramos-Macias A, R. De Miguel A, Falcon-González JC.* Mechanisms of electrode fold-over in cochlear implant surgery when using a flexible and slim perimodiolar electrode array. Acta Otolaryngol [Internet] 2017 Nov;137(11):1129-35. https://doi.org/10.1080/00016489.2016.1271449
10. *Aschendorff A, Briggs R, Brademann G, Helbig S, Hornung J, Lenarz T, et al*. Clinical investigation of the nucleus slim modiolar electrode. Audiol Neurotol 2017;22(3):169-79. https://doi.org/10.1159/000480345
11. *Zuniga MG, Rivas A, Hedley-Williams A, Gifford RH, Dwyer R, Dawant BM, et al.* Tip Fold-over in Cochlear Implantation. Otol Neurotol [Internet] 2017;38(2):199-206. https://doi.org/10.1097/mao.0000000000001283
12. *Sabban D, Parodi M, Blanchard M, Ettienne V, Rouillon I, Loundon N.* Intra-cochlear electrode tip fold-over. Cochlear Implants Int [Internet] 2018;19(4):225-9. https://doi.org/10.1080/14670100.2018.1427823
13. *McJunkin JL, Durakovic N, Herzog J, Buchman CA*. Early Outcomes with a Slim, Modiolar Cochlear Implant Electrode Array. Otol Neurotol 2018;39(1):e28-33. https://doi.org/10.1097/mao.0000000000001652
14. *Debeaupte M, Hermann R, Pialat J-B, Martinon A, Truy E, Ltaief Boudrigua A.* Cone beam versus multi-detector computed tomography for detecting hearing loss. Eur Arch Oto-Rhino-Laryngology [Internet] 2019;276(2):315-21. https://doi.org/10.1007/s00405-018-5214-y
15. *Connor SEJ, Dudau C, Pai I, Gaganasiou M.* Is CT or MRI the optimal imaging investigation for the diagnosis of large vestibular aqueduct syndrome and large endolymphatic sac anomaly? Eur Arch Oto-Rhino-Laryngology [Internet] 2019;276(3):693-702. https://doi.org/10.1007/s00405-019-05279-x
16. *Karkas A, Champfleur NM de, Uziel A, Mondain M, Puel J-L, Venail F*. Benefit of Preoperative Temporal Bone CT for Atraumatic Cochlear Implantation. Otol Neurotol Off Publ Am Otol Soc Am Neurotol Soc [and] Eur Acad Otol Neurotol 2018;39(3):e186-94. https://doi.org/10.1097/mao.0000000000001692
17. *Carlson ML, Driscoll CLW, Gifford RH, Service GJ, Tombers NM, Hughes-Borst BJ, et al*. Implications of minimizing trauma during conventional cochlear implantation. Otol Neurotol 2011;32(6):962-8. https://doi.org/10.1097/mao.0b013e3182204526
18. *Friedland DR, Runge-Samuelson C.* Soft cochlear implantation: rationale for the surgical approach. Trends Amplif 2009;13(2):124-38. https://doi.org/10.1177/1084713809336422
19. *Manrique-Huarte R, Huarte A, Manrique MJ*. Surgical findings and auditory performance after cochlear implant revision surgery. Eur Arch Oto-Rhino-Laryngology 2016;273 (3):621-9. https://doi.org/10.1007/s00405-015-3610-0
20. *Trakimas DR, Kozin ED, Ghanad I, Barber SR, Curtin H, Remenschneider AK*. Precurved cochlear implants and tip foldover: A cadaveric imaging study. Otolaryngol - Head Neck Surg (United States) 2018;158(2):343-9. https://doi.org/10.1177/0194599817738978
21. *Ramos de Miguel Á, Argudo AA, Borkoski Barreiro SA, Falcón González JC, Ramos MA*. Imaging evaluation of electrode placement and effect on electrode discrimination on different cochlear implant electrode arrays. Eur Arch Oto-Rhino-Laryngology [Internet] 2018;275(6):1385-94. https://doi.org/10.1007/s00405-018-4943-2
22. *Grolman W, Maat A, Verdam F, Simis Y, Carelsen B, Freling N, et al*. Spread of excitation measurements for the detection of electrode array foldovers: A prospective study comparing 3-dimensional rotational x-ray and intraoperative spread of excitation measurements. Otol Neurotol 2009;30(1):27-33. https://doi.org/10.1097/mao.0b013e31818f57ab

II.

Perenyi et al. Journal of Otolaryngology - Head and Neck Surgery (2019) 48:46
https://doi.org/10.1186/s40463-019-0361-8

Journal of Otolaryngology - Head & Neck Surgery

ORIGINAL RESEARCH ARTICLE Open Access

Electrophysiological measurements with electrode types of different perimodiolar properties and the same cochlear implant electronics – a retrospective comparison study

A. Perenyi[1*†], F. Toth[1†], B. Dimak[1], R. Nagy[1], P. Schoerg[2], J. Jori[1], J. G. Kiss[1], G. Sprinzl[2], M. Csanady[1] and L. Rovo[1]

Keywords: Cochlear implant, CI532, CI512, CI522, Electrode array, Perimodiolar, Electrophysiology

Introduction

There are currently different trends in cochlear implant electrode design [1]. The manufacturers provide a variety of implant configurations including different receiver-stimulators, electrode arrays (e.g. straight or precurved, full-length or short) and sound processors to choose from, which can facilitate decision making on an individual basis. Proximity to the modiolus [2, 3], electrical current requirements [4], energy consumption, trauma to the cochlea [5], combined electro-acoustic stimulation [6, 7]), preservation of cochlear structures with low-trauma surgical technique [3, 8–10] and hearing preservation [11–14] are important aspects of implant design which have become the focus of many discussions and studies.

For example, recent evidence suggests that speech discrimination is not improved by deep insertion, but it is significantly improved by perimodiolar position of the electrode [15].

Studies in implanted recipient groups using multiple implant types make it difficult to compare the influence of the implant electrode characteristics on outcomes in the presence of additional variables such as implant electronics, sound processors and speech coding paradigms. Hence, to reduce the number of variables, comparison of the influence of electrode designs on outcomes could be interpreted more effectively if a consistent receiver-stimulator design and a common sound processor are used. Recent publications [16–20] represent imaging and electrophysiological results with CI532, but no comparative studies have yet been published.

Our center's postoperative radiological comparative study demonstrated that the Slim Modilar electrode array took a closer position to the modiolus than the Contour Advance electrode array [21].

As a consequence, the authors' aim in this multicenter study that is to their knowledge the first with this focus was to compare the influence of various electrode designs upon selected electrophysiological outcomes for cochlear implant recipients using the same model of receiver-stimulator, Cochlear™ Nucleus® Profile Series and sound processor in a retrospective study.

Materials and methods

Inclusion and allocation of subjects

A total of 139 consecutive subjects who were implanted between 13 June 2014 and 4 May 2017 with a Profile CI532 (CI532), a Profile CI512 (CI512), and a Profile CI522 (CI522) device manufactured by Cochlear Ltd., Australia and gave their informed consent were recruited to this retrospective study from two tertiary referral implant centers. Time periods of the study recruitment were from 13 June 2014 to 14 December 2015 for CI512, from 13 November 2015 to 4 May 2017 for CI532and 11 March 2015 to 29 November 2016 for CI522. All subjects were examined with high resolution computed tomography

* Correspondence: perenyi.adam@med.u-szeged.hu
†Perenyi A and Tóth F contributed equally thus, both of them are shared first authors
[1]Department of Otorhinolaryngology, Head and Neck Surgery, University of Szeged, Tisza Lajos krt. 111, Szeged H-6725, Hungary
Full list of author information is available at the end of the article

and/or magnetic resonance imaging before surgery. Exclusion criteria were cochlear malformations, cochlear otosclerosis, obliterative postmeningitis changes and electrode tip foldover. To the authors knowledge there were no neural disorders in either group. Postoperative radiography was performed in each subject to confirm that the active electrode occupied an intracochlear position with no complications or abnormal electrode position.

The subjects were allocated into groups based on the electrode type implanted as shown in Table 1. Those who received a CI532 formed group 532, those who received a CI512 formed group 512, and those who received a CI522 formed group 522. Subjects were consecutively treated as part of routine clinical practice that was comparable at each respective implant site.

- A total of 159 ears in 139 subjects were implanted with devices, including the same implant receiver-stimulator electronics. CI532 had a 22 electrode array which was perimodiolar and with a relatively smaller diameter (named Slim Modiolar), CI512 had a 22 electrode array which was perimodiolar with a relatively larger diameter (named Contour Advance), and CI522 had a 22 electrode array which was straight, also with a relatively small diameter (named Slim Straight). A total of 54 ears were implanted with CI532 (all in Clinic 1), 54 ears with CI512 (51 in Clinic 1 and 3 in Clinic 2), and 51 ears with CI522 (47 in Clinic 2 and 4 in Clinic 1). Patients who were implanted with CI532 formed the test group. Two control groups were formed from patients who were implanted with Implants 512 and 522. The underlying causes of hearing loss were congenital, progressive, unknown and others (e.g. choesteatoma, infection, Meniere's disease, meningitis, ototoxic drugs, sudden hearing loss, trauma) in 29, 22, 16, and 33% for group 532, 28, 26, 28, and 17% for group 512, and 17, 23, 35, and 25% for group 522, respectively.

Implantation technique

The electrode arrays were inserted into the cochlea according to the manufacturer's instructions provided in the physician's surgical guide. The method of electrode insertion was identical in both implant clinics [22]. Full insertion was achieved via the extended round window approach with CI532 and CI512 and via the round window approach with CI522 in all ears. The AOS (advance off-stylet) technique was used for CI512 and the free-hand technique was used for CI522. Electrode choice was dependent on the actual implant pool of each center (regulated by the health authorities). The age of the patients did not influence implant choice. Discussion of hearing preservation was not an objective of this study.

Electrophysiological testing

The three different types of electrode arrays were compared with regards to outcomes from intraoperative and 3-months postoperative electrophysiological testing performed as per routine clinical protocol (Table 2).

Intraoperative electrophysiological tests were carried out as part of the regular fittings with Nucleus Custom Sound 4.4 software: Impedance was measured for each electrode, the electrical stapedial reflex threshold (ESRT) with 25 μs pulse width for every second electrode contact (No. 2, 4, 6 etc.) and neural response telemetry threshold (T-NRT) for 6 (No. 2, 6, 10, 14, 18 and 22) electrode contacts. ESRT values were compared in

Table 1 Subject demographics for each subject group. Note: For continuous variables, the mean and + 1 standard deviation are shown in brackets

Subject group	532	512	522
Device	CI532	CI512	CI522
Electrode type	Slim modiolar	Contour advance	Slim straight
Number of patients	46	45	48
Number of ears	54	54	51
Age (year)	25.17±26.29	20.80±25.87	55.36±28.59
Sex (male/female)	25/29	23/31	33/18
Duration of deafness (year)	2.94±7,46	3.06±9.34	3.13±12.99
Cause of deafness			
Congenital	29%	28%	17%
Progressive	22%,	26%	23%
Unknown	16%	28%	35%
Others	33%	17%	25%

Table 2 Summary of the intraoperative and postoperative evaluation protocols and available data sets for each type of electrode. The routine protocol in Clinic 2 did not include measurement of intraoperative ESRT, and postoperative T-NRT

	Group 532 Nucleus CI532 (n/54 implants)	Group 512 Nucleus CI512 (n/54 implants)	Group 522 Nucleus CI522 (n/51 implants)
intraoperative ESRT	44	47	0
intraoperative T-NRT	50	47	43
postoperative C-level (1 month)	54	54	51
postoperative C-level (3 month)	54	54	51
postoperative T-NRT (3 month)	32	36	0

groups 532 and 512. T-NRT values in group 532 were compared with those in both control groups. A common sound processor (Nucleus CP910) was used.

The centers followed their normal routine protocol, thus the electrophysiological measurement protocol of the two centers was not identical, i.e. intraoperative ESRT testing, postoperative T-NRT measurements were not included in the routine protocol by Clinic 2, and thus CI522 was not analyzed with regards to these parameters. Furthermore, postoperative NRT was not measured for subjects in each group, where the current required to elicit a threshold response exceeded their discomfort or pain level.

The first fitting was performed 4 weeks after surgery in each case. In order to determine the electric threshold (T-levels), and comfort threshold (C-levels), the subjective fitting method was used in adults and the semi-objective NRT based fitting (based on the intraoperative T-NRT results) was applied in children [23, 24]. Default MAP parameters (25 μs pulse width, 900 Hz stimulation rate and 8 maxima) were used. Postoperative NRT was measured 2 months after the first fitting, i.e. 3-months follow-up. C-levels at first fitting and 3-months follow-up fitting and T-NRT at 3-months follow-up were compared.

Outcomes for precurved slim perimodiolar electrode design, used at one implant clinic were compared to outcomes for two control groups of recipients implanted with precurved perimodiolar and straight electrodes in both implant clinics. Electrode designs were compared on the basis of outcomes for intraoperative objective electrophysiological measures and postoperative threshold levels and comfort levels to characterize electrode position within the cochlea.

Statistical analysis

Statistical analysis with the Student's t-test ($P < 0.05$) and one-way repeated measures ANOVA test were performed with 95% confidence interval ($p < 0.05$). Before the calculation, tests for normality of data distribution were performed. Bonferroni correction was used as needed to consider multiple variables (e.g. comparison of all three implant groups). The comparison was made on each electrode and all of the electrodes (Grand average). The tests were performed with Microsoft Excel 2016 and SPSS for Windows.

Results

All subjects received Nucleus Profile implants. The only difference was the type of electrode. The patient groups were similar in subject numbers, etiology and duration of deafness, and indications.

Electrophysiology testing

Intraoperative measurements

Firstly, intraoperative electrical stapedial reflex threshold (ESRT, Fig. 1) and Neural Response Telemetry (T-NRT, Fig. 2), results were compared across implant groups. A stapedial reflex was tested in all subjects in group 532 and 512 and could be elicited in 44 out of 54 cases in group 532 and in 47 out of 54 cases in the control group (group 512). Figure 3 shows that the mean ESRTs were lower in group 532 than in group 512. This difference

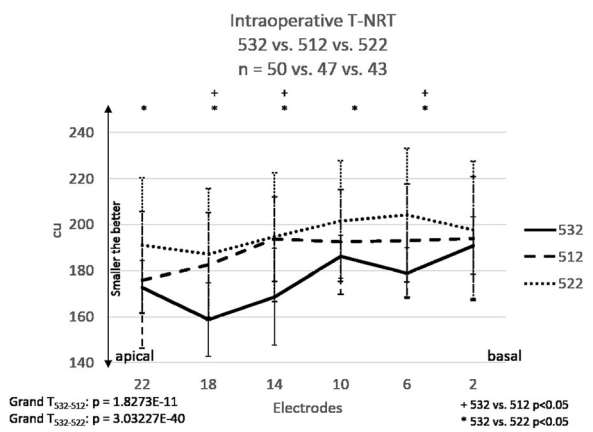

Fig. 1 Intraoperative T-NRT values in all groups: Groups 532 ($n = 50$), 512 ($n = 47$) and 522 ($n = 43$). The "+" stands for significant difference between groups 532 and 512. The "*" represents a significant difference between groups 532 and 522. Error bars represent the standard deviation (SD). The mean NRTs proved to be lower in each electrode in group 532 when compared with both control groups. The difference was significant in 5 measured electrodes when compared with 522 and 3 measured electrodes when compared with 532 (t-probe: $p < 0.05$). Grand $T_{532–512}$ means statistical comparison between groups 532 and 512. Grand $T_{532–522}$ means statistical comparison between groups 532 and 522

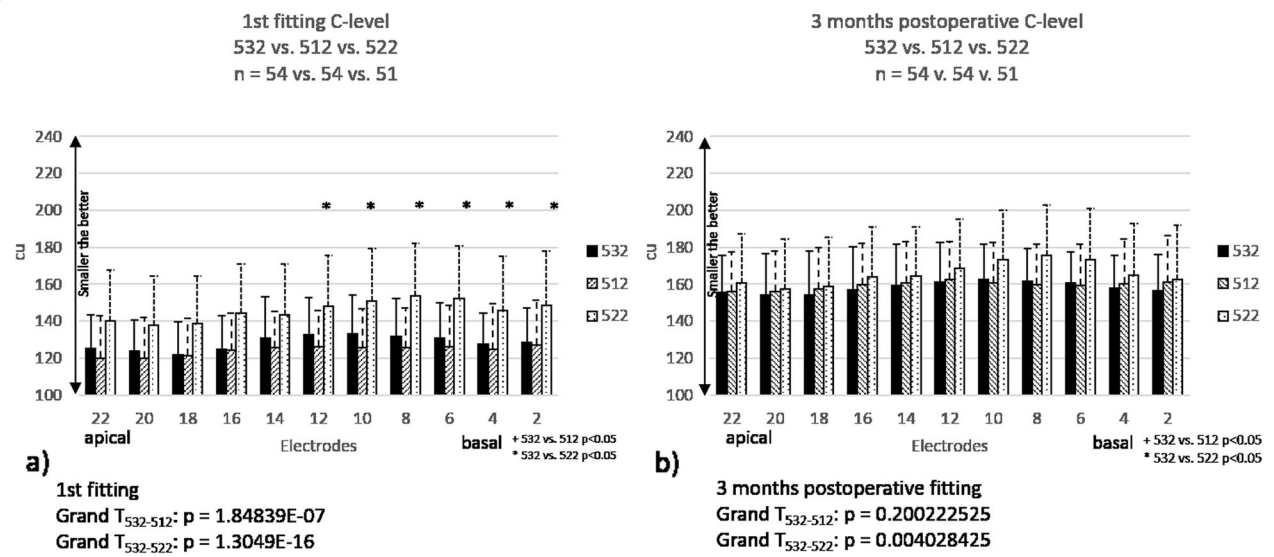

Fig. 2 The mean postoperative C-levels in patient groups with different types of CI: Group 532 ($n = 54$, $n = 54$), group 512 ($n = 54$, $n = 54$) and group 522 ($n = 51$, $n = 51$) at first fitting (**a**) and 2-month follow-up fitting (**b**). The "*" stands for a significant difference between groups 532 and 522. Error bars represent the standard deviation (SD). Grand $T_{532-512}$ means statistical comparison between groups 532 and 512. Grand $T_{532-512}$ means statistical comparison between groups 532 and 522

was significant (t probe: $p = 0.007$) for electrode contact 2. Grand average (all electrodes) statistic calculation (Grand $T_{532-512}$) showed significant differences between groups 532 and 512 ($p < 0.05$).

Intraoperative NRT measurements were performed in all three groups. The neural response threshold was tested in all subjects and could be elicited in 50 out of 54 (group 532), 47 out of 54 (group 512), and 43 out of 51 (group 522) cases. Repeated ANOVA analysis revealed significant difference $p < 0.05$) between the three groups. On examining the significance in pairs, we found that the mean T-NRTs (Fig. 2) proved to be lower in each electrode in group 532 when compared with each control group. The difference was significant in 5 measured electrode contacts when compared with CI522 and 3 measured electrode contacts when compared with CI512 (t-probe: $p < 0.05$). Grand average (all electrodes) statistic calculation (Grand $T_{532-512}$ and Grand $T_{532-522}$) showed significant lower T-NRT values in group 532 compared with the two control groups ($p < 0.05$).

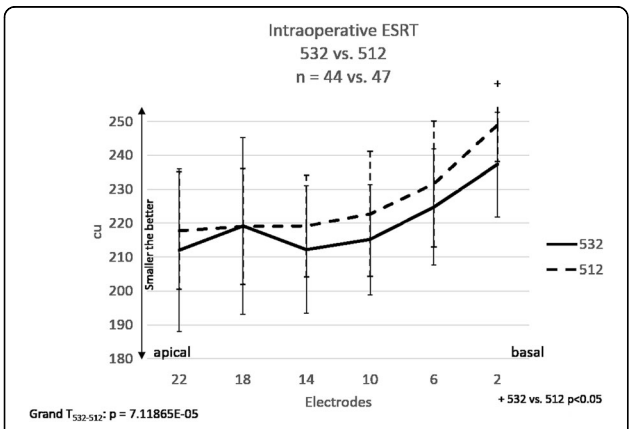

Fig. 3 The mean intraoperative ESRT values in patient groups with different types of CIs: group 532 ($n = 44$) and group 512 ($n = 47$). The "+" means a significant difference between groups (**a**) and (**b**). Error bars stand for the standard deviation (SD). „A" stands for Nucleus CI532 and „B" for Nucleus CI512 implants. Grand $T_{532-512}$ means statistical comparison between groups 532 and 512

Postoperative C-levels

The subjects were scheduled for the first fitting 4 weeks after surgery. C-levels during the first fitting were compared in patient groups with different implants (Fig. 4). No significant difference in mean C-levels was seen on any electrodes between groups 532 and 512, but grand average (all electrodes) statistic calculation (Grand $T_{532-512}$) showed significant differences between the two groups ($p < 0.05$). C-levels were considerably higher on every electrodes in group 522 compared to groups 532 and 512, and the difference was significant for apical electrodes 2 to 12 ($p < 0.05$, Fig. 4)a. Grand average (all electrodes) statistic calculation (Grand $T_{532-522}$) showed significant differences between the groups ($p < 0.05$). However, no significant difference was present on any electrodes in C-levels 2 months after the first fitting, only the grand average statistical analysis (Grand $T_{532-522}$) showed significant differences between groups 532 and 522 (Fig. 4)b.

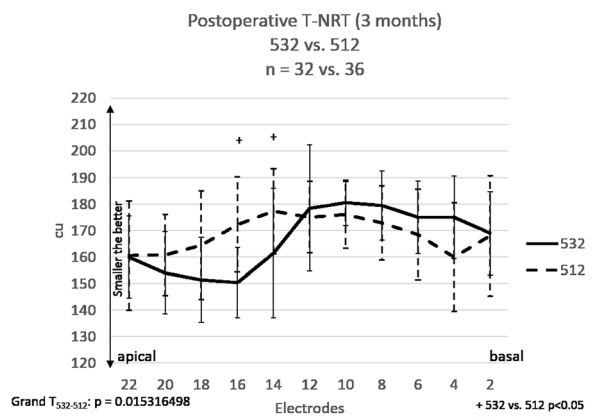

Fig. 4 The mean postoperative T-NRT values in subject groups with CI532 ($n = 32$) and CI512 ($n = 36$). The „+" represents a significant difference between groups 532 and 512. Error bars represent the standard deviation (SD). Grand $T_{532–512}$ means statistical comparison between groups 532 and 512

Postoperative T-NRT

In group 532 and 512, T-NRT measurements were attempted in all subjects at the two-month follow up fitting and the measurements were successfully carried out in 32 subjects in group 532 and 36 subjects in group 512. The intraoperative electrophysiological measurements could be performed in all subjects under general anesthesia, whereas the postoperative measurements were performed in vigil subjects. In the latter case, some of the subjects complained about unpleasant sound volume before a neural response could have been measured, for this reason the electrophysiological testing cannot be performed.

Figure 4 shows the postoperative mean T-NRT values. The mean T-NRT results in the basal section were lower in group 532 than in group 512. The difference was significant ($p < 0.05$) on two electrodes (No 14 and No 16). Grand average (all electrodes) statistic calculation (Grand $T_{532–512}$) showed significant differences between the groups ($p < 0.05$).

Discussion

A wide range of cochlear implants with different electrodes are available for rehabilitation of hearing impaired patients with severe to profound sensorineural hearing loss. Hearing rehabilitation outcomes may be influenced by optimizing device and electrode choice for the individual. Several comparative studies have been conducted including electrophysiological (ESRT, NRT) test methods to evaluate the influence of straight and perimodiolar electrode designs and their in-situ characteristics on clinical outcomes [1–3, 25–27]. Our study is unique in that it measured the influence of various electrode designs combined with a common receiver-stimulator upon electrophysiological assessments for a relatively large routinely treated multicenter study cohort. As such, it is the first study to report on the influence of electrode design while using consistent implant receiver-stimulator electronics. The cooperation of the two clinics was established in 2017 with the aim to compare the perimodiolar and the straight electrode arrays. The study clinics followed a standard protocol enabled by the manufacturer's software, thus a conclusion from their individual results can be made. The results of Hey et al. from their multicenter study on CI532 are in good correlation with our results which proves that our methodology and results are reliable [20].

The Contour Electrode was the first perimodiolar electrode from Cochlear. As reported by researchers, some intracochlear trauma has been associated with its insertion, with a more reliable and less traumatic insertion achieved when deployed using the recommended advance off-Stylet technique [3]. This is largely due to an inherent reduction in intracochlear outer wall force generation when using this technique for this electrode [3].

The Slim Modiolar Electrode is designed for insertion with minimal cochlear trauma. It has the advantage of taking 60% less volume in the scala tympani compared to the Contour Advance Electrode and is therefore placed in a position close to the modiolus. Perimodiolar proximity is an important clinical consideration as Holden et al. [15] concluded, observing that total insertion depth was not associated with better speech discrimination outcomes, however, the distance from the electrodes to the modiolus did indicate a significant influence. The Slim Modiolar electrode array takes a closer position to the modiolus than the Contour Advance electrode array as confirmed by a comparative radiological evaluation [21].

In this retrospective study the data from recipients with the three main types of electrode arrays used in each of the two author implant centers were included. Although the electrode of CI522 was known to take the lateral wall position within the cochlea, the authors' decided to enroll those subjects who were implanted with CI522 to gain a more detailed overview. Although results of two different implant centers were combined for evaluation, upon review, the authors considered the routine clinical practices employed and device parameters used at each site as sufficiently comparable.

Results from the objective intraoperative measurements indicated that the electrode contacts of the CI532 array were located closer to the modiolus than those of CI512. A previous study found that withdrawal of the stylet in the Contour Advance Electrode resulted in better NRT and ESRT responses, than with the stylet in place. They concluded that this is most probably due to a more favorable position of the electrode array towards the modiolus within the scala tympani once the stylet is removed [26].

In our study, although the mean ESRT was only slightly lower with CI532, the difference was statistically significant at the basal most electrodes tested. However, the mean T-NRT for CI532 was significantly lower than for CI512, especially in the apical-middle section, which is considered to be indicative of closer positioning towards the modiolus. An expected rate of scalar dislocations could be 26% with precurved electrode (i.e. CI512) and 3% with straight electrode (i.e. CI522) with round window insertion technique [28] and this dislocation should have a significant impact on the NRT threshold in the apical part of the electrode. In order to minimize scalar dislocation, the extended round window insertion technique was used. Although the institutional protocols did not include postoperative computed tomography, the results from T-NRT and ESRT, both being constantly higher for CI512 when compared with CI532 and T-NRT being constantly lower for CI512 when compared with CI522 are not indicative of significant dislocations between scalae tympani and vestibuli. The sizeable reduction in both T-NRT and ESRT observed in our study are considered sufficiently large to potentially influence differences in clinical outcomes as observed for subjective comfort level [26, 29].

The surface area of an electrode is inversely proportional with the resistance, thus current is proportional with the surface area. If the electrode with a smaller surface is capable of eliciting the same response it means that it is closer to the stimulated structure. The lower objective electrophysiological thresholds of CI532 suggest that the electrodes are capable of eliciting reflex responses with lower stimulation intensity, resulting from closer proximity to the modiolus.

Conclusion

Although the Slim Modiolar electrode is significantly thinner than the Contour Advance and similar sized as the Slim Straight electrode array, the Slim Modiolar electrode provides similar or better stimulation productivity compared to Contour Advance and Slim Straight electrodes. The manufacturer's thinnest electrode array, the Slim Modiolar Electrode takes the position that is closer to the modiolus compared to the Contour Advance Electrode and the Slim Straight Electrode. Our intraoperative and postoperative measurements confirmed this showing that more effective stimulation can be achieved, through the use of the Slim Modiolar Electrode.

Abbreviations

ANOVA: Analysis of variance; C-level: Comfort threshold; ESRT: Electrically evokedstapedial reflex threshold; NRT: Neural response telemetry; T-level: Electric threshold; T-NRT: Neural response telemetry threshold

Acknowledgements

The authors wish to express their gratitude for their colleagues for their professional and patient support.

Availability of data and material

Please contact the corresponding author for data requests.

Authors' contributions

All authors read and approved the final manuscript. AP: designed and performed experiments, analyzed data at both centers and wrote the paper. FT: designed and performed experiments, analyzed data at both centers and wrote the paper. AP and FT contributed equally to this work, thus both of them are shared first authors. BD performed experiments at the center in Hungary, provided statistical analysis and wrote the paper. RN performed experiments at the center in Hungary and provided analysis. PS: performed experiments at the center in Austria. JJ: performed experiments at the center in Hungary. JGK collected and analyzed data from the center in Hungary and provided critical revision. GS performed experiments at the center in Austria and provided critical revision. MC: proofread the manuscript. LR designed the study, performed experiments at the center in Hungary and wrote the paper.

Authors' information

AP: ENT specialist and radiology resident, PhD, member of the Hungarian Society of Oto-Rhino-Laryngology, Head & Neck Surgery; FT: clinical physicist, doctor of the theoretical medical science; BD: info-bionic engineer; RN: info-bionic engineer; PS: clinical engineer; JJ: ENT and Audiology specialist, PhD, member of the Hungarian Society of Oto-Rhino-Laryngology, Head & Neck Surgery. JGK: Physicist, audiologist. PhD, Chair of the Hungarian Society of Audiology, Member of the Hungarian Society of Oto-Rhino-Laryngology, Head & Neck Surgery; GS: ENT, Audiology, Laryngology specialist. PhD. Head of department. MC: ENT, Audiology, Laryngology specialist. PhD. Deputy head of department. LR: ENT, Audiology, Laryngology specialist. PhD. Head of department. Chair of the Hungarian Society of Oto-Rhino-Laryngology, Head & Neck Surgery. Member of the Hungarian Society of Phonetics, Phoniatry and Speech Therapy. Faculty member of the European Laryngological Society.

Funding

The authors declare that they have no financial interest and received no funding. The research was not sponsored by any company.

Ethics approval and consent to participate

The protocol of the investigation was approved by the Institutional Review Board (Human Investigation Review Board, University of Szeged, Albert Szent-Györgyi Clinical Center. Reference number: 38/2014), and the investigators obtained written informed consent from each participant or each participant's guardian. All procedures performed in studies involving human participants were in accordance with the ethical standards of the institutional and/or national research committee and with the 1964 Helsinki declaration and its later amendments or comparable ethical standards.

Consent for publication

not applicable.

Competing interests

The authors declare that they have no competing interests.

Author details

[1]Department of Otorhinolaryngology, Head and Neck Surgery, University of Szeged, Tisza Lajos krt. 111, Szeged H-6725, Hungary. [2]Karl Landsteiner University Hospital of StPölten, Propst-Führer-Straße 4, 3100 St. Pölten, Austria.

Received: 14 August 2018 Accepted: 20 August 2019
Published online: 06 September 2019

References

1. O'Connell BP, Hunter JB, Gifford RH, Rivas A, Haynes DS, Noble JH, et al. Electrode location and Audiologic performance after Cochlear implantation: a comparative study between nucleus CI422 and CI512 electrode arrays. Otol Neurotol. 2016;37:1032–5.
2. Tykocinski M, Cohen LT, Pyman BC, Roland T Jr, Treaba C, Palamara J, et al. Comparison of electrode position in the human cochlea using various perimodiolar electrode arrays. Am J Otol. 2000;21:205–11.

3. Roland JT Jr. A model for cochlear implant electrode insertion and force evaluation: results with a new electrode design and insertion technique. Laryngoscope. 2005;115:1325–39.
4. Wackym PA, Firszt JB, Gaggl W, Runge-Samuelson CL, Reeder RM. Raulie JC Electrophysiologic effects of placing cochlear implant electrodes in a perimodiolar position in young children. Laryngoscope. 2004;114:71–6.
5. Roland PS, Wright CG. Surgical aspects of Cochlear implantation: mechanisms of insertional trauma. Adv Adv Otorhinolaryngol. 2006;64:11–30.
6. Von Ilberg C, Kiefer J, Tillein J, Pfenningdorff T, Hartmann R, Stürzebecher E, et al. Electric-acoustic stimulation of the auditory system. New technology for severe hearing loss. ORL J Otorhinolaryngol Relat Spec. 1999;61:334–40.
7. Gantz BJ, Turner C, Gfeller KE, Lowder MW. Preservation of hearing in cochlear implant surgery: advantages of combined electrical and acoustical speech processing. Laryngoscope. 2005;115:796–802.
8. Skarzynski H, Matusiak M, Lorens A, Furmanek M, Pilka A, Skarzynski PH. Preservation of cochlear structures and hearing when using the nucleus slim straight (CI422) electrode in children. J Laryngol Otol. 2016;130:332–9.
9. Eshraghi AA. Prevention of cochlear implant electrode damage. Curr Opin Otolaryngol Head Neck Surg. 2006;14:323–8.
10. Adunka OF, Pillsbury HC, Kiefer J. Combining perimodiolar electrode placement and atraumatic insertion properties in cochlear implantation fact or fantasy? Acta Otolaryngol. 2006;126:475–82.
11. Fraysse B, Macias AR, Sterkers O, Burdo S, Ramsden R, Deguine O, et al. Residual hearing conservation and electroacoustic stimulation with the nucleus 24 contour advance cochlear implant. Otol Neurotol. 2006;27:624–33.
12. Huarte RM, Roland JT Jr. Toward hearing preservation in cochlear implant surgery. Curr Opin Otolaryngol Head Neck Surg. 2014;22:349–52.
13. Van Abel KM, Dunn CC, Sladen DP, Oleson JJ, Beatty CW, Neff BA, et al. Hearing preservation among patients undergoing cochlear implantation. Otol Neurotol. 2015;36:416–21.
14. Bento RF, Danieli F, Magalhaes AT, Gnansia D, Hoen M. Residual hearing preservation with the EVO® Cochlear implant electrode array: preliminary results. Int Arch Otorhinolaryngol. 2016;20:353–8.
15. Holden LK, Finley CC, Firszt JB, Holden TA, Brenner C, Potts LG, et al. Factors affecting open-set word recognition in adults with cochlear implants. Ear Hear. 2013;34:342–60.
16. Aschendorff A, Briggs R, Brademann G, Helbig S, Hornung J, Lenarz T, et al. Clinical investigation of the nucleus slim Modiolar electrode. Audiol Neurootol. 2017;22:169–79.
17. Cuda D, Murri A. Cochlear implantation with the nucleus slim modiolar electrode (CI532): a preliminary experience. Eur Arch Otorhinolaryngol. 2017; 274:4141–8.
18. Ramos-Macias AR, De Miguel A, Falcon-González JC. Mechanisms of electrode fold-over in cochlear implant surgery when using a flexible and slim perimodiolar electrode array. Acta Otolaryngol. 2017;137:1129–35.
19. McJunkin JL, Durakovic N, Herzog J, Buchman CA. Early outcomes with a slim, Modiolar Cochlear implant electrode Array. Otol Neurotol. 2018;39:28–33.
20. Hey M, Wesarg T, Mewes A, Helbig S, Hornung J, Lenarz T, et al. Objective, audiological and quality of life measures with the CI532 slim modiolar electrode. Cochlear Implants Int. 2018;20:80–90.
21. Perényi Á, Jóri J, Csanády M, Rovó L. Dimensions of the human temporal bone that are relevant to cochlear implantation surgery in infants and toddlers –A clinical-radiological study. [Az emberi halántékcsont csecsemő- és kisgyermekkori cochleáris implantáció szempontjából releváns dimenziói – Klinikoradiológiai vizsgálat] Accepted for publication in Orv Hetil, 2019.
22. Nagy R, Jarabin JA, Dimák B, Perényi Á, Tóth F, Szűts V, et al. Possibilities for residual hearing preservation with nucleus CI532 slim Modiolar electrode array. Case report. Orv Hetil. 2018;159:1680–8.
23. Kiss JG, Toth F, Nagy A, Jarabin J, Szamoskozi A, Torkos A, et al. Neural response telemetry in cochlear implant users. Int Tinnitus J. 2003;9:59–60.
24. Cafarelli Dees D, Dillier N, Lai WK, Von Wallenberg E, van Dijk B, et al. Normative findings of electrically evoked compound action potential measurements using the neural response telemetry of the nucleus CI24M cochlear implant system. Audiol Neurootol. 2005;10:105–16. https://doi.org/10.1159/000083366.
25. Baysal E, Karatas E, Deniz M, Baglam T, Durucu C, Karatas ZA, et al. Intra- and postoperative electrically evoked stapedius reflex thresholds in children with cochlear implants. Int J Pediatr Otorhinolaryngol. 2012;76:649–52.
26. Rajati M, Ghassemi MM, Bakhshaee M, Tale MR, Tayarani H. Effect of stylet removal on neural response telemetry and stapedial reflex thresholds during cochlear implantation. Auris Nasus Larynx. 2014;41:255–8.
27. Müller A, Hocke T, Mir-Salim P. Intraoperative findings on ECAP-measurement: normal or special case? Int J Audiol. 2015;54:257–64.
28. Boyer E, Karkas A, Attye A, Lefournier V, Escude B, Schmerber S. Scalar localization by cone-beam computed tomography of cochlear implant carriers: a comparative study between straight and periomodiolar precurved electrode arrays. Otol Neurotol. 2015;36:422–9.
29. Mittmann P, Todt I, Ernst A, Rademacher G, Mutze S, Göricke S, et al. Electrophysiological detection of scalar changing perimodiolar cochlear electrode arrays: a long term follow-up study. Eur Arch Otorhinolaryngol. 2016;273:4251–6.

Publisher's Note

III.

American Journal of Otolaryngology and Head and Neck Surgery

Research Article
Published: 21 Sep, 2018

Long-term Hearing Preservation with Slim Perimodiolar CI532® Cochlear Implant Array

Roland Nagy, János András Jarabin, Ádám Perényi, Balázs Dimák, Ferenc Tóth, József Jóri, József Géza Kiss and László Rovó*

Department of Otorhinolaryngology, Head and Neck Surgery, University of Szeged, Hungary

Abstract

By using sophisticated surgical techniques in combination with the Slim Perimodiolar cochlear implant electrode array a hitherto unattained high rate of residual hearing preservation in cochlear implantation has been observed that makes potential for electric acoustic stimulation. One of the primary aims of cochlear implant system engineering is to promote atraumatic electrode insertion to maintain optimal postoperative hearing sensitivity by protecting and preserving the delicate inner ear structures.

The study aimed to collect pre-, and postoperative audiological and surgical results from the experience gained from the applied cochlear implant configuration.

About 30 patients (aged 43.32 ± 24 years) with partial hearing loss were supplied with this atraumatic perimodiolar thin electrode which was designed to preserve residual hearing despite intracochlear insertion of an electrode array. All patients were implanted with consentaneous CI system and surgery technique.

The use of new electrode array profiles in cochlear implantation plays a fundamental role in minimally invasive soft surgery, taking into individual needs, and providing long-term acoustic hearing preservation. Hearing preservation was achieved in most cases (partial residual hearing preservation) after a long-term follow-up period (preoperation, at least one year).

Keywords: Cochlear implantation; Hearing preservation; Soft surgery; Perimodiolar electrode profile

OPEN ACCESS

Correspondence:
Roland Nagy, Department of Otorhinolaryngology, Head and Neck Surgery, University of Szeged, H-6725 Szeged, Tisza Lajos krt. 111, Hungary, Tel: +3662 545310; +3630 4089088; Fax: +3662 545848;
E-mail: nagy.roland@med.u-szeged.hu

Received Date: *14 Aug 2018*
Accepted Date*: 18 Sep 2018*
Published Date*: 21 Sep 2018*

Citation:
Nagy R, Jarabin JA, Perényi Á, Dimák B, Tóth F, Jóri J, et al. Long-term Hearing Preservation with Slim Perimodiolar CI532® Cochlear Implant Array. Am J Otolaryngol Head Neck Surg. 2018; 1(4): 1019.

Introduction

Competing companies (Advanced Bionics, Cochlear, Med-El and Oticon, etc.) provide different types of receiver-stimulators, implant electrodes and speech processors. There are several pros and cons when opting for an electrode profile (straight or perimodiolar), cochlear coverage (total or partial), receiver-stimulator (physical attributes) and speech processor (electric or electroacoustic stimulation), that meet the individual needs. One of the primary aims of cochlear implant system engineering is to promote atraumatic electrode insertion to maintain optimal postoperative hearing sensitivity by protecting and preserving the delicate inner ear structures.

Residual hearing sensitivity may deteriorate due to perioperative traumas or complications with delayed onset. The applied surgical approach (Round Window (RW), Extended Round Window (ERW), Cochleostomy (CS)) and the implanted electrode profile mainly lead to immediate or short-term damage, while delayed alteration in cochlear function usually derives from the fibrous or bony remodelling of the endocochlear compartments.

Surgically important properties are the physical attributes of the electrode configuration (perimodiolar vs. straight; rounded vs. smoothened tip; short vs. regular; with or without stylet, etc.), the type of cochlear fenestration (RW, ERW, CS), the method of electrode insertion (standard vs. soft surgery with advance-off-stylet), the use of lubricants or drugs in the cochlea (e.g. intrascalar corticosteroids) and the intrascalar position of the electrode array (perimodiolar, mid-scala, lateral-wall) [1-3].

However, the possible disproportion between the physical dimensions of the electrode profile and the endocochlear compartments (diameter, shape, length of scala tympani) play a significant role in preserving inner ear structures and functions, too.

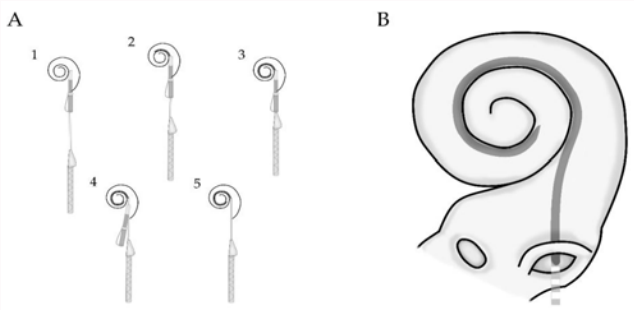

Figure 1: (A) A traumatic electrode insertion in optimal position with the reloadable sheath. (B) Slim, perimodiolar electrode configuration with total cochlear coverage.

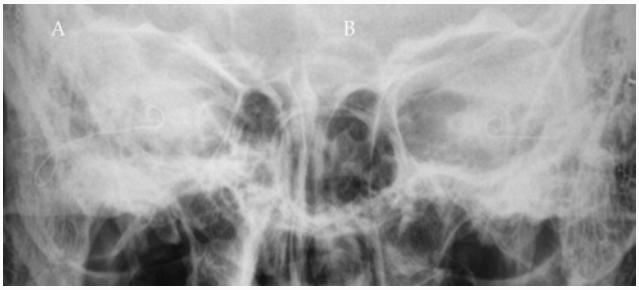

Figure 2: Skull AP axial on the first postoperative day that confirms the proper in situ electrode position. The depicted subject (not included into the present study due to completely missing preoperative hearing) was chosen to interpret the differences between sequentially implanted systems (**A**: right ear: CI512 Contour Advanced; **B**: left ear: CI532 Slim Perimodiolar). A decreased electrode array curvature is seen with the slim perimodiolar system (B).

Minimizing the damage in the inner ear enhances the possibility for hearing preservation, thus leading to better hearing performance. Systemic and/or intratympanic administration of steroids may contribute to hearing preservation. The beneficial effects of glucocorticoids are thought to be mediated through several different pathways: the anti-inflammatory effects; the down-regulation of production of inducible nitric-oxide synthase; and direct inhibition of the MAP/JNK cell death signal cascade [2-5].

We aimed to study long-term hearing preservation in a non-randomized, prospective clinical cohort with cochlear implant systems, limited to ones produced by Australian and Austrian leader companies, provided and fully financed by the Hungarian National Health Insurance.

Materials and Methods

Study cohort

Out of the total number of cochlear implantees with slim perimodiolar implant system (n=94) our study population was recruited on the basis of the following criteria: (1) patient with good compliance; (2) measureable preoperative hearing threshold; (3) slim perimodiolar electrode array implant system; (4) minimum one-year follow-up period. Thirty consecutive subjects were enrolled into this prospective, non-randomized clinical study. Twenty females and ten males with mean age at implantation of 43.32 years, ranged between 10 years to 77 years. All subjects were implanted at the University of Szeged from 2015 until 2017. The postoperative follow-up duration lasted 1.72 years at average (ranged between 1.1 and 2.55 years). All

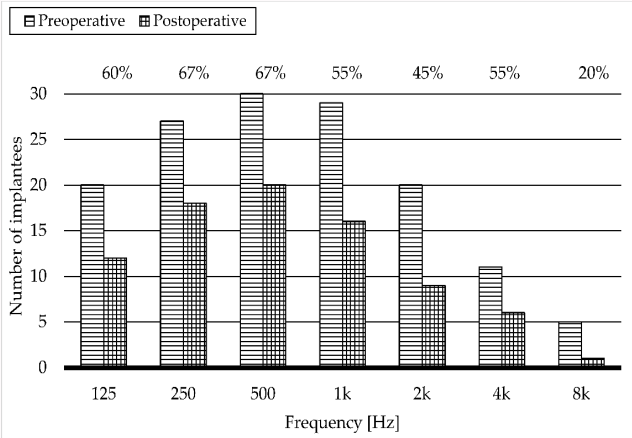

Figure 3: Number of implantees with measurable hearing threshold at different frequencies. Preoperative (striped pattern columns); postoperative (checked pattern columns). On the top horizontal axis, the frequency-specific success rate of hearing preservation is showed in percentages.

subjects met the official indication criteria of Cochlear Implantation (CI). Anatomical / structural malformation was not revealed by the preoperative radiological examinations. For detailed patient data, please see Table 1.

Implant configuration

The studied cochlear implant system has a slim, full-length perimodiolar electrode (Figure 1). The thin implant body has no pedestal and it is designed to minimize bone excavation and skin protrusion. At the implant coil the implant measures 3.7 mm and the implant main body measures 3.9 mm in thickness. The side-by-side symmetrical shape makes the implantation easier for the surgeon. The titanium casing has been used for high impact resistance, and the smooth external geometry to minimize biofilm formation, that reduces the risk of infection. The 98 mm total length of electrode array helps to insert it in a better position, but the main handle assist tool is the reloadable sheath for the smooth electrode insertion. The thin electrode array allows unobstructed access to the scala tympani that has a tip diameter of 0.35 × 0.4 mm and 0.45 × 0.5 mm at the base. At the last edge of the electrode array there are three white marker rings for controlling the insertion depth that are followed by 22 half banded platinum electrode contacts. These properties make this implant configuration easier to use with shorter incision and surgery time. The insertion assistant sheath platform and the physical attributes of the electrode array facilitate to proximate the modiolus and thus prevent the electrode from dislocation into the scalae media or vestibuli [6-8].

Surgical technique

Preserving the residual hearing requires minimally invasive techniques of (1) cochlear fenestration, (2) management of endocochlear fluid compartments and (3) atraumatic electrode insertion, known as soft surgery. Thinner and atraumatic electrode arrays are also designed to accomplish these aims, as postoperative hearing performance can be maximized by minimizing the insertion trauma [3,8-11].

Several important factors contribute to intracochlear damage during implantation: (1) direct physical trauma, (2) pressure wave propagation in the perilymphatic fluid, (3) vibration and/or heat trauma from drilling, (4) loss of perilymph, (5) changes

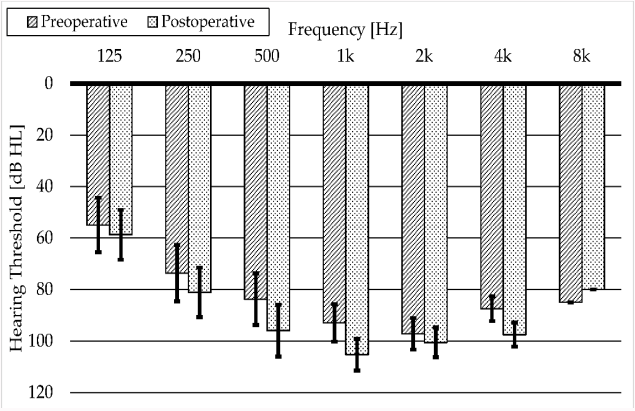

Figure 4: Preoperative (striped pattern columns) and postoperative (dotted pattern columns) hearing thresholds in dBHL at the measured frequencies (*p<0.05).

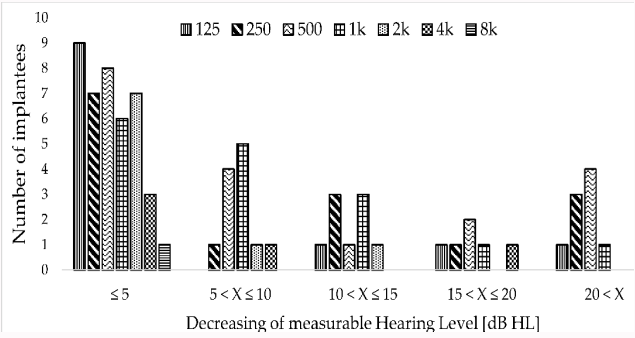

Figure 5: Loss of acoustic sensitivity interpreted in dBHL ranges, while exhibiting the number of implantees frequency-specifically (with different patterns of columns).

in homeosthasis/hydrodynamics of the endocochlear fluid compartments, (6) delayed fibrotic alteration and new bone formation within the cochlear lumen [3,12-16].

The physical attributes (length and diameter) of the electrode array may each limit the postoperatively achieved residual hearing [17].

Comprehensive analysis of imaging diagnostics of the middle and inner ear provide indispensable information for planning the proper surgical access route and electrode [17,18].

Soft surgery

The term soft surgery was introduced by Lehnhardt in 1993 and it provided basis for numerous publications [9,19].

Our routinely applied minimally invasive surgical technique involved electrode insertion *via* the Round Window (RW). In order to reduce bleeding and to prevent blood from accessing the cochlea, we filled the tympanic cavity with adrenaline solution after having the posterior tympanotomy been completed. To prevent bone fragments entering the cochlea, the tympanic and mastoid cavity were flushed with abundant amount of saline. To remove the bony overhang of the round window, we used a 1 mm diamond burr at low speed (max. 350 rpm) in order to avoid noise and heat injury. We opened the RW membrane with a microscopic needle or hook. After opening the inner ear, suction was applied with care in order to avoid reducing the amount of perilymph. Furthermore, the scala tympani was left

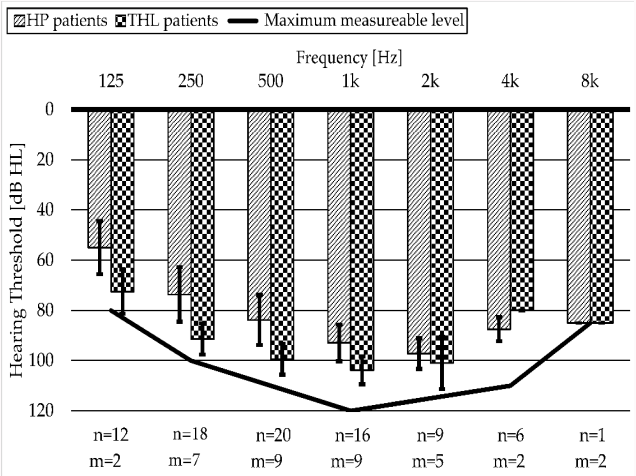

Figure 6: Preoperative threshold of HP (striped pattern columns, n=number of patients) and THL (squared pattern columns, m=number of patients) patients (Continuous line measureable threshold level).

open for the shortest possible period, to prevent bone fragments, blood or other substances entering the inner ear, which might have been sources of primary and/or secondary injuries that finally would lead to loss of residual hearing. As a sort of prevention, after having opened the RW, we placed a piece of gel-foam soaked in corticosteroid solution into the RW niche.

The slim modiolar electrode of the CI532 implant was soaked into methylprednisolone solution (40 mg powder dissolved in 10 ml saline) and it was retracted into the insertion sheath. The insertion sheath together with the electrode array was inserted into the scala tympani with the lowest possible force. Any minute resistance felt by the surgeon would have indicated physical contact of the electrode array to the basilar membrane or the lateral wall of the scala tympani or stria vascularis and possible injury of these structures. After the electrode had been inserted in full length, indicated by the 1st marker ring, the RW was immediately sealed with an autologous tissue (e.g. fascia or muscle) in order to prevent loss of perilymph [9].

Radiological validation

Radiography (skull AP axial/Towne view) was performed on the first postoperative day to confirm the proper intracochlear electrode position (Figure 2).

Pure-tone audiometry

Pure-tone air-conduction thresholds were used to register residual hearing with the ascending method, with 5 dBHL intensity steps. The audiometer (GSI 61 Clinical Audiometer; Grason-Stadler, MN USA) was calibrated according to the standards of the International Organization for Standardization (ISO 389-1:2017). THD-50P (Telephonics Corporation/Griffon Company, NY USA) headphone was used for air conduction hearing measurements.

Results

Pre- and postoperative pure tone hearing threshold measurements were completed for all the 30 recruited subjects. Figure 3 frequency-dependently illustrates the number of patients pre- and postoperatively, where hearing sensitivity was measurable. It is well demonstrated that hearing is the most stable within the 250 to 1000 Hz range, and the least is beyond 4 kHz. This statement is true either pre-, or postoperatively.

Table 1: Population of study patients.

No.	Gender	Age (year)	Implanted ear	Hearing Loss w/wo genetic origin	Total Hearing Loss (THL) after implantation
1	Male	55	Left	No	No
2	Male	59	Left	Yes	Yes
3	Male	16	Right	No	No
4	Male	24	Right	No	No
5	Male	15	Left	No	Yes
6	Male	72	Right	No	No
7	Female	70	Right	No	No
8	Female	71	Left	No	No
9	Female	10	Right	Yes	Yes
10	Male	11	Right	No	No
11	Female	43	Left	Yes	Yes
12	Female	28	Right	No	No
13	Female	28	Left	No	No
14	Female	11	Right	No	No
15	Female	70	Right	No	No
16	Female	24	Right	No	No
17	Male	62	Right	No	No
18	Female	77	Right	No	No
19	Female	42	Right	No	No
20	Female	48	Right	No	Yes
21	Female	71	Left	No	No
22	Female	53	Right	No	Yes
23	Female	59	Right	No	No
24	Male	13	Right	No	No
25	Female	27	Right	No	No
26	Female	35	Left	No	Yes
27	Female	59	Left	No	No
28	Female	30	Right	No	No
29	Male	53	Right	No	No
30	Male	69	Right	No	Yes
Average	Male=10 Female=20	(Mean ± SD) 43.32 ± 24	Right=21 Left=9	Genetic disorder=3 No evidence=27	THL=7

The average preoperative thresholds of the hearing within the lower frequency range were 61.75 dBHL at 125 Hz (no response from 10 patients); 78.52 dBHL at 250 Hz (no response from 3 patients). At the middle frequency range, mean values were 88.67 dBHL at 500 Hz (response from all patients); 97.07 dBHL at 1 kHz (no response from 1 patient) and 100.50 dBHL at 2 kHz (no response from 10 patients). At the higher frequencies, the average values were 91.36 dBHL at 4 kHz (no response from 19 patients) and 84.00 dBHL at 8 kHz (no response from 25 patients).

The difference in height between the striped and checked pattern columns represents the percentage of successful hearing preservation at specific frequencies.

One year postoperatively the average values of the hearing thresholds at the lower frequency range were: 93.89 dBHL at 125 Hz (no response from 17 patients); 87.86 dBHL at 250 Hz (no response from 10 patients). At the middle frequencies mean values were 102.86 dBHL at 500 Hz (no response from 10 patients); 111.61 dBHL at 1 kHz (no response from 14 patients) and 113.75 dBHL at 2 kHz (no response from 21 patients). At the higher frequencies, average values were 115.18 dBHL at 4 kHz (no response from 24 patients) and 99.29 dBHL at 8 kHz (no response from 29 patients).

Figure 4 illustrates the preoperative (striped pattern columns) and the postoperative (dotted pattern columns) hearing thresholds in dBHL at the measured frequencies. Decrease was detected at each examined frequencies but the grade of it varied. The highest decrease was measured at 500 Hz with an average decrease of 14.19 dBHL and at 1000 Hz with an average decrease of 13.77 dBHL. At the lower frequency range, hearing remained substantially stable. At 125 Hz only 3.06 dBHL, while at 250 Hz only 7.19 dBHL loss was detected. At the high frequencies, from 2 to 8 kHz preoperative hearing sensitivity had been already proved to be rather poor, thus further loss had just little consequences.

Figure 5 frequency-specifically demonstrates the degree of loss of acoustic sensitivity grouped into dBHL ranges, while exhibiting the

number of implantees. It is clearly shown that only minute threshold decay with less than 5 dBHL loss is the most frequently found one, while prominent postoperative loss of hearing appears less often.

Subjects with complete loss of hearing following surgery

Nine implantees (9/30=30%) showed up with total loss of residual hearing at every measured frequency following surgery. Their preoperative hearing sensitivity is presented in Figure 6. It is clearly seen that within this subgroup of this cohort the measured average hearing threshold have been already poorer prior to surgery compared to those with preserved hearing. Genetic screening of the 30 recruited subjects revealed mutations in three cases in the background of hearing loss. All of these subjects suffered complete hearing loss postoperatively (3/3=100%), that genetic alteration may serve as a predictor when opting for an electro-acoustic/hybrid device, should be taken into consideration when indicating these systems [20].

Discussion

Preservation of acoustic hearing associated with cochlear implantation improves the postoperatively achievable periodicity and spectral resolution, which improves the patient's speech comprehension and the localization of the tone in particularly difficult conditions [21-26].

The effects of cochlear implantation on residual hearing have been discussed in several studies in which a number of surgical and technical factors have been identified [27]. There are some surgical techniques of approaching the scala tympani (*i.e.,* RW, ERW, CS) with varying risks of harming the fine structures of the cochlea with prompt or delayed onset [13]. Such late complications, like the appearance of endocochlear connective tissue or new bone formation, may lead to a gradual partial or complete loss of residual acoustic hearing [28]. This is most likely to be seen when the round window is extendedly exposed, where endothelial lesions trigger new tissue proliferation. The slightest is the tendency to harm the endocochlear structures when minimally invasive, soft surgery is applied [13].

Physical attributes of the electrode profile may also interfere with postoperative cochlear function. Theoretically, the endocochlear hydrodynamics may also be altered, as the vibration of the basilar membrane is restricted due to the presence of an electrode array. At this point, as the travelling waves to the apical region are modified, the basilar membrane would react to sounds differently, leading to an endocochlear "conductive" hearing loss [29, 30].

The new type of thin-diameter electrode arrays close to the modiolus are expected to have a lower hydrodynamic load, since the bony spiral lamina is attached from below, thus the basilar membrane vibrations remain unrestricted. However, the perimodiolar position of the electrode array allows the adjacent nerve elements of the spiral ganglion to be stimulated with a lower electrical intensity and through a smaller surface.

Cadaver experiments demonstrated that a force, applied to the basilar membrane with an average of 88 mN (42 mN to 122 mN) would be sufficient to accomplish the interscalar dislocation of the electrode, of which manual perceptibility is questionable [31]. Studies with large case numbers (n=100) have shown that the probability of the electrode line being located in the scala vestibuli significantly increased during CS, which also manifested itself in the absence of improvement in speech comprehension [32].

In a number of studies, intraoperatively performed electrocochleography is used to track the electrode insertional trauma, furthermore to postoperative residual hearing follow-ups [33-35].

For the implementation of Electro-Acoustic (EAS) or hybrid speech processors the long-term preservation of residual acoustic hearing is inherently inevitable, thus application of atraumatic surgical techniques and electrode arrays is essential.

Our study cohort obviously demonstrates that by the application of appropriate soft surgery techniques and atraumatic electrodes are able to retain residual hearing on a long run. The positive experience gained with the new type of CI532 Slim Modiolar electrode predicts the possibility for the preservation of structural and functional integrity of all cochlear regions. Furthermore, a prompt, definitive solution could be provided for a possible late hearing loss progression, where only a psychophysical reprogramming of the implant would be enough.

On the basis of our results, if the acoustic hearing loss can be preserved with the assurance and efficacy of the initial experience, we will be able to provide sustained prominent hearing rehabilitation even in the indication of EAS that results in significant improvement in the life quality of many implantees.

In addition, long-term residual hearing loss may be of crucial importance in the subsequent feasibility of regenerative procedures and medical treatments [3,7,36,37].

Conclusion

In cochlear implantation, the use of new electrode array profiles plays a fundamental role in minimally invasive soft surgery, taking into individual needs, and providing long-term acoustic hearing preservation. Our study demonstrates the efficacy of the Nucleus CI532 Slim Modiolar electrode profile and it has the potential for granting residual hearing, which predicts the possible use of this configuration as part of EAS systems and makes it available for future treatments, *i.e.,* the regeneration-based new therapeutic approaches of intracochlear hair-cells.

References

1. Mistrík P, Jolly C. Optimal electrode length to match patient specific cochlear anatomy. Eur Ann Otorhinolaryngol Head Neck Dis. 2016;133:S68-71.
2. Jolly C, Garnham C, Mirzadeh H, Truy E, Martini A, Kiefer J, et al. Electrode features for hearing preservation and drug delivery strategies. Cochlear Implants Hearing Preservation. 2010;67:28-42.
3. Nagy R, Jarabin JA, Dimák B, Perényi A, Tóth F, Szuts V, et al. Possibilities for residual hearing preservation with Nucleus CI532 Slim Modiolar electrode array – case report. Orvosi Hetilap.
4. Lyu AR, Kim DH, Lee SH, Shin DS, Shin SA, Park YH. Effects of dexamethasone on intracochlear inflammation and residual hearing after cochleostomy: A comparison of administration routes. PLoS One. 2018;13(3):e0195230.
5. Zine A, van de Water TR. The MAPK/JNK signalling pathway offers potential therapeutic targets for the prevention of acquired deafness. Curr Drug Targets CNS Neurol Disord. 2004;3(4):325-32.
6. McJunkin JL, Durakovic N, Herzog J, Buchman CA. Early Outcomes With a Slim, Modiolar Cochlear Implant Electrode Array. Otol Neurotol. 2018;39(1):e28-e33.
7. Cuda D, Murri A. Cochlear implantation with the nucleus slim

modiolar electrode (CI532): a preliminary experience. Eur Arch Otorhinolaryngology. 2017;274(12):4141-8.

8. Ramos-Macías A, Borkoski-Barreiro SA, Falcón-González JC, Ramos-de Miguel A. Hearing Preservation with the Slim Modiolar Electrode Nucleus CI532® Cochlear Implant: A Preliminary Experience. Audiol Neurootol. 2017;22(6):317-25.

9. Friedland DR, Runge-Samuelson C. Soft Cochlear Implantation: Rationale for the Surgical Approach. Trends Amplif. 2009;13(2):124-38.

10. Cohen NL. Cochlear implant soft surgery: fact or fantasy? Otolaryngol Head Neck Surg. 1997;117(3):214-6.

11. Carlson ML, Driscoll CL, Gifford RH, Service GJ, Tombers NM, Hughes-Borst BJ, et al. Implications of minimizing trauma during conventional cochlear implantation. Otol Neurotol. 2011;32(6):962-8.

12. Adunka O, Unkelbach MH, Mack M, Hambek M, Gstoettner W, Kiefer J. Cochlear implantation via the round window membrane minimizes trauma to cochlear structures: A histologically controlled insertion study. Acta Otolaryngol. 2004;124(7):807-12.

13. Richard C, Fayad JN, Doherty J, Linthicum FH. Round window versus cochleostomy technique in cochlear implantation: Histologic findings. Otol Neurotol. 2012;33(7):1181-7.

14. Jiam NT, Limb CJ. The impact of round window vs cochleostomy surgical approaches on interscalar excursions in the cochlea: Preliminary results from a flat-panel computed tomography study. World J Otorhinolaryngol Head Neck Surg. 2016;2(3):142-7.

15. Khater A, El-Anwar MW. Methods of Hearing Preservation during Cochlear Implantation. Int Arch Otorhinolaryngol. 2017;21(3):297-301.

16. Koch RW, Ladak HM, Elfarnawany M, et al. Measuring Cochlear Duct Length - a historical analysis of methods and results. J Otolaryngol Head Neck Surg. 2017;46(1):19.

17. Karkas A, Champfleur NM, Uziel A, Mondain M, et al. Benefit of Preoperative Temporal Bone CT for Atraumatic Cochlear Implantation. Otol Neurotol. 2018;39(3):e186-e194.

18. Perényi Á, Bella Zs, Baráth Z, Magyar P, Nagy K, Rovó L. [Role of cone-beam computed tomography in diagnostic otorhinolaryngological imaging]. Orv Hetil. 2016;157(2):52-8.

19. Lehnhardt E. [Intracochlear placement of cochlear implant electrodes in soft surgery technique]. HNO. 1993;41(7):356-9.

20. Szüts V, Jarabin JA, Nagy N, Ötvös F, Nagy R, Nagy A, et al. Altered potassium ion homeostasis in hearing loss. In: Shad Kaneez F, editor. Ion Channel. London: IntechOpen.

21. Dunn CC, Perreau A, Gantz B, Tyler RS. Benefits of Localization and Speech Perception with Multiple Noise Sources in Listeners with a Short-Electrode Cochlear Implant. J Am Acad Audiol. 2010;21(1):44-51.

22. Gifford RH, Dorman MF, Skarzynski H, Lorens A, Polak M, Driscoll CL, et al. Cochlear implantation with hearing preservation yields significant benefit for speech recognition in complex listening environments. Ear Hear. 2013;34(4):413-25.

23. Gifford RH, Driscoll CLW, Davis TJ, Fiebig P, Micco A, Dorman MF. A Within-Subject Comparison of Bimodal Hearing, Bilateral Cochlear Implantation, and Bilateral Cochlear Implantation with Bilateral Hearing Preservation: High-Performing Patients. Otol Neurotol. 2015;36(8):1331-7.

24. Gifford RH, Grantham DW, Sheffield SW, Davis TJ, Dwyer R, Dorman MF. Localization and interaural time difference (ITD) thresholds for cochlear implant recipients with preserved acoustic hearing in the implanted ear. Hear Res. 2014;312:28-37.

25. Loiselle LH, Dorman MF, Yost WA, Cook SJ, Gifford RH. Using ILD or ITD Cues for Sound Source Localization and Speech Understanding in a Complex Listening Environment by Listeners With Bilateral and With Hearing-Preservation Cochlear Implants. J Speech Lang Hear Res. 2016;59(4):810-8.

26. Loiselle LH, Dorman MF, Yost WA, Gifford RH. Sound source localization by hearing preservation patients with and without symmetric, low-frequency acoustic hearing. Audiol Neurootol. 2015;20(3):167-71.

27. Sweeney AD, Hunter JB, Carlson ML, Rivas A, Bennett ML, Gifford RH, et al. Durability of Hearing Preservation after Cochlear Implantation with Conventional-Length Electrodes and Scala Tympani Insertion. Otolaryngol Head Neck Surg. 2016;154(5):907-13.

28. Fayad JN, Makarem AO, Linthicum FH. Histopathologic assessment of fibrosis and new bone formation in implanted human temporal bones using 3D reconstruction. Otolaryngol Head Neck Surg. 2009;141(2):247-52.

29. Banakis Hartl RM, Mattingly JK, Greene NT, Jenkins HA, Cass SP, Tollin DJ. A preliminary investigation of the air-bone gap: Changes in intracochlear sound pressure with air- and bone-conducted stimuli after cochlear implantation. Otol Neurotol. 2016;37(9):1291-9.

30. Chole RA, Hullar TE, Potts LG. Conductive Component After Cochlear Implantation in Patients With Residual Hearing Conservation. Am J Audiol. 2014;23(4):359-64.

31. Schuster D, Kratchman LB, Labadie RF. Characterization of intracochlear rupture forces in fresh human cadaveric cochleae. Otol Neurotol. 2015;36(4):657-61.

32. Wanna GB, Noble JH, Carlson ML, Gifford RH, Dietrich MS, Haynes DS, et al. Impact of electrode design and surgical approach on scalar location and cochlear implant outcomes. Laryngoscope. 2014;124:S1-7.

33. O'Connell BP, Hunter JB, Wanna GB. The importance of electrode location in cochlear implantation. Laryngoscope Investig Otolaryngol. 2016;1(6):169-74.

34. Koka K, Litvak LM. Feasibility of using electrocochleography for objective estimation of electro-acoustic interactions in cochlear implant recipients with residual hearing. Front Neurosci. 2017;11:337.

35. Dalbert A, Pfiffner F, Hoesli M, Koka K, Veraguth D, Roosli C, et al. Assessment of cochlear function during cochlear implantation by extra- and intracochlear electrocochleography. Front Neurosci. 2018;12:18.

36. Plontke SK, Götze G, Rahne T, Liebau A. Intracochlear drug delivery in combination with cochlear implants: Current aspects. HNO. 2017;65:19-28.

37. Mittal R, Nguyen D, Patel AP, Debs LH, Mittal J, Yan D, et al. Recent Advancements in the Regeneration of Auditory Hair Cells and Hearing Restoration. Front Mol Neurosci. 2017;10:236.

IV.

A maradványhallás megőrzésének lehetőségei cochlearis implantáció során Nucleus CI532 Slim Modiolar elektródasorral

Nagy Roland[1]* ▪ Jarabin János András dr.[1]* ▪ Dimák Balázs[1]
Perényi Ádám dr.[1] ▪ Tóth Ferenc dr.[1] ▪ Szűts Viktória dr.[2, 3]
Jóri József dr.[1] ▪ Kiss József Géza dr.[1] ▪ Rovó László dr.[1]****

Szegedi Tudományegyetem, [1]Általános Orvostudományi Kar, Fül-Orr-Gégészeti és Fej-Nyaksebészeti Klinika, [2]Mérnöki Kar, Élelmiszermérnöki Intézet, Szeged
[3]Magyar Tudományos Akadémia, Szegedi Biológiai Kutató Központ, Növénybiológiai Intézet, Szeged

A hallássérült betegek rehabilitációjában alkalmazott cochlearis implantáció során a residualis hallás posztoperatív megőrzése és a hallási teljesítmény maximalizálása az elektródaprofil implantációjakor kialakult trauma minimalizálásától függ. Ennek megvalósításához minimálinvazív módszerek, továbbá vékonyabb, atraumatikus elektródasorok alkalmazására volt szükség. Célunk a posztoperatív akusztikai hallásmaradvány-megőrzés lehetőségének audiológiai nyomon követése volt. Betegünk veleszületett hallászcsökkenése miatt gyermekkora óta hagyományos, légvezetéses hallásjavító készüléket viselt mindkét fülén. A cochlearis implantációt 6 hónappal megelőzően hallászcsökkenésében mindkét oldalon kifejezett progressziót mértünk, ezért cochlearis implantátum beültetése mellett döntöttünk. A beteg a műtétet megelőzően mindkét fülén rendelkezett residualis hallással, ezért Cochlear® Nucleus CI532 Slim Modiolar implantátumot alkalmaztunk. A minimálisan invazív műtétet a beteg jobb fülén végeztük el kerekablakbehatoláson keresztül. A preoperatív hallásküszöbhöz (átlag 85 dBHL) viszonyítva a 4. posztoperatív héten 0,25–1,0 kHz között 5–10 dBHL, míg 2,0–4,0 kHz-en 20–25 dBHL mértékű iniciális hallásküszöbromlást tapasztaltunk. A 6. hónapban mért hallásküszöb az 1 kHz feletti tartományban további kisfokú progressziót mutatott, ugyanakkor a 12. hónapban a hallásküszöb javult, a 4. héten kapott eredményekkel megegyezett. A cochlearis implantáció residualis hallásra gyakorolt hatásait több tanulmány is vizsgálta, melyekben számos sebészi és technikai tényező kulcsszerepét meghatározták. A CI532 Slim Modiolar eletródaprofil modiolushoz közeli elhelyezkedése várhatóan kisebb endocochlearis hidrodinamikai terhelést jelent, mindemellett lehetővé teszi, hogy a ganglion spirale szomszédos idegelemeit alacsonyabb áramintenzitással, kisebb felületen ingerelhessük, ami neuroprotektív hatású lehet. Az akusztikai hallásmaradvány cochlearis implantáció kapcsán történő megőrzése javítja a beteg beszédértését és hanglokalizációs képességét, különösen nehezített körülmények között. A residualis hallás hosszú távú megőrzése kiemelkedő fontosságúnak bizonyulhat továbbá a későbbi regeneratív eljárások, gyógyszeres kezelések megvalósíthatósága kapcsán is.
Orv Hetil. 2018; 159(41): 1680–1688.

Kulcsszavak: cochlearis implantátum, CI532 Slim Modiolar elektróda, maradványhallás-megőrzés, minimálinvazív sebészet

Possibilities for residual hearing preservation with Nucleus CI532 Slim Modiolar electrode array

Case report

During the rehabilitation of hearing-impaired patients, the preservation of residual acoustic hearing following cochlear implantation by minimizing the implantation trauma allows for improved hearing performance. To achieve this, minimally invasive, soft surgery methods and thinner, atraumatic electrodes were required. In our present study, we

***N. R. és *J. J. A. megosztott első szerzőként, **R. L. és **K. J. G. megosztott utolsó szerzőként jegyzik a kéziratot.**

reported a case where Cochlear® Nucleus CI532 Slim Modiolar electrode was implanted in a patient with residual hearing. Our aim was to study the possible preservation of postoperative acoustic residual hearing by audiological monitoring. Since childhood, due to her congenital hearing loss, she has been wearing a conventional, airborne hearing correction device on both ears. Six months before cochlear implantation, we measured the progression on both sides of the hearing loss, so we decided to perform cochlear implantation. The patient had residual hearing on both ears prior to surgery thus the Cochlear® Nucleus CI532 Slim Modiolar Implant was used. The minimally invasive surgery was performed on the patient's right ear through the round window approach. Compared to the preoperative hearing threshold (average 85 dBHL) in the 4th postoperative week, an initial hearing threshold progression of 20–25 dBHL was observed between 0.25 and 1.0 kHz, while of 5–10 dBHL between 2.0–4.0 kHz. Hearing threshold measured in the 6th month showed a slight progression in the range above 1 kHz, but improved by the 12th month, to the results achieved at the 4th week. The effects of cochlear implantation on residual hearing have been studied in numerous studies, in which several key surgical and technical factors have been identified. Nucleus CI532 is a Slim Modiolar electrode profile that is close to the modiolus, so it is expected to have a lower endocochlear hydrodynamic load since it lies in the covering of the osseus spiral lamina, thus less influencing the dynamics of the basilar membrane. However, the perimodiolar location of the electrode array allows the adjacent nerve elements of the spiral ganglion to be stimulated with a lower electrical intensity and a reduced surface that may be neuroprotective. Preservation of acoustic residual hearing following cochlear implantation improves the patient's speech perception and the sound localization skills, particularly in difficult circumstances. Long-term residual hearing preservation may also be of great importance in the subsequent feasibility for regenerative procedures and drug treatments.

Keywords: cochlear implant, CI532 Slim Modiolar electrode, residual hearing preservation, soft surgery

Nagy R, Jarabin JA, Dimák B, Perényi Á, Tóth F, Szűts V, Jóri J, Kiss JG, Rovó L. [Possibilities for residual hearing preservation with Nucleus CI532 Slim Modiolar electrode array. Case report]. Orv Hetil. 2018; 159(41): 1680–1688.

(Beérkezett: 2018. március 1.; elfogadva: 2018. április 5.)

Rövidítések

ASSR = (auditory steady-state response) auditoros steady-state válasz; CI = cochlearis implantátum; CT = (computed tomography) számítógépes tomográfia; BERA = (brainstem evoked response audiometry) agytörzsi kiváltott potenciál vizsgálat; DPOAE = (distortion product otoacoustic emission) disztorziós otoakusztikus emisszió; EAS = (electric-acoustic stimulation) elektroakusztikus stimuláció

A legutóbbi években csaknem az összes súlyossági fokú és típusú halláscsökkenés rehabilitálhatóvá vált valamely implantálható hallásjavító rendszer alkalmazásával [1–3]. A cochlearis implantátumok (CI) évtizedek óta jó funkcionális eredménnyel biztosítják a különböző hátterű cochlearis károsodásból eredő, súlyos fokú halláscsökkenések rehabilitációját mind gyermekek, mind felnőttek esetében [4]. A CI egy műtéti úton, részben beültetett hallásjavító eszköz, mely közvetlenül a csiga lumenébe vezetett, szőrsejtprotézisként működő elektródasoron át hozza ingerületbe a hallóideg még működő perifériás sejtjeit. A cochlearis implantátumok működési elve a következő: a külső beszédprocesszor a környezet hangjait elektromos jelekké alakítja át, melyeket az adótekercs az intakt bőr alatt elhelyezkedő belső implantátumegységhez továbbít. Az elektromos impulzusok ezt követően a belső elektronikához csatlakozó elektródasoron keresztül közvetlenül a ganglion spirale sejtekhez, majd a cent-

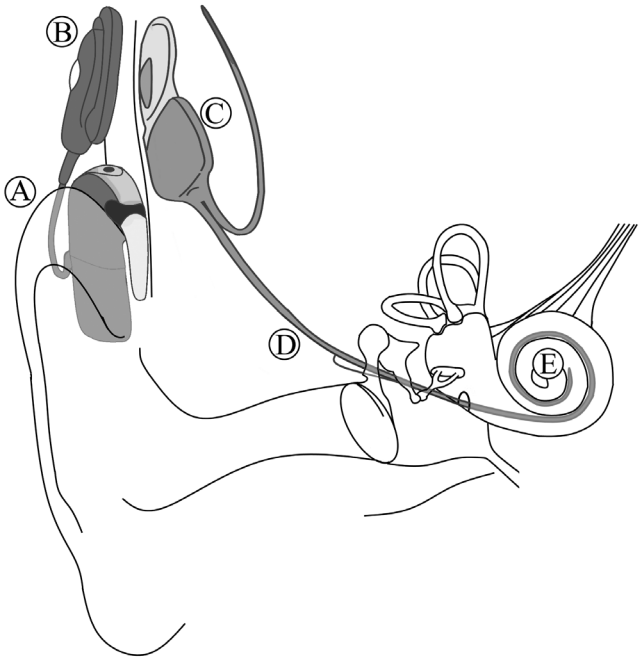

1. ábra A cochlearis implantátum sematikus felépítése és működése. A külső beszédprocesszor (A) a környezet hangjait elektromos jelekké alakítja át, melyeket az adótekercs (B) az intakt bőr alatt elhelyezkedő belső implantátumegységhez (C) továbbít. Az elektromos impulzusok ezt követően a belső elektronikához csatlakozó elektródasoron (D) keresztül közvetlenül a ganglion spirale sejtekhez (E), majd a centrális hallópályán keresztül a hallókéreghez jutnak

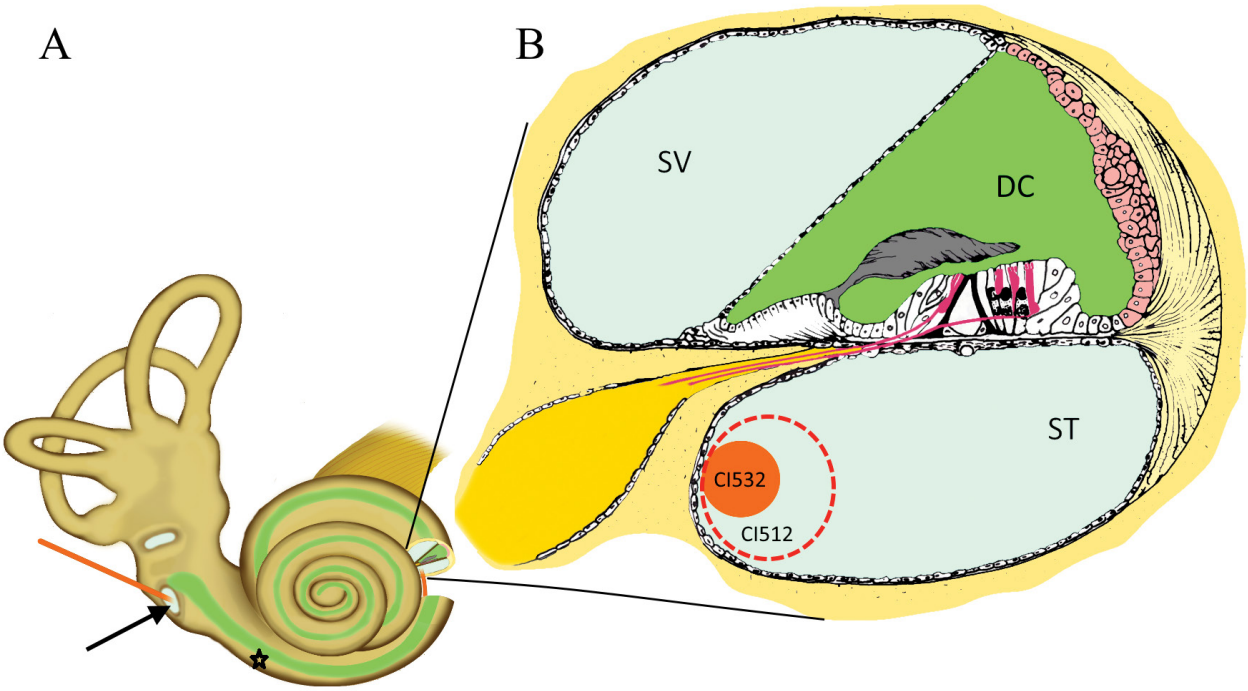

2. ábra A Cochlear® Nucleus CI532 Slim Modiolar elektródaprofil endocochlearis elhelyezkedése. A cochlea megnyitásának leggyakoribb sebészi kapui

(A) A sémás ábra a labyrinthus szerkezetét ábrázolja, melyen jól látható a fenestra rotundán (fekete nyíl) át bevezetett elektródasor (narancsszínű). Alternatív sebészi behatolásként, a cochleostoma furatának helyét az ábrán fekete csillag jelöli. Az ábra jobb oldalán kinagyított átmetszeti kép a csiga mikroszkópos vázlati szerkezetét, az implantáció sikeressége szempontjából nélkülözhetetlen folyadéktereit ábrázolja (ST – scala tympani; SV – scala vestibuli; DC – ductus cochlearis)
(B) Látható a scala tympaniba vezetett elektródasor intracochlearis elhelyezkedése két, eltérő elektródaprofil fizikai paramétereinek illusztrációjával. A CI532-es (narancsszínű, tömör átmetszetű) elektródaprofil körülbelül 60%-os relatív keresztmetszet-csökkenése, következményes intracochlearis-pozíció-változása szembetűnő a korábbi, CI512-es (narancsszínű, szaggatott körvonalú) elektródaprofilhoz képest

rális hallópályán keresztül a hallókéreghez jutnak *(1/A–E ábra)*.

Megjelenésük óta a CI-k jelentős technikai fejlődésen mentek keresztül, ami időről időre a műtéti technikák adaptációját tette szükségessé. A kezdetektől fogva jelen volt az a törekvés, hogy a beteg esetleges residualis hallását a műtétet követően is megőrizzük [5]. Ezen koncepció különösen előtérbe került minden olyan esetben, amikor a beteg mélyhang-hallása még hagyományos hallókészülékkel is rehabilitálható volt, ugyanakkor a beszédértés az egyidejűleg jelen lévő, súlyos fokú, közép- és magashang-vesztés miatt akusztikai erősítés mellett is csaknem lehetetlen volt. Ez vezetett az elektroakusztikus stimuláció (EAS) elvén működő implantátumrendszerek megjelenéséhez, melyek egyszerre alkalmaznak hagyományos, akusztikai erősítést, továbbá implantált, elektromos stimulációt [6]. Az előbbi a mély hangok tartományában nyújt erősítést, míg az utóbbi a magasabb hangok területén biztosít kellő stimulációt, így optimalizálva a beteg beszédértését.

A residualis hallás posztoperatív megőrzése ösztönözte az egyre vékonyabb, atraumatikus elektródasorok megalkotását is [5, 7]. A hallási teljesítmény maximalizálása ugyanis a beillesztési trauma minimalizálásától függ [8]. Cochlearis implantáció során károsodhatnak az endocochlearis struktúrák, melyek azonnali vagy akár késői posztoperatív residualishallás-romlás forrásai lehetnek [9–11]. Az elektródasor bevezetése során esetlegesen kialakuló belsőfül-trauma az eredete alapján, sebészi szempontból, két csoportba sorolható. Ezek közül az első az elektródasornak a scala tympaniba történő célzott bevezetése [12]. A legelterjedtebb sebészi technikák ezt vagy a kerekablak-membránon át (úgynevezett „round window approach”), vagy egy úgynevezett cochleostomán, azaz a cochlea basalis kanyarulatának mesterséges furatán át valósítják meg [10] *(2. ábra)*. A második jelentősebb csoportot az elektródasor minimális traumát okozó bevezetése képezi. Ebben szintén számos tényezőnek lehet meghatározó szerepe, mint például: (1) az elektróda bevezetése során keletkező közvetlen trauma; (2) az implantáció kapcsán a perilympha folyadéktérben kialakuló nyomáshullám hatása; (3) a fúró által okozott vibráció, hangártalom, esetleg hőtrauma; (4) perilymphavesztés; (5) a belső fül folyadéktereinek homeosztázisában létrejövő változások; endolymphaticus hydrops kialakulása; (6) a csiga lumenének késői fibroticus, csontos átalakulása [13, 14]. Az elektródasor hossza és keresztmetszete szintén korlátozhatja a posztoperatívan elérhető residualis hallás megőrzését [15]. A közép- és a belső fül átfogó preoperatív radiológiai elemzése segíthet mind a műtéti behatolás megtervezésében, mind az elektródaprofil kiválasztásában [16–18].

EAS-t alkalmazva a magashang-tartományban károsodott szőrsejtek területét, azaz a basalis régiót sok esetben egy rövid elektródasor bevezetésével fedik le, mellyel megkímélhető az apicalis cochlearis régiók szerkezete, működése. Ez esetben a kihívást a residualis hallás hosszabb távú megőrzése jelenti [19]. Ha ugyanis a mélyhang-hallásban progresszió következik be, az eredetileg optimális hosszúságú elektróda, fizikai lefedettség hiányában, már nem lesz képes pótolni a cochlea ezen régiójának funkcióját. A progresszió hátterében kiváltó okként szerepelhet késői endocochlearis fibrosis vagy csontszövetképződés is [20]. Az ebben a helyzetben felmerülő teljes belsőegység-csere, hosszabb elektródasor bevezetése ennek kapcsán akár fizikai akadályba is ütközhet. Elzáródás hiányában ugyanakkor akár több egymást követő implantáció szükségessé válhat, követve a beteg hallásának folyamatos rosszabbodását, ezzel nyilvánvaló sebészi, altatási terhet róva a betegre. Mindemellett számos finanszírozási kérdés is felmerülhet.

A cél tehát egy atraumatikus elektródasor kifejlesztése volt, mely a residualis hallás maximális megőrzése mellett képes az elektromos hallás hosszú távú biztosítására. A cochlea teljes hosszában bevezetve az elektródasort kezdetben az EAS részeként üzemelhet, majd egy esetlegesen bekövetkező mélyhanghallás-vesztés esetén, az apicalisan elhelyezkedő elektródákat aktiválva, csupán az implantátum programozásának módosításával biztosítható újra a teljes cochlea elektromos hallás lefedése. A folyamat lényege tehát egy hibrid, akusztikus és elektromos rendszerről tisztán elektromos rendszerre történő áttérés a beültetett elektródasor cseréje nélkül.

Az előbbi feltételeknek véleményünk szerint megfelelő elektródasor (Cochlear® Nucleus „CI532 Slim Modiolar") 2015 novemberében „closed-market release" keretében a Szegedi Tudományegyetem Fül-Orr-Gégészeti és Fej-Nyaksebészeti Klinikáján került beültetésre elsőként a világon (operatőr: Prof. Dr. Rovó László tanszékvezető egyetemi tanár).

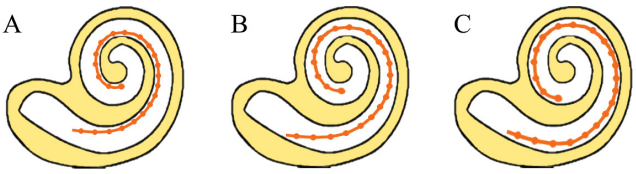

3. ábra Az elektródaprofilok csoportosítása a modiolustól való távolságuk alapján. Az elektródaprofilok modiolustól való távolságuk alapján (A) perimodiolaris, (B) mid-scala, (C) „lateral-wall" típusba sorolhatók. A jelen cikk tárgyát képező Nucleus CI532-es elektróda a perimodiolaris csoport tagja

Klinikánkon ez idáig 89 esetben (69 beteg) ültettünk be CI532-es elektródasort, melyek közül 40 fő esetében mértünk preoperatív residualis hallást. A homogén betegcsoportok adatainak részletes feldolgozása jelenleg folyamatban van.

Jelen tanulmányunkban egy olyan esetről számolunk be, amelyben Cochlear® Nucleus CI532 Slim Modiolar elektródát ültettünk be residualis hallással rendelkező betegnek. Vizsgálatainkkal arra kerestük a választ, hogy rövid vagy akár hosszú távon is megőrizhető marad-e az akusztikai hallás.

Anyag és módszer

Nucleus CI532 Slim Modiolar elektródaprofil

Az elektródaprofilokat a modiolustól való távolságuk alapján perimodiolaris, „mid-scala", illetve „lateral-wall" kategóriákba sorolhatjuk *(3. ábra)* [21]. A Nucleus CI532-es elektródasor jelenleg a világ egyik legkisebb átmérőjű perimodiolaris pozíciójú elektródaprofilja. Basalisan 0,5 mm, míg apicalisan 0,3 mm átmérőjű, ezzel mintegy 60%-ban kisebb térfogatú, mint a gyártó szintén perimodiolaris elhelyezkedésű, előző generációs elektródaprofilja, az úgynevezett Nucleus Contour Advance *(4. ábra)* [22]. Különleges, rugalmas háromdimenziós (3D-s) konformációjának köszönhetően lehe-

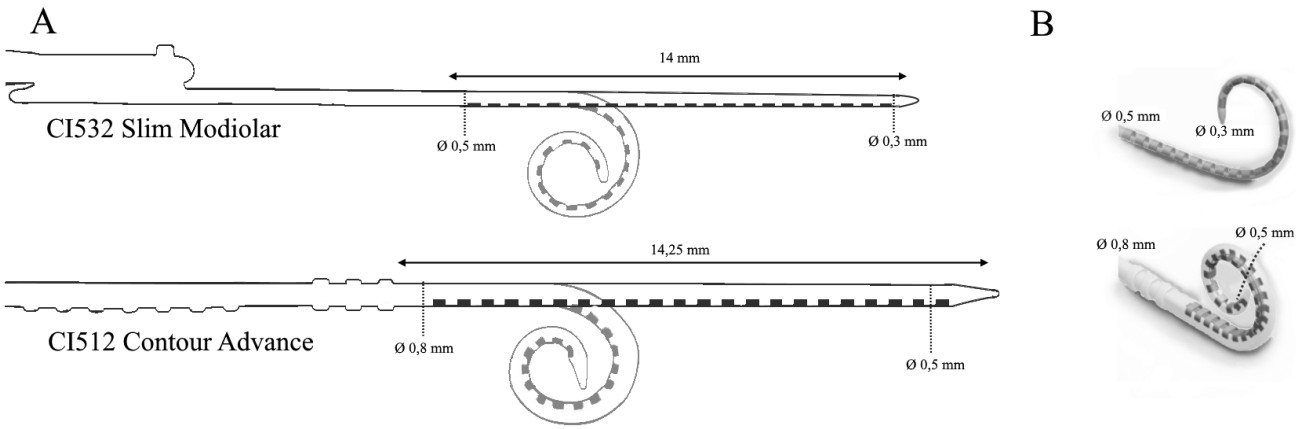

4. ábra Perimodiolaris elektródasorok összehasonlítása. Az ábrán a Nucleus CI532 vékony, perimodiolaris elektródaprofil méretei láthatók az előző, úgynevezett Contour Advance elektródaprofilhoz képest. A Nucleus CI532-es elektródasor jelenleg a világ legkisebb átmérőjű perimodiolaris pozíciójú elektródaprofilja. Basalisan 0,5 mm, míg apicalisan 0,3 mm átmérőjű, ezzel mintegy 60%-ban kisebb térfogatú, mint a szintén perimodiolaris elhelyezkedésű, előző generációs elektródaprofil, az úgynevezett Nucleus Contour Advance CI512

tővé teszi, hogy az elektródák a lamina spiralis ossea eredése alatt helyezkedjenek el, így biztosítva, hogy a stimulációs pontok a ganglion spirale sejtjeinek közelébe kerüljenek *(2/B ábra)*. Atraumatikus kialakítása biztosítja az endocochlearis finomstruktúrák megőrzését [23]. Egyedülálló beillesztési mechanizmussal rendelkezik, amely a sebész számára lehetővé teszi, hogy kiválaszthassa a legmegfelelőbb megközelítést a cochlea anatómiájának függvényében. A biztonság érdekében az elektróda újratölthető vezetőeszközzel rendelkezik, mely szignifikáns mértékben növeli az elektróda optimális helyzetbe kerülésének esélyét [21].

Minimálisan invazív sebészi technika

A residualis hallás cochlearis implantáció során történő megőrzésének szándéka vezetett az úgynevezett „soft surgery", azaz minimálisan invazív műtéti eljárások megjelenéséhez. Ezek alapvetően meghatározzák a cochlea megnyitásának és az endocochlearis manipulációknak minden olyan elemét, amely makro- és mikroszerkezeti károsodások által negatívan befolyásolhatja a posztoperatívan elérhető hallásteljesítményt (direkt trauma és/vagy különböző anyagok bekerülése a cochleába stb.). A minimálisan invazív cochlearis implantációs eljárás tehát nem konkrét műtéti típus, hanem inkább olyan szabályok összessége, melyeket követve egyre tökéletesebb funkciómegőrzés lehetséges. A fogalmat és a főbb szempontokat elsőként *Lehnhardt* közölte 1993-ban [24], ami számos később megjelent publikáció alapját jelentette [25]. A residualis hallás megőrzésének szándéka legújabban az EAS-rendszerekkel történő hallásrehabilitáció során merül fel [26–28].

Minimálinvazív technikát alkalmazva egyaránt választhatunk kerek ablakon, kiterjesztett kerekablak-behatoláson vagy cochleostomán át történő elektródabevezetést [11]. A csont szükséges mértékű elfúrásához minden esetben 1 mm átmérőjű gyémántfúrót használunk lassú fordulatszámon, ezzel elkerülve a fúrás során keletkező hang- és hőártalmat [13, 14]. Az endosteum megnyitása előtt, annak felszínére szteroidtartalmú oldatot vagy nátrium-hialuronát-tartalmú készítményt helyezhetünk. Az endosteum megnyitásához mikrotűt vagy -horgot, továbbá különböző lézereket használhatunk. A belső fül megnyitását követően fokozottan ügyelnünk kell arra, hogy elszívás közben nehogy perilymphavesztést okozzunk. A scala tympani csupán a lehető legrövidebb ideig lehet nyitva, ugyanis azon mint behatolási kapun át primeren vagy az elektródához tapadva szekunder módon csontpor, vér vagy egyéb anyag juthat a belső fülbe, mely számos direkt és/vagy másodlagos károsodás forrása lehet, s ez végső soron a posztoperatív residualis hallás csökkenéséhez, elvesztéséhez vezethet. Bevezetése előtt, a Nucleus CI532-es elektródaszálat az implantátumhoz tervezett speciális vezetősínbe vissza kell húzni. Ez elősegíti az optimális implantációs szög meghatározását, megtartását. Az elektródaszál bevezetése a lehető legkisebb erő kifejtése mellett kell, hogy történjen. Minden érzékelhető ellenállás a basilaris membrán, a lateralis scala tympani fal vagy a stria vascularis kontaktusát, következményes sérülését jelezheti. Az elektródaszál bevezetését elősegítheti felszínének szteroidos oldattal vagy nátrium-hialuronáttal történő bevonása. Amint az elektróda a megfelelő hosszúságban bevezetésre került – amit markergyűrűk jeleznek –, a kerek ablakot vagy a cochleostomát autológ szövettel (például fascia, izomszövet) lezárjuk, megelőzve a további perilymphavesztést [25].

Az implantátumtestet és a referenciaelektródát a gyártó által kiadott templát segítségével a bőr alatt kialakított zsebbe helyezzük.

Betegadatok

Nőbetegünk 1987-ben született. Veleszületett halláscsökkenése miatt gyermekkora óta hagyományos, légvezetéses hallásjavító készüléket viselt mindkét fülén. A cochlearis implantációt 6 hónappal megelőzően halláscsökkenésében mindkét oldalon kifejezett progressziót mértünk, így már készülékeinek viselése mellett sem volt kielégítő beszédmegértési képessége. Műtéti alkalmasságát részletes audiológiai és radiológiai tesztekkel bíráltuk el. Ezt követően az implantációt a beteg 30. életévében végeztük el általános anesztéziában. Mivel a beteg a műtétet megelőzően mindkét fülén rendelkezett residualis hallással, vékony perimodiolaris elektródaprofil (CI532 Slim Modiolar implantátum) alkalmazása mellett döntöttünk. A műtétet a beteg jobb fülén végeztük el a fentebb részletezett minimálisan invazív sebészi technikát alkalmazva kerek ablakon keresztül.

Eredmények

Preoperatív hallásvizsgálatok

A preoperatív hallásdiagnosztika teljes körű szubjektív és objektív tesztekből állt. Az elvégzett tisztahang-küszöbaudiometria a beszédfrekvenciákon (0,25–1,0 kHz) átlagosan 85 dBHL hallásküszöböt igazolt *(5/A ábra)*, míg a beszédaudiometria az audiométer méréshatáráig nem volt vizsgálható.

Az objektív teszteket normális középfül-ventiláció mellett végeztük (normál A típusú timpanogram mindkét oldalon). A disztorziós otoakusztikus emisszió (DPOAE) mérésével egyik oldalon sem volt regisztrálható külsőszőrsejt-aktivitás, ami sensorineuralis halláscsökkenés esetében belsőfül-eredetet igazol. Agytörzsi kiváltott potenciál vizsgálattal (BERA) nagy intenzitás mellett még éppen regisztrálható, kis amplitúdójú, ugyanakkor normál atenciájú, reprodukálható válaszokat regisztráltunk, ami szintén a Corti-szerv-eredet mellett szól. Az agytörzsi szakaszon neuralis érintettségre (úgynevezett retrocochlearis laesióra) utaló jeleket nem láttunk. Auditoros steady-state válaszok (ASSRs) vizsgálata során az

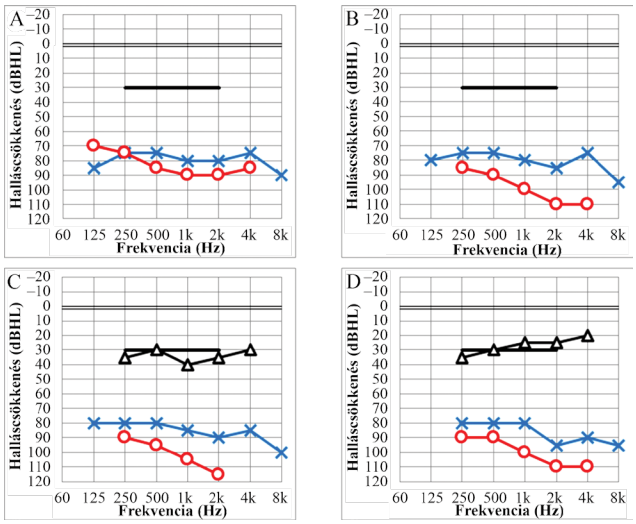

5. ábra Pre- és posztoperatív tisztahang-küszöbaudiometriai eredmények. Az implantációt a jobb fülön végeztük el (piros görbék); az ellenoldali hallást a kék görbék jelzik. A preoperatív tisztahang-küszöbaudiometria a beszédfrekvenciákon (0,25–1,0 kHz) átlagosan 85 dBHL hallásküszöböt igazolt (A). A negyedik posztoperatív héten a beszédfrekvencia-tartományt tekintve 0,25–1,0 kHz között 5–10 dBHL, míg 2,0–4,0 kHz-en 20–25 dBHL mértékű iniciális hallásküszöbromlást tapasztaltunk (B). A 6. hónapban mért hallásküszöb 1 kHz felett ismét progressziót mutatott (C), ugyanakkor a posztoperatív 12. hónapban, javulást követően, a 4. héten kapott eredményekkel megegyező hallásküszöbértékeket mértünk (D). A 6. hónapban elvégzett szabad hangteres hallásküszöb-vizsgálat a jobb fülön viselt cochlearis implantátummal közel a szociális hallásküszöbnek megfelelő hallást igazolt, átlag 35–40 dBHL küszöbszinttel. A posztoperatív 12. hónapban mért szabad hangteres hallásküszöb további javulást mutatott, átlag 25–30 dBHL-nek bizonyult

Jelölések: –X– = bal oldali légvezetéses hallásküszöb; –O– = jobb oldali légvezetéses hallásküszöb; –Δ– = CI-vel mért hallásküszöb szabad hangtérben

objektív hallásküszöböt mindkét oldalon nagy-súlyos fokúnak becsültük *(6. ábra)*.

Eredményeink alapján tehát a beteg bizonyos mértékű residualis hallással rendelkezett ugyan, ez azonban a hagyományos légvezetéses erősítéssel nem lett volna kellő mértékben rehabilitálható. Az objektív tesztek a nervus cochlearis retrolabyrinther károsodását nem vetették fel, melyet a preoperatívan elvégzett nagy felbontású piramiscsont-CT-vizsgálat szintén kizárt. Belsőfül-fejlődési rendellenesség nem ábrázolódott.

Mivel a beteg a cochlearis implantáció audiológiai és radiológiai indikációs kritériumainak megfelelt, műtétet javasoltunk.

Posztoperatív hallásvizsgálatok

Az első ellenőrző tisztahang-küszöbaudiometriai vizsgálatunkra a negyedik posztoperatív héten került sor *(5/B ábra)*. A beszédfrekvencia-tartományt tekintve 0,25–1,0 kHz között 5–10 dBHL, míg 2,0–4,0 kHz-en 20–25 dBHL mértékű iniciális hallásküszöbromlást tapasztaltunk. Ezt követően a posztoperatív hatodik és tizenkettedik hónapban újabb kontroll-hallásvizsgálatot végeztünk. A 6. hónapban mért hallásküszöb 1 kHz felett ismét progressziót mutatott *(5/C ábra)*, ugyanakkor a posztoperatív 12. hónapban *(5/D ábra)*, javulást követően, a 4. héten kapott eredményekkel megegyező hallásküszöbértékeket mértünk. A posztoperatív teszteket tisztán akusztikus ingerrel, a cochlearis implantátum kikapcsolása mellett végeztük el.

Elektrofiziológia

A Nucleus CI532 egy 22 csatornából álló vékony, perimodiolaris elhelyezkedésű elektródaprofillal rendelkező implantátum. A posztoperatív hallásvizsgálatokkal egy időben elvégzett elektródánkénti impedanciamérések számos ingadozást mutatva, a 10–22. elektródatartományban már a 6. hónapban, míg az 1–9. elektródákon a 12. hónapban válnak relatíve stabillá, kiegyenlítetté *(7. ábra)*, ami az elektródasor megfelelő integrációjára, a belsőfül-homeosztáziásnak a rendezettségére utalhat.

Megbeszélés

Az akusztikai residualis hallás cochlearis implantáció kapcsán történő megőrzése javítja a posztoperatívan elérhető periodicitást és spektrális felbontást, aminek köszönhetően javul a beteg beszédértése és hanglokalizációs képessége, különösen nehezített körülmények között, ezért kiemelkedő annak megőrzése [29–35].

A cochlearis implantáció residualis hallásra gyakorolt azonnali hatásait több tanulmány is vizsgálta, melyekben számos sebészi és technikai tényező kulcsszerepét meghatározták [10, 36, 37]. Hasonló vizsgálatok kutatják a mikrofülsebészeti beavatkozások labyrinthfunkciókra gyakorolt hatásait [38]. Az implantációt követő időszakban ugyanakkor számolnunk kell késői komplikációkkal is, úgymint endocochlearis kötő- vagy csontszövetképződéssel, mely másodlagosan a residualis akusztikai hallás romlásához, elvesztéséhez vezethet [20]. Erre a legnagyobb valószínűség a kiterjesztett kerekablak-feltáráskor („extended round window approach") mutatkozik, melynek során az endosteum károsodása vált ki új szöveti proliferációt. A legcsekélyebb a károsodás kialakulásának valószínűsége minimálinvazív kerekablak-behatolás során [10]. A cochlea hidrodinamikai rendszerének károsodása ugyanakkor létrejöhet egy, az alaphártya mozgását korlátozó elektródasor jelenléte miatt is. Ekkor a membrana basilaris eltérő maximummal és helyen tér ki a különböző hangokra, így a haladóhullám terjedését befolyásoló elektródasor a mély frekvenciákért felelős apicalis régió elemeit is károsíthatja, úgynevezett cochlearis vezetéses halláscsökkenést okozva [39, 40]. Az új típusú, vékony átmérőjű, modiolushoz közeli elhelyezkedésű elektródasorok várhatóan kisebb hidrodinamikai terhelést jelentenek, hiszen a lamina spiralis ossea takarásában, az alatt helyezkednek el, a membrana basilarist nem érintik *(2. ábra)*. Az elektródasor perimodiolaris elhelyezke-

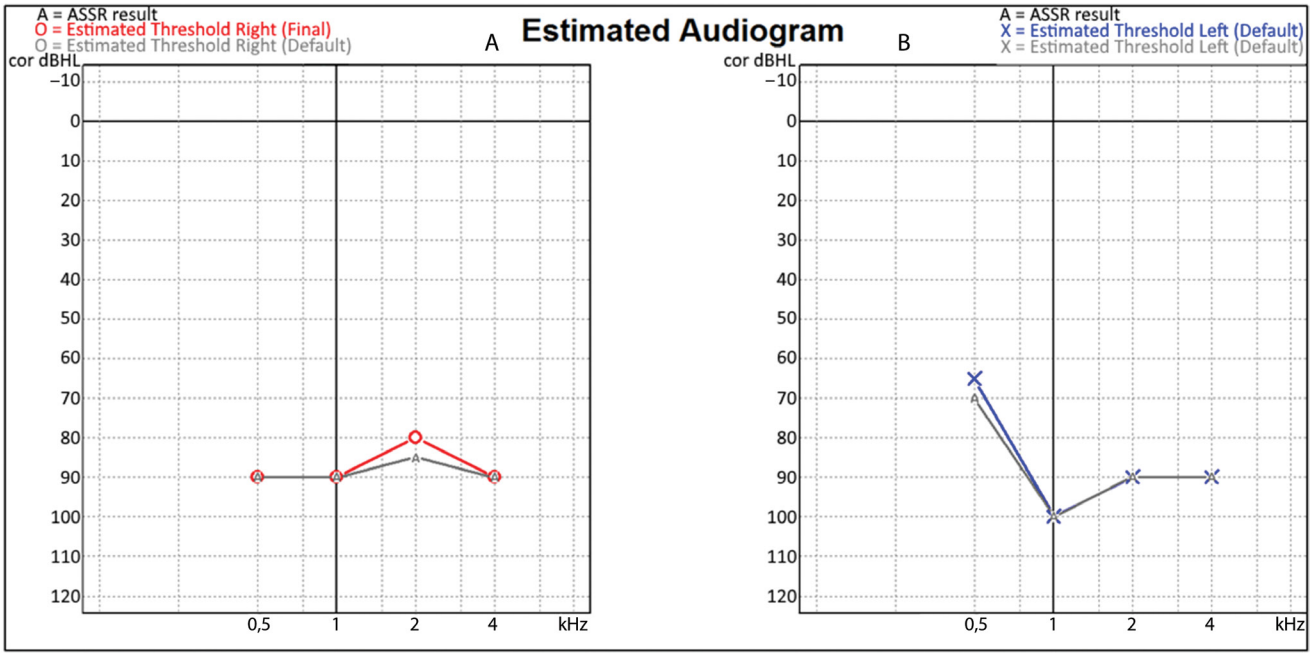

6. ábra Preoperatív objektív hallásküszöbértékek jobb és bal oldalon. Auditoros steady-state válaszok (ASSRs) vizsgálata során az objektív hallásküszöböt, ezzel a residualis hallást mindkét oldalon nagy-súlyos fokban emelkedettnek mértük. A hallásküszöb a jobb oldalon (A) az objektív hallásküszöb 80–90 dB corHL, míg a bal oldalon (B) 90–100 dB corHL mértékűnek bizonyult, bal oldalon 500 Hz-en relatíve megkímélt residualis hallással (corHL: hangintenzitás-korrekciós faktor figyelembevételével, mely tükrözi a beteg életkorát és a rögzítés körülményeit)

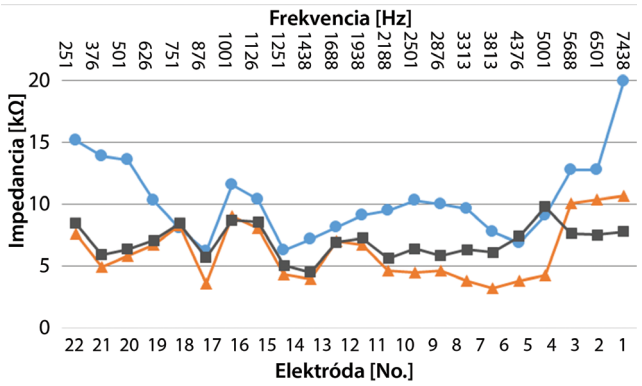

7. ábra Posztoperatív elektródaimpedancia-változások. A posztoperatív hallásvizsgálatokkal egy időben elvégzett elektródánkénti impedanciamérések számos ingadozást mutatva, a 10–22. elektródatartományban már a 6. hónapban, míg az 1–9. elektródákon a 12. hónapban válnak relatíve stabillá, kiegyenlítetté. Ez az elektródasor megfelelő integrációjára, a belsőfül-homeosztázisnak a rendezettségére utalhat. A diagram felső tengelyén a különböző elektródák frekvencialefedettség-átlaga került feltüntetésre

Jelölések: –●– = posztoperatív 4. hét; –▲– = posztoperatív 6. hónap; –■– = posztoperatív 12. hónap

dése mindemellett lehetővé teszi, hogy a ganglion spirale szomszédos idegelemeit alacsonyabb áramintenzitással, kisebb felületen ingerelhessük.

Korai post mortem kadáverkísérletek során igazolták, hogy az interscalaris (azaz a scala tympaniból a scala vestibuliba történő) elektródadiszlokációhoz már 42–122 mN (átlagosan 88 mN) erő kifejtése is elegendő, melynek manuális érzékelhetősége kérdéses [41]. Nagy esetszámon (n = 100) végzett vizsgálatokkal kimutatták, hogy cochleostoma készítése során szignifikáns mértékben nőtt a valószínűsége, hogy az elektródasor a scala vestibuliban helyezkedjen el, ami a betegek beszédértés-javulásának elmaradásában is megnyilvánult [42].

Számos tanulmányban az intraoperatívan elvégzett electrocochleographiai mérések segítségével követhetőnek tartják az elektróda bevezetése során létrejövő traumát, végső soron a posztoperatív residualis hallás megőrzésének tényét [12, 43, 44].

A posztoperatív időszakban esetünkben is mérhető volt a residualis hallás küszöbértékeinek fluktuációja. A funkcionális romlás hátterében az elektródasor megfelelő integrációja, a belsőfül-homeosztázisnak a rendeződése, végső soron egy adaptációs folyamat állhat. Az implantáció által facilitált neuroregeneráció ugyanakkor a hallásküszöb javulását eredményezheti.

Az EAS megvalósításához a külső hibrid beszédprocesszorok (akusztikus és elektromos) önmagukban nem elegendőek, az elektródasornak is atraumatikus profillal kell rendelkeznie, hogy a belső fül struktúráinak megőrzése révén lehetőség legyen a residualis akusztikai hallás hosszabb távú megőrzésére [45].

Esetünk jól demonstrálja, hogy minimálisan invazív technikát, valamint atraumatikus elektródasort alkalmazva a residualis hallás hosszabb távon megőrizhető. Az új típusú CI532 Slim Modiolar elektródasorral nyert kedvező tapasztalataink előrevetítik annak lehetőségét, hogy a cochlea minden régiójának szerkezeti és funkcionális

épsége megőrizhető, ugyanakkor végleges megoldást nyújthat egy esetlegesen bekövetkező késői hallascsökkenés-progresszió kapcsán, amikor is elegendő csupán az implantátum pszichofizikai módszerekkel történő átprogramozása.

Eredményeink alapján, amennyiben a kezdeti tapasztalatoknak megfelelő biztonsággal és hatékonysággal őrizhető meg az akusztikai residualis hallás, úgy lényegesen kevesebb műtéti és altatási teher mellett leszünk képesek tartósan kiemelkedő hallásrehabilitációt biztosítani az EAS indikációjában is, ami jelentős életminőség-javulást, továbbá financiális tehercsökkenést eredményez a beteg és a társadalom számára egyaránt.

Emellett a residualis hallás hosszabb távú megőrzése kiemelkedő fontosságúnak bizonyulhat a későbbi regeneratív eljárások, gyógyszeres kezelések megvalósíthatósága kapcsán is [46, 47].

Következtetés

A cochlearis implantáció során alapvető szerep jut, a minimálinvazív technikák mellett, az individuális igényeket figyelembe vevő, hosszú távon is biztonságos hallásmegőrzést nyújtó elektródasorok alkalmazásának. Esetünk jól demonstrálja a Nucleus CI532 Slim Modiolar elektródaprofil hatékonyságát residualis akusztikai hallás esetében, ami előrevetíti az elektródasorok ezen generációjának EAS-rendszerek részeként történő alkalmazhatóságát, hosszabb távon biztosítva egy esetlegesen a jövőben megjelenő, sejtregeneráción alapuló új terápiás módszer alkalmazhatóságának alapját.

Anyagi támogatás: A közlemény megírása anyagi támogatásban nem részesült.

Szerzői munkamegosztás: N. R.: Elektrofiziológiai mérések elvégzése, az ábrák megszerkesztése, a kézirat nyers változatának elkészítése. J. J. A.: Audiológiai leletek értékelése, a kézirat végleges szövegének megírása. D. B.: Elektrofiziológiai és audiológiai mérések elvégzése. P. Á.: A cochlearis impantációs kivizsgálás megszervezése, részvétel a műtét folyamatában. T. F.: Az elektrofiziológiai mérések értékelése, lektorálás. Sz. V.: A belső fül regenerációját vizsgáló kutatások értékelése, kéziratra adaptálása. J. J.: A kézirat lektorálása, publikációra való felkészítése. K. J. G.: Az elektrofiziológiai mérések, audiológiai vizsgálatok menetének beállítása, ellenőrzése, eredményeik értékelése, tudományos tanácsadás. R. L.: Az implantációs team vezetője, a cochlearis implantáció elvégzése, a beteg posztoperatív gondozása, a végleges kézirat lektorálása, a publikáció folyamatának nyomon követése, irányítása, lektorálás.

Érdekeltségek: A szerzőknek nincsenek érdekeltségeik.

Irodalom

[1] Reinfeldt S, Håkansson B, Taghavi H, et al. New developments in bone-conduction hearing implants: a review. Med Devices (Auckl). 2015; 8: 79–93.

[2] Katona G, Küstel M. Hearing improvement with implantable hearing aids in children. [Hallásjavítás implantálható hallókészülékekkel gyermekkorban.] Gyermekgyógyászat 2016; 67: 113–118. [Hungarian]

[3] Posta B, Jarabin JA, Perényi Á, et al. Pediatric hearing rehabilitation with the Baha® Attract implant system. [Fiatalkori hallásrehabilitáció Baha® Attract implantátumrendszerrel.] Orv Hetil. 2017; 158: 304–310. [Hungarian]

[4] Eshraghi AA, Nazarian R, Telischi FF, et al. The cochlear implant: historical aspects and future prospects. Anat Rec (Hoboken). 2012; 295: 1967–1980.

[5] Friedland DR, Runge-Samuelson C. Soft cochlear implantation: rationale for the surgical approach. Trends Amplif. 2009; 13: 124–138.

[6] Irving S, Gillespie L, Richardson R, et al. Electroacoustic stimulation: now and into the future. Biomed Res Int. 2014; 2014: 350504.

[7] Cohen NL. Cochlear implant soft surgery: fact or fantasy? Otolaryngol Head Neck Surg. 1997; 117: 214–216.

[8] Carlson ML, Driscoll CL, Gifford RH, et al. Implications of minimizing trauma during conventional cochlear implantation. Otol Neurotol. 2011; 32: 962–968.

[9] Adunka O, Unkelbach MH, Mack M, et al. Cochlear implantation via the round window membrane minimizes trauma to cochlear structures: a histologically controlled insertion study. Acta Otolaryngol. 2004; 124: 807–812.

[10] Richard C, Fayad JN, Doherty J, et al. Round window versus cochleostomy technique in cochlear implantation: histological findings. Otol Neurotol. 2012; 33: 1181–1187.

[11] Jiam NT, Limb CJ. The impact of round window vs cochleostomy surgical approaches on interscalar excursions in the cochlea: preliminary results from a flat-panel computed tomography study. World J Otorhinolaryngol Head Neck Surg. 2016; 2: 142–147.

[12] O'Connell BP, Hunter JB, Wanna GB. The importance of electrode location in cochlear implantation. Laryngoscope Investig Otolaryngol. 2016; 1: 169–174.

[13] Khater A, El-Anwar MW. Methods of hearing preservation during cochlear implantation. Int Arch Otorhinolaryngol. 2017; 21: 297–301.

[14] Kiss JG, Jori J. Heat trauma in the surgery of the facial nerve. [Hitzetrauma bei der Chirurgie des Nervus Facialis. In: Zrunek EH, Fleischmajer R. (Hrsg.) Aktuelles in der Otorhinolaryngologie, Österreichischer HNO-Kongress, Graz, 1984.] Thieme Verlag, Stuttgart, 1985; pp. 242–244. [German]

[15] Koch RW, Ladak HM, Elfarnawany M, et al. Measuring cochlear duct length – a historical analysis of methods and results. J Otolaryngol Head Neck Surg. 2017; 46: 19.

[16] Perényi Á, Nagy A, Kiss JG, et al. The role of image reconstructions in ear surgeries, in case of ear malformations. In: Bari F, Almási L. (eds.) [Képi rekonstrukciók szerepe fülműtétekben, fülfejlődési rendellenesség esetében. In: Bari F, Almási L. (szerk.) Orvosi Informatika 2014. A XXVII. Neumann Kollokvium konferencia-kiadványa.] Pannon Egyetem, Veszprém, 2014; pp. 127–130. [Hungarian]

[17] Karkas A, Champfleur NM, Uziel A, et al. Benefit of preoperative temporal bone CT for atraumatic cochlear implantation. Otol Neurotol. 2018; 39: e186–e194.

[18] Perényi Á, Bella Z, Baráth Z, et al. Role of cone-beam computed tomography in diagnostic otorhinolaryngological imaging. [A cone-beam komputertomográfia alkalmazása a fül-orr-gé-

gészeti képalkotásban.] Orv Hetil. 2016; 157: 52–58. [Hungarian]
[19] Pillsbury HC 3rd, Dillon MT, Buchman CA, et al. Multicenter US clinical trial with an electric-acoustic stimulation (EAS) system in adults: final outcomes. Otol Neurotol. 2018; 39: 299–305.
[20] Fayad JN, Makarem AO, Linthicum FH Jr. Histopathologic assessment of fibrosis and new bone formation in implanted human temporal bones using 3D reconstruction. Otolaryngol Head Neck Surg. 2009; 141: 247–252.
[21] Cuda D, Murri A. Cochlear implantation with the nucleus slim modiolar electrode (CI532): a preliminary experience. Eur Arch Otorhinolaryngol. 2017; 274: 4141–4148.
[22] Fraysse B, Macías ÁR, Sterkers O, et al. Residual hearing conservation and electroacoustic stimulation with the Nucleus 24 Contour Advance cochlear implant. Otol Neurotol. 2006; 27: 624–633.
[23] Briggs RJ, Tykocinski M, Lazsig R, et al. Development and evaluation of the modiolar research array – multi-centre collaborative study in human temporal bones. Cochlear Implants Int. 2011; 12: 129–139.
[24] Lehnhardt, E. Intracochlear placement of cochlear implant electrodes in soft surgery technique. HNO 1993; 41: 356–359.
[25] Friedland DR, Runge-Samuelson C. Soft cochlear implantation: rationale for the surgical approach. Trends Amplif. 2009; 13: 124–138.
[26] von Ilberg CA, Baumann U, Kiefer J, et al. Electric-acoustic stimulation of the auditory system: a review of the first decade. Audiol Neurootol. 2011; 16(Suppl 2): 1–30.
[27] Gantz BJ, Turner C, Gfeller KE, et al. Preservation of hearing in cochlear implant surgery: advantages of combined electrical and acoustical speech processing. Laryngoscope 2005; 115: 796–802.
[28] Roland JT Jr, Zeitler DM, Jethanamest D, et al. Evaluation of the short hybrid electrode in human temporal bones. Otol Neurotol. 2008; 29: 482–488.
[29] Dunn CC, Perreau A, Gantz B, et al. Benefits of localization and speech perception with multiple noise sources in listeners with a short-electrode cochlear implant. J Am Acad Audiol. 2010; 21: 44–51.
[30] Gifford RH, Dorman MF, Skarzynski H, et al. Cochlear implantation with hearing preservation yields significant benefit for speech recognition in complex listening environments. Ear Heart 2013; 34: 413–425.
[31] Gifford RH, Driscoll CL, Davis TJ, et al. A within-subject comparison of bimodal hearing, bilateral cochlear implantation, and bilateral cochlear implantation with bilateral hearing preservation: high-performing patients. Otol Neurotol. 2015; 36: 1331–1337.
[32] Gifford RH, Grantham DW, Sheffield SW, et al. Localization and interaural time difference (ITD) thresholds for cochlear implant recipients with preserved acoustic hearing in the implanted ear. Hear Res. 2014; 312: 28–37.
[33] Loiselle LH, Dorman MF, Yost WA, et al. Using ILD or ITD cues for sound source localization and speech understanding in a complex listening environment by listeners with bilateral and with hearing-preservation cochlear implants. J Speech Lang Hear Res. 2016; 59: 810–818.
[34] Loiselle LH, Dorman MF, Yost WA, et al. Sound source localization by hearing preservation patients with and without symmetrical low-frequency acoustic hearing. Audiol Neurootol. 2015; 20: 166–171.
[35] Skarzynski H, Lorens A. Partial deafness treatment. Cochlear Implants Int. 2010; 11(Suppl 1): 29–41.
[36] Sweeney AD, Hunter JB, Carlson ML, et al. Durability of hearing preservation after cochlear implantation with conventional-length electrodes and scala tympani insertion. Otolaryngol Head Neck Surg. 2016; 154: 907–913.
[37] Mittmann P, Ernst A, Todt I. Intracochlear pressure changes due to round window opening: a model experiment. Sci World J. 2014; 2014: 341075.
[38] Harmat K, Thurén G, Simon L, et al. Comparative evaluation of vertigo in patients after stapedotomy and stapedectomy. [Posztoperatív vertigo vizsgálata stapedotomián és stapedectomián átesett betegeknél.] Orv Hetil. 2017; 158: 1503–1511. [Hungarian]
[39] Banakis Hartl RM, Mattingly JK, Greene NT, et al. A preliminary investigation of the air-bone gap: changes in intracochlear sound pressure with air- and bone-conducted stimuli after cochlear implantation. Otol Neurotol. 2016; 37: 1291–1299.
[40] Chole RA, Hullar TE, Potts LG. Conductive component after cochlear implantation in patients with residual hearing conservation. Am J Audiol. 2014; 23: 359–364.
[41] Schuster D, Kratchman LB, Labadie RF. Characterization of intracochlear rupture forces in fresh human cadaveric cochleae. Otol Neurotol. 2015; 36: 657–661.
[42] Wanna GB, Noble JH, Carlson ML, et al. Impact of electrode design and surgical approach on scalar location and cochlear implant outcomes. Laryngoscope 2014; 124(Suppl 6): S1–S7.
[43] Koka K, Litvak LM. Feasibility of using electrocochleography for objective estimation of electro-acoustic interactions in cochlear implant recipients with residual hearing. Front Neurosci. 2017; 11: 337.
[44] Dalbert A, Pfiffner F, Hoesli M, et al. Assessment of cochlear function during cochlear implantation by extra- and intracochlear electrocochleography. Front Neurosci. 2018; 12: 18.
[45] Mahmoud AF, Massa ST, Douberly SL, et al. Safety, efficacy, and hearing preservation using an integrated electro-acoustic stimulation hearing system. Otol Neurotol. 2014; 35: 1421–1425.
[46] Plontke SK, Götze G, Rahne T, et al. Intracochlear drug delivery in combination with cochlear implants: Current aspects. HNO 2017; 65(Suppl 1): 19–28.
[47] Mittal R, Nguyen D, Patel AP, et al. Recent advancements in the regeneration of auditory hair cells and hearing restoration. Front Mol Neurosci. 2017; 10: 236.

(Jarabin János András dr.,
Szeged, Tisza Lajos krt. 111., 6725
e-mail: jarabin.janos.andras@med.u-szeged.hu)

V.

Cochlearis implantátumok különböző, előre görbített elektródasorainak elhelyezkedése a cochlea tengelyéhez viszonyítva

Radiológiai vizsgálat a perimodiolaritás mértékének megállapítására

Perényi Ádám dr. ▪ Nagy Roland ▪ Dimák Balázs
Csanády Miklós dr. ▪ Jóri József dr.
Kiss József Géza dr. ▪ Rovó László dr.

Szegedi Tudományegyetem, Általános Orvostudományi Kar, Fül-Orr-Gégészeti és Fej-Nyaksebészeti Klinika, Szeged

Bevezetés: A cochlearis implantátumok elektródái gyártótól és modelltől függően különböznek hosszukban, vastagságukban és implantációt követően a csiga tengelyéhez (modiolushoz) viszonyított elhelyezkedésükben. Az előre görbített elektródasorok közelebb kerülnek a stimulálandó ganglion spirale sejtekhez, mint az egyenes elektródasorok, ami a stimulációban tapasztalt elektrofiziológiai különbségek mellett előnyös lehet a hangélmény minőségének szempontjából.
Célkitűzés: Előzetes elektrofiziológiai vizsgálataink eredménye szerint ugyanannak a termékcsaládnak (Cochlear™ Nucleus® Profile) a vastagabb (Contour Advance) és vékonyabb (Slim Modiolar) perimodioláris elektródasorai közül a vékonyabbnak az elektródái hasonló töltésmennyiség átadása mellett is képesek hasonló idegi választ kiváltani, mint a vastagabbnak az elektródái. Vizsgálatunkkal arra kerestük a választ, hogy milyen jelenség áll az elektrofiziológiai eredmények hátterében.
Módszer: Betegcsoportonként 54, Contour Advance és Slim Modiolar típusú elektródasorral implantáltakat vontunk be. Az elektródasor bevezetése minden esetben a kerek ablakon keresztül történt, a kerek ablak elülső-alsó csontszélének elfúrását követően vagy a nélkül. A műtét másnapján készült, Stenvers-féle röntgenfelvételeken megmértük az elektródasorok által leírt hurok cochleán belüli legnagyobb átmérőjét. A beültetés után két hónappal megbecsültük a kétféle perimodioláris elektródasorral felszerelt implantátum energiafelhasználási mutatóit.
Eredmények: A posztoperatív röntgenfelvételeken a vékonyabb perimodioláris elektródasorral implantált csoportban az elektródasorok által leírt hurok cochleán belüli átlagos átmérője 4,2 ± 0,5 mm, míg a vastagabb perimodioláris elektródasorral implantált csoportban 4,9 ± 1,1 mm értéknek adódott. Az 'Auto power' a CI532-csoportban 44,81 ± 5,05%, a CI512-csoportban 50,85 ± 8,35% volt, tehát alacsonyabb energiafogyasztást tapasztaltunk a CI532-csoportban.
Következtetés: Képi diagnosztikai módszerrel, viszonylag nagy esetszám bevonásával arra következtettünk, hogy a vékonyabb perimodioláris elektródasor még a vastagabbnál is szignifikánsan közelebb kerül a modiolushoz, ami elfogadható magyarázatot ad előzetes elektrofiziológiai mérési eredményeinkre.
Orv Hetil. 2019; 160(31): 1216–1222.

Kulcsszavak: siketség, cochlearis implantátum, elektródapozíció, modiolus, perimodioláris

The distance from the modiolus of perimodiolar electrode arrays of cochlear implants

A radiological study to evaluate the difference in perimodiolar properties

Introduction: The cochlear implants vary in electrodes in terms of length, width and proximity to the modiolus. The precurved electrode arrays could be placed closer to the modiolus and the ganglion cells compared to straight electrodes. The two types of electrode arrays provide different electrophysiological characteristics; however, proximity to the modiolus may lead to better hearing performance.
Aim: To investigate our preliminary electrophysiological results that suggest that the Slim Modiolar (SM) electrode array has the potential to elicit similar neural responses as the thicker perimodiolar (Contour Advance, CA) electrode from the same generation of implants.
Method: Subjects that were implanted either with CA or SM electrodes were enrolled, 54 consecutive subjects in each group. All electrodes were introduced into the cochlea *via* the round window. The diameter of the largest turn of the electrode arrays within the cochlea was measured through postoperative radiography. The energy consumption parameters were estimated 2 months after implantation.
Results: The mean of the largest turns of the arrays within the cochlea was 4.2 ± 0.5 mm in the SM group and 4.9 ± 1.1 mm in the CA group. 'Auto power' was 44.81 ± 5.05% and 50.85 ± 8.35% with SM and CA, respectively. Estimated energy consumption was lower with SM. The differences were statistically significant.
Conclusion: Our measurements for a large cohort in each group suggest that the SM electrode array takes a significantly closer position to the modiolus than the CA. This finding supports our earlier electrophysiological result and indicates better performance abilities.

Keywords: deafness, cochlear implant, electrode position, modiolus, perimodiolar

Perényi Á, Nagy R, Dimák B, Csanády M, Jóri J, Kiss JG, Rovó L. [The distance from the modiolus of perimodiolar electrode arrays of cochlear implants. A radiological study to evaluate the difference in perimodiolar properties]. Orv Hetil. 2019; 160(31): 1216–1222.

(Beérkezett: 2019. február 21.; elfogadva: 2019. március 25.)

Súlyos fokú sensorineuralis halláscsökkenés esetében, amikor nagy teljesítményű hallókészülékkel sem valósítható meg kielégítő hallás(re)habilitáció, cochlearis implantátum beültetése lehet indokolt. Több gyártó kínál belsőfül-implantátumot és többféle beszédprocesszort, és egyazon gyártótól is több konfiguráció áll rendelkezésre. A konfigurációk különböznek az elektródasorok típusában (például egyenes vagy előre görbített, teljes hosszúságú vagy rövid, vékony vagy vastag), ezáltal lehetőséget biztosítanak a páciensek egyéni anatómiai tulajdonságaira és igényeire szabott eszköz megválasztására. A variációk ugyanakkor megnehezítik a klinikai vizsgálatok eredményeinek összehasonlítását, értékelését. Több kutatócsoport végzett célzott vizsgálatokat a különböző elektródasorok tulajdonságaiból adódó gyakorlati következmények felmérésére, így például a stimuláló elektródasornak a cochlea tengelyéhez, azaz a modiolushoz viszonyított távolságára [1, 2] és ennek elektrofiziológiai hatásaira [3], az energiafogyasztásra, az endocochlearis struktúrák sérülésének mértékére [4], a lehető legkisebb traumával járó sebészi technikákra [2, 5–7], a kombinált elektroakusztikus stimulációra [8, 9] és a hallásmaradvány megőrzésére [10–14] vonatkozóan. A megfelelő hangélmény biztosítását a tudományos közlemények szerzői elsősorban az elektródasor tulajdonságaiban, az elekródasor kíméletes bevezetésében és a beszédprocesszor jó beprogramozásában látják. Egyes szerzők az előre hajlított elektródasorok modiolushoz közeli helyzetével, míg mások a cochlea hosszú elektródasor általi teljes lefedettségével tapasztaltak jobb eredményeket a hallásélményben [15–18].

Az elektródasorok a cochleán belül, típustól függően két „szélső pozícióba" kerülhetnek: az egyenes elektródasorok a modiolustól távoli, ún. *laterális fali* helyzetet, míg az előre görbített elektródasorok modiolushoz közeli, ún. *perimodioláris* helyzetet foglalnak el *(1. ábra)*. Létezik még az úgynevezett *midscala* elhelyezkedésű elektródasor, amely a scala tympaniba vezetve „köztes" pozíciót vehet fel.

Bár vitatott dolog, hogy az egyenes vagy az előre görbített elektródasorokkal érhető el jobb hallásélmény, a stimuláló elektródák és a modiolus viszonyának fontosságára mutat rá az a vizsgálati eredmény, amely szerint a hangélmény és a beszédértés minőségében szignifikáns javulást eredményezhet, ha az elektródák közelebb kerülnek a modiolushoz, előre görbített elektródasorok esetében [15]. Az előre görbített elektródasorok előnye az egyenesekkel szemben az, hogy kialakított tulajdonságuknak köszönhetően az egyes elektródák közelebb kerülhetnek a modiolushoz, ezáltal az elektromosan stimulálandó ganglion spirale sejtekhez is. Következésképpen a leadott töltésmennyiség – a kisebb távolság miatt – ki-

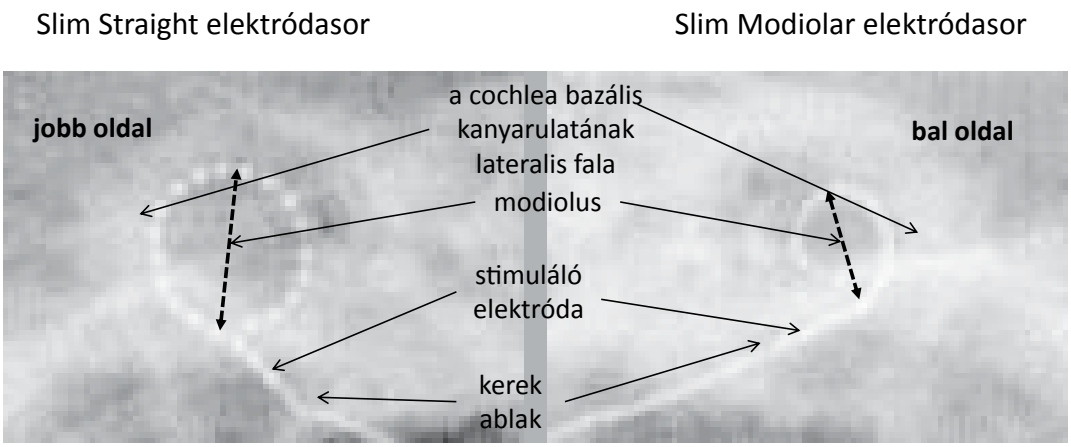

1. ábra Az egyenes és a perimodioláris elhelyezkedésű elektródasorok cochleán belüli helyzetének szemléltetése ugyanannál a páciensnél, szekvenciális cochlearis implantációt követően, Stenvers-szerinti röntgenfelvételeken. A jobb és a bal oldali cochlea szabályos alakú és azonos méretű, amit az implantációkat megelőzően készült komputertomográfiás felvételen, méréssel ellenőriztünk. A jobb cochleába vékony, egyenes stimuláló elektróda (Cochlear™ Slim Straight), a bal cochleába vékony, előre görbített stimuláló elektróda (Cochlear™ Slim Modiolar) került. A szaggatott fekete kettős nyilak az elektródasorok által a cochleán belül leírt hurok legnagyobb átmérőjét mutatják

sebb mértékben szóródik szét a cochlea folyadékterében, így kisebb áramerősségű impulzusok elegendőek a ganglion spirale sejtjeinek ingerléséhez [14, 19, 20]. Emiatt szélesebb a hallásküszöb és a komfortküszöb közötti dinamikai tartomány, csökken az energiafogyasztás, és nő az elem/akkumulátor életideje [1, 21].

Cochlearis implantátum beültetését követően rutinszerűen röntgenfelvételt készítünk. A Stenvers-féle felvételen nagy biztonsággal állapíthatók meg azok a komplikációk, amelyek az elektródasor eltávolítását és újbóli pozicionálását teszik szükségessé, így például ha az elektródasor rendellenes, cochleán kívüli helyzetbe került

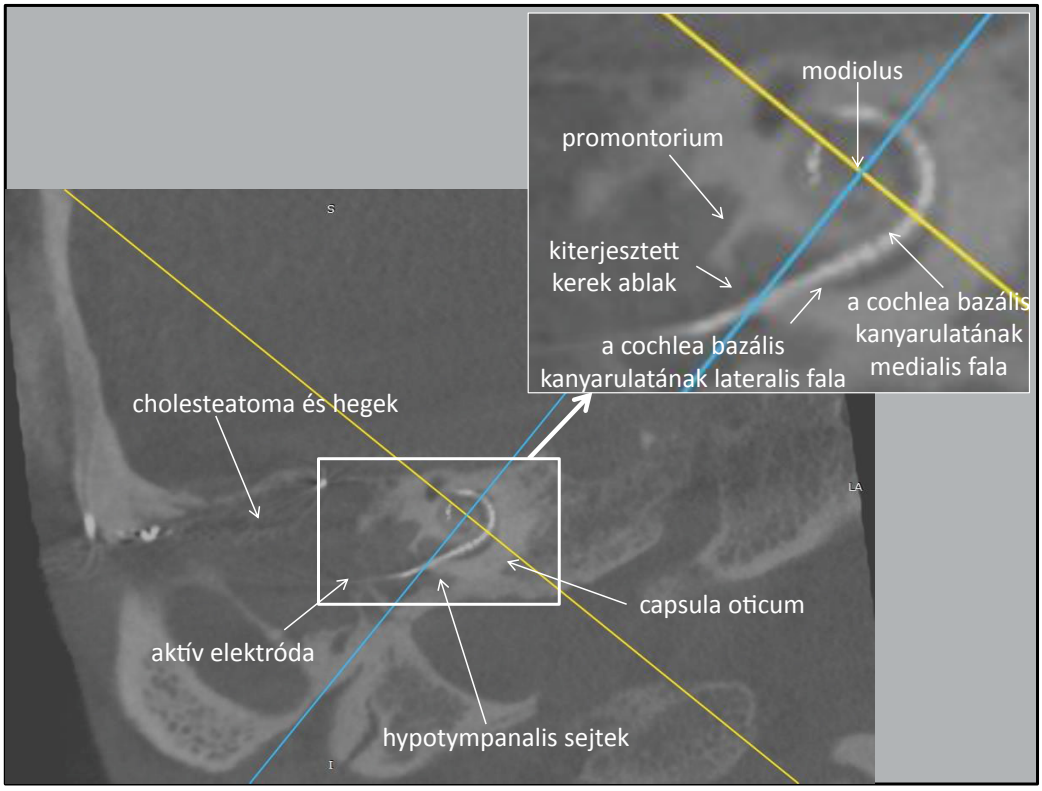

2. ábra Cochlearis implantációt követően 15 évvel, recidiváló cholesteatoma gyanúja miatt készített cone-beam komputertomográfiás vizsgálat, modiolusra centrált, rá merőleges síkú, a cochlea bazális kanyarulatát ábrázoló rekonstrukciója. A cochleában kiterjesztett kerek ablaki behatolásból bevezetett Contour Advance elektródasor látható. A dobüregben – hipodenz megjelenésű levegő helyett – lágyrésznek megfelelő fedettséget (műtéti leletünk alapján recidív cholesteatomát és hegeket) találunk. Elkülöníthető a csontos cochleán belül a hártyás cochlea, és látható, hogy az előre görbített elektródasor nagy része a hártyás cochlea belső falához közel helyezkedik el

vagy a vékony, előre görbített elektródasorok esetében gyakran észlelt 'tip fold-over' (az elektródasor csúcsi részének visszahajlása) [22, 23]. A szummációs röntgenképeken a csigán belüli részletek (scala tympani, scala vestibuli) nem különülnek el. Komplikáció gyanújakor, a részletgazdagabb képi megjelenítés érdekében szóba jön a sziklacsont vékony szeletes komputertomográfiás (CT-) vizsgálata vagy még inkább cone-beam (kúpsugaras) CT-vizsgálata, amely szignifikánsan alacsonyabb effektív sugárdózissal elvégezhető, és kevesebb műterméket okoznak rajra a fémelektródák *(2. ábra)* [24–26].

A hallásmaradvány implantációt követő megőrzésének kiemelten fontos feltétele az, hogy az elektródasor mind a bevezetésekor, mind azt követően a lehető legkisebb traumát okozza a cochleában. Ezért alkalmazunk vékony, hajlékony elektródasorokat, amelyeket az ún. *soft surgery* [27] technikával vezetünk a cochlea scala tympani járatába. A rendelkezésre álló vékony elektródasorokat az *1. táblázatban* mutatjuk be [28–32].

A klinikai vizsgálatok eredményeinek értékelését megnehezítő variációk csökkentése érdekében ugyanannak a termékcsaládnak kétféle előre görbített elektródasorral rendelkező implantátumtípusát választottuk a vizsgálatunkhoz. Munkacsoportunk rendszeresen alkalmazza a Cochlear™ Nucleus® Profile termékcsaládot (Cochlear Limited, Sydney, Ausztrália), és széles körű tapasztalatra tett szert mindkét perimodioláris elektródával. A termékcsalád tagjai csupán az elektródasor típusában különböznek, az implantátumtestben elhelyezkedő elektronikai egység azonos. A Slim Modiolar a jelenleg elérhető egyik legvékonyabb elektródasor, amely 'closed-market release' (zárt piaci kibocsátás) keretében a Szegedi Tudományegyetem Fül-Orr-Gégészeti és Fej-Nyaksebészeti Klinikáján került beültetésre elsőként, 2015 novemberében. A Contour Advance® elektródasor mind az apicalis, mind a bazális átmérőjében (a: 0,5 mm, b: 0,8 mm) szignifikánsan vastagabb a Slim Modiolar elektródasor átmérőinél (a: 0,4 mm, b: 0,5 mm), és az egyes elektródák aktív felülete nagyobb, mint a Slim Modiolar elektródáké [31, 32]. Mivel az ingerlő elektródák felszíne és az ellenállás között fordított arányosság áll fenn, valamint az ingerlő elektródák és a célzott idegelemek (modiolus, ganglion spirale) közötti távolság egyenesen arányos a közeg elektromos ellenállásával, ebből az következik, hogy ha a kisebb felszínű elektródák kisebb töltésmennyiséggel képesek lehetnek kiváltani hasonló mértékű akciós potenciált, akkor közelebb kell lenniük a stimulált struktúrához.

1. táblázat | A vékony elektródasorok típusa és átmérői [28–32]

Elektródasor megnevezése	Elektródasor típusa	Elektródasor átmérője (a: apicalis, b: bazális)
MED-EL FLEX24 és FLEX28	Egyenes	a: 0,3 × 0,5 mm b: 0,8 × 0,8 mm [28]
Advanced Bionics HiFocus™ Mid-Scala	Előre görbített	a: 0,5 mm b: 0,7 mm [29]
Oticon Medical EVO®	Egyenes	a: 0,4 × 0,4 mm b: 0,5 × 0,5 mm [30]
Cochlear™ Nucleus® Profile Slim Straight	Egyenes	a: 0,3 mm b: 0,6 mm [31]
Cochlear™ Nucleus® Profile Slim Modiolar (CI532)	Előre görbített	a: 0,35 × 0,4 mm b: 0,45 × 0,5 mm [32]

Munkacsoportunk korábbi, nagy esetszámon elvégzett elektrofiziológiai vizsgálatainak eredményei arra utalnak, hogy ugyanazon elektronikai egység mellett a Slim Modiolar elektródasor (CI532 típusú implantátum) még alacsonyabb áramerősségű impulzusok mellett is képes idegi választ, akciós potenciált generálni, mint a Contour Advance elektródasor (CI512 típusú implantátum) [33, 34]. Vizsgálatunk célja annak megállapítása volt, hogy a fenti előnyös elektrofiziológiai tulajdonságokból levont következtetést alátámasztják-e az implantátum energiafelhasználási mutatói és a posztoperatív képalkotó vizsgálatok eredményei.

Anyag és módszer

Az első 54, CI532 és az első 54, CI512 készülékkel implantált esetünket vizsgáltuk. A betegcsoportok demográfiai jellemzőit a *2. táblázatban* tüntettük fel.

A műtéteket két, cochlearis implantációban jártas, tapasztalt fülsebész végezte el a nemzetközileg leginkább elfogadott és elterjedt módszerrel, posterior tympanotomiás feltárásból, „soft surgery" technikával a Szegedi Tudományegyetem Szent-Györgyi Albert Klinikai Központja Fül-Orr-Gégészeti és Fej-Nyaksebészeti Klinikáján. Az elektródasorok bevezetése a kerek ablak fülkéjét (fossula fenestrae cochleae) képező csontos struktúrák elvétele után a kerek ablakon keresztül vagy járulékosan a kerek ablak elülső-alsó csontszélének elfúrását követően, ún. kiterjesztett, kerek ablaki behatolásból történt.

2. táblázat | A vizsgálatba bevont betegek demográfiai adatai

Betegcsoport	CI532	CI512
Az implantátum típusa	Cochlear Nucleus CI532	Cochlear Nucleus CI512
Az elektróda típusa	Slim Modiolar (vékony perimodioláris)	Contour Advance (vastag perimodioláris)
Betegszám	46	45
Az implantált fülek száma	54	54
Életkor (év)	25,17 ± 26,29	20,80 ± 25,87
Nem (férfi/nő)	25/29	23/31
A siketség időtartama (év)	2,94 ± 7,46	3,06 ± 9,34
A siketség oka		
veleszületett	29%	28%
progresszív	22%	26%
ismeretlen	16%	28%
egyéb	33%	17%

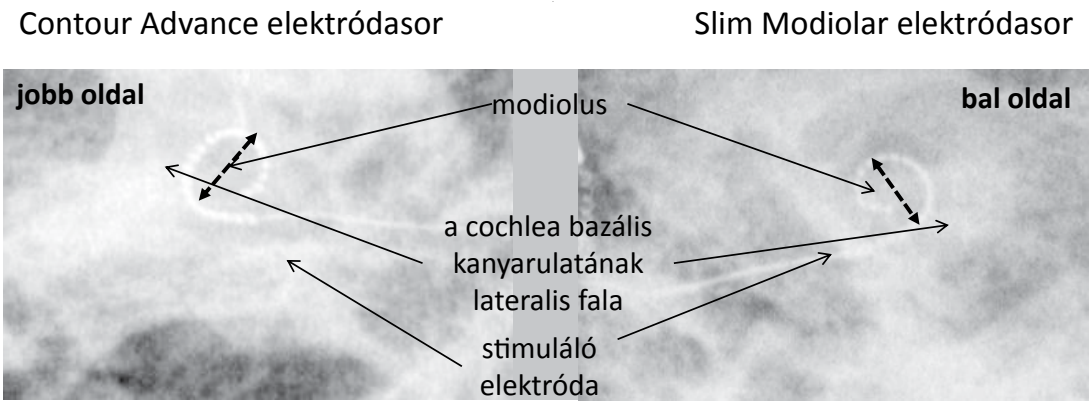

3. ábra Perimodioláris elektródasorok helyzete a cochleán belül, ugyanannál a páciensnél, szekvenciális cochlearis implantációt követően, Stenvers szerinti röntgenfelvételeken. A jobb és a bal oldali cochlea szabályos alakú és azonos méretű, amit az implantációkat megelőzően készült komputertomográfiás vizsgálaton ellenőriztünk. A jobb cochleába a vastagabb előre görbített stimuláló elektródasor (Contour Advance), a bal cochleába a vékonyabb előre görbített elektródasor (Slim Modiolar) került. A szaggatott fekete vonalak az elektródasor által a cochleán belül leírt hurok legnagyobb átmérőjét mutatják

Az első posztoperatív napon protokollunknak megfelelően digitális röntgenfelvétel készült Stenvers-nézetben [35] a beültetett implantátum helyzetének meghatározására. Jellemeztük az elektródasor és a modiolus viszonyát: a *3. ábrán* feltüntetett módon a modiolus tengelyére állított merőleges egyenesen megmértük az elektródasor által leírt hurok cochleán belüli legnagyobb átmérőjét. Összehasonlítottuk az elektródahurkok ezen átmérőit a két betegcsoportban. A statisztikai értékelést kétmintás t-próbával végeztük.

A beültetést követően két hónappal, ugyanannak a beszédprocesszornak (Cochlear™ Nucleus® CP910) az alkalmazása mellett, a készülék beprogramozása után megbecsültük a kétféle perimodioláris elektródasorral rendelkező implantátum energiafelhasználási mutatóit a Cochlear™ Custom Sound® Suite 4.4 verziójú szoftverrel.

Eredmények

A posztoperatív röntgenfelvételeken a CI532-betegcsoportban az elektródahurok cochleán belüli átlagos átmérője 4,2 ± 0,5 mm SD, míg a CI512-betegcsoportban 4,9 ± 0,1 mm SD volt (kétmintás t-próba: p = 0,00136) *(3. ábra)*.

Egyik páciensünk esetében két különböző elektródasorral végeztünk szekvenciális bilaterális implantációt: jobb oldalra CI512 típusú, bal oldalra CI532 típusú implantátumot ültettünk be másfél év különbséggel. Az elektródák perimodioláris elhelyezkedését találtuk mindkét oldalon, ugyanakkor a Slim Modiolar elektródasornak kisebb a cochleán belüli hurokátmérője.

'Tip fold-over'-t a vizsgált 108 esetünkben nem találtunk.

Az 'Auto power' szint szignifikánsan alacsonyabbnak bizonyult a CI532-betegcsoportban (44,81 ± 5,05%), mint a CI512-betegcsoportban (50,85 ± 8,35%) (p<0,05). Nagyobb 'maximaértékek' (7,50 ± 0,87 *versus* 6,56 ± 1,02) mellett is hosszabb az akkumulátor becsült életideje (napi élettartama) a vékonyabb perimodioláris elektródasor esetében *(3. táblázat)*.

Megbeszélés

A nagyfokú halláscsökkenésben szenvedő páciensek (re)habilitációjára több gyártó különféle elektródasorok-

3. táblázat Ugyanannak az implantátumcsaládnak a vékonyabb (Slim Modiolar) és vastagabb (Contour Advance) perimodioláris elektródasorával rendelkező implantátumok energiafelhasználási mutatói ugyanazzal a típusú beszédprocesszorral

Slim Modiolar elektródasor (CI532)		Contour Advance elektródasor (CI512)
44,81 ± 5,05%	*Auto power*	50,85 ± 8,35%
7,5 ± 0,87	*Maxima*	6,56 ± 1,02
43,25 ± 8,46 h	*Battery*	40,04 ± 6,48 h
19,56 ± 1,82 h	*Standard accu*	18,04 ± 2,52 h
11,5 ± 1,15 h	*Compact accu*	10,58 ± 1,51 h

Auto power: A készülékprogramozáshoz szükséges gyártói szoftver lehetővé teszi a teljesítmény automatikus vagy manuális konfigurálását minden egyes paraméterezett beállításhoz, úgynevezett MAP-hez. Ajánlott az Auto power funkció használata minden lehetséges esetben, amely hozzájárul a hangprocesszor teljesítményszintjének automatikus optimalizálásához. Miután meghatároztuk az egyes készülékbeállításhoz szükséges paramétereket, úgy az automatikusan számított teljesítményszint megjelenik a MAP-eken.
Maxima: A maximaérték az egyes beszédkódolási stratégiák paramétere (SPEAK, az ACE™ és az MP3000™); az audiojel azon spektrális felbontás után frekvenciatartományaira utal, amelyek a legnagyobb hangerősséggel rendelkeznek. Ez az érték adja meg az adott jelhez kiválasztott maximaértékek számát, tehát adott időpillanatban a maximaértéknek megfelelő számú legnagyobb hangerősséggel bíró, aktív elektródák számát.
Battery: hagyományos elem, vagyis kettő darab, 675 típusszámú, 1,45 V gombelem.
Standard accu: hagyományos akkumulátor.
Compact accu: kompakt akkumulátor, kisebb a hagyományos akkumulátornál.

kal ellátott cochlearis implantátuma áll rendelkezésre. A hallás(re)habilitáció eredményeire kihat a készülék és az elektróda egyénre szabott megválasztása. A perimodioláris elektródák modiolushoz minél közelibb elhelyezkedésének fontosságára hívja fel a figyelmet *Holden és munkatársainak* 2013-ban publikált eredménye, amely szerint a páciensek hangélményének és beszédértésének minősége elsősorban nem a bevezetett elektródasor hosszától, illetve a bevezetés mélységétől függ, hanem az elektródasor modiolushoz viszonyított helyzetétől [15].

A Contour Advance olyan, előre görbített elektródasor, amelyet belső fém vezetőszál segítségével, kiegyenesített állapotban vezetünk be a cochlea scala tympani járatába. Az 'advance off-stylet' technika jelentős eredményeket hozott az endocochlearis struktúrák sérülésének csökkentésében, ez az elektródasor a vastagsága és a fém vezetőszál miatt mégis nagyobb arányban okoz sérülést, mint a vékonyabb egyenes elektródasorok [2]. A cochleában okozott sérülések csökkentésére fejlesztették ki a szintén előre görbített, vékony és kevésbé merev Slim Modiolar típusú perimodioláris elektródasort, amelyet külső vezetőhüvely segítségével vezetünk be a cochleába. Az utóbbi a scala tympani folyadékteréből jelentősen kisebb volument foglal el a vastagabb elektródasorhoz képest, és azt is döntően a bazális membrán csontos része alatt, ami kevésbé zavarja a cochlea hidrodinamikai működését. Fontos ez a körülmény a műtét előtti hallásmaradvány megőrzésének lehetősége szempontjából [14].

A pácienseinkről rendelkezésre álló posztoperatív digitális röntgenfelvételekről határoztuk meg a stimuláló elektródák cochleán belüli helyzetét. Cone-beam CT-vel *(2. ábra),* rotációs tomográfiával vagy vékony szeletes CT-vizsgálattal részletgazdagabb képeket, ezáltal az egyes esetekben pontosabb távolságmérési adatokat kaphatnánk [24–26, 36]; ezeknek a vizsgálatoknak lényegesen nagyobb a pácienst érintő sugárterhelésük (effektív dózisuk), mint a koponya-röntgenfelvételeké, és korlátozottabban juthatunk hozzájuk a mindennapi ellátásban. Ugyanakkor a standardizált protokollnak köszönhetően a direkt digitális röntgenfelvételeken [34] is jól megállapítható a különböző elektródákkal implantált betegcsoportok közötti különbség, nagy esetszám mellett. Stenvers-felvételen a centrális sugárnyaláb a cochleán hatol keresztül, így a röntgentechnika sajátosságaként ismert nagyítás és torzítás szerepe minden vizsgálatnál csak egyformán kis, gyakorlatilag elhanyagolható mértékben jelentkezik. A szummáció szintén elhanyagolható a fém (elektróda), a csont és a lágyrészek eltérő sugárelnyelő képessége miatt. A páciensek életkorbeli különbségei a képalkotó vizsgálatok szempontjából elhanyagolhatók, mivel a belső fül méretei már a születéskor megegyeznek a felnőttkori méretekkel [37–39].

A fenti vizsgálatainkkal szignifikáns különbséget találtunk a kétféle perimodioláris elektródasor cochleán belüli hurokátmérőjében és az energiafelhasználási mutatókban, a vékonyabb elektródasor javára.

Következtetés

Képi diagnosztikai módszerrel, nagy esetszámon megállapítottuk, hogy ugyanazon termékcsalád vékonyabb perimodioláris elektródasora a vastagabb perimodioláris elektródasornál szignifikánsan közelebb kerül a modiolushoz. A CI532 energiafelhasználási mutatói jobbak a CI512 mutatóinál, tehát a vékonyabb perimodioláris elektródával alacsonyabb energiafelhasználás mellett is ugyanolyan hatékonyan stimulálható a hallóideg *(3. táblázat)*.

Az elektródasor megválasztásának fontos szempontjait (a hallásélmény, a beszédértés javítása, a hallásmaradvány megőrzése) figyelembe véve munkacsoportunk a perimodioláris elektródasorok közül a vékonyabb perimodioláris elektródasor alkalmazását tartja megfelelőnek és kívánatosnak.

Anyagi támogatás: A közlemény megírása, illetve a kapcsolódó kutatómunka anyagi támogatásban nem részesült.

Szerzői munkamegosztás: P. Á.: A protokoll kidolgozása, a mérések elvégzése, a kézirat megszövegezése. N. R., D. B.: Az elektrofiziológiai vizsgálatok elvégzése, a kézirat megszövegezése. Cs. M.: A kézirat megszövegezése. J. J.: Műtétek végzése, a kézirat megszövegezése. K. J. G.: A mérési módszer kidolgozása, statisztikai elemzés. R. L.: A protokoll kidolgozása, műtétek végzése, a kézirat megszövegezése. A cikk végleges változatát valamennyi szerző elolvasta és jóváhagyta.

Érdekeltségek: A szerzőknek nincsenek érdekeltségeik.

Köszönetnyilvánítás

A szerzők köszönetet mondanak a Szegedi Tudományegyetem Szent-Györgyi Albert Klinikai Központja Radiológiai Klinikájának és az Affidea Diagnosztika Kft.-nek a radiológiai vizsgálatok kiváló minőségben történt elvégzéséért.

Irodalom

[1] Tykocinski M, Cohen LT, Pyman BC, et al. Comparison of electrode position in the human cochlea using various perimodiolar electrode arrays. Am J Otol. 2000; 21: 205–211.
[2] Roland JT Jr. A model for cochlear implant electrode insertion and force evaluation: results with a new electrode design and insertion technique. Laryngoscope 2005; 115: 1325–1339.
[3] Wackym PA, Firszt JB, Gaggl W, et al. Electrophysiologic effects of placing cochlear implant electrodes in a perimodiolar position in young children. Laryngoscope 2004; 114: 71–76.
[4] Roland PS, Wright CG. Surgical aspects of cochlear implantation: mechanisms of insertional trauma. Adv Otorhinolaryngol. 2006; 64: 11–30.
[5] Eshraghi AA. Prevention of cochlear implant electrode damage. Curr Opin Otolaryngol Head Neck Surg. 2006; 14: 323–328.
[6] Adunka OF, Pillsbury HC, Kiefer J. Combining perimodiolar electrode placement and atraumatic insertion properties in coch-

lear implantation – fact or fantasy? Acta Otolaryngol. 2006; 126: 475–482.
[7] Skarzynski H, Matusiak M, Lorens A, et al. Preservation of cochlear structures and hearing when using the Nucleus Slim Straight (CI422) electrode in children. J Laryngol Otol. 2016; 130: 332–339.
[8] von Ilberg C, Kiefer J, Tillein J, et al. Electric-acoustic stimulation of the auditory system. New technology for severe hearing loss. ORL J Otorhinolaryngol Relat Spec. 1999; 61: 334–340.
[9] Gantz BJ, Turner C, Gfeller KE, et al. Preservation of hearing in cochlear implant surgery: advantages of combined electrical and acoustical speech processing. Laryngoscope 2005; 115: 796–802.
[10] Fraysse B, Macías AR, Sterkers O, et al. Residual hearing conservation and electroacoustic stimulation with the nucleus 24 Contour Advance cochlear implant. Otol Neurotol. 2006; 27: 624–633.
[11] Huarte RM, Roland JT Jr. Toward hearing preservation in cochlear implant surgery. Curr Opin Otolaryngol Head Neck Surg. 2014; 22: 349–352.
[12] Van Abel KM, Dunn CC, Sladen DP, et al. Hearing preservation among patients undergoing cochlear implantation. Otol Neurotol. 2015; 36: 416–421.
[13] Bento RF, Danieli F, Magalhães AT, et al. Residual hearing preservation with the EVO® Cochlear implant electrode array: preliminary results. Int Arch Otorhinolaryngol. 2016; 20: 353–358.
[14] Nagy R, Jarabin JA, Dimák B, et al. Possibilities for residual hearing preservation with Nucleus CI532 Slim Modiolar electrode array. Case report. [A maradványhallás megőrzésének lehetőségei cochlearis implantáció során Nucleus CI532 Slim Modiolar elektródasorral.] Orv Hetil. 2018; 159: 1680–1688. [Hungarian]
[15] Holden LK, Finley CC, Firszt JB, et al. Factors affecting open-set word recognition in adults with cochlear implants. Ear Hear. 2013; 34: 342–360.
[16] Buchmann CA, Dillon MT, King ER, et al. Influence of cochlear implant insertion depth on performance: a prospective randomized trial. Otol Neurotol. 2014; 35: 1773–1779.
[17] O'Connell BP, Cakir A, Hunter JB, et al. Electrode location and angular insertion depth are predictors of audiologic outcomes in cochlear implantation. Otol Neurotol. 2016; 37: 1016–1023.
[18] O'Connell BP, Hunter JB, Haynes DS, et al. Insertion depth impacts speech perception and hearing preservation for lateral wall electrodes. Laryngoscope 2017; 127: 2352–2357.
[19] Saunders E, Cohen L, Aschendorff A, et al. Threshold, comfortable level and impedance changes as a function of electrode-modiolar distance. Ear Hear. 2002; 23(Suppl): S28–S40.
[20] McKay CM, O'Brien A, James CJ. Effect of current level on electrode discrimination in electrical stimulation. Hear Res. 1999; 136: 159–164.
[21] Macias AR, Morera C, Manrique M et al. Perimodiolar electrode position: effects on thresholds, comfort levels, impedance measurements, and neural response telemetry. Mediterr J Otol. 2007; 3: 140–149.
[22] Zuniga MG, Rivas A, Hedley-Williams A, et al. Tip fold-over in cochlear implantation: case series. Otol Neurotol. 2017; 38: 199–206.
[23] Trakimas DR, Kozin ED, Ghanad I, et al. Precurved cochlear implants and tip foldover: a cadaveric imaging study. Otolaryngol Head Neck Surg. 2018; 158: 343–349.
[24] Aschendorff A, Kubalek R, Turowski B, et al. Quality control after cochlear implant surgery by means of rotational tomography. Otol Neurotol. 2005: 26: 34–37.
[25] Mittmann P, Todt I, Ernst A, et al. Radiological and NRT-ratio-based estimation of Slim Straight cochlear implant electrode positions: a multicenter study. Ann Otol Rhinol Laryngol. 2017; 126: 73–78.
[26] Hassepass F, Aschendorff A, Bulla S, et al. Radiologic results and hearing preservation with a straight narrow electrode *via* round window *versus* cochleostomy approach at initial activation. Otol Neurotol. 2015; 36: 993–1000.
[27] Lehnhardt, E. Intracochlear placement of cochlear implant electrodes in soft surgery technique. HNO 1993; 41: 356–359.
[28] MED-EL Electrode arrays. Designed for Atraumatic Implantation Providing Superior Hearing Performance. Available from: https://s3.medel.com/pdf/21617.pdf [accessed: January 4, 2019].
[29] HiFocus Electrode Family. Available from: https://advancedbionics.com/nz/en/home/products/hi-focus-electrode-family.html [accessed: January 4, 2019].
[30] Oticon electrode arrays. Available from: https://www.oticonmedical.com/-/media/medical/main/files/ci/products/ci-pi/eng/cochlear-implant-system-product-information---english---m80652.pdf?la=en [accessed: January 4, 2019].
[31] Cochlear™ Implant Electrode Comparison. Available from: https://www.cochlear.com/b29815ab-da8c-453c-a8f4-2041e6088459/FUN1142_ISS4_JUL12_Electrode_Comparison4.pdf?MOD=AJPERES&CACHEID=b29815ab-da8c-453c-a8f4-2041e6088459 [accessed: January 4, 2019].
[32] Cochlear Nucleus Profile with Slim Modiolar Electrode 532. Available from: http://www.earcentergreensboro.com/hearing-implants/cochlear_americas_ci.php#nucleus_slim_modiolar [accessed: January 4, 2019].
[33] Perényi A, Tóth F, Dimák B, et al. Angol cím [Különböző perimodiolaritású cochlearis implantátum elektródákkal elért korai szubjektív és objektív eredményeink. In: A Magyar Fül-, Orr-, Gége és Fej-, Nyaksebész Orvosok Egyesülete Audiológiai Szekciójának 54. Vándorgyűlése. Szeged, 2017. szeptember 28–30. Absztraktok.] Fül-Orr-Gégegyógyászat 2017; 63: 145–155. Available from: http://www.orl.hu/cikkek/a-magyar-ful-orr-gege-es-fej-nyaksebesz-orvosok-egyesulete-audiologiai-szekciojanak-54-vandorgyulese [accessed: February 3, 2019]. [Hungarian]
[34] Rovó L, Sprinzl G, Perényi A, et al. Early subjective and objective results with electrode types of different perimodiolar properties and the same cochlear implant electronics. J Hear Sci. 2018; 8: 250.
[35] Shpizner BA, Holliday RA, Roland JT, et al. Postoperative imaging of the multichannel cochlear implant. Am J Neuroradiol. 1995; 16: 1517–1524.
[36] Perényi Á, Bella Zs, Baráth Z, et al. Role of cone-beam computed tomography in diagnostic otorhinolaryngological imaging. [A cone-beam komputertomográfia alkalmazása a fül-orr-gégészeti képalkotásban.] Orv Hetil. 2016; 157: 52–58. [Hungarian]
[37] Dahm MC, Shephard RK, Clark GM. The postnatal growth of the temporal bone and its implications for cochlear implantation in children. Acta Otolaryngol Suppl. 1993; 505: 1–39.
[38] Bast TH. Development of the otic capsule. VI. Histological changes and variations in the growing bony capsule of the vestibule and cochlea. Ann Otol Rhinol Laryngol. 1942; 51: 343–357.
[39] Kiran AS, Varghese AM, Irodi A, et al. Radiological evaluation of cochlear orientation and its implications in cochlear implantation. Indian J Otolaryngol Head Neck Surg. 2018; 70: 1–9.

(Perényi Ádám dr.,
Szeged, Tisza Lajos krt. 111., 6725
e-mail: adam.perenyi@gmail.com)