



|                  |  |
|------------------|--|
| Title            | Assessment of the toxic impacts of acute exposure to fipronil insecticide on Japanese quails |
| Author(s)        | Mohammed, Amany Tharwat; Imam, Tamer Said; Farag, Mayada Ragab; Ghoneim, Mervat Hassan       |
| Citation         | Japanese Journal of Veterinary Research, 64(Supplement 2), S243-S249                         |
| Issue Date       | 2016-04  |
| Doc URL          | <a href="http://hdl.handle.net/2115/61998">http://hdl.handle.net/2115/61998</a>              |
| Type             | bulletin (article)   |
| File Information | p.S243-249 Amany Tharwat Mohammed.pdf  |



[Instructions for use](#)

# Assessment of the toxic impacts of acute exposure to fipronil insecticide on Japanese quails

Amany Tharwat Mohammed<sup>1,\*</sup>, Tamer Said Imam<sup>1</sup>, Mayada Ragab Farag<sup>1</sup> and Mervat Hassan Ghoneim<sup>1</sup>

<sup>1</sup>Forensic Medicine and Toxicology Department, Zagazig University, Zagazig44519, Egypt

\*Correspondence: Amany Tharwat Mohammed, E-mail, Amany\_tharwat@yahoo.com

## Abstract

The acute toxicity of fipronil on mature Japanese quails was investigated. Birds received a single oral dose of fipronil at doses of LD<sub>50</sub> (11.3 mg/kg), 1/2 LD<sub>50</sub>, 1/5 LD<sub>50</sub> and 1/10 LD<sub>50</sub>. All the birds were slaughtered 96h post administration. Specimens from liver, muscle and abdominal fat were collected for applying single cell gel electrophoresis (SCGE) technique, histopathological examination and residual analysis of fipronil. Fipronil increased the percentage of DNA damage and the histopathological alterations in tissues of quails mostly at high doses. Fipronil residues were detected in all examined samples with variable concentrations even in the tissues of control group although there was no any clinical signs or symptoms.

Key words: Fipronil, acute exposure, genotoxicity, residues, Japanese quail.

## Introduction:

Fipronil is a second-generation phenyl pyrazole insecticide which is considered as recent chemical class of pesticides introduced in the early 1990's. Fipronil used in veterinary medicine as well as a pesticide on a broad range of crops<sup>12</sup>. In addition, fipronil was designated by the Environmental Protection Agency<sup>5</sup> as one of the alternatives to the organophosphates for termites and fire-ants control. It is a highly active and broad spectrum insecticide due to its potent disruptor effect on the central nervous system (CNS) of invertebrates, by interfering the binding of the neurotransmitter gamma-amino butyric acid (GABA) to its receptor, blocking chloride ion uptake into the cells leading to uncontrolled CNS hyper excitation which consequently followed by death<sup>15,6</sup>. Fipronil is classified by EPA as "highly toxic" or "very highly toxic" to certain kinds of birds where

small amounts of fipronil kill northern bobwhite quail, red-legged partridges, and pheasants<sup>7</sup>. Genotoxicity of fipronil has been assessed in some non-target species as mice after exposure to high doses that resulted in DNA damage<sup>12</sup>. Fipronil residues has been found to be distributed in tissues of rats especially subcutaneous fat<sup>8</sup>. One of core objectives of this study was to examine the genotoxic effect of fipronil in Japanese quail via acute toxicity. Histopathological changes of liver and muscles as well as detection of fipronil residues in different tissues of tested birds were done.

## Materials and methods:

The fipronil commercial formulation (Fipronil 20% Sc) provided by Yong-nong Bioscience Co, Ltd. China was used. All other chemicals were obtained

from Sigma (St. Louis, MO, USA).

*Birds and husbandry:*

50 mature Japanese quail (*Coturnix coturnix Japonica*) weighing ( $198 \pm 10$  g) were obtained from poultry farm, Faculty of Agriculture, Zagazig University, Egypt. Birds were randomly divided into 5 equal groups (10 birds/each). Room temperature and humidity were maintained throughout the study. Birds were exposed to 16 hr light: 8 hr dark and fed *ad-libitum* and fresh water were available during the experimental period.

*Experimental design:*

Quails received fipronil at the cited LD<sub>50</sub> of 11.3 mg/kg<sup>9</sup>. Birds were fasted overnight prior to testing. Test solution (fipronil in distilled water) were freshly prepared on the day of dosing and administered to birds using a gavage needle. Birds received a single oral dose of LD<sub>50</sub> (11.3 mg/kg), 1/2 LD<sub>50</sub>, 1/5 LD<sub>50</sub> and 1/10 LD<sub>50</sub> groups (1-4) respectively. While group 5 was kept as control group which was orally administered distilled water. All the birds were slaughtered 96h post administration of fipronil.

*Sample collection and preparation:*

After slaughtering, samples from liver were collected in phosphate buffer saline for Single cell gel electrophoresis (SCGE) technique. Samples from liver and muscles were fixed in neutral buffered formalin for histopathological and kept at -20°C for the residual analysis of fipronil. techniques<sup>1</sup>. Also, samples from liver, muscles and fat were collected from birds

Single cell gel electrophoresis (SCGE); Comet assay. The Comet assay was performed under alkaline conditions according to a previously described standard protocol<sup>3</sup>. The Comets were analyzed by a visual scoring method and computerized image analysis<sup>11</sup>.

*Residual analysis:*

Samples from liver, fat and muscles were taken for analysis of fipronil residues using Aglient SampliQ (QuEChERS) European Standard EN Kits for extraction and cleanup of the pesticide residue. The pesticide in the extract is then determined by

liquid chromatography coupled to electro spray ionization tandem mass spectrometer (LC-ESI-MS/MS) operating in positive ion multiple reaction monitoring (MRM) mode.

*Statistical analysis:*

Data of the present study were statistically analyzed using general linear models procedure adapted by SAS for user's guide with one-way ANOVA. The differences among means were determined using the student Newman keuls test.

**Results:**

Signs of intoxication were observed on birds immediately after treatment. The intoxicated birds showed reduction in feed intake and body weights in fipronil- treated birds, table(1).

Some mortalities were recorded in all fipronil-treated birds, on the morning of the third day after treatment. The results of DNA damage parameters were summarized in table (2). Regarding to tail length of damaged DNA, it was significantly increased in both LD<sub>50</sub> and 1/2 LD<sub>50</sub> groups.

**Table (1): Change in body weight of Japanese quail 96 hrs post- administration of different single doses of fipronil**

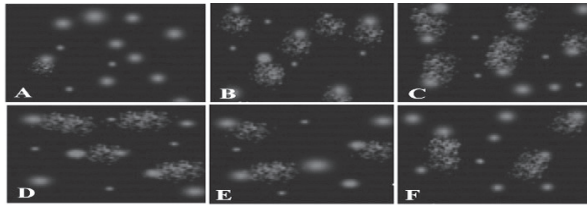
| Items                | Initial body weight (g) | Final body weight(g)     | Body weight change (g)   |
|----------------------|-------------------------|--------------------------|--------------------------|
| Control              | 198.54±6.70             | 200.66±1.55 <sup>a</sup> | 2.00±5.77 <sup>a</sup>   |
| LD <sub>50</sub>     | 200.00±1.65             | 180.33±4.40 <sup>d</sup> | -20.00±1.00 <sup>d</sup> |
| 1/2LD <sub>50</sub>  | 203.66±4.96             | 186.33±5.17 <sup>c</sup> | -17.33±2.60 <sup>c</sup> |
| 1/5LD <sub>50</sub>  | 199.66±3.40             | 194.00±2.30 <sup>b</sup> | -5.33±0.88 <sup>b</sup>  |
| 1/10LD <sub>50</sub> | 206.66±1.82             | 202.33±6.64 <sup>b</sup> | -4.66±8.19 <sup>b</sup>  |

**Table (2): DNA damage parameters in liver cells of Japanese quail 96 hrs post- administration of different single doses of fipronil**

|                       | Tail length            | Tail DNA %             | Tail moment             |
|-----------------------|------------------------|------------------------|-------------------------|
| Control               | 0.04±1.28 <sup>a</sup> | 0.02±1.57 <sup>a</sup> | 0.09±2.01 <sup>a</sup>  |
| LD <sub>50</sub>      | 0.65±7.19 <sup>d</sup> | 0.03±6.58 <sup>d</sup> | 4.57±47.38 <sup>d</sup> |
| 1/2LD <sub>50</sub>   | 0.31±5.11 <sup>c</sup> | 0.19±4.91 <sup>c</sup> | 0.58±24.90 <sup>c</sup> |
| 1/5 LD <sub>50</sub>  | 0.08±3.19 <sup>b</sup> | 0.33±3.63 <sup>b</sup> | 0.68±11.51 <sup>b</sup> |
| 1/10 LD <sub>50</sub> | 0.22±2.46 <sup>b</sup> | 0.03±3.20 <sup>b</sup> | 0.37±8.96 <sup>b</sup>  |

**Table (3): characterization of fipronil residues (ng/g wet weight) in muscle, liver and abdominal fat samples of control and treated Japanese quail (n=10)**

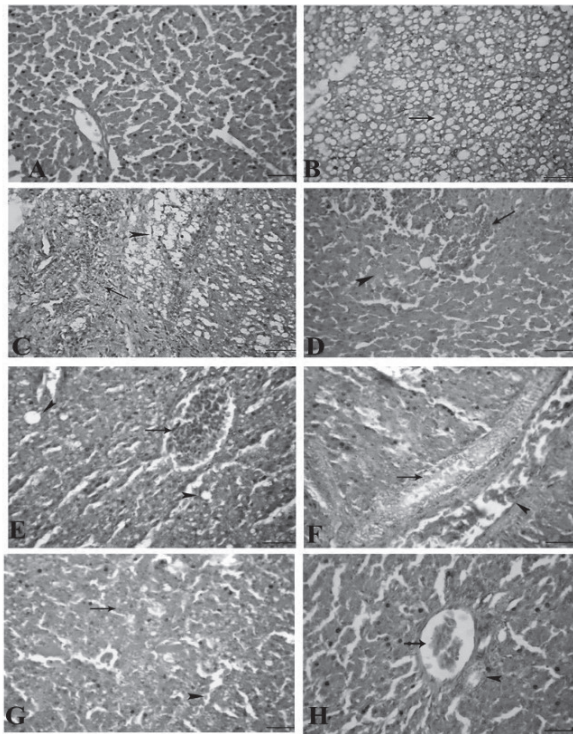
|                  | <b>Muscle</b> | <b>Liver</b> | <b>Abdominal fat</b> |
|------------------|---------------|--------------|----------------------|
| <b>Control</b>   | 1.01±0.29     | 0.51±0.11    | 10.9±0.15            |
| <b>LD50</b>      | 6.34±0.56     | 4.36±0.88    | 9.25±0.33            |
| <b>½ LD50</b>    | 4.02±0.33     | 1.53±0.57    | 5.22±0.38            |
| <b>1/5 LD50</b>  | 2.76±0.21     | 1.97±0.27    | 17.1±0.22            |
| <b>1/10 LD50</b> | N/A           | 7.22±0.22    | 9.01±0.71            |



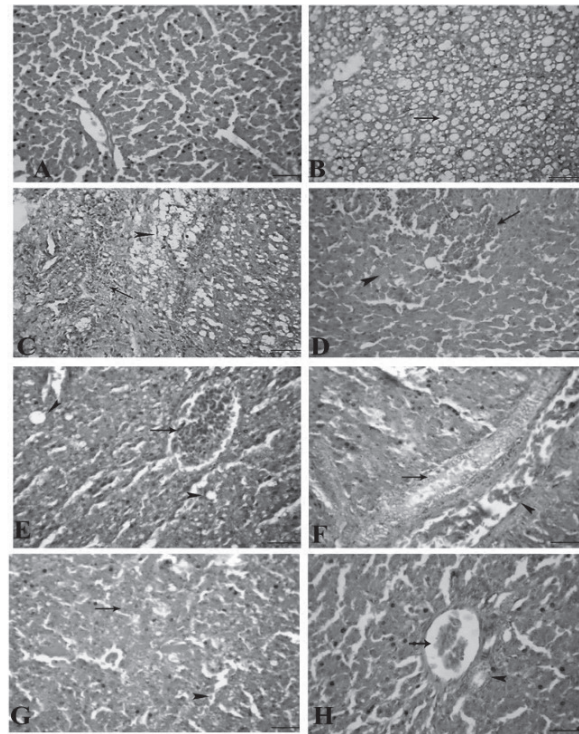
**Figure (1): Images of cells derived from A, liver of quail of control. B and C fipronil LD<sub>50</sub> - treated group. D , 1/2 LD<sub>50</sub> -treated group. E, 1/5 LD<sub>50</sub> treated group. F, 1/10 LD<sub>50</sub> -treated group using comet assay.**

Similar results were seen regarding to tail DNA% and tail moment of damaged DNA (Fig.1)

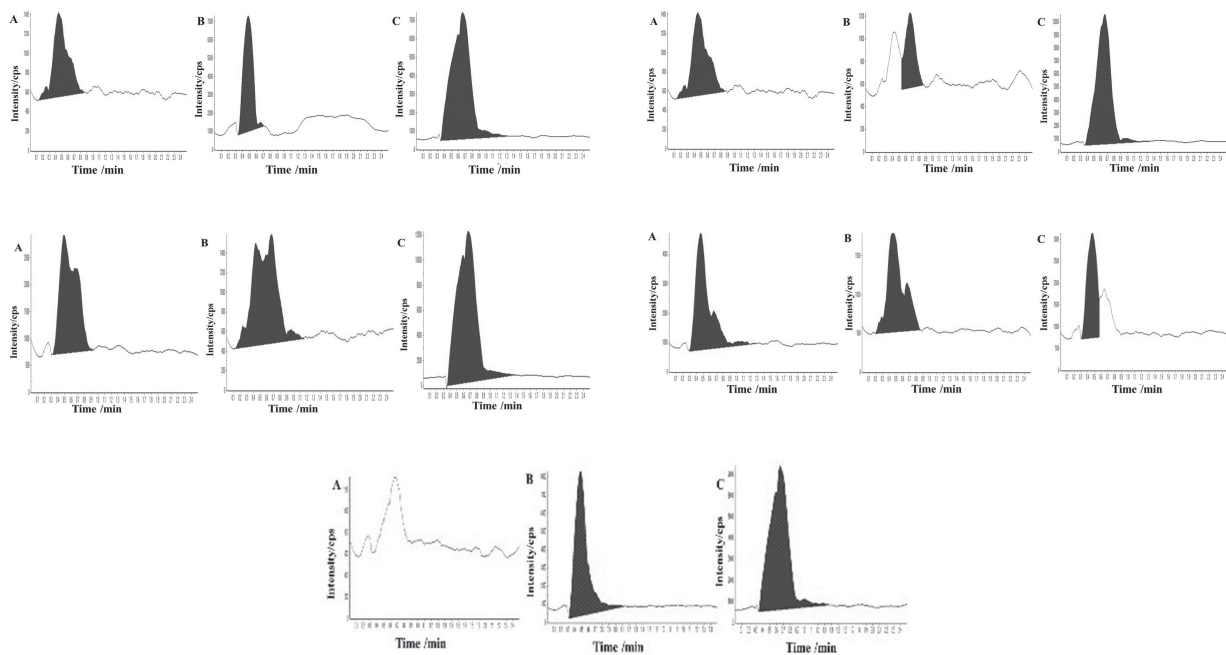
The liver of fipronil- LD<sub>50</sub> - treated quails showed interstitial and portal aggregations of round cells, and various types of cell injuries mainly fatty change (Fig 2B). Sometimes, the portal areas revealed hyperplasia in the biliary epithelia (Fig 2C). The kupffer cells were hypertrophied and rarely contained dark brown pigments of hemosiderin. Coagulative necrosis were visualized throughout the hepatic parenchyma (Fig 2D). The liver of (1/2 LD50-group) showed coagulative necrosis scattered through the hepatic tissue, (Fig, 2F).



**Fig. 2.** Photomicrographs of quail liver : A ,control shows normal hepatic parenchyma. B, liver of fipronil-LD50 treated quails showing diffuse fatty change.C, hyperplasia in the biliary epithelia.D, hypertrophy of kupffer cells with dark brown pigments of hemosiderin. E, liver of 1/2LD50-group showing congestion and vacuolation of hepatocytes . F coagulative necrosis in the hepatic tissue and hyperplasia in the lining epithelium of the bile duct.G, liver of 1/5 LD50-group revealed acute cell swelling in the hepatocytes. H, liver of 1/10 LD50-group showing mild hyperplasia in the biliary epithelia



**Fig.3.** The skeletal muscles of A, control group showing normal architecture. B Skeletal, muscles of LD50 - group showing congestion, hemorrhages and interstitial edema. C, focal Zenker's necrosis. D 1/2LD50 -group showing hyaline degeneration E Muscles of 1/5 LD50-group showing focal hyaline degeneration . F Muscles of 1/10 LD50- group were mostly normal and others hyalinized



**Fig.4.** GC-ECD chromatogram showing the concentration of fipronil residues in A, Muscle. B, Liver and C, Abdominal fat Japanese quail of control group(1), LD<sub>50</sub> group(2),  $\frac{1}{2}$  LD<sub>50</sub> fipronil group(3),  $\frac{1}{5}$  LD<sub>50</sub>fipronil group, and  $\frac{1}{10}$  LD<sub>50</sub> fipronil group(5). Retention time is (0.543) 0.543minutes

Hypertrophy and proliferation of the kupffer cells were focally noticed. The liver of  $\frac{1}{5}$  LD<sub>50</sub>-group revealed cell swelling of some hepatocytes and few extravasated erythrocytes (Fig 2G). While in liver of ( $\frac{1}{10}$  LD<sub>50</sub>-group) showed slight congestion and mild hyperplasia in the biliary epithelia (Fig 2H). Treatment of quail by LD<sub>50</sub> from fipronil, results in severe alterations in skeletal muscle structure where, muscles showed congestion, hemorrhages and interstitial edema (Fig 3, B) and focal Zenker's necrosis in the muscle fibers, myocytolysis (Fig 3, C). ( $\frac{1}{2}$  LD<sub>50</sub>-group) revealed hyaline degeneration in some muscle fibers (Fig 3, D). Muscles of  $\frac{1}{5}$  LD<sub>50</sub>-group showed also focal hyaline degeneration in some muscle fibers (Fig 3, E). Muscles of  $\frac{1}{10}$  LD<sub>50</sub>-group were mostly normal and others showed focal hyaline degeneration in some muscle fiber (Fig 3, F) Characterization of fipronil residues in different tissue samples are summarized in table (3) and represented by figures (4). Where fipronil residues found to be retained and detected in all muscle,

liver and abdominal fat samples of Japanese quail with variable concentrations even in the tissues of control group although there were no clinical signs or symptoms, except the muscles from ( $\frac{1}{10}$ LD<sub>50</sub>) where there was no detectable residues in the studied samples, however the liver samples of this group revealed the highest concentration of fipronil residues among all other liver samples.

## Discussion

In the present study, the reduction in feed intake and body weights together with mortalities among the different treated groups was consistent with previous studies on some fipronil-sensitive galliform species as bobwhite quail, ring-necked pheasant and red-legged partridge<sup>14</sup>.

The present study depicted an obvious increase in the parameters of DNA damage in liver cells (tail%, tail length, DNA tail % and tail moment)

which was more pronounced in LD<sub>50</sub> and 1/2 LD<sub>50</sub> groups indicating the genotoxic and mutagenic potentials of fipronil. The genotoxic effects of fipronil has been analyzed by<sup>13)</sup> in peripheral blood of mice. In this experiment, liver showed reliable pathological lesions which were more intensive in quails received the higher doses (LD<sub>50</sub> and 1/2 LD<sub>50</sub>) of fipronil than in the other doses. These results were accordance with<sup>2)</sup> who found that after acute exposure to fipronil, there was per sinusoidal dilatation with erythrocytes aggregations within sinusoids in liver of rats. Skeletal muscles of quail in our study exhibited Zenker's necrosis in the muscle fibers, myocytolysis, congestion, hemorrhages and interstitial edema. The fore mentioned changes are in line with an earlier study of<sup>10)</sup>. The results of fipronil residual analysis, revealed the ability of fipronil to be distributed and retained in different body tissues after single exposure to different doses. The results of the present study are totally agreed with an earlier study by<sup>15)</sup> in which a single oral administration of fipronil to rats resulted in substantial amounts of residues in various tissues, with predominance in adipose tissue and to a lesser extent in adrenal. Similar findings to our study were reported by<sup>9)</sup> who found that a single oral dose of fipronil in northern bobwhite quail. Our results are also in line with<sup>4)</sup> who studied tissue distribution; metabolic fate and the elimination of fipronil in rats after a single oral dose where the highest levels were found in adipose tissue and liver. Our results are consistent with these values and confirm that adipose tissue can represent a reservoir of fipronil residues.

### Conclusion:

From the obtained results a conclusion could be drawn on the toxic effects of fipronil to non-target organisms. Where, the retention of fipronil in tissues of quails beside its genotoxic effect and structural alterations provide further insight

and confirmed the previous works concerning hazardous effects of fipronil

### References

- 1) Bancroft, G. D. and Stevens, A. 1996. Theory and practice of histopathological technique. 4<sup>th</sup> edition, Churchill Livingstone Edinburgh, London, Sherborn and New York.
- 2) Begymbetova, D. A., S. Kolum-baeva, Zh. and Lovynskaya. A .V. 2011. Toxic effect of fipronil on rats of different age, al-Farabi Kazakh National University.
- 3) Collins, A. R. and Dunsinka, M. 2002. Oxidation of cellular DNA measured with the comet assay. In Armstrong D. (ed.), Methods in Molecular Biology: Oxidative stress Biomarkers and antioxidant Protocols (Humana Press, New Jersey). pp147-159.
- 4) Cravedi, J. P., Delous, G., Zalko, D., Viguie C. and Debrauwer, L. 2013. Desposition of fipronil in rats. *Chemosphere*. **93**: 2276-2283.
- 5) EPA. Fipronil Pesticide Fact Sheet. 1996. PB96-181516. EPA- 737-F- 6-005. U.S. Environmental Protection Agency, Office of Prevention, Pesticides and Toxic Substances. Washington, DC.
- 6) Gunasekara, A. S., Truong, T., Goh, K. S., Spurlock, F. and Tjeerdema, R. S. 2007. Environmental fate and toxicology of fipronil. *J. Pestic. Sci.* **32**: 189-199.
- 7) Hainzl, D., Cole, L. M. and Casida, J. E. 1998. Mechanisms for selective toxicity of fipronil insecticide and its sulfone metabolite and defulfinyl photoproduct. *Chem. Res. Toxicol.* **11**: 1529-1535.
- 8) Hugnet, C., Cadore, J. L. and Bourdoiseau, G. 1999. use of fipronil spray (0.25%) for the treatment of *Damalinea equi* [ (*Wereckiella equi*) infestation]. *Prat. Vet. Equ.* **31**: 65-68.
- 9) Kitulagodage, M. , John, I., William, A. B, Michael J. H. and Lee B. A. 2011a: Fipronil toxicity in northern bobwhite quail *Colinus*

- virginianus: Reduced feeding behavior and sulfone metabolite formation. *Chem.* **83**: 524-530.
- 10) Ling, S. and Zhang, R. 2011. Effect of fipronil on brain and muscle ultra structure of Nilaparvatalugens (Homoptera:Delphacidae). *Ecotoxicol. Environ Safety* **74**: 1348-1354.
- 11) Liu, X., Yao, J., Pisha, E., Yang, Y., Hua, Y., Breemen, R. B. and Bolton J. L. 2002: Oxidative DNA damage induced in equine estrogen metabolites: role of estrogen receptor alpha. *Chem. Res. Toxicol.*; **15**: 512-519.
- 12) Ohi, M., Dalsenter, P. R., Andrade, A. J. M. and Nascimento, A. J. 2004. Reproductive adverse effects of fipronil in wistar rats. *Toxicol. Lett.* **146**: 121-127.
- 13) Oliveira P. R., Gervsio, H. B, Sandra, E. D., Rodrigo J. O. and Maria I. C. M. 2012. Genotoxic and mutagenic effects of fipronil on mice. *Exper. Toxicol. Pathol.* **64**: 569-573.
- 14) Stavola, A., 1994a. DER. Review. M&B 46030: Acute Oral Toxicity (LD50) to the Pheasant. Submitted by Rhone-Poulenc Agriculture Company, Research Triangle Park, USA. MRID No. 429186-15 USEPA, Ecological Effects Branch.
- 15) Tingle, C. C., Rother, J. A., Dewhurst, C. F., Lauer, S. and King, W. J. 2003. Fipronil: environmental fate, ecotoxicology and human health concerns. *Rev. Environ. Contam. Toxicol.* **176**: 1-66.