



Title	Measurement of interleukins in vitreous infusion fluid
Author(s)	Kase, Satoru; Yokoi, Masahiko; Ishida, Susumu; Kase, Manabu
Citation	Biomedical reports, 3(6), 818-820 <a href="https://doi.org/10.3892/br.2015.509">https://doi.org/10.3892/br.2015.509</a>
Issue Date	2015-11
Doc URL	<a href="http://hdl.handle.net/2115/61458">http://hdl.handle.net/2115/61458</a>
Type	article
File Information	br_3_6_818_PDF.pdf



[Instructions for use](#)

# Measurement of interleukins in vitreous infusion fluid

SATORU KASE<sup>1,2</sup>, MASAHIKO YOKOI<sup>1</sup>, SUSUMU ISHIDA<sup>2</sup> and MANABU KASE<sup>1</sup>

<sup>1</sup>Department of Ophthalmology, Teine Keijinkai Hospital, Sapporo, Hokkaido 006-0811; <sup>2</sup>Department of Ophthalmology, Hokkaido University Graduate School of Medicine, Sapporo, Hokkaido 060-8638, Japan

Received July 14, 2015; Accepted July 29, 2015

DOI: 10.3892/br.2015.509

**Abstract.** Measurements of interleukin (IL)-6 and -10 concentrations in the vitreous can be used to differentiate intraocular lymphoma (IOL) from uveitis. This is the first study reporting the IL-6 and -10 concentrations in the undiluted vitreous fluid and vitreous infusion fluid, which were simultaneously examined in the patients. A total of 2 females presented with intraocular inflammation, and underwent pars plana vitrectomy. Undiluted anterior vitreous and vitreous infusion fluid were collected simultaneously. IL concentrations were determined by enzyme-linked immunosorbent assay systems. Vitreous infusion fluid of 20 ml was eventually collected following completion of core vitrectomy in the two patients. IL-6 concentrations of the first patient were 513 and 106 pg/ml in the undiluted vitreous and the infusion fluid, respectively, while those of the second patient were 263 and 29 pg/ml. By contrast, IL-10 was under the detectable levels in all the fluids. The IL-10/-6 ratio was <1 in both fluids in the patients. Cytological examination revealed the presence of reactive inflammatory cells in the vitreous fluid. The two patients were eventually diagnosed with uveitis. Measurements of IL concentrations in the vitreous infusion fluid provided significant evidence on the differential diagnosis between IOL and uveitis, when considering how vitreous infusion fluid was diluted. The present study highlighted a novel application of cytokine analyses using the vitreous infusion fluid, which may contribute to the development of future translational researches on uveitis/IOL patients.

## Introduction

A cytological examination using the vitreous fluid based on the clinical ocular findings is important for differential diagnoses between intraocular lymphoma (IOL) and uveitis (1,2). The diagnostic probability by the cytological examinations, however, varies in each IOL case (1,3). Due to the uncertain results in

cytological analysis with vitreous fluid, studies have reported that measurements of interleukin (IL)-6 and -10 concentrations in the vitreous can be used to identify IOL (1). A recent basic study demonstrated that not only the IL-10/-6 ratio, but also a combination of other cytokine analyses in intraocular fluid, may contribute to an accurate diagnosis for uveitis/IOL (4). Although undiluted vitreous fluid may be an appropriate material for cytokine analysis, the undiluted fluid obtained by vitrectomy or probing from the pars plana is critically limited in volume. Therefore, cytokine analysis using vitreous fluid for clinical or basic study has yet to be elucidated. Therefore, the present study reports 2 patients diagnosed with panuveitis who underwent vitrectomy. Additionally, to the best of our knowledge, this is the first report showing IL-6 and -10 concentrations in the undiluted vitreous fluid and vitreous infusion fluid, which were simultaneously examined in the same patients.

## Case reports

*Patient 1.* An 81-year-old female had complained of blurred vision in both eyes for 3 months. The patient was referred to the Teine Keijinkai Hospital (Sapporo, Hokkaido, Japan) for evaluation and management on October 7, 2013. The patient provided written informed consent. Visual acuity was 0.5 right eye [oculus dexter OD] and 0.01 left eye [oculus sinister OS]. Intraocular pressure was normal. Slit-lamp examination revealed 1+ flare and 1+ cells in the anterior chamber with keratic precipitates oculus uterque (OU). Fundus examination demonstrated marked diffuse vitreous opacity and subretinal exudates with an unclear margin (Fig. 1A). Fluorescein angiography revealed multiple leakages from subretinal exudates. Optical coherence tomography (OCT) exhibited submacular fluids filled with high reflective lesions (Fig. 1B). Results in serological tests and systemic imaging modalities were not noteworthy. Therefore, it was mandatory to make differential diagnoses of panuveitis or IOL in this case. A 23-gauge pars plana vitrectomy was conducted in the left eye on October 15. Prior to performing core vitrectomy, undiluted anterior vitreous fluid was gained while an infusion system was stopped and the pressure was carefully maintained by indentation of the sclera to prevent the eyeball from collapsing. On that occasion, the indentation of the sclera by a scleral depressor made it easier to gather vitreous gel and fluid near the vitreous base. Subsequently, central vitreous gel and fluid were removed with an active infusion system. IL-6 and -10 concentrations were determined by a conventional

---

*Correspondence to:* Dr Satoru Kase, Department of Ophthalmology, Hokkaido University Graduate School of Medicine, Nishi 7, Kita 15, Sapporo, Hokkaido 060-8638, Japan  
E-mail: kaseron@med.hokudai.ac.jp

*Key words:* interleukin, vitreous infusion fluid, diagnosis

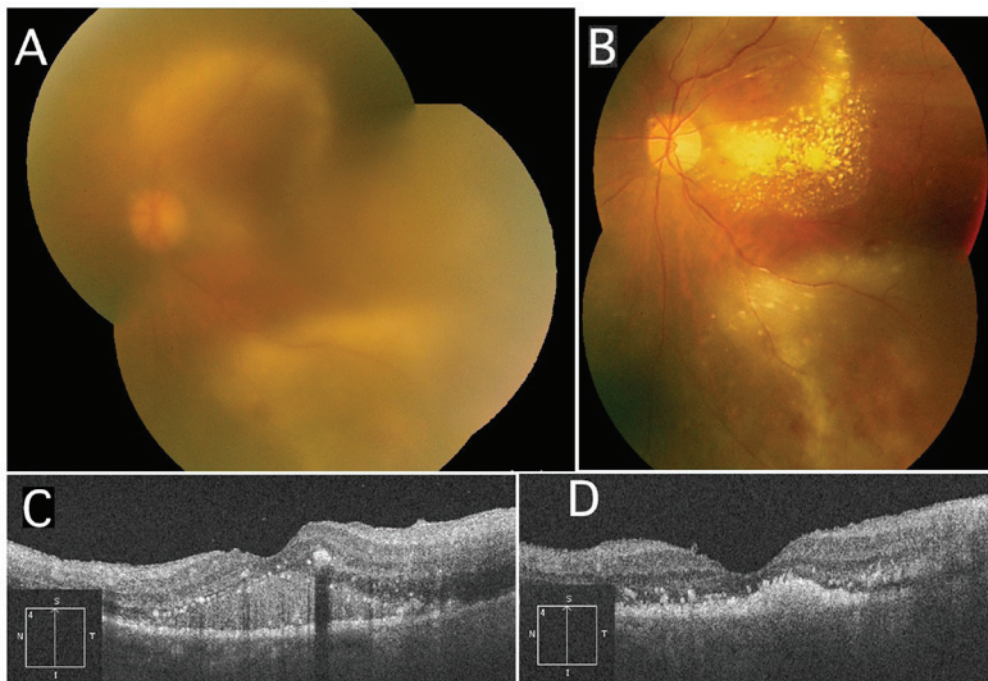


Figure 1. Fundus examination and optical coherence tomography (OCT) prior and subsequent to the treatments in patient 1. (A) Fundus examination shows marked vitreous opacity and subretinal exudates with an unclear margin. (B) Subsequent to the vitrectomy and corticosteroid administration, fundus demonstrates a marked hard exudates within the arcade, together with improved subretinal lesions and vitreous opacity. (C) OCT exhibits submacular fluids filled with high reflective lesions. (D) OCT reveals resolution of submacular lesions.

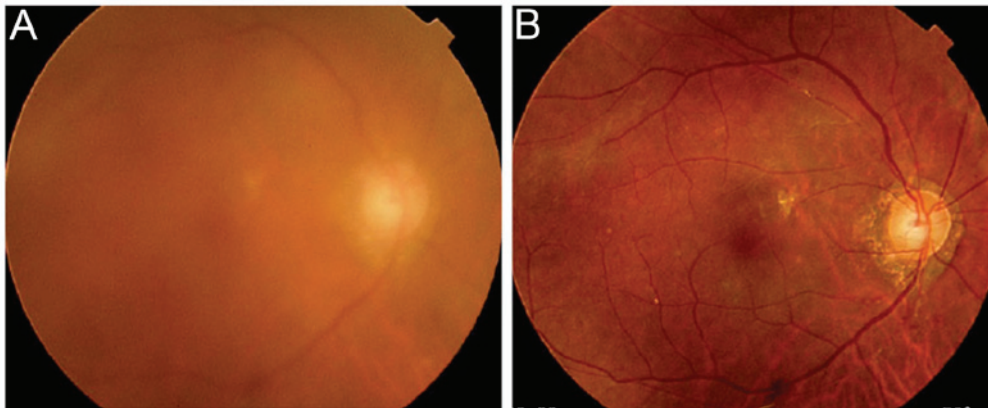


Figure 2. Fundus examination prior and subsequent to the vitrectomy in patient 2. (A) Fundus examination shows marked vitreous opacity, (B) which are resolved following vitrectomy.

enzyme linked immunosorbent assay system. The patient was administered 80 mg methyl-prednisolone intravenously for 2 days, which was thereafter changed to oral administration of 40 mg prednisolone, which was tapered gradually. Fundus showed marked hard exudates within the arcade together with reduced subretinal lesions and vitreous opacity (Fig. 1C). OCT exhibited resolution of submacular lesions (Fig. 1D). Visual acuity improved to 0.05 OS in November 2013.

**Patient 2.** A 79-year-old female had complained of blurred vision in both eyes following cataract surgery in 2012. The patient provided written informed consent. Visual acuity was 0.4 OU. Intraocular pressure was normal. Slit-lamp examination revealed 1+ flare and 1+ cells in the anterior chamber with keratic precipitates OU. Fundus examination demonstrated

diffuse vitreous opacity, and subretinal hemorrhage and exudates (Fig. 2A). Fluorescein angiography revealed several leakages from the retinal vessels. OCT exhibited mild macular edema OS. The patient was administered 30 mg oral corticosteroid for 3 months; however, the vitreous opacity and exudates were not resolved. A 23-gauge pars plana vitrectomy was conducted to make a diagnosis in the right eye in June 2014. Undiluted anterior vitreous fluid was obtained by the same vitrectomy way as in patient 1, however, not near the vitreous base by indentation. Subsequently, diluted infusion fluid was gained. The fluid was submitted for measurements of IL-6 and -10 concentrations, as described in patient 1. No additional treatments were required and visual acuity remained 0.6 OD (Fig. 2B). Intraocular inflammation did not recur during a follow-up period.

**Interleukin concentrations.** Approximately 800  $\mu$ l of undiluted anterior vitreous fluid was collected, whereas vitreous infusion fluid of 20 ml was eventually collected following core vitrectomy in the two patients. IL-6 concentrations were 513 and 106 pg/ml in the undiluted vitreous and the infusion fluid in patient 1, and 263 and 29 pg/ml in patient 2, respectively. By contrast, IL-10 was under the detectable levels in all the fluids. Cytological examinations using the infusion fluids showed numerous cluster of differentiation 68 (CD68)-positive macrophages infiltrating the vitreous, whereas reactive CD3 and CD20-positive T and B-cells were not identified in patient 1. A few small lymphoid cells were present in the fluid in patient 2.

## Discussion

In the present study, IL-6 and -10 in the undiluted anterior vitreous fluid and infusion vitreous fluid were simultaneously measured in 2 uveitis patients, showing that concentrations of IL-6 in the former and latter fluid were 513 and 106 pg/ml in patient 1, and 263 and 29 pg/ml in patient 2, respectively. By contrast, IL-10 concentrations were under the detectable levels in the two cases. The IL-10/-6 ratio was  $<1$  in the two fluids in each patient. These findings strongly indicate that severe inflammation was caused by uveitis rather than IOL (1). The value of IL-6 concentration was significantly high in the undiluted fluid, comparing with that in the diluted infusion fluid in the two patients. Thus, the present study potentially shows that the measurement of IL analysis with vitreous fluid was useful for differential diagnosis between uveitis and IOL. Furthermore, it is indicated that the dilution rate of the concentrations in vitreous infusion fluid was different among individuals, as this difference may be associated with the infusion volume during vitrectomy or width of the vitreous fluid removed. Therefore, in case of these analyses using the

fluid diluted with infusion water during vitrectomy, it is of note that the values of cytokine concentration were too small in the diluted vitreous infusion fluid as shown in the present study.

The values of IL-6 concentration in the undiluted fluid were also different between the two cases. These results may be based on the regional differences in IL-6 concentration within the vitreous cavity, as peripheral vitreous gel and liquid were clearly gathered to the vitreous base in patient 1 but not in patient 2. By contrast, the severity in intraocular inflammation was likely to be responsible for this difference.

In conclusion, measurements of IL concentrations in vitreous infusion fluid provide with significant evidence on the differential diagnosis between IOL and uveitis, when considering how vitreous infusion fluid was diluted. Therefore, the present study highlighted a novel application of cytokine analyses using the vitreous infusion fluid, which may contribute to the development of future translational research on uveitis/IOL patients.

## References

1. Kimura K, Usui Y and Goto H; Japanese Intraocular Lymphoma Study Group: Clinical features and diagnostic significance of the intraocular fluid of 217 patients with intraocular lymphoma. *Jpn J Ophthalmol* 56: 383-389, 2012.
2. Kase S, Namba K, Jin XH, Kubota KC and Ishida S: Spontaneous regression of intraocular lymphoma. *Ophthalmology* 119: 1083-1084, 2012.
3. Sugita S, Takase H, Sugamoto Y, Arai A, Miura O and Mochizuki M: Diagnosis of intraocular lymphoma by polymerase chain reaction analysis and cytokine profiling of the vitreous fluid. *Jpn J Ophthalmol* 53: 209-214, 2009.
4. Fisson S, Ouakrim H, Touitou V, Baudet S, Ben Abdelwahed R, Donnou S, Miloudi A, Galand C, Bodaghi B, Lehoang P, *et al*: Cytokine profile in human eyes: Contribution of a new cytokine combination for differential diagnosis between intraocular lymphoma or uveitis. *PLoS One* 8: e52385, 2013.