



Title	Multi-institutional retrospective study for the evaluation of ocular function-preservation rates in maxillary sinus squamous cell carcinomas with orbital invasion
Author(s)	Sakashita, Tomohiro; Hayashi, Ryuichi; Homma, Akihiro; Matsuura, Kazuto; Kato, Kengo; Kawabata, Kazuyoshi; Monden, Nobuya; Hasegawa, Yasuhisa; Onitsuka, Tetsuro; Fujimoto, Yasushi; Iwae, Shigemichi; Okami, Kenji; Matsuzuka, Takashi; Yoshino, Kunitoshi; Fujii, Masato
Citation	Head & Neck, 37(4), 537-542 <a href="https://doi.org/10.1002/hed.23639">https://doi.org/10.1002/hed.23639</a>
Issue Date	2015-04
Doc URL	<a href="http://hdl.handle.net/2115/61134">http://hdl.handle.net/2115/61134</a>
Rights	This is the peer reviewed version of the following article: Sakashita, T., Hayashi, R., Homma, A., Matsuura, K., Kato, K., Kawabata, K., Monden, N., Hasegawa, Y., Onitsuka, T., Fujimoto, Y., Iwae, S., Okami, K., Matsuzuka, T., Yoshino, K. and Fujii, M. (2015), Multi-institutional retrospective study for the evaluation of ocular function-preservation rates in maxillary sinus squamous cell carcinomas with orbital invasion. Head Neck, 37: 537-542, which has been published in final form at <a href="http://doi.org/10.1002/hed.23639">http://doi.org/10.1002/hed.23639</a> . This article may be used for non-commercial purposes in accordance with Wiley Terms and Conditions for Self-Archiving: <a href="http://olabout.wiley.com/WileyCDA/Section/id-820227.html#terms">http://olabout.wiley.com/WileyCDA/Section/id-820227.html#terms</a>
Type	article (author version)
File Information	manuscript.pdf



[Instructions for use](#)

**Title:** A multi-institutional retrospective study for the evaluation of ocular function preservation rates in maxillary sinus squamous cell carcinomas with orbital invasion.

**Authors:** Tomohiro Sakashita, M.D.<sup>1</sup>, Ryuichi Hayashi, M.D.<sup>2</sup>, Akihiro Homma, M.D., Ph.D.<sup>1</sup>, Kazuto Matsuura, M.D., Ph.D.<sup>3</sup>, Kengo Kato, M.D., Ph.D.<sup>4</sup>, Kazuyoshi Kawabata, M.D., Ph.D.<sup>5</sup>, Nobuya Monden, M.D., Ph.D.<sup>6</sup>, Yasuhisa Hasegawa, M.D., Ph.D.<sup>7</sup>, Tetsuro Onitsuka, M.D., Ph.D.<sup>8</sup>, Yasushi Fujimoto, M.D., Ph.D.<sup>9</sup>, Shigemichi Iwae, M.D., Ph.D.<sup>10</sup>, Kenji Okami, M.D., Ph.D.<sup>11</sup>, Takashi Matsuzuka, M.D., Ph.D.<sup>12</sup>, Kunitoshi Yoshino, M.D., Ph.D.<sup>13</sup>, Masato Fujii, M.D., Ph.D.<sup>14</sup>

**Departments:**<sup>1</sup> Department of Otolaryngology-Head and Neck Surgery, Hokkaido University Graduate School of Medicine, Sapporo, Japan.

<sup>2</sup> Division of Head and Neck Surgery, National Cancer Center Hospital East, Kashiwa, Japan.

<sup>3</sup> Division of Head and Neck Surgery, Miyagi Cancer Center, Sendai, Japan.

<sup>4</sup> Department of Otolaryngology-Head and Neck Surgery, Tohoku University School of Medicine, Sendai, Japan.

<sup>5</sup> Department of Head and Neck Oncology, Cancer Institute Hospital, Japanese Foundation for Cancer Research, Tokyo, Japan.

<sup>6</sup> Department of Otorhinolaryngology-Head and Neck Surgery, National Shikoku Cancer Center, Matsuyama, Japan

<sup>7</sup> Department of Head and Neck Surgery, Aichi Cancer Center, Nagoya, Japan.

<sup>8</sup> Department of Head and Neck surgery, Shizuoka Cancer Center, Shizuoka, Japan.

<sup>9</sup> Department of Otolaryngology, Nagoya University Graduate School of Medicine, Nagoya, Japan.

<sup>10</sup> Department of Head and Neck Surgery, Hyogo Cancer Center, Akashi, Japan.

<sup>11</sup> Department of Otolaryngology, Tokai University, Isehara, Japan.

<sup>12</sup> Department of Otolaryngology, Fukushima Medical University, Fukushima, Japan.

<sup>13</sup> Department of Otolaryngology, Head and Neck Surgery, Osaka Medical Center for Cancer and Cardiovascular Diseases, Osaka, Japan.

<sup>14</sup> Department of Otorhinolaryngology, National Tokyo Medical Center, Tokyo, Japan.

**Financial support:** None.

**Conflict of interest:** None.

**Corresponding author:** Akihiro Homma

**Reprint requests:** Department of Otolaryngology-Head and Neck Surgery, Hokkaido University Graduate School of Medicine. Kita 15, Nishi 7, Kita-ku, Sapporo 060-8638, Japan

Phone: +81-11-707-3387; Fax: +81-11-717-7566;

E-mail address: [ak-homma@med.hokudai.ac.jp](mailto:ak-homma@med.hokudai.ac.jp)

**Key words:** maxillary sinus cancer, orbital invasion, ocular function, squamous cell carcinoma, chemoradiotherapy

**Running title:** The evaluation of ocular function preservation rates in maxillary sinus cancer.

## **ABSTRACT**

**Background.** This study aimed to evaluate ocular function and survival rates among treatment modalities in patients with maxillary sinus cancer with orbital invasion.

**Methods.** Eighty-seven patients were classified according to the main treatment modality. Ocular function preservation rates and survival rates were evaluated for each therapeutic modality.

**Results.** The 5-year overall survival rate for the en bloc resection, conservative surgery, superselective intra-arterial chemotherapy and radiotherapy (RADPLAT), intra-venous chemoradiotherapy (IV-CRT) was 70%, 35%, 49%, and 31%, respectively. Ocular function preservation rate for each group was 15%, 27%, 30%, and 17%, respectively. In the en bloc resection group, there was no significant difference in the 5-year overall survival rate between patients with orbital exenteration and those without orbital exenteration (72% vs 71%,  $p=0.9321$ ).

**Conclusions.** The en bloc resection group showed a favorable survival rate, but a low preservation rate. Preservation of orbital contents did not reduce the survival rate.

## **INTRODUCTION**

The majority of patients with maxillary sinus cancer are diagnosed in the locally advanced stage. Orbital invasion occurs in 60% to 80% of maxillary sinus malignancies [1]. In such cases, it is still controversial whether the orbital contents should be preserved or not when en bloc surgical resection is indicated. The two main points of contention are the oncological safety of orbital preservation and the functional outcome in the preserved eyes. The indications and need for orbital exenteration have recently evolved with improvements in diagnostic imaging modalities. It was reported that orbital preservation was oncologically safe in selected cases and did not reduce the rate of cure or local control [1-2].

In addition, Nishino *et al.* reported the results of conservative surgery combined with radiotherapy and chemotherapy, in which two-stage surgical treatments, including antrostomy and minimally invasive segmental maxillary resection, were performed for the purpose of preserving maxilla and ocular function. This conservative multidisciplinary therapy was reported to be feasible for the treatment of advanced maxillary sinus cancer and enable preservation of orbital contents by use of a surgical microscope [3,4].

Further, superselective intra-arterial chemotherapy and concomitant radiotherapy (RADPLAT) has been attempted for preserving the orbital contents and ocular function in patients with advanced maxillary sinus cancer. This non-surgical treatment was reported to be both safe and highly effective [5,6].

There have been no reports on survival rates and ocular function among the various treatment modalities because of the low incidence of maxillary sinus cancer. Recently, a multi-institutional joint research program for maxillary sinus cancer was undertaken in Japan. Twenty-eight institutions participated in this research and the data for 128 patients were obtained. This study was aimed at evaluating ocular function preservation rates and survival rates among treatment modalities in patients with maxillary sinus cancer with orbital invasion.

## **MATERIALS AND METHODS**

The data for 128 patients with previously untreated maxillary sinus squamous cell carcinomas were obtained from 28 institutions belonging to the Head and Neck Cancer Study Group of the Japan Clinical Oncology Group (JCOG) between January 2006 and December

2007. The therapeutic strategy varied widely among the institutions. The maxillary sinus cancer involved the orbital contents in 94 patients. Of these 94 patients, five patients underwent palliative therapy because of distant metastasis or their general condition. In addition, two patients were treated at other institutions for their wishes. These seven patients were excluded from the analysis. The remaining 87 patients were eligible for this study. Table 1 shows patient demographics.

This study was a retrospective analysis. Therefore, the selection criteria for therapeutic modality were decided according to the policy of each institution or individual patient preference. This multi-institutional joint research has been representatively approved by the appropriate ethical committees in the National Hospital Organization Tokyo Medical Center, Tokyo, Japan.

Eighty-seven patients were classified according to the main treatment modality under five categories, such as the en bloc resection group, the conservative surgery group, the RADPLAT group, the intra-venous chemoradiotherapy (IV-CRT) group, and the radiation alone group. The en bloc resection group consisted of patients undergoing total maxillectomy with or without orbital exenteration. The conservative surgery consisted of two-stage conservative surgery, combining antrostomy and minimally invasive segmental maxillary resection, with radiotherapy and chemotherapy [3-4].

Following a previously published report [2], ocular function was assessed using basic clinical parameters: day-to-day use of the eye, subjective change in visual acuity, diplopia, gross visual fields, exposure keratitis, blepharitis or conjunctivitis, lacrimal system dysfunction, and so on. Ocular function was graded as functional vision without impairment (no persistent ophthalmologic sequelae), functional vision with impairment (one or more significant chronic ophthalmologic sequelae), nonfunctional (blindness, light-perception only, nonserviceable visual acuity, or intractable diplopia), or totally removed on the basis of the medical records at the end of observation (median 52 months post-treatment).

The Kaplan-Meier method was applied for the analysis of survival and local control rates, and the survival and local control rates were compared using the log rank test. The time of interest for survival and local control rates was the period from the start of treatment to death or failure. The time of interest for preservation of ocular function was the period from

the start of treatment to death, removal of orbital contents or loss of ocular function. A p-value of less than 0.05 was considered statistically significant. JMP Pro 10.0.0 statistical software (SAS Institute, Cary, NC) was used for the statistical analysis.

## **RESULTS**

A total of 33 (38%) of the 87 patients were categorized into en bloc resection group. En bloc resection without orbital exenteration was performed for seven patients. En bloc resection with orbital exenteration was performed for sixteen patients. En bloc resection with anterior craniotomy and orbital exenteration was performed for nine patients. In one patient, en bloc resection was planned after pre-operative chemotherapy and radiotherapy. However, this patient refused en bloc resection before surgery and he was irradiated with a total of 70 Gy. This case was categorized into the en bloc resection group for intention-to-treat analysis.

A further 15 patients (17%) underwent conservative surgery, 21 patients (24%) underwent RADPLAT, 14 patients (16%) underwent IV-CRT, and 4 patients (5%) underwent radiation alone. Of the 33 patients in the en bloc resection group, 26 patients (79%) were classified as T4a. In addition, 11 patients (73%) undergoing conservative surgery, 5 patients (24%) undergoing RADPLAT, and 5 patients (36%) undergoing IV-CRT were classified as T4a. Adjunctive radiotherapy and adjunctive chemotherapy was performed in 91% (30/33) and 73% (24/33) of patients undergoing en bloc resection, respectively. All patients in the conservative surgery group underwent adjunctive radiotherapy, and adjunctive chemotherapy was performed in 87% of patients in this group (Table 2). Details of the tumor-involved orbital sites are shown in Table 3. The orbital apex was involved in 57% of the RADPLAT group.

Table 4 shows the evaluation of ocular function. In 25 of 33 patients in the en bloc resection group, orbital exenteration was performed. One patient undergoing RADPLAT needed total maxillectomy and orbital exenteration four months after the completion of RADPLAT because of primary tumor recurrence. One patient in the IV-CRT group had an ocular problem before the onset of maxillary cancer, and ocular function was not recorded in another patient in this group. These two patients were excluded from the evaluation of ocular function.

Figure 1 indicates the overall survival rate curves for treatment modalities. The 5-year overall survival rates of all 87 patients, the en bloc resection group, the conservative surgery group, the RADPLAT group, and the IV-CRT group were 47%, 70%, 35%, 49%, and 31%, respectively. All four patients undergoing radiation alone died within two years of the start of treatment.

Figure 2 indicates the local control rate curves for treatment modalities. The 5-year local control rates of all 87 patients, the en bloc resection group, the conservative surgery group, the RADPLAT group, and the IV-CRT group were 45%, 70%, 30%, 42%, and 21%, respectively.

Figure 3 shows the preservation of ocular function. The 5-year preservation rates for ocular function in all 85 patients, the en bloc resection group, the conservative surgery group, the RADPLAT group, and the IV-CRT group were 19%, 15%, 27%, 30%, and 17%, respectively.

Twenty-five (66%) of 38 patients with T4b were treated by RADPLAT or IV-CRT. In patients with T4b, there were significant differences in both overall survival and preservation of ocular function between the RADPLAT group (n=16) and IV-CRT group (n=9) (p=0.0166 and p=0.0173, respectively). (Figure 4 and Figure 5)

Analyzing the clinical outcome in the en bloc resection group, there was no significant difference in the 5-year overall survival rate between patients with orbital exenteration and those without orbital exenteration (72% vs 71%, p=0.9321). (Figure 6) There was no significant difference in the 5-year local control rate between patients with orbital exenteration and those without orbital exenteration (78% vs 71%, p=0.6310) as well. In 6 of 7 patients without orbital exenteration (86%), ocular function was evaluated as functional without impairment. Ocular function of remaining one patient without orbital exenteration (14%) was evaluated as functional with impairment.

## **DISCUSSION**

With regard of the treatment of advanced malignant maxillary sinus cancer, many authors have recommended combined therapies consisting of en bloc radical resection



together with irradiation. This combined therapy has shown 5-year overall survival rates of 44% to 58% [7-10]. The 5-year overall survival rate of patients undergoing en bloc resection in our multi-institutional study was 70%, which is favorable in comparison to recent reports. One reason for the favorable results may be the improvements in surgical technique as the incidence of maxillary sinus cancer has been historically relatively high in Japan, comprising more than 1% of all malignancies and about 23% of all malignant head and neck tumors [11]. Another reason may be that the combined approach with intra-arterial chemotherapy, surgery and radiotherapy had been gradually developing for patients with maxillary sinus cancer since the 1950s in Japan [12-13].

Homma *et al.* reported that RADPLAT consisting of targeting superselective intra-arterial chemotherapy and concurrent radiotherapy was performed for patients with T3 to T4 nasal and paranasal sinus cancer. The 5-year overall survival rate was reported to be 69.3% [5]. This non-surgical treatment is expected to preserve the orbital contents and to avoid cosmetic problems for patients with advanced maxillary sinus cancer.

In this multi-institutional study, survival rates and ocular function were evaluated among various treatment modalities. However, we recognized that our study was limited by its retrospective nature, which resulted in a bias toward treatment selection. T4b maxillary sinus cancer is generally considered unresectable. Therefore, most of patients with T4b maxillary sinus cancer were not treated by en bloc resection. It is probably inappropriate to compare overall survival rates among treatment modalities because of this inequality. Therefore, we analyzed the overall survival rates and ocular function preservation rates between patients with T4b cancer treated by RADPLAT or IV-CRT, and noticed that both the overall survival rate and ocular function preservation rate in the RADPLAT group were significantly higher than those in the IV-CRT group. A randomized phase 3 trial in the Netherlands indicated that RADPLAT was not superior to cisplatin-based IV-CRT for advanced head and neck cancer in terms of loco-regional control and survival [14]. However, it was reported in this literature that there were significantly higher local and locoregional rates and disease free survival with RADPLAT for large (>30mL) lateralized tumors. Advanced maxillary sinus cancers are generally large and lateralized, do not extend beyond the midline, and have simple artery feeding that is easy to access. Therefore, we believe that

RADPLAT has an advantage over IV-CRT in the control of massive primary tumors for patients with advanced maxillary sinus cancer.

In terms of surgical treatment, it was reported that sparing of the orbital soft tissue during en bloc resection did not reduce the rate of cure or local control when the periorbital had not been transgressed [1]. In addition, Imola *et al.* suggested that eye preservation could be attempted in paranasal sinus cancers that invaded the orbital soft tissues with penetration through the periorbital, and overall eye function was reported as functional without impairment in 54%, functional with impairment in 37%, and nonfunctional in 9% for patients in whom orbital contents had been preserved [2]. On the other hand, Dulguerov *et al.* suggested that the role of orbital exenteration was significant in cases with orbital invasion. It was reported that the locoregional control rate in patients with orbital exenteration was higher than that in patients without orbital exenteration (79% vs 14%, respectively,  $p=0.03$ ) [15].

Our results indicated that the overall survival rate of patients without orbital exenteration were comparable to that of patients with orbital exenteration. Therefore, it was considered that preserving orbital contents was applied adequately in this multi-institutional study. Furthermore, ocular function was evaluated as functional without impairment in 86% of patients without orbital exenteration. These favorable data support selective orbital preservation. However, we need further study to determine the indication of orbital preservation during en bloc resection, and we can not ignore the role of adjunctive treatment for patients without orbital exenteration. On the other hand, our results showed that 76% of patients undergoing en bloc resection needed orbital exenteration and suffered significant cosmetic problems consequently. It is probably difficult to spare the orbit when en bloc resection is applied to patients with maxillary sinus cancer with orbital invasion.

In conclusions, the overall survival rate of the en bloc resection group was favorable, and preservation of orbital contents did not reduce the survival rate for patients undergoing en bloc resection. However, it may be difficult to preserve orbital contents during en bloc resection as we found that 76% of the en bloc resection group underwent orbital exenteration in our study. In addition, it is thought that RADPLAT has higher oncologic efficacy than IV-CRT against T4b maxillary sinus cancer.

## ACKNOWLEDGEMENTS

This study was supported in part by a Health and Labour Sciences Research Grant for Clinical Cancer Research (H22-Gannrinshou-Ippan-017) from the Ministry of Health, Labour and Welfare of Japan, and the National Cancer Center Research and Development Fund (23-A-21) of Japan.

## APPENDIX

In addition to the authors, the following investigators participated in this study: *Aichi Medical University, Nagakute* - A. Ikeda; *Iwate Prefectural Central Hospital, Morioka* - S. Kato; *Kanagawa Cancer Center, Yokohama* - A. Kubota; *Kyoto Prefectural University of Medicine, Kyoto* - K. Ikebuchi; *Kochi Health Sciences Center, Kochi* - K. Kozakura; *Kobe University Graduate School of Medicine, Kobe* - K. Nibu; *Jichi Medical University, Shimotsuke* - H. Nishino; *Jikei University School of Medicine, Tokyo* - T. Kato; *Tokyo University Graduate School of Medicine, Tokyo* - T. Asakage; *Japanese Red Cross Nagoya Daiichi Hospital, Nagoya* - K. Kawata; *Nara Medical University, Kashihara* - I. Ota; *Hiroshima University Hospital, Hiroshima* - T. Ueda; *Keiyukai Sapporo Hospital, Sapporo* - A. Watanabe; *Kyoto University Graduate School of Medicine, Kyoto* - M. Kitamura.

## REFERENCES

- [1] Carrau RL, Segas J, Nuss DW, et al. Squamous cell carcinoma of the sinonasal tract invading the orbit. *Laryngoscope*. 1999;109:230-235.
- [2] Imola MJ, Schramm VL Jr. Orbital preservation in surgical management of sinonasal malignancy. *Laryngoscope*. 2002 Aug;112(8 Pt 1):1357-65.
- [3] Nishino H, Ichimura K, Tanaka H, et al. Results of orbital preservation for advanced malignant maxillary sinus tumors. *Laryngoscope*. 2003;113:1064-1069.
- [4] Nishino H, Takanosawa M, Kawada K, et al. Multidisciplinary therapy consisting of minimally invasive resection, irradiation, and intra-arterial infusion of 5-fluorouracil for maxillary sinus carcinomas. *Head Neck*. 2012 Jun 23. doi: 10.1002/hed.23030. [Epub ahead of print]

- [5] Homma A, Oridate N, Suzuki F, et al. Superselective high-dose cisplatin infusion with concomitant radiotherapy in patients with advanced cancer of the nasal cavity and paranasal sinuses: a single institution experience. *Cancer*. 2009;115:4705-4714.
- [6] Shiga K, Yokoyama J, Hashimoto S, et al. Combined therapy after superselective arterial cisplatin infusion to treat maxillary squamous cell carcinoma. *Otolaryngol Head Neck Surg*. 2007;136:1003-1009.
- [7] Paulino AC, Marks JE, Bricker P, Melian E, Reddy SP, Emami B. Results of treatment of patients with maxillary sinus carcinoma. *Cancer*. 1998;83:457-465.
- [8] Stern SJ, Goepfert H, Clayman G, et al. Squamous cell carcinoma of the maxillary sinus. *Arch Otolaryngol Head Neck Surg*. 1993;119:964-969.
- [9] St-Pierre S, Baker SR. Squamous cell carcinoma of the maxillary sinus: analysis of 66 cases. *Head Neck Surg*. 1983;5:508-513.
- [10] Tsujii H, Kamada T, Arimoto T, et al. The role of radiotherapy in the management of maxillary sinus carcinoma. *Cancer*. 1986;57:2261-2266.
- [11] Segi M, Tominaga S, Aoki K, Fujimoto I. *Cancer Mortality and Morbidity Statistics: Japan and the World*. Tokyo: Gann monograph on Cancer Research No.26: Japan Scientific Societies Press, 1981;121-250.
- [12] Sato Y, Morita M, Takahashi HO, Watanabe N, Kirikae I. Combined surgery, radiotherapy, and regional chemotherapy in carcinoma of the paranasal sinuses. *Cancer*. 1970 ;25:571-579.
- [13] Sakai S, Fuchihata H, Hamasaki Y. Treatment policy for maxillary sinus carcinoma. *Acta Otolaryngol*. 1976;82:172-181.
- [14] Rasch CR, Hauptmann M, Schornagel J, et al. Intra-arterial versus intravenous chemoradiation for advanced head and neck cancer: Results of a randomized phase 3 trial. *Cancer*. 2010;116:2159-2165.
- [15] Dulguerov P, Jacobsen MS, Allal AS, Lehmann W, Calcaterra T. Nasal and paranasal sinus carcinoma: are we making progress? A series of 220 patients and a systematic review. *Cancer*. 2001;92:3012-3029.

## **FIGURE LEGENDS**

**Figure 1.** The 5-year overall survival rates for treatment modalities obtained using the Kaplan-Meier methods.

Abbreviations: RADPLAT; superselective intra-arterial chemotherapy and radiotherapy, IV-CRT; intra-venous chemoradiotherapy

**Figure 2.** The 5-year local control rates for treatment modalities obtained using the Kaplan-Meier methods.

Abbreviations: RADPLAT; superselective intra-arterial chemotherapy and radiotherapy, IV-CRT; intra-venous chemoradiotherapy

**Figure 3.** The 5-year preservation rates of ocular function for treatment modalities obtained using the Kaplan-Meier methods.

Abbreviations: RADPLAT; superselective intra-arterial chemotherapy and radiotherapy, IV-CRT; intra-venous chemoradiotherapy

**Figure 4.** The 5-year overall survival rates for patients with T4b cancer undergoing superselective intra-arterial chemotherapy and radiotherapy (RADPLAT) or intra-venous chemoradiotherapy (IV-CRT) obtained using the Kaplan-Meier methods.

**Figure 5.** The 5-year preservation rates of ocular function for patients with T4b cancer undergoing superselective intra-arterial chemotherapy and radiotherapy (RADPLAT) or intra-venous chemoradiotherapy (IV-CRT) obtained using the Kaplan-Meier methods.

**Figure 6.** The 5-year overall survival rates for patients undergoing en bloc resection with orbital exenteration and those undergoing en bloc resection without orbital exenteration obtained using the Kaplan-Meier methods.

Figure 1.

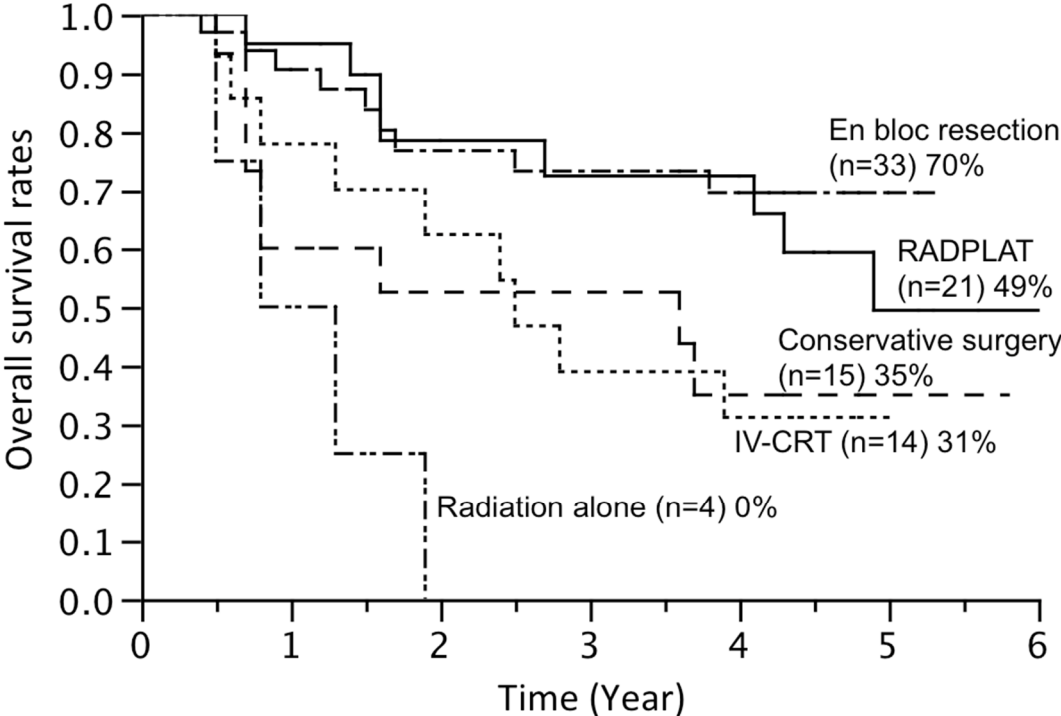


Figure 2.

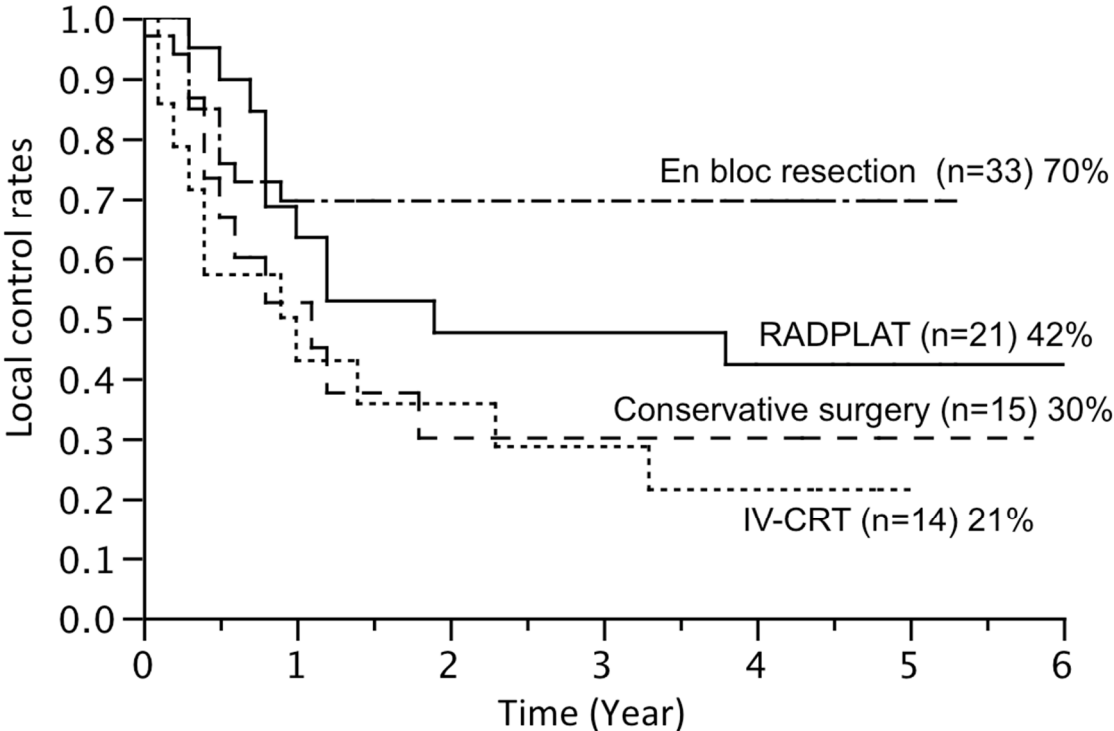


Figure 3.

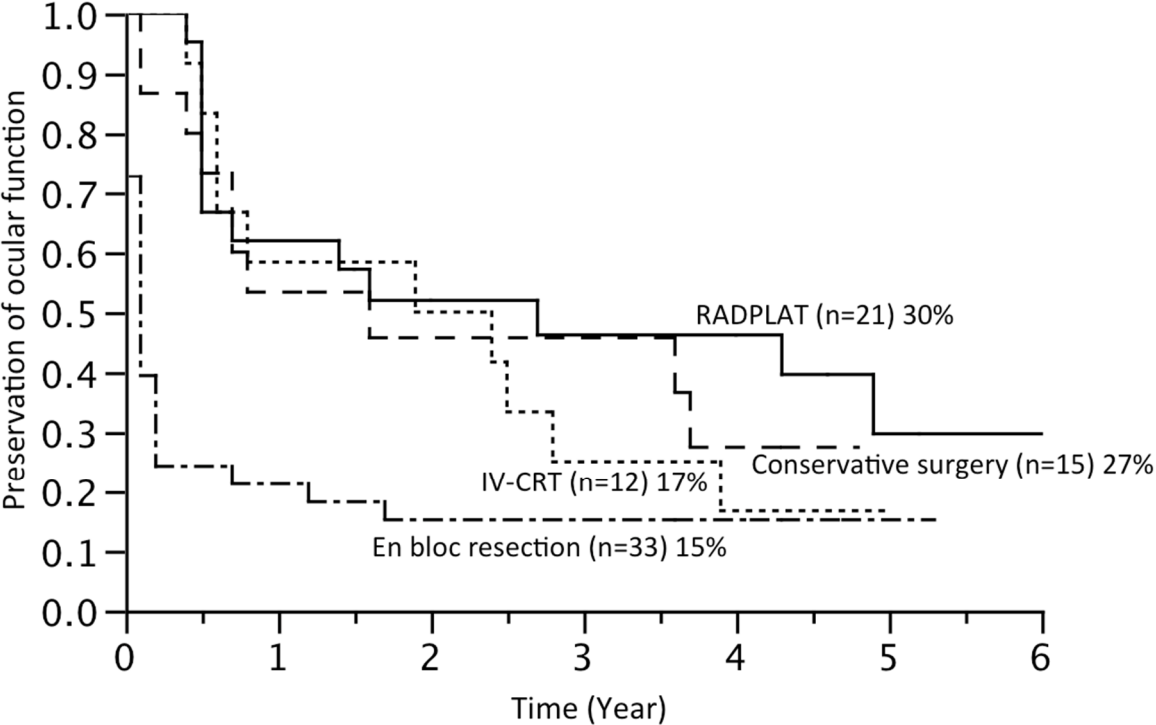




Figure 4.

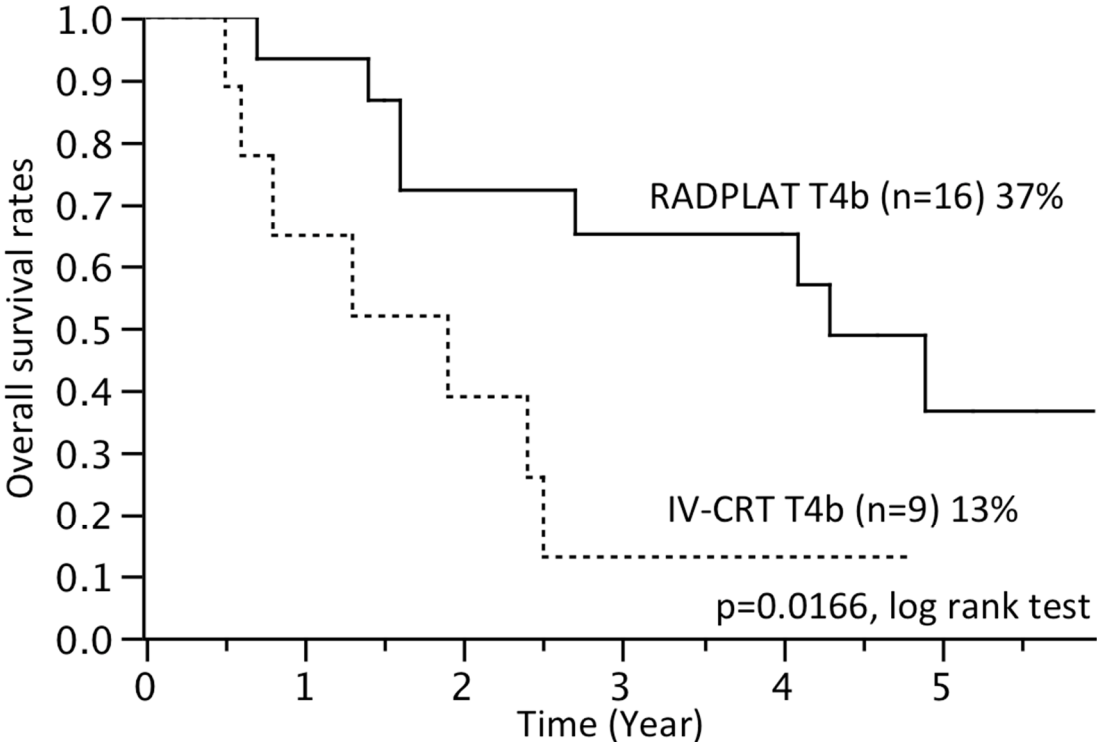


Figure 5.

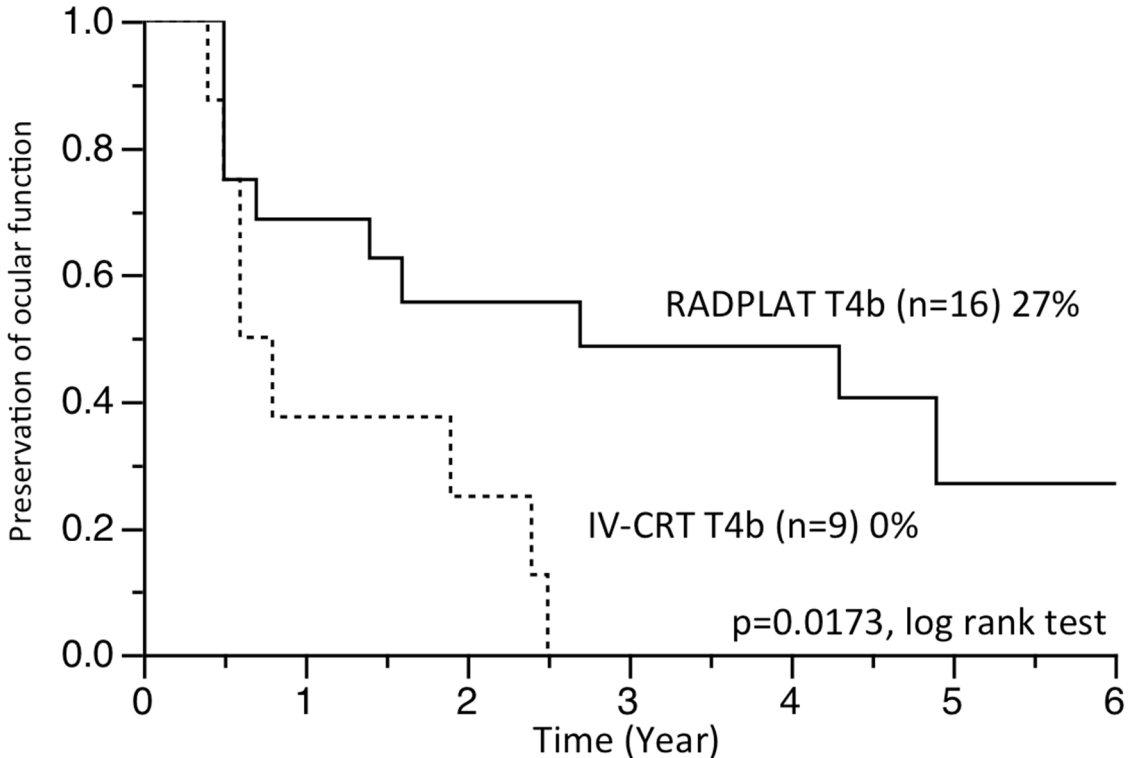


Figure 6.

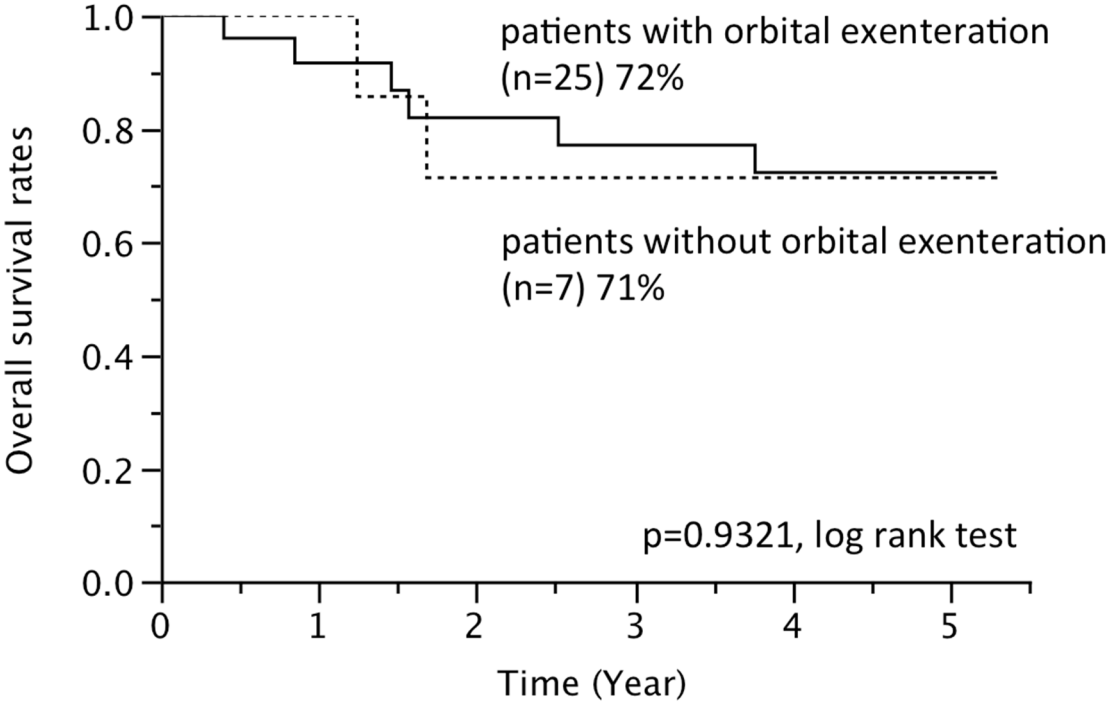


Table 1. Patient Demographics

Characteristic	No. of patients (%)
Total	87
Gender	
Male	63 (72%)
Female	24 (28%)
Age, years	
Median	65
Range	30-84 (Ave. 63.6)
Follow-up period, months	
Median	52.0
Range	6.0-71.8 (Ave. 46.3)
T classification	
T4a	49 (56%)
T4b	38 (44%)
N classification	
N0	73 (84%)
N1	5 (6%)
N2a-c	9 (10%)
N3	0 (0%)

Table 2. TN classification and adjunctive treatment

	No. of patients	T classification		N classification		Adjunctive treatment	
		T4a	T4b	N0	N>1	Radiotherapy	Chemotherapy
En bloc resection	33	26 (79%)	7 (21%)	30 (91%)	3 (9%)	30 (91%)	24 (73%)
Conservative surgery	15	11 (73%)	4 (27%)	12 (80%)	3 (20%)	15 (100%)	13 (87%)
RADPLAT	21	5 (24%)	16 (76%)	17 (81%)	4 (19%)	–	5 (24%)
IV-CRT	14	5 (36%)	9 (64%)	12 (86%)	2 (14%)	–	2 (14%)
Radiation alone	4	2 (50%)	2 (50%)	2 (50%)	2 (50%)	–	1 (25%)

Table 3. Details of tumor-involved orbital sites

	No. of patients	Tumor-involved orbital sites			
		Anterior orbit	External eye muscle	Fat tissue	Orbital apex
<b>En bloc resection group</b>	33	27 (82%)	16 (48%)	28 (85%)	4 (12%)
without orbital exenteration	7	7 (100%)	1 (14%)	5 (71%)	0 (0%)
with orbital exenteration	16	14 (88%)	9 (56%)	14 (88%)	1 (6%)
with craniotomy and orbital exenteration	9	5 (56%)	6 (67%)	8 (89%)	3 (33%)
not performed	1	1 (100%)	0 (0%)	1 (100%)	0 (0%)
<b>Conservative surgery group</b>	15	11 (73%)	5 (33%)	10 (67%)	4 (27%)
<b>RADPLAT group</b>	21	19 (90%)	8 (38%)	15 (71%)	12 (57%)
<b>IV-CRT group</b>	14	10 (71%)	9 (64%)	10 (71%)	6 (43%)
<b>Radiation alone group</b>	4	2 (50%)	2 (50%)	4 (100%)	1 (25%)

Table 4. Evaluation of ocular function

	No. of patients	Ocular function				
		Removed	Non-functional	Functional with impairment	Functional without impairment	Unknown
En bloc resection	33	25 (76%)	0 (0%)	1 (3%)	7 (21%)	0
Conservative surgery	15	1 (7%)	2 (13%)	3 (25%)	9 (60%)	0
RADPLAT	21	1 (5%)	6 (28%)	5 (24%)	9 (43%)	0
IV-CRT	14	0 (0%)	4 (33%)	4 (33%)	4 (33%)	2
Radiation alone	4	0 (0%)	0 (0%)	1 (25%)	3 (75%)	0