



Title	Treatment Strategy for Bilateral Carotid Stenosis: 2 Cases of Carotid Endarterectomy for the Symptomatic Side Followed by Carotid Stenting
Author(s)	Hokari, Masaaki; Isobe, Masanori; Asano, Takeshi; Itou, Yasuhiro; Yamazaki, Kazuyoshi; Chiba, Yasuhiro; Iwamoto, Naotaka; Isu, Toyohiko
Citation	Journal of stroke & cerebrovascular diseases, 23(10), 2851-2856 <a href="https://doi.org/10.1016/j.jstrokecerebrovasdis.2014.07.014">https://doi.org/10.1016/j.jstrokecerebrovasdis.2014.07.014</a>
Issue Date	2014-12
Doc URL	<a href="http://hdl.handle.net/2115/57788">http://hdl.handle.net/2115/57788</a>
Type	article (author version)
File Information	Text_JSCVD2.pdf



[Instructions for use](#)

**Treatment strategy for bilateral carotid stenosis: Two cases of carotid endarterectomy for the symptomatic side followed by carotid stenting**

Masaaki Hokari<sup>1</sup> MD, PhD, Masanori Isobe<sup>1</sup> MD, PhD, Takeshi Asano<sup>2</sup> MD, PhD, Yasuhiro Itou<sup>1</sup> MD, Kazuyoshi Yamazaki<sup>1</sup> MD, Yasuhiro Chiba<sup>1</sup> MD, PhD, Naotaka Iwamoto<sup>1</sup> MD, Toyohiko Isu<sup>1</sup> MD, PhD

Department of Neurosurgery, Kushiro Rousai Hospital<sup>1</sup>

Department of Neurosurgery, Asahikawa Red Cross Hospital<sup>2</sup>

**Disclosure Statement**

There is no conflict of interest to report.

**Correspondence:**

Masaaki Hokari, MD, PhD,

Department of Neurosurgery, Hokkaido University Graduate School of Medicine, North 15 West 7,  
Kita-ku, Sapporo 060-8638, Japan

TEL : +81-11-706-5987 FAX : +81-11-708-7737

E-mail: [karimasa@med.hokudai.ac.jp](mailto:karimasa@med.hokudai.ac.jp)

**Running Title: Treatment strategy for bilateral carotid stenosis**

## **Abstract**

Since the introduction of carotid stenting (CAS), a combined treatment for bilateral lesions using carotid endarterectomy (CEA) and CAS has been developed. However, there has been only one report about CEA then CAS. Herein we describe two patients with bilateral severe carotid stenosis who were treated by CEA for the symptomatic side and by CAS for the contra-lateral asymptomatic side.

A 71-year-old man underwent CEA for the symptomatic side. Although the patient suffered hyperperfusion syndrome after CEA, he recovered fully after 3 weeks of rehabilitation. Two months later, CAS was performed for the asymptomatic side and he was discharged with no deficit.

A 67-year-old man underwent CEA for the symptomatic side. The patient developed no post-operative neurological deficits except for hoarseness. Four weeks later, CAS was performed for the contralateral asymptomatic side. After the procedure, however, severe hypotension occurred, and treatment by continuous injection of catecholamine was necessary to maintain systematic blood pressure. The patient was ultimately discharged with no deficit.

The combined therapy of CAS for the asymptomatic side and then CEA for the symptomatic side has been recommended by several authors. However, one of the problems of this strategy is the higher incidence of post procedural hemodynamic complications, and hypotension after CAS may be dangerous for the symptomatic hemisphere. We suggest a combined therapy using CEA for the symptomatic side and then CAS for the asymptomatic side can be one beneficial treatment option for patients with bilateral carotid stenosis without coronary artery disease.

**Keywords:** carotid endarterectomy; carotid stenting; hyperperfusion syndrome; bilateral

## **Introduction**

Carotid endarterectomy (CEA) and carotid stenting (CAS) are beneficial procedures for patients with high-grade cervical carotid stenosis<sup>1-4</sup>. However, it is sometimes difficult to manage patients with bilateral severe carotid stenosis. Since the introduction of CAS, a combined treatment for bilateral lesions using CEA and CAS has been developed<sup>5-8</sup>. Its treatment strategy is complex, and there are several possible approaches that have yet to be decided which side to treat first, which procedure to perform, etc.—but will be determined by general condition, symptoms, plaque characteristics, anatomical situation, hemodynamic state, and other factors. Herein we describe two patients with bilateral severe carotid stenosis who were treated by CEA for the symptomatic side and by CAS for the contra-lateral asymptomatic side.

## **Patients and Methods**

Between April 2012 and December 2013, 15 patients (18 sides) with carotid stenosis (60% to 99%) were surgically treated at our hospital (12 males, mean age 72.1, range 64-83). CEA and CAS were performed for 14 and 4 lesions, respectively. All CEAs were performed under general anesthesia. Carotid shunts with intraoperative monitors of Near Infra-Red Spectroscopy (NIRS) and motor evoked potential (MEP) were used as a matter of routine. CAS was performed under local anesthesia, and pre-dilation was performed after distal protection was inserted in the internal carotid artery (ICA), after which a stent was placed. Among them, three patients had bilateral severe carotid stenosis (>60%). One patient had asymptomatic bilateral ICA stenosis (right 80%, left 60%) and underwent a right CEA; he underwent a left CEA 12 months later, because the left ICA stenosis had progressed. The remaining two patients were symptomatic, and they underwent CEA for the symptomatic side and CAS for the asymptomatic side. They are the subjects in this report.

## **Case presentations**

### ***Case 1***

A 71-year-old man with a history of hypertension (HT) and diabetes mellitus (DM) developed transient motor weakness of his left extremities and was admitted to our hospital. Diffusion-weighted image (DWI) of magnetic resonance imaging (MRI) revealed several spotty high signals on the bilateral cerebral hemispheres (Fig.1A) and magnetic resonance angiography (MRA) showed a faint flow signal of the right ICA (Fig.1B). <sup>123</sup>I-IMP single photon emission tomography (SPECT) demonstrated that cerebral blood flow (CBF) had been reduced in the bilateral frontal cortex (right: 26.3ml /100g < left: 29.4ml/100g) (Fig.1C). Digital subtraction angiograms (DSAs) showed the near occlusion of the right relatively high cervical ICA and 80% stenosis of the left ICA (Fig.1D-E). T1-weighted image of Black Blood (BB) method showed high intensity in the right ICA plaque and iso-intensity in the left plaque (arrows in Fig.1F-G). Antiplatelet medication was immediately administered to the patients, and coronary heart disease check-up revealed that he had no risks for general anesthesia. Two weeks after onset, right CEA was performed for the symptomatic lesion, since the right side could have been a high-risk plaque for CAS. Cramping durations of ICA were 6 minutes (shunt insertion) and 6 minutes (shunt removal), respectively. During the occlusion, there were no changes in the NIRS and the MEP monitors. The plaque consisted of lipid rich and intraluminal hematoma. The patient developed no neurological deficits immediately after surgery, although on the day following the operation he suffered from headaches, restlessness, and disorientation. One day after the operation, DWI revealed no high signals (Fig.2A), and MRA showed improvement of flow signal of right ICA (Fig.2B). <sup>123</sup>I-IMP SPECT demonstrated postoperative hyperperfusion in the right frontal lobes (arrowhead in Fig. 2C). Subsequently, the patient was kept under mild sedation, and systolic blood pressure was controlled between 100 and 140 mmHg for 7 days using a continuous infusion of nicardipine. The patient

recovered fully after 3 weeks of rehabilitation and he was finally discharged with no neurological deterioration. Two months later, CAS was performed for the left asymptomatic stenosis. The postoperative course of CAS was uneventful, and postoperative 3-dimensional CT angiography (3D-CTA) revealed excellent dilatations of the bilateral lesions (Fig.2D). The patient was discharged on the 10<sup>th</sup> postoperative day with no deficits.

### ***Case 2***

A 67-year-old man with a history of HT, habitual smoking, and hyperlipidemia complained of dysarthria and transient weakness of his left extremities, and he was referred to our hospital three weeks after onset. DWI illustrated several spotty high signals on bilateral cerebral hemispheres (Fig.3A), and <sup>123</sup>I-IMP SPECT demonstrated CBF were reduced in the right hemisphere (Fig.3B). DSAs showed severe stenosis of bilateral relatively high cervical ICA (Fig.3C-D), and BB imaging showed high intensity in the bilateral plaques (Fig.3E-F). A coronary heart disease check-up and treatment by antiplatelets and statins were immediately started. He had no risks for general anesthesia. Six weeks after onset, a right CEA was performed for symptomatic lesion, because it was thought that the right side would be more dangerous and thus should be treated first. Cramping durations of ICA were 7 minutes (shunt insertion) and 5 minutes (shunt removal), respectively. During the occlusion, there were no changes in the NIRS and the MEP monitors. The plaque was lipid rich plaque. He developed no neurological deficits except for hoarseness. Although the left side plaque was not symptomatic, an initial MRA also detected cerebral infarction in his left hemisphere. Therefore, we thought that we should not wait for him to recovery from hoarseness for several months. While the left side plaque may have also been a relatively high-risk plaque for CAS, it was possible that statins could cause plaque stabilization. Four weeks later, therefore, CAS was performed for left asymptomatic ICA stenosis. During the procedure, severe bradycardia and hypotension occurred, and the patient recovered by atropine injection. However, 6 hours after the

procedure, he developed hypotension (60mmHg/34mmHg) again, although he had no anemia. Treatment by continuous injection of catecholamine was necessary to maintain systematic blood pressure above 100mmHg for 3 days. The postoperative 3D-CTA revealed excellent dilatations of the bilateral lesions (Fig.3F-H), and the patient was discharged on the 14<sup>th</sup> postoperative day with no deficit.

### **Discussion**

There are four treatment strategies for bilateral cervical carotid artery stenosis: (1) CEA→CEA, (2) CAS→CAS, (3) CAS→CEA, and (4) CEA→CAS. There have been several reports about the reconstruction of bilateral ICA stenosis<sup>5-14</sup>. However, there has been only one report about CEA then CAS written in Chinese<sup>15</sup>. Here we describe two patients with bilateral severe carotid stenosis who were treated by CEA then CAS.

Before introduction of CAS, bilateral CEA was the only treatment strategy to reconstruct bilateral ICA stenosis. However, many neurosurgeons instituted deliberate delay of a few months in order to prevent complications such as neurological deficits, nerve injuries, and vocal cord paresis<sup>16, 17</sup>. Sannella et al. reported that vocal cord paralysis was a relatively common complication of CEA in their careful laryngoscopic examination, and they recommended that we should carefully select patients who undergo bilateral CEA<sup>18</sup>. Moreover, Ille et al. highlighted a case of hypertensive encephalopathy associated with baroreflex failure syndrome after bilateral CEA<sup>12</sup>. Therefore, the number of cases in which bilateral CEA has been performed has been decreasing since the introduction of CAS<sup>5, 8</sup>.

According to the recent reports of bilateral CAS (CAS→CAS or simultaneous bilateral CAS)<sup>9-11, 13</sup>, bilateral CAS was less invasive, effective, and generally safer treatment method in a selective group of patients with bilateral ICA stenosis. One of the merits of this strategy is a short or

nonexistent interval of the reconstructions. However, the frequency of post-procedural hemodynamic complications such as hypotension and bradycardia was more than 50%<sup>9, 13</sup>. Moreover, one of the remaining issues of CAS is the relatively higher incidence of ipsi-lateral ischemic lesions after the procedure, even under distal protection<sup>19</sup>. Despite neurological-protections during the procedure, there have been several reports about delayed plaque protrusion after CAS, especially in the patients with carotid vulnerable plaque<sup>14, 20, 21</sup>. Subsequently, CEA should be chosen for these lesions. Therefore, combined therapy using CAS and CEA could be beneficial for a relatively large group of patients with bilateral carotid stenosis<sup>5, 8</sup>.

Recently, the combined therapy of CAS followed by CEA has been recommended by several authors<sup>5-8</sup>, who suggest that this strategy is a safe and feasible option for patients with bilateral carotid stenosis and coronary artery disease, because CAS can be usually performed under local anesthesia<sup>6, 7</sup>. Most of the symptomatic patients without coronary artery disease in their article also underwent CAS for the asymptomatic side and then CEA for the symptomatic side, because symptomatic plaques are often vulnerable and sometimes unsafe for CAS<sup>5, 8</sup>. It was thought that CAS would be better for the first revascularization procedure than CEA, because contralateral stenosis would adversely affect CEA. One of the reasons the authors explained their strategy was that cramping time would be longer in CEA than in CAS. However, our cramping times were shorter than 10 minutes under routine use of shunts, and distal protection in CAS also took 5-10 minutes. One of the problems of this strategy is the higher incidence of post procedural hemodynamic complications. Although contralateral carotid occlusion does not adversely impact CAS<sup>22-24</sup>, there have been no reports indicating that CAS is safer in patients with contralateral severe ICA stenosis than is CEA. Rather, we think that hypotension after CAS for the asymptomatic side may be dangerous for the symptomatic hemisphere, because CAS for the asymptomatic side usually does not improve hemodynamics in the symptomatic cerebral



hemisphere.

The early risk of recurrent strokes during medical treatment is also high in patients with recent symptomatic carotid severe stenosis; relatively early surgery is recommended <sup>25, 26</sup>. Moreover, symptomatic carotid plaques often consist of lipid-rich and intra-plaque hematoma and these vulnerable plaques should be treated by CEA. Therefore, we think the symptomatic side should be first treated by CEA under general anesthesia, because our two cases had no risks for general anesthesia. While it is almost certain that this strategy has been performed elsewhere, there has only been one report about CEA followed by CAS <sup>15</sup>. We suggest that combined therapy using CEA for the symptomatic side and then CAS for the asymptomatic side can be beneficial for patients with bilateral carotid stenosis without coronary artery disease.

However, one of the most important questions of this strategy is whether contralateral stenosis increases the risk of patients undergoing CEA. Although several reports have confirmed that contralateral carotid occlusion does not adversely affect CAS <sup>22-24</sup>, previous studies have shown conflicting results regarding the perioperative risk of the patients with contralateral ICA occlusion undergoing CEA <sup>22, 24, 27-31</sup>. Antoniou et al. conducted a systematic review, and showed contralateral occlusion increases the incidence of perioperative strokes <sup>27</sup>. However, they also wrote that their analysis is limited by the heterogeneity in performing the intraoperative procedure.

Interestingly, Goodney et al., who had previously reported contralateral stenosis increases the risk of patients undergoing CEA <sup>31</sup>, analyzed the perioperative risk of CEA with contralateral ICA occlusion, and they suggested that routine shunt use during CEA was associated with fewer complications. Surgeons who place shunts selectively during CEA have higher rates of complication, however <sup>32</sup>. Estruch-Perez et al. reported, moreover, that patients with severe contralateral stenosis (> 50%) have a higher risk of requiring shunt use during CEA <sup>33</sup>. There have been a few reports regarding the perioperative risks to the patients with contralateral ICA

severe stenosis, and these have resulted in conflicting results<sup>30, 34</sup>. However, the perioperative risk of CEA using shunts routinely may not adversely affect in an exceptional group of patients with contralateral ICA occlusion or severe stenosis because cerebral hemodynamics impairment and cognitive dysfunction are more severe in patients with bilateral carotid stenosis than those with unilateral stenosis<sup>35</sup>

This study has limitations, in that there is no data for comparison analysis among the strategies. Therefore, we cannot suggest that the combination therapy using CEA followed by CAS is better than others. Although further study is needed to evaluate whether or not contralateral stenosis increases the risk of patients undergoing CEA using shunts routinely, we suggest a combined therapy using CEA for the symptomatic side followed by CAS for the asymptomatic side can be one beneficial treatment option for patients with bilateral carotid stenosis without coronary artery disease.

## References

1. Collaborators NASCET. Beneficial effect of carotid endarterectomy in symptomatic patients with high-grade carotid stenosis. North american symptomatic carotid endarterectomy trial collaborators. *N Engl J Med.* 1991;325:445-453
2. Group ECSTC. Mrc european carotid surgery trial: Interim results for symptomatic patients with severe (70-99%) or with mild (0-29%) carotid stenosis. European carotid surgery trialists' collaborative group. *Lancet.* 1991;337:1235-1243
3. Sheffet AJ, Roubin G, Howard G, et al. Design of the carotid revascularization endarterectomy vs. Stenting trial (crest). *Int J Stroke.*5:40-46
4. Yadav JS, Wholey MH, Kuntz RE, et al. Protected carotid-artery stenting versus endarterectomy in high-risk patients. *N Engl J Med.* 2004;351:1493-1501
5. Kawabata Y, Nagata I, Sakai N, et al. Treatment of bilateral internal arotid artery stenosis. *Surgery for Cerebral Stroke.* 2001;29:339-334
6. Kiris I, Gulmen S, Yilmaz S, et al. Management of concomitant coronary and bilateral carotid artery disease: A case report. *J Card Surg.* 2007;22:149-151
7. Shichinohe H, Kuroda S, Asano T, et al. [novel stent/cea strategy for patients with bilateral carotid artery stenosis and coronary artery disease: Report of 2 cases]. *No Shinkei Geka.* 2005;33:149-153
8. Tsukahara T, Hatano T, Ogino E, et al. Surgical treatment for bilateral carotid arterial stenosis. *Acta Neurochir Suppl.* 2005;94:133-136
9. Alurkar A, Karanam LS, Nayak S, et al. Simultaneous bilateral carotid stenting in a series of 9 patients: A single-center experience with review of literature. *J Clin Imaging Sci.*2:72
10. Dong H, Jiang XJ, Peng M, et al. Comparison of the safety of simultaneous bilateral carotid artery stenting versus unilateral carotid artery stenting: 30-day and 6-month results. *Chin Med J (Engl).*125:1010-1015
11. Henry M, Gopalakrishnan L, Rajagopal S, et al. Bilateral carotid angioplasty and stenting. *Catheter Cardiovasc Interv.* 2005;64:275-282
12. Ille O, Woimant F, Pruna A, et al. Hypertensive encephalopathy after bilateral carotid endarterectomy. *Stroke.* 1995;26:488-491
13. Qureshi AI, Luft AR, Sharma M, et al. Frequency and determinants of postprocedural hemodynamic instability after carotid angioplasty and stenting. *Stroke.* 1999;30:2086-2093
14. Ogata N, Harashima K, Kanetani K, et al. Delayed plaque protrusion after carotid artery stenting for the patient with symptomatic bi-lateral carotid artery stenosis. *Cardiovasc Interv Ther.*29:65-69
15. Zhou DB, Xu BN, Yu XG, et al. [the strategy of management for bilateral carotid atherosclerotic stenosis]. *Zhonghua Wai Ke Za Zhi.* 2009;47:404-406

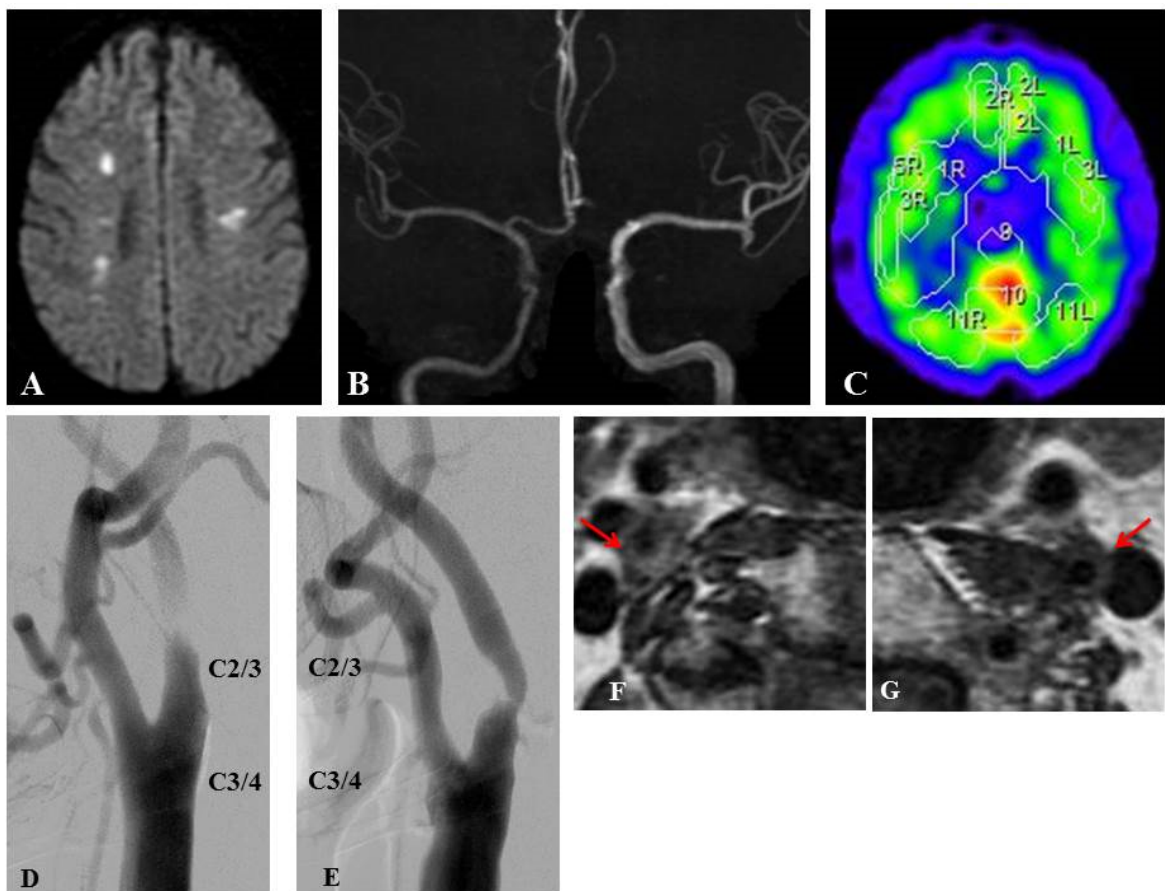
16. Rodriguez-Lopez JA, Diethrich EB, Olsen DM. Postoperative morbidity of closely staged bilateral carotid endarterectomies: An intersurgical interval of 4 days or less. *Ann Vasc Surg.* 2001;15:457-464
17. Sundt TM, Sandok BA, Whisnant JP. Carotid endarterectomy. Complications and preoperative assessment of risk. *Mayo Clin Proc.* 1975;50:301-306
18. Sannella NA, Tober RL, Cipro RP, et al. Vocal cord paralysis following carotid endarterectomy: The paradox of return of function. *Ann Vasc Surg.* 1990;4:42-45
19. Maleux G, Demaerel P, Verbeken E, et al. Cerebral ischemia after filter-protected carotid artery stenting is common and cannot be predicted by the presence of substantial amount of debris captured by the filter device. *AJNR Am J Neuroradiol.* 2006;27:1830-1833
20. Aikawa H, Kodama T, Nii K, et al. Intraprocedural plaque protrusion resulting in cerebral embolism during carotid angioplasty with stenting. *Radiat Med.* 2008;26:318-323
21. Takigawa T, Matsumaru Y, Kubo T, et al. Recurrent subacute in-stent restenosis after carotid artery stenting due to plaque protrusion. *Neurol Med Chir (Tokyo).* 2009;49:413-417
22. Faggioli G, Pini R, Mauro R, et al. Contralateral carotid occlusion in endovascular and surgical carotid revascularization: A single centre experience with literature review and meta-analysis. *Eur J Vasc Endovasc Surg.* 46:10-20
23. Keldahl ML, Park MS, Garcia-Toca M, et al. Does a contralateral carotid occlusion adversely impact carotid artery stenting outcomes? *Ann Vasc Surg.* 26:40-45
24. Yang SS, Kim YW, Kim DI, et al. Impact of contralateral carotid or vertebral artery occlusion in patients undergoing carotid endarterectomy or carotid artery stenting. *J Vasc Surg.* 59:749-755
25. Rantner B, Pavelka M, Posch L, et al. Carotid endarterectomy after ischemic stroke--is there a justification for delayed surgery? *Eur J Vasc Endovasc Surg.* 2005;30:36-40
26. Rothwell PM, Slattery J, Warlow CP. A systematic comparison of the risks of stroke and death due to carotid endarterectomy for symptomatic and asymptomatic stenosis. *Stroke.* 1996;27:266-269
27. Antoniou GA, Kuhan G, Sfyroeras GS, et al. Contralateral occlusion of the internal carotid artery increases the risk of patients undergoing carotid endarterectomy. *J Vasc Surg.* 57:1134-1145
28. Brewster LP, Beaulieu R, Kasirajan K, et al. Contralateral occlusion is not a clinically important reason for choosing carotid artery stenting for patients with significant carotid artery stenosis. *J Vasc Surg.* 56:1291-1294; discussion 1294-1295
29. Coyle KA, Smith RB, 3rd, Salam AA, et al. Carotid endarterectomy in patients with contralateral carotid occlusion: Review of a 10-year experience. *Cardiovasc Surg.* 1996;4:71-75
30. Gasecki AP, Eliasziw M, Ferguson GG, et al. Long-term prognosis and effect of endarterectomy in patients with symptomatic severe carotid stenosis and contralateral carotid stenosis or occlusion: Results from nascet. North american symptomatic carotid endarterectomy trial

- (nascet) group. *J Neurosurg.* 1995;83:778-782
31. Goodney PP, Likosky DS, Cronenwett JL. Factors associated with stroke or death after carotid endarterectomy in northern new england. *J Vasc Surg.* 2008;48:1139-1145
  32. Goodney PP, Wallaert JB, Scali ST, et al. Impact of practice patterns in shunt use during carotid endarterectomy with contralateral carotid occlusion. *J Vasc Surg.*55:61-71 e61
  33. Estruch-Perez MJ, Plaza-Martinez A, Hernandez-Cadiz MJ, et al. Interaction of cerebrovascular disease and contralateral carotid occlusion in prediction of shunt insertion during carotid endarterectomy. *Arch Med Sci.*8:236-243
  34. Burke PE, Prendiville E, Tadros E, et al. Contralateral stenosis and stump pressures: Parameters to identify the high risk patient undergoing carotid endarterectomy under local anaesthesia. *Eur J Vasc Surg.* 1993;7:317-319
  35. Balucani C, Viticchi G, Falsetti L, et al. Cerebral hemodynamics and cognitive performance in bilateral asymptomatic carotid stenosis. *Neurology.*79:1788-1795

## FIGURE LEGENDS

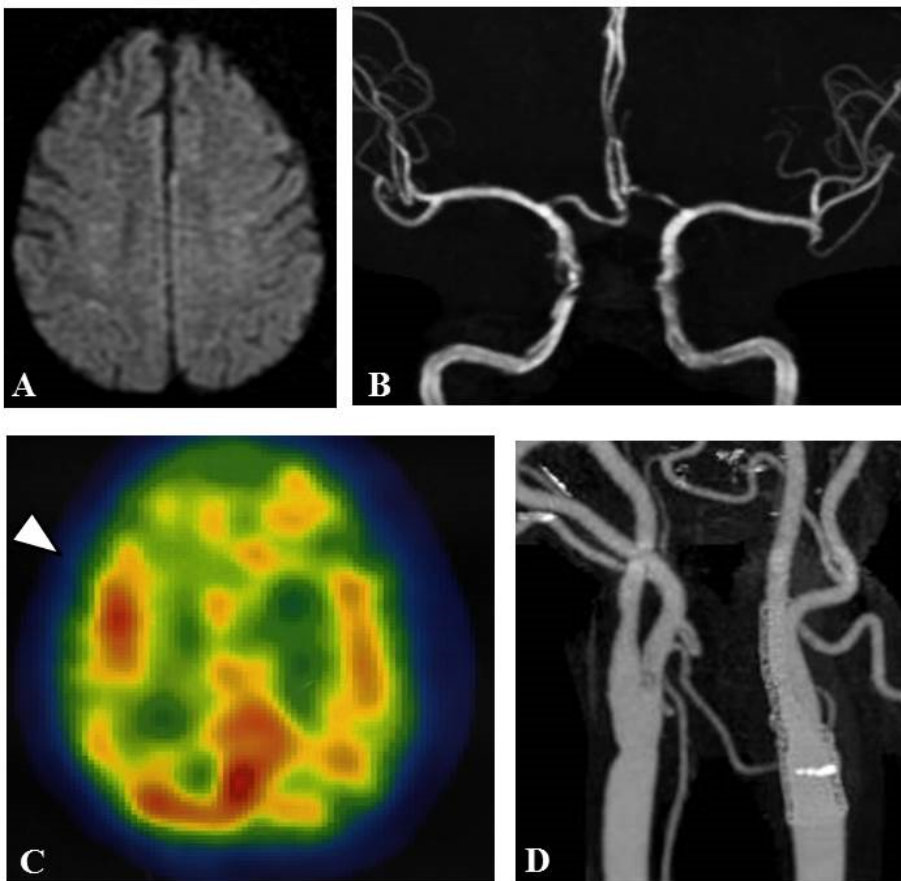
**Fig. 1:** Pre-operative neuroradiological findings of Case 1

Diffusion-weighted image (DWI) of magnetic resonance imaging (MRI) revealed several spotty high signals on the bilateral cerebral hemispheres (Fig.1A) and magnetic resonance angiography (MRA) illustrated a faint flow signal of the right ICA (Fig.1B).  $^{123}\text{I}$ -IMP single photon emission tomography (SPECT) demonstrated that cerebral blood flow (CBF) was reduced in the bilateral frontal cortex (Fig.1C). Digital subtraction angiograms (DSAs) showed the near occlusion of the right relatively high cervical ICA and 80% stenosis of the left ICA (Fig.1D; lateral view of the right carotid angiogram, Fig.1E; lateral view of the left carotid angiogram). T1-weighted image of Black Blood (BB) method showed high intensity in the right ICA plaque and iso- intensity in the left plaque (arrows in Fig.1F-G).



**Fig. 2:** Post-operative neuroradiological findings of Case 1

One day after the carotid endarterectomy, DWI revealed no high signal (Fig.2A) and MRA showed improvement of flow signal of the right ICA (Fig.2B).  $^{123}\text{I}$ -IMP SPECT demonstrated postoperative hyperperfusion in the right frontal lobes (arrow head in Fig. 2C). Three-dimensional CT angiography (3D-CTA) after carotid stenting revealed excellent dilatations of the bilateral lesions (Fig.2D)



**Fig. 3:** Neuroradiological findings of Case 2

DWI illustrated several spotty high signals on bilateral cerebral hemispheres (Fig.3A), and  $^{123}\text{I}$ -IMP SPECT demonstrated CBF were reduced in the right hemisphere (Fig.3B). BB imaging showed

high intensity in the bilateral plaques (arrows in Fig.3C-D). DSAs showed the near occlusion of the right relatively high cervical ICA and 80% stenosis of the left ICA (Fig.3E; lateral view of the right carotid angiogram, Fig.3F; lateral view of the left carotid angiogram). Postoperative 3D-CTA revealed excellent dilatations of the bilateral lesions (Fig.3G; right ICA, Fig.3H; left ICA).

