



Title	Difference from Bile Duct Cancer and Relationship between Bile Duct Wall Thickness And Serum IgG/IgG4 Levels in IgG4-Related Sclerosing Cholangitis
Author(s)	Kuwatani, Masaki; Kawakami, Hiroshi; Zen, Yoh; Kawakubo, Kazumichi; Kudo, Taiki; Abe, Yoko; Kubo, Kimitoshi; Sakamoto, Naoya
Citation	Hepato-Gastroenterology, 61(135), 1852-1856 https://doi.org/10.5754/hge14546
Issue Date	2014-10
Doc URL	http://hdl.handle.net/2115/60252
Type	article (author version)
File Information	Difference_from_BDC.pdf



[Instructions for use](#)

**Difference from bile duct cancer and relationship between bile duct wall thickness and serum
IgG/IgG4 levels in IgG4-related sclerosing cholangitis**

Masaki Kuwatani¹⁾, M.D. Ph.D.; Hiroshi Kawakami, M.D., Ph.D.; Yoh Zen²⁾, M.D., Ph.D.;

Kazumichi Kawakubo¹⁾, M.D., Ph.D.; Taiki Kudo, M.D.; Yoko Abe, M.D.; Kimitoshi Kubo, M.D.;

Naoya Sakamoto, M.D., Ph.D.

1) Department of Gastroenterology and Hepatology, Hokkaido University Graduate School of
Medicine, North 15, West 7, Kita-ku, Sapporo 060-8638, Japan

2) Department of Pathology, Kobe University Graduate School of Medicine, 7-5-1 Kusunoki-cho,
Chuo-ku, Kobe 650-0017, Japan

Corresponding author: M. Kuwatani, E-mail: mkuwatan@med.hokudai.ac.jp

Tel: +81-11-716-1161 (ext. 5918); Fax: +81-11-706-7867

Key words: IgG4-related sclerosing cholangitis, IgG4, IgG, bile duct, intraductal ultrasonography

Text word count: 3052

Tables count: 5

Figures count: 3

Abbreviations

AD, antispasmodic drug; BD, bile duct; BDC, bile duct cancer; EUS-FNA, endoscopic ultrasonography-guided fine-needle aspiration; IDUS, intraductal ultrasonography; SC, sclerosing cholangitis

Abstract

Background/Aims: IgG4-related sclerosing cholangitis (IgG4-SC) is a newly established entity. The purpose of this study was to investigate the differences in intraductal ultrasonography (IDUS) findings between IgG4-SC and bile duct (BD) cancer (BDC) as well as the relationship among BD wall thickness, serological and pathological findings in IgG4-SC.

Methodology: Based on the diagnostic criteria of IgG4-SC, we reviewed patients in our hospital between April 2005 and June 2013, and analyzed the data obtained from 32 patients with IgG4-SC and 40 patients with BDC.

Results: Regarding IDUS findings, significantly more cases in BDC indicated rigid/papillary inner margin than in IgG4-SC, while biopsy was more efficient. There were no significant correlations between BD wall thickness and serum IgG/IgG4 levels or the number of IgG4-positive cells of the BD specimens. All the IgG4-SC patients without steroid treatment revealed discordant results in the shifts of IgG, IgG4 and BD wall thickness between the 1st and 2nd examinations, while all patients with steroid had completely concordant results of the shifts.

Conclusions: IDUS findings alone are insufficient for differentiation between IgG4-SC and BDC. BD wall thickness, serum IgG and IgG4 proportionally shift and reflect the effect of steroid on IgG4-SC after steroid treatment, not before it.

Introduction

IgG4-related sclerosing cholangitis (IgG4-SC) is a new entity which is characterized by specific bile duct (BD) stricture in the intrahepatic and extrahepatic BD, elevated serum IgG4 levels, coexistence of IgG4-related sclerosing lesions (autoimmune pancreatitis, dacryoadenitis/sialadenitis, or retroperitoneal fibrosis), and histological findings with IgG4-positive cells¹. In clinical practice, it is also important to differentiate IgG4-SC from BD cancer (BDC) and primary sclerosing cholangitis, because treatment strategies for each of these conditions are completely different. Regarding the differentiation of IgG4-SC from the others, some reports indicated the availabilities of cholangiogram findings², a cut-off value for serum IgG4 levels³ and findings of ultrasonography (US)⁴ or intraductal ultrasonography (IDUS)⁵ of the BD.

IDUS produces high resolution of images and can be accomplished by performing cholangiography and biliary drainage through the major papilla. Tamada et al. reported that each IDUS finding of a semicircular fashion, notched outer margin, rigid inner margin, papillary inner margin, or heterogeneous internal echoes with BD wall thickening, had a positive predictive value for diagnosing cancer extension (100%, 100%, 83%, 100%, and 90%, respectively)⁶. Naitoh et al. revealed that it was possible to efficiently distinguish IgG4-SC from BDC by using IDUS and that circular-symmetric wall thickness, a smooth outer and inner margin and a homogeneous internal echo in the stricture were significant characteristics of IgG4-SC⁵. However, the relationship between

BD wall thickness and serum IgG level in addition to serum IgG4 level and coexistence of IgG4-related sclerosing lesions other than SC have not been elucidated. We therefore aimed to investigate the BD wall thickness and IDUS findings associated with such serological findings and clinical manifestations in addition to differences in IDUS findings between IgG4-SC and BDC.

Methodology

Patients

We diagnosed and treated patients with IgG4-SC or extrahepatic BDC at Hokkaido University Hospital between April 2005 and June 2013. Based on the clinical diagnostic criteria of IgG4-SC 2012¹, we reviewed the patients and retrospectively analyzed the data obtained from 32 patients with IgG4-SC and 40 patients with BDC who underwent IDUS and curative surgery during the same period. All 32 patients with IgG4-SC underwent serological examinations for serum IgG4 and IgG levels and endoscopic retrograde cholangiography (ERC) with IDUS before biliary drainage or stenting, and 18 patients among them had a biopsy of the BD after IDUS. All 40 patients with BDC underwent ERC and IDUS before biliary drainage or stenting and biopsy.

This study was approved by the institutional review board of our hospital (clinical research approval number 013-0206). Written informed consent for ERC, IDUS, and sampling of bile duct biopsy specimen was obtained from all the patients.

ERC, IDUS and biopsy procedures

ERC and related procedures including IDUS and biopsy were performed when patients were under deep conscious sedation with fentanyl citrate/pethidine and midazolam/diazepam. Administration of antispasmodic drugs, scopolamine butylbromide or glucagon, and oxygen supply

through a nasal tube (2–3 L/min) were also appropriately performed. BD cannulation was performed with an endoscopic retrograde cholangiopancreatography (ERCP) catheter (Article-No.0130211; MTW Endoskopie, Wesel, Germany or StarTip cannula, PR-106Q; Olympus medical systems, Tokyo, Japan) with contrast medium or wire-guided cannulation technique with a triple-lumen papillotome (CleverCut3V, Olympus) or ERCP catheter as described above with a guidewire (Jagwire™; 0.035-inch, Boston Scientific, MA, USA or VisiGlide™; 0.025-inch, Olympus medical systems, Tokyo, Japan). After successful selective cannulation of the BD, ERC was performed for estimating the type of IgG4-SC (type1 to type 4)^{1,2} or BD stricture due to BDC and a guidewire was introduced into the intrahepatic BD for IDUS. Along the guidewire, an IDUS probe with a monorail type tip (UM-G20-29R, Olympus medical systems, Tokyo, Japan) was inserted into the BD, and scanning was performed by using a frequency of 20 MHz. After that, transpapillary biopsies of the BD wall were performed by using biopsy forceps (Radial Jaw3®; Boston Scientific or FB-45Q-1; Olympus) in 18 patients with IgG4-SC and in 36 patients with BDC.

Histological examinations

The biopsied or resected specimens were fixed in neutral formalin and embedded in paraffin. Sections (4 mm) were cut from each paraffin block and stained with hematoxylin–eosin. In the case of IgG4-SC, the sections were also examined by performing IgG4 immunostaining, which

was carried out with an autostainer (HX System Benchmark, Ventana Medical Systems, Tucson, AZ, USA) following the manufacturer's instructions. The primary antibody was an anti-IgG4 mouse monoclonal antibody (ZYMED Laboratory, San Francisco, CA, USA). IgG4-positive plasma cells were counted in the most inflamed high power field ($\times 400$) as previously described⁷.

Serum examination

We examined serum IgG and IgG4 levels of all patients with IgG4-SC at the initial diagnosis (1st examination) and at follow-up 1 to 6 months after diagnosis (2nd examination). The measurements of serum IgG and IgG4 concentrations were performed with nephelometry, by using IgG (N-Assay TIA IgG-SH Nittobo, Nittobo medical, Tokyo) and IgG4 (Mitsubishi Chemical Medience, Tokyo) kit, respectively at our institute.

Estimation of IDUS findings

BD wall thickness was measured at the site of the severest stricture in the cholangiogram in all 32 patients with IgG4-SC. At the same site, the structure of the thickened BD wall was evaluated regarding the following items as described in previous reports^{5, 6}: (1) layers (3 layers, hyper-hypo-hyperechoic layers; 1–2 layers, a hypoechoic layer or hypo-hyperechoic layers from the

inner side) (Figure 1), (2) outer margin (smooth, notched), (3) inner margin (smooth, spickle, rigid, or papillary), (4) internal echo (homogeneous, heterogeneous).

Statistical analyses

Categorical data were examined by using the χ^2 test. The Mann-Whitney U test, Kruskal-Wallis H test or *t*-test was used for comparison of quantitative data. Spearman correlation analysis was performed to test for correlations. These tests were performed with Microsoft Excel software (Redmond, WA), and the results were regarded as significant if $P < 0.05$.

Results

1. Characteristics of study patients

A total of 32 patients with IgG4-SC and 40 patients with BDC were enrolled and analyzed. Patient characteristics are shown in Table 1 and Table 2. The patients with IgG4-SC were divided into single extrabiliary lesion (EBL) group and multiple EBLs group according to the number of the IgG4-related lesions other than SC. The average age and the male-to-female ratios were not significantly different between the groups. All the patients with IgG4-SC had single or multiple IgG4-related sclerosing extrabiliary lesions (EBL) among the pancreas, salivary gland and retroperitoneum (single/multiple EBLs, 20/12 cases) (Table 1, 2). In the single EBL group, all the patients except for one case had EBL in the pancreas alone, while in the multiple EBLs group, all the patients had EBLs in the salivary gland or retroperitoneum in addition to the pancreas ($P=0.003$) (Table 2). Regarding classification of IgG4-SC, type 1 was the most frequent (47%, 15/32). Serum IgG and IgG4 values were not significantly different between the single and multiple EBLs groups (Table 2) or among the four types of IgG4-SC (Table 3), and BD wall thickness was also similar between the single and multiple EBLs groups (Table 2) or among the four types (Table 3), although the average BD wall thickness and serum IgG4 level tended to be high in the multiple EBLs group (1.7 mm vs. 2.3 mm, $P=0.11$; 500 mg/dL vs. 727 mg/dL, $P=0.10$) (Table 2). Meanwhile, the rate of cases with a BD wall ≥ 2 mm was significantly higher in the multiple EBLs group than in the single EBL group (Figure 2A).

2. IDUS findings of the BD wall in IgG4-SC and BDC

Next, we examined IDUS findings of the BD wall (layer structure, internal echo, inner margin and outer margin) between the single and multiple EBLs groups or the IgG4-SC and BDC groups (Figure 1, 2). Regarding layer structure, although the rate of 1-2 layers tended to be higher in the single EBL group or BDC patients than in the multiple EBLs group or IgG4-SC patients, it was not significantly different (Figure 2B, 2C). Regarding internal echo levels, IDUS revealed homogeneous echoes in most cases in both groups (Figure 2D). With respect to the inner and outer margins, many cases in both groups showed smooth outer margins, while significantly more cases in the BDC group indicated rigid or papillary inner margins (sensitivity, 58%; specificity, 72%) than in the IgG4-SC group (Figure 2E, 2F).

3. Relationship between BD wall thickness, serum IgG, IgG4 and IgG4-positive cells

In addition, we investigated the relationship between BD wall thickness, serum IgG, IgG4 and IgG4-positive cells in the biopsy specimen of BD, which were all considered to be candidates for indicators of the activity of IgG4-SC. First, we analyzed the relationships at the initial diagnosis of IgG4-SC (1st examination). Unexpectedly, there were no significant correlations between BD wall thickness and serum IgG or IgG4 level in the 32 cases (Figure 3A, 3B) and IgG4-positive cells in 18 cases (Figure 3C, Table 4). Meanwhile, we could obtain specimens which contained >10

IgG4-positive cells/high-power field in 11/18 IgG4-SC cases (61.1%) and we could also acquire specimens of adenocarcinoma in 33/36 cases (91.7%) with BDC.

Subsequently, we researched the changes in IgG, IgG4, and BD wall thickness between the 1st and 2nd examinations in the IgG4-SC patients without biliary stenting after the 1st examination in consideration of stent artifact (9 cases, Table 5). The median of intervals between 1st and 2nd examinations was 7.5 months (range, 0.5-28 months) in the 9 patients. Interestingly, the patients without steroid treatment (cases 1 to 4) revealed discordant results of the changes, while the patients with steroid treatment (cases 6 to 9) had the completely concordant results in the changes (all decreased). Case 5, with the past administration of steroid, indicated all increased changes. These results show that these changes could be barometers of the effect of steroid treatment.

Discussion

In clinical practice treating IgG4-SC, BD wall thickness, serum IgG, and IgG4 proportionally shift after steroid treatment, and they can be barometers of the effect of steroid treatment, while BD wall thickness and IgG or IgG4 do not correlate at the initial diagnosis.

Although IgG4-SC is classified into four types according to the diagnostic criteria of IgG4-SC¹, it has previously been shown that there is no significant difference in serum IgG4 levels between the four types³, and we showed for the first time in this study that there were no significant differences in serum IgG and IgG4 levels and BD wall thickness between the four types. This means that the type of IgG4-SC is not related to the activity of SC.

In general, serum IgG4 level is considered to be the best predictor of the activity of IgG4-related diseases^{8,9}. Thus, in the beginning, we supposed that at the initial diagnosis, serum IgG4 level would significantly correlate with BD wall thickness which would reflect the strength of cholangitis. However, our assumption was unexpectedly invalid as was the report of Naitoh et al⁵. One reason for the result would be that elevation of serum IgG4 level is a systemic reaction which can reflect conditions of various sites, while BD wall thickening is a focal reaction. This is also indicated in the relationship between serum IgG4 level and the number of IgG4-related lesions in the present study and in the previous report¹⁰ which showed that both had proportional relationships. In some cases, both systemic and focal reactions can be strong, and both serum IgG4 and BD wall thickness values can be high.

In differentiation of IgG4-SC or cholangitis from BDC, IDUS plays an important role as described in previous reports^{5,6}. Naitoh et al. revealed that IDUS findings of a smooth outer and inner margin and a homogeneous internal echo in the stricture were significant characteristics in IgG4-SC, but not in BDC⁵. Meanwhile, Tamada et al. indicated that a notched outer margin, rigid inner margin, papillary inner margin and heterogeneous internal echoes were useful for diagnosing cancer extension⁶. In the present study, although a rigid/papillary inner margin alone was a significant finding of BDC, the sensitivity (58%) and specificity (72%) were not sufficient as compared with the diagnostic accuracy of BD biopsy of BDC (91.7%). This means that IDUS findings of IgG4-SC are unexpectedly various and those of both IgG4-SC and BDC overlap each other to some extent.

The interpretation of layer structure of the BD in US or IDUS is still controversial. Koyama et al.⁴ reported that there were two types of ultrasonography findings in IgG4-SC, a 3-layer type and a parenchymal-echo type (similar to the 1–2 layers type in this study). They described that the difference between the two types is caused by the strength of inflammation which may be stronger in the parenchymal-echo type. However, our data showed the adverse result that IgG4⁺ cells in the biopsy specimen and serum IgG4 in the group of three layers (3-layer type) tended to be higher in the group of 1–2 layers (parenchymal-echo type). The shift from three layers to 1–2 layers or the reverse may not necessarily be unidirectional, although layer structure would reflect the inflammatory condition (acute or chronic phase, edematous or fibrous and the balance of the amount

of infiltrating cells and fibrosis¹¹. It needs to be clarified in the future what a difference in layer structure reflects.

Regarding changes of serum IgG, IgG4, and BD wall thickness, we obtained interesting and paradoxical results. When a steroid was not used, the changes did not necessarily parallel. Once a steroid was used, changes of the three indicators were concordant. Namely, all of the changes can be good barometers of the effect of steroid on IgG4-SC. We should pay attention to the changes, rather than to the values themselves.

In conclusion, IDUS findings alone are insufficient for differentiation between IgG4-SC and BDC. Although there are no correlations between BD wall thickness and serum IgG/IgG4 levels or the number of IgG4-positive cells of the BD before steroid treatment, BD wall thickness, serum IgG, and IgG4 proportionally change and reflect the steroid effect on IgG4-SC after steroid treatment.

Conflicts of interest

No potential conflict of interest relevant to this article was reported.

References

1. Ohara H, Okazaki K, Tsubouchi H, et al: Clinical diagnostic criteria of IgG4-related sclerosing cholangitis 2012. *J Hepatobiliary Pancreat Sci* 2012; 19:536-42.
2. Nakazawa T, Ohara H, Sano H, et al: Schematic classification of sclerosing cholangitis with autoimmune pancreatitis by cholangiography. *Pancreas* 2006; 32: 229-234.
3. Ohara H, Nakazawa T, Kawa S, et al: Establishment of a serum IgG4 cut-off value for the differential diagnosis of IgG4-related sclerosing cholangitis: A Japanese cohort. *J Gastroenterol Hepatol* 2013; 28:1247-51.
4. Koyama R, Imamura T, Okuda C, et al: Ultrasonographic imaging of bile duct lesions in autoimmune pancreatitis. *Pancreas* 2008; 37:259-64.
5. Naitoh I, Nakazawa T, Ohara H, et al: Endoscopic transpapillary intraductal ultrasonography and biopsy in the diagnosis of IgG4-related sclerosing cholangitis. *J Gastroenterol* 2009; 44:1147-55.
6. Tamada K, Kanai N, Wada S, et al: Utility and limitations of intraductal ultrasonography in distinguishing longitudinal cancer extension along the bile duct from inflammatory wall thickening. *Abdom Imaging* 2001; 26:623-31.
7. Kawakami H, Zen Y, Kuwatani M, et al: IgG4-related sclerosing cholangitis and autoimmune pancreatitis: histological assessment of biopsies from Vater's ampulla and the bile duct. *J Gastroenterol Hepatol* 2010; 25:1648-55.

8. Tabata T, Kamisawa T, Takuma K, et al: Serial changes of elevated serum IgG4 levels in IgG4-related systemic disease. *Intern Med* 2011; 50:69-75.
9. Hamano H, Kawa S, Horiuchi A, et al: High serum IgG4 concentrations in patients with sclerosing pancreatitis. *N Engl J Med* 2001; 344:732-738.
10. Ryu JH, Horie R, Sekiguchi H, et al: Spectrum of Disorders Associated with Elevated Serum IgG4 Levels Encountered in Clinical Practice. *Int J Rheumatol.* 2012; 2012:232960. doi: 10.1155/2012/232960
11. Zen Y, Harada K, Sasaki M, et al: IgG4-related sclerosing cholangitis with and without hepatic inflammatory pseudotumor, and sclerosing pancreatitis-associated sclerosing cholangitis: do they belong to a spectrum of sclerosing pancreatitis? *Am J Surg Pathol* 2004; 28:1193-203.

Figure legends

Figure 1: Schemas and examples of IDUS findings of the BD wall. In schemas, a white line indicates a hyperechoic layer and a gray line indicates a hypoechoic layer. The “3 layers” type of the BD wall in IDUS consists of hyper-hypo-hyperechoic layers from the inner side, while the “1–2 layers” type consists of hypoechoic or hypo-hyperechoic layers. In the upper row, two cases of IgG4-SC (A) and BDC (B) in the “3 layers” type are shown. In the lower row, two cases of IgG4-SC (C) and BDC (D) in the “1–2 layers” type are shown.

Figure 2: The frequencies of categories of BD wall thickness ($<2\text{mm}$ and $\geq 2\text{mm}$) (A) and layer structure (B) in IDUS in the single EBL and multiple EBLs groups are indicated. Furthermore, various types in respective IDUS findings of the BD wall (layer structure, internal echo, inner margin and outer margin) in the IgG4-SC and BDC groups (C–F) are also shown. An asterisk indicates a significant difference ($P<0.05$).

‘Single’ and ‘Multiple’ mean single EBL group and multiple EBLs group, respectively.

‘homo’ indicates ‘homogeneous’; hetero, heterogeneous; pap, papillary.

Figure 3: The relationships between the BD wall thickness and serum IgG, IgG4 or the number of IgG4⁺ cells in the biopsy specimen of the BD wall are plotted (A–C). The BD wall thickness did not correlate with either serum IgG or IgG4 levels, or the number of IgG4⁺ cells.

Table 1. Characteristics of patients.

	IgG4-SC	BDC	P value
Number	32	40	0.99
Age, year, (mean±SD)	68.0±7.6	68.2±8.1	0.67
Male/Female	27/5	31/9	
Single/multiple EBL ^a	20/12		
Classification of SC Type 1	15		
Type 2	6		
Type 3	7		
Type 4	3		
Type X ^b	1		

SD, standard deviation; SC, sclerosing cholangitis; BDC, bile duct cancer; EBL, extrabiliary lesion

^aExtrabiliary lesions are among the three areas that are the pancreas, salivary gland and retroperitoneum.

^bType X indicates 'not classified'.

Table 2. Characteristics of patients with IgG4-SC according to extrabiliary lesions^a.

	Single-EBL	Multiple-EBL	P value
Number	20	12	
Age, year, (mean±SD)	68.8±7.2	66.8±8.2	0.47
Male/Female	16/4	11/1	0.63
Areas of EBLs			
Pancreas	19	12 ^b	
Salivary gland	1	7	
Retroperitoneum	0	10	0.003
BD wall thickness	1.7±0.67	2.3±0.96	0.11
Serum IgG	1947±698	2239±856	0.30
Serum IgG4	500±317	727±445	0.10

SC, sclerosing cholangitis; EBL, extrabiliary lesion

Valules in age, BD wall thickness, serum IgG and IgG4 indicate mean±standard deviation.

^aExtrabiliary lesions are among the three areas that are the pancreas, salivary gland and retroperitoneum.

^bFive in 12 patients had all the three EBLs.

Table 3. Serum IgG, IgG4, and BD wall thickness in each type of IgG4-SC.

Classification of IgG4-SC	Serum IgG		Serum IgG4		BD wall thickness	
	(mg/dl)	P value	(mg/dl)	P value	(mm)	P value
Type 1 (n=15)	1954±778		468±290		1.9±0.6	
Type 2 (n=6)	2355±1060		602±324		1.9±0.5	
Type 3 (n=7)	1906±332		812±457		2.1±1.0	
Type 4 (n=3)	2391±229	0.12	630±422	0.36	2.2±1.4	0.89

SD, standard deviation; SC, sclerosing cholangitis; BD, bile duct

Table 4. BD wall thickness, serum IgG4 and IgG4⁺ cells in a biopsy specimen of BD.

Case	BD wall thickness (mm)	Serum IgG4 (mg/dl)	IgG4+ cells (/HPF)
1	1.6	216	22
2	1.5	251	32
4	1.8	1280	16
5	1.3	312	0
6	1.6	556	0
10	3.8	291	24
11	1.5	937	0
12	2.1	195	0
13	1.2	204	0
14	1.4	389	14
15	1.3	625	20
16	1.8	341	0
17	2.6	641	157

18	1.5	272	4
19	1.7	414	47
20	2.6	410	43
21	1.4	820	12
22	1.6	90	55

BD, bile duct; HPF, high power field

Table 5. Shifts of IgG, IgG4 and BD wall thickness.


Case	Serum IgG (mg/dl)			Serum IgG4 (mg/dl)			BD wall thickness (mm)		
	1st	2nd	change	1st	2nd	change	1st	2nd	change
1	1435	1498	+	216	346	+	1.6	1.0	-
2	1846	1755	-	251	245	-	1.5	2.6	+
3	2197	2662	+	888	1340	+	1.1	1.1	±
4	2462	2733	+	1280	1180	-	1.8	2.2	+
5	1821	1991	+	312	484	+	1.3	1.6	+
6	1748	1162	-	556	345	-	1.6	1.0	-
7	2264	1232	-	968	263	-	4.2	1.6	-

8	2427	1001	–	1270	241	–	2.4	1.6	–
9	2713	2083	–	35	5	–	1.4	1.0	–

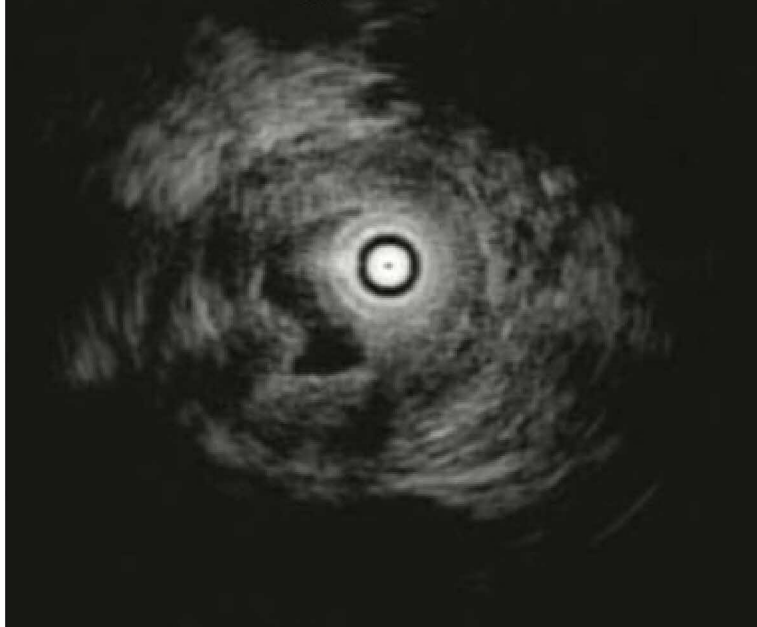
BD, bile duct; 1st, 1st examination; 2nd, 2nd examination; +, increase from 1st to 2nd examination; –, decrease from 1st to 2nd examination

Case1 to 4 were not treated and case 6 to 9 were treated with steroid after the 1st examination. Case 5 alone had experienced steroid treatment for another disease in the past and not treated during this period. * In change, + indicates an increase from 1st to 2nd examination; –, decrease.

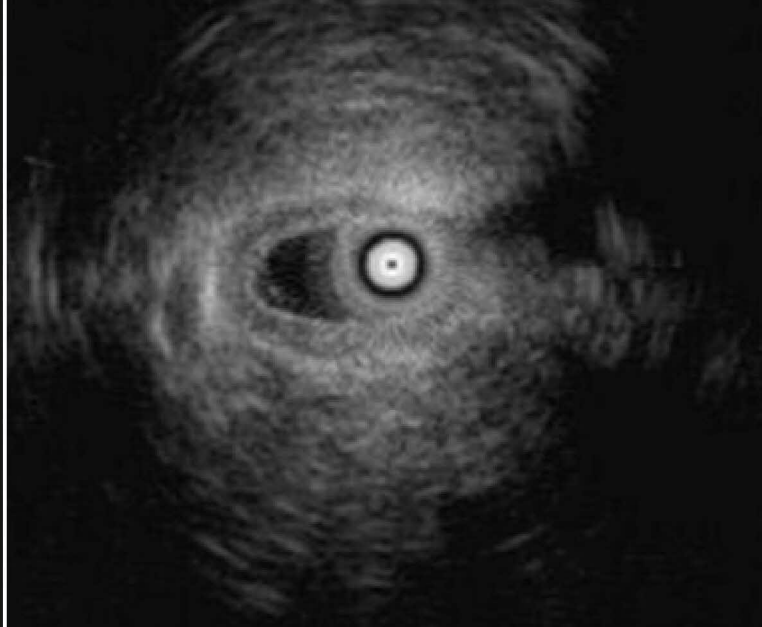3 layers




A IgG4-SC



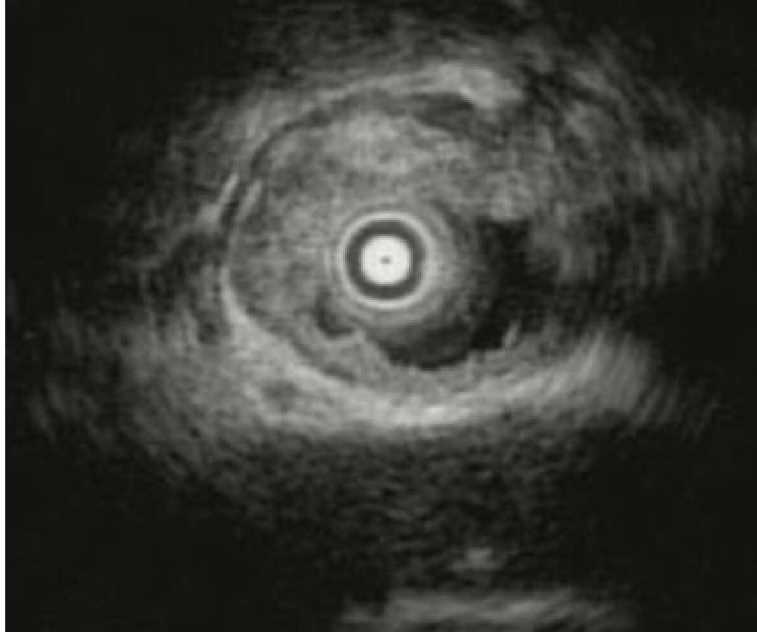
B BDC



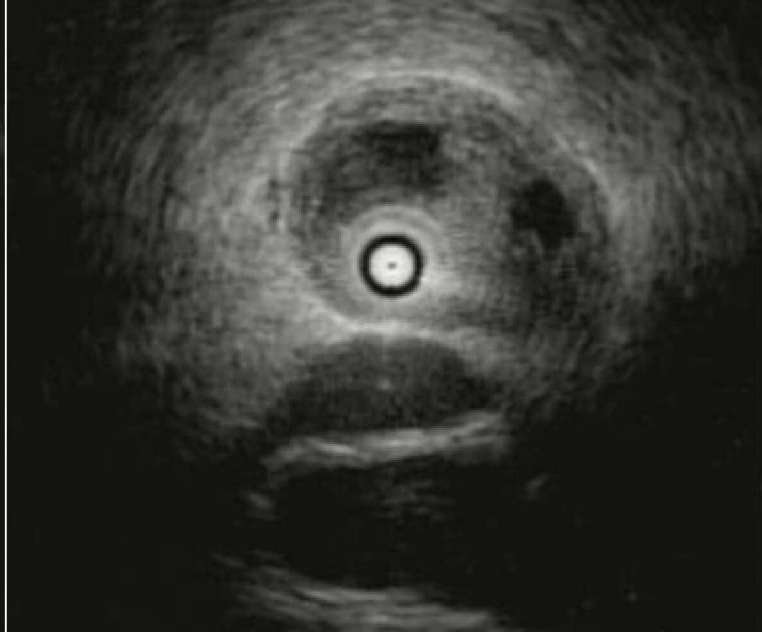1-2 layers



C

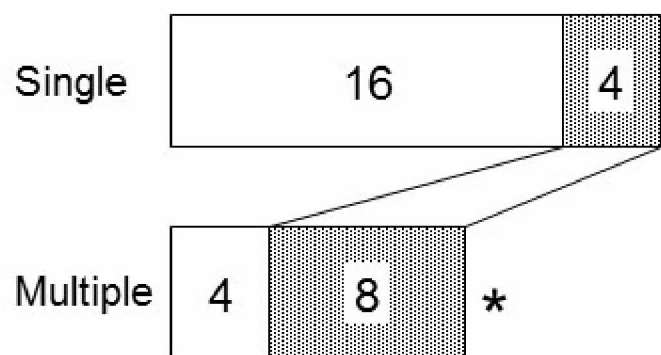


D



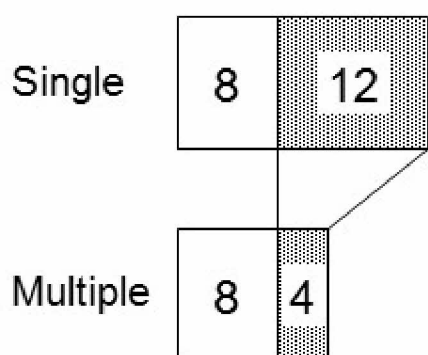
A

□ BD wall < 2 mm ■ BD wall ≥ 2 mm



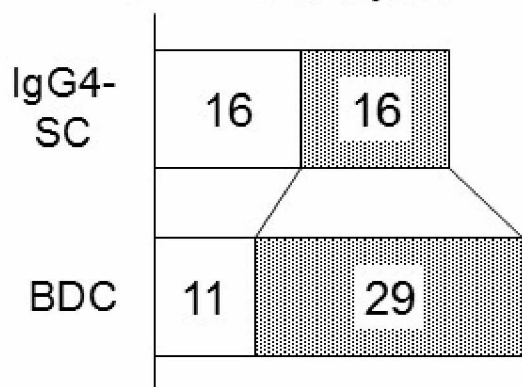
B Layer structure

□ 3 layers ■ 1–2 layers



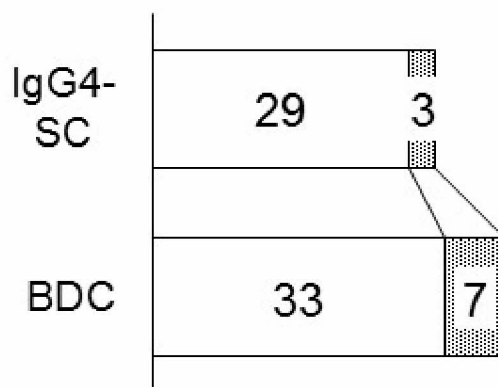
C Layer structure

□ 3 layers ■ 1–2 layers



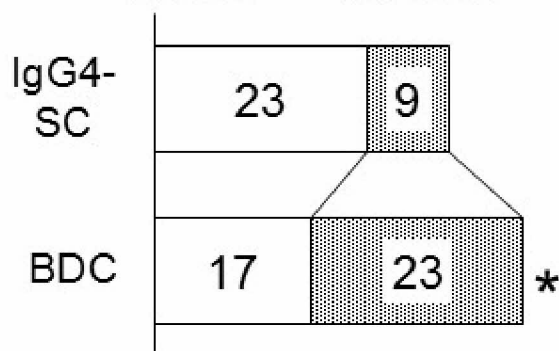
D Internal echo

□ homo ■ hetero



E Inner margin

□ smooth ■ rigid/pap



F Outer margin

□ smooth ■ notched

