



Title	Prognostic significance of epithelial-mesenchymal transition-related markers in extrahepatic cholangiocarcinoma : comprehensive immunohistochemical study using a tissue microarray
Author(s)	Nitta, T.; Mitsuhashi, Tomoko; Hatanaka, Y.; Miyamoto, M.; Oba, K.; Tsuchikawa, T.; Suzuki, Y.; Hatanaka, K. C.; Hirano, S.; Matsuno, Y.
Citation	British Journal of Cancer, 111(7), 1363-1372 <a href="https://doi.org/10.1038/bjc.2014.415">https://doi.org/10.1038/bjc.2014.415</a>
Issue Date	2014-09-23
Doc URL	<a href="http://hdl.handle.net/2115/59851">http://hdl.handle.net/2115/59851</a>
Rights(URL)	<a href="http://creativecommons.org/licenses/by-nc-sa/3.0/">http://creativecommons.org/licenses/by-nc-sa/3.0/</a>
Type	article
Note	Supplementary Information accompanies this paper on British Journal of Cancer website.
Note(URL)	<a href="http://www.nature.com/bjc/journal/v111/n7/supinfo/bjc2014415s1.html">http://www.nature.com/bjc/journal/v111/n7/supinfo/bjc2014415s1.html</a>
File Information	bjc2014415a.pdf



[Instructions for use](#)

**Keywords:** EMT; extrahepatic cholangiocarcinoma; immunohistochemistry; tissue microarray; prognosis; survival; cadherin switch

# Prognostic significance of epithelial–mesenchymal transition-related markers in extrahepatic cholangiocarcinoma: comprehensive immunohistochemical study using a tissue microarray

T Nitta<sup>1,2</sup>, T Mitsuhashi<sup>\*1</sup>, Y Hatanaka<sup>1</sup>, M Miyamoto<sup>2</sup>, K Oba<sup>3</sup>, T Tsuchikawa<sup>2</sup>, Y Suzuki<sup>1</sup>, K C Hatanaka<sup>1</sup>, S Hirano<sup>2</sup> and Y Matsuno<sup>1</sup>

<sup>1</sup>Department of Surgical Pathology, Hokkaido University Hospital, N14, W5, Kita-ku, Sapporo, Hokkaido 060-8648, Japan;

<sup>2</sup>Department of Gastroenterological Surgery II, Hokkaido University Graduate School of Medicine, N14, W5, Kita-ku, Sapporo, Hokkaido 060-8648, Japan and <sup>3</sup>Translational Research and Clinical Trial Center, Hokkaido University Hospital, N14, W5, Kita-ku, Sapporo, Hokkaido 060-8648, Japan

**Background:** Epithelial–mesenchymal transition (EMT) is characterised by the loss of cell-to-cell adhesion and gaining of mesenchymal phenotypes. Epithelial–mesenchymal transition is proposed to occur in various developmental processes and cancer progression. ‘Cadherin switch’, a process in which cells shift to express different isoforms of the cadherin transmembrane protein and usually refers to a switch from the expression of E-cadherin to N-cadherin, is one aspect of EMT and can have a profound effect on tumour invasion/metastasis. The aim of this study was to investigate the clinicopathological significance of EMT-related proteins and cadherin switch in extrahepatic cholangiocarcinoma (EHCC).

**Methods:** We investigated the association between altered expression of 12 EMT-related proteins and clinical outcomes in patients with EHCC ( $n=117$ ) using immunohistochemistry on tissue microarrays.

**Results:** Univariate and multivariate analyses revealed that, in addition to N classification ( $P=0.0420$ ), the expression of E-cadherin ( $P=0.0208$ ), N-cadherin ( $P=0.0038$ ) and S100A4 ( $P=0.0157$ ) was each an independent and a significant prognostic factor. We also demonstrated that cadherin switch was independently associated with poor prognosis ( $P=0.0143$ ) in patients with EHCC.

**Conclusions:** These results may provide novel information for selection of patients with EHCC who require adjuvant therapy and strict surveillance.

Cholangiocarcinoma (CC) is a primary tumour originating from the bile duct epithelium and is classified as either intrahepatic or extrahepatic (Gandou *et al*, 2013; Aishima *et al*, 2014). As a result of the different embryological origins of extrahepatic and intrahepatic bile ducts, there may be the phenotypic diversity between extrahepatic and intrahepatic CC (Gandou *et al*, 2013).

Extrahepatic CC (EHCC) is a highly malignant neoplasm, and the 5-year survival rate for patients who undergo surgical resection is reported to be only 20–40% (DeOliveira *et al*, 2007; Van der Gaag *et al*, 2012). Extrahepatic CC is a relatively uncommon disease with a reported incidence of 1–2 cases per 100 000 per year (Van der Gaag *et al*, 2012). The therapeutic gold standard for EHCC is

\*Correspondence: Dr T Mitsuhashi; E-mail: mitsut74@huhp.hokudai.ac.jp

Received 3 February 2014; revised 25 June 2014; accepted 1 July 2014; published online 31 July 2014

© 2014 Cancer Research UK. All rights reserved 0007–0920/14

complete resection of the tumour; however, local and distant recurrences occur in many patients after surgery (DeOliveira *et al*, 2007; Araki *et al*, 2011; Van der Gaag *et al*, 2012). Therefore, for such biologically aggressive EHCC, adjuvant therapy is often needed after surgical resection. For this reason, it is necessary to identify factors that can accurately predict outcomes in patients with EHCC.

Epithelial–mesenchymal transition (EMT) was first recognised as a central differentiation process in early embryonic morphogenesis, and is characterised by loss of cell-to-cell junctions, specifically loss of epithelial phenotypes, and increased mobility due to cells gaining mesenchymal phenotypes (Thiery *et al*, 2009). The hallmark of EMT is downregulation of E-cadherin, an essential transmembrane protein for stable adherence junctions, and upregulation of mesenchymal molecules such as vimentin, fibronectin and N-cadherin (Thiery *et al*, 2009).

Epithelial–mesenchymal transition is also regulated by several transcription factors, such as Snail, Slug, Twist, Zeb1 and Zeb2 (Uchikado *et al*, 2005; Shioiri *et al*, 2006; Hotz *et al*, 2007; Wang *et al*, 2007; Usami *et al*, 2008; Sato *et al*, 2010; Gemmill *et al*, 2011; Kahlert *et al*, 2011; Ru *et al*, 2011; Sung *et al*, 2011; Dai *et al*, 2012; Kurahara *et al*, 2012). The functions of these factors are regulated by complex signalling networks present in the tumour micro-environment, such as transforming growth factor  $\beta$ , notch and Wnt pathways (Thiery *et al*, 2009; Sato *et al*, 2010; Kurahara *et al*, 2012).

It has recently become clear that EMT has an important role in tumour progression and metastasis (Thiery *et al*, 2009). In the gastrointestinal tract, many studies have shown that EMT is implicated in the progression and metastasis of cancers such as oesophageal (Usami *et al*, 2008; Sung *et al*, 2011), gastric (Kim *et al*, 2009; Ru *et al*, 2011; Dai *et al*, 2012; Ryu *et al*, 2012), colorectal (Shioiri *et al*, 2006; Kahlert *et al*, 2011) and pancreatic cancers (Hotz *et al*, 2007; Kurahara *et al*, 2012). Many EMT-related proteins including transcription factors have been investigated, and some of them have been shown to correlate with poor prognosis in some carcinomas (Thiery *et al*, 2009). Moreover, ‘cadherin switch’, one aspect of EMT showing a loss of E-cadherin expression and a gain of N-cadherin expression, has a profound effect on tumour invasion/metastasis and is associated with unfavourable outcomes in several types of cancer (Gravdal *et al*, 2007; Wheelock *et al*, 2008; Jäger *et al*, 2010; Araki *et al*, 2011). Loss of E-cadherin expression and gain of N-cadherin expression is reminiscent of the cadherin switching that is seen during normal embryonic development and probably underpins many of the phenotypic changes in cancers. To our knowledge, only a few reported case series of EHCC have investigated a clinicopathological significance of EMT and cadherin switch in relation to tumour progression (Sato *et al*, 2010; Araki *et al*, 2011; Fabris *et al*, 2011). However, these studies were limited by the small numbers of cases and EMT-related proteins investigated, the prognostic significance of EMT and cadherin switch in EHCC has not yet been examined in detail.

The aim of this study was to investigate the clinicopathological significance of the expression of EMT-related proteins and cadherin switch in a large series of patients who underwent resection of EHCC.

## MATERIALS AND METHODS

**Cell lines.** First of all, we need to validate antibodies used in this study, because many of the EMT-related proteins especially transcription factors have not been fully studied in actual surgically resected EHCC. The pancreatic adenocarcinoma cell lines Panc-1 and AsPc-1, the lung adenocarcinoma cell lines H1299 and H1650, and the breast carcinoma cell lines MDA-MB231, MCF7 and T47D

were used for antibody validation (Hotz *et al*, 2007; Taube *et al*, 2010; Gemmill *et al*, 2011; Devarajan *et al*, 2012). Panc-1, H1299 and MDA-MB231 were cultured in D-MEM (Gibco BRL, Grand Island, NY, USA), and AsPc-1, H1650 and T47D were grown in RPMI-1640 (Sigma-Aldrich Japan, Tokyo, Japan), both of which were supplemented with 10% foetal bovine serum (FBS) and 1% penicillin/streptomycin. MCF7 was cultured in D-MEM supplemented with 10% FBS, 1% penicillin/streptomycin and 1% non-essential amino acids. All cell lines were maintained in a humidified incubator with 5% CO<sub>2</sub> in air at 37 °C.

**Reverse transcription-polymerase chain reaction.** Total RNAs from the cell lines were extracted using Trizol reagent (Invitrogen Life Technologies, Carlsbad, CA, USA) and cDNA was synthesised with the Transcript First Strand cDNA Synthesis Kit (Roche, Indianapolis, IN, USA) in accordance with the manufacturer’s protocols. The expression of EMT transcription factors was examined by reverse transcription polymerase chain reaction (RT-PCR) using the following primers (Hotz *et al*, 2007; Lindley and Briegel, 2010): Snail (557 bp) (forward) 5′-CAGACCCACTCA GATGTCAA-3′, (reverse) 5′-CATAGTTAGTCACACCTCGT-3′; Slug (182 bp) (forward) 5′-TGCGATGCCAGTCTAGAAA-3′, (reverse) 5′-TTCTCCCCCGTGTGAGTTC-3′; Twist (196 bp) (forward) 5′-GTCCGCAGTCTTACGAGGAG-3′, (reverse) 5′-TG GAGGACCTGGTAGAGGAA-3′; Zeb1 (195 bp) (forward) 5′-CCT GTCCATATTGTGATAGAGGC-3′, (reverse) 5′-ACCCAGACTG CGTCACATGT-3′; Zeb2 (190 bp) (forward) 5′-AGGGACAGAT CAGCACAAA-3′, (reverse) 5′-GTGCGAACTGTAGGAAC CAG-3′; GAPDH (150 bp) (forward) 5′-ATCAAGTGGGGCGAT GCTG-3′, (reverse) 5′-ACCCATGACGAACATGGGG-3′.

GAPDH cDNA was amplified as a control. The PCR conditions were: initial denaturing at 94 °C for 5 min, followed by 30 cycles of denaturing at 94 °C for 30 s, annealing at 55 °C for 30 s and extension at 72 °C for 60 s. All PCR products were visualised by electrophoresis and ethidium bromide staining in 2% agarose gels.

**Samples from patients.** Surgical specimens of resected EHCC obtained between January 1995 and November 2006 at the Department of Gastroenterological Surgery II, Hokkaido University Graduate School of Medicine, were used in this study. A total of 117 specimens obtained from 92 males and 25 females (median age 71 years, range 44–87 years) were examined using the tissue microarray method. The median follow-up period was 26 months (range 0–151 months), and 89 patients (76.1%) died during follow-up. None of the patients received chemotherapy preoperatively. The tumour stage was classified according to the 7th TMN classification of the Union for International Cancer Control (Sobin *et al*, 2009). Extrahepatic CC was classified as a perihilar ( $n = 74$ ) or distal ( $n = 43$ ) on the basis of the location of the tumour epicentre or predominance of the main tumour (DeOliveira *et al*, 2007; Ebata *et al*, 2009). Macroscopically, the tumours were classified into three broad categories: papillary ( $n = 18$ ), nodular ( $n = 79$ ) and infiltrating ( $n = 20$ ). The latter two categories were grouped together as non-papillary tumours because the papillary form has specifically been associated with favourable survival outcomes (Jarnagin *et al*, 2005). Superficial spread was defined as extension of noninvasive carcinoma (carcinoma *in situ*) by >20 mm from the main tumour (Nakanishi *et al*, 2008). All informed consent processes for this study were conducted in accordance with the guidelines of the Hokkaido University Institutional Review Board.

**Tissue microarray.** Archival slides for all the cases were reviewed to select two representative areas (both the invasive front and bulk of tumour) and one representative area of non-neoplastic bile duct as an internal control. Tissue microarray blocks were then constructed using a manual tissue microarrayer (JF-4; Sakura Finetek Japan, Tokyo, Japan) with a 2.0-mm diameter needle. The

finalised array blocks were sliced into 4- $\mu$ m-thick sections and mounted on glass slides. To check the histopathological diagnosis and adequacy of tissue sampling, a section from each microarray was stained with haematoxylin and eosin and examined by an experienced pathologist (TM).

**Immunohistochemical evaluation.** Tissue sections were deparaffinised in xylene and rehydrated through a graded ethanol series. Heat-induced antigen retrieval was carried out in high-pH antigen retrieval buffer (Dako Cytomation, Glostrup, Denmark). Endogenous peroxidase was blocked by incubation in 3% H<sub>2</sub>O<sub>2</sub> for 5 min. Details of the primary antibodies used are listed in Table 1. These sections were visualised by the HRP-labelled polymer method (Dako EnVision FLEX system) and an automated immunostaining system (Dako Autostainer Link). Immunostained sections were counterstained with haematoxylin, dehydrated in ethanol and cleared in xylene. Double immunostaining for N-cadherin and E-cadherin was performed using the HRP/DAB and ALP/Permanent red detection systems, respectively. After immunostaining for N-cadherin as described above, the sections were heat treated to strip the first step antibody in citrate-based buffer pH 6.0 (Dako Cytomation). The sections were immunostained for E-cadherin, and then visualised using the ALP-labelled LSAB method (Ventana iVIEW universal kit, Basel, Switzerland). Immunostained sections were counterstained with haematoxylin.

In this study, we evaluated immunohistochemical staining in terms of both staining intensity and proportion of stained tumour cells in the TMA cores. We initially evaluated the staining intensities of tumour cells, based on the staining of the control

normal bile duct epithelium. The staining of epithelial markers E-cadherin and CK19 were considered positive (high expression), if the staining intensity was equivalent to that in normal epithelium. The staining of mesenchymal and transcription factor markers were considered positive (high expression), if weak to strong positive staining was seen compared with normal epithelium. The proportions of tumour cells with recognised staining alteration compared with normal epithelium were quantified as a percentage of the total number of tumour cells for an each TMA core. The staining results of these 12 markers were finally evaluated based on the mean proportion of two EHCC cores in each case. As for the evaluation of podoplanin, stromal expression of podoplanin was defined as positive when over than 30% of stromal fibroblastic cells were stained, as previously reported (Shindo *et al*, 2013). Ki67-positive cells were evaluated after identifying the areas where the highest number of the nuclear-positive cells were detected or 'hot spots'. In this study, we used  $\alpha$ -smooth muscle actin ( $\alpha$ -SMA) as markers for both mesenchymal (i.e., EMT-related) and cancer-associated fibroblasts (CAFs). As for the immunohistochemical evaluation of  $\alpha$ -SMA as CAFs' marker, the staining in the fibroblasts within tumour stroma was qualitatively classified into four groups (grade 0, +1, +2 and +3), as previously reported (Chuaysri *et al*, 2009). For statistical analysis, the grades 0 and +1 were categorised as negative expression and grades +2 and +3 as positive expression.

Two researchers (TN and TM), who were blinded to the patients' clinical information, independently examined and scored each case. Differences in interpretation were resolved by consensus agreements of them.

Table 1. Antibodies used for immunohistochemistry

Marker	Type	Source	Clone	Dilution	Antigen retrieval	Immunohistochemical patterns	Antibody validation control cell line (positive/negative)	Cutoff value of immunohistochemistry (%)
E-cadherin	EM	Invitrogen (Carlsbad, CA, USA)	4A2C7	RTU	Tris-EDTA	Cytoplasmic membrane	—	43
CK19	EM	Novocastra (Newcastle-upon-Tyne, UK)	b170	1:100	Tris-EDTA	Cytoplasm	—	20
Vimentin	MM	Ventana (Basel, Switzerland)	V9	RTU	Tris-EDTA	Cytoplasm	—	43
N-cadherin	MM	Dako (Carpinteria, CA, USA)	6G11	1:50	Tris-EDTA	Cytoplasmic membrane	—	35
S100A4	MM	Abcam (Cambridge, UK)	PAb (rabbit)	1:200	Prot K	Nuclear	—	50
$\alpha$ -SMA	MM/CAFs	Dako	1A4	1:50	Tris-EDTA	Cytoplasm	—	5 <sup>a</sup>
Fibronectin	MM	Dako	PAb (rabbit)	1:2000	Prot K	Cytoplasm	—	8
Snail	TF	Abcam	PAb (goat)	1:500	Tris-EDTA	Nuclear	Panc1/H1299	60
Slug	TF	Abcam	PAb (rabbit)	1:100	Tris-EDTA	Nuclear	MDA-MB231/T47D	33
Twist	TF	Abcam	Twist2C1a	1:20	Tris-EDTA	Nuclear	T47D/Panc1	15
Zeb1	TF	GenWay (San Diego, CA, USA)	416A7H10	1:20	Tris-EDTA	Nuclear	MDA-MB231/MCF7	50
Zeb2	TF	Novus Biological (Littleton, CO, USA)	PAb (rabbit)	1:400	Tris-EDTA	Cytoplasm	H1299/MCF7	63
Podoplanin	CAFs	Dako	D2-40	RTU	Tris-EDTA	Stromal fibroblasts	—	30
Ki67	—	Dako	MIB-1	1:200	Tris-EDTA	Nuclear	—	—

Abbreviations: CAFs = cancer-associated fibroblasts marker; CK = cytokeratin; EM = epithelial marker; MM = mesenchymal marker; PAb = polyclonal antibody; Prot K = proteinase K solution; RTU = ready to use;  $\alpha$ -SMA =  $\alpha$ -smooth muscle actin; TF = transcription factor marker; Tris-EDTA = Tris-EDTA-based solution.

<sup>a</sup>This cutoff value of  $\alpha$ -SMA is that for the mesenchymal marker (i.e., EMT-related marker). As for the immunohistochemical evaluation of  $\alpha$ -SMA as a CAFs marker, refer to the main text.

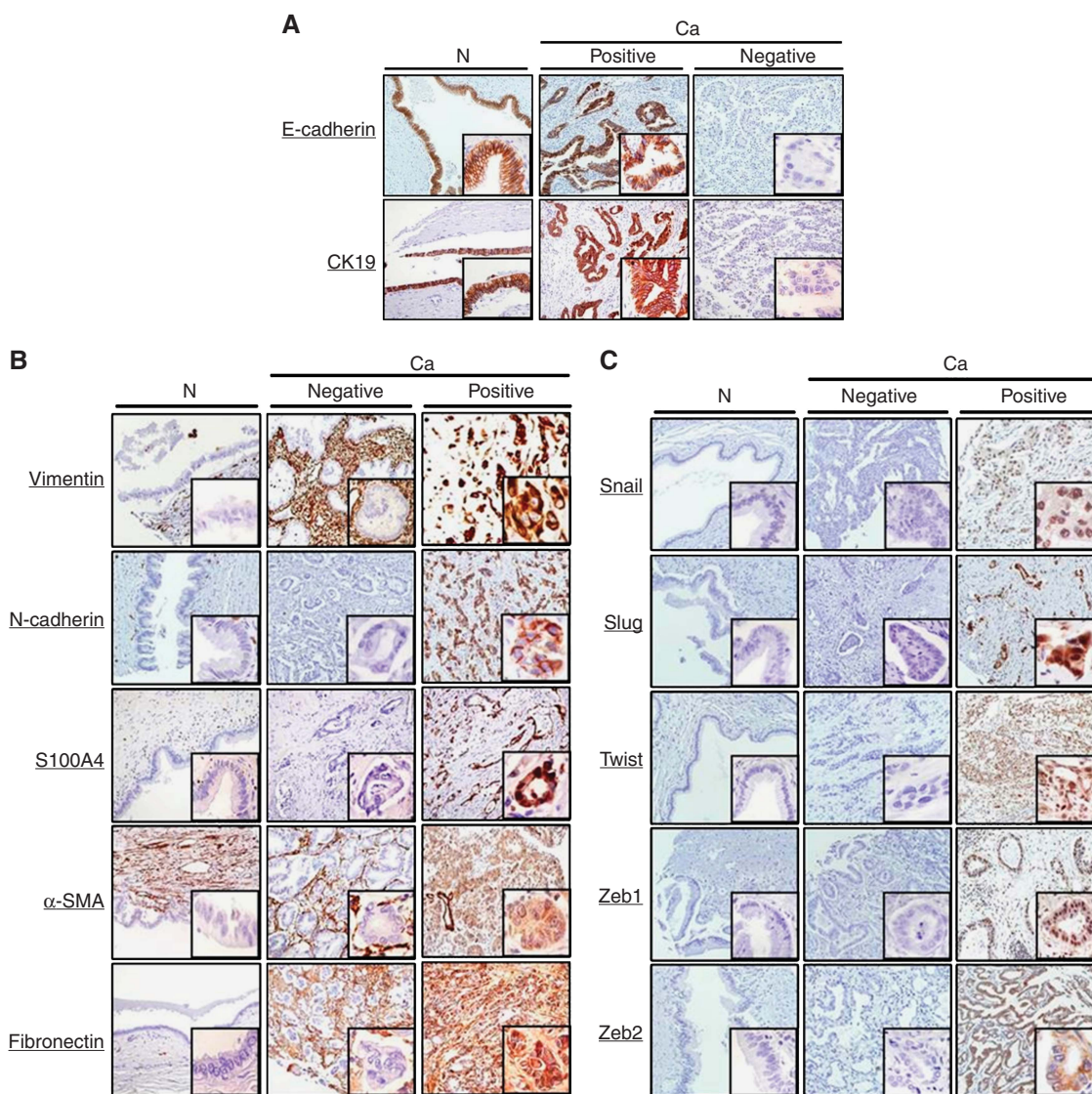
**Statistical analysis.** To determine a suitable cutoff point for the proportion of tumour cells with recognised staining alteration and dichotomising the level of immunohistochemical staining into either high or low expression groups, we used a receiver operating characteristic (ROC) curve according to the previous report (Tripathi *et al*, 2012) with modifications. The values of the proportions of tumour cells with recognised staining alteration as a continuous variable and survival (alive or dead at the median follow-up time) as a binary variable were subjected to ROC analysis.

Statistical analysis of the immunohistochemical staining was performed using the  $\chi^2$  test, Fisher's exact test and Mann-Whitney *U*-test. Overall patient survival was calculated from the date of surgery to the date of the last follow-up or patient death. Univariate survival analysis was performed according to the Kaplan-Meier method, and survival was compared using the log-rank test. Multivariate analysis was conducted using the Cox proportional hazards regression model. The level for significance was  $P < 0.05$  and the confidence interval (CI) was determined at the 95% level. Statistical analysis was performed using the JMP 10.0 software package (SAS Institute, Inc., Cary, NC, USA) for Windows.

## RESULTS

**Antibody validation for immunohistochemistry of EMT transcription factors.** We validated the antibodies against EMT transcription factors and optimised their staining conditions in formalin-fixed, paraffin-embedded (FFPE) materials because these antibodies are not generally used for routine histological diagnoses and less well characterised. Positive and negative control FFPE cell blocks were prepared on the basis of the results obtained by RT-PCR (Supplementary Data 1a). Representative immunohistochemical staining patterns for EMT transcription factors are shown in Supplementary Data 1b. These validation data are also incorporated in Table 1.

**Expression of EMT-related proteins in EHCC.** Figure 1A–C show representative immunohistochemical staining patterns from different cases for EMT-related proteins in the areas of carcinomas and non-neoplastic epithelia of the bile ducts. E-cadherin and N-cadherin showed a membranous staining pattern (Figure 1A and B). On the other hand, CK19, vimentin,  $\alpha$ -SMA and fibronectin were detected in the cytoplasm (Figure 1A and B).



**Figure 1.** Representative immunohistochemical staining patterns for 12 EMT-related markers are shown for carcinoma lesions (Ca) and non-neoplastic epithelium (N) of the bile duct. For each marker, positive and negative areas are from different patients. (A) epithelial markers, (B) mesenchymal markers and (C) transcription factor markers.

Although S100A4 showed cytoplasmic and nuclear staining in cancer cells, nuclear S100A4 staining was considered to be positive because of its cytoplasmic expression in the non-neoplastic component that was induced by an epithelial reaction to damage (Fabris *et al*, 2011; Figure 1B). Immunohistochemical localisation of EMT transcription factors was consistent with cell block analysis (Figure 1C).

#### Survival analysis on the basis of EMT-related protein expression.

Overall patient survival rates were determined using the log-rank test with respect to expression of the 12 EMT-related proteins. In terms of epithelial markers, low expression of E-cadherin ( $P=0.0180$ ) was correlated with a poor outcome. High expression of vimentin ( $P=0.0193$ ), N-cadherin ( $P=0.0004$ ), S100A4 ( $P=0.0017$ ) and fibronectin ( $P=0.0092$ ) was each correlated with an unfavourable prognosis. However, no significant difference in patient outcome was found with respect to the expression status of the transcription factors, CK19 and  $\alpha$ -SMA (Figure 2). In addition to EMT-related proteins, univariate analysis of overall survival using the log-rank test identified venous invasion ( $P=0.0020$ ), histological classification ( $P=0.0291$ ), T classification ( $P=0.0357$ ), N classification ( $P=0.0010$ ) and residual tumour ( $P=0.0471$ ) as significant prognostic indicators. Moreover, multivariate analysis using the Cox regression model on the same set of patients was performed using the factors shown to be significant by univariate analysis. Those results showed that low expression of E-cadherin (hazard ratio (HR), 2.09;  $P=0.0208$ ), high expression of N-cadherin (HR, 2.53;  $P=0.0038$ ) and high expression of

S100A4 (HR, 2.51;  $P=0.0157$ ) was each an independent unfavourable prognostic factor, in addition to N classification (HR, 1.60;  $P=0.0420$ ; Table 2).

**Relationships between patient survival and expression of E-cadherin and N-cadherin.** We divided the 117 cases of EHCC into the following three subgroups: A, E-cadherin high expression and N-cadherin low expression phenotype (Ecad-H/Ncad-L); B, incomplete phenotype (Ecad-H/Ncad-H or Ecad-L/Ncad-L); and C, E-cadherin low expression and N-cadherin high expression phenotype (Ecad-L/Ncad-H). In this study, we defined subgroup C as the 'cadherin switch' phenotype because this subgroup consistently showed downregulation of E-cadherin and upregulation of N-cadherin (Gravdal *et al*, 2007; Wheelock *et al*, 2008; Jäger *et al*, 2010; Araki *et al*, 2011). We showed the representative double immunohistochemical staining patterns for the cadherin switch in Figure 3A. In the immunohistochemical staining of the cell proliferation marker, Ki67, there was no significant differences of Ki67 labelling index between the cadherin switch-positive and -negative cases both in invasive front ( $P=0.9758$ ) and bulk of tumour ( $P=0.6366$ ; see Supplementary Data 2). In addition, to study whether the tumour reactive stroma was more expressed in specimens showing the cadherin switch, we immunohistochemically examined the expression of  $\alpha$ -SMA and podoplanin, which have been reported to be the CAFs markers (Chuayri *et al*, 2009; Vered *et al*, 2010; Pula *et al*, 2011; Neri *et al*, 2012; Herrera *et al*, 2013; Shindo *et al*, 2013), both in invasive front and bulk of tumour. As a result, no significant correlation was found between

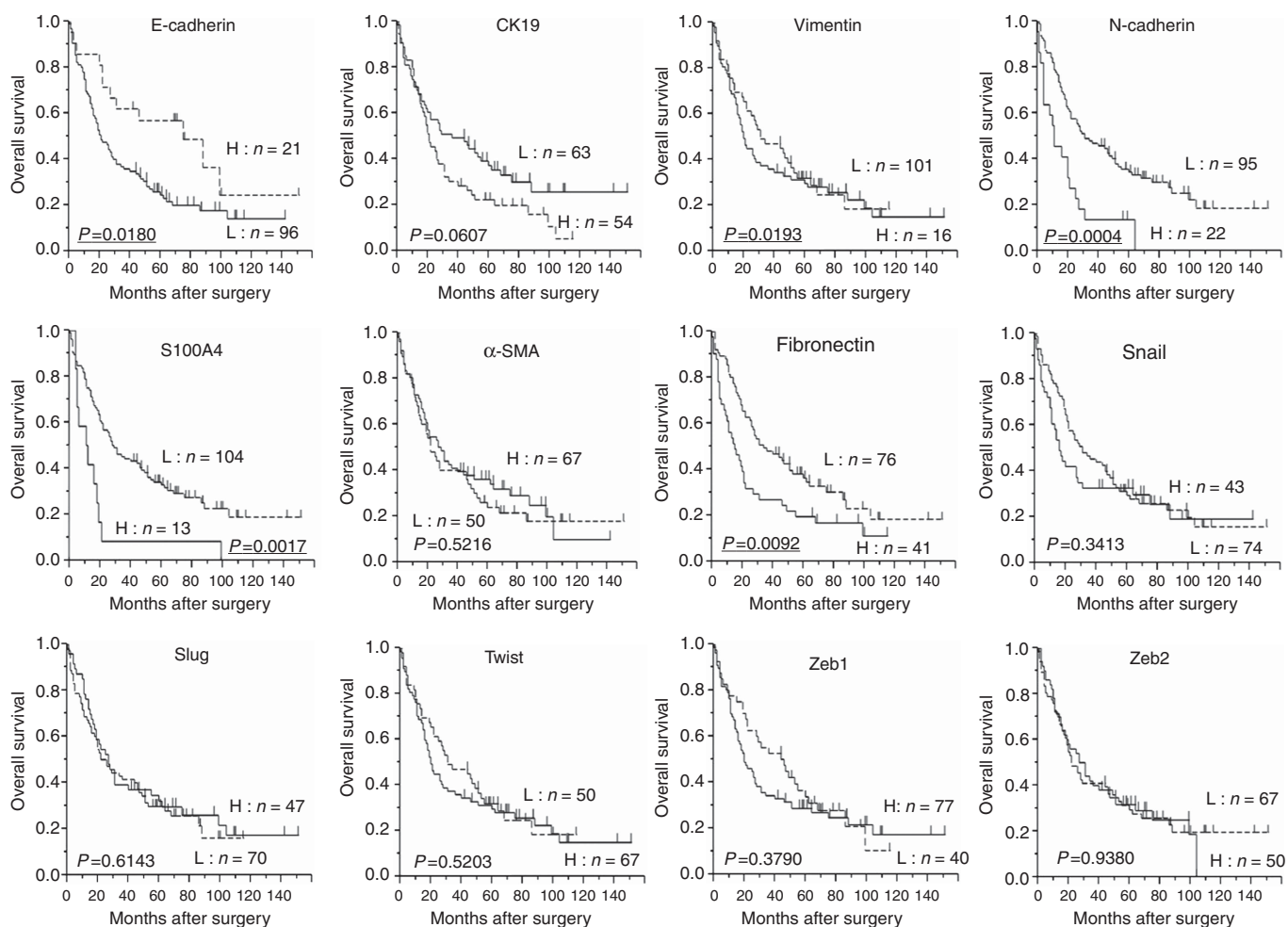


Figure 2. Kaplan-Meier survival curves with the log-rank test for expression of 12 EMT-related proteins. Abbreviations: H = high expression group; L = low expression group.

Table 2. Survival analysis

		Survival (%)		Univariate	Multivariate	
Variable	n	3-Year	5-Year	P-value	Relative risk (95% CI)	P-value
<b>Gender</b>						
Male	92	41.7	32.1	0.4798		
Female	25	36.0	24.0			
<b>Age</b>						
<71	56	40.0	29.1	0.4722		
≥71	61	40.9	33.5			
<b>Tumour size</b>						
<3 cm	89	41.5	31.6	0.2027		
≥3 cm	28	37.2	26.0			
<b>Location</b>						
Distal	43	33.3	30.7	0.4266		
Perihilar	74	44.5	30.0			
<b>Macroscopic type</b>						
Papillary	18	50.0	37.5	0.5582		
Non-papillary	99	38.7	29.0			
<b>Depth of tumour invasion</b>						
Within fm	8	75.0	37.5	0.1633		
Beyond fm	109	37.9	29.9			
<b>Invasion to the hepatic artery</b>						
Negative	112	40.5	30.8	0.9620		
Positive	5	40.0	20.0			
<b>Invasion to the portal vein</b>						
Negative	91	43.3	35.0	0.1554		
Positive	26	30.7	15.3			
<b>Lymphatic vessel invasion</b>						
Negative	40	55.0	39.1	0.1322		
Positive	77	32.9	25.4			
<b>Venous invasion</b>						
Negative	52	57.6	45.4	<b>0.0020</b>	1.00 1.37 (0.85–2.22)	0.2002
Positive	65	26.5	18.2			
<b>Perineural invasion</b>						
Negative	15	46.6	33.3	0.5534		
Positive	102	39.6	29.9			
<b>Superficial spread</b>						
Negative	97	40.6	29.8	0.9510		
Positive	20	40.0	33.3			
<b>Histopathological classification</b>						
Well + Pap	37	59.4	45.1	<b>0.0291</b>	1.00 1.29 (0.75–2.26)	0.3528
Mod + poor + others	80	31.6	23.5			
<b>pT</b>						
1 + 2	62	48.3	39.8	<b>0.0357</b>	1.00 1.22 (0.76–1.96)	0.4162
3 + 4	55	31.5	19.8			
<b>pN</b>						
0	63	52.3	42.4	<b>0.0010</b>	1.00 1.60 (1.02–2.54)	<b>0.0420</b>
1	54	26.4	16.0			

Table 2. (Continued)

Variable	n	Survival (%)		Univariate	Multivariate	
		3-Year	5-Year	P-value	Relative risk (95% CI)	P-value
<b>pStage</b>						
I + II	66	47.6	39.4	0.0607		
III + IV	51	31.3	19.0			
<b>R</b>						
0	95	44.7	33.5	<b>0.0471</b>	1.00 1.27 (0.67–2.29)	0.4475
1	22	22.7	17.1			
<b>E-cadherin</b>						
High expression	21	61.9	56.7	<b>0.0180</b>	1.00 2.09 (1.11–4.27)	<b>0.0208</b>
Low expression	96	35.8	24.4			
<b>Vimentin</b>						
Low expression	101	44.0	32.3	<b>0.0193</b>	1.00 1.21 (0.61–2.25)	0.5662
High expression	16	18.7	18.7			
<b>N-cadherin</b>						
Low expression	95	46.8	34.2	<b>0.0004</b>	1.00 2.53 (1.36–4.54)	<b>0.0038</b>
High expression	22	13.6	13.6			
<b>S100A4</b>						
Low expression	104	44.2	32.8	<b>0.0017</b>	1.00 2.51 (1.20–4.96)	<b>0.0157</b>
High expression	13	8.3	8.3			
<b>Fibronectin</b>						
Low expression	76	48.0	36.2	<b>0.0092</b>	1.00 1.08 (0.64–1.79)	0.9093
High expression	41	26.8	19.5			

Abbreviation: CI = confidence interval. The bold and underlined entities indicate statistical significance ( $P < 0.05$ ).

the presence of  $\alpha$ -SMA/podoplanin-expressing CAFs and the expression of cadherin switch both in invasive front and bulk of tumour (see Supplementary Data 3).

With regard to survival analysis, as shown in Figure 3B, the cadherin switch-positive group (subgroup C) was prognostically more unfavourable than the cadherin switch-negative group (subgroups A and B;  $P < .0001$ ,  $P = 0.0099$ , respectively). We then performed multivariate analysis to confirm the cadherin switch as an independent prognostic factor, and included the same set of significant factors derived from univariate analysis (excluding E-cadherin and N-cadherin). This analysis showed that the cadherin switch was an independent unfavourable prognostic factor (HR, 2.34;  $P = 0.0143$ ), in addition to S100A4 expression (HR, 2.29;  $P = 0.0263$ ) and N classification (HR, 1.65;  $P = 0.0316$ ; Table 3).

## DISCUSSION

Previous reports have analysed the relationship between expression of EMT-related proteins including cadherin switch and prognosis in EHCC (Sato *et al*, 2010; Araki *et al*, 2011; Fabris *et al*, 2011). However, those studies examined only a limited number of EMT-related proteins and small sample cohorts. To our knowledge, this is the first study to have investigated the correlation between the expression of multiple EMT-related proteins including representative transcription factors and clinicopathological outcomes in a large series of patients with EHCC. We confirmed that the results of immunohistochemistry performed on tissue microarrays

paralleled those of the corresponding whole sections, based on the random selection of 10 cases. Among the 10 cases studied in whole sections, the staining localisation in tumour cells of each case was identical with the cores included in TMA, and the staining intensity was similar between invasive front and bulk of the tumours. According to the previous report (Kahlert *et al*, 2011), overexpression of Zeb2, one of the EMT-related transcriptional factors, in the invasive front correlated with patients' prognosis in colorectal cancer. On the other hand, in our pilot study, the expression of any transcriptional factor markers in the invasive front or bulk of tumour was not correlated with EHCC patients' prognosis. Therefore, we evaluated the staining results of TMA core based on the mean value of two tumour cores (both invasive front and bulk of tumour) in each case.

We evaluated the prognostic significance of both E-cadherin and N-cadherin expression in EHCC patients as similar to that in many other carcinomas previously reported (Gravdal *et al*, 2007; Kim *et al*, 2009). In several types of carcinoma, the E- to N-cadherin switch that influences cell phenotype and behaviour as a major aspect of EMT, has found to be associated with patient prognosis (Gravdal *et al*, 2007; Wheelock *et al*, 2008; Jäger *et al*, 2010; Araki *et al*, 2011). In EHCC, Araki *et al* (2011) confirmed that the cadherin switch occurred in CC cells as a result of TGF- $\beta$ -induced EMT *in vitro*, and that this cadherin switch was related to the migratory and invasive properties of CC cells. In an immunohistochemical study of 38 EHCC specimens, they also revealed that the cadherin switch was correlated with patients' survival (Araki *et al*, 2011). In this study, we demonstrated for the first time in the EHCC patients that the cadherin switch was a more significant factor associated with poor prognosis than either



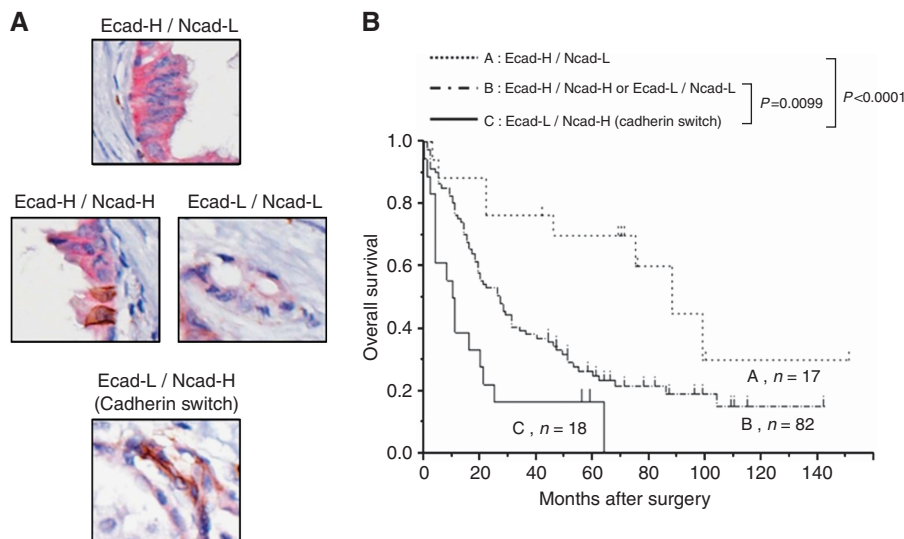


Figure 3. The 117 cases of EHCC are divided into three subgroups: A, E-cadherin high expression and N-cadherin low expression phenotype (Ecad-H/Ncad-L); B, incomplete phenotype (Ecad-H/Ncad-H or Ecad-L/Ncad-L); C, E-cadherin low expression and N-cadherin high expression phenotype (Ecad-L/Ncad-H). The subgroup C is defined as the ‘cadherin switch’. (A) Representative double immunohistochemical staining patterns for the cadherin switch. The expression of E-cadherin; red colour, the expression of N-cadherin; brown colour. (B) Kaplan–Meier survival curves with the log-rank test for combined E-cadherin and N-cadherin expression. The cadherin switch-positive group (subgroup C) was prognostically more unfavourable than the cadherin switch-negative group (subgroups A and B) ( $P < .0001$ ,  $P = 0.0099$ , respectively).

Table 3. Multivariate analysis including the cadherin switch

Characteristics	HR	95% CI of relative risk	P-value
Venous invasion (negative vs positive)	1.54	0.97–2.50	0.0681
Histological classification (well + Pap vs mod + poor + others)	1.14	0.67–1.98	0.6218
T classification (1 + 2 vs T3 + 4)	1.28	0.80–2.03	0.3024
N classification (negative vs positive)	1.65	1.05–2.62	<b>0.0316</b>
Residual tumour (R0 vs R1/R2)	1.21	0.65–2.16	0.5348
Vimentin (low vs high expression)	1.34	0.68–2.47	0.3819
S100A4 (low vs high expression)	2.29	1.11–4.45	<b>0.0263</b>
Fibronectin (low vs high expression)	1.06	0.64–1.74	0.8194
Cadherin switch (negative vs positive)	2.34	1.19–4.35	<b>0.0143</b>

Abbreviations: CI = confidence interval; HR = hazard ratio. The bold and underlined entities indicate statistical significance ( $P < 0.05$ ).

E-cadherin or N-cadherin alone. Multivariate analysis also showed that the cadherin switch was an independent prognostic factor. The reason why the cadherin switch is a more significant factor than altered expression of E-cadherin or N-cadherin alone is not clear. In our study, no significant difference in Ki67 labelling index was found between cadherin switch-positive and -negative groups.

Recently, it has been reported that interaction between cancer cells and surrounding CAFs has a pivotal role in cancer progression (Chuaysri *et al*, 2009; Vered *et al*, 2010; Pula *et al*, 2011; Neri *et al*, 2012; Herrera *et al*, 2013; Shindo *et al*, 2013). One of the most common CAFs’ markers is  $\alpha$ -SMA (Chuaysri *et al*, 2009; Vered *et al*, 2010; Herrera *et al*, 2013). Detection of  $\alpha$ -SMA in tumour stroma has been studied in various carcinomas, and was proposed to have an association with an aggressive phenotype of cancer cells (Chuaysri *et al*, 2009; Vered *et al*, 2010; Herrera *et al*, 2013). Podoplanin, which is a representative lymphatic vessel marker (D2-40), have gained attention as a CAFs’ marker, and the podoplanin-expressing CAFs has been reported to be associated

with malignant potential in several types of cancer (Pula *et al*, 2011; Neri *et al*, 2012; Shindo *et al*, 2013). However, in this study, no significant correlation was found between the presence of  $\alpha$ -SMA/podoplanin-expressing CAFs and the expression of cadherin switch both in invasive front and bulk of tumour. Although, in some reports, the contribution of the CAFs to the cancer progression has been found (Chuaysri *et al*, 2009; Vered *et al*, 2010; Pula *et al*, 2011; Neri *et al*, 2012; Herrera *et al*, 2013; Shindo *et al*, 2013), the exact role of CAFs in cancer is not fully understood and may have functional heterogeneity according to the types of cancer (Shindo *et al*, 2013). The malignant potential of the cadherin switch may be explained by the association between cadherins and the growth factor receptor signalling pathway (Wheelock *et al*, 2008). Growth factor receptors, such as the epidermal growth factor receptor and fibroblast growth factor receptor, regulate many aspects of tumour cell behaviour, including cell motility and invasion (Wheelock *et al*, 2008). It has been suggested that when epithelial tumour cells switch from E- to N-cadherin expression, they also gain the ability to activate growth factor receptor pathways to enhance cell growth and invasion (Wheelock *et al*, 2008). As for cadherin switch, it is also interesting to examine the correlation between the expression of more advanced mesenchymal markers showing complete EMT, such as  $\alpha$ -SMA and fibronectin, and the cadherin switch *in vitro* study. Further insight into this aspect awaits future studies.

S100A4 is a member of the S100 family of  $Ca^{2+}$ -binding proteins and is expressed in both mesenchymal cells and some malignant epithelial tumours (Helfman *et al*, 2005; Schneider *et al*, 2008; Fabris *et al*, 2011). S100A4 is involved in the regulation of a wide range of biological phenomena including cell motility, survival, differentiation, contractility, fibrosis and EMT (Schneider *et al*, 2008; Fabris *et al*, 2011). Moreover, S100A4 has been shown to be a candidate molecular marker of metastatic potential with high prognostic significance in several cancers (Helfman *et al*, 2005; Schneider *et al*, 2008; Fabris *et al*, 2011). Fabris *et al* (2011) reported that the expression of nuclear S100A4 was an independent predictor of survival in CC including both intrahepatic ( $n = 55$ ) and extrahepatic ( $n = 31$ ) types. They also demonstrated that the nuclear expression of S100A4 was associated

with the enhanced metastatic potential of CC cell lines xenotransplanted into SCID mice, and that the silencing of S100A4 was associated with reduced motility, invasiveness and the expression of MMP9 *in vitro* (Fabris *et al*, 2011). In our large-scale study of EHCC, S100A4 was revealed to be an independent prognostic factor, being consistent with the previous study (Fabris *et al*, 2011).

Transcription factors that orchestrate EMT have been correlated with poor prognosis in several types of carcinoma. For example, in the gastrointestinal tract, expression of Snail, Slug, Twist, Zeb1 and Zeb2 has been associated with unfavourable survival outcomes in patients with oesophageal (Uchikado *et al*, 2005), gastric (Kim *et al*, 2009; Ru *et al*, 2011; Dai *et al*, 2012), colorectal (Shioiri *et al*, 2006; Kahlert *et al*, 2011) or pancreatic cancer (Kurahara *et al*, 2012). Sato *et al* (2010) reported that EHCC patients whose tumours showed marked immunohistochemical expression of Snail had a significantly poorer prognosis than those with tumours showing negative or mild-to-moderate expression. Although a large number of studies have suggested that these transcription factors may be useful as prognostic parameters, our present results indicated that none of the transcription factors investigated here were predictive of patient outcome. In addition to the pathways triggered by the transcription factors investigated in this study, many other molecules, such as Kruppel-like factor 8, Gooseoid and FoxC2, have recently been described as EMT inducers (Wang *et al*, 2007; Thiery *et al*, 2009). In EHCC, these other transcription factors may be key transcription factors inducing EMT. Moreover, a discrepancy between our results and those obtained by others may be also explained by the differences of case numbers, patients' characteristics, antibodies used in those studies, periods of follow-up, storage conditions and the methods of fixation for the specimens. In addition, the way of setting the cutoff point for immunohistochemistry may also be a cause of inconsistency.

In conclusion, we have demonstrated that the expression of E-cadherin, N-cadherin and S100A4 may each be a novel prognostic indicator reflecting the aggressiveness of EHCC. Furthermore, the cadherin switch may be a prognostic parameter for EHCC patients, showing a higher discriminative power than expression of E-cadherin or N-cadherin alone. Although the validation of these results with the same cutoffs in an independent patient cohort is necessary, these results may provide useful information for selecting the appropriate adjuvant therapy protocol and strict surveillance for EHCC patients.

## ACKNOWLEDGEMENTS

We appreciate the contributions of Jun Moriya, Tomohiro Shimizu and Sanae Mochizuki for their technical support in the Department of Surgical Pathology.

## CONFLICT OF INTEREST

The authors declare no conflict of interest.

## REFERENCES

- Aishima S, Kubo Y, Tanaka Y, Oda Y (2014) Histological features of precancerous and early cancerous lesions of biliary tract carcinoma. *J Hepatobiliary Pancreat Sci* **21**(7): 448–452.
- Araiki K, Shimura T, Suzuki H, Tsutsumi S, Wada W, Yajima T, Kobayahi T, Kubo N, Kuwano H (2011) E/N-cadherin switch mediates cancer progression via TGF- $\beta$ -induced epithelial-to-mesenchymal transition in extrahepatic cholangiocarcinoma. *Br J Cancer* **105**(12): 1885–1893.
- Chuaysri C, Thuwajit P, Paupairoj A, Chau-In S, Suthiphongchai T, Thuwajit C (2009) Alpha-smooth muscle actin-positive fibroblasts promote biliary cell proliferation and correlate with poor survival in cholangiocarcinoma. *Oncol Rep* **21**(4): 957–969.
- Dai YH, Tang YP, Zhu HY, Lv L, Chu Y, Zhou YQ, Huo JR (2012) ZEB2 promotes the metastasis of gastric cancer and modulates epithelial mesenchymal transition of gastric cancer cells. *Dig Dis Sci* **57**(5): 1253–1260.
- DeOliveira ML, Cunningham SC, Cameron JL, Kamangar F, Winter JM, Lillemoe KD, Choti MA, Yeo CJ, Schulick RD (2007) Cholangiocarcinoma: thirty-one-year experience with 564 patients at a single institution. *Ann Surg* **245**(5): 755–762.
- Devarajan E, Song YH, Krishnappa S, Alt E (2012) Epithelial-mesenchymal transition in breast cancer lines is mediated through PDGF-D released by tissue-resident stem cells. *Int J Cancer* **131**(5): 1023–1031.
- Ebata T, Kamiya J, Nishio H, Nagasaka T, Nimura Y, Nagino M (2009) The concept of perihilar cholangiocarcinoma is valid. *Br J Surg* **96**(8): 926–934.
- Fabris L, Cadamuro M, Moserle L, Dziura J, Cong X, Sambado L, Nardo G, Sonzogni A, Colledan M, Furlanetto A, Bassi N, Massani M, Cillo U, Mescoli C, Indraccolo S, Rugge M, Okolicsanyi L, Strazzabosco M (2011) Nuclear expression of S100A4 calcium-binding protein increases cholangiocarcinoma invasiveness and metastasization. *Hepatology* **54**(3): 890–899.
- Gandou C, Harada K, Sato Y, Igarashi S, Sasaki M, Ikeda H, Nakanuma Y (2013) Hilar cholangiocarcinoma and pancreatic ductal adenocarcinoma share similar histopathologies, immunophenotypes, and development-related molecules. *Hum Pathol* **44**(5): 811–821.
- Gemmill RM, Roche J, Potiron VA, Nasarre P, Mitas M, Coldren CD, Helfrich BA, Garrett-Mayer E, Bunn PA, Drabkin HA (2011) ZEB1-responsive genes in non-small cell lung cancer. *Cancer Lett* **300**(1): 66–78.
- Gravdal K, Halvorsen OJ, Haukaas SA, Akslen LA (2007) A switch from E-cadherin to N-cadherin expression indicates epithelial to mesenchymal transition and is of strong and independent importance for the progress of prostate cancer. *Clin Cancer Res* **13**(23): 7003–7011.
- Helfman DM, Kim EJ, Lukanidin E, Grigorian M (2005) The metastasis associated protein S100A4: role in tumour progression and metastasis. *Br J Cancer* **92**(11): 1955–1958.
- Herrera M, Herrera A, Dominguez G, Silva J, Garcia V, Garcia JM, Gomez I, Soldevilla B, Munoz C, Provencio M, Campos-Martin Y, Garcia de Herreros A, Casal I, Bonilla F, Pena C (2013) Cancer-associated fibroblast and M2 macrophage markers together predict outcome in colorectal cancer patients. *Cancer Sci* **104**(4): 437–444.
- Hotz B, Arndt M, Dullat S, Bhargava S, Bühr HJ, Hotz HG (2007) Epithelial to mesenchymal transition: expression of the regulators snail, slug, and twist in pancreatic cancer. *Clin Cancer Res* **13**(16): 4769–4776.
- Jarnagin WR, Bowne W, Klimstra DS, Ben-Porat L, Roggin K, Cymes K, Fong Y, DeMatteo RP, D'Angelica M, Koea J, Blumgart LH (2005) Papillary phenotype confers improved survival after resection of hilar cholangiocarcinoma. *Ann Surg* **241**(5): 703–712; discussion 712–714.
- Jäger T, Becker M, Eisenhardt A, Tilki D, Tötsch M, Schmid KW, Romics I, Rübben H, Ergün S, Szarvas T (2010) The prognostic value of cadherin switch in bladder cancer. *Oncol Rep* **23**(4): 1125–1132.
- Kahlert C, Lahes S, Radhakrishnan P, Dutta S, Mogler C, Herpel E, Brand K, Steinert G, Schneider M, Mollenhauer M, Reissfelder C, Klupp F, Fritzmann J, Wunder C, Benner A, Kloor M, Huth C, Contin P, Ulrich A, Koch M, Weitz J (2011) Overexpression of ZEB2 at the invasion front of colorectal cancer is an independent prognostic marker and regulates tumor invasion *in vitro*. *Clin Cancer Res* **17**(24): 7654–7663.
- Kim MA, Lee HS, Lee HE, Kim JH, Yang HK, Kim WH (2009) Prognostic importance of epithelial-mesenchymal transition-related protein expression in gastric carcinoma. *Histopathology* **54**(4): 442–451.
- Kurahara H, Takao S, Maemura K, Mataka Y, Kuwahata T, Maeda K, Ding Q, Sakoda M, Iino S, Ishigami S, Ueno S, Shinchi H, Natsugoe S (2012) Epithelial-mesenchymal transition and mesenchymal-epithelial transition via regulation of ZEB-1 and ZEB-2 expression in pancreatic cancer. *J Surg Oncol* **105**(7): 655–661.
- Lindley LE, Briegel KJ (2010) Molecular characterization of TGF beta-induced epithelial-mesenchymal transition in normal finite lifespan human mammary epithelial cells. *Biochem Biophys Res Commun* **399**(4): 659–664.
- Nakanishi Y, Zen Y, Kawakami H, Kubota K, Itoh T, Hirano S, Tanaka E, Nakanuma Y, Kondo S (2008) Extrahepatic bile duct carcinoma with extensive intraepithelial spread: a clinicopathological study of 21 cases. *Mod Pathol* **21**(7): 807–816.
- Neri S, Ishii G, Taira T, Hishida T, Yoshida J, Nishimura M, Nagai K, Ochiai A (2012) Recruitment of podoplanin positive cancer-associated fibroblasts in metastatic lymph nodes predicts poor prognosis in pathological N2 stage III lung adenocarcinoma. *Ann Surg Oncol* **19**(12): 3953–3962.

- Pula B, Jethon A, Piotrowska A, Gomulkiewicz A, Owczarek T, Calik J, Wojnar A, Witkiewicz W, Rys J, Ugorski M, Dziegiel P, Podhorska-Okolow M (2011) Podoplanin expression by cancer-associated fibroblasts predicts poor outcome in invasive ductal breast carcinoma. *Histopathology* **59**(6): 1249–1260.
- Ru GQ, Wang HJ, Xu WJ, Zhao ZS (2011) Upregulation of Twist in gastric carcinoma associated with tumor invasion and poor prognosis. *Pathol Oncol Res* **17**(2): 341–347.
- Ryu HS, Park DJ, Kim HH, Kim WH, Lee HS (2012) Combination of epithelial-mesenchymal transition and cancer stem cell-like phenotypes has independent prognostic value in gastric cancer. *Hum Pathol* **43**(4): 520–528.
- Sato Y, Harada K, Itatsu K, Ikeda H, Kakuda Y, Shimomura S, Shan Ren X, Yoneda N, Sasaki M, Nakanuma Y (2010) Epithelial-mesenchymal transition induced by transforming growth factor- $\beta$ 1/Snail activation aggravates invasive growth of cholangiocarcinoma. *Am J Pathol* **177**(1): 141–152.
- Schneider M, Hansen JL, Sheikh SP (2008) S100A4: a common mediator of epithelial-mesenchymal transition, fibrosis and regeneration in diseases? *J Mol Med (Berl)* **86**(5): 507–522.
- Shioiri M, Shida T, Koda K, Oda K, Seike K, Nishimura M, Takano S, Miyazaki M (2006) Slug expression is an independent prognostic parameter for poor survival in colorectal carcinoma patients. *Br J Cancer* **94**(12): 1816–1822.
- Shindo K, Aishima S, Ohuchida K, Fujiwara K, Fujino M, Mizuuchi Y, Hattori M, Mizumoto K, Tanaka M, Oda Y (2013) Podoplanin expression in cancer-associated fibroblasts enhances tumor progression of invasive ductal carcinoma of the pancreas. *Mol Cancer* **12**(1): 168–184.
- Sobin LH, Gospodarowicz MK, Wittekind Ch eds (2009) *TNM Classification of Malignant Tumours*. 7th edn. Wiley-Blackwell: Oxford, pp 122–128.
- Sung CO, Park CK, Kim SH (2011) Classification of epithelial-mesenchymal transition phenotypes in esophageal squamous cell carcinoma is strongly associated with patient prognosis. *Mod Pathol* **24**(8): 1060–1068.
- Taube JH, Herschkowitz JI, Komurov K, Zhou AY, Gupta S, Yang J, Hartwell K, Onder TT, Gupta PB, Evans KW, Hollier BG, Ram PT, Lander ES, Rosen JM, Weinberg RA, Mani SA (2010) Core epithelial-to-mesenchymal transition interactome gene-expression signature is associated with claudin-low and metaplastic breast cancer subtypes. *Proc Natl Acad Sci USA* **107**(35): 15449–15454.
- Thiery JP, Acloque H, Huang RY, Nieto MA (2009) Epithelial-mesenchymal transitions in development and disease. *Cell* **139**(5): 871–890.
- Tripathi SC, Kaur J, Matta A, Gao X, Sun B, Chauhan SS, Thakar A, Shukla NK, Duggal R, Choudhary AR, DattaGupta S, Sharma MC, Ralhan R, Siu KW (2012) Loss of DLC1 is an independent prognostic factor in patients with oral squamous cell carcinoma. *Mod Pathol* **25**(1): 14–25.
- Uchikado Y, Natsugoe S, Okumura H, Setoyama T, Matsumoto M, Ishigami S, Aikou T (2005) Slug Expression in the E-cadherin preserved tumors is related to prognosis in patients with esophageal squamous cell carcinoma. *Clin Cancer Res* **11**(3): 1174–1180.
- Usami Y, Satake S, Nakayama F, Matsumoto M, Ohnuma K, Komori T, Semba S, Ito A, Yokozaki H (2008) Snail-associated epithelial-mesenchymal transition promotes oesophageal squamous cell carcinoma motility and progression. *J Pathol* **215**(3): 330–339.
- Van der Gaag NA, Kloek JJ, de Bakker JK, Musters B, Geskus RB, Busch OR, Bosma A, Gouma DJ, van Gulik TM (2012) Survival analysis and prognostic nomogram for patients undergoing resection of extrahepatic cholangiocarcinoma. *Ann Oncol* **23**(10): 2642–2649.
- Vered M, Dayan D, Yahalom R, Dobriyan A, Barshack I, Bello IO, Kantola S, Salo T (2010) Cancer-associated fibroblasts and epithelial-mesenchymal transition in metastatic oral tongue squamous cell carcinoma. *Int J Cancer* **127**(6): 1356–1362.
- Wang X, Zheng M, Liu G, Xia W, McKeown-Longo PJ, Hung MC, Zhao J (2007) Krüppel-like factor 8 induces epithelial to mesenchymal transition and epithelial cell invasion. *Cancer Res* **67**(15): 7184–7193.
- Wheelock MJ, Shintani Y, Maeda M, Fukumoto Y, Johnson KR (2008) Cadherin switching. *J Cell Sci* **121**(Pt 6): 727–735.

This work is published under the standard license to publish agreement. After 12 months the work will become freely available and the license terms will switch to a Creative Commons Attribution-NonCommercial-Share Alike 3.0 Unported License.

Supplementary Information accompanies this paper on British Journal of Cancer website (<http://www.nature.com/bjc>)