



Title	Utility of Early Post-treatment Single-Photon Emission Computed Tomography Imaging to Predict Outcome in Stroke Patients Treated with Intravenous Tissue Plasminogen Activator
Author(s)	Abumiya, Takeo; Katoh, Masahito; Moriwaki, Takuya; Yoshino, Masami; Aoki, Takeshi; Imamura, Hiroyuki; Aida, Toshimitsu; Scichinohe, Hideo; Nakayama, Naoki; Kazumata, Ken; Houkin, Kiyohiro
Citation	Journal of Stroke & Cerebrovascular Diseases, 23(5), 896-901 https://doi.org/10.1016/j.jstrokecerebrovasdis.2013.07.028
Issue Date	2014-05
Doc URL	http://hdl.handle.net/2115/56601
Type	article (author version)
File Information	J Stroke Cerebrovasc Dis_23(5)_896-901.pdf



[Instructions for use](#)

Utility of early post-treatment SPECT imaging to predict outcome in stroke patients treated with intravenous tissue plasminogen activator

Takeo Abumiya, MD, PhD, ^{**†} Masahito Katoh, MD, PhD, ^{*} Takuya Moriwaki, MD, PhD, ^{*} Masami Yoshino, MD, ^{*} Takeshi Aoki, MD, ^{*} Hiroyuki Imamura, MD, PhD, ^{*} Toshimitsu Aida, MD, PhD, ^{*} Hideo Sichinohe, MD, PhD, [†] Naoki Nakayama, MD, PhD, [†] Ken Kazumata, MD, PhD, [†] Kiyohiro Houkin, MD, PhD[†]

^{*}Hokkaido Neurosurgical Memorial Hospital, [†]Department of Neurosurgery, Hokkaido University Graduate School of Medicine, Sapporo, Japan

Address correspondence to Takeo Abumiya, MD, PhD

Hokkaido Neurosurgical Memorial Hospital,

Hachiken-9, Higashi-5, Nishi, Sapporo 063-0869, Japan.

Tel.: +81-11-717-2131

Fax: +81-11-717-2688

E-mail: abumiya@hnsmdp.or.jp

Short title: Utility of early post-treatment SPECT in tPA therapy

Key words: acute ischemic stroke, tPA, SPECT

Summary

It is important to predict the outcome of tPA-treated patients early after the treatment for considering the post-tPA treatment option. We assessed cerebral blood flow (CBF) of tPA-treated patients with single photon emission computed tomography (SPECT) one hour after tPA infusion to predict the patient outcome. Technetium-99m-hexamethylpropyleneamine oxime SPECT was performed in 35 consecutive tPA-treated patients. Asymmetry index, a contralateral-to-ipsilateral ratio of CBF, was calculated to analyze CBF quantitatively. Hypoperfusion or hyperperfusion was defined as a decrease of $\geq 25\%$ or an increase of $\geq 25\%$ in asymmetry index, respectively. Of all 35 patients, 23 had only hypoperfusion, 8 had both hypoperfusion and hyperperfusion, 2 had only hyperperfusion, and 2 had no perfusion abnormality. When evaluating the association between hypoperfusion and outcome, hypoperfusion volumes were significantly correlated with mRS at 3 months ($r = 0.634$, $p < 0.001$). Hyperperfusion was observed in 10 patients (28.6%) and they showed a marked NIHSS score improvement in the first 24-hour period, which were significantly greater than those of 25 patients without hyperperfusion ($p = 0.033$). Eight patients (22.9%) with intracerebral hemorrhage (ICH) were all asymptomatic. Most ICHs were located in hypoperfusion areas and no ICH was related to hyperperfusion. The results of the present study demonstrated that hypoperfusion volume was associated with poor outcome, while the presence of hyperperfusion seemed to be predictive of symptom improvement, but not of development of ICH. Taken together, early post-treatment SPECT imaging seems to be a useful biomarker of outcome in tPA-treated patients. (241 words)

Intravenous tissue plasminogen activator (tPA) therapy has been established as a standard first-line treatment for acute ischemic stroke. The accumulation of cases with intravenous tPA therapy has shown the benefits and limitations of this therapy. Postmarketing studies showed that the percentage of good outcomes (modified Rankin scale [mRS], 0-1) varied from 32 to 39 % while those of poor outcomes (mRS, 4-6) varied from 20 to 47%;¹ The percentage of poor outcomes is not low and still needs to be reduced. Therefore, it is important to predict the outcome of tPA-treated patients early after the treatment for considering the post-tPA treatment option.

Since brain ischemic damage is associated with the severity and duration of ischemia, therapeutic outcome of intravenous tPA therapy depends on the degree and timing of revascularization, divided into recanalization and reperfusion, in ischemic brain tissue. Recanalization after tPA therapy was noted in around 50% of patients with middle cerebral artery occlusion (MCAO) at 6 hours after stroke onset.^{2,3} Although recanalization of the occluded artery is critical in acute ischemic stroke, recanalization does not always mean appropriate reperfusion or restoration of blood flow in the vascular bed.⁴ No-reflow phenomenon has been well documented in animal transient ischemic models.⁵⁻⁷ Meanwhile, hyperperfusion demonstrated in the clinical radiological examination is known as another abnormal reperfusion pattern after recanalization;⁸ however, it is uncertain to what extent and how often reperfusion abnormality happens in the clinical course of tPA-treated patients; therefore, it is important to evaluate cerebral perfusion after intravenous tPA therapy to predict the therapeutic outcome. Another concern after intravenous tPA therapy is the risk of

developing hemorrhagic transformation, which is the main issue in therapeutic safety. Symptomatic intracerebral hemorrhage (ICH) is the most difficult complication to deal with during thrombolytic and antithrombotic therapy and is associated with a poor outcome; therefore, it is important to predict the development of ICH on tPA therapy.

Based on this background, we attempted to measure the cerebral blood flow (CBF) of tPA-treated patients to predict outcome in the early post-treatment period by using single photon emission computed tomography (SPECT) with technetium-99m-hexamethylpropyleneamine oxime (^{99m}Tc HMPAO). We analyzed the association of cerebral perfusion and the therapeutic outcome including the development of hemorrhagic transformation after intravenous tPA therapy.

Methods

Subjects

This is a retrospective analysis of prospectively collected data in 35 consecutive tPA-treated patients due to ischemic stroke in the anterior circulation. A total dose of 0.6 mg/kg tPA with 10% of the dose given as a bolus was administered for 60 minutes within 3 hours of the initial symptoms following the directions for use of tPA in Japan. The severity of the patients' neurological deficits was assessed before and after t-PA therapy with National Institutes of Health Stroke Scale (NIHSS; scored from 0 to 31). Clinical outcome was measured at 3 months with mRS.

MRI and CT scans

An emergent MRI scan was performed with 1.5T MRI systems before tPA therapy in all stroke patients without contraindications to MRI. The emergency MRI protocol consisted of diffusion-weighted imaging (DWI), fluid attenuation inversion recovery (FLAIR) image, T2-weighted imaging, and MR angiography. Follow-up MRI scans were performed at day2 and day7. When hemorrhagic transformation was suspected by MRI scans, a CT scan was added to confirm the hemorrhagic findings.

SPECT imaging

^{99m}Tc-HMPAO SPECT was performed one hour after tPA therapy using a double-head rotating γ -camera (ECAM, Toshiba) equipped with a fan beam collimator. After intravenous injection of 740MBq of ^{99m}Tc-HMPAO, dynamic planar images were obtained immediately for 2 minutes, and then the collection of SPECT data was started at 5 minute after the injection with the following parameters: 64 x 64 matrix, 180 degree rotation, and 45 views per detector and 4 times of acquisition repeated (total imaging time, 20 minutes). Patlak plot method developed by Matsuda et al. was employed to convert from SPECT images to CBF images.⁹ This method depends on graphic analysis to evaluate the unidirectional influx constant of the tracer from the blood to the brain.⁹ The acquired individual CBF data were anatomically normalized to the standard brain by NEUROSAT developed by Minoshima et al.¹⁰ This method involves linear scaling to correct an individual brain size and nonlinear warping to minimize regional anatomic variation among subjects, resulting in facilitating pixel-by-pixel comparisons of CBF images.¹⁰ To perform semi-quantitative analysis of CBF,

asymmetry index, a contralateral-to-ipsilateral ratio of CBF, of each symmetrical pixel was obtained with the following equation: $[1-(\text{CBF}_{\text{ipsi}}/\text{CBF}_{\text{contra}})] \times 100 \%$. Hypoperfusion was defined as a CBF decrease of $\geq 25\%$ compared with the contralateral CBF using the asymmetry index. The reason why the 25% threshold was chosen for the definition of hypoperfusion was that the 25% threshold provided a more similarity between hypoperfusion areas in asymmetry index image and DWI lesion areas compared with 20% or 30% threshold (Fig.1). Meanwhile hyperperfusion was defined as a CBF increase of $\geq 25\%$ compared with the contralateral CBF to match the threshold magnitude of hypoperfusion. To quantitatively analyze the hypoperfusion volume, it was quantified as the percentage of the ipsilateral hemispheric volume. We assessed the association of cerebral perfusion and the patient outcome including the development of hemorrhagic transformation after intravenous tPA therapy.

Statistical analysis

Statistical analysis was performed using Ekuseru-Toukei 2008. Data are given as the mean \pm standard deviation. The Mann-Whitney U test was used to compare unpaired data. A level of $p < 0.05$ was accepted as significant.

Results

We evaluated CBF of 35 tPA-treated patients (21 male, mean age 73.3 ± 12.1 years) with $^{99\text{m}}\text{Tc}$ -HMPAO SPECT one hour after intravenous tPA therapy. The subtypes of ischemic stroke included 25 cardioembolism, 7 large artery atherosclerosis, and 3 small artery occlusion. The sites of

arterial occlusion confirmed by MRA included 3 internal carotid artery, 15 M1 segment, 11 M2-M3 segment, 5 non-detectable, and 1 non-examined. The time from symptom onset to the start of tPA infusion was 131 ± 27 minutes. Baseline NIHSS was 13.1 ± 6.9 and NIHSS at the end of tPA infusion was 9.8 ± 7.3 , implying that intravenous tPA therapy contributed to improving ≥ 3 points on NIHSS.

Of 35 patients, 23 had only hypoperfusion, 8 had both hypoperfusion and hyperperfusion, 2 had only hyperperfusion, and 2 had no hypo- or hyperperfusion in the early post-treatment SPECT imaging. When evaluating the association between hypoperfusion and symptom/outcome, hypoperfusion volumes were significantly correlated with NIHSS 24 hours after tPA infusion ($r = 0.555$, $p < 0.001$) and mRS at 3 months ($r = 0.634$, $p < 0.001$) (Figure 2). Some patients were not applicable to this correlation due to the dissociation of outcome from the hypoperfusion state. They showed a worse outcome with less hypoperfusion due to non-stroke-related disabilities, such as advanced age over 85 and preceding dementia, or severe hemiparesis due to a small infarct on the pyramidal tract. Hyperperfusion was observed in 10 patients (28.6%). Follow-up MRI revealed that 3 of them showed a delayed signal increase in the hyperperfusion region at day 7. It is noteworthy that the temporal pattern of signal change in MRI was distinctly different from that in usual infarction, especially on day 2 (Figure 3). The 10 patients with hyperperfusion (baseline NIHSS: 14.2 ± 7.7) showed a marked NIHSS score improvement (Δ NIHSS) in the first 24-hour period, which were significantly greater than the improvements of the remaining 25 patients without

hyperperfusion (baseline NIHSS: 12.6 ± 6.7) (Δ NIHSS of the patients with hyperperfusion; 7.0 ± 4.7 , Δ NIHSS of the patients without hyperperfusion; 3.5 ± 5.0 , $p=0.033$) (Figure 4).

ICH was observed in 8 patients (22.9%) and all cases were asymptomatic. Their baseline NIHSS of 13.8 ± 6.1 was almost the same as that of all patients. Seven of the eight ICHs were located in hypoperfusion areas (Figure 5). A case with simultaneous hyperperfusion and hypoperfusion developed subsequent ICH in the hypoperfusion area (case 3 in Figure 5). No hemorrhage was observed in the hyperperfusion area in the present study.

Discussion

We demonstrated the association of the early post-treatment SPECT findings with the patient outcome in intravenous tPA therapy. Hypoperfusion volume was associated with mRS at 3 months after intravenous tPA therapy. This means that early post-treatment SPECT is a useful biomarker of outcome in tPA-treated patients. Meanwhile, the presence of hyperperfusion was likely related to symptom improvement, although the region of hyperperfusion in some cases showed a delayed signal increase in follow-up MRI. No hyperperfusion was related to ICH and most ICH occurred in the hypoperfusion area under the conditions of SPECT imaging used in the present study.

There are few studies assessing cerebral perfusion before tPA therapy because of the priority to reduce door-to-needle time for tPA. Seitz et al. demonstrated that DWI lesion volumes and perfusion weighted image (PWI) lesion volumes obtained by MRI modalities on admission were significantly correlated with the final lesion volumes in 37 patients treated with intravenous tPA thrombolysis.¹¹

Their multiple regression analysis revealed that the initial PWI lesion volumes did not predict well the final lesion volumes and neurological deficit, compared with the initial DWI lesion volume.¹¹

Although Seitz's data showed that perfusion image was not a strong biomarker of outcome in tPA-treated patients, we think that the results would be different if perfusion image was obtained by SPECT early after tPA therapy, as performed in the present study. Since perfusion status can be changed after thrombolysis, it is highly likely that perfusion evaluation after treatment provides more reliable estimation of lesion extent than that before treatment. In addition, it should be noted that MR PWI tends to overestimate the core of irreversible infarction as well as the penumbra when compared to PET or SPECT.¹²

It has been demonstrated that postischemic hyperperfusion has harmful effects on brain tissue in animal experimental models.⁸ However, postischemic hyperperfusion in clinical settings is likely to have a different aspect. In a clinical study of intra-arterial thrombolysis by Kidwell et al., although hyperperfusion occurred in about 40-50% of their treated patients and the region of persistent hyperperfusion overlapped with DWI hyperintensity lesion at day 7, the presence of hyperperfusion had no harmful effects on the degree of clinical improvement.¹³ Kidwell's study and our study suggest that hyperperfusion can commonly occur in thrombolytic therapy, which is sometimes related to DWI hyperintensity lesion, but the net effects of reperfusion seem to be beneficial or at least harmless under certain conditions of reperfusion.¹³

A systematic review to compare the incidence of symptomatic ICH after tPA therapy in 24 clinical studies demonstrated that the overall mean symptomatic ICH and mortality rates were 5.6% and 14.7 %, respectively.¹⁴ Many clinical studies on intravenous tPA therapy attempted to identify predictors of ICH with multivariate analysis. They identified serum glucose level,¹⁵ systolic blood pressure,¹⁶ hyperdense artery sign on CT,¹⁶ apparent diffusion coefficient (ADC),¹⁷ DWI lesion volume,^{18,19} and persistent arterial occlusion on transcranial Doppler²⁰ as independent predictors of ICH. Meanwhile, a couple of studies on cerebral blood volume (CBV) maps using bolus contrast MRI demonstrated that regional very low CBV predicted hemorrhage better than did DWI lesion volume or threshold ADC lesion volume.^{21,22} In our previous report, we showed that symptomatic ICH developed in a tPA-treated patient without large DWI lesion volume and with early symptomatic improvement.²³ ^{99m}Tc-ethylcysteinate dimer (ECD) SPECT imaging of the patient early after tPA therapy demonstrated that small but severe hypoperfusion area was co-localized with the center of hemorrhage.²³ In the present study, hemorrhage often developed in the region without large DWI lesion and with persistent hypoperfusion as shown in Case 2 and 3 in Figure 5. Therefore, we also think that perfusion status may be more important for predicting hemorrhage than DWI lesion volume.

A couple of studies on intraarterial thrombolytic therapy have demonstrated that pre- or post-treatment SPECT could be used to predict the risk of ICH.^{24,25} A study with post-treatment SPECT demonstrated that the colocalization of hyperactivity on ^{99m}Tc-HMPAO and hypoactivity on

^{99m}Tc -ECD was a predictive sign of the development of ICH.²⁵ In the present study, however, ICHs were developed in hypoperfusion (but not hyperperfusion) areas demonstrated with ^{99m}Tc -HMPAO SPECT as shown in Case 3 of Figure 5. We think that this discrepancy of ^{99m}Tc -HMPAO reactivity in the development of ICH may depend on the timing of the recanalization of occluded arteries.

In addition to being retrospective with a small sample size, there are other limitations of the present study. First, we could not perform pre-treatment SPECT imaging due to the need for urgent tPA administration. In this situation, the efficacy of intravenous tPA therapy cannot be assessed precisely in terms of perfusion parameters. Second, we could not know the exact relationship between reperfusion and recanalization at the same time, since the first post-treatment MRI/MRA was performed the day after intravenous tPA therapy in the present study. This makes it difficult to elucidate whether there was a no-reflow phenomenon. Finally, so far, the asymmetry index cannot be used to make decisions regarding acute ischemic stroke therapy in real-time clinical practice. Making images of the asymmetry index has been a time-consuming process; therefore, we have to wait until the software to produce the asymmetry index quickly and automatically becomes available.

Recently, endovascular approach is thought to be the next step when intravenous tPA therapy fails to achieve early reperfusion. It has been demonstrated that intraarterial thrombolysis or thrombectomy after failed intravenous tPA therapy is safe and feasible enough to achieve recanalization and a favorable outcome.^{26,27} In this situation, it is important to note the perfusion state before intraarterial thrombolysis or thrombectomy to predict severe reperfusion injury and ICH;

therefore, we believe and advocate that early and reliable post-treatment CBF measurements in intravenous tPA therapy should be applied in clinical practice for ischemic stroke.

Figure Legends

Figure 1

SPECT image and asymmetry index image. Asymmetry index (AI) image with the 25% threshold shows a more similarity between the hypoperfusion area and the DWI lesion area compared with other asymmetry index images with 20% or 30% threshold.

Figure 2

Association between hypoperfusion and symptom/outcome. Hypoperfusion volume was significantly correlated with NIHSS at the end of tPA infusion ($r = 0.549$, $p < 0.001$)(A) and with mRS at 3 months ($r = 0.634$, $p < 0.001$)(B).

Figure 3

Hyperperfusion region demonstrated by early post-treatment SPECT and subsequent MRI. Blue arrows indicate usual infarction showing MRI high signal changes constantly in the acute phase and red arrows indicate hyperperfusion region showing a delayed signal increase at day 7, respectively.

Figure 4

Comparison of improvement of NIHSS between patients with hyperperfusion ($n=10$) and those without hypoperfusion ($n=25$). A significantly difference was observed between the two groups ($p = 0.033$).

Figure 5

Relationship between ICH and CBF patterns in SPECT in 3 cases. ICH is located within the hypoperfusion area. ICH is co-localized with hypoperfusion (blue arrows) but not with hyperperfusion (red arrows) in case 3.

References

- 1, Nakagawara J, Minematsu K, Okada Y, et al. Thrombolysis with 0.6 mg/kg intravenous alteplase for acute ischemic stroke in routine clinical practice: the Japan post-Marketing Alteplase Registration Study (J-MARS). *Stroke*. 2010; 41: 1984-1989.
- 2, Mori E, Minematsu K, Nakagawara J, et al. Effects of 0.6 mg/kg intravenous alteplase on vascular and clinical outcomes in middle cerebral artery occlusion: Japan Alteplase Clinical Trial II (J-ACT II). *Stroke*. 2010; 41: 461-465.
- 3, Molina CA, Alexandrov AV, Demchuk AM, et al. Improving the predictive accuracy of recanalization on stroke outcome in patients treated with tissue plasminogen activator. *Stroke*. 2004; 35: 151-156.
- 4, Soares BP, Chien JD, Wintermark M: MR and CT monitoring of recanalization, reperfusion, and penumbra salvage: everything that recanalizes does not necessarily reperfuse! *Stroke*. 2009; 40: S24-27.
- 5, del Zoppo GJ, Mabuchi T: Cerebral microvessel responses to focal ischemia. *J Cereb Blood Flow Metab*. 2003; 23: 879-894.
- 6, Wong CH, Crack PJ: Modulation of neuro-inflammation and vascular response by oxidative stress following cerebral ischemia-reperfusion injury. *Curr Med Chem*. 2008; 15: 1-14.

- 7, Pan J, Konstas AA, Bateman B, Ortolano GA, et al. Reperfusion injury following cerebral ischemia: pathophysiology, MR imaging, and potential therapies. *Neuroradiology*. 2007; 49: 93-102.
- 8, Marchal G, Young AR, Baron JC. Early postischemic hyperperfusion: pathophysiologic insights from positron emission tomography. *J Cereb Blood Flow Metab*. 1999; 19: 467-482.
- 9, Matsuda H, Tsuji S, Shuke N, et al. A quantitative approach to technetium-99m hexamethylpropylene amine oxime. *Eur J Nucl Med*. 1992;19:195-200.
- 10, Minoshima S, Koeppe RA, Frey KA, et al. Anatomic standardization: linear scaling and nonlinear warping of functional brain images. *J Nucl Med*. 1994;35:1528-1537.
- 11, Seitz RJ, Oberstrass H, Ringelstein A, et al. Failed recovery from thrombolysis is predicted by the initial diffusion weighted imaging lesion. *Cerebrovasc Dis*. 2011;31:580-587.
- 12, Heiss WD. The ischemic penumbra: correlates in imaging and implications for treatment of ischemic stroke. The Johann Jacob Wepfer award 2011. *Cerebrovasc Dis*. 2011;32:307-320.
- 13, Kidwell CS, Saver JL, Mattiello J, et al. Diffusion-perfusion MRI characterization of post-recanalization hyperperfusion in humans. *Neurology*. 2001; 57: 2015-2021.
- 14, Seet RC, Rabinstein AA. Symptomatic Intracranial Hemorrhage following Intravenous Thrombolysis for Acute Ischemic Stroke: A Critical Review of Case Definitions. *Cerebrovasc Dis*. 2012;34:106-14.

15, Demchuk AM, Morgenstern LB, Krieger DW, et al. Serum glucose level and diabetes predict tissue plasminogen activator-related intracerebral hemorrhage in acute ischemic stroke. *Stroke*. 1999; 30: 34-39.

16, Derex L, Hermier M, Adeleine P, et al. Clinical and imaging predictors of intracerebral haemorrhage in stroke patients treated with intravenous tissue plasminogen activator. *J Neurol Neurosurg Psychiatry*. 2005; 76:70-75.

17, Selim M, Fink JN, Kumar S, et al. Predictors of hemorrhagic transformation after intravenous recombinant tissue plasminogen activator: prognostic value of the initial apparent diffusion coefficient and diffusion-weighted lesion volume. *Stroke*. 2002; 33: 2047-2052.

18, Lansberg MG, Thijs VN, Bammer R, et al. Risk factors of symptomatic intracerebral hemorrhage after tPA therapy for acute stroke. *Stroke*. 2007; 38: 2275-2278.

19, Singer OC, Humpich MC, Fiehler J, et al. MR Stroke Study Group Investigators: Risk for symptomatic intracerebral hemorrhage after thrombolysis assessed by diffusion-weighted magnetic resonance imaging. *Ann Neurol*. 2008; 63: 52-60.

20, Saqqur M, Tsivgoulis G, Molina CA, et al. Symptomatic intracerebral hemorrhage and recanalization after IV rt-PA: a multicenter study. *Neurology*. 2008; 71: 1304-1312.

21, Alsop DC, Makovetskaya E, Kumar S, et al. Markedly reduced apparent blood volume on bolus contrast magnetic resonance imaging as a predictor of hemorrhage after thrombolytic therapy for acute ischemic stroke. *Stroke*. 2005; 36: 746-750.

22, Campbell BC, Christensen S, Butcher KS, et al. Regional very low cerebral blood volume predicts hemorrhagic transformation better than diffusion-weighted imaging volume and thresholded apparent diffusion coefficient in acute ischemic stroke. *Stroke*. 2010; 41: 82-88.

23, Abumiya T, Katoh M, Moriwaki T, et al. Small but severe residual hypoperfusion relates to symptomatic hemorrhage even after early perfusion improvement in tissue plasminogen activator therapy. *Cerebrovasc Dis*. 2012;34:446-447

24, Ueda T, Sakaki S, Yuh WT, et al. Outcome in acute stroke with successful intra-arterial thrombolysis and predictive value of initial single-photon emission-computed tomography. *J Cereb Blood Flow Metab*. 1999; 19: 99-108.

25, Ogasawara K, Ogawa A, Ezura M, et al. Brain single-photon emission CT studies using ^{99m}Tc-HMPAO and ^{99m}Tc-ECD early after recanalization by local intraarterial thrombolysis in patients with acute embolic middle cerebral artery occlusion. *AJNR Am J Neuroradiol*. 2001; 22: 48-53.

26, Lee KY, Kim DI, Kim SH, et al. Sequential combination of intravenous recombinant tissue plasminogen activator and intra-arterial urokinase in acute ischemic stroke. *AJNR Am J Neuroradiol.* 2004; 25: 1470-1475.

27, Shi ZS, Loh Y, Walker G, et al. Endovascular thrombectomy for acute ischemic stroke in failed intravenous tissue plasminogen activator versus non-intravenous tissue plasminogen activator patients: revascularization and outcomes stratified by the site of arterial occlusions. *Stroke.* 2010; 41: 1185-1192.

Figure 1

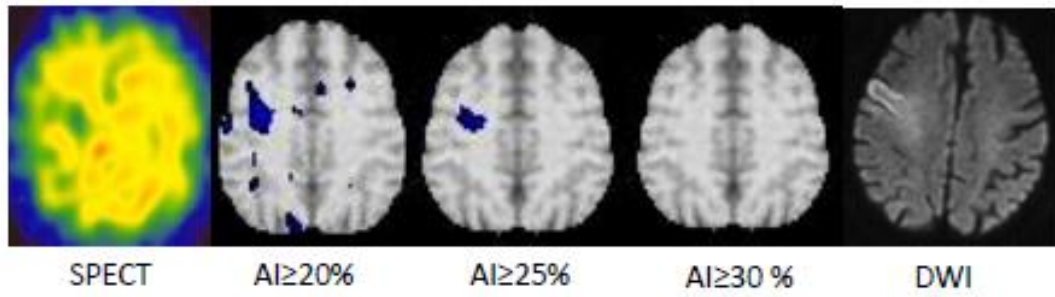
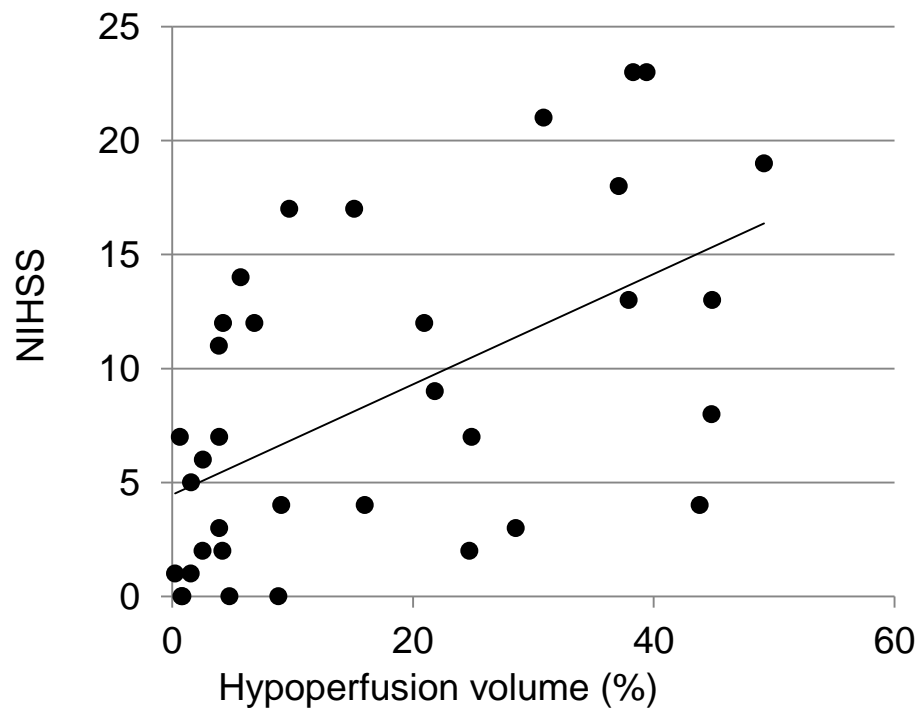


Figure 2

A



B

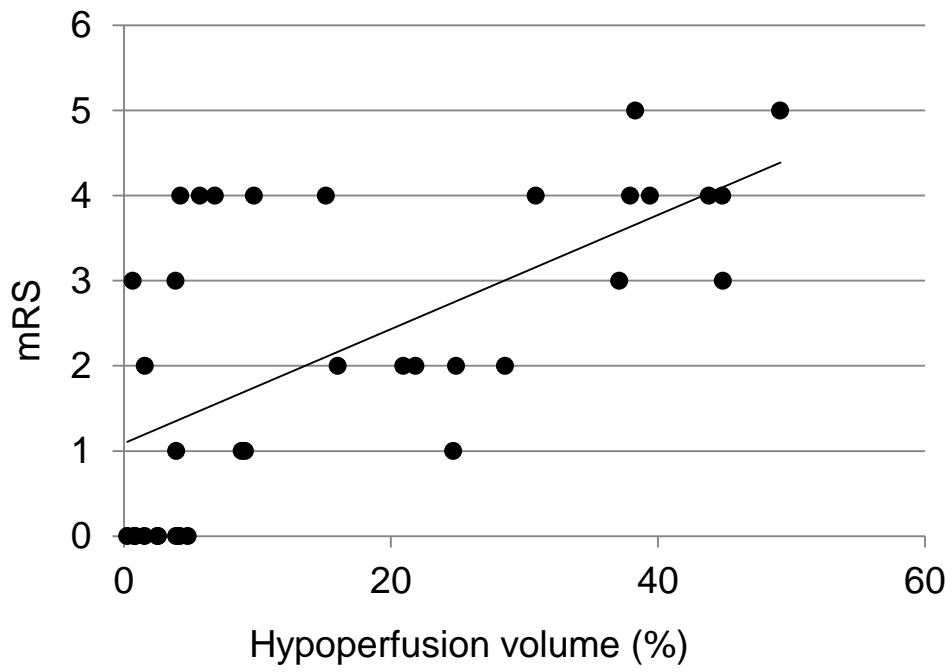


Figure 3

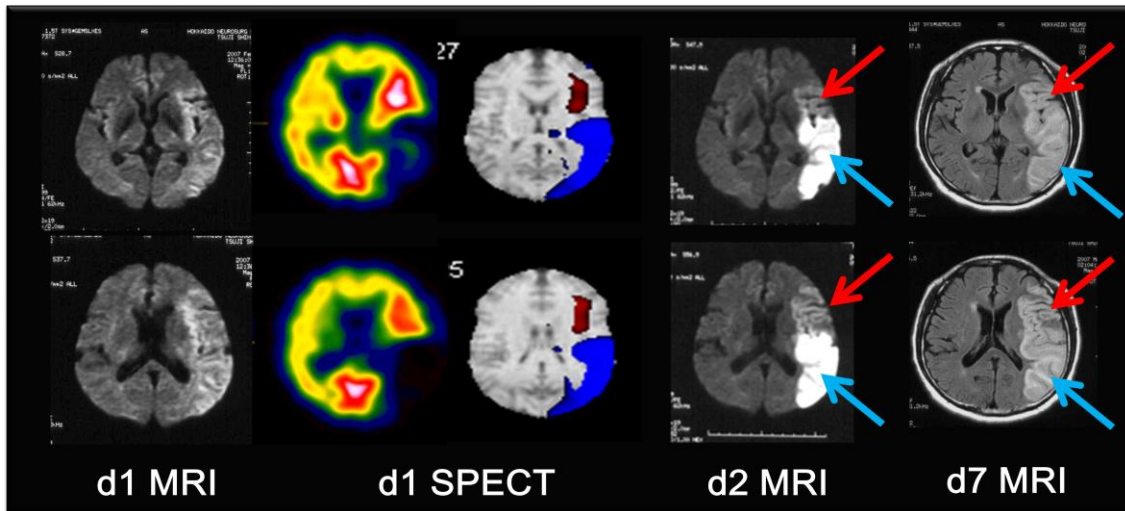


Figure 4

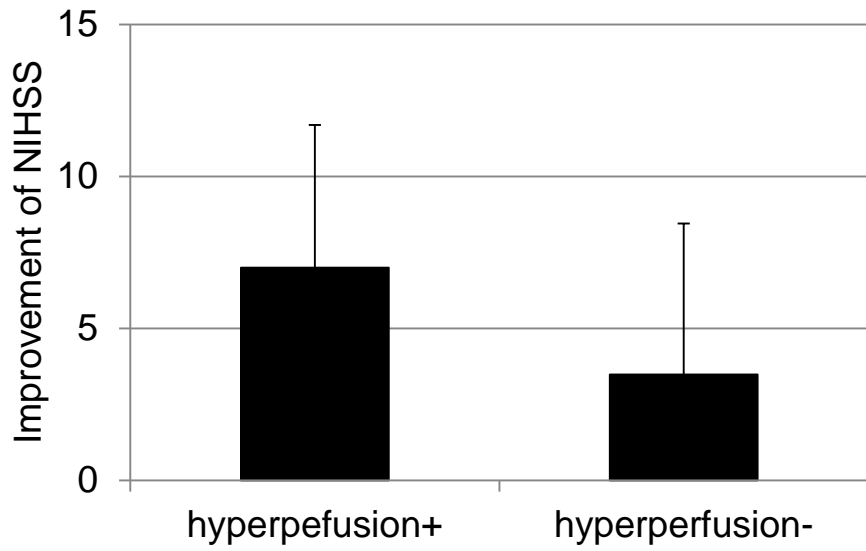


Figure 5

