



Title	Magnetoencephalography localizing spike sources of atypical benign partial epilepsy
Author(s)	Shiraishi, Hideaki; Haginoya, Kazuhiro; Nakagawa, Eiji; Saitoh, Shinji; Kaneko, Yutaka; Nakasato, Nobukazu; Chan, Derrick; Otsubo, Hiroshi
Citation	Brain & development, 36(1), 21-27 https://doi.org/10.1016/j.braindev.2012.12.011
Issue Date	2014-01
Doc URL	http://hdl.handle.net/2115/54865
Type	article (author version)
File Information	Brain Dev_36(1)_21-27.pdf



[Instructions for use](#)

Magnetoencephalography localizing spike sources of atypical benign partial
epilepsy

*Hideaki Shiraishi, **Kazuhiro Haginoya, ***Eiji Nakagawa, *Shinji Saitoh, ****Yutaka Kaneko, *****Nobukazu Nakasato, \$+Derrick Chan, \$ Hiroshi Otsubo

* Department of Pediatrics, Hokkaido University Graduate School of Medicine, Sapporo, Hokkaido, Japan

** Department of Pediatrics, Tohoku University School of Medicine, Sendai, Miyagi, Japan

*** Department of Neurology, National Hospital for Mental, Nervous and Muscular Disorders, National Center of Neurology and Psychiatry, Kodaira, Tokyo, Japan

**** Department of Neurosurgery, National Hospital for Mental, Nervous and Muscular Disorders, National Center of Neurology and Psychiatry, Kodaira, Tokyo, Japan

***** Department of Epileptology, Tohoku University School of Medicine, Sendai, Miyagi, Japan

\$ Division of Neurology, The Hospital for Sick Children, University of Toronto, Toronto, Ontario, Canada

+ Neurology Service, Department of Pediatric Medicine, KK Women's and Children's Hospital Singapore

Running title

MEG for ABPE

Key words

Epileptic negative myoclonus; Focal seizure; Atypical absence; Centro-temporal spike, Continuous spike and waves during sleep, Secondary bilateral synchrony

Corresponding author

Hiroshi Otsubo, MD

1
2
3
4
5
6
7 Division of Neurology, The Hospital for Sick Children
8 555 University Avenue, Toronto, ON, M5G 1X8 Canada
9 E-mail: hiotsubo@rogers.com OR hiroschi.otsubo@sickkids.ca
10 Tel.: +1-416-813-6660, Fax: +1-416-813-6334
11
12
13
14

15 Text pages: 24 pages (including cover page)

16 Words: 2489 words

17
18 Tables: 2 (Proposed size: Table1: 5% of a page; Table2: 10%)

19 Figures: 2 (Proposed size: Figure1: 20% of a page; Figure2: 20%)

20 Supplemental videos: 2
21
22
23
24
25
26
27
28
29
30
31
32
33
34
35
36
37
38
39
40
41
42
43
44
45
46
47
48
49
50
51
52
53
54
55
56
57
58
59
60
61
62
63
64
65

Summary

Rationale: Atypical benign partial epilepsy (ABPE) is characterized by centro-temporal electroencephalography (EEG) spikes, continuous spike and waves during sleep (CSWS), and multiple seizure types including epileptic negative myoclonus (ENM), but not tonic seizures. This study evaluated the localization of magnetoencephalography (MEG) spike sources (MEGSSs) to investigate the clinical features and mechanism underlying ABPE.

Methods: We retrospectively analyzed seizure profiles, scalp video EEG (VEEG), and MEG in ABPE patients.

Results: Eighteen ABPE patients were identified (nine girls and nine boys). Seizure onset ranged from 1.3 to 8.8 years (median, 2.9 years). Initial seizures consisted of focal motor seizures (15 patients) and absences/atypical absences (3). Seventeen patients had multiple seizure types including drop attacks (16), focal motor seizures (16), ENM (14), absences/atypical absences (11), and focal myoclonic seizures (10). VEEG showed centro-temporal spikes and CSWS in all patients. Magnetic resonance imaging (MRI) was reported as normal in all patients. MEGSSs were localized over the following regions: both Rolandic-sylvian (8), peri-sylvian (5), peri-Rolandic (4), parieto-occipital (1), bilateral (10), and unilateral (8). All patients were on more than two antiepileptic medications. ENM and

1
2
3
4
5
6
7
8 absences/atypical absences were controlled in 14 patients treated with adjunctive
9
10 ethosuximide.

11
12
13
14 Conclusion: MEG localized the source of centro-temporal spikes and CSWS in the
15
16
17 Rolandic-sylvian regions. Centro-temporal spikes, Rolandic-sylvian spike sources, and
18
19
20 focal motor seizures are evidence that ABPE presents with Rolandic-sylvian onset seizures.
21
22
23 ABPE is therefore a unique, age-related, and localization-related epilepsy with a
24
25
26 Rolandic-sylvian epileptic focus plus possible thalamo-cortical epileptic networks in the
27
28
29
30 developing brain of children.
31
32
33
34
35
36
37
38
39
40
41
42
43
44
45
46
47
48
49
50
51
52
53
54
55
56
57
58
59
60
61
62
63
64
65

Introduction

Atypical benign partial epilepsy in childhood (ABPE) initially presents with the following signs and symptoms: (i) onset age of 2.5-6 years; (ii) multiple seizure types including focal motor, atypical absences, and myoclonic-atonic seizures; (iii) electroencephalography (EEG) showing central and mid-temporal spikes and diffuse slow spike-wave activities during drowsiness or sleep; and, (iv) normal development or mild mental retardation [1].

Despite multiple seizure types and slow spike and waves on EEG, ABPE is distinguished from Lennox-Gastaut syndrome by its characteristic spontaneous remission, lack of tonic seizures or developmental delay, and normal awake EEG background activity. Since hemi-convulsive seizures during sleep and contralateral/bilateral centro-temporal epileptiform discharges are present at the beginning, the electro-clinical findings of ABPE are indistinguishable from those of benign epilepsy with centro-temporal spikes (BECTS) [2-5]. BECTS is the most well-recognized, age-related idiopathic focal epilepsy with occasional epileptic seizures despite frequent centro-temporal spikes on EEG. In contrast, ABPE patients tend to develop atypical absences or myoclonic-atonic seizures during the course of their condition. Tovia et al. [6] showed that 0.5% of patients with BECTS were categorized as atypical variants, while Doose et al. [7] found that 29% of the relatives of

1
2
3
4
5
6
7
8 ABPE patients had some abnormal activities on EEG. Finally, Gobbi et al. [8] reviewed
9
10 several subtypes of idiopathic focal epilepsies to categorize ABPE as a “Rolandic
11
12 Epilepsy-Related Disorder”; these age-related epilepsies including ABPE and BECTS were
13
14 attributed to a maturational continuum with different manifestations.
15
16
17

18
19
20 Epileptic negative myoclonus (ENM) is one of the characteristic seizure patterns in ABPE.

21
22
23 Oguni et al. [6] analyzed the ictal EEG findings of ENM and demonstrated generalized,
24
25
26 bilateral synchronous discharges, while ictal magnetoencephalography (MEG) of an ABPE
27
28
29 patient showed that the spike sources of ENM were localized at the peri-sylvian region [7].
30
31
32

33
34
35
36 MEG is a relatively new clinical technique that uses superconducting quantum interference
37
38
39 devices (SQUIDs) to measure and localize sources of extracranial magnetic fields
40
41
42 generated by intraneuronal electric currents. Current MEG machines have a whole-head
43
44
45 array of more than 100 sensors contained within a helmet-shaped Dewar, which effectively
46
47
48 covers most of the brain surface. MEG has been increasingly used for localization of the
49
50
51 epileptic zone and functional mapping in epilepsy patients. MEG in BECTS patients
52
53
54 showed spike sources with an anterior-posterior oriented perpendicular to the Rolandic
55
56
57 fissure [8, 9]. No case series of ABPE have thus far used MEG to localize epileptic spike
58
59
60
61
62
63
64
65

1
2
3
4
5
6
7
8 sources.
9
10
11
12
13

14 We conducted a multi-center study to collect clinical, EEG, and MEG findings in ABPE
15
16 patients, with MEG used to characterize the spike sources (MEGSSs) in ABPE. We
17
18 hypothesize that the epileptic network in ABPE is localized in both the Rolandic-sylvian
19
20
21 cortex and thalamo-cortical networks, based on their unique clinical and
22
23
24
25
26
27 electrophysiological features.
28
29
30
31
32
33
34
35
36
37
38
39
40
41
42
43
44
45
46
47
48
49
50
51
52
53
54
55
56
57
58
59
60
61
62
63
64
65

Patients and Methods

We collaborated with four institutions on this study: the Department of Pediatrics, Hokkaido University School of Medicine (HU); Department of Pediatrics, Tohoku University School of Medicine (TU); Department of Pediatrics, National Center of Neurology and Psychiatry (NCNP), Japan; and the Division of Neurology, The Hospital for Sick Children (HSC), Toronto, Ontario, Canada.

Patients

We studied 18 patients with ABPE (9 females and 9 males). We diagnosed ABPE according to the triad of diagnostic criteria as follows: 1, focal motor seizures, absences/atypical absences, atonic seizures including ENM, myoclonic seizures and drop attacks described by parents; 2, EEG findings of central and middle temporal spikes and generalized slow spike-wave activity during drowsiness or sleep similar to continuous spike and slow waves during sleep (CSWS); 3, normal development or mild mental retardation during the clinical course.

EEG

Scalp video EEGs were recorded using the International 10-20 electrode placement system and electromyography (EMG) electrodes for bilateral deltoid muscles to capture ENM. Awake and sleep EEGs were recorded in all patients.

MEG and magnetic resonance imaging

Initial MEG studies were conducted at the onset of ENM. Seven patients had multiple MEG studies up to six times. Parents or guardians of all patients provided written informed consent for the MEG studies. MEG and EEG were done in a magnetically shielded room. MEG was recorded using a system with 306 SQUIDS (Vectorview; Elekta-Neuromag Ltd., Helsinki, Finland) at HU, NCNP, and TU, and with an Omega system (151 channels, VSM MedTech Ltd., Port Coquitlam, BC, Canada) at HSC. MEG data were recorded with a band pass filter of 0.03-133 Hz at HU, NCNP, and TU, and of 1-208 Hz at HSC. Sampling frequency was 400 Hz at HU, 600Hz at NCNP and TU and 625 Hz at HSC. EEGs were recorded using the International 10-20 system, with additional electrocardiogram (ECG) electrodes. MEG data were recorded for > 1 hour per patient, collecting data in 4-minute blocks at HU, NCNP and TU. At HSC, MEG was recorded in 15 two-minute blocks for a total of 30 minutes [10]. Patients were lying in the supine

1
2
3
4
5
6
7
8 position. Sedative agents were used for uncooperative patients. The relative position of the
9
10 head and the MEG sensors were determined by attaching three small head-position
11
12 indicator coils to the head. The positions of the coils were digitized and subsequently
13
14 recorded by the MEG sensors for co-registration with 1.5 tesla (T)/3T magnetic resonance
15
16 image (MRI) with high-resolution sequences.
17
18
19
20
21

22 23 24 25 26 MEG source analysis

27
28 MEG data were digitally filtered using a band filter of 3-30 Hz at HU, NCNP, and
29
30 TU, or at 3-70 Hz at HSC for offline analysis. Segments containing abnormal paroxysms
31
32 were selected manually. Individual spikes were analyzed to localize the spike source per
33
34 spike using an equivalent current dipole (ECD) model or dynamic statistical parametric
35
36 mapping (dSPM) [11, 12].
37
38
39
40
41
42
43
44
45
46
47
48
49
50
51
52
53
54
55
56
57
58
59
60
61
62
63
64
65

Results

Seizure profiles (Table 1)

Seizure onsets ranged from 1.3 to 8.8 years with a median age of 2.9 years. The seizures started as focal motor seizures in 15 patients (83%) and absences/atypical absences in 3 patients (17%).

All patients except one patient had multiple types of seizures in their seizure histories. Drop attacks, in which the precise seizure type remains unknown, were most common (16 patients, 89%). One patient (patient 17) presented with a history of only drop attack seizures. Focal motor seizures (16 patients, 89%), ENM (14 patients, 78%), absences/atypical absences (11 patients, 61%), myoclonic seizures (10 patients, 56%), and secondarily generalized tonic-clonic seizures (9 patients, 50%) were seen in more than half of the patients (Supplementary videos 1 and 2). Focal sensory seizures (6 patients, 33%) and epileptic spasms (2 patients, 11%) were also reported.

Past and Family history

There was no past history of epilepsy before the seizure onset in any of the 18 patients, while 3 (17%) had a positive family history of febrile seizures.

Cognitive functions

Cognitive function was evaluated in 15 patients. All 15 patients had the evaluations while they presented with ENM. A developmental quotient results ranged from 54 to 85 in 5 patients. The full-scale intelligence quotient test (Wechsler Intelligence Scale for Children) results ranged from 53 to 103 in 10 patients.

MRI

No patient showed an abnormality on MRI.

EEG (Figure 1)

EEG showed interictal centro-temporal spikes in all 18 patients. Continuous generalized and/or centro-temporal spike and waves during sleep were also noticed in all patients. When video EEG captured ENM, generalized high-amplitude spike or polyspikes and waves were associated with a brief attenuation of EMG activities corresponding to muscle atonia in 12 patients. (Supplementary video 1) Absences/atypical absences showed generalized and irregular spike and slow waves around 3 Hz on EEG in 16 patients (Supplementary video 2).

(Please insert Figure 1 here)

MEG (Figure 2, Table 2)

MEG localized MEGSSs over both Rolandic-sylvian fissures in 8 patients, the peri-sylvian region alone in 5 patients, and the peri-Rolandic region alone in 4 patients. One patient had MEGSSs in the left parieto-occipital region, even though EEG showed left centro-temporal spikes (patient 6). Most spike sources were oriented perpendicularly to either the Rolandic or sylvian fissure. The spike sources demonstrated identical orientations in 11 patients (61%). MEGSSs were located in bilateral hemispheres in 10 patients (56%) and in a unilateral hemisphere in 8 patients (44%). In all 10 patients with bilateral MEGSS, the MEGSS showed identical patterns and locations in the both hemispheres. ECD could not be estimated in one patient due to diffuse right hemispheric discharges without leading spikes. Therefore, we applied dSPM and localized the MEGSSs in the right sylvian fissure (patient 7). Seven patients underwent multiple MEG studies. Six patients with bilateral MEGSS became unilateral MEGSS. One patient showed consistent unilateral MEGSS. Six patients showed no MEGSS at the last MEG study when they were seizure free.

(Please insert Figure 2 here)

Treatments

All 18 patients were administered multiple antiepileptic medications ranging from 2 to 12 medications (mean 5.8) during their courses. Ethosuximide (ESM) succeeded in controlling various seizure types of ABPE, especially ENM and absences/atypical absences in 14 patients (78%); of these, all achieved seizure freedom after ESM was started, and 11 (89%) of the 14 were still on ESM at the last follow-up. Two of three patients in whom ESM was discontinued were no longer on any antiepileptic medication. CBZ was initially started in 16 patients (89%), but 14 (88%) experienced worsening of seizures after CBZ was initiated, and the treatment was discontinued. Two patients were seizure free on a combination of CBZ and ESM (Patient 6) or CBZ, ZNS, and CLB (Patient 8). Valproic acid (VPA) was tried in 16 (89%) patients, and 6 of these (38%) were still on VPA at the last follow-up. Other medications tried included zonisamide (10 patients, 56%), clobazam (10 patients, 56%), clonazepam (eight patients, 44%) acetazolamide (5 patients, 28%), phenytoin (5 patients, 28%), and diazepam (4 patients, 22%). The medications still being used at the last follow-up consisted of zonisamide in 3/10 patients (30%), clobazam in 4/10 patients (40%), clonazepam in 3/8 patients (38%), acetazolamide in 2/5 patients (40%), and diazepam in 2/4 patients (50%).

1
2
3
4
5
6
7
8 Two patients underwent epilepsy surgery. Patient 8 underwent cortical excision
9
10 over the left supra-marginal gyrus at the age of 12 years. Surgical pathology revealed
11
12 microdysgenesis with increased ganglion cells. She achieved 75-90% seizure reduction
13
14 after the surgery, and was seizure free on three medications at 17.5 years old. Anterior
15
16 two-thirds corpus callosotomy was performed at the age of 6 years for drop attacks in
17
18 patient 9. The patient was seizure free on two medications at 10 years old.
19
20
21
22
23
24
25
26
27
28

29 Seizure outcome

30
31 The age at last follow-up of the 18 patients ranged from 5.4 to 17.5 years (median
32
33 11.8 years). All were seizure free, two patients (11%) without any medication. Five patients
34
35 (28%) were only on one medication, including four patients with ESM. The remaining 11
36
37 patients had multiple medications; six were on 2 medications, four were on 3 medications,
38
39 and one patient was on 4 medications. Among seven patients with multiple MEG studies,
40
41 medication changes, cognitive results effected less prominent for MEGSS than seizure
42
43
44
45
46
47
48
49
50
51 improvements.
52
53
54
55
56
57
58
59
60
61
62
63
64
65

Discussion

MEG localized a Rolandic-sylvian epileptic focus of ABPE

In ABPE, interictal MEG revealed localized clusters of spike sources around the Rolandic-sylvian fissures corresponding to both centro-temporal spikes and CSWS on EEG. The identically clustered Rolandic-sylvian MEGSSs of interictal epileptic discharges in patients with ABPE suggested that the epileptic focus was located around the Rolandic-sylvian regions involving the motor cortex in most cases. In our series, the peri-sylvian region MEGSSs were also recorded in 13 of 18 ABPE patients. In contrast, MEGSSs in BECTS were specifically localized along the Rolandic region with definite identical orientations vertical to the central sulcus [8, 9]. In the older children with BECTS, MEGSSs shifted to the lower part of the Rolandic region close to the operculum.

Kubota et al. [10] reported an ictal MEG study localizing the spike source of ENM with generalized EEG spikes at the sylvian fissure in one ABPE patient [7]. ENM was characterized by spike or polyspikes on EEG time-locked to attenuation of EMG activity, which corresponded to muscle atonia [6]. Series of ENM often caused atonic seizures. Both interictal and ictal MEGSSs indicate that a subset of the epileptogenic zones responsible for focal seizures and ENM in ABPE patients is localized around the Rolandic-sylvian regions. In contrast, MEGSSs in three patients with Lennox-Gastaut syndrome with ENM were

1
2
3
4
5
6
7
8 localized over inconsistent and various brain regions that did not include the
9
10
11 Rolandic-sylvian regions [13].
12
13

14 Fifteen of eighteen patients in this series presented with focal motor seizures at the
15
16 onset, and these persisted in addition to multiple other seizure types developing in 16
17
18 patients. ABPE might also be confused diagnostically with BECTS as ABPE appears
19
20 superficially similar on scalp EEG and also presents with focal motor seizures. In ABPE
21
22 patients, MEGSS extended to perisylvian region in addition to Rolandic region or localized
23
24 even perisylvian region alone.
25
26
27
28
29
30
31

32 33 34 35 MEG localized spike dipoles in CSWS of ABPE

36
37 Sleep EEG often shows almost-continuous generalized or centro-temporal spike and
38
39 waves during sleep in ABPE patients, resembling CSWS. Another differential diagnosis of
40
41 ABPE is epileptic encephalopathy with CSWS (ECSWS), and there are no reports of source
42
43 localizations using MEG in patients with ECSWS. The role of MEG remains to be explored
44
45 in this entity. Kelemen et al. [17] reported three patients with CSWS secondary to
46
47 destructive lesions in the thalamus [14], and CSWS development was often observed in
48
49 patients with a thalamic lesion, indicative of thalamo-cortical dysfunction with an epileptic
50
51
52
53
54
55
56
57
58
59
60
61
62
63
64
65

1
2
3
4
5
6
7 network [15, 16]. ESM can be efficacious for seizures In ABPE patients, especially for
8
9
10
11 ENM [6]. In 13 (72%) of the 18 ABPE patients studied herein, ESM completely suppressed
12
13
14 their ENM. In other studies, systemic administration of ESM significantly reduced spike
15
16
17 and wave discharges in genetic absence epilepsy models [17-19]. Continuous and
18
19
20 generalized slow spike and waves during sleep in patients with ECSWS have been
21
22
23 associated with secondary bilateral synchrony with leading foci [20, 21]. The CSWS in
24
25
26 ABPE could also be due to secondary bilateral synchrony, but originating specifically from
27
28
29 the Rolandic-sylvian regions. The effect of ESM on the clinical seizures and CSWS
30
31
32 indicates that the epileptic substitute of thalamic and Rolandic-sylvian networks produce
33
34
35
36 ABPE.
37
38

39 Patry et al. [25] reported six patients with ECSWS, and heterogeneous seizure types
40
41
42 of ECSWS that comprise focal motor seizures, absences, and epileptic falls while awake
43
44
45 [21] resemble those of ABPE. Consequently, it can be difficult to distinguish ABPE from
46
47
48 ECSWS clinically not analyzing the localization of epileptic foci. Further investigation of
49
50
51 MEG in ECSWS may therefore serve to differentiate epileptic sources in these patients and
52
53
54 improve our understanding of the epileptic networks and mechanisms leading to the
55
56
57 observed cognitive disabilities.
58
59
60
61
62
63
64
65

Conclusions

MEG localized spike dipoles of centro-temporal spikes and CSWS over the Rolandic-sylvian regions in ABPE, indicating that ABPE is the localization-related epilepsy with Rolandic-sylvian onset seizures. In addition, the effects of ESM on ENM and atypical absences suggest the involvement of thalamo-cortical circuitry in the epileptic network. ABPE is a unique age-related epilepsy involving the Rolandic-sylvian plus thalamo-cortical networks in the developing brain of children.

Disclosure of Conflicts of Interest

The authors have no financial or personal relations that could pose a conflict of interest.

We confirm that we have read the Journal's position on issues involved in ethical publication and affirm that this report is consistent with those guidelines.

Figure legends

Figure 1

MEG and EEG in case 18

A: A-P bipolar EEG shows continuous spike and waves during sleep at the time of MEG study (low frequency filter, 3Hz; high frequency filter, 70Hz).

B: The same EEG of A is expanded to demonstrate left centro-temporal spikes preceding to the right central spikes after the red cursor.

C: 151 MEG channels are labeled by two colors (red for right hemisphere and blue for left hemisphere), and show the view of overlay (left), right channels (middle), and left channels (right). MEG shows more complex polyspikes than EEG on the overlay left channels. Note the MEG spikes (red cursor) leading to EEG spikes (behind the red cursor) on B.

D: MEG topography (left) and EEG topography (right). Note that magnetic and electric topographies are perpendicular to each other.

E: Axial MRI shows MEG spike source at the time of red cursor at the left Rolandic region (circle, position; tail, orientation, and moment).

F: Sagittal MRI shows the same MEG spike source of (E) at the left Rolandic region. The equivalent current dipole (spike source) is oriented horizontally, projecting negativity towards the frontal region and positivity towards the parietal region, corresponding to the EEG topography (D, right).

Figure 2

MRI with MEG spike sources in 18 cases

Red circles demonstrate the source of MEG spikes. Tails indicate orientations and moments of the MEG spike sources. Case 7 shows dynamic statistical parametric mapping. The color bar indicates the P value, ranging from gray, 1×10^{-1} to yellow, $1 \times 10^{-4.3}$.

Supplementary information

Video 1

Epileptic negative myoclonus of the arm and head drop in case 18

A-P bipolar EEG shows frequent bilateral/generalized high-amplitude spike/polyspikes and waves with left centro-temporal predominance. The high-amplitude polyspikes and wave at the middle of the EEG trace corresponds to a brief attenuation of the right deltoid EMG (R Deltoid EMG at the bottom) associated with epileptic negative myoclonus of the right hand and head drop on the video.

Video 2

Absence in case 18

A-P bipolar EEG shows paroxysmal generalized high-amplitude, 3-Hz spike and waves lasting 3.5 seconds that are associated with staring and blinking on the video. At the beginning, left centro-temporal spike and waves lead at T3-T5 and C3-P3. The right hemisphere is spared except for the homologous centro-temporal region at F8-T4 and F4-C4.

References

- [1] Aicardi J, Chevrie JJ. Atypical benign partial epilepsy of childhood. *Developmental medicine and child neurology*. 1982;24:281-92.
- [2] Beaumanoir A, Ballis T, Varfis G, Ansari K. Benign epilepsy of childhood with Rolandic spikes. A clinical, electroencephalographic, and telencephalographic study. *Epilepsia*. 1974;15:301-15.
- [3] Bernardina BD, Tassinari CA. EEG of a nocturnal seizure in a patient with "benign epilepsy of childhood with Rolandic spikes". *Epilepsia*. 1975;16:497-501.
- [4] Blom S, Heijbel J. Benign epilepsy of children with centro-temporal EEG foci. Discharge rate during sleep. *Epilepsia*. 1975;16:133-40.
- [5] Fejerman N, Caraballo R, Tenenbaum SN. Atypical evolutions of benign localization-related epilepsies in children: are they predictable? *Epilepsia*. 2000;41:380-90.
- [6] Oguni H, Uehara T, Tanaka T, Sunahara M, Hara M, Osawa M. Dramatic effect of ethosuximide on epileptic negative myoclonus: implications for the neurophysiological mechanism. *Neuropediatrics*. 1998;29:29-34.
- [7] Kubota M, Nakura M, Hirose H, Kimura I, Sakakihara Y. A magnetoencephalographic study of negative myoclonus in a patient with atypical benign partial epilepsy. *Seizure : the journal of the British Epilepsy Association*. 2005;14:28-32.
- [8] Minami T, Tasaki K, Yamamoto T, Gondo K, Yanai S, Ueda K. Magneto-encephalographical analysis of focal cortical heterotopia. *Developmental medicine and child neurology*. 1996;38:945-9.
- [9] Ishitobi M, Nakasato N, Yamamoto K, Iinuma K. Opercular to interhemispheric source distribution of benign rolandic spikes of childhood. *NeuroImage*. 2005;25:417-23.
- [10] RamachandranNair R, Otsubo H, Shroff MM, Ochi A, Weiss SK, Rutka JT, et al. MEG predicts outcome following surgery for intractable epilepsy in children with normal or nonfocal MRI findings. *Epilepsia*. 2007;48:149-57.
- [11] Dale AM, Liu AK, Fischl BR, Buckner RL, Belliveau JW, Lewine JD, et al. Dynamic statistical parametric mapping: combining fMRI and MEG for high-resolution imaging of cortical activity. *Neuron*. 2000;26:55-67.
- [12] Shiraishi H, Ahlfors SP, Stufflebeam SM, Takano K, Okajima M, Knake S, et al. Application of magnetoencephalography in epilepsy patients with widespread spike or slow-wave activity. *Epilepsia*. 2005;46:1264-72.
- [13] Sakurai K, Tanaka N, Kamada K, Takeuchi F, Takeda Y, Koyama T.

Magnetoencephalographic studies of focal epileptic activity in three patients with epilepsy suggestive of Lennox-Gastaut syndrome. *Epileptic disorders : international epilepsy journal with videotape*. 2007;9:158-63.

[14] Kelemen A, Barsi P, Gyorsok Z, Sarac J, Szucs A, Halasz P. Thalamic lesion and epilepsy with generalized seizures, ESES and spike-wave paroxysms--report of three cases. *Seizure : the journal of the British Epilepsy Association*. 2006;15:454-8.

[15] Battaglia D, Veggiotti P, Lettori D, Tamburrini G, Tartaglione T, Graziano A, et al. Functional hemispherectomy in children with epilepsy and CSWS due to unilateral early brain injury including thalamus: sudden recovery of CSWS. *Epilepsy research*. 2009;87:290-8.

[16] Guzzetta F, Battaglia D, Veredice C, Donvito V, Pane M, Lettori D, et al. Early thalamic injury associated with epilepsy and continuous spike-wave during slow sleep. *Epilepsia*. 2005;46:889-900.

[17] Hanaya R, Sasa M, Ujihara H, Fujita Y, Amano T, Matsubayashi H, et al. Effect of antiepileptic drugs on absence-like seizures in the tremor rat. *Epilepsia*. 1995;36:938-42.

[18] Marescaux C, Micheletti G, Vergnes M, Depaulis A, Rumbach L, Warter JM. A model of chronic spontaneous petit mal-like seizures in the rat: comparison with pentylenetetrazol-induced seizures. *Epilepsia*. 1984;25:326-31.

[19] van Rijn CM, Sun MS, Deckers CL, Edelbroek PM, Keyser A, Renier W, et al. Effects of the combination of valproate and ethosuximide on spike wave discharges in WAG/Rij rats. *Epilepsy research*. 2004;59:181-9.

[20] Kobayashi K, Nishibayashi N, Ohtsuka Y, Oka E, Ohtahara S. Epilepsy with electrical status epilepticus during slow sleep and secondary bilateral synchrony. *Epilepsia*. 1994;35:1097-103.

[21] Tassinari CA, Rubboli G, Volpi L, Meletti S, d'Orsi G, Franca M, et al. Encephalopathy with electrical status epilepticus during slow sleep or ESES syndrome including the acquired aphasia. *Clinical neurophysiology : official journal of the International Federation of Clinical Neurophysiology*. 2000;111 Suppl 2:S94-S102.

Figure1
[Click here to download high resolution image](#)

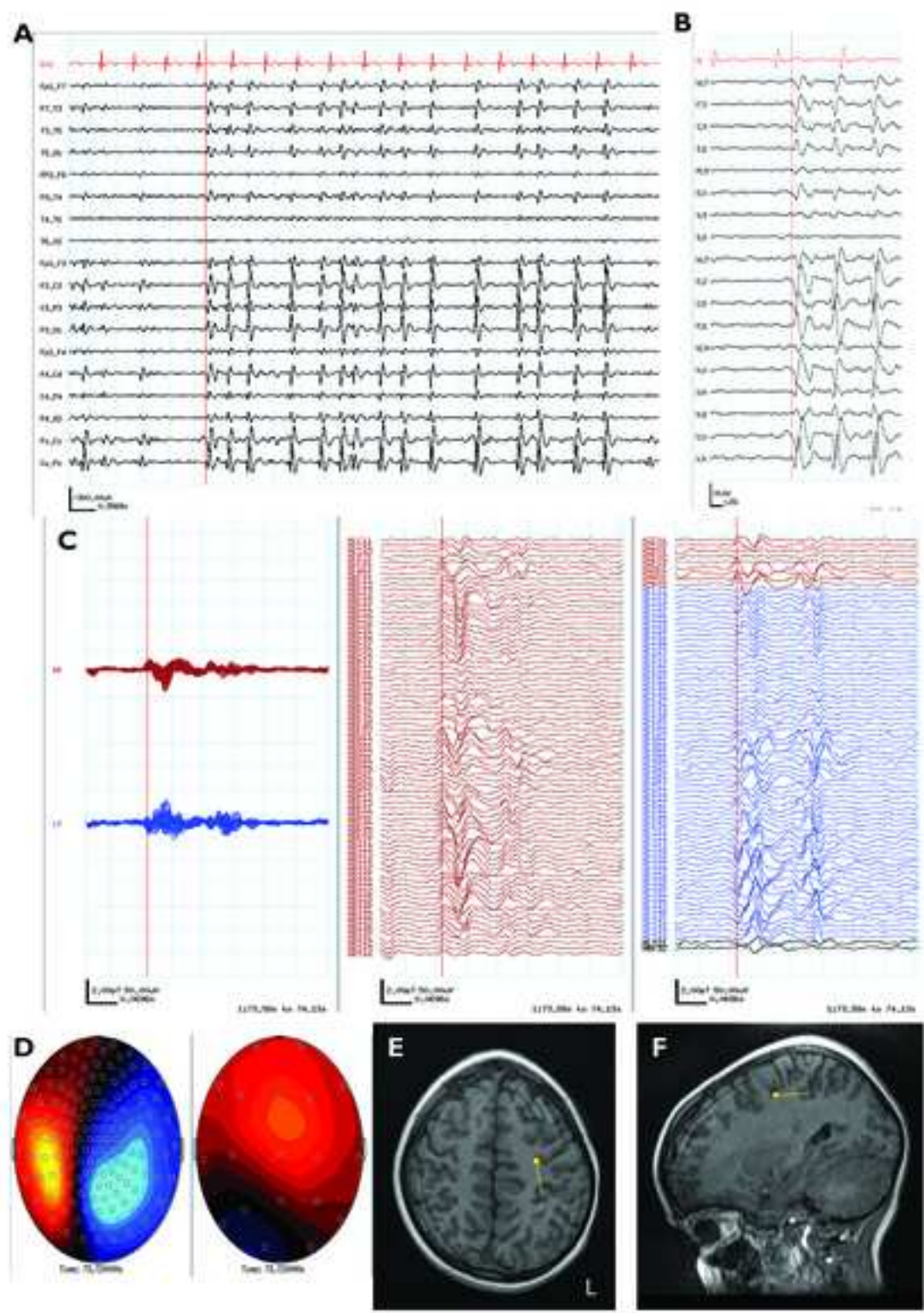
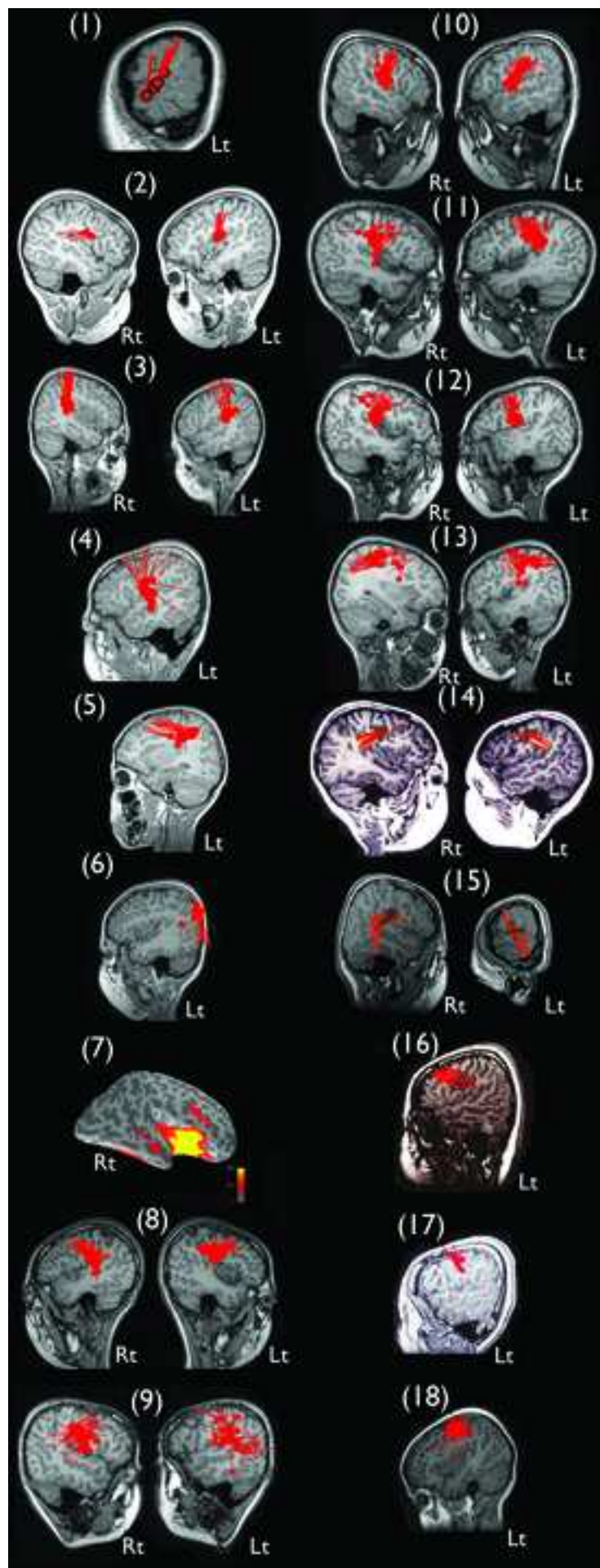


Figure2

[Click here to download high resolution image](#)



Seizure onset	1.3 - 8.8 years (median, 2.9 years)	
Initial seizures	Focal motor seizures	15 (83%)
	Absences/atypical absences	3 (17%)
Type of seizures in patient history	Drop attacks	16 (89%)
	Focal motor seizures	16 (89%)
	Epileptic negative myoclonus	14 (78%)
	Absences/atypical absences	11 (61%)
	Myoclonic seizures	10 (56%)
	Secondarily generalized tonic-clonic seizures	9 (50%)
	Focal sensory seizures	6 (33%)
Epileptic spasms	2 (11%)	

Table 1: Seizure profiles

Table2

Patients	Regions			Hemispheres	
	Rolandic	Sylvian	Other lobe	Bilateral	Unilateral
1		1			1
2	1	1		1	
3		1		1	
4		1			1
5	1				1
6			occipital		1
7		1			1
8	1	1		1	
9	1	1		1	
10		1		1	
11	1	1		1	
12	1	1		1	
13	1	1		1	
14	1			1	
15	1	1		1	
16	1				1
17	1				1
18	1	1			1
Total	12	13		10	8

Table 2: MEG spike source localization