



Title	Unique preferential conduction within the isolated septal substrate in a patient with ventricular tachycardia complicated with non-ischemic dilated cardiomyopathy
Author(s)	Watanabe, Masaya; Yokoshiki, Hisashi; Mitsuyama, Hirofumi; Mizukami, Kazuya; Tsutsui, Hiroyuki
Citation	Journal of electrocardiology, 46(6), 682-685 https://doi.org/10.1016/j.jelectrocard.2013.03.015
Issue Date	2013-11
Doc URL	http://hdl.handle.net/2115/54126
Type	article (author version)
File Information	J Electrocardiol_46(6)_682-685.pdf



[Instructions for use](#)

Unique preferential conduction within the isolated septal substrate in a patient with ventricular tachycardia complicated with non-ischemic dilated cardiomyopathy

Masaya Watanabe, MD.; PhD., Hisashi Yokoshiki, MD., PhD.;

Hirofumi Mitsuyama, MD., PhD.; Kazuya Mizukami, MD.; and

Hiroyuki Tsutsui, MD., PhD.

Department of Cardiovascular Medicine, Hokkaido University Graduate School of Medicine

Short title: Preferential conduction within the isolated septal substrate

Address for correspondence: Hisashi Yokoshiki, MD, PhD

Department of Cardiovascular Medicine,

Hokkaido University Graduate School of Medicine,

Kita-15, Nishi-7, Kita-ku, Sapporo 060-8638, Japan.

Phone: 81-11-706-6973

Fax: 81-11-706-7874

Total word count of the manuscript: 1965

Total numbers of figures: 3

Abstract

We describe the case of a 67-year-old woman with non-ischemic dilated cardiomyopathy who underwent successful radiofrequency catheter ablation for ventricular tachycardia (VT) originated from the isolated ventricular septal substrate. Pacemapping exhibited either left, identical to clinical VT, or right bundle branch block like wide QRS morphology. Time interval from the stimulus to QRS onset (St-QRS) was prolonged at the center of the substrate, while St-QRS at the border was shortened. Difference in the morphology of pacemapping was dependent on whether or not the pacing stimulus could propagate directly into the right ventricle due to the possible intramural conduction disturbance.

Key Word: ventricular tachycardia, isolated septal substrate, non-ischemic dilated cardiomyopathy

Introduction

The development in the substrate-based ablation strategy has led to the improved success of the catheter ablation for ventricular tachycardia (VT) associated with the structural heart diseases, such as non-ischemic dilated cardiomyopathy (NIDCM).^{1,2}

The major substrates for VT in patients with NIDCM have been reported to be the basal periannular region of the left ventricle (LV).¹⁻⁴ On the other hand, isolated septal substrate is reported to be rare, and found in only 10% of these patients.⁵ In addition, the treatment of VT associated with the septal substrate is challenging because the scar area exists entirely intramural zone or there are multiple VT circuits.⁵

In the present report, we describe a case of VT in a patient with NIDCM associated with the isolated septal substrate, in which unique conduction property was documented.

Case Report

A 67-year-old woman was admitted to our hospital due to recurrent heart failure. She had been diagnosed as non-ischemic dilated cardiomyopathy (NIDCM) and cardiac resynchronization therapy with defibrillator (CRT-D) was performed in October 2010. Echocardiogram showed a markedly dilated left ventricle with reduced ejection function (23%) and moderate mitral regurgitation.

Monitoring of electrocardiogram (ECG) showed incessant appearance of asymptomatic VT. Therefore, we considered that such recurrent VT was one of the causes of worsening heart failure. At first, continuous tranvenous infusion of amiodarone was administered to her, which decreased the frequency of VT. However, we could not eliminate it completely. Then, we performed catheter ablation for her.

The 12-lead ECG during atrial pacing showed left bundle branch block (LBBB)-like wide QRS morphology with left axis deviation (**Figure 1A**). This QRS morphology was similar to that during spontaneous VT (**Figure 1B**), suggesting that the circuit of VT was present around the ventricular septum.

After obtaining a written informed consent for her, an electrophysiological study was performed. A quadripolar catheter was positioned in the apical septum of the right ventricle. Using an electroanatomical mapping system (CARTO®, Biosense Webster, Diamond Bar, CA, USA), we created a substrate map of left ventricular (LV) endocardium during the biventricular pacing. The voltage map showed broad low voltage (< 1.5mV) area within the LV septum, while the intrinsic voltage amplitude was preserved in other regions (**Figure 2A**). Low voltage area within the LV septum

was 58.2 cm² and occupied one-fourth of the LV endocardial surface area.

The pacemapping at low voltage area exhibited two different QRS morphologies; one was identical to clinical VT (pace map 1 in **Figure 2B**) and the other was right bundle branch block (RBBB)-like wide QRS morphology with superior axis deviation (pace map 2 in **Figure 2B**). The pacing sites, where the QRS morphology identical to pace map 1 was obtained, were marked by yellow tags, and those identical to pace map 2 were marked by blue tags. Interestingly, the borderline of two pace maps was identified in the center of low voltage area, and subtle movement of the pacing catheter produced completely different QRS morphologies; that is pace map 1 and pace map 2 in **Figure 2B**.

Time interval from the stimulus to the onset of the QRS (St-QRS (ms)) was prolonged at the the center of low voltage area (e.g., points B and C in **Figures 2A** and **2B**). On the other hand, St-QRS at the border of the low voltage area was shortened (e.g., points A and D in **Figures 2A** and **2B**). The combined St-QRS map for both pace map1 and pace map 2 was given in **Figure 2C**. St-QRS ranged from 67 to 179 ms with pace map 1 and from 60 to 189 ms with pace map 2, respectively.

Radiofrequency catheter ablation (RFCA) was performed during biventricular pacing. Radiofrequency energy (35-40W, temperature limit 55°C, NaviStar DS; Biosense-Webster, Diamond Bar, CA) was delivered at the sites with pace map 1 or 2 within low voltage area. After RFCA of overall 43 times, VT, which had been induced easily by catheter stimulation or pacing, became no longer inducible. The patient was discharged with significant decrease in BNP from 1434 to 990 pg/dL after RFCA and has been free of recurrence of VT and heart failure for 12 months.

Discussion

We reported a case of VT related to the isolated septal substrate with unique preferential conduction in NIDCM, which could be successfully eliminated by catheter ablation. NIDCM is known to have increased risk of VT, the substrate of monomorphic VT in NIDCM often exists in the deep endocardium² or adjacent to a valve annulus on both the epicardium and endocardium.¹⁻⁴ Haqqani et al reported that the isolated septal substrate in patients with NIDCM was rare and only 11.6% of these patients.⁵

Although we tried to demonstrate the concealed entrainment at the initial strategy, the VT did not sustain long enough to perform such diagnostic maneuvers. For example, the pace stimulation at the critical sites could induce the VT, but it was terminated easily by the stimulation which precluded the analysis of post pacing interval. On the other hand, in ischemic VT, the endocardial low voltage area produced by previous myocardial infarction (i.e., scar) creates the substrate for reentry, and often presents channels of electrograms with a particular topography and propagation of activation^{6,7}. In addition, the pace mapping QRS configuration identical to that of the VT was obtained in the low voltage area with St-QRS longer than 40 ms (**Figure 2C**), indicative of conduction delay in the reentry circuits⁷. Therefore, we consider that the mechanism of this VT was reentry.

In this case, the pacing within the low voltage area exhibited two different QRS morphologies. One was LBBB-like wide QRS morphology with left axis deviation observed in the basal region of the low voltage area, named as pace map 1,

and the other was RBBB-like QRS morphology with superior axis deviation observed in the apical region, named as pace map 2. Interestingly, in the borderline of the two regions, slight change in the pacing sites made two complete different QRS morphologies (**Figures 2A** and **2B**). In addition, when the pacing at point B in **Figure 2A** exhibited the QRS morphology of pace map1, time interval from pacing stimulation to RV catheter (St-RV (ms)) was about 200 ms (**Figure 3A** left panel). On the other hand, when the pacing at point C in **Figure 2A** exhibited the QRS morphology of pace map 2, St-RV was significantly prolonged up to 300 ms (**Figure 3A** right panel). The previous report by Auricchio et al showed the the trans-septal activation time among the patients with severe heart failure (EF < 35%) and CLBBB was 40 ms in average and limited up to 100 ms⁸. Therefore, we speculated that the pacing stimulation with pace map 1 could capture the intramural myocardium and propagate into RV through slow conduction area within the ventricular septum, whereas that with pace map 2 could not propagate through the ventricular septum. This is because there might be dense intramural septal scar at the mid and apical region, which prevented direct conduction from the pace map 2 sites to RV endocardium. We could not demonstrate the presence of alterations in intramural myocardial tissues such as fibrosis by using magnetic resonance imaging (MRI)⁹ because CRT-D was implanted in this patient. However, our consideration could be supported by the following two observations. First, the conduction was delayed in the mid and apical region of the LV endomyocardium during biventricular pacing. **Figure 3B** showed the time interval from the pacing spike delivered by the RV lead located at upper septum to the electrogram recorded from the ablation catheter located in the LV endocardium. Time

interval was significantly prolonged in the mid and apical region, indicating that the conduction from RV upper septum to those regions was severely disturbed. Second, the scar region was located in the mid region, where maximum stimulation with 10 V at pulse width of 1 ms could not activate myocardium. It was marked by the gray tag and observed around the mid region of low voltage area. It does not only represent the severe conduction disturbance in the LV septal endocardium, but also might indicate trans-mural disturbance in the mid region.

We demonstrated a case of cured VT in NIDCM with a unique preferential conduction property within the isolated septal substrate, which might be associated with intramural conduction disturbance.

References

1. Hsia HH, Callans DJ, Marchlinski FE. Characterization of endocardial electrophysiological substrate in patients with nonischemic cardiomyopathy and monomorphic ventricular tachycardia. *Circulation*. 2003;108:704-710
2. Soejima K, Stevenson WG, Sapp JL, Selwyn AP, Couper G, Epstein LM. Endocardial and epicardial radiofrequency ablation of ventricular tachycardia associated with dilated cardiomyopathy: The importance of low-voltage scars. *Journal of the American College of Cardiology*. 2004;43:1834-1842
3. Hsia HH, Marchlinski FE. Characterization of the electroanatomic substrate for monomorphic ventricular tachycardia in patients with nonischemic cardiomyopathy. *Pacing and clinical electrophysiology : PACE*. 2002;25:1114-1127
4. Cano O, Hutchinson M, Lin D, Garcia F, Zado E, Bala R, Riley M, Cooper J, Dixit S, Gerstenfeld E, Callans D, Marchlinski FE. Electroanatomic substrate and ablation outcome for suspected epicardial ventricular tachycardia in left ventricular nonischemic cardiomyopathy. *Journal of the American College of Cardiology*. 2009;54:799-808
5. Haqqani HM, Tschabrunn CM, Tzou WS, Dixit S, Cooper JM, Riley MP, Lin D, Hutchinson MD, Garcia FC, Bala R, Verdino RJ, Callans DJ, Gerstenfeld EP, Zado ES, Marchlinski FE. Isolated septal substrate for ventricular tachycardia in nonischemic dilated cardiomyopathy: Incidence, characterization, and implications. *Heart rhythm : the official journal of the Heart Rhythm Society*.

2011;8:1169-1176

6. Soejima K, Stevenson WG, Maisel WH, Sapp JL, Epstein LM. Electrically unexcitable scar mapping based on pacing threshold for identification of the reentry circuit isthmus: Feasibility for guiding ventricular tachycardia ablation. *Circulation*. 2002;106:1678-1683
7. Stevenson WG, Sager PT, Natterson PD, Saxon LA, Middlekauff HR, Wiener I. Relation of pace mapping qrs configuration and conduction delay to ventricular tachycardia reentry circuits in human infarct scars. *Journal of the American College of Cardiology*. 1995;26:481-488
8. Auricchio A, Fantoni C, Regoli F, Carbucicchio C, Goette A, Geller C, Kloss M, Klein H. Characterization of left ventricular activation in patients with heart failure and left bundle-branch block. *Circulation*. 2004;109:1133-1139
9. Nazarian S, Bluemke DA, Lardo AC, Zviman MM, Watkins SP, Dickfeld TL, Meininger GR, Roguin A, Calkins H, Tomaselli GF, Weiss RG, Berger RD, Lima JA, Halperin HR. Magnetic resonance assessment of the substrate for inducible ventricular tachycardia in nonischemic cardiomyopathy. *Circulation*. 2005;112:2821-2825

Figure Legends

Figure 1

Twelve-lead electrocardiograms of atrial pacing (left panel) and spontaneously recorded ventricular tachycardia (VT) (right panel).

Figure 2

(A) Left ventricular (LV) endocardial voltage maps from right anterior oblique (RAO) view (left panel) and left anterior oblique (LAO) view (right panel). Broad low voltage area was seen in the ventricular septum. Yellow or blue tag indicates the point with pace map 1 or pace map 2 shown in **Figure 2B**, respectively. Red tag indicates the ablation point, and the gray tag indicates the scar point unexcitable by maximum stimulation of 10 V with the pulse width of 1ms. (B) The QRS morphologies of the clinical VT and the pace maps. Pace maps at the point A and B had the QRS morphologies similar to clinical VT (Pace map 1). Pace maps at the point B and C showed almost the same QRS morphology with RBBB and superior axis deviation (Pace map 2). Stimulus-QRS intervals (St-QRS) are shown between lead I and II of surface ECGs. Because of the sensing failure of biventricular pacemaker, there are ineffective pacing spikes in panels B,C and D. (C) Relationship between stimulus-QRS interval (St-QRS) and anatomy of LV. Color scale was constructed with St-QRS from all the points with either pace map 1 (yellow tag) or 2 (blue tag). White tags have only geometrical information, and do not affect the St-QRS interval map. The gray tag indicates the scar point. LAO, left anterior oblique; RAO, right anterior

oblique; AVA, aortic valve annulus; MVA, mitral valve annulus.

Figure 3

(A) Time interval from the pacing stimulation to electrogram recorded at the RV catheter (St-RV). Surface and intracardiac electrograms during pacemapping are shown. St-RV at the point B in **Figure 2A**, where pace map 1 was obtained, was much shorter than that at the point C in **Figure 2A**, where pace map 2 was obtained. (B) Time interval from RV stimulation spike to focal activation. Note that there are two pacing spikes due to biventricular pacing with V-V delay. The latter is a pacing spike from the RV lead. Left panel displays geometrical distribution of the time interval. The RV lead was located in the upper RV septum. The descriptions of the colored tags and the abbreviations are the same in **Figure 2**. Right panel shows the electrocardiograms and intracardiac electrograms at each point.

A pace (70ppm)

VT (CL = 560ms)

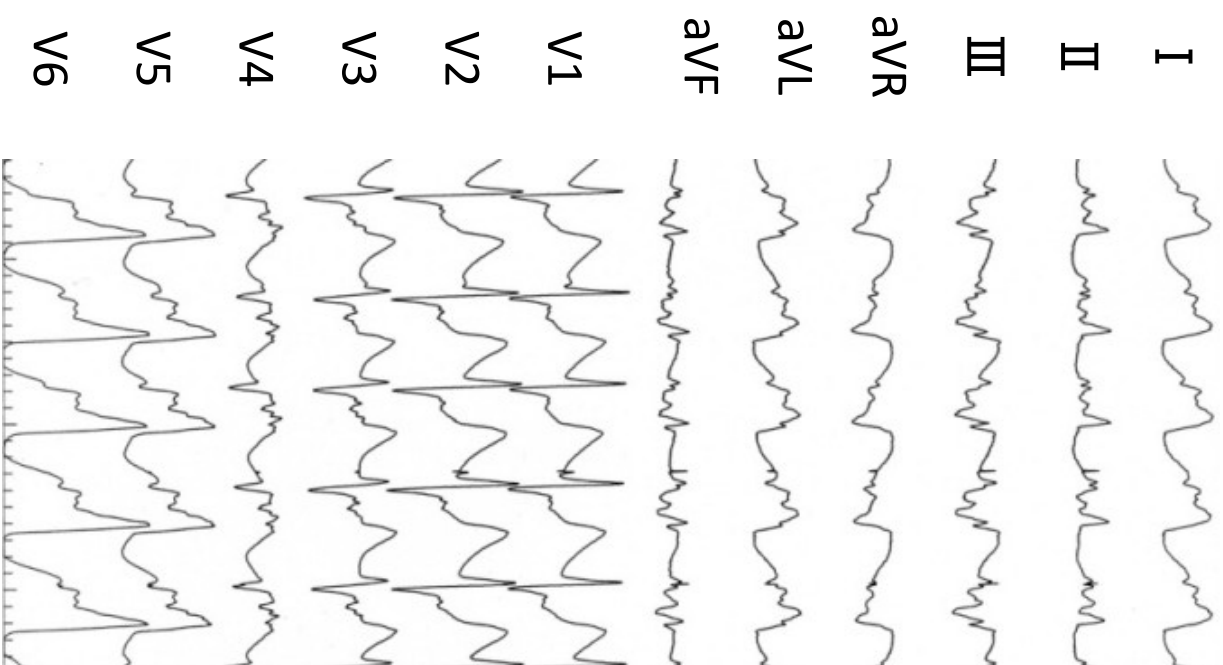
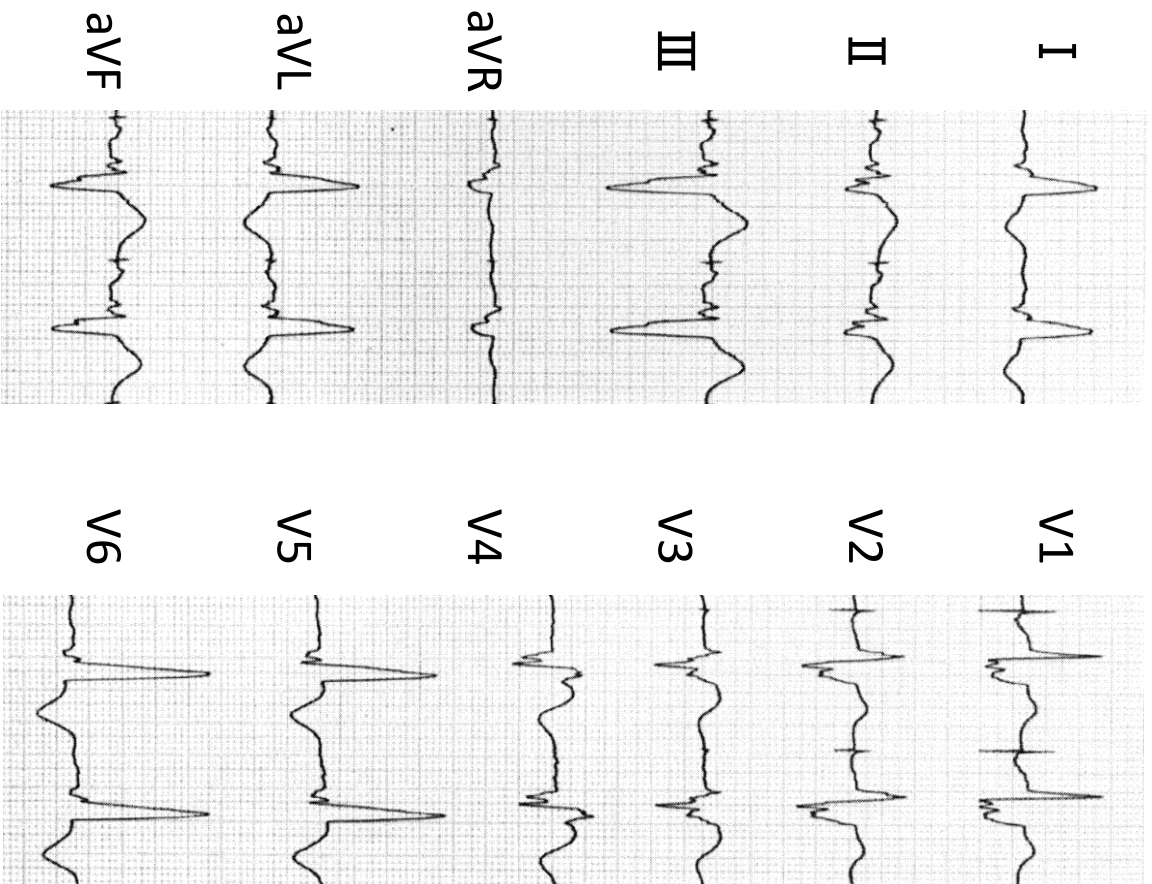
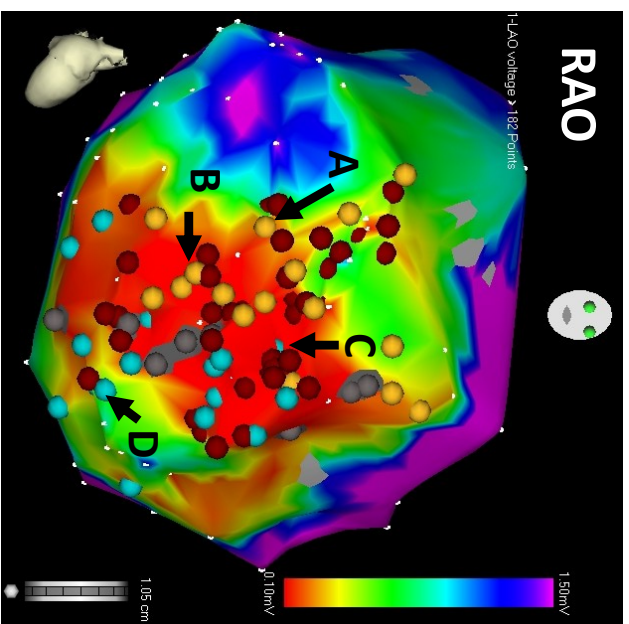


Figure 1

A

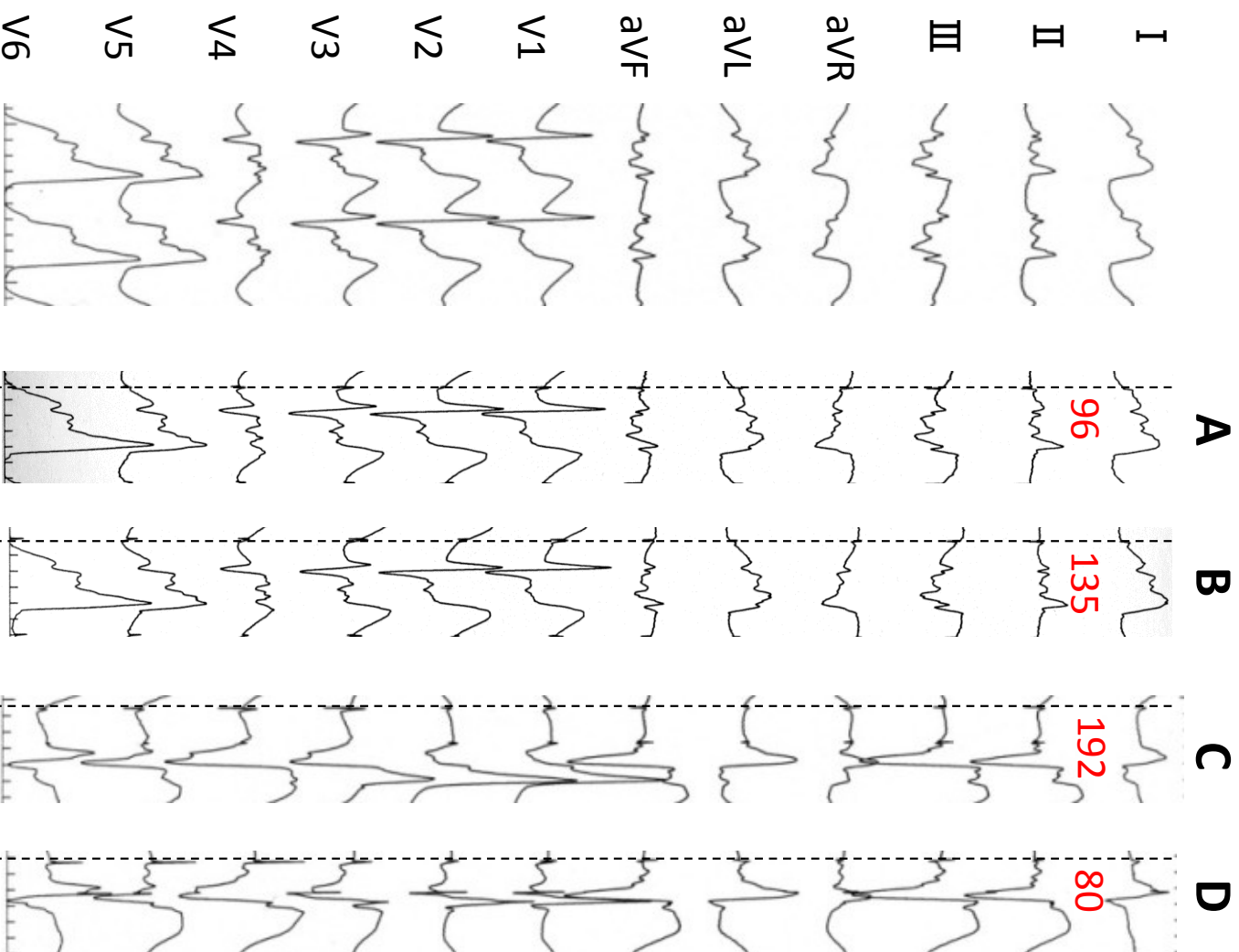
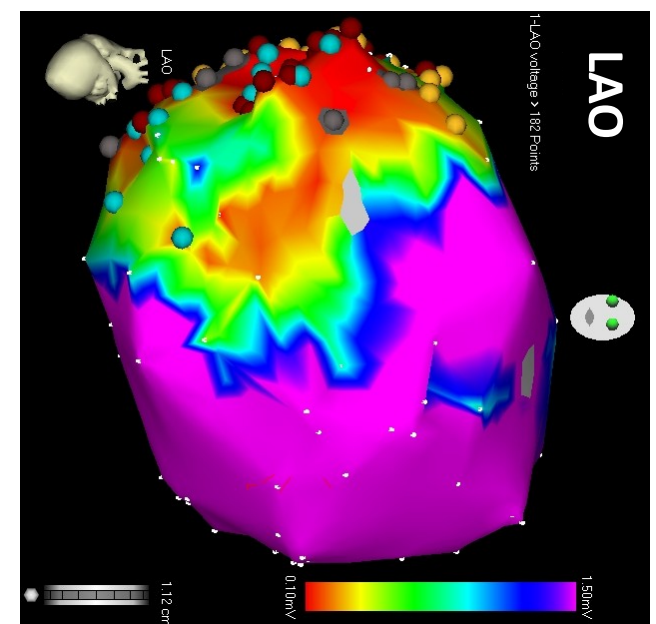


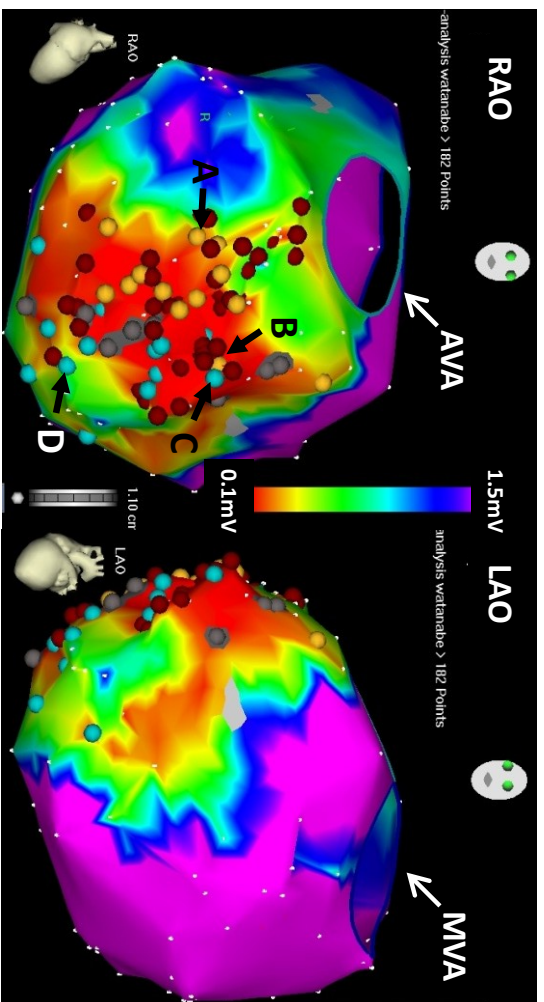
B

VT

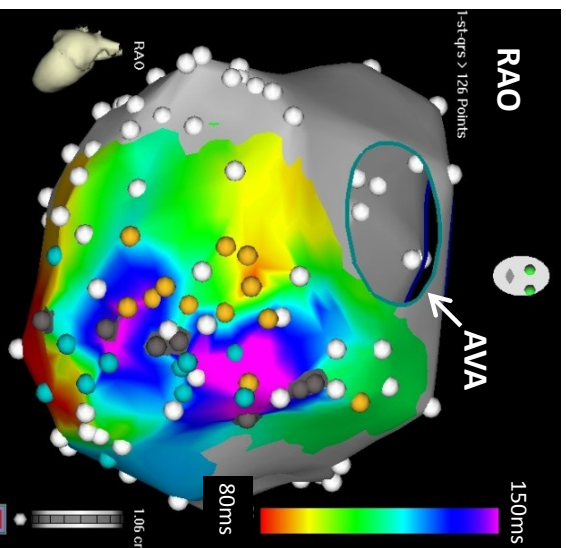
● Pace map 1

● Pace map 2





C



B

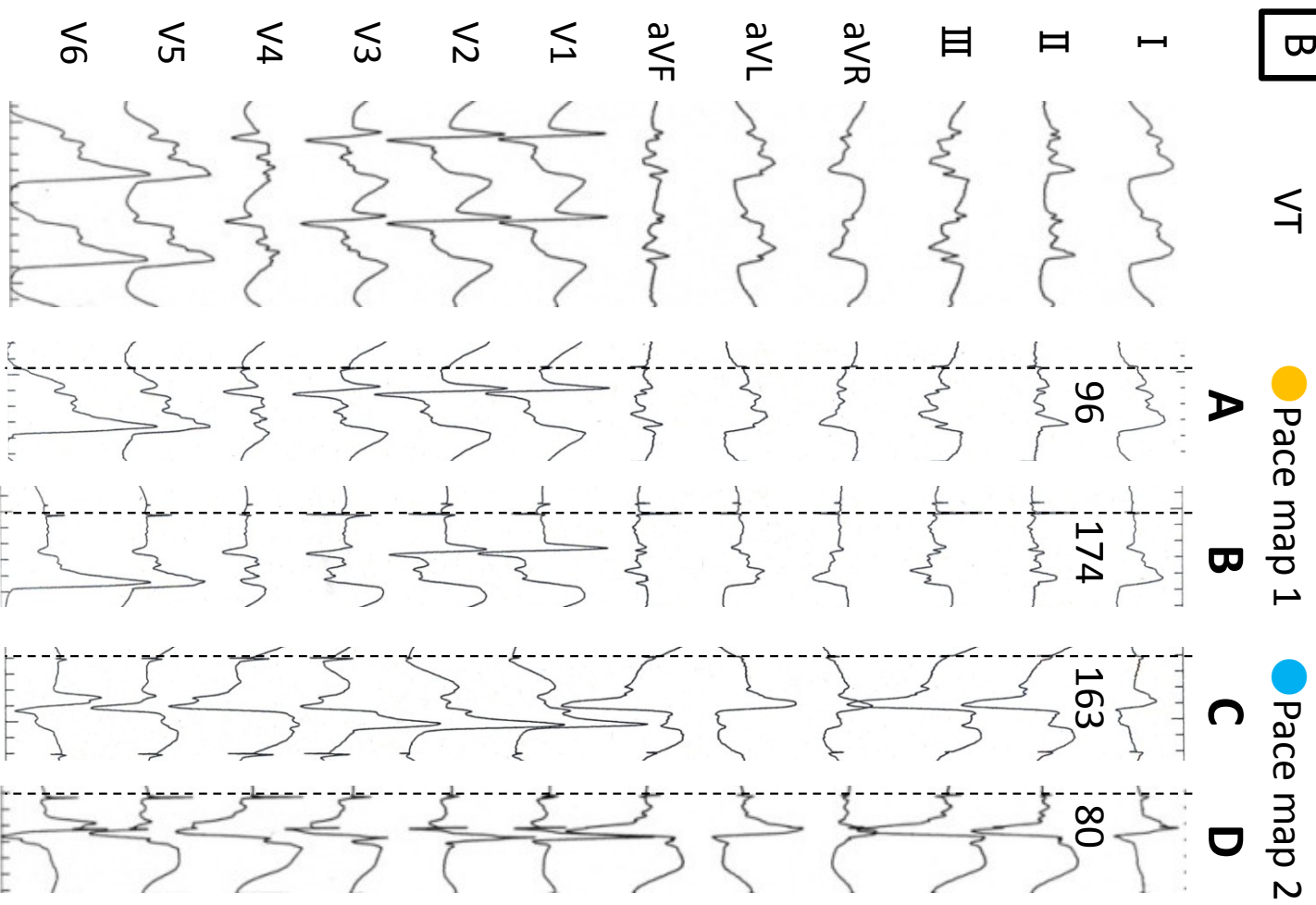
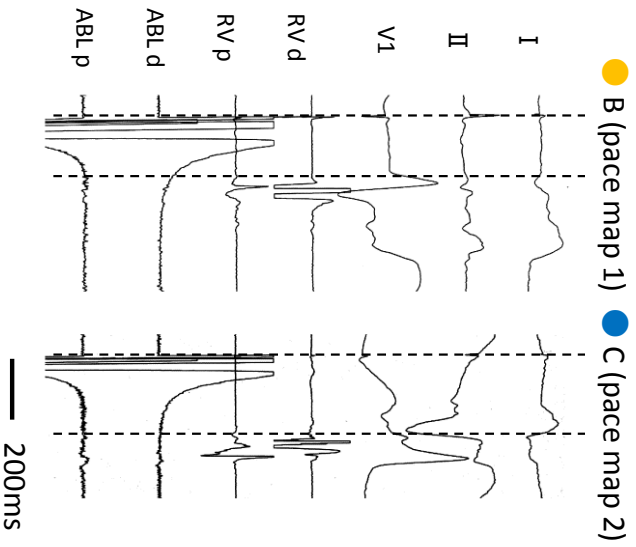


Figure 2

A



B

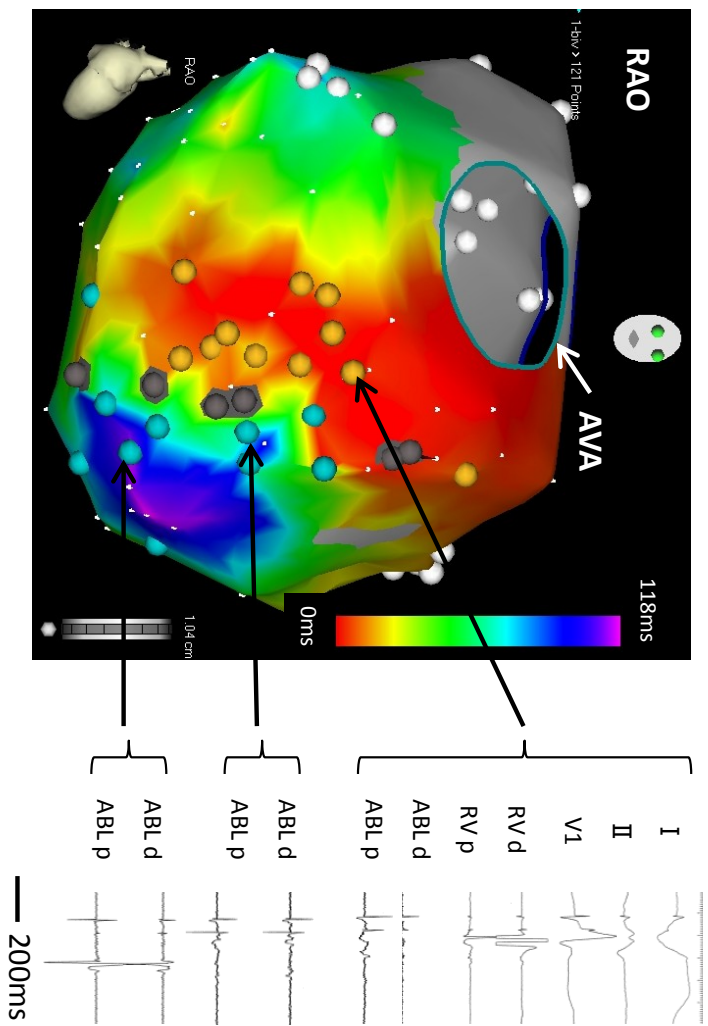


Figure 3