



Title	Three Novel IGSF1 Mutations in Four Japanese Patients With X-Linked Congenital Central Hypothyroidism
Author(s)	Nakamura, Akie; Bak, Beata; Silander, Tanya L. R.; Lam, Jessica; Hotsubo, Tomoyuki; Yorifuji, Toru; Ishizu, Katsura; Bernard, Daniel J.; Tajima, Toshihiro
Citation	Journal of clinical endocrinology & metabolism, 98(10), E1682-E1691 <a href="https://doi.org/10.1210/jc.2013-1224">https://doi.org/10.1210/jc.2013-1224</a>
Issue Date	2013-10
Doc URL	<a href="http://hdl.handle.net/2115/57864">http://hdl.handle.net/2115/57864</a>
Type	article
File Information	J Clin Endocrinol Metab_98(10)_E1682-1691.pdf



[Instructions for use](#)

## Three Novel *IGSF1* Mutations in Four Japanese Patients With X-Linked Congenital Central Hypothyroidism

Akie Nakamura, Beata Bak, Tanya L.R. Silander, Jessica Lam, Tomoyuki Hotsubo, Toru Yorifuji, Katsura Ishizu, Daniel J. Bernard, and Toshihiro Tajima

Department of Pediatrics (A.N., K.I., T.T.), Hokkaido University School of Medicine, Sapporo, Japan 060-8635; Department of Pharmacology and Therapeutics (B.B., T.L.R.S., J.L., D.J.B.), McGill University, Montreal, Canada H3G 1Y6; Department of Pediatrics (T.H.), NTT East Japan Sapporo Hospital, Sapporo, Japan 060-0061; and Department of Pediatrics (T.Y.), Osaka City Medical Center for Children, Osaka, Japan 534-0021

**Context:** Congenital central hypothyroidism (C-CH) is a rare disease. We investigated the molecular basis of unexplained C-CH in 4 Japanese boys.

**Patients and Methods:** C-CH was diagnosed by low free T<sub>4</sub> and/or T<sub>3</sub> and low basal TSH concentrations. We used whole-exome sequencing of one patient with C-CH to identify potential disease-causing mutations. Thereafter, PCR direct sequencing was performed to identify genetic defects underlying C-CH in 3 more patients. We then assessed the effects of mutations identified in the Ig superfamily, member 1 (*IGSF1*), gene on protein expression and membrane trafficking.

**Results:** All patients had congenital hypothyroidism, and 2 had definitive prolactin deficiency. Two patients were detected by neonatal screening. The other patients were diagnosed by short stature and failure to thrive. We identified a novel nonsense variant in *IGSF1* by whole-exome sequencing in patient 1, which was confirmed by PCR direct sequencing (p.R1189X). PCR direct sequencing identified the identical nonsense mutation in patient 2. Patients 3 and 4 harbored distinct missense (p.V1082E) or nonsense (p.Q645X) mutations in *IGSF1*. The mothers of patients 1, 3, and 4 were heterozygous for these mutations. The R1189X mutant, which lacks the transmembrane domain, failed to traffic to the plasma membrane. V1082E could be observed at the cell surface, but at greatly diminished levels relative to the wild-type form of the protein. The severely truncated Q645X mutant could not be detected by Western blot.

**Conclusion:** Our findings provide additional genetic evidence that loss-of-function mutations in *IGSF1* cause an X-linked form of C-CH and variable prolactin deficiency. (*J Clin Endocrinol Metab* 98: E1682–E1691, 2013)

Congenital central hypothyroidism (C-CH) is a rare condition characterized by low levels of thyroid hormones and TSH (1, 2). Individuals with this disorder are not detected by neonatal screening programs that rely exclusively on TSH concentrations, which are frequently in the low to normal range. However, C-CH has been identified by neonatal screening involving measurement of both T<sub>4</sub> or free T<sub>4</sub> (FT<sub>4</sub>) and TSH (1–4).

Mutations in transcription factor genes cause C-CH (5–10), most often in the context of combined pituitary hormone deficiency (9–12). In contrast, isolated C-CH is a rare disease, caused principally by genetic defects in the TSH  $\beta$ -subunit (OMIM 188540) or the TRH receptor (OMIM 188545) (13–18). In the course of our own investigations, Sun et al (19) demonstrated that an X-linked syndrome of C-CH, variable prolactin deficiency, and

macro-orchidism is caused by loss-of-function mutations and deletions in the Ig superfamily, member 1 (*IGSF1*), gene. *IGSF1* encodes a plasma membrane Ig superfamily glycoprotein (20–22), containing 12 C2-type Ig loops, a transmembrane domain, and a short intracellular C tail (22). The protein is cotranslationally cleaved such that only the C-terminal domain, containing 7 Ig loops, reaches the plasma membrane (22). Human *IGSF1* and murine *Igsf1* mRNAs are highly expressed in Rathke's pouch and in adult pituitary gland and testis (19). *IGSF1* protein is expressed in murine thyrotropes, somatotropes, and lactotropes (19).

In this study, we describe 3 novel *IGSF1* mutations in 4 Japanese boys with C-CH from 4 unrelated families.

## Patients and Methods

### Neonatal screening for congenital hypothyroidism and serum thyroid hormone levels

Approximately 10 000 infants are born annually in Sapporo, Japan; almost all are subject to neonatal screening for congenital hypothyroidism (CH). The screening method and the frequency of C-CH in Sapporo have been described (3, 23).

### Patients

We analyzed a Japanese boy with C-CH (patient 1) by whole-exome sequencing. After the identification of a novel *IGSF1* variant, we recruited an additional 3 C-CH Japanese boys from unrelated families and analyzed *IGSF1* by PCR direct sequencing. Two patients (patients 1 and 3) were detected by neonatal screening for CH. Their clinical characteristics and endocrine findings are summarized in Table 1.

Serum TSH and prolactin concentrations were determined in response to exogenous TRH (5  $\mu$ g/kg). GH provocative tests were performed using insulin (0.1 IU/kg) or GHRH (1  $\mu$ g/kg). Serum LH and FSH concentrations were determined in response to GnRH (2  $\mu$ g/kg).

Our institutional ethics committee approved the study, and the patients' parents provided written informed consent.

### Target selection and sequencing

Exome sequencing was conducted on patient 1. Genomic DNA was extracted from whole blood using a NucleoSpin Blood Genomic DNA kit (Takara), sheared into approximately 150- to 200-bp fragments, and used to make a library for multiplexed paired-end sequencing (Illumina). The constructed library was hybridized to biotinylated cRNA oligonucleotide baits from the SureSelect Human All Exon 50Mb Kit (Agilent Technologies) for exome capture. Targets were sequenced on an Illumina HiSeq2000 platform in paired-end 101-bp configuration.

### Mapping and single nucleotide variation (SNV)/Indel calling

Adapter sequences and low-quality bases were removed by Cutadapt (version 1.1). After quality control, reads were mapped to the reference human genome (hg19) using BWA (version

0.5.9). Mapping results were corrected using Picard (version 1.49) to remove duplicates and GATK (version 1.1–31) for local alignment and quality score recalibration. SNV and Indel calls were performed with multisample calling using GATK and filtered to coordinates with VQS passed and genotype quality score  $\geq 30$ . Annotations of SNVs and Indels were based on dbSNP135, CCDS (NCBI, November 2011), RefSeq (UCSC Genome Browser, November 2011), Encode (UCSC Genome Browser, version 7), and 1000 Genomes (October 2011). Variants were further filtered according to the following criteria: 1) genotype call existed in all of the 5 samples at the detected position; 2) predicted to cause frameshift, nonsense, read-through, missense, deletion, insertion, or insertion-deletion; 3) located outside the Segmental Duplications region (UCSC Genome Browser, November 2011); and 4) located outside the Simple Tandem Repeats region (UCSC Genome Browser, November 2011).

### Sequence analysis of *IGSF1*

Genomic DNA was extracted from patients 2 to 4 and the mothers of patients 1, 3, and 4 as described above for patient 1. Exon and exon-intron boundaries of *IGSF1* were amplified from genomic DNA by PCR using primers reported previously (19). PCR products were sequenced directly with an ABI 373A automated fluorescent sequencer (PE Applied Biosystems).

### In vitro analysis of mutant *IGSF1*

#### Constructs

The human Myc-*IGSF1*-3xHA expression construct was from Dr Peter Scheiffele (Biozentrum, University of Basel, Switzerland). The *IGSF1*-C-terminal domain (CTD) antibody epitope therein was modified using the QuikChange site-directed mutagenesis (Stratagene) to match that of the murine protein to facilitate detection with the antimurine *IGSF1*-CTD polyclonal antibody (22). The p.V1082E, p.R1189X, and p.Q645X mutations were introduced into the construct using the QuikChange method and the primers in Table 2. The constructs were verified by DNA sequencing (McGill University and Genome Québec Innovation Centre).

#### Cell culture and transfections

For Western blotting and cell surface biotinylation, HEK293 cells were seeded in 6-well plates, grown until 80% confluent, and transfected with 200 ng expression vector using Lipofectamine 2000 (Invitrogen) following the manufacturer's instructions. For immunofluorescence, HEK293 cells were seeded on glass coverslips at 50 000 cells per well and transfected with 100 ng expression vector. For Northern blotting, HEK293 cells were seeded in 10-cm dishes and transfected when 70% confluent with 4  $\mu$ g of the indicated expression constructs.

#### Deglycosylation and Western blotting

Whole-cell protein extracts were prepared from transfected HEK293 cells 24 hours after transfection using RIPA buffer (150 mM NaCl, 50 mM NaF, 10 mM NaPO<sub>4</sub>, 2 mM EDTA, 1% Nonidet P-40, 1% sodium deoxycholate, 0.1% sodium dodecyl sulfate [SDS]) with protease inhibitors (Roche). Protein lysates were deglycosylated using peptide-N-glycosidase F (PNGaseF) and endoglycosidase H (EndoH) (New England Biolabs) according to the manufacturer's instructions (2 hours at 37°C). The

**Table 1.** Endocrinological Findings and *IGSF1* Mutations in 4 Japanese Patients With C-CH<sup>a</sup>

	Patient				
	1	1 (second test)	2	3	4
Age at diagnosis	5 d (screening)		4 y	5 d (screening)	21 d
Symptoms	None		Short stature (−3.8 SD)	None	Failure to thrive, constipation
Blood FT <sub>4</sub> at MS, ng/dL <sup>b</sup>	0.68		ND	0.79	ND
Blood TSH at MS, μU/mL	1.2		Normal	2.7	Normal
FT <sub>4</sub> at referral, ng/dL	0.57 <sup>c</sup> (22 d)		0.76 <sup>d</sup> (4 y)	0.52 <sup>c</sup> (24 d)	0.78 <sup>c</sup> (21 d)
FT <sub>3</sub> at referral, pg/mL	3.60 <sup>c</sup> (22 d)		2.35 <sup>d</sup> (4 y)	1.96 <sup>c</sup> (24 d)	3.82 <sup>c</sup> (21 d)
TSH at referral	2.7 <sup>c</sup> (22 d)		2.35 <sup>d</sup> (4 y)	3.5 <sup>c</sup> (24 d)	<0.01 <sup>c</sup> (21 d)
PRL, ng/mL <sup>e</sup> (age at test)	3.5 (6 y)	1.7 (11 y)	0.99 (4 y)	86.2 (24 d)	3.1 (7 mo)
TSH levels after TRH stimulation (age at test)					
Basal	12.67	0.02	3.98	7.95	ND
Peak	50.89	0.05 (11 y)	6.72 (4 y)	23.47	
120 min	22.15 (6 y)			15.5 (24 d)	
FT <sub>4</sub> levels after TRH test					
Basal	0.69	0.40	ND	ND	ND
120 min	0.82	0.38			
PRL levels after TRH stimulation (age at test)					
Basal	3.5	1.7	0.99	86.2	ND
Peak	21.5 (6 y)	10.3 (11 y)	1.52	131.8 (24 d)	
GH, ng/mL (stimulus)					
Basal	0.35		0.36	ND	ND
Peak	20.1 (by GHRH)		0.82 (by ITT)		
LH, mIU/mL <sup>f</sup> (age at test)					
Basal	0.05	0.06	0.33	0.31 (4 mo)	0.43 (7 mo)
Peak	2.6 (5 y)	3.1 (11 y)	8.48 (4 y)		
FSH, mIU/mL <sup>f</sup> (age at test)					
Basal	1.6	2.0	2.42	4.29 (4 mo)	2.47 (7 mo)
Peak	19.8 (5 y)	17.4 (11 y)	10.9 (4 y)		
Mutations of <i>IGSF1</i>	p.R1189X		p.R1189X	p.V1082E	p.Q645X
Mother	Carrier		ND	Carrier	Carrier

Abbreviations: MS, mass screening; ITT, insulin tolerance test; ND, not determined; PRL, prolactin.

<sup>a</sup> The conversion factors to the SI unit are as follows: FT<sub>4</sub>, 12.87 (pmol/L); TSH, 1.0 (mIU/L); FT<sub>3</sub>, 1.536 (pmol/L); PRL, 1.0 (μg/L); GH, 1.0 (μg/L); LH, 1.0 (IU/L); and FSH, 1.0 (IU/L).

<sup>b</sup> Cutoff level of FT<sub>4</sub> at neonatal screening was <1.0 ng/dL.

<sup>c</sup> Normal range for this age, FT<sub>4</sub>, 1.40–1.74 ng/dL, FT<sub>3</sub>, 3.5–4.9 pg/mL, TSH, 0.30–3.50 μU/mL.

<sup>d</sup> Normal range for this age: FT<sub>4</sub>, 1.09–1.55 ng/dL; FT<sub>3</sub>, 3.9–5.1 pg/mL; TSH, 0.012–4.89 μU/mL.

<sup>e</sup> Normal range for 5-year-old, 1.6–14.8 ng/mL; normal range for 12-year-old, 1.3–10.8 ng/mL.

<sup>f</sup> Normal range for LH for <10-year-old, 0.02–0.15 (basal) and 1.70–3.77 (peak); for >10-year-old, 0.04–0.25 (basal) and 2.03–11.8 (peak) mIU/mL. Normal range for FSH for <10-year-old, 0.38–0.1.11 (basal) and 0.95–3.57 (peak); for >10-year-old, 4.38–9.48 (basal) and 5.69–16.6 (peak) mIU/mL.

proteins were denatured at 100°C for 5 minutes in Laemmli buffer containing 2% 2-mercaptoethanol and resolved by SDS-PAGE on 8% Tris-glycine gels. The proteins were transferred to nitrocellulose membranes (25 V, 1.5 hours), the membranes blocked with 5% milk in 0.05% Tween 20 in Tris-buffered saline (TBST), and incubated overnight at 4°C in a 1:10 000 dilution of mouse antihuman influenza hemagglutinin (HA) antibody

(H9658; Sigma) or a 1:1000 dilution of rabbit anti-IGSF1-CTD antibody in blocking buffer. The next day, membranes were washed 3 times for 15 minutes each in TBST and incubated with goat antimouse or goat antirabbit horseradish peroxidase-conjugated secondary antibody (Bio-Rad; 1:3000 in blocking buffer) for 1 hour at room temperature. The membranes were washed 3 times for 15 minutes each in TBST, followed by incu-

**Table 2.** Mutagenesis Primers

Mutation	Forward Primer (5'–3')	Reverse Primer (5'–3')
c.3245T→A, p.V1082E	tggtcccatgaggccctggcg	cgccaggggctccatggggacca
c.3565C→T, p.R1189X	cacccttcagtgctgaggaccctgccc	ggcaggggtcctcagcactgaagggtg
c.1933C→T, p.Q645X	cggcctcagagtaggtccgggctg	cagcccggactactctgaggccgg

bation in ECL Plus reagent (PerkinElmer) and then exposed to x-ray film (GE Healthcare).

### Cell immunofluorescence

Transfected HEK293 cells grown on glass coverslips in 24-well plates were subjected to immunofluorescence as previously described (19).

### Cell surface biotinylation and immunoprecipitation

Transfected HEK293 cells grown in 6-well plates were subjected to cell surface biotinylation as previously described (19).

### Northern blotting

RNA was extracted from HEK293 cells approximately 24 hours after transfection using Trizol. Twenty micrograms of each RNA were resolved on formaldehyde-MOPS [3-*N*-morpholino]propanesulfonic acid] gels as previously described (24). RNA was transferred overnight with 20× saline-sodium citrate (SSC) to nylon membranes (Hybon-N+; Amersham Biosciences). The membranes were sequentially hybridized overnight at 42°C with [<sup>32</sup>P]dCTP-labeled (3000 Ci/mmol, 10 mCi/mL; PerkinElmer) cDNA probes corresponding to exons 18 to 20 of murine *Igsf1* or murine *Rpl19* (the same probes as in Sun et al [19]) in 50% formamide, 5× SSC, 1× Denhardt's, 20mM NaPO<sub>4</sub> (pH 6.8), 1% SDS, 5% dextran sulfate, and 100 μg/mL denatured salmon sperm DNA. Membranes were washed twice for 30 minutes each in 2× SSC/0.1% SDS at room temperature and at 65°C and then exposed to x-ray film.

## Patient reports

### Patient 1

Patient 1, now a 12-year-old Japanese boy, was born after 39 weeks gestation by normal vaginal delivery in Sapporo City and was the third child of nonconsanguineous, healthy parents. There was no family history of thyroid disease. His birth weight was 3530 g, and his length was 51.0 cm. Neonatal mass screening for CH showed blood TSH of 1.2 μU/mL and FT<sub>4</sub> of 0.68 ng/dL at 5 days of age. On the basis of these results, a second blood filter paper sample was taken at 14 days, the results of which were as follows: TSH 1.5 μU/mL and FT<sub>4</sub> 0.47 ng/dL, indicating CH. He was referred to our hospital at 22 days. At that time, he showed no symptoms; however, bilateral femoral epiphyses were absent by x-ray examination. His serum thyroid function was: TSH 2.7 μU/mL, FT<sub>4</sub> 0.57 ng/dL, FT<sub>3</sub> 3.60 pg/mL (normal range for this age, TSH 0.30–3.50 μU/mL, FT<sub>4</sub> 1.40–1.74 ng/dL, and FT<sub>3</sub> 3.5–4.9 pg/mL, respectively). As he was confirmed to have CH, levothyroxine was initiated. At the age of 6 years, he underwent <sup>123</sup>I scintigraphy after levothyroxine treatment was discontinued for 1 month, and his thyroid and pituitary function were evaluated. The scintigraph was normal, and uptake was 34% at 24 hours. Serum TSH exhibited a high peak and delayed decrease in response to TRH stimulation (basal 12.67 μU/mL, peak 50.89 μU/mL at 30 minutes, and 22.15 μU/mL at 120 minutes). The serum prolactin response was normal (from 3.5–21.5 ng/mL). Basal FT<sub>4</sub> and FT<sub>3</sub> were 0.69 ng/dL and 1.41 pg/mL, respectively (normal range for this age, FT<sub>4</sub> 1.09–1.55 ng/dL and FT<sub>3</sub> 3.9–5.1 pg/mL, respectively). Serum FT<sub>4</sub> increased after TSH stimulation (to 0.82 ng/dL at 120 minutes). A GnRH test showed a normal response of LH and FSH for his age (LH, 0.05–2.6 mIU/mL and FSH 1.6–19.8 mIU/mL). Brain magnetic resonance

imaging (MRI) showed normal findings, including the hypothalamic-pituitary region. At 12 years of age, his height was 140.5 cm (−0.91 SD for a normal Japanese boy), his weight was 37.1 kg (−0.40 SD for a normal Japanese boy), and his body mass index was 18.9 (+0.34 SD for a normal Japanese boy) (25). His bilateral testicular sizes were 3 mL, and pubic hair was Tanner stage 1. As shown in Table 1, in response to GnRH provocation, LH remained low, which corresponds to the result expected at prepubertal age (basal LH 0.06 mIU/mL, peak LH 3.1 mIU/mL, basal FSH 2.0 mIU/mL, and peak FSH 17.4 mIU/mL). These findings indicated that he had delayed puberty compared with normal Japanese boys. The second TRH stimulation at this time showed a low response of serum TSH.

### Patient 2

Patient 2 is now a 13-year-old Japanese boy born after 42 weeks gestation by normal vaginal delivery. His birth weight was 4000 g, and his birth height was 53.2 cm. CH screening in his area was based on TSH alone, and the result was normal. He was the first child of nonconsanguineous parents. At the age of 4 years, he was referred to the hospital because of short stature. At that time, his height was 85.5 cm (−3.9 SD for a normal Japanese boy) and his weight was 14.0 kg (−1.0 SD for a normal Japanese boy). His bone age was markedly delayed (1.6 years old by Japanese Tanner-Whitehouse 2). His serum IGF-1 was markedly low (0.64 ng/mL; normal range for this age, 29–173 ng/dL) and basal prolactin was also low (0.99 ng/mL) (Table 1). CH was evident (FT<sub>4</sub> 0.76 ng/dL and TSH 2.35 μU/mL [normal range for this age, FT<sub>4</sub> 1.09–1.55 ng/dL and TSH 0.12–4.89 μU/mL]). A TRH stimulation test showed low responses of serum TSH and prolactin (TSH, basal 3.98 μU/mL and peak 6.72 μU/mL; prolactin, basal 0.99 ng/mL and peak 1.52 ng/mL). An insulin tolerance test showed low responses of GH (0.36–0.82 ng/mL) (Table 1). A brain MRI showed a normal hypothalamic-pituitary region. Based on these findings, he was diagnosed as having GH deficiency and CH; GH and levothyroxine were initiated. At 12.9 years of age, his height was 147.1 cm (−1.4 SD for a normal Japanese boy), weight was 57.7 kg (+1.0 SD for a normal Japanese boy), and body mass index was 26.7 (+2.8 SD for a normal Japanese boy). His bilateral testicular size was 4 mL, and pubic hair was Tanner stage 1. Recent blood examination showed LH <0.2 mIU/mL, FSH 6.2 mIU/mL, and prolactin <1.0 ng/mL.

### Patient 3

Patient 3 was born in Sapporo City by normal vaginal delivery after 36 weeks gestation. There was no family history of thyroid disease. His birth weight and height were 2924 g and 45.7 cm. Neonatal screening for CH at 5 days of age was positive (blood TSH 2.7 μU/mL, FT<sub>4</sub> 0.79 pg/dL). A second blood sample was obtained at 20 days, at which time TSH was <0.5 μU/mL, and FT<sub>4</sub> was 0.52 ng/dL. At the age of 24 days, he was referred to us for endocrinological evaluation. FT<sub>4</sub> and FT<sub>3</sub> were 0.52 ng/dL and 1.96 pg/mL, respectively (normal range for this age, FT<sub>4</sub> 1.40–1.74 ng/dL and FT<sub>3</sub> 3.5–4.9 pg/mL, respectively). Brain MRI was normal. In response to TRH stimulation, serum TSH rose from 7.95 to 23.47 μU/mL at 30 minutes. At 120 minutes, serum TSH remained elevated (15.50 μU/mL). TRH also stimulated serum prolactin, from 86.2 to 131.8 ng/mL. Based on these findings, he was diagnosed with CH, and levothyroxine treatment was started. He is currently 1.3 years old, and his

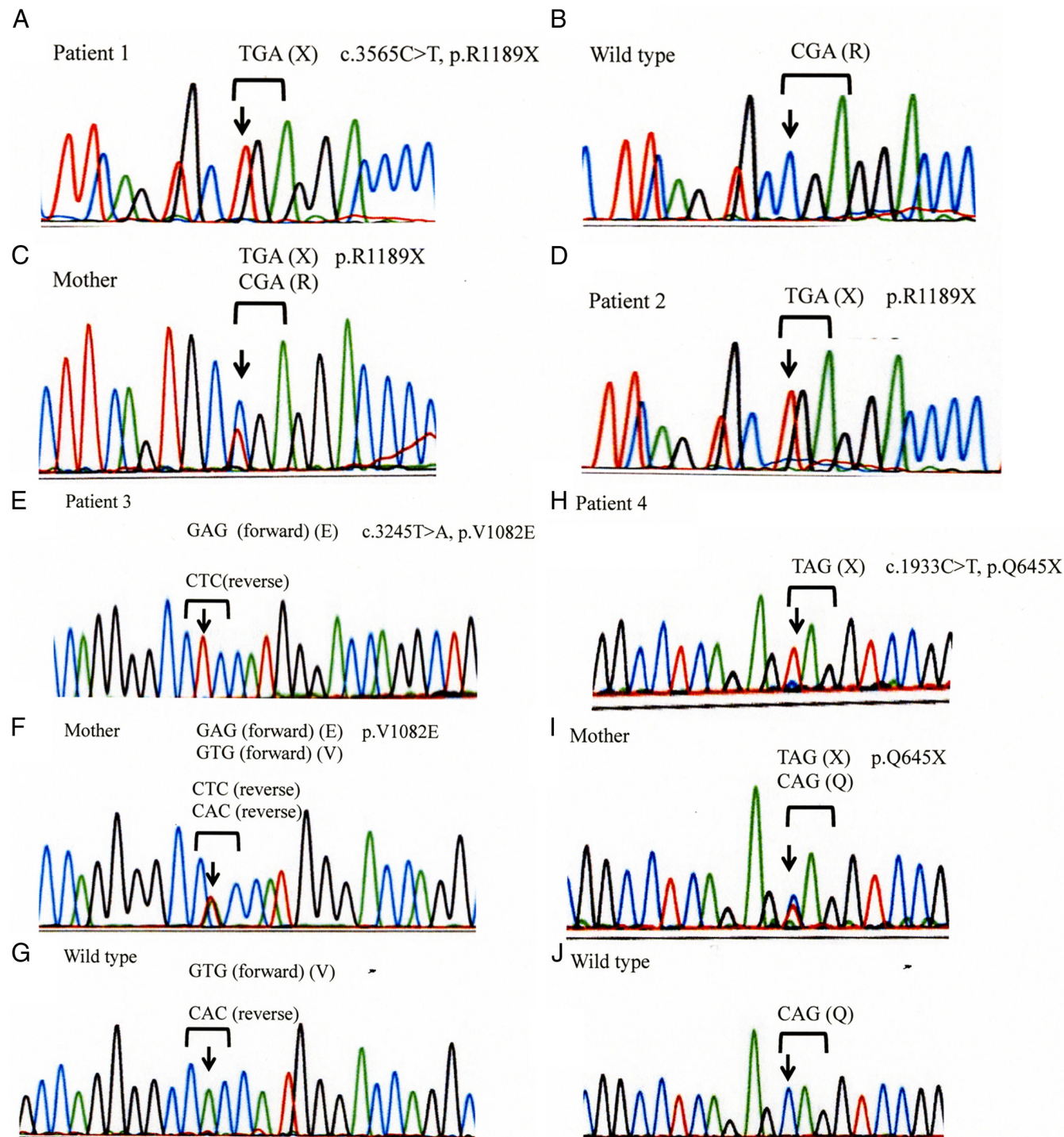


developmental milestones are within the normal range. His bilateral testicular size is 1 mL.

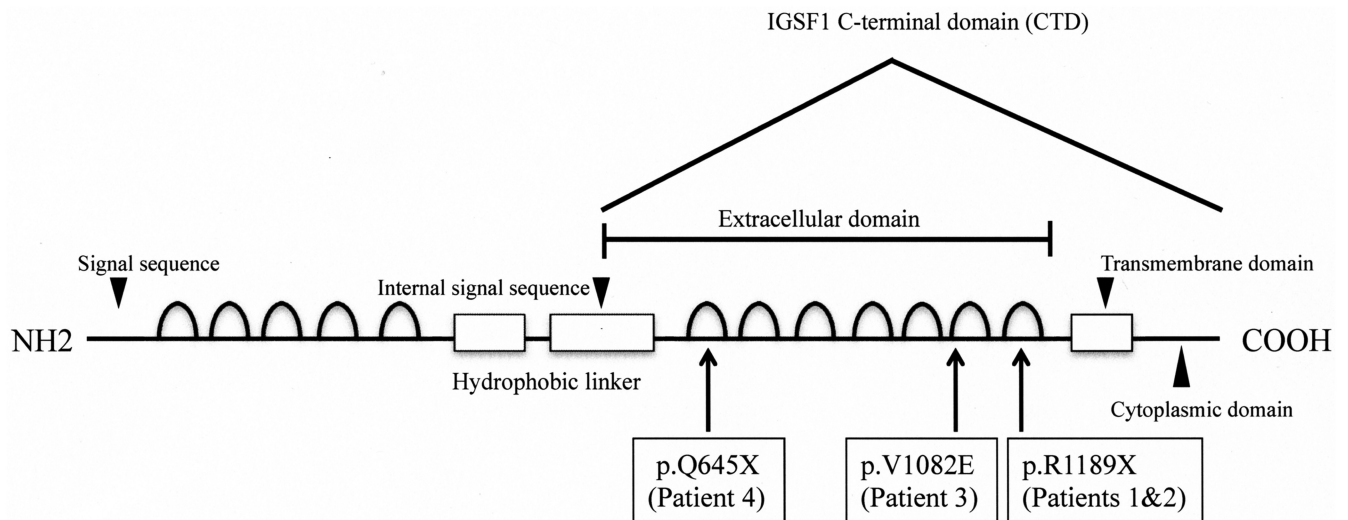
**Patient 4**

The patient was born by normal vaginal delivery after 40 weeks gestation. His birth weight and height were 4510 g and

53.6 cm. CH screening in his area was based on TSH alone, and the result was normal. There was no family history of thyroid disease. At 21 days, he showed failure to thrive and constipation. At this time, his serum TSH was  $<0.01 \mu\text{U/mL}$ ,  $\text{FT}_4$  was 0.78 ng/dL, and  $\text{FT}_3$  was 3.82 pg/mL. He was suspected of having CH, and levothyroxine was started. MRI showed that the brain and



**Figure 1.** *IGSF1* mutations in patients 1, 2, 3, and 4. A, Patient 1 had the mutation c.3565C→T (p.R1189X) in *IGSF1*. B, A chromatograph showing the corresponding sequence in a control sample. C, Patient 1’s mother was heterozygous for the c.3565C→T (p.R1189X) mutation. D, Patient 2 had an identical mutation to patient 1. E, Patient 3 had a missense mutation (c.3245T→A, p.V1082E) in *IGSF1*. The chromatograph presented is from the reverse (antisense) strand. F, Patient 3’s mother was heterozygous for this mutation. G, A chromatograph showing the corresponding sequence in a control sample. H, patient 4 harbored a nonsense mutation (c.1933 C→T, p.Q645X) in *IGSF1*. I, His mother was heterozygous for this mutation. J, A chromatograph showing the corresponding sequence in a control sample.



**Figure 2.** Schematic representation of the IGSF1 protein domain structure and the relative locations of mutations identified in this study.

hypothalamic-pituitary regions were normal. Since initiation of levothyroxine, symptoms have disappeared and he has grown well. At the age of 7 months, he was referred to a pediatric endocrinologist for follow-up. At that time, endocrine examination demonstrated low normal serum prolactin (3.1 ng/mL; normal range for this age, 2.0–19.6 ng/mL) and normal LH and FSH levels (LH 0.43 mIU/mL and FSH 2.47 mIU/mL, respectively). He is currently 1.6 years old, and his growth and developmental milestones are within normal ranges. His bilateral testicular size is 1 mL.

## Results

Whole-exome sequencing of DNA from patient 1 identified many nonsynonymous variants, but only 1 hemizygous mutation (c.3565C→T, p.R1189X) in the Xq25-linked *IGSF1* gene. We suspected that this may explain his TSH concentrations, prolactin deficiency, and low responses of LH and FSH for his age, because the region of Xq25 in which *IGSF1* is located was previously implicated in pituitary hormone deficiency (19, 26, 27). Furthermore, this base change was not identified in 200 normal Japanese control alleles. Sanger sequencing confirmed the presence of the mutation (Figure 1A). The corresponding sequence from a control subject is shown for reference (Figure 1B). The boy's mother was heterozygous for the c.3565C→T mutation (Figure 1C), indicative of X-linked recessive inheritance. We therefore considered this nonsense mutation as a candidate cause of his C-CH.

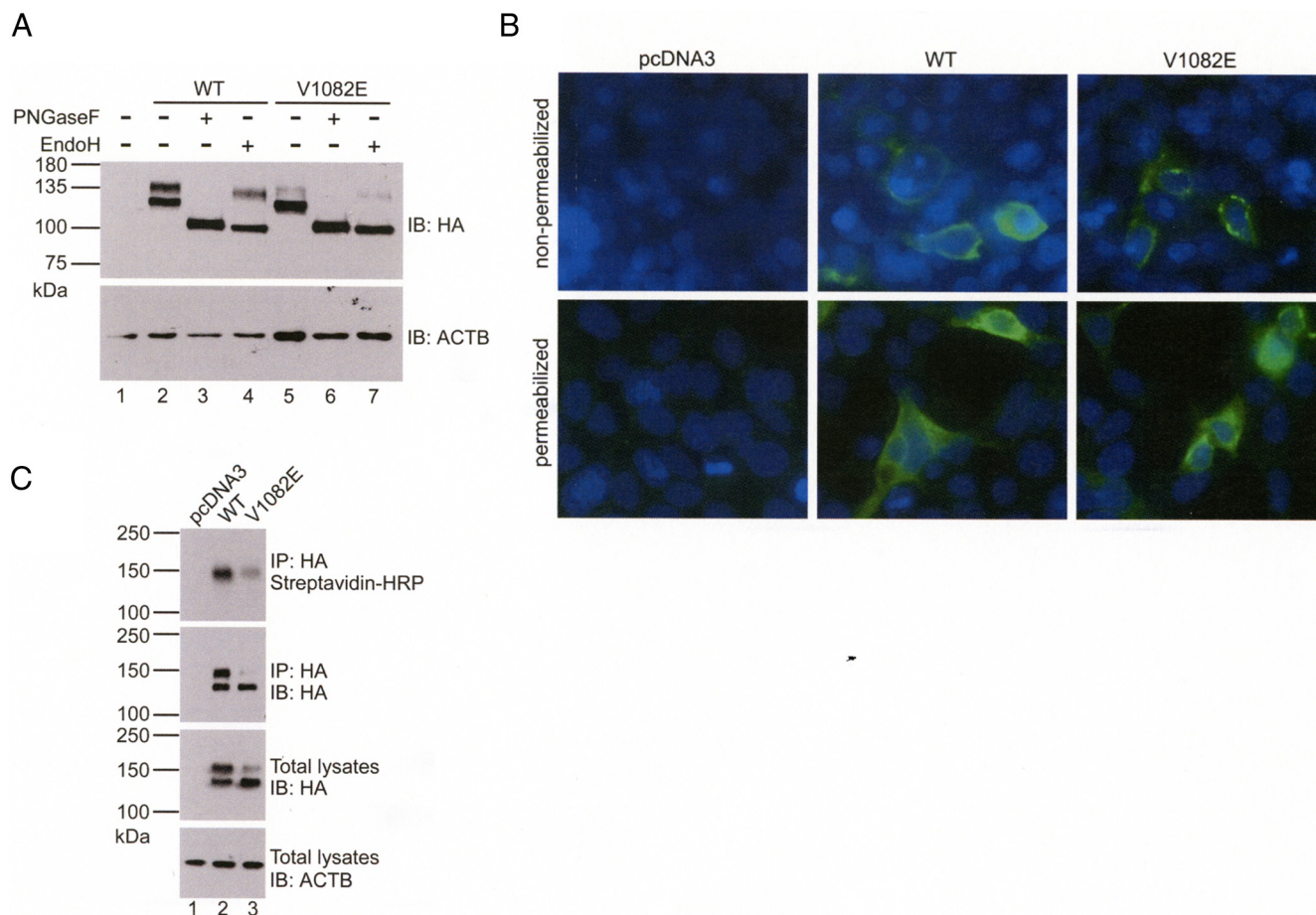
We analyzed 3 more Japanese boys with C-CH by PCR direct sequencing. Patient 2, who has no known relationship to patient 1, nonetheless harbored the identical *IGSF1* mutation (c.3565C→T, p.R1189X) (Figure 1D). His mother declined genetic analysis. Patient 3, who was also detected by neonatal screening, had a different, missense, mutation (c.3245T→A, p.V1082E), again in

*IGSF1* (Figure 1E). His mother was heterozygous for the mutation (Figure 1F), whereas it was absent in 200 normal Japanese alleles (e.g., Figure 1G). Further sequence analysis in patient 4 identified yet another base change, c.1933C→T, in *IGSF1* (Figure 1H), generating a premature stop codon (p.Q645X). In the course of our investigations, Sun et al (19) described 10 *IGSF1* mutations or whole-gene deletions in males with C-CH, macro-orchidism, and variable prolactin deficiency. None of the 3 mutations we identified matched those described in Sun et al. However, similar to their observations, our mutations clustered in the 3' part of the gene, which encodes the CTD of the IGSF1 protein (Figure 2).

We next examined whether the 3 mutations might be pathogenic. When introduced into a human IGSF1 expression vector, the V1082E mutation impaired protein maturation relative to wild-type in heterologous HEK293 cells (compare the upper bands in Figure 3A, lanes 2 and 5). Most the mutant protein was EndoH-sensitive (compare lanes 4 and 7), indicating that it was retained in the endoplasmic reticulum (ER) during its biosynthesis. Although some V1082E mutant protein reached the cell surface in transfected cells (Figure 3B), it was greatly impaired in doing so compared with wild-type, as indicated by cell surface biotinylation (upper panel in Figure 3C).

A similar analysis was applied to the R1189X truncation mutant (Figure 4). Here, the mutant protein migrated as a single, EndoH-sensitive band on SDS-PAGE, again indicating ER retention (Figure 4A, compare lanes 5 and 7). Indeed, no R1189X protein could be detected at the cell membrane in intact (nonpermeabilized) cells (Figure 4B, top right panel). The Q645X mutant is predicted to generate a protein of only 63 amino acids that terminates within the first Ig loop of the CTD. IGSF1 is internally cleaved at G582-V583 by a signal peptidase-like protease





**Figure 3.** The V1082E mutation impairs protein trafficking to the plasma membrane. **A**, HEK293 cells were transfected with pcDNA3 (empty vector) or wild-type (WT) or V1082E IGSF1-1 expression vectors. Protein lysates were deglycosylated with either PNGaseF or EndoH, resolved by SDS-PAGE, and immunoblotted using an human influenza hemagglutinin (HA) antibody. **B**, HEK293 cells were transfected with the same constructs as in **A**. Expression of IGSF1-CTD was analyzed by immunofluorescence using the IGSF1-CTD antibody under nonpermeabilizing and permeabilizing conditions. Nuclei were stained with 4',6-diamidino-2-phenylindole dihydrochloride (DAPI) (blue). **C**, HEK293 cells were transfected with the same constructs as in **A**. Membrane expression of IGSF1-CTD was analyzed by cell-surface biotinylation. Abbreviations: HRP, horseradish peroxidase; IB, immunoblot; IP, immunoprecipitation; ACTB,  $\beta$ -actin.

(22). Although the epitope recognized by our CTD antibody is retained within the 63-amino-acid peptide that would be generated by a Q645X expression vector, we failed to detect the predicted 6.9-kDa protein by Western blotting in lysates from transfected cells (data not shown). However, the mRNA transcribed from the Q645X vector was comparable to that of the wild-type vector (Supplemental Figure 1, published on The Endocrine Society’s Journals Online website at <http://jcem.endojournals.org>). Therefore, impairment in the expression of this mutant appears to be posttranscriptional.

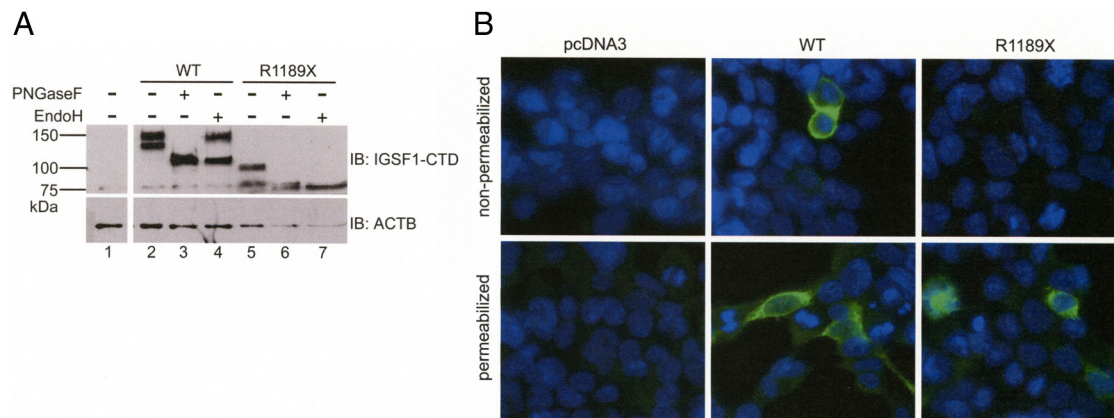
### Discussion

We identified 3 novel hemizygous *IGSF1* mutations in 4 male patients with C-CH. In addition, X-recessive inheritance of this disease was confirmed in 3 cases. Although patients 1 and 2 had identical mutations, based on inter-

views, there was no apparent relation between the two families, although this was not ruled out experimentally. Consistent with our results, Sun et al (19) recently reported that loss-of-function mutations in *IGSF1* caused X-linked C-CH and macro-orchidism in 11 unrelated European families. During the review of the present communication, we also reported an additional *IGSF1* insertion mutation in a teenage male with C-CH, but normal-sized testes (28).

Four nonsense and 4 missense or in-frame deletion mutations were described in Sun et al (19). In vitro analyses to determine the functional consequences of these mutations indicated that the encoded proteins migrated predominantly as immature glycoforms on SDS-PAGE and were largely retained in the ER, resulting in decreased membrane expression levels. Application of these analyses to the 1 missense and 2 nonsense mutations identified here revealed similar results. V1082E was severely impaired in its posttranslational modification and membrane traffick-





**Figure 4.** The R1189X mutation prevents protein trafficking to the plasma membrane. A, HEK293 cells were transfected with pcDNA3 (empty vector) or wild-type or R1189X IGSF1-1 expression vectors. Protein lysates were treated as in Figure 3A, but immunoblotted using the IGSF1-CTD antibody. B, HEK293 cells were transfected with the same constructs as in A and subjected to immunofluorescence as in Figure 3B. Abbreviations: IB, immunoblot; WT, wild-type.

ing, whereas R1189X was completely absent at the cell surface. We were unable to detect Q645X protein in transfected cells. Because the mRNA is normally expressed from a Q645X expression vector, it is likely that the 63-amino-acid IGSF1-CTD peptide generated from this variant is highly unstable and is rapidly degraded after its translation. Thus, all of the pathogenic *IGSF1* mutations associated with C-CH identified thus far cluster in the portion of the gene encoding the CTD (or are entire gene deletions) and are predicted to cause the loss of normal IGSF1 protein function and/or expression in the pituitary gland.

In Sun et al (19), 6 familial cases of C-CH in The Netherlands and 1 in Italy were identified in neonatal screening. Using a previously reported neonatal screening method in Sapporo City, based on simultaneous determination of TSH and FT<sub>4</sub> (3), we similarly identified 2 patients with CH and associated *IGSF1* mutations. One patient (patient 2) showed growth retardation, and medical examination identified both GH deficiency and CH. It is possible that CH might impair GH secretion in this patient. Alternatively, because IGSF1 is expressed in somatotropes (at least in mice), we cannot rule out a direct effect of the gene defect in these cells. In Sun et al (19), 4 patients were diagnosed with GH deficiency along with CH; GH therapy was accordingly initiated. GH secretion was reevaluated in 3 patients in young adulthood, and GH deficiency was not detected (19). Reevaluation of GH secretion is therefore needed for our patient who was diagnosed with GH deficiency.

Three of our 4 patients had low prolactin levels. In Sun et al (19), 18 of 26 cases were similarly prolactin-deficient (19). Two of our patients showed delayed puberty (the other 2 are still too young to evaluate in this regard), and their serum LH and FSH levels remained at prepubertal levels even at 12 years of age. In Sun et al (19), 10 of 11

evaluated patients showed delayed testosterone production and pubertal growth. Delayed secondary sex characteristics may therefore be one of the clinical hallmarks in patients with pathogenic *IGSF1* mutations. Moreover, Sun et al (19) reported testicular enlargement after adolescence as a defining feature of the syndrome associated with *IGSF1* mutations. Careful follow-up for pubertal development and testicular size is therefore required in our current and future patients. However, it should be noted that we observed normal testicular size in another Japanese male with C-CH and an *IGSF1* mutation (28).

A TRH stimulation test in our patient 1 at 5 years of age showed high basal and peak serum TSH, in addition to a delayed decrease at 120 minutes. In patient 3, an increased basal TSH level and delayed decrease of TSH after TRH stimulation were also observed. Sun et al demonstrated lower responses of serum TSH levels after TRH stimulation in patients with *IGSF1* defects than in age-matched controls (19). Therefore, the results of our two studies appear to diverge with respect to the effects of TRH stimulation. Several reports show that an impaired TSH response is indicative of primary pituitary disease, whereas an excessive and delayed rise in serum TSH is indicative of primary hypothalamic disease (29, 30). However, there is still controversy surrounding this differentiation (31–33). Recent studies have demonstrated overlap between patients with pituitary disturbance and those with hypothalamic disturbance in terms of the serum TSH response to TRH (32, 33). Thus, it remains plausible that TSH deficiency is caused by a pituitary defect in our patients. That said, IGSF1 is expressed in murine hypothalamus (34); therefore, C-CH patients with inactivating *IGSF1* mutations may possess both pituitary and hypothalamic defects.

A TRH test was performed twice in patient 1. Compared with the result of the first TRH test, a markedly low

response of serum TSH was observed in the second test. In *Igsf1*-knockout mice, pituitary TSH synthesis and secretion are reduced, and murine pituitary TRH receptor mRNA expression is decreased (19). It was speculated, therefore, that impaired TRH receptor signaling might be a mechanism of C-CH in *IGSF1*-deficient patients. TRH signaling through the TRH receptor is important for normal proliferation of thyrotropes (35, 36). A diminished TSH response to TRH stimulation with age in our patient 1 may be caused by failure of thyrotropes to proliferate normally during postnatal development. This may indicate that *IGSF1*, together with the TRH signaling system, is involved in thyrotrope proliferation and differentiation, in addition to TSH secretion. The physiological role of *IGSF1* in TRH-mediated TSH secretion requires more investigation.

To date, the exact prevalence of C-CH caused by *IGSF1* defects has not determined. We screened 83 232 neonates and identified 6 patients with C-CH from 2000 to 2004, as reported previously (3). Among these 6 patients, only 1 (patient 1 in the present study) had an *IGSF1* mutation, and the remaining 5 patients were diagnosed as having congenital pituitary abnormalities or Prader-Willi syndrome (3). Therefore, the frequency of *IGSF1* mutations may be rare, but more study is required to clarify the prevalence of C-CH caused by *IGSF1* defects.

In conclusion, we identified 3 novel loss-of-function mutations in the *IGSF1* gene as the likely cause of C-CH in 4 Japanese patients.

## Acknowledgments

Address all correspondence and requests for reprints to: Akie Nakamura, MD, Department of Pediatrics, Hokkaido University School of Medicine, North 15 West 7, Kitaku, Sapporo, Japan 060-8635. E-mail: akieda@med.hokudai.ac.jp.

The Natural Sciences and Engineering Research Council of Canada provided a studentship (to B.B.) and operating grant support (341801-07 to D.J.B.).

Disclosure Summary: The authors have nothing to disclose.

## References

- Hanna CE, Krainz PL, Skeels MR, Miyahira RS, Sesser DE, LaFranchi SH. Detection of congenital hypopituitary hypothyroidism: ten-year experience in the Northwest Regional Screening Program. *J Pediatr*. 1986;109:959–964.
- van Tijn DA, de Vijlder JJ, Verbeeten B Jr, Verkerk PH, Vulsma T. Neonatal detection of congenital hypothyroidism of central origin. *J Clin Endocrinol Metab*. 2005;90:3350–3359.
- Fujiwara F, Fujikura K, Okuhara K, et al. Central congenital hypothyroidism detected by neonatal screening in Sapporo, Japan (2000–2004) its prevalence and clinical characteristics. *Clin Pediatr Endocrinol*. 2008;17:65–69.
- Adachi M, Soneda A, Asakura Y, Muroya K, Yamagami Y, Hira-hara F. Mass screening of newborns for congenital hypothyroidism of central origin by free thyroxine measurement of blood samples on filter paper. *Eur J Endocrinol*. 2012;166:829–838.
- Tatsumi K, Miyai K, Notomi T, et al. Cretinism with combined hormone deficiency caused by a mutation in the PIT1 gene. *Nat Genet*. 1992;1:56–58.
- Pfäffle RW, DiMattia GE, Parks JS, et al. Mutation of the POU-specific domain of Pit-1 and hypopituitarism without pituitary hypoplasia. *Science*. 1992;257:1118–1121.
- Wu W, Cogan JD, Pfäffle RW, et al. Mutations in PROP1 cause familial combined pituitary hormone deficiency. *Nat Genet*. 1998;18:147–149.
- Netchine I, Sobrier ML, Krude H, et al. Mutations in LHX3 result in a new syndrome revealed by combined pituitary hormone deficiency. *Nat Genet*. 2000;25:182–186.
- Tajima T, Hattori T, Nakajima T, et al. Sporadic heterozygous frameshift mutation of HESX1 causing pituitary and optic nerve hypoplasia and combined pituitary hormone deficiency in a Japanese patient. *J Clin Endocrinol Metab*. 2003;88:45–50.
- Tajima T, Yorifuji T, Ishizu K, Fujieda K. A novel mutation (V101A) of the LHX4 gene in a Japanese patient with combined pituitary hormone deficiency. *Exp Clin Endocrinol Diabetes*. 2010;118:405–409.
- Reynaud R, Saveanu A, Barlier A, Enjalbert A, Brue T. Pituitary hormone deficiencies due to transcription factor gene alterations. *Growth Horm IGF Res*. 2004;14:442–448.
- Romero CJ, Pine-Twaddell E, Radovick S. Novel mutations associated with combined pituitary hormone deficiency. *J Mol Endocrinol*. 2011;46:R93–R102.
- Miyai K, Azukizawa M, Kumahara Y. Familial isolated thyrotropin deficiency with cretinism. *N Engl J Med*. 1971;285:1043–1048.
- Hayashizaki Y, Hiraoka Y, Endo Y, Miyai K, Matsubara K. Thyroid-stimulating hormone (TSH) deficiency caused by a single base substitution in the CAGYC region of the beta-subunit. *EMBO J*. 1989;8:2291–2296.
- Dacou-Voutetakis C, Feltquate DM, Drakopoulou M, Kourides IA, Dracopoli NC. Familial hypothyroidism caused by a nonsense mutation in the thyroid-stimulating hormone beta-subunit gene. *Am J Hum Genet*. 1990;46:988–993.
- Doeker BM, Pfäffle RW, Pohienz J, Andier W. Congenital central hypothyroidism due to a homozygous mutation in the thyrotropin beta-subunit gene follows an autosomal recessive inheritance. *J Clin Endocrinol Metab*. 1998;83:1762–1765.
- Collu R, Tang J, Castagné J, et al. A novel mechanism for isolated central hypothyroidism: inactivating mutations in the thyrotropin-releasing hormone receptor gene. *J Clin Endocrinol Metab*. 1997;82:1561–1565.
- Bonomi M, Busnelli M, Beck-Peccoz P, et al. A family with complete resistance to thyrotropin-releasing hormone. *N Engl J Med*. 2009;360:731–734.
- Sun Y, Bak B, Schoenmakers N, et al. Loss-of-function mutations in *IGSF1* cause an X-linked syndrome of central hypothyroidism and testicular enlargement. *Nat Genet*. 2012;44:1375–1381.
- Mazzarella R, Pengue G, Jones J, Jones C, Schlessinger D. Cloning and expression of an immunoglobulin superfamily gene (*IGSF1*) in Xq25. *Genomics*. 1998;48:157–162.
- Bernard DJ, Burns KH, Haupt B, Matzuk MM, Woodruff TK. Normal reproductive function in *InhBP/p120*-deficient mice. *Mol Cell Biol*. 2003;23:4882–4891.
- Robakis T, Bak B, Lin SH, Bernard DJ, Scheiffele P. An internal signal sequence directs intramembrane proteolysis of a cellular immunoglobulin domain protein. *J Biol Chem*. 2008;283:36369–36376.
- Tajima T, Jo W, Fujikura K, Fukushi M, Fujieda K. Elevated free thyroxine levels detected by a neonatal screening system. *Pediatr Res*. 2009;66:312–316.
- Bernard DJ, Woodruff TK. Inhibin binding protein in rats: alter-

- native transcripts and regulation in the pituitary across the estrous cycle. *Mol Endocrinol*. 2001;15:654–667.
25. Inokuchi M, Matsuo N, Anzo M, Hasegawa T. Body mass index reference values (mean and SD) for Japanese children. *Acta Paediatr*. 2007;96:1674–1676.
  26. Phelan PD, Connelly J, Martin FI, Wettenhall HN. X-linked recessive hypopituitarism. *Birth Defects Orig Artic Ser*. 1971;7:24–27.
  27. Lagerström-Fermér M, Sundvall M, Johnsen E, et al. X-linked recessive panhypopituitarism associated with a regional duplication in Xq25–q26. *Am J Hum Genet*. 1997;60:910–916.
  28. Tajima T, Nakamura A, Ishizu K. A novel mutation of *IGSF1* in a Japanese patient of congenital central hypothyroidism without macrorchidism. *Endocr J*. 2013;60:245–249.
  29. Costom BH, Grumbach MM, Kaplan SL. Effect of thyrotropin-releasing factor on serum thyroid-stimulating hormone. An approach to distinguishing hypothalamic from pituitary forms of idiopathic hypopituitary dwarfism. *J Clin Invest*. 1971;50:2219–2225.
  30. Faglia G, Beck-Peccoz P, Ferrari C, et al. Plasma thyrotropin response to thyrotropin-releasing hormone in patients with pituitary and hypothalamic disorders. *J Clin Endocrinol Metab*. 1973;37:595–601.
  31. Crofton PM, Tepper LA, Kelnar CJ. An evaluation of the thyrotropin-releasing hormone stimulation test in paediatric clinical practice. *Horm Res*. 2008;69:53–59.
  32. Mehta A, Hindmarsh PC, Stanhope RG, Brain CE, Preece MA, Dattani MT. Is the thyrotropin-releasing hormone test necessary in the diagnosis of central hypothyroidism in children. *J Clin Endocrinol Metab*. 2003;88:5696–5703.
  33. van Tijn DA, de Vijlder JJ, Vulsma T. Role of the thyrotropin-releasing hormone stimulation test in diagnosis of congenital central hypothyroidism in infants. *J Clin Endocrinol Metab*. 2008;93:410–419.
  34. Bischof JM, Wevrick R. Genome-wide analysis of gene transcription in the hypothalamus. *Physiol Genomics*. 2005;22:191–196.
  35. Malaguti A, Della Casa C, Castorina S, et al. Molecular mechanisms for pituitary thyrotroph cell growth. *J Endocrinol Invest*. 2004;27(6 Suppl):151–167.
  36. Shibusawa N, Yamada M, Hirato J, Monden T, Satoh T, Mori M. Requirement of thyrotropin-releasing hormone for the postnatal functions of pituitary thyrotrophs: ontogeny study of congenital tertiary hypothyroidism in mice. *Mol Endocrinol*. 2000;14:137–146.



Make sure your patients are getting the best medical care. Learn more about The Endocrine Society's *The Evaluation of Thyroid Nodules Practice Improvement Module(PIM)*.

[www.endoselfassessment.org](http://www.endoselfassessment.org)