



Title	Bone Augmentation Using Novel Unidirectional Porous Hydroxyapatite with Bone Morphogenetic Protein-2 on Rat Skull
Author(s)	Kashiwazaki, Haruhiko; Harada, Naoki; Akazawa, Toshiyuki; Kabir, Md. Arafat; Minamida, Yasuhito; Murata, Masaru
Citation	Journal of hard tissue biology, 22(3), 337-341 https://doi.org/10.2485/jhtb.22.337
Issue Date	2013-07
Doc URL	http://hdl.handle.net/2115/53343
Type	article
File Information	62533_pdf.pdf



[Instructions for use](#)

Original

Bone Augmentation Using Novel Unidirectional Porous Hydroxyapatite with Bone Morphogenetic Protein-2 on Rat Skull

Haruhiko Kashiwazaki¹⁾, Naoki Harada¹⁾, Toshiyuki Akazawa²⁾, Md. Arifat Kabir³⁾,
Yasuhito Minamida³⁾ and Masaru Murata³⁾

¹⁾ Department of Oral Health Science, Graduate School of Dental Medicine, Hokkaido University, Sapporo, Japan

²⁾ Industrial Research Institute, Industrial Technology Research Development, Hokkaido Research Organization, Sapporo, Japan

³⁾ Department of Oral and Maxillofacial Surgery, School of Dentistry, Health Sciences University of Hokkaido, Tobetsu-Cho, Japan
(Accepted for publication, May 15, 2013)

Abstract: Unidirectional porous hydroxyapatite (UDPHAp) is a material whose microstructure consists of cross-sectional oval pores with a pore diameter in the range of 100-300 μm that penetrate through the material. UDPHAp has proven suitable for osteogenesis and angiogenesis. The present study was designed to evaluate the osteogenic effect of a newly developed UDPHAp as a carrier of recombinant human bone morphogenetic protein-2 (rhBMP-2) in a rat onlay graft model. UDPHAp was implanted beneath the calvarial periosteum of rats to simulate alveolar bone augmentation in a clinical condition. At 2 weeks after implantation, UDPHAp with rhBMP-2 resulted in active bone formation, and the augmented bone was connected directly with the original bone, whereas commercialized porous hydroxyapatite (PHAp) with rhBMP-2 showed little bone formation. These results suggest that UDPHAp in this model is suitable for onlay graft and is an effective biomaterial for the rhBMP-2 delivery system.

Key words: Unidirectional porous hydroxyapatite (UDPHAp), Onlay graft, Bone augmentation, Recombinant human bone morphogenetic protein-2 (rhBMP-2)

Introduction

Porous hydroxyapatite (HAp) has been used as a bone substitute because of its osteoconductivity and safety. On the other hand, it may have risks of instability and crack after implantation *in vivo* for lack of bone ongrowth and ingrowth to the material. The interconnective porous structure is one of the important factors for bone ingrowth to the material¹⁾. Iwasashi et al. reported that a novel unidirectional porous hydroxyapatite (UDPHAp) whose microstructure consists of cross-sectional oval pores (diameter, 100-300 μm) that penetrate through the material; UDPHAp has a porosity of 75% and the initial compressive strength of approximately 14 MPa, parallel to the unidirectional pores. Furthermore, it possesses good osteoconductivity, as shown by its implantation in the femoral intramedullary cavity and in the tibial cortical defect in a rabbit²⁻⁴⁾.

One of the important points in clinical use of biomaterials is that they must be not only biocompatible but also stable

immediately after they are implanted. To facilitate bone formation and shorten the time for bone union, recombinant human bone morphogenetic proteins (rhBMPs) are available, which are known to induce ectopic bone formation in skeletal and nonskeletal sites⁵⁻⁸⁾. The present study was designed to evaluate osteogenic effect of a newly developed UDPHAp as a carrier of rhBMP-2 in the rat onlay graft model.

Materials and Methods

An UDPHAp with 75% porosity obtained from Kuraray Co., Ltd. was used in this study. Digital microscopic (DM) and scanning electron microscopic (SEM) photographs of UDPHAp were taken to observe the morphology and microstructure (Figure 1). The UDPHAp was cut into pieces of 3 x 3 x 3 mm in size and soaked in a rhBMP-2 solution (0 and 5 μg of rhBMP-2 in 20 μl of phosphate-buffered saline solution; PEPROTECH Co., London) in a sterilized culture dish. UDPHAp with or without 5 μg of rhBMP-2 were implanted beneath the calvarial periosteum of 10-week-old SD rats to assess bone development (4 animals each) according to previous reports⁹⁻¹³⁾. The direction of the unidirectional pore was perpendicular to the parietal bone. At 2

correspondence to: Dr. Haruhiko Kashiwazaki, Department of Oral Health Science, Graduate School of Dental Medicine, Hokkaido University, Kita-13 Nishi-7, Kita-ku, Sapporo, Hokkaido, 060-8586 Japan; Tel: +81-11-706-4321; Fax: +81-11-706-4582; E-mail: kashi@den.hokudai.ac.jp

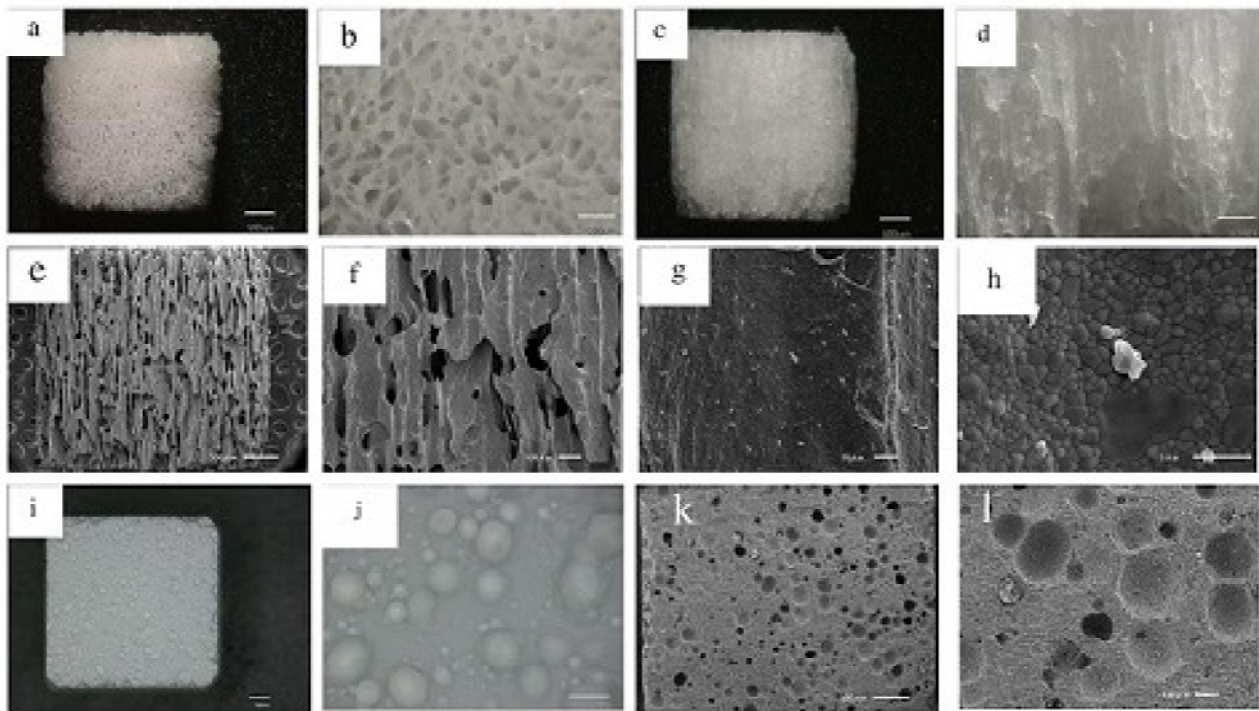


Figure 1. Digital microscopic (DM) and scanning electron microscopic (SEM) photographs of UDPHAp and PHAp. Unidirectional pores toward the vertical direction and some interconnection toward the horizontal direction are observed.

a: DM image of UDPHAp (horizontal dimension); b: DM image of UDPHAp (horizontal dimension); c: DM image of UDPHAp (vertical dimension); d: DM image of UDPHAp (vertical dimension); e: SEM image of UDPHAp; f: SEM image of UDPHAp; g: SEM image of UDPHAp; h: SEM image of UDPHAp; i: DM image of PHAp; j: Higher magnification of i; k: SEM image of PHAp; l: Higher magnification of k. Scale bar = 500 μm (in a, c, e, i, k) or 200 μm (in b,d, j) or 100 μm (in f, l) or 10 μm (in g) or 5 μm (in h).

and 4 weeks after operation, the implant and the skull were removed *en bloc* without stripping away the soft tissues and fixed in 10% neutral buffered formalin, dehydrated and cleared with graded alcohols and xylol, and embedded in paraffin wax. Sectioned at 5 μm thickness with a microtome, the paraffin wax-embedded specimens were stained with hematoxylin and eosin (H & E). Histological observation and recording were carried out with an optical microscope (Olympus BX-51, Tokyo, Japan). All procedures followed the International Guidelines for Experiments on Animals. This project was approved by the Ethical Committee for Animals Care at Hokkaido University.

For comparison, we purchased a commercialized porous hydroxyapatite (PHAp; Boneceram PTM; Sumitomo Pharmaceuticals Co., Ltd., Funabashi, Japan), which has been used in orthopedic or dental surgery. The pore size ranged from 50 to 300 μm , the mean porosity was 48 %, and the bending strength was 8 Mpa, according to the manufacturer's information.

Results

Microstructure

Fig. 1 shows DM and SEM photographs of UDPHAp and PHAp. UDPHAp had tubular micropores unidirectionally aligned to the ice growth direction. The cross sections perpendicular to

the pore axis showed spindle-shaped pores in random directions. PHAp had microscopic random pores with spherical shape, and the pore size was widely distributed in the range 50-300 μm .

Histological findings

In the UDPHAp without rhBMP-2, dense fibrous tissue was observed in most of the pores of UDPHAp at 2 weeks (Fig. 2a, b). Osteogenesis was not observed in the pore of the UDPHAp. Neither bone nor cartilage was found inside the UDPHAp without rhBMP-2. In the UDPHAp with rhBMP-2, new bone formation was observed in some pores close to the host parietal bone at 2 weeks (Fig. 2c). The augmented bone was connected directly with the original bone (Fig. 2d). At 4 weeks postoperatively active osteogenesis was observed and newly bone formation increased (Fig. 2e). The interconnected trabecular bone and bone marrow were found inside it. Numerous osteocytes and new blood vessel growth were observed in an immature trabecular bone with continuous osteoblasts lining (Fig. 2f). Cartilage was not found in any of the specimens. For the PHAp with rhBMP-2 at 2 weeks postoperatively, new bone formation was observed only on the surface of the material (Fig. 2g, h). No invasion of bone tissue or vessels could be detected in any of the pores inside the material.

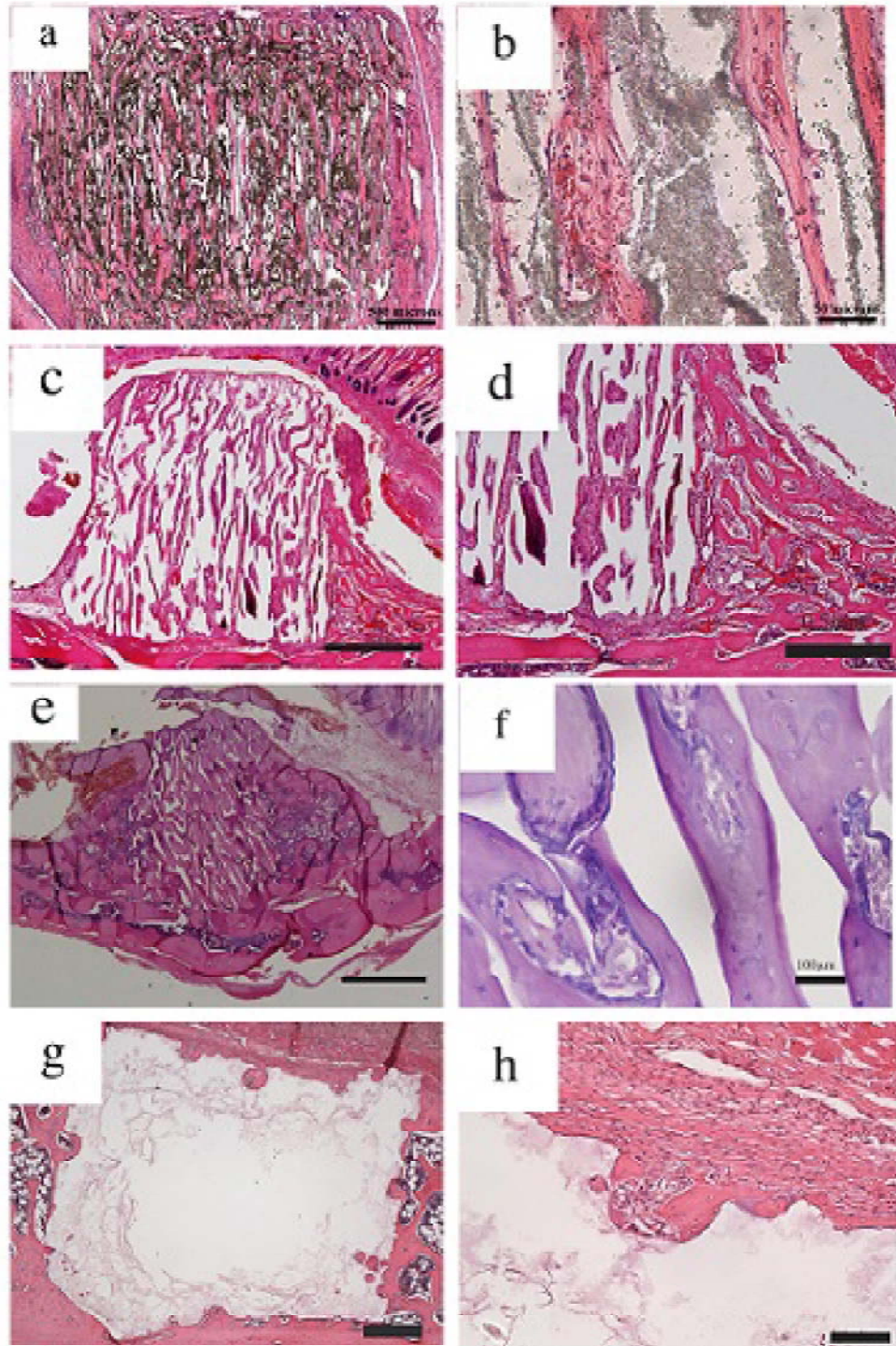


Figure 2. HE-stained histological sections of UDPHAP and PHAP implanted beneath the calvarial periosteum of SD rats. a: UDPHAP alone at 2 weeks. UDPHAP caused little inflammation, and dense fibrous tissue was observed in most of the pores of UDPHAP; b: Higher magnification of a. Neither bone nor cartilage was found in any of UDPHAP without rhBMP-2; c: UDPHAP with rhBMP-2 at 2 weeks. New bone formation occurred in some pores close to the host parietal bone; d: Higher magnification of c. The augmented bone was connected directly with the original bone; e: UDPHAP with rhBMP-2 at 4 weeks. Active osteogenesis was observed in most of the pores of UDPHAP; f: Higher magnification of e. Numerous osteocytes and new blood vessel growth were observed in an immature trabecular bone with continuous osteoblasts lining; g: PHAP with rhBMP-2 at 2 weeks. New bone formation was observed only on the surface of the material; h: Higher magnification of g. No invasion of bone tissue or vessels could be detected in any of the pores inside the material. Scale bar = 1 mm (in c, e) or 500 μ m (in a, d, g) or 100 μ m (in f, h) or 50 μ m (in b).

Discussion

Previously, Iwasashi et al. reported good osteogenesis after implantation of UDPHAp in tibial cortical bone defects of rabbits and dogs²⁻⁴). In the result section, we speculate whether UDPHAp would be suitable for the treatment of alveolar bone augmentation by the onlay graft with rhBMP-2. In the present study, UDPHAp was implanted beneath the calvarial periosteum of rats to simulate alveolar bone augmentation in a clinical condition. The present study demonstrated that UDPHAp with rhBMP-2 resulted in active bone formation under the periosteum and the augmented bone was connected directly with the original bone, whereas PHAp with rhBMP-2 resulted in little bone formation at 2 weeks after implantation. The distinct differences between the two implants indicates that the rhBMP-2 increased bone ingrowth into UDPHAp and facilitated its replacement by new bone and marrow. These results indicate that the structure of UDPHAp might offer an environment that does not inhibit invasions of rhBMP-2-target cells and capillaries and, thus, contributes to osteoblast differentiation in the presence of rhBMP-2.

A previous research suggested that favorable porous diameters for cell migration are over 50 μm , and over 100-300 μm for angiogenesis¹⁴⁻¹⁶). UDPHAp is close to these qualifications, which contribute to osteogenic cell's migration and osteogenesis at 2 weeks after implantation. Furthermore, angiogenesis was observed at 2 weeks, this may contribute to nutrition and to subsequent osteogenesis.

To be implanted on bone, i.e. onlay bone graft, it is necessary for materials to have sufficient mechanical strength corresponding to the pressure from the periosteum, mucosa, or skin. Fujita et al.¹⁷) reported that the mechanical strength of materials implanted on bone influences osteogenesis in comparison with the pore size. In this study, the compressive strength of UDPHAp was approximately 1.5 times as great as that of PHAp, and the amount of newly formed bone with UDPHAp was greater than that with PHAp, despite their having almost the same pore size. These results suggest that UDPHAp in this model is suitable for onlay graft because of its excellent invasiveness of rhBMP-2-target cells and mechanical strength. In conclusion, the onlay graft of UDPHAp with rhBMP-2 should be biologically a novel effective system for bone augmentation.

Acknowledgements

This work was supported in part by Grant-in-Aid for Scientific Research (C) from the Ministry of Education, Culture, Sports, Science, and Technology of Japan (No. 21592489).

References

1. Tamai N, Myoui A, Tomita T, Nakase T, Ochi T and Yoshikawa H. Novel hydroxyapatite ceramics with an interconnective porous structure exhibit superior osteoconduction *in vivo*. J

- Biomed Mater Res 59: 110-117, 2002
2. Iwasashi M, Sakane M, Suetsugu Y and Ochiai N. Bone regeneration at cortical bone defect with unidirectional porous hydroxyapatite *in vivo*. Key Eng Mater 396-398: 11-14, 2009
3. Suetsugu Y, Hotta Y, Iwasashi M, Sakane M, Kikuchi M, Ikoma T, Higaki T, Ochiai N and Tanaka J. Structural and tissue reaction properties of novel hydroxyapatite ceramics with unidirectional pores. Key Eng Mater 330-332: 1003-1006, 2007
4. Watanabe A, Sakane M, Funayama T, Iwasashi M, Kanamori A and Ochiai N. Nobel unidirectional porous hydroxyapatite used as a bone substitute for tibial wedge osteotomy in canines. Biomater Res 14: 6-9, 2010
5. Urist MR. Bone: Formation by autoinduction. Science 150: 893-899, 1965
6. Hollinger JO, Uludag H and Winn SR. Sustained release emphasizing recombinant human bone morphogenetic protein-2. Adv Drug Deliv Rev 31: 303-318, 1998
7. Groeneveld E H J and Burger E H. Bone morphogenetic proteins in human bone regeneration. Eur J Endocrinol 142: 9-21, 2000
8. Akazawa T, Murata M, Sasaki T, Tazaki J, Kobayashi M, Kanno T, Nakamura K and Arisue M. Biodegradation and bioabsorption innovation of the functionally graded bovine bone-originated apatite with blood permeability. J Biomed Mater Res A76: 44-51, 2006
9. Ono I, Ohura T, Murata M, Yamaguchi H, Ohnuma Y and Kuboki Y. A study on bone induction in hydroxyapatite combined with bone morphogenetic protein. Plast Reconstr Surg 90: 870-879, 1992
10. Murata M, Huang BZ, Shibata T, Imai S, Nagai N and Arisue M. Bone augmentation by recombinant human BMP-2 and collagen on adult rat parietal bone. Int J Oral Maxillofac Surg 28: 232-237, 1999
11. Murata M, Maki F, Sato D, Shibata T and Arisue M. Bone augmentation by onlay implant using recombinant human BMP-2 and collagen on adult skull without periosteum. Clin Oral Implant Res 11: 289-295, 2000
12. Murata M, Sato D, Qin CL, Nagai N, Kuboki Y and Arisue M. Combination of recombinant human BMP-2 and atelocollagen implant with cortical perforations for bone augmentation. J Hard Tissue Biol 10: 1-6, 2001
13. Kashiwazaki H, Yamaguchi K, Harada N, Akazawa T, Murata M, Iizuka T, Ikoma T, Tanaka J and Inoue N. In vivo evaluation of a novel chitosan/HAp composite biomaterial as a carrier of rhBMP-2. J Hard Tissue Biol 19: 181-186, 2010
14. Kuboki Y, Takita H, Kobayashi D, Tsuruga E, Inoue M, Murata M, Nagai N, Dohi Y and Ohgushi H. BMP-induced

- osteogenesis on the surface of hydroxyapatite with geometrically feasible and nonfeasible structures: Topology of osteogenesis. *J Biomed Mater Res* 39: 190-199, 1998
15. Lu JX, Frautre B, Anselme K, Hardouin P, Gallur A, Descamps M and Thierry B. Role of interconnections in porous bioceramics on bone recolonization *in vitro* and *in vivo*. *J Mater Sci Mater Med* 10: 111-120, 1999
 16. Karageorgiou V and Kaplan D. Porosity of 3D biomaterial scaffolds and osteogenesis. *Biomaterials* 26: 5474-5491, 2005
 17. Fujita R, Yokoyama A, Kawasaki T and Kohgo T. Bone augmentation osteogenesis using hydroxyapatite and beta-tricalcium phosphate blocks. *J Oral Maxillofac Surg* 61: 1045-1053, 2003