



Title	Thrombosis in the Pulmonary Vein Stump After Left Upper Lobectomy as a Possible Cause of Cerebral Infarction
Author(s)	Ohtaka, Kazuto; Hida, Yasuhiro; Kaga, Kichizo; Kato, Tatsuya; Muto, Jun; Nakada-Kubota, Reiko; Sasaki, Tsukasa; Matsui, Yoshiro
Citation	Annals of Thoracic Surgery, 95(6), 1924-1929 https://doi.org/10.1016/j.athoracsur.2013.03.005
Issue Date	2013-06
Doc URL	http://hdl.handle.net/2115/53024
Type	article (author version)
File Information	OhtakaPV_ATSunmarked.pdf



[Instructions for use](#)

Thrombosis in the pulmonary vein stump after left upper lobectomy as a possible cause of cerebral infarction

Running head: Pulmonary vein thrombosis after lobectomy

Kazuto Ohtaka, MD,* Yasuhiro Hida, MD, PhD,* Kichizo Kaga, MD, PhD,* Tatsuya Kato, MD, PhD,* Jun Muto,
MD*, Reiko Nakada-Kubota, MD, PhD,* Tsukasa Sasaki, RT, ** Yoshiro Matsui, MD, PhD*

*Department of Cardiovascular and Thoracic Surgery, Hokkaido University Graduate School of Medicine,

Sapporo, Hokkaido, Japan

**Department of Radiology, Hokkaido University Hospital, Sapporo, Hokkaido, Japan

Address for correspondence

Yasuhiro Hida, MD, PhD

Department of Cardiovascular and Thoracic Surgery, Hokkaido University Graduate School of Medicine, North 15,

West 7, Kita-ku, Sapporo, Hokkaido 060-8638, Japan. Fax: +81 11 706 7612. Tel: +81 11 706 6042. E-mail:

yhida@med.hokudai.ac.jp

(1849 words)

ABSTRACT

OBJECTIVE: Thrombus in the stump of the pulmonary vein (PV) is not a well-known complication after lung resection, and it has the potential to cause embolism to vital organs. To clarify the frequency, risk factors, and cause of this complication, a retrospective clinical study of patients who underwent lobectomy was performed.

METHOD: The subjects were 193 patients with primary lung cancer who underwent lobectomy from 2005 to 2011 and contrast-enhanced chest CT within 2 years after lobectomy. Contrast-enhanced CT was retrospectively interpreted to check for thrombus in the PV stump.

RESULTS: The operative procedures were 65 right upper lobectomies, 14 right middle lobectomies, 40 right lower lobectomies, 52 left upper lobectomies (LUL), and 22 left lower lobectomies. Of the 193 patients, 7 (3.6%) developed thrombus in the PV stump after lobectomy. All patients with thrombus had undergone LUL, and 13.5% of those who had undergone LUL developed thrombus. Univariate analyses revealed that LUL and operation time were significant risk factors, and that adjuvant chemotherapy was marginally significant. It appears that thrombus may be attributable to the length of the PV stump. Measurement of the length of the PV stump using three-dimensional CT images of the PV revealed that the stump of the left superior PV was longer than the others.

CONCLUSION: Thrombus in the PV stump occurred in 13.5% of cases after LUL. These findings suggest that contrast-enhanced CT should be recommended for patients after LUL to help identify patients with a high risk for thromboembolism.

(246 words)

KEY WORDS: lobectomy, thrombus, pulmonary vein, cerebral infarction, contrast-enhanced CT

INTRODUCTION

We have previously reported 3 cases of patients who were found to have thrombus in the stump of the pulmonary vein (PV) after left upper lobectomy (LUL) [1], one of whom developed lethal cerebral infarction. There have been only 6 reported cases with a thrombus in the PV stump after lobectomy [2-4].

A thrombus in the PV stump is very rare [1-4], and it is likely to result in a bad outcome because it can easily enter the systemic circulation and cause embolism to vital organs such as the brain, kidney, and intestines. Of the previously reported 6 cases including ours, 4 developed embolism, 1 developed cerebral infarction, 1 developed renal infarction, 1 developed a transient ischemic heart attack, and 1 developed acute obstruction of the external iliac artery [1-4]. Although there was no radiological proof of the thrombus in the PV stump, there have been 3 reported cases that developed embolism to other vital organs in the early postoperative period after lobectomy [5,6].

All 9 previously reported cases with proven or suspected thrombus in the PV stump occurred after LUL [1-5]. Therefore, we hypothesized that LUL is a risk factor for thrombus in the PV stump and embolism to vital organs after lung resection. Since there have been no clinical studies of thrombus in the PV stump after lung resection, its frequency, risk factors, and possible causes remain to be elucidated. To clarify these issues, the clinical data of post-lobectomy patients were reviewed retrospectively.

PATIENTS AND METHODS

Patients

Of 234 consecutive patients with primary lung cancer who underwent lobectomy from July 2005 to May 2011 who were followed postoperatively at Hokkaido University Hospital, 193 who underwent contrast-enhanced

chest-CT (CECT) at least once within 2 years after lobectomy were selected for this study. The pathological staging was based on the 7th edition of the Union Internationale Contra le Cancer (UICC) staging system with the tumor-node-metastasis (TNM) classification. Our institutional review board approved this retrospective study and waived the requirement for informed consent.

Surgical resection

Two-port video-assisted thoracoscopic surgery (VATS) was performed for all cases except those with chest wall invasion, bronchial invasion, or pulmonary vessel invasion. The VATS procedure was converted to an open thoracotomy as needed. Lobectomy was performed as follows. First, the PV was divided using a linear stapler. Second, a few branches of the PA were divided either with ligations or linear staplers. Finally, the bronchus was divided using a linear stapler.

Prophylaxis for thrombosis

No perioperative or postoperative prophylactic heparin was administered, although the patient was administered graduated-compression, antiembolism stockings.

Postoperative adjuvant chemotherapy

Postoperative adjuvant chemotherapy was indicated for all patients who gave informed consent except for patients with Stage IA. Some of the patients with pT1bN0M0 stage IA were prescribed UFT for 2 postoperative years. Other patients underwent intravenous chemotherapy. The following patients who underwent chemotherapy were classified into the group without chemotherapy for the analyses: the patients who discontinued UFT within 2 months, and the patients who discontinued intravenous chemotherapy within 1 cycle.

Postoperative follow-up

The patients who underwent lobectomy returned every 3 to 6 months for measurements of serum tumor markers

and either chest CT or chest X-rays for the first 2 years, and then every 6 to 12 months for the next 3 years.

The length of the PV stump

We hypothesized that a thrombus in the left superior PV (LSPV) stump was due to a longer stump than other PV stumps. Therefore, the length of the PV stump was measured using the three-dimensionally reconstructed images of the PV after lobectomy. Thirty-eight patients who visited our hospital for postoperative follow-up from March 2010 to December 2011 and gave informed consent for use of contrast medium were selected.

The length of the PV stump was measured with the view showing the longest PV stump (Fig 1a and 1b).

Statistical Analysis

Univariate and multivariate analyses were performed using the Mann-Whitney U test or Fisher's exact test, and logistic regression analysis, respectively with Stat Flex ver.6.0 software (Artech Co., Ltd., Osaka, Japan). A p value of less than 0.05 was considered significant.

RESULTS

Frequency and risk factors for PV thrombosis

Of the 193 patients, 7 patients (3.6%) had thrombus in the PV stump. Figure 1c shows the three-dimensional image of the LSPV stump with a thrombus. All patients with thrombus had undergone LUL (7/52; 13.5%) and had normal values of D-dimer and fibrin degradation products when they were found to have the thrombus. The median postoperative period to detect the thrombus was 3 months (range, 2 - 19 months). Of the 7 patients with thrombus in the PV stump, 6 were found to have the thrombus on the first CECT after lobectomy. Six patients underwent anticoagulant therapy followed by successful disappearance of the thrombus. The other patient developed cerebral infarction on the same day as the CT that showed the thrombus was done.

Univariate analyses revealed that LUL and operation time were significantly associated with thrombus in the PV stump ($p < 0.001$ and $p = 0.045$, respectively; Table). Adjuvant chemotherapy was marginally associated with thrombus ($p = 0.054$). Multivariate analysis could not be performed for statistical reasons because all patients with thrombus underwent LUL.

The median postoperative follow-up period was 25 months (range, 4 - 75 months). Three patients developed cerebral infarction; 2 had undergone left lower lobectomy (LLL) and 1 LUL. Of these 3 patients, only the 1 patient with LUL was shown to have thrombus on CECT. The causes for cerebral infarction of the remaining 2 patients after LLL were suspected to be carotid artery plaque in 1 and unclear in 1. None of the 3 patients developed or had a history of arrhythmia.

The length of the stump of the pulmonary vein

The subjects consisted of 13 right upper lobectomies, 9 right lower lobectomies, 11 LUL, and 5 LLL patients. The LSPV stump was significantly longer (median length 1.71 cm; range, 1.15 - 2.60 cm) than the right inferior PV stump (median 0.50 cm; range, 0.31 - 0.90 cm), the right superior PV (RSPV) stump (median 0.56 cm; range, 0.21 - 1.80 cm), and the left inferior PV stump (median 0.54 cm; range, 0.39 - 1.10 cm) ($p = 0.0003$, 0.0002 , and 0.0018 , respectively; Fig 2).

DISCUSSION

In the present study, the frequency of and risk factors for thrombus in the PV stump after pulmonary lobectomy were identified for the first time. Thrombus in the PV stump after lobectomy occurred in 3.6% of patients. All patients with thrombus in the PV stump had undergone LUL, and 13.5% of patients who underwent LUL developed thrombus. Univariate analyses revealed that LUL and operative time were the risk factors for

thrombus in the PV stump. Adjuvant chemotherapy was a marginal risk factor for thrombus.

There have been some reports about the causes of PV thrombus: idiopathic, radiofrequency ablation for atrial fibrillation, pulmonary arteriovenous malformation, and pulmonary arteriovenous fistula [7-11]. These thrombi sometimes cause embolism to vital organs [8, 11]. Lung resection, lobectomy, lung torsion, and lung transplantation have previously been reported as causes of PV thrombus [12-15]. There are two types of thrombus in the PV stump after lobectomy. As in the 6 previously reported cases [1-4], one is a floating thrombus in the PV stump that could cause embolism to vital organs. This type of thrombus may be caused by stagnant blood flow in the long stump of the PV. Another type is thrombus in the stump of the RSPV branch after right upper or middle lobectomies; such a thrombus could obstruct the remaining branch of the RSPV. This thrombus has been reported in 8 cases [16-22]; it may be caused by damaged vascular endothelium and is likely to cause obstruction of the remaining branches of the RSPV rather than embolism to vital organs.

In the present study, a thrombus in the PV stump after lobectomy was detected in 3.6% of all patients and 13.5% of LUL patients. There have been only 6 case reports of PV stump thrombus so far, although it seems to have been relatively frequent after lobectomy in the present study. This might be because postoperative follow-up was mostly performed using plain chest CT rather than the CECT used in other institutes. Most guidelines for follow-up of lung cancer after curative-intent resection advocated by various organizations, including the American Society of Clinical Oncology (ASCO), the American College of Chest Physician (ACCP), the National Comprehensive Cancer Network (NCCN), and the European Society for Medical Oncology (ESMO), recommend follow-up with plain CT or without CT [23]. In our institute, postoperative follow-up had previously been performed with plain chest CT. After we found a patient who had undergone contrast-enhanced chest CT for a checkup of another disease and was incidentally found to have a thrombus in the PV stump, CECT was performed

at least once for postoperative follow-up. This might be the reason why we found more patients with thrombus than other institutes. We anticipate that more patients with thrombus in the PV stump would be found in other institutes if they carefully searched for it with CECT.

In the present study, the median postoperative period to detect a thrombus was 3 months. Most cases of thrombus in the PV stump were detected on the first CECT after lobectomy. These results suggest that thrombus in the PV stump might develop relatively soon after lobectomy. There might be some patients who had developed the thrombus in the PV stump at an early period after lobectomy but it had disappeared spontaneously before it was found. Thus, we might have underestimated the frequency of the thrombus.

It was also shown that the length of the LSPV stump was longer than the others by measuring the length of the PV stump using the three-dimensional images of the PV reconstructed from CECT images. Although there was no direct evidence to show that the length contributed to thrombus formation, stagnant blood flow in the long stump of the PV might have contributed to thrombus formation.

If the longer stump of the PV is responsible for the thrombus in the PV stump, one may argue that we should divide the LSPV in order to form a shorter stump and prevent development of such a thrombus. This could be done if the LSPV was divided in the pericardium. However, it is not practical to undertake this maneuver for all patients because of the complicated and invasive nature of the procedure. Moreover, it is premature to conclude that short stumps prevent thrombus formation.

It remains arguable whether detection of the PV thrombus and anticoagulant therapy would prevent embolism. In the present study, all patients with thrombus in the PV stump had normal values of D-dimer and fibrin degradation products when they were found to have thrombus. Therefore, blood tests would not identify high-risk patients for thrombus. To address these issues, we are accumulating evidence regarding thrombus in the PV

stump after lobectomy using CECT.

CONCLUSION

In the present study, thrombus in the PV stump after lobectomy was relatively frequent after LUL. Routine CECT should be recommended for patients after LUL to help identify patients with a high risk for thromboembolism.

Because thrombus in the PV stump may have been overlooked until now, a multicenter clinical study is needed to elucidate the frequency and causes of PV thrombus and the necessity for anticoagulant therapy.

REFERENCE

- 1) Ohtaka K, Hida Y, Kaga K, Iimura Y, Shiina N, Muto J, et al. Pulmonary vein thrombosis after video-assisted thoracoscopic left upper lobectomy. *J Thorac Cardiovasc Surg* 2012; 143: e3-5.
- 2) Nagaoka E, Yano M, Sugano T, Miyamoto T. Thrombus in the left superior pulmonary vein after left upper pulmonary lobectomy. *J Thorac Cardiovasc Surg* 2008; 135: 709-10.
- 3) Schwalm S, Ward RP, Spencer KT. Transient ischemic attack in a patient with pulmonary vein thrombosis after left upper lobectomy for squamous cell lung cancer. *J Am Soc Echocardiogr* 2004; 17: 487-8.
- 4) Seki M, Endo M, Kidani M, Kobayashi H, Sato H, Noto T. A rare case of left atrial thrombus after left upper pulmonary lobectomy [Article in Japanese]. *Nippon Kyobu Geka Gakkai Zasshi* 1989; 37: 1371-5.
- 5) Asteriou C, Barbetakis N, Efstathiou A, Kleontas A, Tsilikas C. Renal artery thrombosis following lobectomy for lung cancer. *Case Rep Oncol* 2010; 3: 208-211.
- 6) Oura H, Hirose M, Aikawa H, Ishiki M. Abdominal organ infarction encountered immediately after surgery of primary lung cancer [Article in Japanese]. *Kyobu Geka* 2005; 58: 137-42.
- 7) Alexander GR, Reddi A, Reddy D. Idiopathic pulmonary vein thrombosis: A rare cause of massive hemoptysis. *Ann Thorac Surg* 2009; 88: 281-3.
- 8) Kinsella JA, MacCarthy AJ, Kiernan TJ, Moore DP, McDermott RS, McCabe DJH. Transesophageal echocardiographically-confirmed pulmonary vein thrombosis in association with posterior circulation infarction. *Case Rep Neurol* 2010; 2: 24-31.
- 9) Yataco J, Stoller JK. Pulmonary venous thrombosis and infarction complicating pulmonary venous stenosis following radiofrequency ablation. *Respiratory Care* 2004; 49: 1525-1527.
- 10) Ghaye B, Szapiro D, Dacher JN, Rodriguez LM, Timmermans C, Devillers D, et al. Percutaneous ablation for

atrial fibrillation: the role of cross-sectional imaging. *Radiographics* 2003; 23: S19-S33.

11) Cohen R, Cabanes L, Burckel C, Duboc D, Touze E. Pulmonary arteriovenous fistula thrombosis responsible for recurrent stroke. *J Neurol Neurosurg Psychiatry* 2006; 77: 707-708.

12) Cable DG, Deschamps C, Allen MS, Miller DL, Nichols FC, Trastek VF, et al. Lobar torsion after pulmonary resection: presentation and outcome. *J Thorac Cardiovasc Surg* 2001; 122: 1091-3.

13) Apostolakis E, Koletsis EN, Panagopoulos N, Prokakis C, Dougenis D. Fatal stroke after completion pneumonectomy for torsion of left upper lobe following left lower lobectomy. *J Cardiothorac Surg* 2006; 1: 25.

14) Schulman LL, Anandarangam T, Leibowitz DW, DiTullio MR, McGregor CC, Galantowicz ME, et al. Four-year prospective study of pulmonary venous thrombosis after lung transplantation. *J Am Soc Echocardiogr* 2001; 14: 806-12.

15) Leibowitz DW, Smith CR, Michler RE, Ginsburg M, Schulman LL, McGregor CC, et al. Incidence of pulmonary vein complications after lung transplantation: A prospective transesophageal echocardiographic study. *J Am Coll Cardiol* 1994; 24: 671-675.

16) Genta PR, Ho N, Beyruti R, Takagaki TY, Terra-Filho M. Pulmonary vein thrombosis after bilobectomy and development of collateral circulation. *Thorax* 2003; 58: 550-551.

17) Hovaguimian H, Morris JF, Gately HL, Floten HS. Pulmonary vein thrombosis following bilobectomy. *Chest* 1991; 99: 1515-16.

18) Venter CP, Dannheimer IPL. Pulmonary venous thrombosis complicating lobectomy. *S Afr Med J* 1973; 47: 2339-42.

19) Burri E, Duwe J, Kull C, Glaser C, Maurer CA. Pulmonary vein thrombosis after lower lobectomy of the left lung. *J Cardiovasc Surg* 2006; 47: 609-12.

20) Gyves-Ray KM, Spizarny DL, Gross BH. Unilateral pulmonary edema due to postlobectomy pulmonary vein thrombosis. *AJR* 1987; 148: 1079-80.

21) Urschel JD. Venous thrombosis of the middle lobe after upper lobectomy. *Can Assoc Radiol J* 1993; 44: 133-4.

22) Aldana-Diaz EM, Fernandez-Torres B, Herrera-Saval JC, Toro-Ibanez D, de las Mulas-Bejar M. Unilateral postbilobectomy pulmonary edema originating from thrombosis of the pulmonary vein. *Rev Esp Anestesiol Reanim* 1996; 43: 375-8.

23) Rubins J, Unger M, Colice GL. Follow-up and Surveillance of the Lung Cancer Patient Following Curative Intent Therapy. *ACCP Evidence-Based Clinical Practice Guideline(2nd Edition)*. *Chest* 2007;132:355S-367S

Table. Univariate analyses of clinicopathological factors associated with thrombus in the PV stump

		Patients with thrombosis (n=7)	Patients without thrombosis (n=186)	P value
Age (y.o.)				
Median value (range)		68 (52-78)	67 (40-84)	0.632
Sex				
Male / Female		4 / 3	130 / 56	0.472
Brinkman index				
Median value (range)		200 (0-2160)	800 (0-4100)	0.519
Comorbidity				
	+ / -	6 / 1	120 / 66	0.247
Hypertension	+ / -	1 / 6	53 / 133	0.411
Diabetes mellitus	+ / -	0 / 7	27 / 159	0.277
Hyperlipidemia	+ / -	0 / 7	24 / 162	0.310
Cerebral infarction	+ / -	0 / 7	4 / 182	0.695
Arrhythmia	+ / -	1 / 6	6 / 180	0.124
Cardiovascular disease	+ / -	1 / 6	19 / 167	0.729
Steroids	+ / -	0 / 7	3 / 183	0.735
Operative procedure				
LUL / LLL / RU(M)L / RLL		7 / 0 / 0 / 0	45 / 22 / 80 / 39	<0.001
LUL / Others		7 / 0	45 / 141	<0.001
Operative approach				

Thoracotomy / VATS		1 / 6	40 / 146	0.647
Operative time (min.)				
Median value (range)		300 (195-493)	280 (133-548)	0.045
Blood loss (ml)				
Median value (range)		50 (0-360)	110 (0-1670)	0.351
Duration of postoperative drainage (days)				
Median value (range)		2.5 (2-4)	3 (0-18)	0.834
Postoperative hospital stay (days)				
Median value (range)		8 (7-33)	10.5 (5-132)	0.274
Postoperative complication	+ / -	1 / 6	49 / 137	0.475
Arrhythmia	+ / -	1 / 6	12 / 174	0.417
Histological type				
SCC / ADC / SQC / Other		0 / 6 / 0 / 1	7 / 106 / 53 / 20	0.348
Pathological stage				
I / II / III / IV		4 / 2 / 1 / 0	110 / 35 / 38 / 3	0.901
Adjuvant chemotherapy	+ / -	5 / 2	66 / 119	0.054

Footnotes: LUL, left upper lobectomy; LLL, left lower lobectomy; RU(M)L, right upper or middle lobectomy; RLL, right lower lobectomy; SCC, small cell carcinoma; ADC, adenocarcinoma; SQC, squamous cell carcinoma.

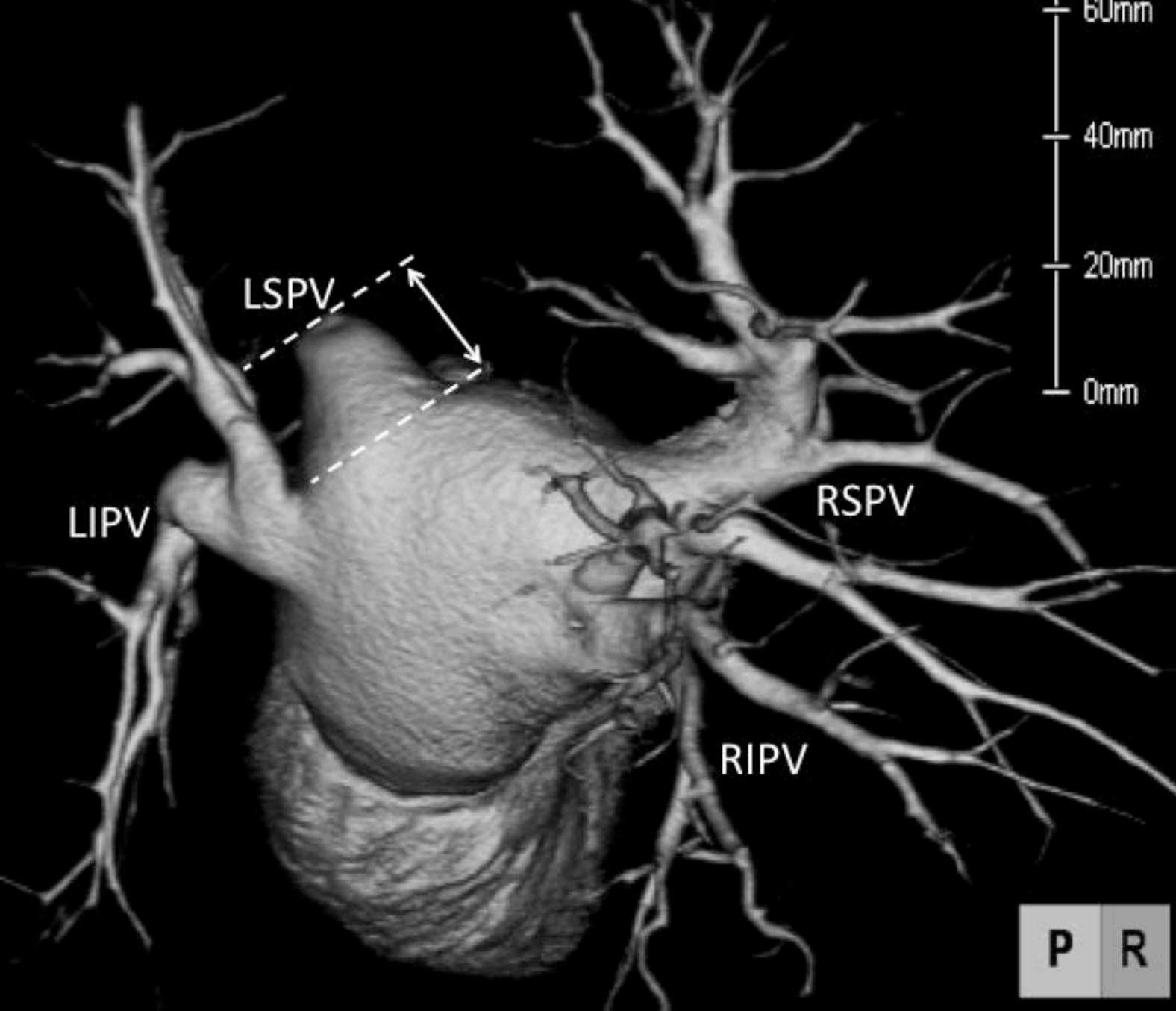
Figure legends

Figure 1. The length of the pulmonary vein (PV) stump is measured using the three-dimensional images of the PV reconstructed from contrast-enhanced CT images after lobectomy. The length of the PV stump is measured from the stump to the left atrium (a). The length of the right superior PV after right upper lobectomy is measured from the stump of the divided branch to the join point with the remaining branches (b). A white arrowhead points to a thrombus in the stump of the left upper PV (c).

LSPV, left superior pulmonary vein; LIPV, left inferior pulmonary vein; RSPV, right superior pulmonary vein; RIPV, right inferior pulmonary vein.

Figure 2. The length of the RSPV, RIPV, LSPV, and LIPV stumps. The LSPV stump is longer than the others.

LSPV, left superior pulmonary vein; LIPV, left inferior pulmonary vein; RSPV, right superior pulmonary vein; RIPV, right inferior pulmonary vein.



LIPV

LSPV

RSPV

RIPV

P

R

60mm
40mm
20mm
0mm

