



Title	Comparison of Gastric Relaxation and Sensory Functions between Functional Dyspepsia and Healthy Subjects Using Novel Drinking-Ultrasonography Test
Author(s)	Hata, Tamotsu; Kato, Mototsugu; Kudo, Takahiko; Nishida, Mutsumi; Nishida, Urara; Imai, Aki; Yoshida, Takeshi; Hirota, Jyojyo; Kamada, Go; Ono, Shouko; Nakagawa, Manabu; Nakagawa, Soichi; Shimizu, Yuichi; Takeda, Hiroshi; Asaka, Masahiro
Citation	Digestion, 87(1), 34-39 https://doi.org/10.1159/000343935
Issue Date	2013-01
Doc URL	http://hdl.handle.net/2115/52030
Rights	© 2013 S. Karger AG, Basel
Type	article (author version)
File Information	Dig87-1_34-39.pdf



[Instructions for use](#)

Comparison of gastric motor and sensory functions between functional dyspepsia and healthy subjects using novel drinking-ultrasonography test

Tamotsu HATA¹⁾, Mototsugu KATO²⁾, Takahiko KUDO²⁾, Mutsumi NISHIDA³⁾, Urara NISHIDA¹⁾, Aki IMAI¹⁾, Takeshi YOSHIDA¹⁾, Jyojyo HIROTA¹⁾, Go KAMADA¹⁾, Shouko ONO²⁾, Manabu NAKAGAWA²⁾, Soichi NAKAGAWA²⁾, Yuichi SHIMIZU²⁾, Hiroshi TAKEDA¹⁾, Masahiro ASAKA¹⁾

¹⁾ Department of Gastroenterology, Hokkaido University Graduate School of Medicine, Sapporo, Japan, ²⁾ Division of Endoscopy, Hokkaido University Hospital, Sapporo, Japan,

³⁾ Department of Clinical Laboratory, Support of Clinical practice, Hokkaido University Hospital, Sapporo, Japan

KEY WORDS: Functional gastroduodenal disorders, Drink test, Ultrasonography, Gastric accommodation, Gastric emptying, Visceral hypersensitivity

SHORT TITLE: novel drinking-ultrasonography test

Corresponding Author & Address:

Mototsugu Kato, M.D. Ph. D.

Division of Endoscopy, Hokkaido University Hospital

North 14, West 5, Kita-ku, Sapporo 060-8648, JAPAN

Tel. +81 11 716 1161, Fax +81 11 706 7867

E-mail: m-kato@med.hokudai.ac.jp

Abstract

Background: Functional dyspepsia (FD) is a heterogeneous disease characterized by various upper abdominal symptoms. The major mechanism of FD includes impaired fundic accommodation, delayed gastric emptying, and visceral hypersensitivity. We developed a novel drinking-ultrasonography test to combine a drink test with ultrasonography to assess gastric motility and sensory function of FD patients. **Method:** Subjects were 20 healthy volunteers and 26 successive FD patients according to the Rome III criteria. The subjects ingested 200 ml of water at 2-min intervals 4 times (total 800 ml) through a straw. The maximum cross section of the proximal stomach was visualized before water intake, after each water intake, and 5 and 10 min after the completion of drinking using extracorporeal ultrasonography. Abdominal symptoms were evaluated using the visual analog scale (VAS) a total of 5 times. **Results:** The mean cross-sectional area of the fornix after 800-ml water intake was significantly lower in the FD group compare with the control group. In the FD group, marked abdominal symptoms developed immediately after initiation of water intake and VAS score differed significantly ($P < 0.01$) between the control and FD groups at each time point. **Conclusion:** We developed the drinking-ultrasonography test and this novel test revealed abnormalities in gastric accommodation and sensation in patients with FD compared with healthy controls. This approach can be readily performed and allows the simultaneous evaluation of gastric accommodation, emptying, and sensation.

Introduction

Functional dyspepsia (FD) is a clinical condition characterized by various upper abdominal symptoms, such as postprandial fullness, early satiation, epigastric pain or burning, marked by the absence of organic, systemic, or metabolic disease that would explain the symptoms.

Recently, the Rome III committee proposed new diagnostic criteria for functional gastrointestinal disorders including FD [1]. Rome III criteria divided FD into two categories according to predominant dyspeptic symptoms: postprandial distress syndrome (PDS) and epigastric pain syndrome (EPS). However, the two subtypes overlap greatly. Heterogeneity of FD symptoms depends on different pathophysiological features. The major mechanism of FD symptoms includes impaired fundic accommodation, delayed gastric emptying, and visceral hypersensitivity, as well as other complicating factors [2,3]. It seems likely that understanding of pathophysiology in different types of FD patients is required for different management approaches.

Tests of gastric motility and sensory function are available in clinical practice. Gastric barostat is regarded as the gold standard for the measurement of gastric accommodation [4,5]. However, it is not widely used because the procedure is extremely invasive. Imaging methods such as single photon emission computer tomography, magnetic resonance imaging or scintigraphy have also been occasionally reported [6,7,8,9]. These tests also cannot be used extensively because of radiation exposure and long examination time. On the other hand, ultrasonography, which is safe, non-invasive and inexpensive, allows the direct observation of gastric movements [10,11,12]. In addition, a drink test has recently been developed for the

evaluation of sensory function [13,14,15]. We combined a similar drink test of our own design with ultrasonography to assess gastric motility and sensory function of FD patients in terms of a pathophysiological classification and compared gastric motor and sensory functions of healthy subjects and FD patients.

Subjects and Methods

1) Subjects

Twenty healthy volunteers and 26 successive subjects that had been diagnosed with FD according to the Rome III criteria at Hokkaido University Hospital between August 2006 and August 2007 were enrolled in this study. FD patients had had one or more of the following symptoms in the preceding 3 months: postprandial fullness, early satiation, epigastric pain or burning. All subjects underwent upper gastrointestinal endoscopy and abdominal ultrasonography to exclude organic abdominal disease. This study was approved by the Ethics Committee of Hokkaido University Hospital, and written informed consent was obtained from all subjects.

2) Basic procedure

A drinking-ultrasonography test was performed after subjects had fasted for at least 6 h. Subjects were supine and ingested water through a straw that was placed at facial height so that they raised themselves minimally. Commercially available water in PET bottles (Alkali Ion Water®; Kirin, Tokyo, Japan) and graduated plastic cups were used. During the drinking period, the subjects ingested 200 ml of water at 2-min intervals 4 times (total 800 ml). When

they felt unable to ingest more, the test was discontinued. Examination of the emptying period was conducted 5 and 10 min after the completion of drinking 800 ml (or discontinuation), at which point the test was concluded.

3) Evaluation of the gastric cross-sectional area

All ultrasonographic examinations were performed using an Aplio™ XV (Toshiba, Tokyo, Japan) and a 3.5-MHz convex-type probe (375BT) by one ultrasonography technician with more than 20 years of experience. The cross section of the proximal stomach was visualized by extracorporeal ultrasonography via the 10th intercostal space using the spleen as an echo window. The maximum cross section of the proximal stomach was visualized before water intake, after each water intake at 2-min intervals, and 5 and 10 min after the completion of the drinking test. After the image was frozen, the mucosal surface of the gastric lumen was traced using the ultrasonography system, and the cross-sectional area was calculated. Static and animated images were stored on hard disk.

4) Evaluation of symptoms

During the drinking period, abdominal symptoms were evaluated using the visual analog scale (VAS) a total of 5 times, as well as before the test and immediately after each ingestion of water. Abdominal symptoms before the test were used as the baseline. Subjects were asked about difficulty in drinking due to symptoms such as abdominal fullness and epigastric pain. During the test, they filled out a questionnaire by themselves using a numerical scale of 0 (no difficulty) to 10 (most difficult).

5) Statistical analysis

All values were expressed as the mean \pm SD. Differences between the two groups were analyzed by Student's *t*-test, and *P*-values of less than 0.05 were considered to indicate statistical significance. All data were statistically analyzed using SPSS software (version 11.0 for Microsoft Windows).

Results

1) Baseline characteristics

The healthy control group consisted of 20 subjects (10 males and 10 females) with a mean age of 37.0 (24-53) and a mean body mass index (BMI) of 21.4. The FD group consisted of 26 patients (5 males and 21 females) with a mean age of 38.6 (21-59) and a mean BMI of 20.9 (Table 1).

2) Gastric accommodation

The mean cross-sectional area of the fornix after 800-ml water intake was significantly lower in the FD group ($75.2 \pm 19.0 \text{ cm}^2$) compared with the control group ($98.5 \pm 23.7 \text{ cm}^2$) (Figure 1).

3) Gastric emptying

The percentages of the cross-sectional area of the fornix after 5 and 10 minutes were $81.7 \pm 14.8\%$ and $69.6 \pm 15.7\%$, respectively, in the control group and $86.0 \pm 25.2\%$ and $77.5 \pm$

28.4%, respectively, in the FD group. Although no significant differences were observed ($P = 0.272$) between two groups, the mean value of cross-sectional area of the fornix in the FD group was higher than that in the control group, suggesting delayed emptying in FD (Figure 2).

4) Gastric sensation

In the FD group, marked symptoms such as abdominal fullness and epigastric pain developed immediately after the initiation of water intake, and the VAS score tended to be high compare with controls. The VAS score differed significantly ($P < 0.01$) between the control and FD groups at each time point (after 200 mL of water intake, 0.5 ± 1.5 vs. 2.8 ± 3.5 ; after 400 mL of water intake, 1.4 ± 1.9 vs. 4.2 ± 3.3 ; after 600 mL of water intake, 2.7 ± 2.3 vs. 6.2 ± 3.2 ; and after 800 mL of water intake, 4.2 ± 2.8 vs. 7.0 ± 3.3 , respectively), suggesting hyperesthesia in the FD group (Figure 3).

Discussion

We developed the drinking-ultrasonography test and evaluated the pathological condition of patients with FD in comparison with healthy volunteers. In this drinking-ultrasonography test, a drink load is given at equal intervals, the cross-sectional area of the fornix is measured, and symptoms are verbally assessed at each interval. This approach allows the simultaneous evaluation of gastric relaxation, sensory function, and gastric emptying. It seems that the greatest benefit of the drinking-ultrasonography test is its non-invasive nature, ease of use, tolerability, and short duration (under 20 min) for patients. Recently, minimally invasive tests

of gastric motility and sensory function such as ultrasonography, ¹³C-octanoic acid urea breath test, and drink test have been reported. These tests are able to evaluate gastric relaxation, gastric emptying, gastroduodenal reflux, or visceral hypersensitivity. However, these minimally invasive tests do not detect simultaneously both gastric motor disorder and sensory disorder. The drinking-ultrasonography test does not require radiation, expensive chemical substances, and unusual equipment. In terms of money and time-saving, this novel test is useful for routine examination of dyspeptic patients.

To develop the drinking-ultrasonography test, we examined adequate interval time, tidal volume, and total volume of water intake. Initially, 100-ml water intake at 1-minute intervals was considered based on the study by Boeckxstaens GE [13]. However, at these intervals, the time available for ultrasonography was very short and inquiry into symptoms was inadequate. Then we tried and evaluated 100-ml intake at 5-minute intervals and 200-ml intake at 2-minute intervals. The intake of 100 ml of water at 5-minute intervals was time-consuming, and ingested water flowed into the duodenum and deeper areas early during the test, causing high data variance. The intake of 200 ml of water at 2-minute intervals did not produce this phenomenon or high data variance and was considered optimal. However, to avoid subjects' maximum satiety, the determination of the upper limit of water intake was necessary. Since the mean cross-sectional area of the fornix showed significant differences after about 800 mL intake between healthy and FD patient groups, the intake of 800 mL of water was considered appropriate. We used loading of zero-calorie mineral water, because previous studies have shown that acid secretion due to fat intake affects gastric movement, causing hyperesthesia of

visceral organs[16,17]. Further studies involving loading of calorie-containing liquids may be necessary and interesting.

In this study, the VAS score during water intake significantly differed between the healthy control and FD groups. The reported incidence of impaired gastric accommodation in patients with FD is about 40-50% [18], and several studies have also shown gastric impairment in patients with FD compared with healthy subjects[6,9]. Symptoms due to relaxation failure have been suggested to be caused by excessive excitation of fundic stretch receptors[19] or contents moved to the antrum early due to distension failure[20]. Delayed gastric emptying has long been considered the main pathology of FD and extensively studied. Recent studies have shown that the incidence of delayed gastric emptying is about 25% [21,22], and many studies have suggested no association between delayed gastric emptying and specific symptoms. In the present study, slightly delayed gastric emptying was observed in the FD group, but there were no significant differences between two groups.

The pathophysiological mechanisms of FD include motility disorders, perception disorders, acid hypersensitivity, psychological factors, *Helicobacter pylori* infection, duodenal dysfunction and abnormalities within the brain-gut axis. Further study is necessary to clarify the relationship between the pathophysiological classification using this novel test and the strategy of FD treatment.

Conclusion

The drinking-ultrasonography test revealed abnormalities in gastric accommodation and sensation in patients with FD compared with healthy controls. This test can be readily performed and allows the simultaneous evaluation of gastric accommodation, emptying, and sensation.

Disclosure Statement

The authors declare that no financial or other conflicts of interest exist in relation to the content of the article.

References

- 1 Talley NJ, Camilleri M, Holtmann G, Hu P, Malagelada JR, Stanghellini V : Functional gastroduodenal disorders. *Gastroenterology*. 2006 ; 130 : 1466-79.
- 2 Tack J, Piessevaux H, Coulie B, Caenepeel P, Janssens J : Role of impaired gastric accommodation to a meal in functional dyspepsia. *Gastroenterology* 1998 ; 115 : 1346-1352.
- 3 Tack J, Lee KJ : Pathophysiology and treatment of functional dyspepsia. *J clin Gastroenterol* 2005 ; 39 : S211-216.
- 4 Azpiroz F, Malagelada JR : Physiological variations in canine gastric tone measured by an electronic barostat. *Am J Physiol*. 1985 ; 248 : G229-37.
- 5 Tack J, Caenepeel P, Fischler B, Piessevaux H, Janssens J : Symptoms associated with hypersensitivity to gastric distention in functional dyspepsia . *Gastroenterology* 2001 ; 121 : 526—535.

- 6 Piessevaux H, Tack J, Walrand S, Pauwels S, Geubel A : Intra-gastric distribution of a standardized meal in health and functional dyspepsia ; Correlation with specific symptoms. *Neurogastroenterol Motil* 2003 ; 15 : 447-455.
- 7 van den Elzen BD, Bennink RJ , Wieringa RE , Tytgat GN, Boeckxstaens GE : Fundic accommodation assessed by SPECT scanning : comparison with the gastric barostat. *Gut* 2003 ; 52 : 1548—1554.
- 8 de Zwart IM, Mearadji B, Lamb HJ, Eilers PH, Masclee AA, de Roos A, Kunz P : Gastric motility ; Comparison of assessment with real-time MR imaging or barostat measurement initial experience. *Radiology* 2002 ; 224 : 592-597.
- 9 Fruehauf H, Goetze O, Steingötter A, Kwiatek M, Boesiger P, Thumshirn M, Schwizer W, Fried M : Intersubject and intrasubject variability of gastric volumes in response to isocaloric liquid meals in functional dyspepsia and health. *Neurogastroenterol Motil* 2007 ; 19 : 553-561.
- 10 Schwizer W, Steingötter A, Fox M, Zur T, Thumshirn M, Bösiger P, Fried M : Noninvasive measurement of gastric accommodation in humans. *Gut* 2002 ; 51 : i59—i62.
- 11 H Kusunoki, K Haruma, J Hata, H Tani, E Okamoto, K Sumii, G Kajiyama : Real-time ultrasonographic assessment of antroduodenal motility after ingestion of solid and liquid meals by patients with functional dyspepsia . *Journal of Gastroenterology and Hepatology* 2000 ; 15 : 1022-1027.
- 12 Gilja OH, Lunding J, Hausken T, Gregersen H : Gastric accommodation assessed by ultrasonography. *World J Gastroenterol* 2006 ; 12 : 2825—2829.
- 13 Boeckxstaens GE, Hirsch DP, Kuiken SD, Heisterkamp SH, Tytgat GN :The proximal

stomach and postprandial symptoms in functional dyspeptics . Am J Gastroenterol 2002 ; 97 : 40—48.

14 Jones MP, Hoffman S, Shah D, Patel K, Ebert CC : The water load test : observations from healthy controls and patients with functional dyspepsia. Am J Physiol Gastrointest Liver Physiol 2003 ; 284 : G896—G904.

15 Gonenne J, Castillo EJ, Camilleri M, Burton D, Thomforde GM, Baxter KL, Zinsmeister AR : Does the nutrient drink test accurately predict postprandial gastric volume in health and community dyspepsia? Neurogastroenterol Motil 2005 ; 17 : 44—50.

16 Sarnelli G, Caenepeel P, Geypens B, Janssens J, Tack J : Symptoms associated with impaired gastric emptying of solids and liquids in functional dyspepsia. Am J Gastroenterol 2003 ; 98 : 783—788.

17 Drossman DA : The functional gastrointestinal disorders and the Rome III process . Gastroenterology 2006 ; 130 : 1377—1390.

18 Lee KJ, Vos R, Janssens J, Tack J : Influence of duodenal acidification on the sensorimotor function of the proximal stomach in humans. Am J Physiol Gastrointest Liver Physiol 2004 ; 286 : G278-G284.

19 Feinle C, Rades T, Otto B, Fried M : Fat digestion modulates gastrointestinal sensations induced by gastric distention and duodenal lipid in humans. Gastroenterology 2001 ; 120 : 1100-1107.16

20 Caldarella MP, Azpiroz F, Malagelada JR : Antrofundic dysfunctions in functional dyspepsia. Gastroenterology 2003 ; 124 : 1220—1229.

21 Lee KJ, Vos R, Janssens J, Tack J : Differences in the sensorimotor response to

distension between the proximal and distal stomach in humans. Gut 2004 ; 53 : 938—943.

22 Talley NJ, Verlinden M, Jones M : Can symptoms discriminate among those with delayed or normal gastric emptying in dysmotility-like dyspepsia ? Am J Gastroenterol 2001 ; 96 : 1422—1428.

Figure reference

Table 1: Baseline characteristics by HVs and patients with FD
HV: Healthy volunteers , FD : Functional dyspepsia patients
BMI : Body mass index

Figure 1: The cross-sectional area of the fornix (gastric accommodation) during the drinking-ultrasonography test. Impairment of gastric accommodation was significant in FD patients on 800ml water intake.

Vertical line: cross-sectional area of the fornix (cm²)
Horizontal axis: volume of water intake (ml)

Figure 2: Cross-sectional area of the fornix after water intake. No significant difference was recognized between the groups.

Vertical line: percentage of the cross-sectional area of the fornix (%)
Horizontal axis: time from the end of examination (min)

Figure 3: VAS (visual analog scale) during the drinking-ultrasonography test. FD groups tended to complain of upper-gastrointestinal symptoms from an early stage of the examination.

Vertical line : VAS during water intake (minimum: 0-maximum: 10)
Horizontal axis : volume of water intake (ml)

Table 1
Baseline characteristics of subjects

	HVs (n=20) Mean \pm SD	FD (n=26) Mean \pm SD	
Male/Female	10/10	5/21	n.s.
Age (minimum-maximum)	37.0 \pm 10.3 (24-53)	38.6 \pm 10.3 (21-59)	n.s.
BMI	21.4 \pm 3.3	20.9 \pm 5.0	n.s.
Height (cm)	166.0 \pm 8.6	160.2 \pm 7.6	n.s.
Weight (kg)	60.4 \pm 12.2	53.6 \pm 10.6	n.s.

Figure 1

Cross-sectional area of fornix and volume of water intake

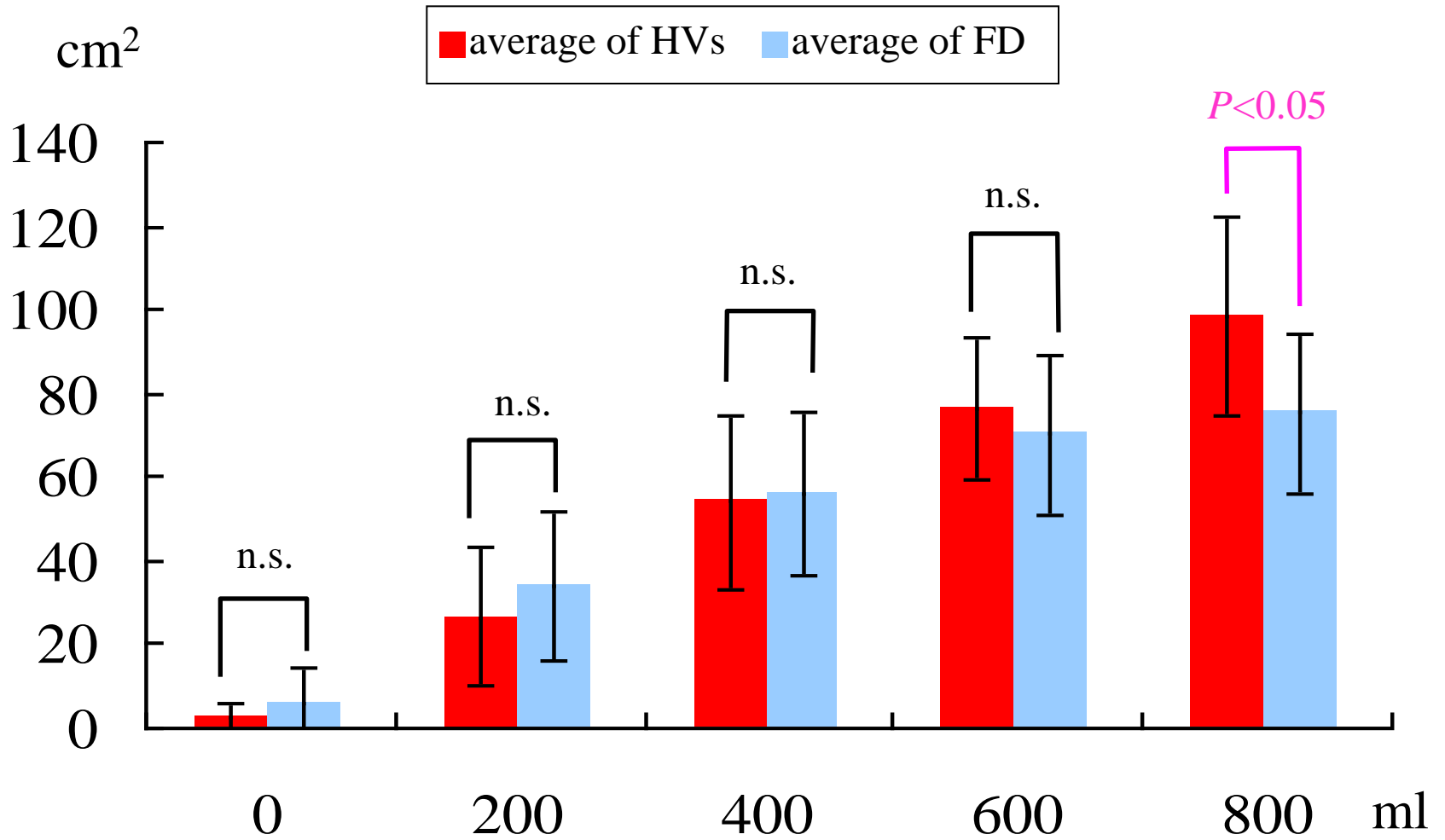


Figure 2

Cross-sectional area of fornix and time after water intake

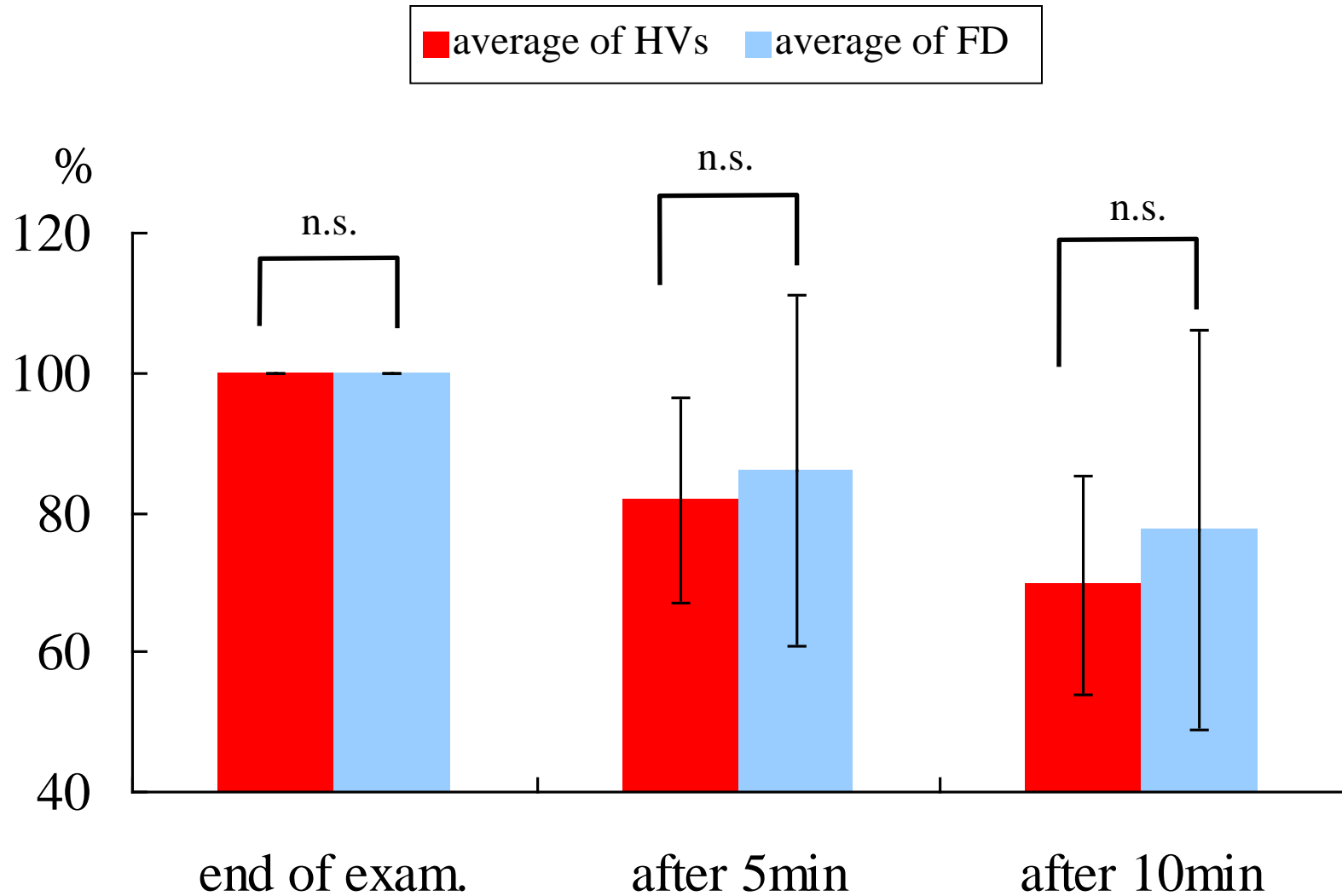


Figure 3
Mean VAS and volume of water intake

