



Title	The role of endoscopic ultrasound in the evaluation of rectal polypoid lesions in 25 dogs
Author(s)	Hayashi, Kohtaro; Okanishi, Hiroki; Kagawa, Yumiko; Asano, Kazushi; Watari, Toshihiro
Citation	Japanese Journal of Veterinary Research, 60(4), 185-189
Issue Date	2012-11
DOI	10.14943/jjvr.60.4.185
Doc URL	http://hdl.handle.net/2115/50886
Type	bulletin (article)
File Information	獣医学部紀要60巻4号_02_Hayashi他.pdf



[Instructions for use](#)

The role of endoscopic ultrasound in the evaluation of rectal polypoid lesions in 25 dogs

Kohtaro Hayashi¹⁾, Hiroki Okanishi¹⁾, Yumiko Kagawa³⁾,
Kazushi Asano²⁾ and Toshihiro Watari^{1)*}

¹⁾Laboratory of Comprehensive Veterinary Clinical Studies, College of Bioresource Sciences, Nihon University, 1866 Kameino, Fujisawa, Kanagawa 252-0880, Japan

²⁾Laboratory of Veterinary Surgery, College of Bioresource Sciences, Nihon University, 1866 Kameino, Fujisawa, Kanagawa 252-0880, Japan

³⁾North Lab, 8-35 Hondori 2-Chome Kita, Shiroisi-ku, Sapporo, Hokkaido 003-0027, Japan

Received for publication, August 9, 2012; accepted, September 20, 2012

Abstract

We investigated the role of endoscopic ultrasound in the evaluation of rectal polypoid lesions in 25 dogs. Twenty-five cases of rectal polypoid lesions in dogs who underwent surgery after endoscopic and EUS assessment were studied. The invasion depth of the polypoid lesion was classified as M stage (lesions in the mucosa only), SM stage (lesions in the mucosa and submucosa), and MP stage (lesions extending to the muscularis propria). Transabdominal ultrasound was performed in nine cases, but not all were evaluated in detail. EUS provided detailed images for all cases and showed a significant correlation with surgical pathology in the T stage (accuracy, 92%; $\kappa = 0.77$). As per classification by invasion depth, inflammatory polyps were only M polypoid lesions, whereas SM and MP polypoid lesions were only adenocarcinomas ($P < 0.05$). The average survival time according to specific condition was as follows: 1,235 days for inflammatory polyps, and 804 days for M adenocarcinoma. The survival time of two SM adenocarcinoma cases was 756 and 2,114 days, respectively, and the survival time of two MP adenocarcinoma cases was 16 and 42 days, respectively. EUS were useful for the evaluation of rectal polypoid lesions in dogs, whereas transabdominal ultrasound was not. Determination of the invasion depth of polypoid lesions using EUS may be useful for the evaluation of malignancy and prognosis.

Key Words: dog, endoscopic ultrasound, rectal polypoid lesions

Introduction

Large intestinal polypoid lesions are a common form of intestinal disease in dogs and

frequently occur in the rectum^{2,4,5,6,11,12,14}. Detailed evaluations of rectal polypoid lesions are essential for selecting endoscopic treatment and minimal access surgery. However, detailed

*Corresponding author: T. WATARI, Laboratory of Comprehensive Veterinary Clinical Studies, College of Bioresource Sciences, Nihon University, 1866 Kameino, Fujisawa, Kanagawa 252-0880, Japan
Phone: +81-466-84-3899. Fax: +81-466-84-3899. E-mail: watari@brs.nihon-u.ac.jp

visualization and evaluation using transabdominal ultrasound (TAUS) is difficult because the polypoid lesions are far from the abdominal wall¹⁰. In contrast, endoscopy is used to evaluate the surface of polypoid lesions. Thus, the treatment is performed without an assessment of the invasion depth.

Evaluation of the invasion depth of rectal polypoid lesions has been commonly performed in the human medicine^{1,8,13,16} using endoscopic ultrasound (EUS), magnetic resonance imaging (MRI), and computed tomography (CT)³. In veterinary medicine, CT has not been studied whether it can be sufficiently evaluated the layer structure of the gastrointestinal tract, MRI of the abdomen is required anesthesia for a long period of time and not general. However, endoscopic evaluation of rectal polypoid lesions is commonly performed^{9,14}. Therefore, EUS as an ancillary of endoscopy is effective for the evaluation of the invasion depth of rectal polypoid lesions in dogs.

This study aimed to investigate the role of endoscopic ultrasound in the evaluation of rectal polypoid lesions in 25 dogs.

Materials and Methods

In this retrospective study, the medical records with rectal polypoid lesions diagnosed by endoscopy and EUS between March 2006 and August 2011 at the Nihon University Animal Medical Center were analyzed. Of these, only rectal polypoid lesions that were surgically treated after assessment by EUS were included in the study. The data collected included signalment (i.e., age, sex, weight, and breed); clinical signs; blood tests; TAUS (convex probe, 6 MHz; linear probe, 12 MHz, NEMIO SSA-550A, Toshiba, Tokyo, Japan); EUS; histopathological findings; and prognosis.

Following the administration of an enema under general anesthesia, lower gastrointestinal endoscopy was performed with the subjects in the left lateral recumbent position. After

observation of the polypoid lesion form by endoscopy, the lumen of the rectum was filled with saline. EUS was performed using a 20-MHz radial probe (EU-M 30S, Olympus, Tokyo, Japan), which was inserted from the biopsy channel of the endoscope. The scan was initiated when the tip entered the lumen. After the rostral end of the lesion was visualized, the invasion depth of the lesion was investigated in detail. The invasion depth of the polypoid lesion was classified by lesion stage on the basis of the five-layer structure in the gastrointestinal tract: M stage, lesions in the mucosa only; SM stage, lesions in the mucosa and submucosa; and MP stage, lesions extending to the muscularis propria^{1,7}. After evaluated by EUS, the polypoid lesions were resected by surgery. The diagnosis and lesion stage of the resected polypoid lesion was determined by histopathological examination.

Surgical pathological lesion staging was compared with EUS lesion staging. Results were evaluated by means of κ interobserver analysis. A likelihood ratio test was used to compare the inflammatory polyps and adenocarcinomas according to the invasion depth as evaluated by surgical pathology. $P < 0.05$ was considered statistically significant. Inflammatory polyps and adenocarcinomas subclassified into M, SM, and MP stages were evaluated with respect to survival duration. All statistical analyses were performed using GraphPad Prism 5 software (GraphPad Software, San Diego, CA, USA) and SPSS 17.0 (SPSS Inc, Chicago, USA).

Results

Twenty-five cases (13 females and 12 males; median age, 8 years; range, 3–12 years; median weight, 6.0 kg; range, 2.3–20 kg) were eventually included in the study. The breeds and associated polypoid lesion types included miniature Dachshunds ($n = 15$) with inflammatory polyp and miniature Dachshunds ($n = 5$), Shih-tzu ($n = 3$), a Shetland sheepdog ($n = 1$), and a Border

collie ($n = 1$) with adenocarcinomas. The most common clinical signs were hematochezia ($n = 24$), tenesmus ($n = 14$), and dyschezia ($n = 8$). Blood tests, performed in all cases, revealed the following: increased C-reactive protein (more than 1 mg/dl; $n = 5$) and leukocytosis (more than 19,000/ μ l; $n = 2$) in cases with inflammatory polyps and increased C-reactive protein ($n = 4$), leukocytosis ($n = 3$), and decreased packed cell volume (less than 35%; $n = 2$) in cases with adenocarcinomas. TAUS was performed in nine cases; six of these could not be visualized, whereas three could be visualized but could not be evaluated in detail.

The polypoid lesions in all cases could be evaluated in detail by EUS (Fig. 1). Invasion depth of the polypoid lesions as determined by EUS and surgical pathology are shown in Table 1. EUS findings significantly correlated with surgical pathology with an accuracy of 92% (23/25, $\kappa = 0.77$). In addition, none of the M and SM polypoid lesions evaluated by EUS were found to have invaded beyond the muscularis layer by histopathology. In the result of classification by invasion depth, inflammatory polyps were only M polypoid lesions, whereas SM and MP polypoid lesions were diagnosed only as adenocarcinomas ($P < 0.05$).

All dogs with M and SM polypoid lesions survived. However, two dogs with MP polypoid

lesions succumbed within 2 months. The median survival time could not be precisely determined for both the inflammatory polyp and adenocarcinomas. The average survival time according to specific condition was as follows: 1,235 days for inflammatory polyps, and 804 days for M adenocarcinoma. The survival time of two SM adenocarcinoma cases was 756 and 2,114 days, respectively, and the survival time of two MP adenocarcinoma cases was 16 and 42 days, respectively.

Discussion

In this study, the findings of age, sex, and clinical symptoms in dogs with rectal polypoid lesions were comparable to those from previous reports^{2,5,12,14}. The miniature Dachshund was the only breed with inflammatory polyp in this study. Inflammatory polyp has been previously reported in miniature dachshund⁹; therefore, inflammatory polyp of the rectum may be a characteristic disease in this breed. Blood test findings revealed increased C-reactive protein and leukocytosis, which were considered to be caused by inflammation of the polypoid lesions, and decreased packed cell volume, which was considered to be caused by hematochezia and chronic inflammation. However, these blood tests

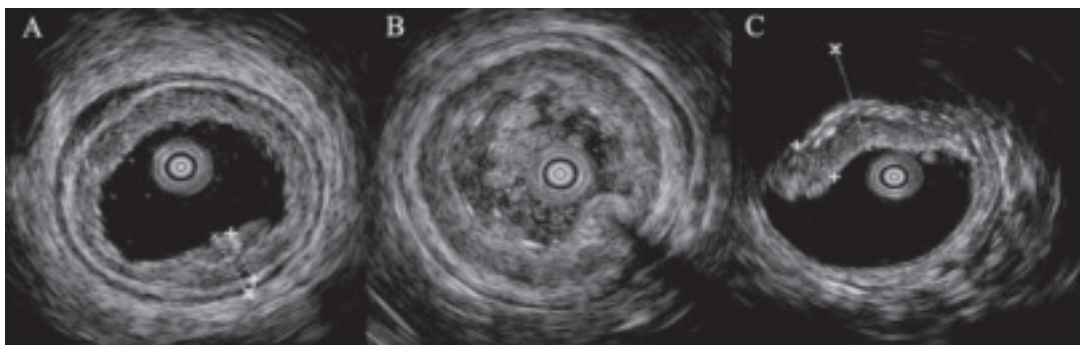


Fig. 1. Endoscopic ultrasound findings for the rectal polypoid lesions. (A) M polypoid lesion: the polypoid lesion has invaded only the mucosal layer, which is thickened. The hyperechoic submucosal interface is intact. (B) SM polypoid lesion: the polypoid lesion invades the mucosal and submucosal layers, and the mucosal-submucosal layer is thickened. The hyperechoic submucosal interface is absent, and hypoechoic muscularis interface is intact. (C) MP polypoid lesion: the polypoid lesions extending to the muscularis layer, which is thickened. The hyperechoic submucosal interface is absent.

Table 1. Comparison of invasion depth of the polypoid lesions as evaluated by EUS with that evaluated by surgical pathology.

	Surgical pathological stage		
	M	SM	MP
EUS stage			
M	19	2	0
SM	0	2	0
MP	0	0	2

Figures are the number of cases. EUS, endoscopic ultrasound

were nonspecific, which suggests that these were not characteristic findings for rectal polypoid lesions, as was previously reported¹⁴.

There have been few reports on ultrasound examinations of rectal polypoid lesions in dogs. In a report of TAUS for gastrointestinal tumors, colorectal tumors were observed in six cases; however, they were not examined in detail, including invasion depth¹⁰. In the present study, six cases could not be visualized by TAUS at all, and remaining three cases that could be visualized could not be evaluated in detail. A previous report noted that ultrasound may not be suitable for many dogs with rectal or distal colonic tumors because the lesions are too distal to be completely imaged^{4,10}. Therefore, it is suggested that TAUS is not useful for detailed preoperative evaluations of rectal polypoid lesions in dogs.

In this study, EUS was used to perform detailed preoperative evaluations of rectal polypoid lesions in dogs. In human medicine, evaluation of rectal polypoid lesions using TAUS is difficult¹. Accordingly, EUS, MRI, and CT have been investigated as alternatives to TAUS^{3,8,13,16}. The accuracy of determining invasion depth by these methods was approximately 80%, and these methods were used depending on specific circumstances³. Among these methods, EUS proves useful for obtaining images of areas having substances that may obstruct and hamper quality of the image obtained, such as food residues in the gastrointestinal tract and the

anatomical positions of the bladder and pelvis. EUS can easily evaluate invasion depth by observing the lesion and its adjacent areas¹⁵. In the present study, EUS was used to accurately determine the invasion depth of polypoid lesions. Therefore, it was suggested that EUS was useful for the evaluation of invasion depth of rectal polypoid lesions in dogs. However, half (2/4) the cases of SM polypoid lesion evaluated by EUS were M polypoid lesion according to surgical pathology staging. Distinguish between M and SM polypoid lesion may be difficult when lesions are present. Therefore, it was considered that submucosal irregularities were incorrectly visualized by EUS. In addition, SM and MP polypoid lesions were a few. Then, the use of EUS for rectal SM and MP polypoid lesions requires further investigation.

The prognosis of M and SM adenocarcinomas was good in this study. In contrast, the prognosis of MP adenocarcinomas was poor. In previous reports, rectal adenocarcinomas in dogs have had a poor prognosis^{2,5}. In contrast, although the survival time of dogs with carcinoma in situ has not been reported in detail, long-term survival is reported for many cases¹⁴. Thus, it was considered that rectal adenocarcinoma with a poor prognosis was the MP type, whereas the prognosis of M and SM adenocarcinomas was similar to that of carcinomas in situ. In addition, as per classification by invasion depth, inflammatory polyps were only M polypoid lesions, whereas SM and MP polypoid lesions were diagnosed only as adenocarcinomas ($P < 0.05$) in this study. Therefore, diagnosis of the invasion depth by EUS may be useful for the evaluation of malignancy and prognosis in patients with adenocarcinoma because the prognosis of polypoid lesions classified by EUS is different.

In conclusion, EUS were shown to be useful for the evaluation of rectal polypoid lesions in dogs. TAUS was not useful because evaluation of invasion depth is difficult with this procedure. The accuracy of EUS was high in evaluating the

invasion depth of rectal polypoid lesions. EUS could be therefore useful for surgical procedure selection and prognosis assessment in dogs with rectal polypoid lesions. In addition, diagnosis of the invasion depth of polypoid lesions using EUS may be useful to evaluate malignancy.

References

- 1) Adams, D. R., Blatchford, G. J., Lin, K. M., Terner, C. A., Thorson, A. G. and Christensen, M. A. 1999. Use of preoperative ultrasound staging for treatment of rectal cancer. *Dis. Colon Rectum*, **42**: 159-166.
- 2) Church, E. M., Mehlhaff, C. J. and Patnaik, A. K. 1987. Colorectal adenocarcinoma in dogs: 78 cases (1973-1984). *J. Am. Vet. Med. Assoc.*, **191**: 727-730.
- 3) Dinter, D. J., Hofheinz, R. D., Hartel, M., Kaehler, G. F., Neff, W. and Diehl, S. J. 2008. Preoperative staging of rectal tumors: comparison of endorectal ultrasound, hydro-CT, and high-resolution endorectal MRI. *Onkologie*, **31**: 230-235.
- 4) Holt, P. E. 2007. Evaluation of transanal endoscopic treatment of benign canine rectal neoplasia. *J. Small Anim. Pract.*, **48**: 17-25.
- 5) Holt, P. E. and Lucke, V. M. 1985. Rectal neoplasia in the dog: a clinicopathological review of 31 cases. *Vet. Rec.*, **116**: 400-405.
- 6) Knottenbelt, C. M., Simpson, J. W. and Chandler, M. L. 2000. Neutrophilic leucocytosis in a dog with a rectal tumour. *J. Small Anim. Pract.*, **41**: 457-460.
- 7) Morello, E., Martano, M., Squassino, C., Iussich, S., Caccamo, R., Sammartano, F., Zabardino, S., Bellino, C., Pisani, G. and Buracco, P. 2008. Transanal pull-through rectal amputation for treatment of colorectal carcinoma in 11 dogs. *Vet. Surg.*, **37**: 420-426.
- 8) Norton, S. A. and Thomas, M. G. 1999. Staging of rectosigmoid neoplasia with colonoscopic endoluminal ultrasonography. *Br. J. Surg.*, **86**: 942-946.
- 9) Ohmi, A., Tsukamoto, A., Ohno, K., Uchida, K., Nishimura, R., Fukushima, K., Takahashi, M., Nakashima, K., Fujino, Y. and Tsujimoto, H. 2012. A retrospective study of inflammatory colorectal polyps in miniature dachshunds. *J. Vet. Med. Sci.*, **74**: 59-64.
- 10) Paoloni, M. C., Penninck, D. G. and Moore, A. S. 2002. Ultrasonographic and clinicopathologic findings in 21 dogs with intestinal adenocarcinoma. *Vet. Radiol. Ultrasound*, **43**: 562-567.
- 11) Prater, M. R., Flatland, B., Newman, S. J., Sponenberg, D. P. and Chao, J. 2000. Diffuse annular fusiform adenocarcinoma in a dog. *J. Am. Anim. Hosp. Assoc.*, **36**: 169-173.
- 12) Seiler, R. J. 1979. Colorectal polyps of the dog: a clinicopathologic study of 17 cases. *J. Am. Vet. Med. Assoc.*, **174**: 72-75.
- 13) Siddiqui, A. A., Fayiga, Y. and Huerta, S. 2006. The role of endoscopic ultrasound in the evaluation of rectal cancer. *Int. Semin. Surg. Oncol.*, **3**: 36.
- 14) Valerius, K. D., Powers, B. E., McPherron, M. A., Hutchison, J. M., Mann, F. A. and Withrow, S. J. 1997. Adenomatous polyps and carcinoma in situ of the canine colon and rectum: 34 cases (1982-1994). *J. Am. Anim. Hosp. Assoc.*, **33**: 156-160.
- 15) Wojtowycz, A. R., Spirt, B. A., Kaplan, D. S. and Roy, A. K. 1995. Endoscopic US of the gastrointestinal tract with endoscopic, radiographic, and pathologic correlation. *Radiographics*, **15**: 735-753.
- 16) Zhou, P., Yao, L., He, G., Gao, W. and Qin, X. 2003. Clinical application of ultrasonic probing for preoperative staging of colorectal carcinoma. *Asian J. Surg.*, **26**: 13-16.