



Title	Chronological Change in Pulmonary Vascular Response to Hypoxia in Hepatopulmonary Syndrome
Author(s)	Tanino, Yoshinori; Makita, Hironi; Tsujino, Ichizo; Shinano, Hideki; Nishimura, Masaharu
Citation	Respiration, 84(3), 242-245 <a href="https://doi.org/10.1159/000336622">https://doi.org/10.1159/000336622</a>
Issue Date	2012-08
Doc URL	<a href="http://hdl.handle.net/2115/50398">http://hdl.handle.net/2115/50398</a>
Rights	Copyright © 2012 S. Karger AG, Basel
Type	article (author version)
File Information	Res84-3_242-245.pdf



[Instructions for use](#)

# **Chronological Change in Pulmonary Vascular Response to Hypoxia in Hepatopulmonary Syndrome**

Yoshinori Tanino<sup>1, 2)</sup>, Hironi Makita<sup>1)</sup>, Ichizo Tsujino<sup>1)</sup>,

Hideki Shinano<sup>1)</sup>, and Masaharu Nishimura<sup>1)</sup>

1) First Department of Medicine, Hokkaido University School of Medicine

2) Department of Pulmonary Medicine, Fukushima Medical University School  
of Medicine

Address correspondence to: Yoshinori Tanino, M.D.

Department of Pulmonary Medicine, Fukushima Medical University School of  
Medicine, 1 Hikarigaoka, Fukushima, 960-1295, JAPAN.

Tel: +81-24-547-1360, Fax: +81-24-548-9366,

E-mail: [ytanino@fmu.ac.jp](mailto:ytanino@fmu.ac.jp)

Short title: Pulmonary Vascular Response to Hypoxia in HPS

Key words: Hepatopulmonary syndrome, Spontaneous resolution, Pulmonary  
hypertension, Pulmonary vascular response

**Established Facts**

- In hepatopulmonary syndrome, there have been only a few cases that reported spontaneous resolution of hypoxaemia with development of pulmonary hypertension without liver transplantation.

**Novel Insights**

- This is the first report that shows remarkable change in the pulmonary vascular response to hypoxia before and after the spontaneous resolution of hypoxaemia in hepatopulmonary syndrome.

## **Abstract**

We here present a case with hepatopulmonary syndrome (HPS) where spontaneous resolution of severe hypoxaemia occurred with the development of pulmonary hypertension over several years after the initial diagnosis of HPS. The pulmonary vascular responses to hypoxia examined before and after the spontaneous resolution of HPS confirmed that the pathogenesis of HPS could be functional and reversible in nature. To the best of our knowledge, this is the first report demonstrating a remarkable change in the pulmonary vascular response to hypoxia before and after the spontaneous resolution of hypoxaemia in HPS.

## **Introduction**

HPS is characterised by a triad of chronic liver disease, oxygenation defect, and intrapulmonary vascular dilatation [1]. The hypoxaemia in HPS is generally progressive and no effective therapy has been established except liver transplantation. However, spontaneous resolution of hypoxaemia has been documented, and subsequent development of pulmonary hypertension (PH) has been reported in a few cases [2, 3]. In the present case, repeated examinations by right-sided heart catheterization (RHC) and lung perfusion scans using macroaggregated albumin (MAA) confirmed the chronological change in the pulmonary vascular response to hypoxia.

## Case Report

A 52-year-old man who had been diagnosed with HPS forty months ago was admitted for further evaluation of improving hypoxaemia that had been noticed since several months before. He had received a massive transfusion for leg injuries, and was diagnosed as having post-transfusion liver cirrhosis (Child-Pugh score 5) at the age of 43 years. Long-term oxygen therapy (LTOT) had been prescribed because of severe hypoxaemia (Table) and he complained of dyspnoea even on mild exercise at the first evaluation. However, he reported at this time that his exertional dyspnoea had been definitely getting better over the last few months. His physical examination was remarkable for clubbed fingers, spider nevi scattered on the anterior chest and hepatomegaly. The breath sound was clear, as it had been at the initial diagnosis. The results of circulatory blood counts were unremarkable, and liver function tests showed no signs of deterioration. Chest roentgenograms demonstrated cardiomegaly with mottled vascular markings in bilateral lower lung fields.

Arterial blood gas analysis while breathing room air confirmed marked improvement of the hypoxaemia (Table: PaCO<sub>2</sub>, 34.5 torr, and PaO<sub>2</sub> 77.0 torr). Spirometric measurement didn't show apparent ventilatory dysfunction but a decline of the diffusing capacity (vital capacity, 3.04 L [84.9% predicted], forced expiratory volume in one second/forced vital capacity, 71.0%, and diffusion capacity for carbon monoxide, 11.45 ml/min/mmHg [50.4% predicted]).

We examined the right to left shunt by breathing 100% oxygen. The right to left shunt calculated by the shunt equation was 3.0% at this time that was improved compared with 8.4% at the initial evaluation. MAA lung perfusion scans showed a more dramatic change. The shunt value by this method was around 30% at the diagnosis. It was 10.3% after 40 months, and was further reduced to as low as 3.0% after 62 months. We then conducted RHC for further haemodynamic evaluation. Circulatory parameters measured under room air breathing confirmed the development of PH. We examined the pulmonary vascular responses to various arterial oxygen tensions as previously described [4]. Briefly, we let the patient receive 100% oxygen at first, and then

attempted to control his SaO<sub>2</sub> measured by a pulse oximeter by changing the inspiratory gas concentration. Measurements were done at least three minutes after a steady state was achieved at the SaO<sub>2</sub> levels of nearby 100%, 95%, and 90% (Figure). When the SaO<sub>2</sub> reached 90%, the mPAP was 41 mmHg and the PVR was 338 dynes·s·cm<sup>-5</sup>, both of which were higher than the values obtained at the SaO<sub>2</sub> level of nearby 100% (35 mmHg and 312 dynes·s·cm<sup>-5</sup>, respectively). The pulmonary vascular response to graded arterial oxygen saturation indicated the presence of hypoxic pulmonary vasoconstriction (HPV), which was in a sharp contrast with the finding at the initial evaluation. As previously reported, inhalation of 100% of oxygen had evoked paradoxical pulmonary vasoconstriction three months after diagnosis [4].

Sixty two months after the diagnosis, LTOT was discontinued according to the patient's request because of further improvement of hypoxaemia and exertional dyspnoea, although PAP estimated by Doppler-echocardiogram remained high or even higher than before. At this time, we conducted RHC again and confirmed that the mPAP (48 mmHg) and the PVR (534 dynes·s·



cm<sup>-5</sup>) were further elevated while the CO or CI was decreased compared to the values of 22 months before (Table).

## Discussion

In the present case, pulmonary artery has constricted on exposure to hyperoxia and then gradually dilated during progressive hypoxic inhalation at the first admission [4]. Interestingly, this paradoxical response has disappeared and normal HPV was observed after 37 months. Such a paradoxical response in the pulmonary artery should result in abnormal VA/Q relationships in the lungs, thus further contributing to the hypoxaemia observed in HPS. In general, the presence of HPS in chronic liver diseases is considered to indicate a poor prognosis. Indeed, a median survival was reported to be 24 months among patients who were not candidates for liver transplantation [5]. However, spontaneous resolution of hypoxaemia and dyspnoea occurred over the next several years after the initial diagnosis in this case, and this surprising event was associated with the new development of PH. In fact, there are a few past cases that reported such spontaneous resolution of hypoxaemia in HPS with the development of PH [3, 4], however, we demonstrated for the first time that the pulmonary vascular response could be

returned to be normal from paradoxical. In other words, we could confirm the recovery of HPV with resolution of hypoxaemia in this case, which should potentially contribute to the improvement of hypoxaemia. Although the pathogenesis of HPS remains to be elucidated, these findings indicate HPS could be functional and reversible in nature and may lead to the future discovery of pharmacological therapy for HPS.

In cirrhotic patients, Daoud et al. demonstrated the complete loss of HPV and concluded this phenomenon resulted in abnormal VA/Q relationships and hypoxaemia [6]. In contrast, Naeije et al. reported HPV was preserved in the majority of individuals with cirrhosis [7]. The mechanism by which the pulmonary vascular response to hypoxaemia changed over the years in this case was unclear. In general, the pulmonary vascular response is considered to be determined by the net balance between vasoconstrictor and vasodilatory factors. Therefore, the chronological change in the pulmonary vascular response in this case may suggest changes in vasodilatory factors as well as vasoconstrictive mechanisms. A balance of vasoconstrictive and vasodilatory

factors such as endothelin-1 (ET-1) and nitric oxide may possibly be involved in our case [8-10].

Like HPS, PH is another well-known complication of chronic liver disease, although its prevalence is reported to be as low as 2% in cirrhosis and portal hypertension [9]. The hemodynamic features of HPS and portopulmonary hypertension (PPHTN) are seemingly opposite, with pulmonary vascular resistance being low in the former and elevated in the latter. Although the precise pathogenesis of PPHTN has not been clarified, recent evidence suggests the possible role of ET-1 [11]. Because ET-1 is also considered to be involved in HPS, Umeda et al. have discussed a biphasic property of ET-1 in liver cirrhosis (at first vasodilation, then vasoconstriction) [3]. From this point of view, it is interesting to see the two complications in the same patient.

In conclusion, the change in pulmonary vascular responses which we presented here indicates that the pathogenesis of HPS could be functional and reversible in nature. Although the precise mechanism remains to be clarified, these findings provide insight into the pathogenesis and mechanisms of

pulmonary vascular abnormalities associated with chronic liver disease.

## References

- 1) Rodríguez-Roisin R, Krowka MJ: Hepatopulmonary syndrome – A liver-induced lung vascular disorder. *N Engl J Med* 2008;358:2378-2387.
- 2) Mal H, Burgière O, Durand F, Fartoukh M, Cohen-Solal A, Fournier M: Pulmonary hypertension following hepatopulmonary syndrome in a patient with cirrhosis. *J Hepatol* 1999;31:360-364.
- 3) Ueda A, Tagawa M, Kohsaka T, Miyakawa T, Kawasaki K, Kitamura M, Nakano M: Hepatopulmonary syndrome can show spontaneous resolution: Possible mechanism of portopulmonary hypertension overlap? *Respirology* 2006;11:120-123.
- 4) Kobayashi S, Aida A, Aoi K, Nishimura M, Kawakami Y: Liver cirrhosis with severe hypoxemia and paradoxical vascular response to graded inspiratory oxygen tension. *Chest* 1993;103:958-960.
- 5) Swanson KL, Wiesner RH, Krowka MJ: Natural history of hepatopulmonary syndrome: impact of liver transplantation. *Hepatology* 2005;41:1122-1129.

- 6) Daoud FS, Reeves JT, Schaefer JW: Failure of hypoxic pulmonary vasoconstriction in patients with liver cirrhosis. *J Clin Invest* 1972;51:1076-1080.
- 7) Naeije R, Hallemans R, Mols P, Melot C: Hypoxic pulmonary vasoconstriction in liver cirrhosis. *Chest* 1981;80:570-574.
- 8) Schenk P, Madl C, Rezaie-Madj S, Muller C: Methylene blue improves the hepatopulmonary syndrome. *Ann Intern Med* 2000;133:701-706.
- 9) Rodríguez-Roisin R, Krowka MJ, Hervé P, Fallon MB; ERS Task Force Pulmonary-Hepatic Vascular Disorders (PHD) Scientific Committee. Pulmonary-Hepatic Vascular Disorders (PHD). *Eur Respir J* 2004;24:861-880.
- 10) Dernaika TA, Beavin M, Kinasewitz GT: Iloprost improves gas exchange and exercise tolerance in patients with pulmonary hypertension and chronic obstructive pulmonary disease. *Respiration* 2010;79:377-382.
- 11) Mukhtar NA, Fix OK: Portopulmonary hypertension. *J Clin Gastroenterol* 2011;45:703-10.

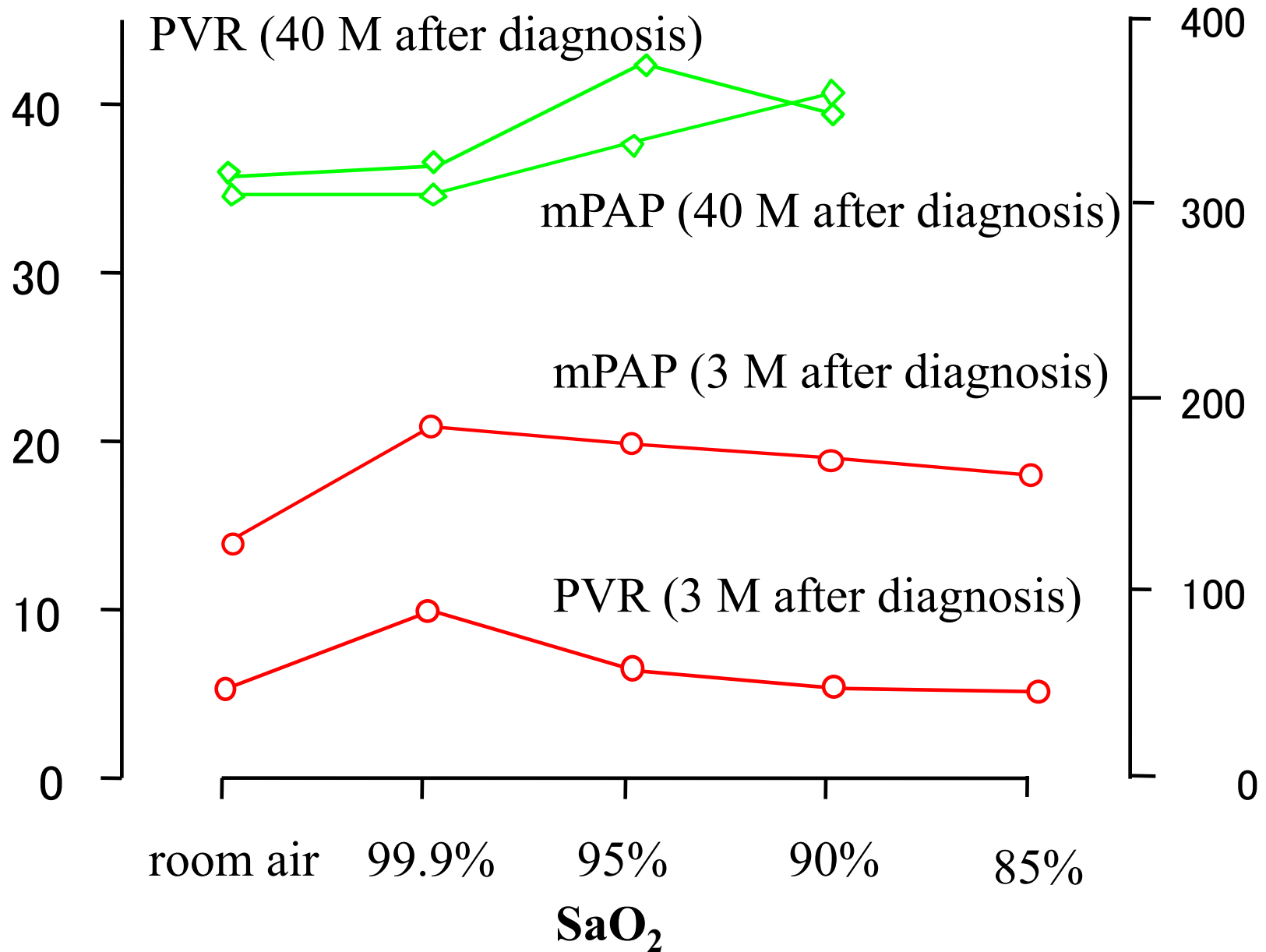
### **Figure legend**

In the first evaluation performed three month after the initial diagnosis, pure O<sub>2</sub> inhalation raised pulmonary vascular resistance (PVR), suggesting that hyperoxia led to vasoconstriction. As SaO<sub>2</sub> was lowered, PVR gradually decreased. When SaO<sub>2</sub> finally reached 85%, PVR was somewhat lower than the initial value, indicating that hypoxia resulted in paradoxical hypoxic vasodilation in the pulmonary artery. In the second evaluation performed 40 months after diagnosis, the baseline pulmonary arterial pressure was elevated, and PVR was even higher than the initial value under hypoxemia, suggesting the presence of pulmonary hypoxic vasoconstriction.



**mPAP (mmHg)**

**PVR (dyn\*s\*cm<sup>-5</sup>)**



**Figure. Pulmonary Vascular Response to Graded Hypoxia.**

# TABLE

## Results of Right-sided Heart Catheterisation and Shunt Value Estimated by a MAA Lung Scan.

Time after Diagnosis	At Diagnosis	3 M	10 M	40 M	62 M
HR beats/min	69	73	66	65	64
SBP s/d/m mmHg	95/57/69	109/59/75	108/66/80	104/64/77	113/64/80
RAP mmHg	3	10	3	8	9
PAP s/d/m mmHg	19/9/12	25/14/20	19/10/13	56/18/36	76/28/48
CO l/min	8.24	8.98	8.49	5.84	5.54
CI l/min/m <sup>2</sup>	4.31	4.70	4.49	3.07	2.27
PVR dynes·s·cm <sup>-5</sup>	29	53	57	370	534
SVR dynes·s·cm <sup>-5</sup>	641	579	726	94	1025
Shunt Value* %	29.3	33.2	41.3	10.3	3.0
PaCO <sub>2</sub> torr	26.6	24.4	26.7	34.5	32.7
PaO <sub>2</sub> torr	63.4	58.2	61.2	77.0	83.1

\* : Shunt Value was estimated by a macroaggregated albumin (MAA) lung perfusion scan.

SBP s/d/m: systemic blood pressure, systolic, diastolic, mean ; RAP: right atricular pressure; PAP: pulmonary arterial pressure; CO: cardiac output; CI: cardiac index; PVR: pulmonary vascular resistance; SVR: systemic vascular resistance.