



Title	In Vivo Vascularity Alterations in Repaired Rotator Cuffs Determined by Contrast-Enhanced Ultrasound
Author(s)	Funakoshi, Tadao; Iwasaki, Norimasa; Kamishima, Tamotsu; Nishida, Mutsumi; Ito, Yoichi; Nishida, Kinya; Motomiya, Makoto; Suenaga, Naoki; Minami, Akio
Citation	American Journal of Sports Medicine, 39(12), 2640-2646 https://doi.org/10.1177/0363546511420077
Issue Date	2011-12
Doc URL	http://hdl.handle.net/2115/50772
Rights	The final, definitive version of this article has been published in the Journal, American Journal of Sports Medicine, 39(12), 2011 of publication, © American Orthopaedic Society for Sports Medicine, 2011 by SAGE Publications Ltd at the American Journal of Sports Medicine page: http://ajs.sagepub.com/ on SAGE Journals Online: http://online.sagepub.com/
Type	article (author version)
File Information	AJSM39-12_2640-2646.pdf



[Instructions for use](#)

Vascularity Alterations in Repaired Rotator Cuffs

***In Vivo* Vascularity Alterations in Repaired Rotator Cuffs Using
Contrast-enhanced Ultrasound**

Vascularity Alterations in Repaired Rotator Cuffs

The alterations in blood flow after rotator cuff repair remain unclear. Visualization of vascular patterns could clarify basic and clinical investigations.

Purpose: To assess longitudinal blood flow inside the repaired cuff and the surrounding tissue after rotator cuff repair, using contrast-enhanced ultrasonography.

Study Design: Controlled laboratory study.

Methods: Fifteen patients (7 men, 8 women, mean age 65.0 ± 9.8 years) consented to their participation. The patients underwent an ultrasound scan before and 1, 2, and 3 months after surgery. Enhanced ultrasound images were recorded for 1 min after intravenous injection of contrast reagent. Four regions of interest inside the cuff, and 2 regions in the anchor hole and subacromial bursa were superimposed on the obtained images. Calculated areas under the time–intensity curves were expressed in acoustic units (AU).

Results: We found area-dependent differences in patterns of alteration and magnitude of blood flow inside the repaired cuff and peritendinous tissues. Vascularity in the articular distal and bursal distal region of the repaired cuff at 1 month postoperatively increased significantly compared with that at the preoperative baseline (76 vs. 5 AU, $P = .0037$, 92 vs. 7 AU, $P = .043$). The vascularity peaked at 1 month after surgery in the bursal area within the cuff, but at 2 months in the articular area. The vascularity in the articular proximal region of the repaired cuff was significantly lower than that in the bursal proximal ($P = .0046$), bursal distal ($P = .0183$), and articular distal regions ($P = .0163$) 1 month after surgery.

Conclusions: Enhancement patterns in intratendinous tissue increased at 1 or 2 months postoperatively and decreased at 3 months. We found area-dependent differences in enhancement patterns inside the repaired cuff and peritendinous tissue.

Vascularity Alterations in Repaired Rotator Cuffs

Clinical Relevance: Visualization of vascularization using contrast-enhanced ultrasound could help in deciding on appropriate repair technique or on the form of postoperative rehabilitation following rotator cuff repair.

Keywords: rotator cuff; contrast-enhanced ultrasound; vascularity; subacromial bursa

Vascularity Alterations in Repaired Rotator Cuffs

The limited healing of a ruptured rotator cuff has been documented in human subjects.^{12,}

¹⁷ Previous studies have shown that 25–90% of repaired rotator cuffs tear again.^{3, 9, 11, 13,}

¹⁵ Revascularization plays a critical role in the healing process of tendon-to-bone insertions. Several histological studies have clarified the vascularity of the rotator cuff.^{10,}

¹⁶⁻¹⁸ However, those studies could not investigate the same subject repeatedly, and the histological studies were performed *in vitro*. Doppler ultrasound (US) has now been

developed for the visualization of small vessels *in vivo*. Although Silvestri et al.²⁰ suggested that Doppler US has limited sensitivity in detecting low flow rates,

microbubble-based US contrast agents have now improved the visualization of low volume and flow rates by increasing the signal-to-noise ratio. Several studies have

reported the feasibility of contrast-enhanced US (CEUS) for visualizing blood flow in the rotator cuff.^{1, 6, 8, 19} **Fealy and his group^{5, 8, 19} showed that although no**

asymptomatic volunteers demonstrated intravenous flow on conventional power Doppler sonography, flow was demonstrated in all of them with contrast.

Therefore, contrast agents allow the visualization of microvascular patterns. Some authors have reported an age-related reduction in blood flow in the intact rotator

cuff,^{6, 19} so microvascular pattern in an elder population would not be similar to that in a young population. Furthermore, a hypovascular pattern inside the tendon

was seen regardless of whether it was ruptured.⁶ A more recent study showed that the major blood supply to the repaired tendon was derived from the peribursal tissues and

the anchor site.⁸ However, any alterations in the blood flow patterns after rotator cuff repair have remained unclear. We hypothesized that the blood flow patterns inside the

tendon and adjacent repaired rotator cuff would change with time following surgery. Therefore, the purpose of this investigation was to use CEUS in evaluating the

alterations in blood flow pattern inside of the repaired cuff and the surrounding tissue after rotator cuff repair. The data obtained here should be useful in investigating the influence of repair techniques on revascularization as a possible risk factor for the repeated tearing of the rotator cuff.

MATERIALS AND METHODS

Data Collection

This study was approved by the Institutional Review Board of our hospital. CEUS imaging data for 15 patients (7 men, 8 women aged 41–80 years, mean 65.0) were collected for further analysis (Table 1). **The criterion for inclusion in this study was a grade 3 partial-thickness tear, according to Ellman’s classification⁴ or a small or medium full-thickness tear according to Cofield’s classification.²** Patients with massive tears were excluded from this study. Diabetes, cardiovascular disease, tobacco use and other vascular conditions were not exclusion criteria. Informed consent for participating in the present study was obtained from each subject. The rationale for selecting this group size was a paired Student’s *t* test of a mean difference with a two-sided significance level of .05, assuming a common standard deviation of 40 units based on a previous study⁶ and correlation of 0.7, a sample size of 15 pairs has a power of 0.828 for detecting a mean difference of 25. **All patients underwent a physical examination before surgery. In the current study, there were 2 partial tears, 2 small tears, and 11 medium tears. The patients underwent 14 arthroscopic rotator cuff repairs and 1 open rotator cuff repair, all of which required at least 1 suture anchor. Twelve patients underwent rotator cuff repair with a surface-holding technique,⁷ 9 with transosseous sutures (Figure 1) and 3 with Mitek super anchors**

(Depuy-Mitek, Raynham, Massachusetts). Two single-row repair techniques were used for 1 small tear and 1 partial tear. One double-row repair technique was used for 1 partial tear (Table 1). Corkscrew titanium anchors (Arthrex, Naples, Florida) or Twin Fix titanium anchors (Smith & Nephew, Andover, Massachusetts) were used as the suture anchors. Eleven edges of the repaired cuffs were refreshed using a shaver or a knife. The other 4 edges of the involved tendons were not touched at the operation. **The arm was supported in a sling with an abduction pillow for 6 weeks postoperatively. Passive-motion exercises were performed after the removal of the drainage tube. At 3 months postoperatively, all patients underwent a physical examination and a magnetic resonance imaging (MRI) scan.**

CEUS

The patients underwent CEUS before and at 1, 2 and 3 months after the operation. **All 60 examinations were performed by a single certified sonographer (N.M.) and a single investigator (F.T.), using an SSA-790A US unit (AplioXG, Toshiba Medical Systems Corp., Otawara, Japan) with a PLT-704AT probe (7.5 MHz linear center frequency).** The imaging mode used was gray-scale Pulse Subtraction using phase inversion-based wideband harmonic imaging (T/R = 4.0/8.0 MHz) with a low mechanical index US exposure. The imaging mode of CEUS was pulse subtraction.

All scans were performed with the shoulder in extension to optimize visualization of the supraspinatus tendon–bone junction. The rotator cuff was imaged in the oblique coronal plane (Figures 2A, 3A). A baseline scan was initially performed to confirm the optimum visualization of the ruptured rotator cuff. After the operation, the proximal anchor hole (AH) was used as a marker to identify the same imaging plane. **We focused**

on the tendon-to-bone insertion rather than the distal AH since the difficulty of standardizing the distal anchor. The distal AH was not investigated in the current study. An intravenous catheter was placed in the contralateral arms of the repaired rotator cuff. The patients underwent CEUS with the intravenous US contrast agent, Sonazoid® (Daiichi Sankyo, Tokyo, Japan) consisting of perfluorobutane microbubbles and lipid shells. This was injected intravenously at a concentration of 0.015 mL/kg, followed by a 10 mL saline flush. The CEUS images were recorded digitally for 1 min after the contrast medium had been injected. No patient experienced any adverse event.

Time–Intensity Curve Analysis of CEUS

The stored images were analyzed using the AplioXG-dedicated software ImageLab (Toshiba Medical Systems Corp., Otawara, Japan). This is prototypical research software, run on consumers' personal computers. It computes the internal dynamic range, gain and provides a color scale with which to calculate the precise antilogged magnitude from the images. The regions of interest (ROIs) in the peritendinous tissue were identified as 2 circles, 150 ± 10 pixels in area covering the subacromial bursa (SAB) and the AH (Figure 3D). The inside of the tendon was evaluated for 4 oval ROIs, 2000 ± 50 pixels in area, bursal proximal (BP), bursal distal (BD), articular proximal (AP) and articular distal (AD) (Figure 3D). These 4 oval-shaped ROIs were defined as the maximally covered positions inside the repaired tendon. Preoperative images were investigated only for the distal tendon (BD and AD) because of the difficulty in evaluating the **proximal** side of the tendon using CEUS (Figure 2D). To envisage the vascular pattern in detail, relatively small ROIs were examined intensely for the bursa and AH. Conversely, we used relatively large ROIs to evaluate the inside of the tendon

compared with the bursa or anchor because unacceptable dispersion was observed there (Figures 2D, 3D).

A time–intensity curve was calculated using an original program (Figures 2C, 3C). The data obtained were normalized for each shoulder relative to the baseline magnitude using an average from the first 280 frames (about 18 s). The values for the areas under the time–intensity curves were used for statistical analysis and were expressed as acoustic units (AU, time-dB). All analyses were performed in a blinded fashion and not in real time by a single investigator.

Statistical Analysis

All statistical analyses were performed with Excel 2000 (Microsoft Corp., Redmond, Washington), JMP 8.0 (SAS Institute, Cary, North Carolina), and SAS 9.2 (SAS Institute, Cary, North Carolina). The means of 2 repeated measurements were used for all analyses. **Multiple comparisons in the repeated measures model²³ were used for the statistical analysis of AU in the intratendinous regions (BD, BP, AD, and AP). Although the same method was used to compare the means in the peritendinous tissue regions (SAB and AH), we could not compare the enhancement patterns inside the tendon with those in the peritendinous tissue because of differently sized ROIs. A probability of < .05 was considered significant. Linear regression analyses were employed to determine the correlations between age and vascularity in the preoperative subjects. Intraobserver reproducibility was calculated on the basis of 2 consecutive measurements. An intraclass correlation coefficient (ICC) of 1.0 represents perfect agreement, and ICC = 0 suggests that the measurements are entirely random. Appropriate reproducibility of intraobserver values depends on**

how one defines clinical agreement for the analysis. In this study, when the ICC was 0.80 or over, the reproducibility was considered acceptable.

RESULTS

No patients had any obvious complications from the intravenous contrast agent used and the MRI images of all patients showed no obvious reruptured cuff 3 months postoperatively. **The ranges of motion had improved in all patients at 3 months after surgery (138.7 ± 12.6 degrees of flexion and 31.0 ± 12.6 degrees of external rotation) compared with their preoperative ranges of motion (92.3 ± 18.5 degrees of flexion and 5.0 ± 4.3 degrees of external rotation). There was no obvious correlation between age and vascularity in the current study.**

Postoperative Alterations in Blood Flow inside the Repaired Cuff

In all preoperative images, the CEUS procedures showed that the mean (\pm SD) vascularity values inside the supraspinatus tendon were less than 10 AU (Table 2). According to a previous report,⁶ this confirms the preoperative presence of a hypovascular pattern inside the supraspinatus tendon. Basically, vascularity inside of the repaired cuff increased at 1 or 2 months postoperatively and then decreased at 3 months (Figure 4, Table 2). Vascularity in the BD and AD at 1 month postoperatively increased significantly compared with that at the preoperative baseline (92 vs. 7 AU, $P = .043$, and 76 vs. 5 AU, $P = .0037$, respectively; Figure 4). Different peak enhancement patterns were observed in each area inside the repaired tendon (Figure 4). Vascularity of the bursal area (BP and BD) peaked at 1 month postoperatively, whereas the maximum vascularity of the articular area (AP and AD) was seen at 2 months postoperatively.

Vascularity Alterations in Repaired Rotator Cuffs

Evaluation of the torn end of the cuff using CEUS had an inherent limitation because it prevented the visualization of the more proximal regions of the ruptured cuff. Therefore, we have no preoperative data for the BP and AP regions. **We selected the proximal AH as a marker to identify the same imaging plane in the present study. Therefore, we could not find the suture site where it pierced the tendon in some subjects. No typically altered pattern in the blood flow at the suture site was identified in this study.**

Area-dependent Differences in Blood Flow inside the Repaired Cuff

We found area-dependent differences in blood flow enhancement in the 4 different areas inside the repaired cuff. There was significantly lower blood flow in the AP compared with the BP, BD, and AD at 1 month, respectively (30 vs. 141, 92, and 76 AU, $P = .0046$, $.0183$, and $.0163$; Figure 4; Table 2). **Vascularity in the AD was significantly higher than in the BD at 2 month postoperatively (93 vs. 52 AU, $P = .0132$).** There were no significant differences in the AU measures among the other areas at 3 months postoperatively.

Postoperative Alterations of Blood Flow in the Peritendinous Tissue

We then focused on enhancement patterns in the AH and SAB as factors affecting tendinous vascularity. There was no obvious enhancement **on the footprint** before surgery. However, enhancement was clearly seen in the **proximal AH** at the postoperative evaluation in all patients (Figure 5, Table 2). The enhancement in the AH increased and remained elevated for up to 3 months. Conversely, alteration of the enhancement pattern in SAB differed from that in the AH. Vascularity in the SAB at 1

Vascularity Alterations in Repaired Rotator Cuffs

month postoperatively was significantly higher than at preoperative evaluation (255 vs. 137 AU, respectively, $P = .0037$). Although there were no statistically significant differences in vascularity between 1 and 2 months or 2 and 3 months, vascularity in the SAB tended to decrease at 2 or 3 months. The mean vascularity in the SAB after 2 and 3 months postoperatively was quite similar to its preoperative magnitude. Therefore the blood flow in the SAB had an obvious peak at 1 month postoperatively and had recovered to the preoperative level by 2 months after surgery (Figure 5).

ICC for Intraobserver Reproducibility

The ICC for intraobserver reproducibility was 0.87 (95% confidence interval, 0.79–0.92). The agreement in intraobserver variations during the analysis of CEUS after cuff repair was almost acceptable.

DISCUSSION

The most notable contribution of this study is a longitudinal description of blood flow in the intratendinous tissue after rotator cuff repair. We also found area-dependent differences in patterns of alteration and magnitude of blood flow inside the repaired cuff and peritendinous tissues.

Several authors have reported enhanced blood flow patterns in rotator cuff tissues using CEUS.^{1, 6, 8, 19} **A previous study⁶ reported hypovascular patterns in the intact and torn cuffs in elderly subjects. That report implied theoretical hypovascularity in the proximal side of the cuff, although we could not evaluate the same region before surgery.** Using Doppler US, another study demonstrated that the vascularity

score decreased from 6 weeks to 6 months after rotator cuff repair.⁵ Our findings revealed alterations in enhancement pattern inside the repaired cuff at 3 monthly time points postoperatively. **Of interest, a dramatic alteration of microvascular pattern was found inside of torn cuff, even though the subjects were elderly. In the current study, no obvious correlation was found between age and obtained AU. However, the effects exerted by the ruptured cuff and the surgical technique used to repair it could not be analyzed statistically in the current study. Moreover, massive cuff tears were excluded from the study because they were visually obstructed by the acromion bone. The tear-size-dependent differences in the patterns of change and the magnitude of the blood flow within the repaired cuff should be considered. Further study is required to clarify these size-dependent differences.**

The other important finding of this study is the area-dependent differences in magnitude of blood flow inside the repaired cuff. The vascular enhancement in the BP, BD, and AD regions inside tendon was significantly higher than that in the AP region at 1 month postoperatively. Several histological evaluations have suggested that the bursa plays an important role in the healing process,^{14,21,22} and our *in vivo* visualization of the postoperative vascular patterns showed that the bursa plays an important role via the revascularization on the bursal side. We also found that alteration of enhancement patterns differed between the bursal and articular sides. Blood flow enhancement in the bursal area (BP and BD) inside the cuff was increased at 1 month postoperatively and gradually decreased by 2 and 3 months. The enhancement on the bursal side of the cuff altered in parallel with that in the SAB. Conversely, postoperative peak enhancement on the articular side of the cuff (AP and AD) occurred later than in the bursal side of the

Vascularity Alterations in Repaired Rotator Cuffs

cuff. These findings indicate that the blood supply **from the bony surface** may be associated with the revascularization in the articular proximal area in the tendon-to-bone interface. We consider that the blood flow in AH provides the neovascularization on the articular side of the cuff because the enhancement in AH remained at the same level from 1 month to 3 months after surgery.

Within the peritendinous tissue, the enhancement of vascularity in the SAB was significantly higher than that in the AH at 1 month postoperatively. Although the enhancement on the articular side of the repaired cuff was less than that on the bursal side, the neovascularization from the anchor hole would have been an important factor ensuring cuff integrity. Recent histological findings have showed that healing occurs more quickly at the most firmly held points at the sutured site.²¹ In the present study, low and late enhancement patterns on the articular side of the repaired cuff prolonged the time required for firm contact to be achieved between the articular-side tendon and the bone surface. Sonnabend et al²¹ showed that the surgical removal of the hyaline cartilage at the site of the bone–tendon repair appeared to contribute little to the healing process. The remnant of torn cuff and cortical bone on the footprint were removed in the present series. We could find no hypervascular patterns in the resurfaced footprint in most images after surgery. However, the postoperative images showed obvious enhancement in the proximal AH. The relationship between the postoperative vascularity and the healing process should be investigated in future basic studies.

Our study had several technical and inherent limitations. First, **we evaluated differences in only single plane (articular/bursal, proximal/distal)**. Because we could not investigate the three-dimensional differences in vascularity enhancement inside the cuff, all factors could not be investigated simultaneously in any particular

Vascularity Alterations in Repaired Rotator Cuffs

session in which the data were acquired. The structures comprising the repaired cuff, the proximal and distal AH, the proximal sutures passing to the tendon, and the bridging suture threads were all of different dimensions. In this study, we could only measure alterations of vascularity enhancement in the tendon and peritendinous tissues around the proximal AH, because the proximal AH was marked, to allow repeated scans to be performed in the same position. Second, the magnitude of vascularity measured in the intratendinous regions might not correctly indicate the magnitude of blood flow on CEUS. In the US images, collagen fibers in the tendon appeared either as a dark amorphous area or as a bright area with a fibrillar pattern. However, the healing of the collagen fibrils in the repaired tendon might affect the AU measures. The altered baseline vascularity measured by AU is an inherent artifact in gray-scale CEUS. **Finally, this study included heterogeneous background variables, such as age (young vs old), tear size (partial vs full thickness), vascular conditions (with and without diabetes), and treatments (arthroscopic vs open, single row vs double row). These factors could have affected our results. The number of anchors depends on the size of the cuff tear and the suture fashion. Although 1 anchor was used in the single-row repair technique, a variety of sizes, positions, and numbers of anchors were used for the other repair techniques. The lack of standardization of the repair technique would have been a limitation in the current study.**

In conclusion, this investigation has revealed area-dependent alterations in blood flow enhancement in the intratendinous tissue of repaired rotator cuffs. Vascularity in the proximal bursal part of the cuff was increased at 1 month postoperatively compared with the preoperative value and then decreased over time. Maximum enhancement in the articular part of the cuff was seen at 2 months postoperatively. Our findings should

Vascularity Alterations in Repaired Rotator Cuffs

help to clarify the process of revascularization at the tendon-to-bone interface *in vivo*. Visualization of this revascularization and angiogenesis could be useful in selecting the appropriate suture type or the patient's postoperative rehabilitation course.

REFERENCES

1. Adler RS, Fealy S, Rudzki JR, et al. Rotator cuff in asymptomatic volunteers: contrast-enhanced US depiction of intratendinous and peritendinous vascularity. *Radiology*. 2008;248(3):954–961.
2. Cofield RH, Parvizi J, Hoffmeyer PJ, Lanzer WL, Ilstrup DM, Rowland CM. Surgical repair of chronic rotator cuff tears. A prospective long-term study. *J Bone Joint Surg Am*. 2001;83-A(1):71–77.
3. Cummins CA, Murrell GA. Mode of failure for rotator cuff repair with suture anchors identified at revision surgery. *J Shoulder Elbow Surg*. 2003;12(2):128–133.
4. Ellman H. Diagnosis and treatment of incomplete rotator cuff tears. *Clin Orthop Relat Res*. 1990(254):64–74.
5. Fealy S, Adler RS, Drakos MC, et al. Patterns of vascular and anatomical response after rotator cuff repair. *Am J Sports Med*. 2006;34(1):120–127.
6. Funakoshi T, Iwasaki N, Kamishima T, et al. In vivo visualization of vascular patterns of rotator cuff tears using contrast-enhanced ultrasound. *Am J Sports Med*. 2010;38(12):2464–2471.
7. Funakoshi T, Suenaga N, Sano H, Oizumi N, Minami A. In vitro and finite element analysis of a novel rotator cuff fixation technique. *J Shoulder Elbow Surg*. 2008;17(6):986–992.
8. Gamradt SC, Gallo RA, Adler RS, et al. Vascularity of the supraspinatus tendon three months after repair: characterization using contrast-enhanced ultrasound. *J Shoulder Elbow Surg*. 2009;19(1):73–80.
9. Gerber C, Fuchs B, Hodler J. The results of repair of massive tears of the rotator cuff. *J Bone Joint Surg Am*. 2000;82(4):505–515.

Vascularity Alterations in Repaired Rotator Cuffs

10. Goodmurphy CW, Osborn J, Akesson EJ, Johnson S, Stanescu V, Regan WD. An immunocytochemical analysis of torn rotator cuff tendon taken at the time of repair. *J Shoulder Elbow Surg.* 2003;12(4):368–374.
11. Harryman DT 2nd, Mack LA, Wang KY, Jackins SE, Richardson ML, Matsen FA 3rd. Repairs of the rotator cuff. Correlation of functional results with integrity of the cuff. *J Bone Joint Surg Am.* 1991;73(7):982–989.
12. Hawkins RJ, Misamore GW, Hobeika PE. Surgery for full-thickness rotator-cuff tears. *J Bone Joint Surg Am.* 1985;67(9):1349–1355.
13. Jost B, Zumstein M, Pfirrmann CW, Gerber C. Long-term outcome after structural failure of rotator cuff repairs. *J Bone Joint Surg Am.* 2006;88(3):472–479.
14. Koike Y, Trudel G, Uhthoff HK. Formation of a new enthesis after attachment of the supraspinatus tendon: a quantitative histologic study in rabbits. *J Orthop Res.* 2005;23(6):1433–1440.
15. Liu SH, Baker CL. Arthroscopically assisted rotator cuff repair: correlation of functional results with integrity of the cuff. *Arthroscopy.* 1994;10(1):54–60.
16. Longo UG, Franceschi F, Ruzzini L, et al. Histopathology of the supraspinatus tendon in rotator cuff tears. *Am J Sports Med.* 2008;36(3):533–538.
17. Matthews TJ, Hand GC, Rees JL, Athanasou NA, Carr AJ. Pathology of the torn rotator cuff tendon. Reduction in potential for repair as tear size increases. *J Bone Joint Surg Br.* 2006;88(4):489–495.
18. Moseley HF, Goldie I. The arterial pattern of the rotator cuff of the shoulder. *J Bone Joint Surg Br.* 1963;45:780–789.
19. Rudzki JR, Adler RS, Warren RF, et al. Contrast-enhanced ultrasound characterization of the vascularity of the rotator cuff tendon: age- and activity-related

Vascularity Alterations in Repaired Rotator Cuffs

changes in the intact asymptomatic rotator cuff. *J Shoulder Elbow Surg.* 2008;17(1 Suppl):96S–100S.

20. Silvestri E, Biggi E, Molfetta L, Avanzino C, La Paglia E, Garlaschi G. Power Doppler analysis of tendon vascularization. *Int J Tissue React.* 2003;25(4):149–158.

21. Sonnabend DH, Howlett CR, Young AA. Histological evaluation of repair of the rotator cuff in a primate model. *J Bone Joint Surg Br.* 2010;92(4):586–594.

22. Uhthoff HK, Sarkar K. Surgical repair of rotator cuff ruptures. The importance of the subacromial bursa. *J Bone Joint Surg Br.* 1991;73(3):399–401.

23. Westfall PH, Randall DT, Dror R, Russell DW, Yosef H. *Multiple Comparisons and Multiple Tests Using the SAS System.* Cary, North Carolina: SAS Institute Inc.; 1999:213–217.

FIGURE LEGENDS

Figure 1. Ultrasound technique used to evaluate rotator cuff tears. The probe was positioned longitudinally to the supraspinatus tendon. Surface-holding with a transosseous technique was used for cuff repair. SSP, supraspinatus tendon; Deltoid, deltoid muscle.

Figure 2. Preoperative ultrasonography of a torn rotator cuff (subject #13). a, B-mode image. HH, humeral head; SSP, supraspinatus tendon; deltoid, deltoid muscle. b, A schematic depiction of Figure 2A. HH, humeral head; SSP, supraspinatus tendon; Deltoid, deltoid muscle. c, Time–intensity curves for each region of interest (ROI) imaged with contrast-enhanced ultrasound (CEUS). d, CEUS image (same plane as in A). Three ROIs are shown: SAB, subacromial bursa (orange dot); BD, bursal distal tendon (dark green oval) and AD, articular distal tendon (light green oval).

Figure 3. Ultrasonography of the repaired cuff at 1 month postoperatively (subject #13). a, B-mode image; AH, anchor hole; SSP, supraspinatus tendon; Deltoid, deltoid muscle. b, A schematic depiction of Figure 3A. SSP, supraspinatus tendon; Deltoid, deltoid muscle c, Time–intensity curves for each region of interest (ROI) imaged using contrast-enhanced ultrasound (CEUS). d, CEUS image (same plane as for 3A). Six ROIs are shown: SAB, subacromial bursa (orange dot); AH, anchor hole (purple dot); BD, bursal distal tendon (dark green oval); AD, articular distal tendon (light green oval); BP, bursal proximal tendon (pink oval); AP, articular proximal tendon (light pink oval).

Figure 4. Alterations in vascularity measured in acoustic units (AU) inside the tendon are shown. Preoperative data on the BP and AP regions were not collected. Vascularity inside the repaired cuff increased and then decreased over 3 months postoperatively.

Vascularity Alterations in Repaired Rotator Cuffs

Vascularity in the AD and BD at 1 month postoperatively increased significantly compared with that at the preoperative baseline (*76 vs. 5 AU, respectively, $P = .0037$, *92 vs. 7 AU, respectively, $P = .043$). Vascularity in the AP was significantly lower than in the BP, BD, and AD at 1 month postoperatively (**30 vs. 141, 92, and 76 AU, respectively, $P = .0046$, $.0183$, and $.0163$). Vascularity in the AD was significantly higher than in the BD at 2 month postoperatively (+93 vs. 52 AU, respectively, $P = .0132$). BP, bursal proximal tendon; BD, bursal distal tendon; AP, articular proximal tendon; AD, articular distal tendon.

Figure 5. Alterations in vascularity in the subacromial bursa and anchor hole are shown. Vascularity in the SAB at 1 month after surgery was significantly higher than that at baseline (*preoperative AU value vs. 1 month in the SAB, respectively, $P = .0037$). Vascularity in the AH increased and persisted up to 3 months postoperatively. SAB, subacromial bursa; AH, anchor hole.

Vascularity Alterations in Repaired Rotator Cuffs

TABLE 1 Patient Data^a

Patient Data					Condition of Ruptured Cuff			Surgical Technique		
No.	Age	Sex	Injured Side	Occupation	Tear Size (cm ²)	Tear Type	Trauma	Treatment	Refreshment	No. of Anchors
1	73	M	R	Retired	3 x 3	Full-thickness	Y	SH anchor	Yes	3
2	80	M	R	Retired	1 x 1	BPRCT	Y	DR	Yes	2
3	58	F	R	Housewife	1 x 2	Full-thickness	N	SH trans	No	2
4	41	M	R	Carpenter	2 x 2	Full-thickness	Y	SH anchor	No	2
5	60	F	L	Employee	2 x 2	Full-thickness	N	SH trans	Yes	2
6	61	F	L	Factory Worker	2 x 3	Full-thickness	N	SH anchor	Yes	2
7	63	M	R	Teacher	3 x 3	Full-thickness	N	SH trans	Yes	2
8	64	M	R	Farmer	3 x 3	Full-thickness	Y	SH trans	No	1
9	73	F	R	Housewife	2 x 3	Full-thickness	N	SH trans	Yes	1
10	60	F	R	Housewife	3 x 3	Full-thickness	N	Open SH	No	1

Vascularity Alterations in Repaired Rotator Cuffs

11	65	F	R	Housewife	1 x 2	Full-thickness	N	SR	Yes	1
12	73	F	R	Housewife	2 x 3	Full-thickness	N	SH trans	Yes	1
13	74	M	R	Retired	3 x 3	Full-thickness	N	SH trans	Yes	2
14	74	M	R	Retired	3 x 3	Full-thickness	N	SH trans	Yes	1
15	56	F	L	Housewife	1 x 1	BPRCT	Y	SR	Yes	1

Key: ^aTrauma: Y, obvious traumatic history; N, no obvious traumatic history. SH, surface-holding technique; DR, double-row repair; SR, single-row repair; BPRCT, bursal-side partial rotator cuff tear; trans, transosseous repair technique.

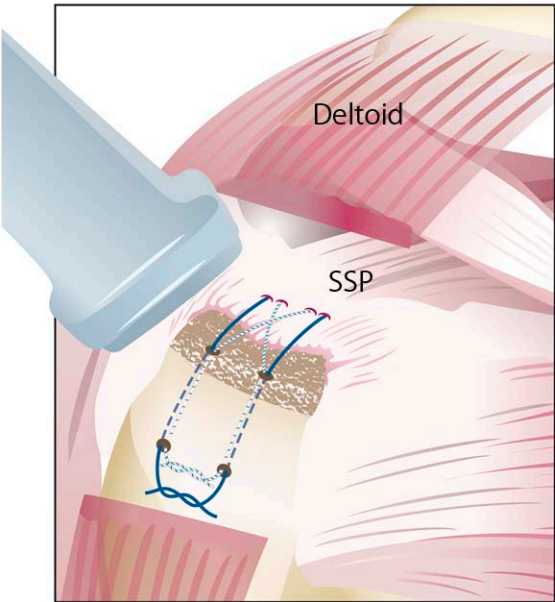
Vascularity Alterations in Repaired Rotator Cuffs

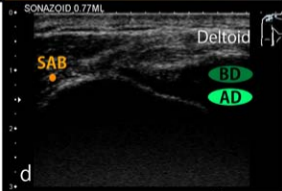
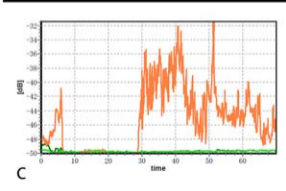
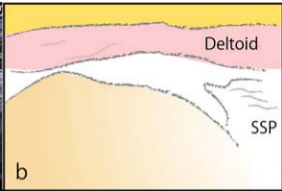
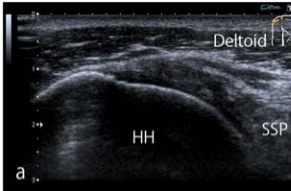
TABLE 2

Area Under the Curve Over Time in Acoustic Units^a

	Inside Cuff				Peritendinous Tissue	
	BP	BD	AP	AD	AH	SAB
Preoperative	NA	7	NA	5	0	137
1 month	141	92	30	76	177	255
2 months	95	52	58	93	172	152
3 months	80	33	58	45	142	165

Key: ^aBP, bursal proximal tendon; BD, bursal distal tendon; AP, articular proximal tendon; AD, articular distal tendon; AH, anchor hole; SAB, subacromial bursa.





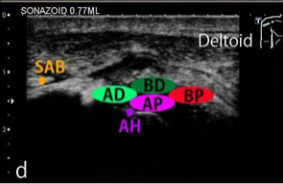
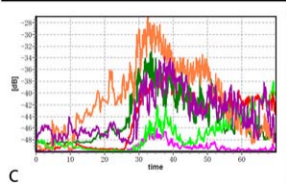
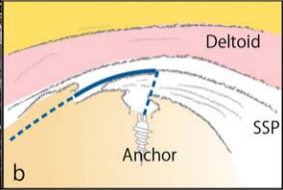
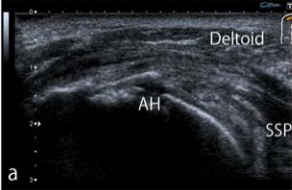


Figure 4

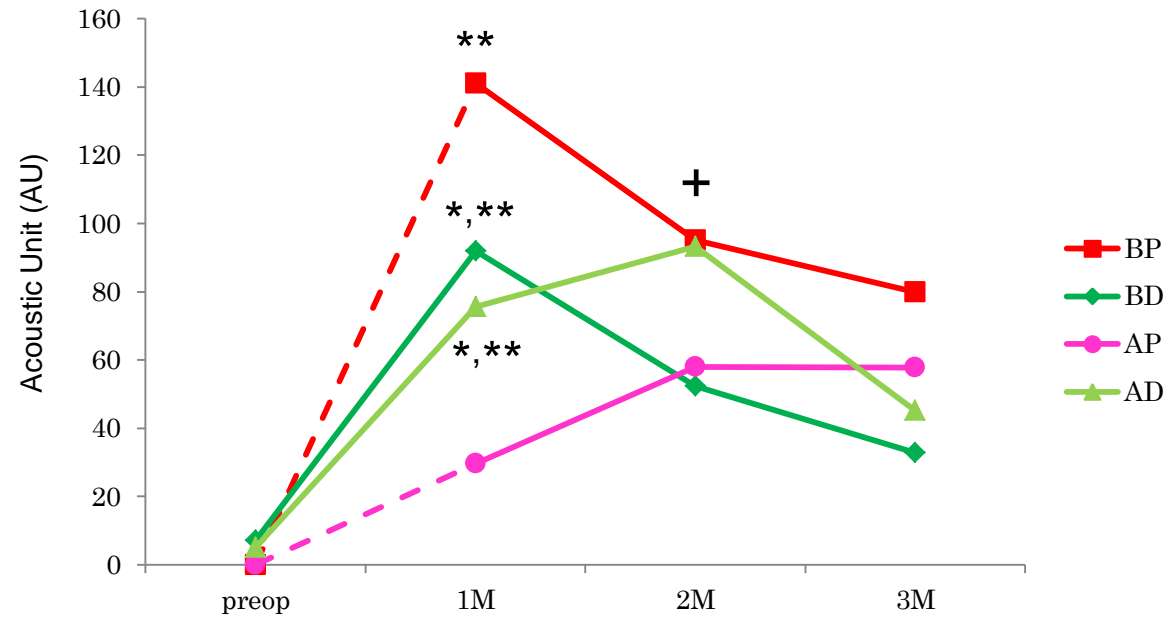


Figure 5

