



Title	Autoimmune pancreatitis associated with hemorrhagic pseudocysts: a case report and literature review.
Author(s)	Kawakami, Hiroshi; Kuwatani, Masaki; Shinada, Keisuke; Yamato, Hiroaki; Hirano, Satoshi; Kondo, Satoshi; Yonemori, Atsuya; Itoh, Tomoo; Matsuno, Yoshihiro; Asaka, Masahiro
Citation	Internal medicine, 47(7), 603-608 https://doi.org/10.2169/internalmedicine.47.0731
Issue Date	2008
Doc URL	http://hdl.handle.net/2115/47172
Type	article (author version)
File Information	IM47-7_603-608.pdf



[Instructions for use](#)

**Autoimmune pancreatitis associated with hemorrhagic pseudocysts: a case report
and literature review**

Hiroshi Kawakami¹, Masaki Kuwatani¹, Keisuke Shinada¹, Hiroaki Yamato¹,
Satoshi Hirano², Satoshi Kondo², Atsuya Yonemori³, Tomoo Itoh³, Yoshihiro Matsuno³,
& Masahiro Asaka¹

¹ Department of Gastroenterology, Hokkaido University Graduate School of Medicine,
Sapporo, Japan

² Department of Surgical Oncology, Hokkaido University Graduate School of Medicine,
Sapporo, Japan

³ Department of Surgical Pathology, Hokkaido University Hospital, Sapporo, Japan

Address correspondence to: Hiroshi Kawakami MD, PhD

Department of Gastroenterology, Hokkaido University Graduate School of Medicine,
Kita 15, Nishi 7, Kita-ku, Sapporo, 060-8638, Japan.

TEL: +81 11 716 1161 (Ext 5920). FAX: +81 11 706 7867.

E-mail: hiropon@med.hokudai.ac.jp (H.Kawakami)

Running Head: Autoimmune pancreatitis with pseudocyst

Abstract

Autoimmune pancreatitis (AIP) is a new category of pancreatic diseases. AIP associated with pseudocysts is rare; only 8 cases have been reported in the literature. A 63-year-old man was admitted to our department because of upper left abdominal pain and back pain. Various imaging studies demonstrated swelling of the tail of the pancreas with hemorrhagic pseudocysts. The patient underwent a surgical operation. A pancreatogram of the specimen revealed total occlusion of the main pancreatic duct in the tail of the pancreas. Histopathological examination revealed that it was AIP with hemorrhagic pseudocysts.

Key Words: Autoimmune pancreatitis; Pancreatic cyst; Pseudocyst

Introduction

Autoimmune pancreatitis (AIP) is a unique form of chronic pancreatitis characterized by a high serum IgG4 concentration and complications involving a variety of extrapancreatic lesions. Various imaging findings show pancreatic swelling, irregular narrowing of the main pancreatic duct, and stenosis of the lower bile duct. Histopathological examination shows extensive proliferation of lymphocytes, plasma cell infiltration, and fibrosis with infiltration of many IgG4-bearing plasma cells (1). For the diagnosis of AIP, the Japan Pancreas Society proposed a revision of clinical criteria in 2006 (2), but little is known about a possible direct association of AIP and pancreatic pseudocysts. AIP associated with hemorrhagic pseudocysts is rare. Herein, we present such a rare case.

Case report

In May 2007, a 63-year-old male was referred to our department for further examination because of liver dysfunction since 1997, although it was asymptomatic. He had no drinking habit and no personal or family history of liver or pancreatic disease. The abdomen was soft; no mass was palpable. Laboratory data were as follows: total bilirubin (T. Bil), 0.7 mg/dL (normal range: 0.2-1.2); aspartate aminotransferase (AST), 66 IU/L (5-40); alanine aminotransferase (ALT), 55 IU/L (4-45); lactate dehydrogenase (LDH), 174 IU/L (119-229); gammaglutamyl transpeptidase (γ -GTP), 43 IU/L (7-77); alkaline phosphatase (ALP), 230 IU/L (103-335); amylase, 351 IU/L (43-131); lipase, 1026 U/mL (13-49); trypsin, 1026 ng/mL (101-480); elastase-I, 971 ng/dL (<400); γ -globulin, 4.17 g/dl (0.69-1.66), IgG, 4460 mg/dl (870-1700); IgG4, 1200 mg/dL

(4.8-105); IgE, 1958.2 IU/mL (<400); C-reactive protein (CRP), 0.02 mg/dL (<0.39); soluble interleukin-2 receptor, 860 U/mL (<459); HBV DNA, $1.0 \times 10^{3.9}$ copies/mL (< $1.0 \times 10^{2.6}$); HCV RNA, 56 KIU/mL (<0.5); white blood cell count (WBC), 3700/ μ L (3500-9300), hemoglobin level, 13.1 g/dL (13.4-17.6); and platelet level, 18.9×10^4 / μ L (12-40). The fasting blood glucose level was 114 mg/dL (<110), and hemoglobin A_{1C} was 5.6% (<5.8). Antinuclear antibody (ANA) was positive (1:160) (normal range: 0-1:20), and anti double-stranded DNA antibody (ds-DNA-Ab) was <5 U/mL (0-10), and rheumatoid factor (RF) was <9.5 IU/ml (0-16.3). Anti-Sjögren's syndrome (SS)-A antibody and anti-SS-B antibody were negative. Tumor marker values were as follows: alpha-fetoprotein (AFP), 3.8 ng/ml (<10); carcinoembryonic antigen (CEA), 3.8 ng/mL (1.0-6.5); carbohydrate-associated antigen 19-9 (CA19-9), 32.4 U/mL (<37); and DUPAN-2, 95 U/mL (<150).

Ultrasonography (US) demonstrated no swelling and no dilatation of the main pancreatic duct in the head or body of the pancreas. However, imaging the tail of the pancreas was impossible and dilatation of the intrahepatic bile duct was not found by US. Portal phase-enhanced computed tomography (CT) revealed swelling and a low contrast margin expressed as a capsule-like low-density rim in the tail of the pancreas associated with pancreatic cysts (Fig. 1A). Endoscopic ultrasonography (EUS) showed hypoechoic pancreatic parenchyma with scattered high-echo spots in the enlarged area associated with pseudocysts in the tail of the pancreas (Fig. 1B). Based on the clinical, laboratory and imaging findings, the patient was diagnosed as having chronic hepatitis and suspected of having AIP. Endoscopic retrograde cholangiopancreatography (ERCP) for the pancreatic lesion was not performed because informed consent was not obtained.

The patient was not monitored with laboratory data or CT at regular intervals at his request.

In August 2007, the patient was admitted to our department because of upper left abdominal pain and back pain of sudden onset. On admission, he had spontaneous severe pain and tenderness at the left upper abdomen. Laboratory test data were as follows: T. Bil, 0.5 mg/dL; AST, 45 IU/L; ALT, 47 IU/L ; LDH, 143 IU/L; γ -GTP, 29 IU/L; ALP, 258 IU/L; amylase, 143 IU/L; lipase, 97 U/mL; trypsin, 442 ng/mL; elastase-I, 553 ng/dL; γ -globulin, 3.89 g/dl, IgG, 5343 mg/dl; IgG4, 1160 mg/dL; CRP, 4.41 mg/dL; WBC, 8200/ μ L, hemoglobin level, 11.9 g/dL; and platelet level, 19.2×10^4 / μ L. The fasting blood glucose level was 116 mg/dL. Tumor marker values were as follows: AFP, 2.3 ng/ml; CEA, 2.9 ng/mL; CA19-9, 32.1 U/mL; DUPAN-2, 94 U/mL.

While portal phase-enhanced CT revealed localized enlargement and a contrast effect in the tail of the pancreas similar to the findings at the initial CT, plain and enhanced CT showed enlargement of the pseudocysts due to intracystic hemorrhage, and the hemorrhage extended to the dorsal side of the stomach (Fig. 2 A-C). EUS showed a similar echoic level of the pancreas and enlargement of the pseudocysts with hemorrhage similar to the findings at the initial EUS.

The enlargement of the pseudocysts with hemorrhage was associated with the upper left abdominal pain and back pain. As the initial treatment on admission, the patient received intravenous fluids and was forbidden to have any oral intake. Intravenous administration of a protease inhibitor and antibiotics and peroral administration of 50 mg of pentazocine for pain control were started. Inflammatory response (WBC and CRP) was slightly reduced, but physical examination results were not improved. Distal

pancreatectomy with concomitant resection of the spleen was performed with the preoperative diagnosis of AIP associated with hemorrhagic pseudocysts that had intraperitoneal rupture. A pancreatogram of the resected specimen revealed total occlusion of the main pancreatic duct in the tail of the pancreas (Fig. 3). Gross appearance of the resected specimen was a white nodular mass, measuring 3.0×2.5 cm, with cystic lesions, measuring 4.5×3.0 cm at the greatest dimension. Imaging of the cut surface of the pancreatic tail showed whitish matter inside the dilated peripheral pancreatic duct, which was not detected preoperatively; the whitish matter was accumulated protein plaques (Fig. 4).

Histopathological examination revealed significant lymphoplasmatic infiltration and fibrosis in the tail of the pancreas (Fig. 5A). Immunohistochemistry revealed numerous IgG4-positive plasma cells that had inflated the pancreas (Zymed, Carlsbad, CA; dilution 1:500) (Fig. 5B). The resected cysts had no epithelial cells (Fig. 5C), and the inner surfaces were covered with fibrinohemorrhagic exudative tissue and granulation tissue. The postoperative course was uneventful and the patient was discharged after eight days. Two months after the operation, the serum IgG4 concentration was not lowered (1190 mg/dL); however, this symptom was not a recurrence. ERCP revealed normal findings of the main pancreatic duct in the residual pancreas and both intrahepatic and extrahepatic bile ducts. No complication of sclerosing sialadenitis, retroperitoneal fibrosis, orbital pseudocumor or Riedel's thyroiditis has been found to date, and the patient is under observation as an outpatient.

Discussion

We herein described a case of AIP associated with hemorrhagic pseudocysts. AIP is a peculiar type of pancreatitis presumed to be of autoimmune etiology. A revision of clinical criteria for diagnosis of AIP was proposed by the Japan Pancreas Society in 2006. (2) AIP has many features clinically, serologically, morphologically, and histopathologically. Since the concept of AIP is widespread, it has come to be diagnosed on the basis of a combination of those features. They have included radiological findings of pancreatic parenchyma (diffuse or localized swelling of the pancreas) and pancreatic duct (narrowing of the main pancreatic duct); however, little is known about a direct association of AIP and pancreatic cyst.

Studies have shown that non-neoplastic pancreatic cysts accompanying AIP include two types: retention cysts (3) and pseudocysts (4-11). Histopathological study has so far been carried out only on a limited number of surgically treated cases, and there has been no discussion on which type of cyst is more likely to develop. Further study of such cases is needed.

There have been only 8 cases of pseudocysts associated with AIP prior to the present case (Table 1) (4-11). Intracystic hemorrhage was reported in one of the 8 cases, but it was minor bleeding and spontaneously healed (5). Intraperitoneal rupture of hemorrhagic pseudocysts as in the present case has not been reported previously.

Corticosteroid treatment in AIP patients is clinically, morphologically, and serologically effective and has become accepted as a standard treatment for AIP. Previous studies have shown that corticosteroid treatment is effective in AIP patients in the short term (11). Long-term prognoses for patients with AIP, including patients who

received corticosteroid treatment, have recently been reported (9). It should be noted that corticosteroid treatment carries the risk of a variety of adverse effects, including susceptibility to infection, impaired glucose tolerance, peptic ulcer and osteoporosis. Thus, it still remains to be determined whether corticosteroid treatment is necessary for all patients with AIP. In fact, conditions improve spontaneously in some AIP patients (12,13). Four cases of pseudocysts associated with AIP were treated with corticosteroid, and the pseudocysts disappeared in three of them.

Nishimura et al (6) suggested that the severe narrowing of the branched pancreatic ducts might be responsible for the regrowth of pseudocysts. Corticosteroid treatment possibly ameliorated the narrowing of the pancreatic duct and released pancreatic juice, which induced rapid resolution of pancreatic ducts; cyst formation in AIP patients might represent a highly active state of the inflammatory process. The pancreatogram findings and results of histological examination, the present case suggested an etiological mechanism similar to that proposed by Nishimura et al (6). Since we did not perform ERCP at our initial attempt at diagnosis, because informed consent had not been obtained, we cannot exclude the possibility that we might have observed therapeutic effects of corticosteroid treatment if we had been able to make a definite diagnosis of AIP by performing ERCP and performed treatment. However, considering that the pancreatic duct was completely occluded and that protein plaques, histopathologically related to pancreatic stricture, were present, we speculate that chronic changes had been occurring in the pancreatic stricture, which were irreversible, and thus corticosteroid treatment would not have been effective, if applied at the operation.

Recently, Hirano et al (9) reported that a growing pancreatic pseudocyst developed in

an AIP patient who did not receive corticosteroid treatment. On the other hand, Nakazawa et al (10) reported that a pancreatic cyst in an AIP patient spontaneously disappeared before corticosteroid treatment. In the present case, we have to give priority to surgical treatment since there was heavy hemorrhage within the cysts caused by rupture of fragile vessels due to enlargement of the cysts and intracystic hemorrhage. Although indication for corticosteroid treatment for pseudocysts in AIP is difficult, we suggest that corticosteroid treatment should be started immediately when a pseudocyst appears, accompanying AIP, because the pseudocyst does disappear with treatment (or at least there has been no report of pseudocyst enlargement after corticosteroid treatment).

Generally, corticosteroid treatment is indicated for AIP patients when they have obstructive jaundice due to stenosis of the bile duct or complications of autoimmune diseases that present abnormal symptoms or findings (14,15). Continuation of corticosteroid treatment is important for prevention of progression of the disease and other relevant diseases. However, the appropriate period of corticosteroid treatment and required continuity of corticosteroid administration remain to be determined (16).

REFERENCES

1. Kawa S, Hamano H. Clinical features of autoimmune pancreatitis. *J Gastroenterol* **42** [Suppl XVIII]:9–14, 2007.
2. Okazaki K, Kawa S, Kamisawa T, et al. Clinical diagnostic criteria of autoimmune pancreatitis: revised proposal. *J Gastroenterol* **41**:626-631, 2006.
3. Muraki T, Hamano H, Ochi Y, et al. Corticosteroid-responsive pancreatic cyst found in autoimmune pancreatitis. *J Gastroenterol* **40**:761-766, 2005.
4. Kitoh H, Kondoh S, Urayama N, et al. Focal autoimmune pancreatitis which discovered for formation of a large pancreatic pseudocyst. A case report. *Nippon Naika Gakkai Zasshi* **92**: 161-163, 2003 (in Japanese).
5. Okamoto T, Niwakawa M, Yasuoka T, et al. Autoimmune pancreatitis complicated with pseudocyst. A case report. *J Jpn Pancreas Soc* **18**:228–234, 2003 (in Japanese).
6. Nishimura T, Masaoka T, Suzuki H, et al. Autoimmune pancreatitis with pseudocysts. *J Gastroenterol* **39**:1005-1010, 2004.
7. Welsch T, Kleeff J, Esposito I, et al. Autoimmune pancreatitis associated with a large pancreatic pseudocyst. *World J Gastroenterol* **12**:5904-5906, 2006.
8. Falck VG, Dixon E. Pseudocysts may be seen in immunoglobulin G4-associated autoimmune pancreatitis. *Arch Pathol Lab Med* **131**:16, 2007.
9. Hirano K, Tada M, Isayama H, et al. Long-term prognosis of autoimmune pancreatitis without and with corticosteroid treatment. *Gut* **56**: 1719-1724, 2007
10. Nakazawa T, Ohara H, Sano H, et al. Difficulty in diagnosing autoimmune pancreatitis by imaging findings. *Gastrointest Endosc* **65**:99-108, 2007.
11. Okazaki K, Chiba T. Autoimmune related pancreatitis. *Gut* **51**:1-4, 2002.

- 12.** Kamisawa T, Yoshiike M, Egawa N, et al. Treating patients with autoimmune pancreatitis: results from a long-term follow-up study. *Pancreatology* **5**:234–238, 2005.
- 13.** Ozden I, Dizdaroglu F, Poyanli A, et al. Spontaneous regression of a pancreatic head mass and biliary obstruction due to autoimmune pancreatitis. *Pancreatology* **5**:300–303, 2005.
- 14.** Chari ST. Current concepts in the treatment of autoimmune pancreatitis. *JOP* **8**:1-3, 2007.
- 15.** Kamisawa T, Yoshiike M, Egawa N, et al. Treating patients with autoimmune pancreatitis: results from a long-term follow-up study. *Pancreatology* **5**:234-238, 2005.
- 16.** Kuwatani M, Kawakami H, Makiyama H, et al. Autoimmune pancreatitis with retroperitoneal fibrosis which responded to steroid therapy but was complicated with refractory renal dysfunction. *Intern Med* **46**:1557-1564, 2007.

Figure Legends

Figure 1

(A) Portal phase-enhanced computed tomography (CT) performed in May 2007 showing swelling and a low-contrast margin expressed as a capsule-like low-density rim in the tail of the pancreas (*arrows*) associated with pancreatic cysts (*broken arrows*).

(B) Endoscopic ultrasonography (EUS) showing a hypoechoic pancreatic parenchyma with scattered high-echo spots in the enlarged area (*arrows*) associated with pseudocysts (*broken arrows*) in the tail of the pancreas.

Figure 2

(A) Portal phase-enhanced CT performed in August 2007 showing localized enlargement and a contrast effect in the tail of the pancreas similar to the findings at the initial EUS.

(B) Plain and portal phase-enhanced CT showing enlargement of the pseudocysts with hemorrhage (*broken arrows*) in the tail of the pancreas.

(C) Portal phase-enhanced CT showing extension of hemorrhage to the dorsal side of the stomach due to intraperitoneal rupture of the hemorrhage cysts (*arrows*).

Figure 3

Pancreatogram of the specimen showing total occlusion of the main pancreatic duct in the tail of the pancreas.

Figure 4

A cut surface view of the pancreatic tail. Whitish matter is seen within the dilated peripheral pancreatic duct. The whitish matter was an accumulation of protein plaques (*arrows*).

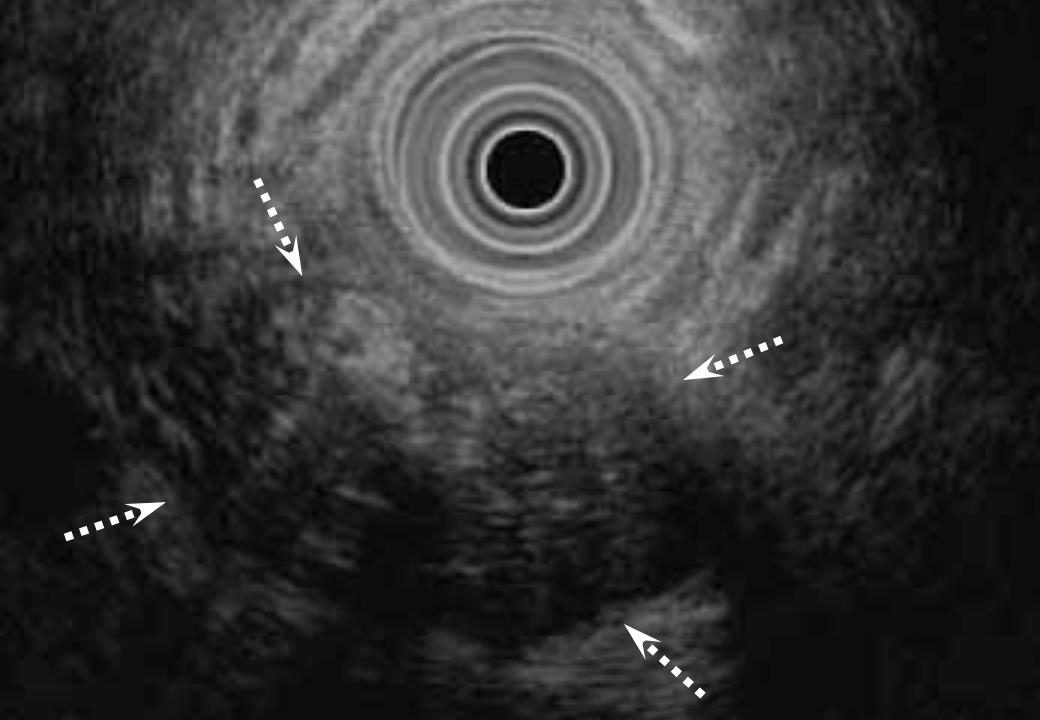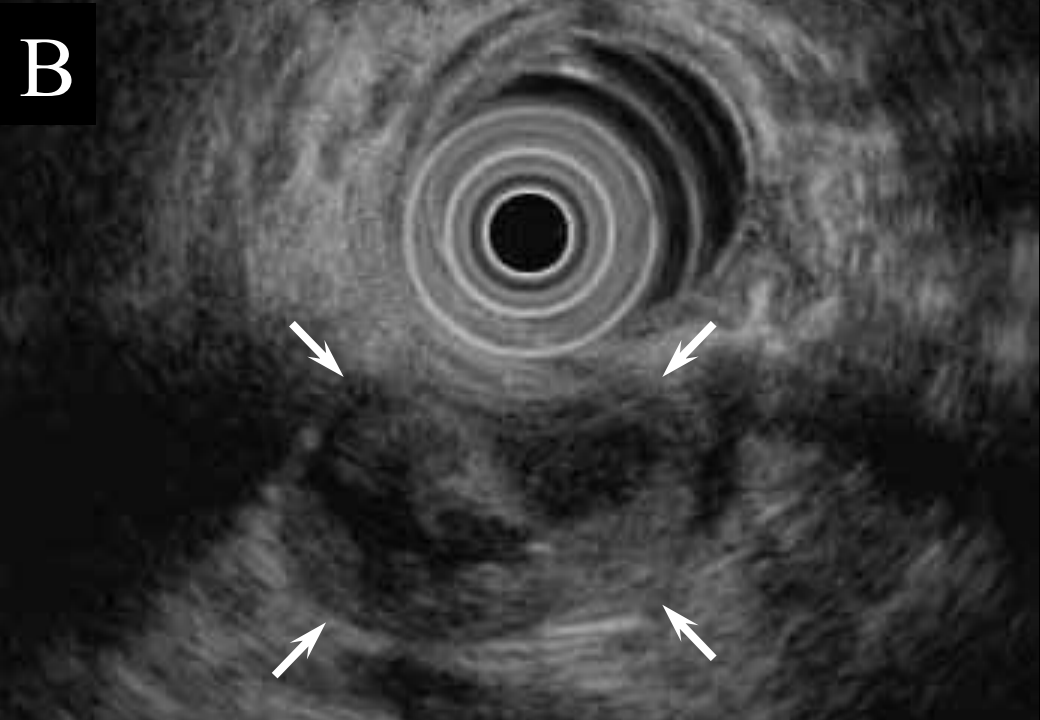
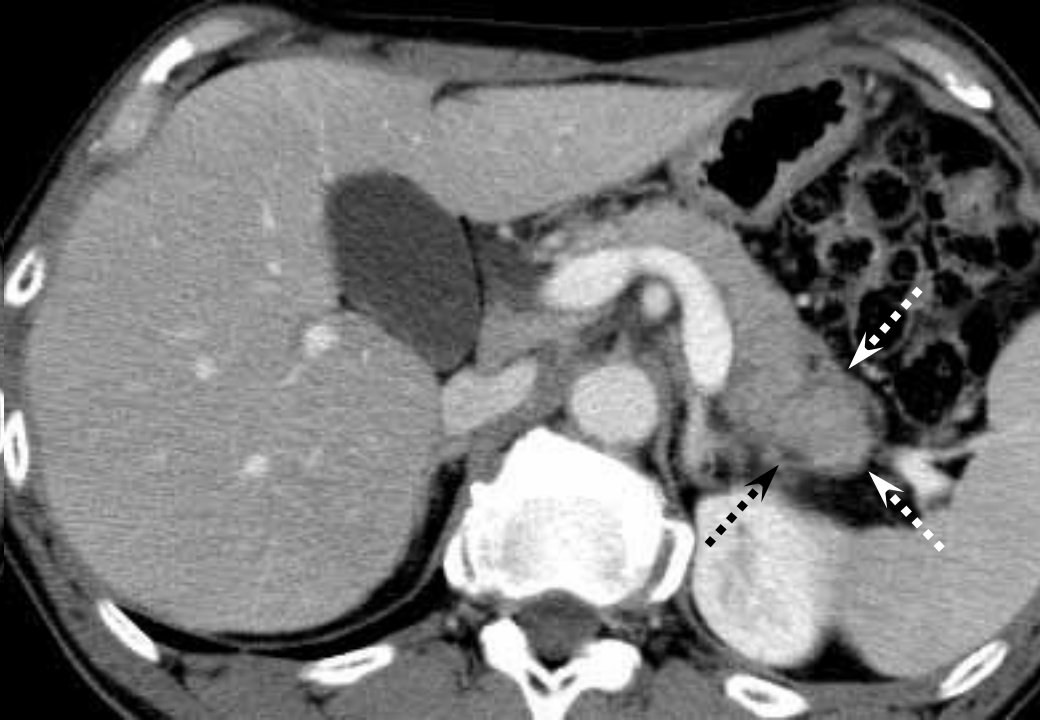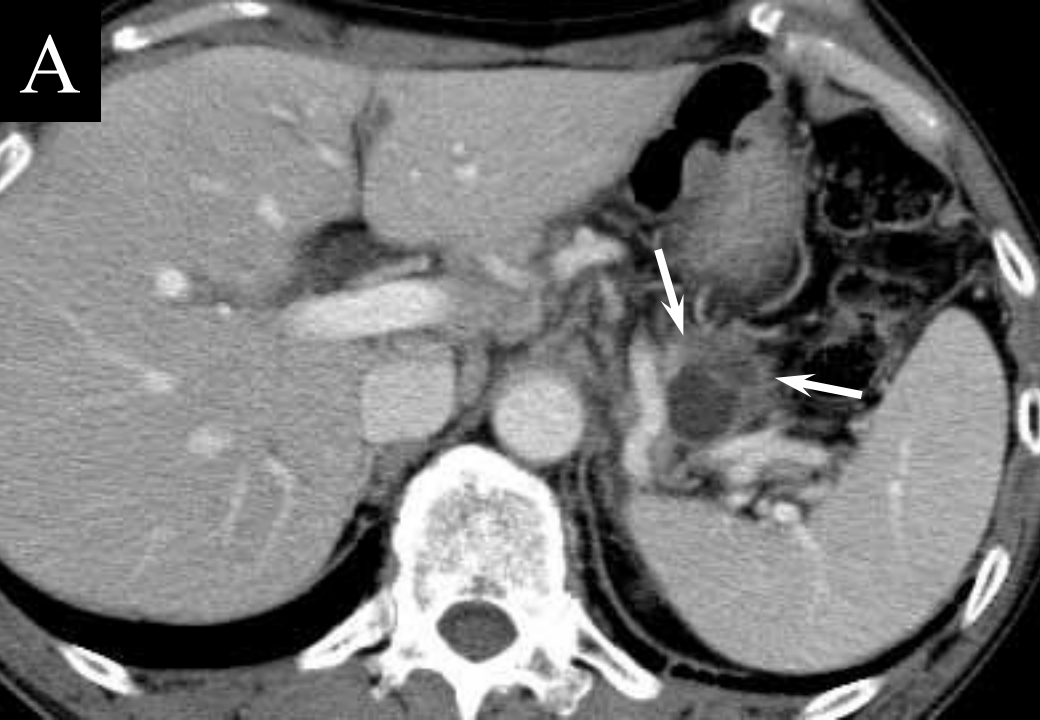Figure 5

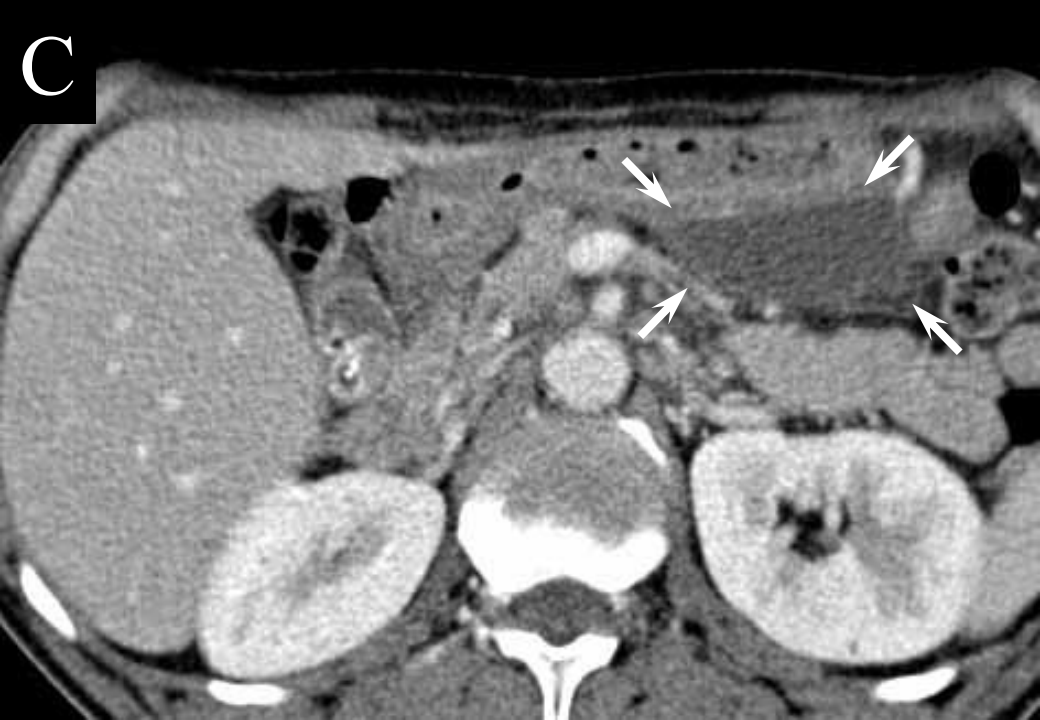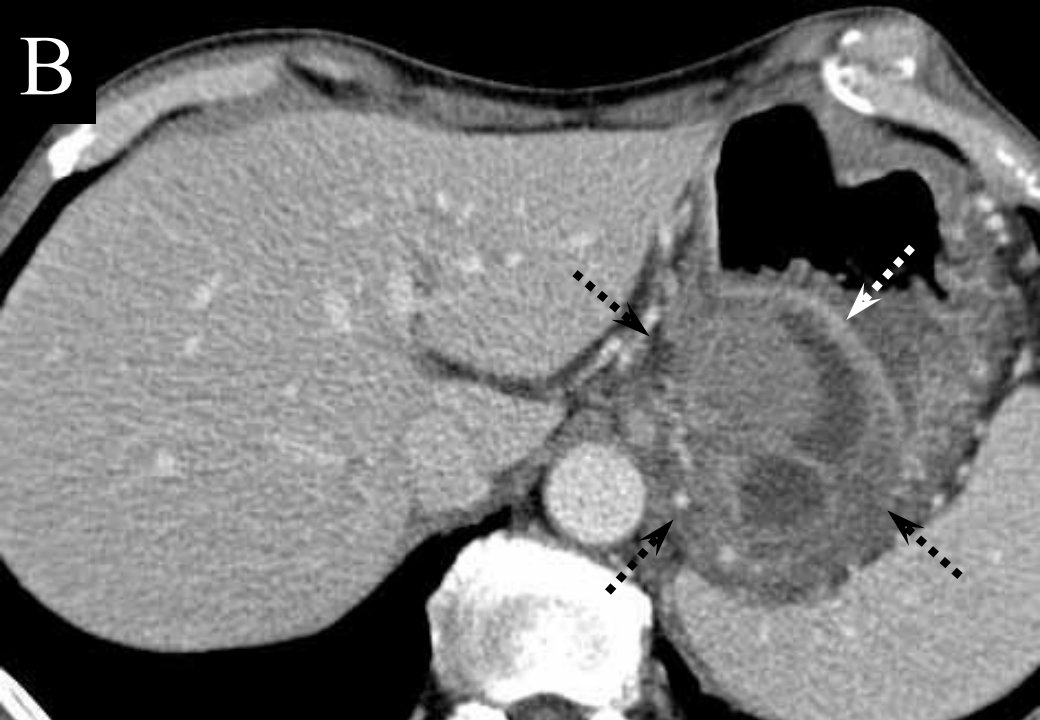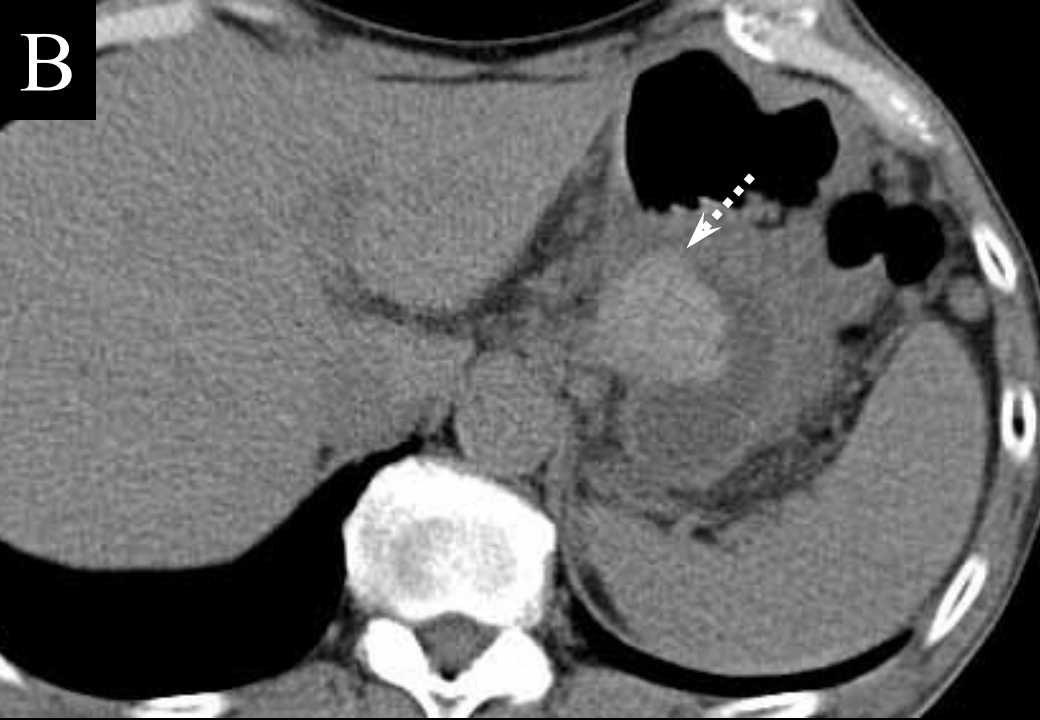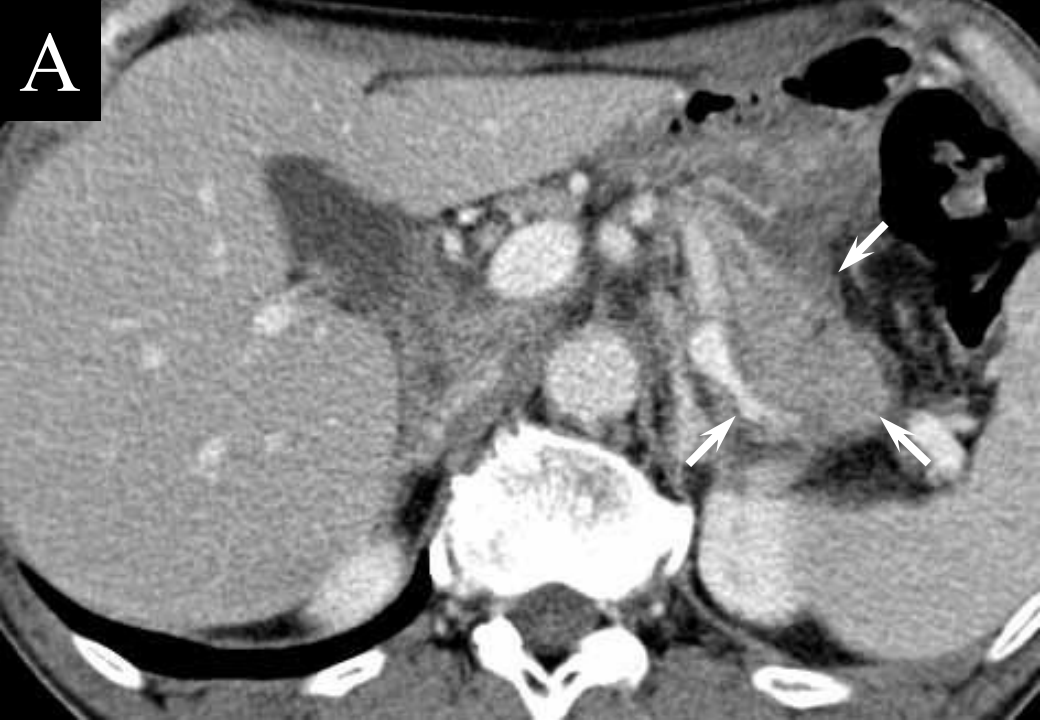(A) Photomicrograph of the resected specimen showing accumulated protein plaques within the dilated peripheral pancreatic duct (H&E; original magnification 20 ×).

(B) Photomicrograph of the resected specimen showing significant lymphoplasmatic infiltration and fibrosis in the tail of the pancreas (H&E; original magnification 100 ×).

(C) Photomicrograph of the resected specimen showing numerous IgG4-positive plasma cells had infiltrated the pancreas (IgG4 immunostaining; original magnification 200 ×).

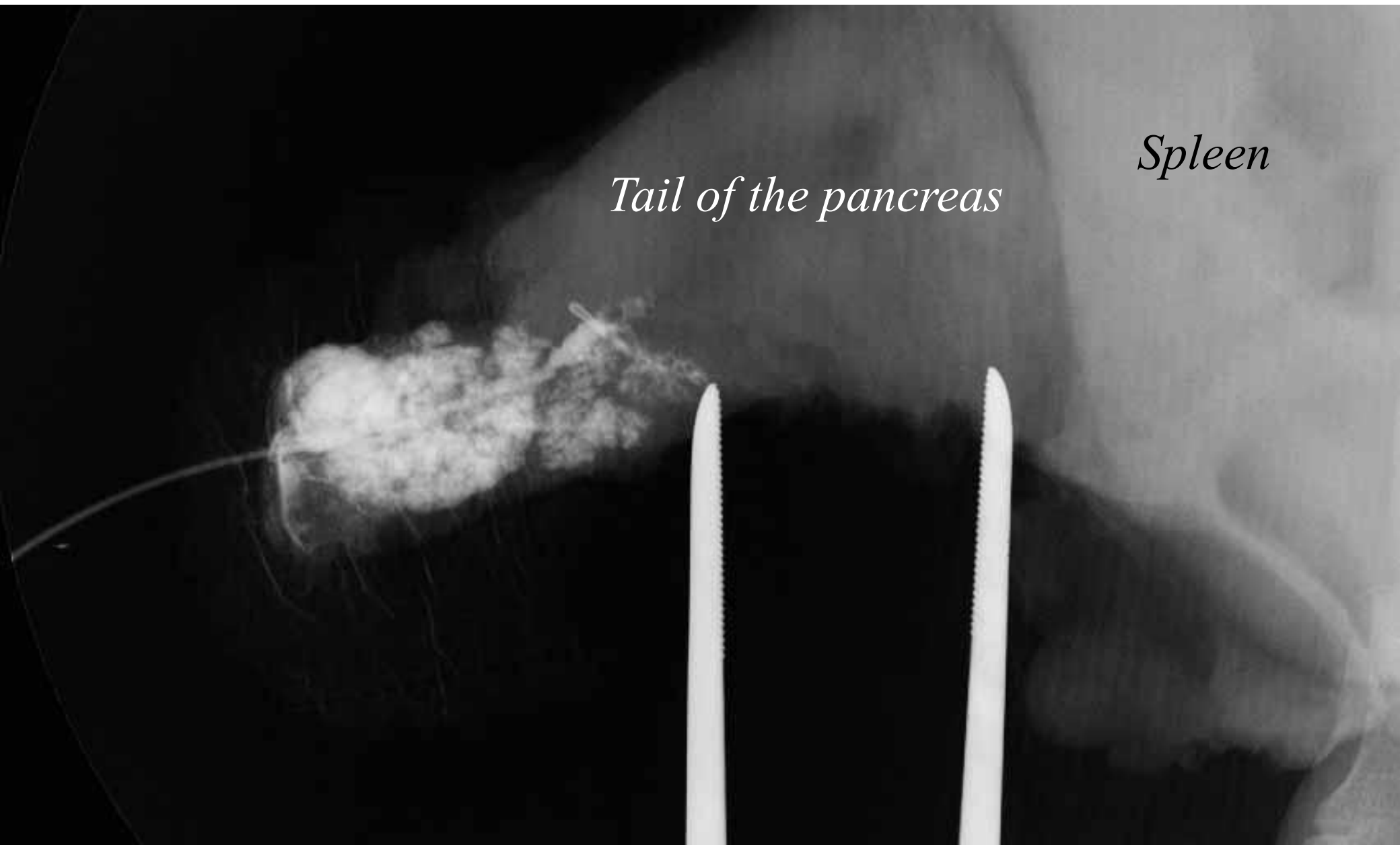
(D) Photomicrograph of the resected specimen showing that there were no epithelial cells but the inner surface was covered with fibrinohemorrhagic exudative tissue and granulation tissue (H&E; original magnification 100 ×).


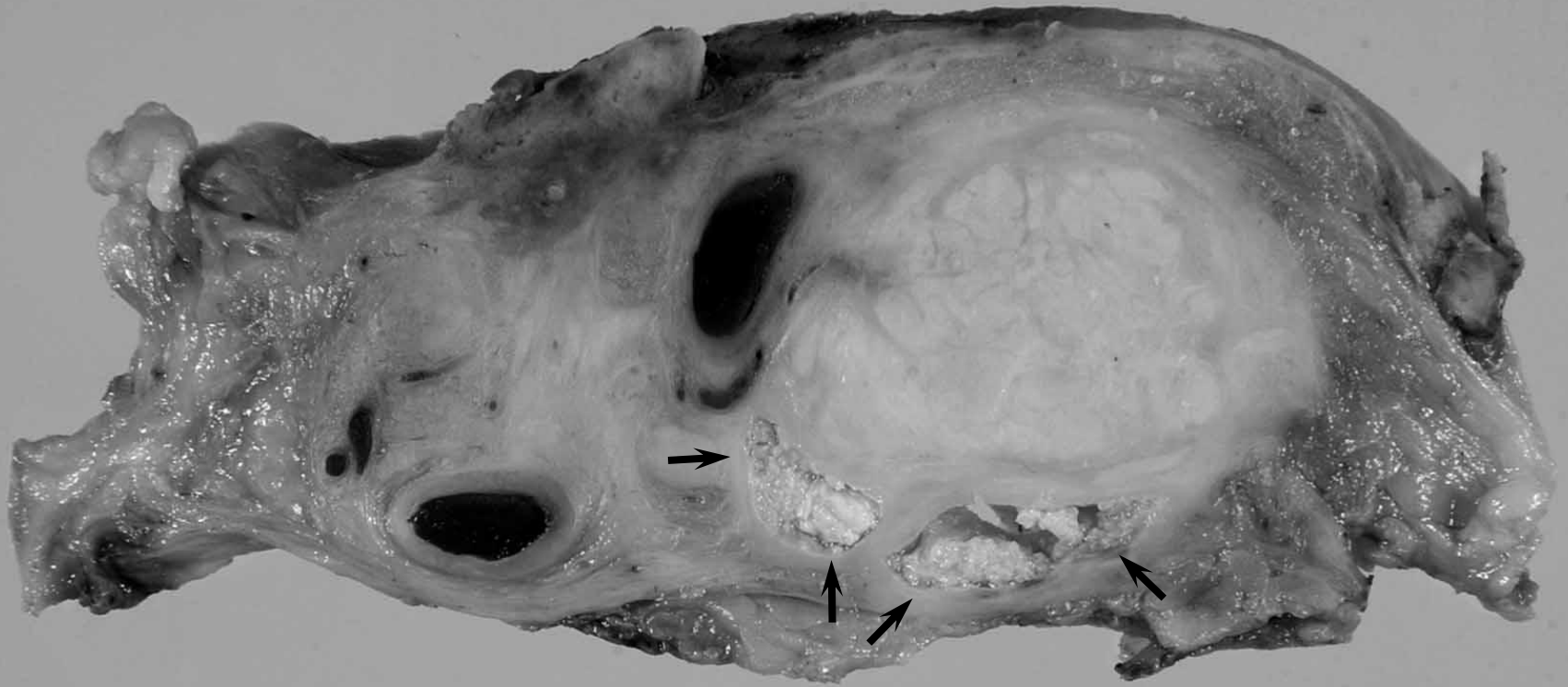




Tail of the pancreas

Spleen






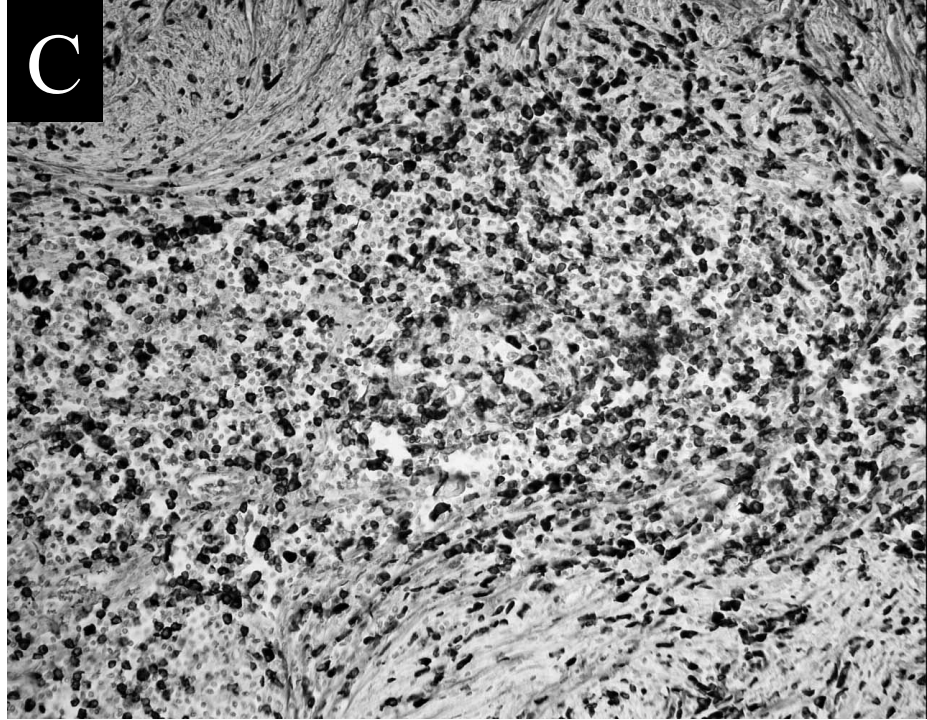
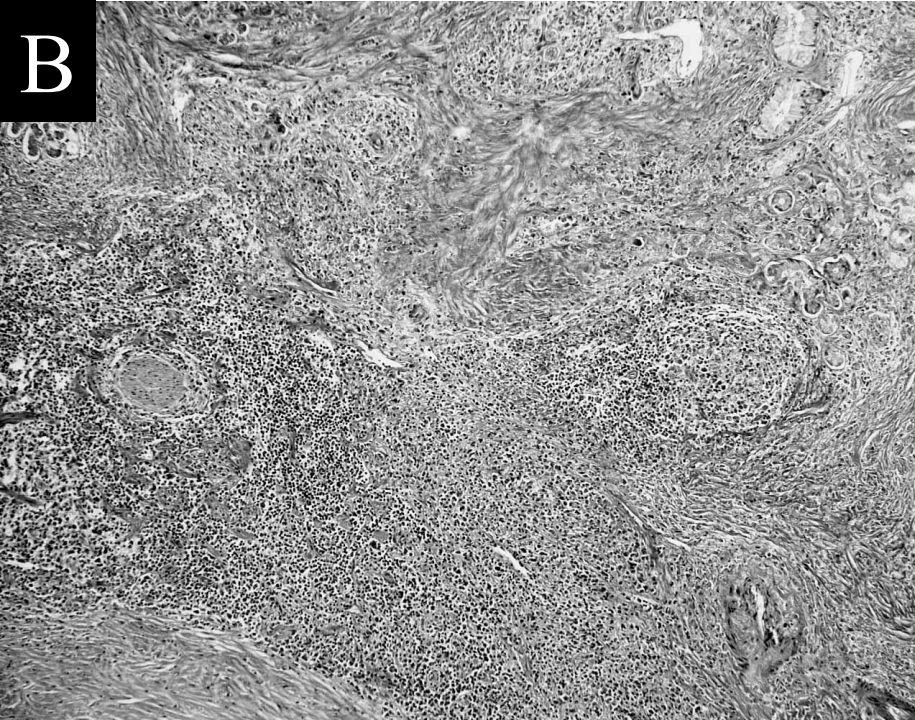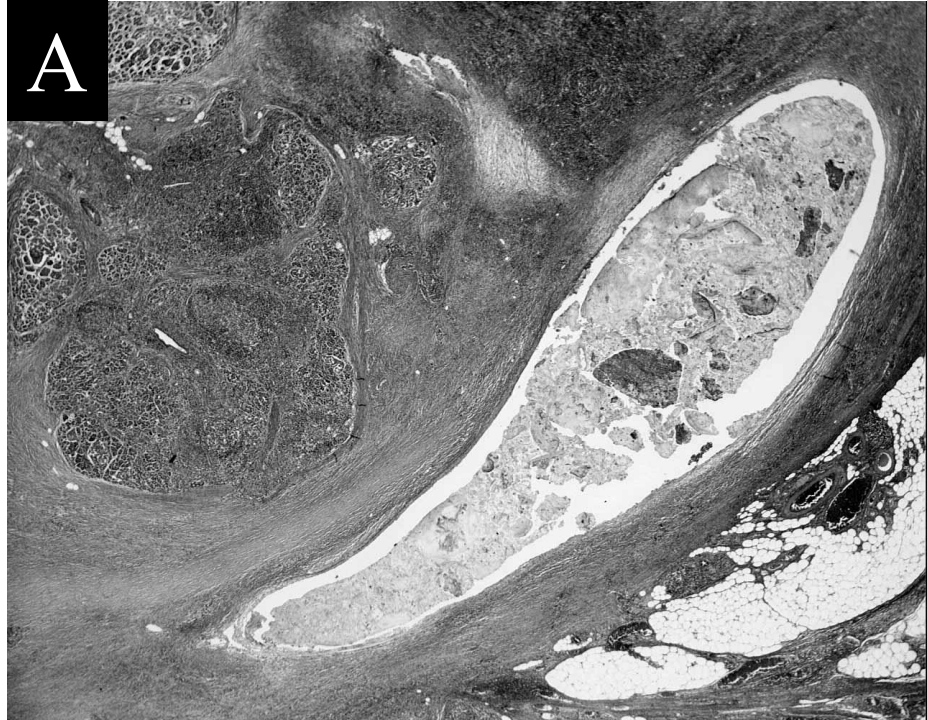


Table 1-1. Reported cases of autoimmune pancreatitis associated with pseudocyst

Author	Patient's age (y)	Gender	Abdominal pain	WBC (mm ³)	CRP (mg/dL)	IgG (mg/dL)	IgG4 (mg/dL)	Pancreatic enzyme level
Kitoh H et al.	66	M	(+)	7,900	14.8	ND	ND	Elevated
Okamoto T et al.	63	M	(+)	8,000	6.36	2,365	ND	Elevated
Nishimura T et al.	47	F	(+)	7,000	5.83	2,900	623	Elevated
Welsch T et al.	64	M	(+)	6,900	ND	ND	ND	Elevated
Falck VG et al.	59	M	(+)	ND	ND	ND	281	Elevated
Hirano K et al.	65	F	(-)	ND	ND	ND	374	ND
Nakazawa T et al.	49	F	ND	ND	ND	ND	Elevated	ND
Nakazawa T et al.	59	M	ND	ND	ND	ND	Elevated	ND
Present case	63	M	(+)	8,200	4.41	5,343	1,160	Elevated

M, Male; *F*, Female; *ND*, Not described

Table 1-2. Reported cases of autoimmune pancreatitis associated with pseudocyst

Author	Pancreatic ductal change	Location of the pseudocyst	Initial treatment	Effects of the treatment on pseudocyst
Kitoh H et al.	Local	Pt	CS	Disapperance
Okamoto T et al.	Diffuse	Pt	CS	Disapperance
Nishimura T et al.	Diffuse	Pt	CS	Disapperance
Welsch T et al.	Local	Ph	PD	(-)
Falck VG et al.	ND	Pt	Operation	(-)
Hirano K et al.	Diffuse	ND	None	Apperance
Nakazawa T et al.	ND	ND	None	Disapperance
Nakazawa T et al.	ND	ND	CS	ND
Present case	Local	Pt	DP	(-)

Pt, Tail of the pancreas; *Ph*, Head of the pancreas; *ND*, Not described; *CS*, Corticosteroid; *PD*, Pancreatoduodenectomy; *DP*, Distal pancreatectomy