



Title	Preoperative biliary drainage for hilar cholangiocarcinoma : which stent should be selected?
Author(s)	Kawakami, Hiroshi; Kondo, Satoshi; Kuwatani, Masaki; Yamato, Hiroaki; Ehira, Nobuyuki; Kudo, Taiki; Eto, Kazunori; Haba, Shin; Matsumoto, Joe; Kato, Kentaro; Tsuchikawa, Takahiro; Tanaka, Eiichi; Hirano, Satoshi; Asaka, Masahiro
Citation	Journal of Hepato-Biliary-Pancreatic Sciences, 18(5), 630-635 https://doi.org/10.1007/s00534-011-0404-7
Issue Date	2011-09
Doc URL	http://hdl.handle.net/2115/47044
Rights	The original publication is available at www.springerlink.com
Type	article (author version)
File Information	JHBPS18-5_630-635.pdf



[Instructions for use](#)

Preoperative biliary drainage for hilar cholangiocarcinoma: Which stent should be selected?

Hiroshi Kawakami,¹; Satoshi Kondo,²; Masaki Kuwatani,¹; Hiroaki Yamato,¹; Nobuyuki Ehira,¹; Taiki Kudo,¹; Kazunori Eto,¹; Shin Haba,¹; Joe Matsumoto,²; Kentaro Kato,²; Takahiro Tsuchikawa,²; Eiichi Tanaka,²; Satoshi Hirano,²; Masahiro Asaka,¹

¹ Department of Gastroenterology, Hokkaido University Graduate School of Medicine, Sapporo, Japan

² Department of Surgical Oncology, Hokkaido University Graduate School of Medicine, Sapporo, Japan

Address correspondence to: Hiroshi Kawakami, MD, PhD

Department of Gastroenterology, Hokkaido University Graduate School of Medicine, Kita 15, Nishi 7, Kita-ku, Sapporo 060-8638, Japan

Tel: +81 11 716 1161 (Ext 5920); Fax: +81 11 706 7867

E-mail: hiropon@med.hokudai.ac.jp (H. Kawakami)

Key words

Hilar cholangiocarcinoma

Preoperative biliary drainage

Endoscopic biliary drainage

Endoscopic nasobiliary drainage

Bilateral biliary drainage

Abstract

The controversy over whether and how to perform preoperative biliary drainage (PBD) in patients with hilar cholangiocarcinoma (HCA) remains unsettled. Arguments against PBD before pancreatoduodenectomy have recently been gaining momentum. However, the complication-related mortality rate is as high as 10% for patients with HCA who have undergone major liver resection, and liver failure is a major cause of postoperative death. This suggests the need for PBD to treat jaundice in HCA patients scheduled for major surgical resection of the liver and to perform major surgery only after recovery of hepatic function. No definite criteria or guidelines outlining indications for PBD are currently available. In patients with HCA, PBD may be performed by either percutaneous transhepatic biliary drainage (PTBD) or endoscopic biliary drainage (EBD). No consensus, however, has been reached regarding which drainage method is more appropriate. No reported study has compared the effectiveness of PTBD, endoscopic biliary stenting (EBS), and endoscopic nasobiliary drainage (ENBD) in patients with HCA. This review summarizes the results of our study comparing the three methods and outlines the preoperative endoscopic management of segmental cholangitis (SC) in HCA patients undergoing PBD.

Introduction

Debate over whether and how to perform PBD in patients with HCA remains unresolved. A series of randomized controlled trials conducted in the 1980s on preoperative PTBD did validate PBD, due to the high incidence of complications with PTBD [1-3]. However, most patients enrolled in these studies were treated with palliative surgery; hepatectomy was performed in only a small number of patients included in the randomized controlled study by McPherson *et al.* [2]. PBD performed prior to extended hepatectomy in patients with obstructive jaundice secondary to cholangiocarcinoma was reported by Cherqui *et al.* [4] and Ferrero *et al.* [5]. Both studies showed a negative trend for patient survival after PBD. However, in the study by Cherqui *et al.* [4], no data was provided on preoperative hepatic function or percentage of resected liver volume, and PBD was performed only in patients with obstructive jaundice lasting 1 month or longer. The clinical criteria for performing PBD were not clearly outlined by Ferrero *et al.* [5], who found a higher, though not statistically significant, mortality rate for patients who did not undergo PBD. Thus, their results should be interpreted cautiously. In the systematic review by Liu *et al.* [6], the clinical outcome of HCA surgery was compared between patients with and without PBD. This review also requires a careful interpretation because of several limitations: (1) specific PBD procedures were not reported, (2) internal PBD was performed at a rate exceeding 40%, (3) the mean percentage of the resected liver volume in each group was not reported, and (4) only a minor proportion of patients underwent preoperative portal vein embolization (PVE). Moreover, most of the patients with internal PBD presumably underwent EBS, and the occurrence of acute obstructive cholangitis, resulting from stent occlusion, may account for the high rate of infection in

patients who underwent PBD in this review, suggesting a potential bias.

At high-volume Japanese surgical centers, preoperative PVE is routinely conducted in patients requiring a major hepatic resection in consideration of the future remnant liver volume [7-9]. Definitive surgery will be scheduled 2-4 weeks after PVE at the earliest. Consequently, PBD is generally performed in these patients [10-12]. While PTBD has been the long-standing treatment for patients with HCA, several recent studies have demonstrated the effectiveness of EBD [13,14]. Takahashi *et al.* [15] recently reported a relatively high 5.2% recurrence rate of cholangiocarcinoma in the PTBD fistula, a poor survival outcome despite surgical removal of the fistula and other sites of recurrence, and argued in favor of EBD over PTBD. However, no consensus has been reached regarding the choice between PTBD and EBD. This review briefly outlines our results with PBD and explains the practical and appropriate techniques for PBD and the management of SC.

Which is more suitable for hilar cholangiocarcinoma, endoscopic or percutaneous biliary drainage?

In a recent study [16], we reviewed 128 consecutive HCA patients treated with PBD from September 1999 to December 2009. All patients underwent HCA surgery following successful PBD. In this study, we categorized patients who had received PBD, including those with referrals, into three groups for analysis by the initial type of drainage: ENBD, EBS, or PTBD. There was no significant difference between the groups in terms of patient demographics or preoperative laboratory data (Table 1, adapted from reference 16 with permission). Outcome analysis found that ENBD was the most appropriate method of PBD because (1) in the EBS group, there was a high

incidence of cholangitis as a complication (a risk factor for postoperative liver failure), (2) in the PTBD group, there were several documented cases of damage and obstruction of the portal vein branches, which required alteration of the surgical plan, and (3) in the PTBD group, there were several documented cases of cancer dissemination (Table 2, adapted from reference 16 with permission). There was no difference in the incidence of surgical complications or the hospital mortality rate between the three groups. Despite its possible disadvantages relative to EBS (Table 3), ENBD is the safest of the three modalities, suggesting that ENBD will become the primary treatment. This retrospective study demonstrated the superiority of ENBD over the other drainage methods.

Because a majority of the cases evaluated in this study consisted of referral patients from other medical institutions, many patients had already been treated with bilateral liver lobe drainage at admission to our department. However, we consider unilateral drainage of the future remnant lobe sufficient in most cases. Bilateral drainage is suitable for the treatment of cholangitis occurring in both hemilivers, which will be explained in more detail later. Arguments remain as to whether drainage of the lobe planned for resection is appropriate. In our opinion, drainage of the lobe planned for resection should be discouraged, to maintain and promote functional reserve of the future remnant hepatic lobe by decreasing the function of the lobe planned for resection through the compression of the portal vein branches secondary to bile duct dilatation. We consider performing PBD of the lobe planned for resection only in the presence of cholangitis.

Tips for endoscopic nasobiliary tube placement

In placing an ENBD tube, attention should be paid to minimizing the amount of contrast medium used, to avoid SC of the undrained area (contralateral SC). Although this principle applies to stent placement generally, particular care should be taken not to aggravate possibly preexisting interruption of the bile duct associated with hilar biliary stenosis. Patients with HCA often experience jaundice, which decreases the hepatic functional reserve. Thus, this calls for careful use of contrast media to prevent an increase in the internal pressure of the biliary tract and the development of retrograde cholangitis. Prior to PBD, it is necessary to determine the anatomical arrangement of the biliary tree by multidetector computed tomography or magnetic resonance cholangiopancreatography to help guide the surgical plan and the site of tube placement. We recommend a thorough cholangiography-based diagnostic evaluation of tumor progression after the hepatic functional reserve of the future remnant lobe is recovered by PBD.

Endoscopists should be fully familiar with the basic surgical procedures related to the placement site. Anatomically, the junction of the left and right hepatic ducts is located in the upper right quadrant of the hepatoduodenal ligament at the root of the right liver Glissonian pedicle; it is located away from the root of the left liver Glissonian pedicle in the upper left area of the hepatoduodenal ligament. These anatomical features make resection of the right lobe more surgically advantageous because it allows for a complete resection of the junction of the left and right hepatic ducts along with its surrounding tissues [10-12]. The incidence of postoperative liver failure dramatically decreased with the routine clinical use of preoperative PVE [7-9]. Surgeons are thus selecting the combination of right hepatic lobectomy, caudate lobectomy, and extrahepatic bile duct resection at an increasing frequency, because it

offers the surgical advantage mentioned above. Thus, left-sided drainage is most commonly selected, as long as the anatomy of the biliary tree at the hilum does not provide a contraindication. Of course, left-sided lobectomy with resection of the caudate lobe and extrahepatic bile duct is chosen for the surgical management of tumors predominantly involving the left hepatic duct. In such cases, right-sided drainage will be performed.

Two types of ENBD tubes are available: straight and “pigtail” types. Pigtail catheters may have a higher risk of their distal tips stabbing into the wall of the bile duct or liver parenchyma. There is also a risk of insufficient drainage with pigtail catheters because the side holes are concentrated only in the pigtail area. These potential risks require their careful application. Despite these risks, we advocate the use of pigtail type catheters, because dislocation of ENBD catheters without looped ends was observed [16].

Cases treated with the combination of ENBD and EBS have been reported in the literature. We caution against the use of EBS placement because it increases the risk of acute cholangitis resulting from stent occlusion.

Management of SC

SC that develops during PBD in the hemiliver not subjected to artificial drainage may pose significant problems. Because cholangitis is a definitive risk factor for postoperative liver failure [17-19], appropriate medical care should be taken immediately. Cholangitis in the context of ENBD warrants an accurate and prompt work-up to determine whether it is developing in the undrained segments or the drained segments: the bile color and output, which can be readily determined, will

help in identifying the location of cholangitis development [16].

If cholangitis develops, insertion of an additional PTBD catheter was previously used to manage SC in our department. Placement of multiple ENBD catheters, however, is our current treatment of choice.

Only a few studies to date have reported the effectiveness of multiple ENBD catheter placement [14,16], requiring further investigation of its utility. Our clinical experience has demonstrated its benefit for the management of SC [16].

Indications for and method for double ENBD

The use of two ENBD catheters is indicated for, but not limited to, SC occurring simultaneously in the right and left lobes. Two-catheter catheterization may be applied for the treatment of Bismuth type IV bile duct stenosis, when both tubes are introduced into either the right or left lobe (for example, each catheter is inserted into the bile ducts in the following combinations: segment II and segment III; left posterolateral segment and left anterolateral segment (B_{2+3}) and segment IV; anterior and posterior segmental).

The use of two ENBD tubes requires a duodenoscope with a large diameter instrument channel. A duodenoscope with a 3.7-mm channel size (e.g., JF-260V, Olympus Medical Systems, Tokyo, Japan) allows for the placement of two tubes if the sum of their outer diameters does not exceed 11 French (Fr), while a duodenoscope with a 4.2-mm channel size (e.g., TJF-200, 240, 260V, Olympus Medical Systems) permits two tubes if the sum of their outer diameters does not exceed 12 Fr. In either case, the use of two tubes incurs poor endoscopic operability if the sum of the tube diameters equals 12 Fr. A pair of 5 Fr tubes or a pair of 5 and 6 Fr tubes are favorable.

Endoscopists must be aware of the risk of kinking when using two 5 Fr ENBD catheters. Additionally, endoscopists should perform endoscopic sphincterotomy (ES) with a sufficient incision to avoid compression and obstruction of the main pancreatic duct, which is possible with double ENBD. ES may elevate the risk of retrograde cholangitis in patients with hilar biliary strictures. We have, however, experienced no such cases in our department to date. It is possible to consider performing pancreatic duct stenting instead of ES before placing two ENBD tubes. However, we contend that ES is more appropriate because of the issues related to the patency of pancreatic stent and stent removal, as well as the possibility of causing pancreatitis associated with the use of stents designed for spontaneous dislodgement.

Results of double ENBD for preoperative biliary drainage

We retrospectively examined a total of 24 consecutive patients for whom placement of two ENBD catheters was attempted before undergoing surgical resection of HCA in our department from April 2005 to May 2009. There were 17 males (70.8%) and seven females (29.2%), whose median age was 67.7 years (range: 58-84). They were classified by tumor type as Bismuth type II ($n = 8$), IIIa ($n = 5$), IIIb ($n = 1$), and IV ($n = 10$). Factors that necessitated the use of two ENBD tubes included: bilateral SC ($n = 9$), contralateral SC ($n = 9$), ipsilateral SC ($n = 3$), and other ($n = 3$; Table 4). All patients had successful insertion of both ENBD tubes (diameter range: 5 to 7 Fr, a pair of 5 Fr tubes, a pair of 5 and 6 Fr tubes, or a pair of 5 and 7 Fr tubes). Cholangitis resolved rapidly, within 1-4 days (mean: 2.3 days), except in one patient. In this patient, SC of the undrained segment persisted after the placement of two ENBD catheters and ultimately required PTBD. ES-induced

retroperitoneal microperforation was observed in one patient (4.2%), which was the only complication recorded in this study. The symptoms quickly resolved with conservative treatment.

A majority of SC cases can be adequately controlled by the placement of two ENBD tubes. SC in the undrained segment of patients with bilateral ENBD may represent reaching the limitations of preoperative management by ENBD. Some patients can be appropriately treated with the use of three ENBD tubes, but this is, however, not always the case. Successful insertion of the third tube is not always guaranteed, and endoscopists must also assess in advance the risk of tube dislodgement upon withdrawal of the endoscope. Thus, we conclude that from the perspective of operative safety and reliability that PTBD should be performed in these circumstances. It is a common practice in our department to perform PTBD in patients requiring further biliary drainage of more than two ENBD tubes for the treatment of SC.

The patients reviewed in this study included a large proportion (10/24, 41.7%) of patients with EBS occlusion (cholangitis) in the right and left lobes of the liver. In patients scheduled for surgery for HCA, PBD should be performed by modalities other than EBS, preferably ENBD. However, acute cholangitis was documented in approximately 10% of the patients undergoing ENBD [16]. Particular attention should be paid to the bile color and output.

Conclusions

We recommend ENBD of the future remnant lobe for PBD in patients expected to undergo definitive surgery for HCA. SC occurring after the start of unilateral biliary

drainage can be appropriately dealt with by the use of two ENBD tubes. Admittedly, ENBD is inferior to EBS with respect to patient symptoms (e.g., pharyngeal discomfort and pain, and increased nasal mucous discharge) and the disruption of the enterohepatic circulation of bile salts. However, EBS should be avoided to prevent the occurrence of acute obstructive cholangitis that leads to a significant deterioration of the hepatic functional reserve. This review underscores the need for establishing more advanced and safer biliary drainage methods, using new placement techniques and long-term indwelling stents.

References

1. Hatfield AR, Tobias R, Terblanche J, Girdwood AH, Fataar S, Harries-Jones R, et al. Preoperative external biliary drainage in obstructive jaundice. A prospective controlled clinical trial. *Lancet*. 1982;2:896-9.
2. McPherson GA, Benjamin IS, Hodgson HJ, Bowley NB, Allison DJ, Blumgart LH. Pre-operative percutaneous transhepatic biliary drainage: the results of a controlled trial. *Br J Surg*. 1984;71:371-5.
3. Pitt HA, Gomes AS, Lois JF, Mann LL, Deutsch LS, Longmire WP Jr. Does preoperative percutaneous biliary drainage reduce operative risk or increase hospital cost? *Ann Surg*. 1985;201:545-53.
4. Cherqui D, Benoist S, Malassagne B, Humeres R, Rodriguez V, Fagniez PL. Major liver resection for carcinoma in jaundiced patients without preoperative biliary drainage. *Arch Surg*. 2000;135:302-8.
5. Ferrero A, Lo Tesoriere R, Viganò L, Caggiano L, Sgotto E, Capussotti L. Preoperative biliary drainage increases infectious complications after hepatectomy for proximal bile duct tumor obstruction. *World J Surg*. 2009;33:318-25.
6. Liu F, Li Y, Wei Y, Li B. Preoperative biliary drainage before resection for hilar cholangiocarcinoma: Whether or not? A systematic review. *Dig Dis Sci*. 2010 Jul 16. [Epub ahead of print]
7. Makuuchi M, Thai BL, Takayasu K, Takayama T, Kosuge T, Gunvén P, et al. Preoperative portal embolization to increase safety of major hepatectomy for hilar bile duct carcinoma: a preliminary report. *Surgery*. 1990;107:521-7.
8. Nagino M, Kamiya J, Nishio H, Ebata T, Arai T, Nimura Y. Two hundred forty consecutive portal vein embolizations before extended hepatectomy for biliary cancer:

surgical outcome and long-term follow-up. *Ann Surg.* 2006;243:364-72.

9. Nagino M, Takada T, Miyazaki M, Miyakawa S, Tsukada K, Kondo S, et al. Preoperative biliary drainage for biliary tract and ampullary carcinomas. *J Hepatobiliary Pancreat Surg.* 2008;15:25–30.

10. Seyama Y, Kubota K, Sano K, Noie T, Takayama T, Kosuge T, et al. Long-term outcome of extended hemihepatectomy for hilar bile duct cancer with no mortality and high survival rate. *Ann Surg.* 2003;238:73-83.

11. Kawasaki S, Imamura H, Kobayashi A, Noike T, Miwa S, Miyagawa S. Results of surgical resection for patients with hilar bile duct cancer: application of extended hepatectomy after biliary drainage and hemihepatic portal vein embolization. *Ann Surg.* 2003;238:84-92.

12. Kondo S, Hirano S, Ambo Y, Tanaka E, Okushiba S, Morikawa T, et al. Forty consecutive resections of hilar cholangiocarcinoma with no postoperative mortality and no positive ductal margins: results of a prospective study. *Ann Surg.* 2004;240:95-101.

13. Maguchi H, Takahashi K, Katanuma A, Osanai M, Nakahara K, Matuzaki S, et al. Preoperative biliary drainage for hilar cholangiocarcinoma. *J Hepatobiliary Pancreat Surg.* 2007;14:441-6.

14. Arakura N, Takayama M, Ozaki Y, Maruyama M, Chou Y, Kodama R, et al. Efficacy of preoperative endoscopic nasobiliary drainage for hilar cholangiocarcinoma. *J Hepatobiliary Pancreat Surg.* 2009;16:473-7.

15. Takahashi Y, Nagino M, Nishio H, Ebata T, Igami T, Nimura Y. Percutaneous transhepatic biliary drainage catheter tract recurrence in cholangiocarcinoma. *Br J Surg.* 2010;97:1860-6.

16. Kawakami H, Kuwatani M, Onodera M, Haba S, Eto K, Ehira N, et al.
Endoscopic nasobiliary drainage is most suitable for preoperative management in patients with hilar cholangiocarcinoma. *Journal of Gastroenterology*. 2010 Aug 11. [Epub ahead of print].
17. Nagino M, Nimura Y, Hayakawa N, Kamiya J, Kondo S, Sasaki R, et al.
Logistic regression and discriminant analyses of hepatic failure after liver resection for carcinoma of the biliary tract. *World J Surg*. 1993;17:250-5.
18. Kanai M, Nimura Y, Kamiya J, Kondo S, Nagino M, Miyachi M, et al.
Preoperative intrahepatic segmental cholangitis in patients with advanced carcinoma involving the hepatic hilus. *Surgery* 1996;119:498-504.
19. Sakata J, Shirai Y, Tsuchiya Y, Wakai T, Nomura T, Hatakeyama K.
Preoperative cholangitis independently increases in-hospital mortality after combined major hepatic and bile duct resection for hilar cholangiocarcinoma. *Langenbecks Arch Surg*. 2009;394:1065-72.

Table 1. Baseline characteristics

	ENBD (<i>n</i> = 60)	EBS (<i>n</i> = 20)	PTBD (<i>n</i> = 48)	
Median age, years (range)	71 (45-81)	70 (59-77)	71 (45-81)	N.S.
Gender				
Male	44	16	36	N.S.
Female	16	4	12	
Major hepatectomy	47 (78.3%)	16 (80%)	38 (79.2%)	N.S.
Bismuth classification				
Type I/II/IIIa/IIIb/IV	12/16/12/8/12	3/6/4/3/4	4/12/8/8/16	N.S.
Drained area				
Unilateral/Bilateral	57/3	15/5	35/13	N.S.
Preoperative laboratory data				
T.Bil * > 2.0 mg/dL	38 (63.3%)	9 (45%)	36 (75%)	N.S.

T.Bil, mg/dL (average [range])	9.9 [2.2-29.3]	9.0 [2.4-14.7]	12.0 [3-25.3]	N.S.
ICG, % (average [range])	21.0 [3.5-35]	13.6 [9.9-22.7]	30.0 [3.5-35]	N.S.
Decompression period**, days (average [range])	11.5 [1-134]	11.9 [1-28]	11.0 [1-154]	N.S.

ENBD, endoscopic nasobiliary drainage; EBS, endoscopic biliary stenting; PTBD, percutaneous transhepatic biliary drainage;
N.S., Not significant; ICG, indocyanine green retention at 15 min.

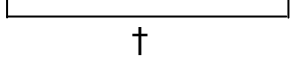
Major hepatectomy included right or left trisectionectomy, right or left hepatectomy including caudate lobectomy, or more extensive hepatectomy

A *p* value of <0.05 was considered to indicate statistical significance

* T.Bil: The maximum total bilirubin value for each patient was determined.

** Decompression period refers to the number of days needed to reach normal total bilirubin levels after biliary drainage.

Table 2. Complication rates and characteristics of preoperative biliary drainage

	ENBD (<i>n</i> = 60)	EBS (<i>n</i> = 20)	PTBD (<i>n</i> = 48)	
Total	23 (38.3%)	13 (65%)	15 (31.3%)	† <i>p</i> < 0.05
				
Minor complications				
Tube occlusion with cholangitis	6 (10%)	12 (60%)*	1 (2.1%)	* <i>p</i> < 0.0001
Tube dislocation	9 (15%)	1 (5%)	7 (14.6%)	N.S.
Contralateral SC	6 (10%)	1 (5%)	4 (8.3%)	N.S.
Post-ERCP pancreatitis	2 (3.3%)	1 (5%)	-	
Major complications				
Total	1 (1.7%) §	-	7 (14.6%) §	§ <i>p</i> < 0.01

Retroperitoneal perforation	1 (1.7%)	-	-
Portal vein injury	-	-	4 (8.3%)
Cancer dissemination	-	-	3 (6.3%)

ENBD, endoscopic nasobiliary drainage; EBS, endoscopic biliary stenting; PTBD, percutaneous transhepatic biliary drainage; SC, segmental cholangitis; N.S., Not significant

A p value < 0.05 was considered to indicate statistical significance.

Some patients had more than one complication.

† The complication rate in the EBS group was significantly higher than that in the PTBD group ($p < 0.05$).

* Among minor complications, it was especially notable that there was a significantly higher rate of tube occlusion in the EBS group than in either the ENBD or PTBD groups ($p < 0.0001$).

§ Among major complications, the complication rate in the PTBD group was significantly higher than that in the ENBD group ($p < 0.01$).

Table 3. Comparison of endoscopic biliary drainage methods

	Advantages	Disadvantages
ENBD	<p>Allows on-the-spot determination of bile color and output</p> <p>Low risk of retrograde cholangitis</p> <p>Enables repeated cholangiography</p> <p>Collecting bile samples for culture is simplified</p> <p>Cytology of bile can be readily performed</p>	<p>May cause pharyngeal discomfort and pain</p> <p>May increase nasal discharge</p> <p>Risk of catheter dislodgement</p> <p>Patient may attempt to remove the catheter</p> <p>Patient's ADL may be decreased</p> <p>Cholangiography via tube may cause cholangitis in the undrained area</p> <p>Decreased absorption of fat-soluble vitamins</p>
EBS	<p>Low level of patient pain</p> <p>Does not deteriorate patient's ADL</p> <p>Permits easy placement of multiple catheters</p> <p>Patient cannot access the stent</p>	<p>Bile color and output cannot be readily determined</p> <p>Risk of retrograde infection</p> <p>Not suitable for cholangiography or collection of surveillance culture samples</p>

Risk of stent occlusion

Risk of stent dislodgement

Risk of stent migration

ENBD, endoscopic nasobiliary drainage; EBS, endoscopic biliary stenting; ADL, activities of daily living

Table 4. Indications for double endoscopic nasobiliary drainage

	Bilateral SC	Contralateral SC	Ipsilateral SC	Others
Total	9 (37.5%)	9 (37.5%)	3 (12.5%)	3 (12.5%)
EBS occlusion	5	4	-	1*
Post unilateral ENBD **	2	4	-	-
Cholangiography via ENBD	1	1	-	-
Insuficient biliary drainage	1	-	3	1
PTBD tube dislocation	-	-	-	1

SC, segmental cholangitis; EBS, endoscopic biliary stenting; ENBD, endoscopic nasobiliary drainage; PTBD, percutaneous transhepatic biliary drainage.

* Icterus without cholangitis; ** Previous ENBD was performed for the future remnant liver.