



Title	The incidence and mechanism of sunitinib-induced thyroid atrophy in patients with metastatic renal cell carcinoma
Author(s)	Shinohara, Nobuo; Takahashi, Masayuki; Kamishima, Tamotsu; Ikushima, Hitoshi; Otsuka, Noriyuki; Ishizu, Akihiro; Shimizu, Chikara; Kanayama, Hiroomi; Nonomura, Katsuya
Citation	British Journal of Cancer, 104(2), 241-247 https://doi.org/10.1038/sj.bjc.6606029
Issue Date	2011-01-18
Doc URL	http://hdl.handle.net/2115/46823
Type	article (author version)
File Information	BJC104-2_241-247.pdf



[Instructions for use](#)

Title:

The incidence and the mechanism of sunitinib-induced thyroid atrophy in patients with metastatic renal cell carcinoma

Running title: **Sunitinib-induced thyroid atrophy in metastatic RCC**

Authors:

Nobuo Shinohara ^a, Masayuki Takahashi ^b, Tamotsu Kamishima ^c, Hitoshi Ikushima ^d,
Noriyuki Otsuka ^e, Akihiro Ishizu ^f, Chikara Shimizu^g, Hiroomi Kanayama ^b, Katsuya
Nonomura ^a

^a Department of Renal and Genitourinary Surgery, Hokkaido University Graduate School of Medicine, North-15, West-7, Kitaku, Sapporo, 060-8638, Japan

^b Department of Urology, University of Tokushima Graduate School, Kuramae-cho 3-choume, Tokushima, 770-8503, Japan

^c Department of Radiology, Hokkaido University Graduate School of Medicine, North-15, West-7, Kitaku, Sapporo, 060-8638, Japan

^d Department of Radiology, University of Tokushima Graduate School, Tokushima,

Kuramae-cho 3-choume, Tokushima, 770-8503, Japan

^e Department of Pathology, Hokkaido University Graduate School of Medicine,

North-15, West-7, Kitaku, Sapporo, 060-8638, Japan

^f Faculty of Health Sciences, Hokkaido University, North-12, West-5, Kitaku, Sapporo,

060-0812, Japan

^g Division of Laboratory and Transfusion Medicine, Hokkaido University Hospital, North-14,

West-5, Kitaku, Sapporo, 060-8648, Japan

Corresependence: Nobuo Shinohara, MD

Department of Urology, Hokkaido University Graduate School of Medicine,

North-15, West-7, Kitaku, Sapporo, 060-8638, Japan.

Telephone number: 011-706-5966

Fax number: 011-706-7853

E-mail: nobuo-s@med.hokudai.ac.jp

Conflict of interest: None

Abstract

Background: In order to elucidate the incidence and the mechanisms of sunitinib-induced thyroid atrophy, we investigated the serial volumetric and functional changes, and evaluated histological changes of the thyroid gland in metastatic renal cell carcinoma patients who received sunitinib.

Methods: Thyroid volume measured by CT volumetry and thyroid function were measured at baseline, during the treatment, and at post-treatment periods. Histological evaluation of thyroid gland was performed in 4 autopsied patients.

Results: The median reduction rate in thyroid volume at last evaluation during sunitinib treatment was 30% in all 17 patients. The incidence of hypothyroidism during sunitinib treatment was significantly higher in the high reduction rate group (n=8; more than 50% reduction in volume) than in the low reduction rate group (n=9; less than 50% reduction in volume). Half of patients in the high reduction rate group exhibited a transient TSH suppression suggesting thyrotoxicosis during sunitinib treatment.

Histological evaluation demonstrated atrophy of thyroid follicles and degeneration of follicular epithelial cells without critical diminution of vascular volume in the thyroid gland.

Conclusion: Thyroid atrophy is frequently observed following sunitinib treatment and

may be brought about by sunitinib-induced thyrotoxicosis or the direct effects of sunitinib that leads to degeneration of thyroid follicular cells.

Key words: Thyroid atrophy, hypothyroidism, sunitinib, renal cell carcinoma

Introduction

Sunitinib malate (SUTENT, Pfizer Inc., New York, NY, USA) is an oral, multitargeted tyrosine kinase inhibitor of vascular endothelial growth factor receptors (VEGFRs), platelet-derived growth factor receptors (PDGFRs), stem cell factor receptor (c-KIT), and rearranged during transfection (RET). It has been approved for the treatment of gastrointestinal stromal tumor (GIST) and metastatic renal cell carcinoma (RCC). Single-agent sunitinib showed unprecedented antitumor activity in two phase II trials with patients with metastatic RCC, demonstrating an objective response rate of 33% (Motzer et al, 2006a; Motzer et al, 2006b). Furthermore, sunitinib demonstrated superior first-line efficacy over IFN-alpha, with significantly greater progression-free survival (Motzer et al, 2007; Motzer, et al 2009). On the basis of these results, sunitinib is one of the standard drugs for treatment-naïve RCC in the National Comprehensive Cancer Network (NCCN) treatment guidelines.

Although sunitinib is a potent drug, it is relatively toxic and is reported to have several treatment-related adverse events such as myelosuppression, hypertension, hand-foot syndrome, and diarrhea (Motzer et al, 2009; Theou-Anton et al, 2009). Of these, hypothyroidism has recently been recognized as one of the most frequently

observed adverse events and a clinically relevant toxicity of sunitinib. In a prospective study by Desai et al., hypothyroidism developed in 15 (36%) of 42 patients with GIST treated with sunitinib for a mean of 50 weeks (Desai et al, 2006). Rini et al. reported that hypothyroidism occurred in 56 (85%) of 66 patients with metastatic RCC at a median of 2 cycles of sunitinib treatment (Rini et al, 2007). Although the mechanism behind this complication remains unclear, it is considered that treatment with levothyroxine sodium can control subclinical and overt hypothyroidism induced by sunitinib.

Sunitinib is reported to induce another type of toxicity of the thyroid, thyroid atrophy, in some patients. In the study by Desai et al., severe thyroid atrophy occurred in two patients who experienced sunitinib-induced thyrotoxicosis, which was probably due to destructive thyroiditis (Desai et al, 2006). On the other hand, Mannavola et al. reported that, in 11 patients with GIST, the thyroids of whom were evaluated by ultrasonography, no changes in volume and/or echographic pattern were recorded during the sunitinib treatment (Mannavola et al, 2007). Thus, no consensus has yet been reached on whether sunitinib induces thyroid atrophy during the treatment. Furthermore, there is no data on the histological changes in the thyroid gland in patients who have received sunitinib. In order to elucidate the incidence and the underlying

mechanisms of thyroid atrophy, we investigated the serial volumetric and functional changes, and evaluated histological changes of thyroid gland, in patients with metastatic RCC who received sunitinib.

Patients and Methods:

1. Patients

A total of 17 patients with metastatic RCC were enrolled in a prospective observational study. Twelve patients were treated in a phase II trial investigating single-agent sunitinib therapy for Japanese patients with metastatic RCC (Uemura et al, 2010). The remaining 5 patients were enrolled after April 2008 as a cohort of a post-marketing surveillance study. Patients having a history of medical treatment for thyroid disease and those with sunitinib therapy for less than 4 weeks were excluded from the present study.

In most patients, sunitinib was administered at a starting dose of 50 mg orally, once daily, in the morning, without regard to meals, in repeated 6-week cycles according to Schedule 4/2 (4 weeks on treatment followed by 2 weeks off). Patients were monitored for toxicity, and doses were adjusted following individual patient tolerance according to the following protocol. Doses were reduced to 37.5 mg/day in cases of treatment-related grade ≥ 3 adverse events, and additionally to a minimum dose of 25 mg/day if toxicities persisted. Treatment was continued until one of the following occurred: disease progression; requirement for additional anticancer treatment; development of left ventricular dysfunction; or treatment withdrawal.

Tumour assessments were based on the Response Evaluation Criteria in Solid Tumours (RECIST) (Therasse et al, 2000), with computed tomography obtained before treatment and on day 1 of treatment cycles. All patients gave written informed consent.

The present study was approved by the institutional review board (IRB) at two institutions and was conducted in accordance with the International Conference on Harmonization Guidelines for Good Clinical Practice.

2. Evaluation of thyroid function

Thyroid function test (TFT) was assessed at baseline and on days 1 of each treatment cycle in all but one patient, for whom the collection of a blood sample at baseline was not carried out. As a TFT, we measured serum TSH (thyroid-stimulating hormone; reference range 0.38-4.31 mIU/L), free triiodothyronine (fT3; reference range 2.1-3.8 pg/mL), and free thyroxine (fT4; reference range 0.82-1.63 ng/dL). A TFT was always carried out before performing a CT scan with iodine contrast. In some patients, antithyroglobulin antibody (reference range 0-13.6 IU/ml) and antithyroid peroxidase antibody (reference range 0-3.2 IU/ml) were assessed.

Subclinical hypothyroidism is defined as serum TSH above the upper limit of normal values, with fT4 within normal limits at baseline and on day 1 of each cycle.

Overt hypothyroidism is defined as low serum fT4 together with elevated TSH.

Thyroid hormone replacement therapy utilizing levothyroxine sodium was initiated in patients with at least two consecutive serum TSH measurements >10 mIU/L or with any symptoms compatible with hypothyroidism according to the recommendation in Desai et al. (Desai et al, 2006).

3. Measurement of thyroid gland volume with CT scan

In all patients, thyroid volume was measured serially by CT volumetry on a cervical-pelvic CT scan, which was evaluated every 1 or 2 cycles to assess tumor response. CT volumetry was performed by two radiologists (T.K. and H.I.) who had no clinical information on thyroid function, using a commercially available workstation (ZIOSOFT, ZIOSOFT Inc., Tokyo, Japan) (Kato et al, 2009). With ZIOSOFT, three-dimensional (3D) reconstruction images of thyroid glands were created using contrast-enhanced CT images of the renal parenchymal phase with a slice thickness of 5 mm (Figure 1a). After creating 3D reconstruction images of thyroid glands (Figure 1b), the volume of thyroid glands was obtained. By CT volumetry, the volume of thyroid gland in patient 5 (before sunitinib treatment) was measured to be 7.8 ml. Figures 1c and 1d showed a cross sectional image and a 3D reconstruction image of

thyroid gland, respectively, 15 months after the start of sunitinib treatment in same patient (thyroid volume=1.2mL).

4. Histological evaluation of thyroid gland at autopsy

Histological evaluation of the thyroid gland was performed in the 4 patients who received sunitinib and subsequently died of progressive disease, and in a 57-year-old male patient who died of cardiac attack. The patient who died of cardiac attack was never administered sunitinib. Two pathologists (N.O. and A.I.), who had no clinical information on thyroid function, evaluated the hematoxylin-eosin (HE)-stained specimens of thyroid gland obtained from the 4 autopsied patients. Furthermore, immunohistochemistry with antibody to CD34 was undertaken to analyze thyroidal capillarization and arterializations.

5. Statistical analysis

Groups of subjects were compared using Mann-Whitney U test (continuous variables) or using Pearson's χ^2 test or Fischer's exact test (discrete variables). Progression-free survival (PFS) was defined as the interval from the start of sunitinib treatment until confirmation of disease progression or death. PFS was

evaluated by the Kaplan–Meier method with the significance determined using the log-rank test. For all statistical analyses, $p < 0.05$ was regarded as statistically significant.

Results:

The backgrounds of the 17 patients are summarized in Table 1. The median age was 62 years (range 23-78). Nine patients (53%) had undergone previous treatment with IFN- α . At the time of final analysis, patients had received a median of 6 cycles of sunitinib treatment (range 1-23). The objective response rate by RECIST was 53%, with 1 patient (6%) and 8 patients (47%) achieving confirmed CR and confirmed PR, respectively. Stable disease (SD) for 6 months or longer was also obtained in 3 patients (18%). Median PFS of all 17 patients was 11.9 months. In terms of the TFT at baseline, 12 patients had no abnormal TFT and 4 patients showed subclinical hypothyroidism. Median serum TSH concentration at baseline was 1.63 mIU/L (range 0.53-10.14). There was no significant difference in serum TSH concentration (mean+SD) at baseline between patients who receive IFN- α and those who did not (1.69+0.87 vs 5.22+4.19, $p=0.244$). Thyroid autoantibodies, anti-thyroglobulin and anti-thyroid peroxidase antibody, were not detected in all 6 patients assessed, in whom 2

patients were subclinical hypothyroidism and the remainings showed euthyroid at baseline. No patient had any symptoms suggesting hypothyroidism at the entry.

With regard to the thyroid function impairment during treatment with sunitinib, 9 patients (53%) developed hypothyroidism and received an appropriate dose of levothyroxine sodium (50-150 µg/day) in all but one patient (patient 8). Of these, four patients experienced a transient TSH suppression suggesting thyrotoxicosis before the development of overt hypothyroidism. The remaining 8 patients retained euthyroid status throughout treatment with sunitinib, with a median of 2 cycles (range 1-6). All 4 patients with subclinical hypothyroidism at baseline developed to overt hypothyroidism during sunitinib treatment. In the 12 patients with euthyroid at baseline, hypothyroidism occurred in 4 patients and 8 patients retained their euthyroid status. These results suggest that hypothyroidism are likely to occur in patients with subclinical hypothyroidism at baseline, compared with those with euthyroid (p=0.083).

In 17 patients evaluated in the present study, median thyroid volume at baseline was 13.6 mL (range 5.8-20.2 mL). There was no difference in thyroid volume (mean+SD) at baseline between patients who previously receive IFN- α and those who did not (13.99+5.39 mL vs 13.50+4.17 mL, p=0.810). Since dispersion of thyroid volume at baseline was shown among the patients, the changes in thyroid volume were

evaluated as rate of reduction in thyroid volume at each measurement during treatment with sunitinib relative to that at baseline. The median reduction rate was 30% at the last evaluation during sunitinib treatment.(median 6 cycles, range 1-23 cycles). On the basis of the reduction rate in thyroid volume, we could clearly stratify the patients into two groups: high reduction rate group (more than 50% reduction) in 8 patients and low reduction rate group (less than 50% reduction) in 9 patients. The median reduction rate of thyroid volume and median thyroid volume at the last evaluation during sunitinib treatment were 78% (range 52-95) and 2.1 mL (range 0.4-8.0) in the high reduction rate group, respectively. The serial changes of thyroid volume and serum TSH level in each patient of the high reduction rate group are shown in Figures 2a and 2b. The median reduction rate of thyroid volume and median thyroid volume at the last evaluation during sunitinib treatment were 10% (range 0-30) and 13.0 mL (range 2.8-20.9) in the low reduction rate group, respectively (Figure 3). The patient characteristics in the two groups are listed in Table 2. The patients of the high reduction rate group received significantly more cycles of sunitinib treatment and had a significantly higher response rate than the patients of the low reduction rate group. Furthermore, median PFS was significantly longer in the former than in the latter. Although there was no significant difference in the incidence of subclinical

hypothyroidism at baseline between the two groups, the incidence of hypothyroidism during sunitinib treatment was significantly higher in the high reduction rate group (100%) than in the low reduction rate group (11%). Additionally, 4 of 8 patients in the high reduction rate group exhibited signs of thyrotoxicosis during sunitinib treatment. The maximum TSH value during sunitinib treatment was also significantly higher in the high reduction rate group.

Of 17 patients evaluated in the present study, 6 patients have continued to receive sunitinib treatment and sunitinib was stopped in 11 patients owing to disease progression. In the latter group, 4 patients died of cancer in the period after the discontinuation of sunitinib therapy. We evaluated the changes in TSH value and thyroid volume in 4 of the remaining 7 patients who underwent subsequent therapy. No increase in thyroid volume was observed in 2 patients of the high reduction rate group during sunitinib treatment. These 2 patients experienced overt hypothyroidism with a profound elevation in TSH (326 mIU/L, 123 mIU/L) after the discontinuation of sunitinib and levothyroxine sodium in accordance with the suggestion made by Mannavola et al. (Mannavola et al, 2007). On the other hand, changes in thyroid volume and TSH value did not occur in the two patients belonging to the low reduction rate group.

We also evaluated the histological changes in thyroid gland in the 4 autopsied patients. Although atrophy of thyroid follicles and degeneration of follicular epithelial cells were observed in all 4 patients, 2 patients (Cases 2 and 5) of the high reduction rate group who received sunitinib for a long period had more marked changes in the thyroid gland than the 2 patients (cases 12 and 15) with short-term treatment of sunitinib who belonged to the low reduction rate group (Figure 4). In the thyroid glands without atrophy, the vessels were distributed around the follicles. On the other hand, the mesh distribution of vessels was destroyed with destruction of the follicles in the 2 patients who belonged to the high reduction rate group. However, the volume of vessels in the thyroid gland was relatively well preserved even in the 2 patients with marked thyroid atrophy (Figure 5).

Discussion

The present study revealed that sunitinib can induce a reduction in thyroid volume, thyroid atrophy, as well as hypothyroidism. It is well known that hypothyroidism is frequently associated with sunitinib treatment (Desai et al, 2006; Rini et al, 2007; Mannavola et al, 2007; Wolter P et al, 2008). In the present study, about half of the patients evaluated developed hypothyroidism after a median of 2 cycles of treatment. Sunitinib-induced hypothyroidism is common in Japanese patients as well as in Caucasian patients. On the other hand, whether or not thyroid atrophy is caused by sunitinib treatment has remained unclear. In order to clarify the actual effect of sunitinib on the thyroid gland, we measured serial changes in thyroid volume and evaluated histological changes in the thyroid gland in patients who received sunitinib.

Although the size of the thyroid gland is generally evaluated by ultrasonography, we measured it by CT volumetry on cervical-pelvic CT scans. Although there is the problem of radiation exposure in CT volumetry, unlike in ultrasonographic evaluation, operator-dependent bias for the measurement of the thyroid volume may be small in CT volumetry (Nygaard et al, 2002). The median thyroid volume measured by CT volumetry in the 17 patients before sunitinib treatment was 13.6 ml. Furthermore, thyroid volume at baseline was not affected by previous IFN- α treatment. Lee et al.

recorded a thyroid volume of 17.5 ± 6.6 ml by CT measurement in their study (Lee et al, 2006). The standard volume of the thyroid gland in adults has been reported as 13-18 ml, and the baseline volume in our patients could be considered as equivalent to this adult standard (Langer, 1989).

In patients receiving sunitinib, a serial reduction in thyroid volume occurred in 8 of the 17 patients evaluated. There have been a few studies on changes in thyroid size in patients receiving sunitinib treatment. Desai et al. reported that two patients with destructive thyroiditis had marked thyroid atrophy that caused hypothyroidism (Desai et al, 2006). More recently, Rogiers et al. reported that markedly shirinkage of thyroid volume during treatment with sunitinib was observed in two RCC patients with a preexisting nodular thyroid gland (Rogiers et al, 2010). On the other hand, Mannavola et al. reported that there was no evidence of thyroid atrophy in patients undergoing sunitinib treatment (Mannavola et al, 2007). It is questionable whether their observation period was long enough, since our study showed that a reduction in thyroid volume of more than 50% occurred in most patients who received more than 6 cycles of treatment. All eight patients with more than 50% reduction in thyroid size had hypothyroidism, and half of them developed it after a transient TSH suppression suggesting thyrotoxicosis. From the data on thyroid autoantibodies, a transient TSH

suppression in 2 patients does not appear to result from autoimmune mediated hyperthyroidism. Furthermore, we have to consider the possibility that thyrotoxicosis might be brought about by the Iodine contrast medium which was used at CT scan. However, the effect of Iodine contrast medium on the development of thyrotoxicosis does not appear to be too strong because a thyroid function test was carried out before performing a CT scan in all patients. These results suggest that thyrotoxicosis which was induced by sunitinib itself would be one of the mechanisms that result in thyroid atrophy.

In order to clarify the effects of sunitinib on the thyroid gland and the mechanism underlying thyroid atrophy, histological evaluation of the thyroid gland was carried out in patients who underwent autopsy. To the best of our knowledge, histological examination of the thyroid gland has not been reported in patients who received sunitinib. We found that there was less damage to the blood supply of the thyroid gland, but there were atrophic thyroid follicles and degeneration of follicular epithelial cells. These changes were pronounced in patients with severe thyroid atrophy after long-term sunitinib treatment. The patients who had received short-term treatment without changes in thyroid volume also showed atrophic thyroid follicles and degeneration of follicular epithelial cells. Kamba et al. reported that a loss of thyroid

homeostasis was associated with inhibition of vascularization by tyrosine kinase inhibitor in a mouse model and that this might be one of the causes of hypothyroidism and thyroid atrophy (Kamba et al, 2006). Makita et al. described the RCC patient who displayed overt hypothyroidism with an atrophic thyroid during on-periods in the sunitinib treatment cycles and who showed a recovery of thyroid size during off-periods (Makita et al, 2010). They speculated that thyroid function and volume depended on the vascularity which was negatively regulated by sunitinib. On the other hand, Mannavola et al. demonstrated that there was no reduction in thyroid blood flow in patients receiving sunitinib in ultrasonographic evaluation with color Doppler, a finding that supports our results (Mannavola et al, 2007). Salem et al. showed that sunitinib acts on the thyroid gland by inhibiting the growth of FRTL-5 thyroid cells in a time-related and dose-related manner (Salem et al, 2008). The degeneration of thyroid follicular cells revealed by our study may indicate a direct effect of sunitinib on these cells.

We also examined whether or not thyroid volume increased after discontinuation of sunitinib. However, there were no patients who showed an increase in thyroid volume after the discontinuation. Furthermore, two patients developed a marked elevation in serum TSH and symptoms of hypothyroidism after discontinuation of both sunitinib and

levothyroxine sodium. Mannavola et al. claimed that patients with hypothyroidism caused by sunitinib treatment would improve spontaneously after cessation of treatment with sunitinib and levothyroxine sodium (Mannavola et al, 2007). However, our results suggest that hypothyroidism associated with severe thyroid atrophy caused by sunitinib may be irreversible, at least during a short-term follow-up.

The present study demonstrated that sunitinib causes not only hypothyroidism but also thyroid atrophy in RCC patients who receive the drug over a long period, and that this can result in irreversible hypothyroidism. Possible causes for this are considered to be sunitinib-induced thyrotoxicosis in some patients and a direct effect of sunitinib that leads to degeneration of thyroid follicular cells in others.

References

Desai J, Yassa L, Marqusee E, George S, Frates MC, Chen MH, Morgan JA, et al:

(2006) Hypothyroidism after sunitinib treatment for patients with gastrointestinal stromal tumor. *Ann Intern Med* 145: 660-664.

Kamba T, Tam BY, Hashizume H, Haskell A, Sennino B, Mancuso MR, Norberg SM,

O'Brien SM, Davis RB, Gowen LC, Anderson KD, Thurston G, Joho S, Springer ML,

Kuo CJ, McDonald DM (2006) VEGF-dependent plasticity of fenestrated capillaries in the normal adult microvasculature. *Am J Physiol Heart Circ Physiol* 290: H560-576.

Kato F, Kamishima T, Morita K, Muto NS, Okamoto S, Omatsu T, Oyama N, Terae S,

Kanegae K, Nonomura K, Shirato H (2009) Rapid estimation of split renal function in kidney donors using software developed for computed tomographic renal volumetry.

Eur J Radiol. Dec 4. [Epub ahead of print]

Langer P (1989) Normal thyroid size versus goiter--postmortem thyroid weight and

ultrasonographic volumetry versus physical examination. *Endocrinol Exp.* 23: 67-76.

Lee DH, Cho KJ, Sun DI, Hwang SJ, Kim DK, Kim MS, Cho SH (2006) Thyroid dimensions of Korean adults on routine neck computed tomography and its relationship to age, sex, and body size. *Surg Radiol Anat.* 28: 25-32.

Makita N, Miyakawa M, Fijita T, Iiri T (2010) Sunitinib induces hypothyroidism with a markedly reduced vascularity. *Thyroid* 20: 323-326

Mannavola D, Coca P, Vannucchi G, Bertuelli R, Carletto M, Casali PG, Beck-Peccoz P, Fugazzola L (2007) A novel tyrosine-kinase selective inhibitor, sunitinib, induces transient hypothyroidism by blocking iodine uptake. *J Clin Endocrinol Metab* 92: 3531-3534.

Motzer RJ, Michaelson MD, Redman BG, Hudes GR, Wilding G, Figlin RA, et al: (2006a) Activity of SU11248, a multitargeted inhibitor of vascular endothelial growth factor receptor and platelet-derived growth factor receptor, in patients with metastatic renal cell carcinoma. *J Clin Oncol* 24: 16-24

Motzer 2006b; Motzer RJ, Rini BI, Bukowski RM, Curti BD, George DJ, Hudes GR, et al (2006b) Sunitinib in patients with metastatic renal cell carcinoma. *JAMA* 295: 2516-2524.

Motzer RJ, Hutson TE, Tomczak P, Michaelson MD, Bukowski RM, Rixe O, et al (2007) Sunitinib versus interferon alfa in metastatic renal-cell carcinoma. *N Engl J Med* 356: 115-124.

Motzer RJ, Hutson TE, Tomczak P, Michaelson MD, Bukowski RM, Oudard S, et al (2009) Overall survival and updated results for sunitinib compared with interferon alfa in patients with metastatic renal-cell carcinoma. *J Clin Oncol* 27: 3584-3590.

Nygaard B, Nygaard T, Court-Payen M, Jensen LI, S e-Jensen P, Gerhard Nielsen K, Fugl M, Heged s L (2002) Thyroid volume measured by ultrasonography and CT. *Acta Radiol* 43: 269-74.

Rini BI, Tamaskar I, Shaheen P, Salas R, Garcia J, Wood L, Reddy S, Dreicer R,

Bukowski RM (2007) Hypothyroidism in patients with metastatic renal cell carcinoma treated with sunitinib. *J Natl Cancer Inst* 99: 81-83.

Rogiers A, Wolter P, de Beeck KO, Thijs M, Decallonne B, Schoffski P (2010)

Shrinkage of thyroid volume in sunitinib-treated patients with renal cell carcinoma: a potential marker of irreversible thyroid dysfunction. *Thyroid* 20: 317-322.

Salem AK, Fenton MS, Marion KM, Hershman JM (2008) Effect of sunitinib on growth and function of FRTL-5 thyroid cells. *Thyroid*. 18: 631-635.

Therasse P, Arbuck SG, Eisenhauer EA, Wanders J, Kaplan RS, Rubinstein L, et al (2000) New guidelines to evaluate the response to treatment in solid tumors. *J Natl Cancer Inst* 92: 205–16.

Theou-Anton N, Faivre S, Dreyer C, Raymond E (2009) Benefit-risk assessment of

sunitinib in gastrointestinal stromal tumors and renal cancer. *Drug Safety* 32: 717-734.

Uemura H, Shinohara N, Yuasa T, Tomita Y, Fujimoto H, Niwakawa M, Mugiya S, Miki T, Nonomura N, Takahashi M, Hasegawa Y, Agata N, Houk B, Naito S, Akaza H (2010)

A Phase II Study of Sunitinib in Japanese Patients with Metastatic Renal Cell

Carcinoma: Insights into the Treatment, Efficacy and Safety. *Jpn J Clin Oncol*

40:194-202.

Wolter P, Stefan C, Decallonne B, Dumez H, Bex M, Carmeliet P, Schöffski P (2008)

The clinical implications of sunitinib-induced hypothyroidism: a prospective evaluation.

Br J Cancer 99: 448-454.

Figure legends

Figure. 1 Measurement of thyroid gland volume with CT scan

A cross sectional image (Figure 1a) and 3D reconstruction image (Figure 1b) of thyroid gland in CT scan with contrast at baseline in patient 5 (Thyroid volume 7.8 mL). A cross sectional image (Figure 1c) and 3D reconstruction image (Figure 1d) of thyroid gland in same patient 15 months after the start of sunitinib treatment (Thyroid volume was 1.2 ml).

Figure. 2 Serial changes in thyroid volume and serum TSH level in high reduction rate group (n=8)

The 4 patients experienced a transient TSH suppression suggesting thyrotoxicosis before the development of hypothyroidism (Figure 2a). A maximum suppression level of serum TSH and duration of a TSH suppression were 0.03 mIU/L and 28 days, 0.05 mIU/L and 14 days, 0.08 mIU/L and 28 days, and 0.03 mIU/L and 14 days, in patients 1,2,3,and 4, respectively. The remaining 4 patients did not show signs of thyrotoxicosis (Figure 2b). The bold lines delineate the change of thyroid gland volume during sunitinib treatment and the dotted lines demonstrate serial change of serum TSH level measured at day 1 of each cycle . ★: the development of thyrotoxicosis. ▼: the start of levothyroxine. TSH, thyroid-stimulating hormone

Figure. 3 Serial changes in thyroid volume in low reduction rate group (n=9)

Figure. 4 Histological changes in thyroid gland

a: Thyroid gland obtained from patient who received sunitinib for 15 months

(Patient 5). The patient underwent best supportive care for 6 months after the discontinuation of sunitinib therapy and no change in thyroid gland volume had been observed.

b: Thyroid gland obtained from patient who received sunitinib for 2 months

(Patient 12). The patient died of cancer one month after the discontinuation of sunitinib therapy.

c: Thyroid gland obtained from patient who died of cardiac attack without the past history of thyroidal disease..

Figure 5 Vascular distribution of thyroid gland

a: Thyroid gland obtained from patient who received sunitinib for 15 months

(Patient 5).

b: Thyroid gland obtained from patient who received sunitinib for 2 months

(Patient 12)

c: Thyroid gland obtained from patient who died of cardiac attack

Table 1 Baseline demographic and clinical characteristics of 17 patients

Pt	Gender/age (Yr)	Pre-Tx with IFN /duration (months)	Total cycle of sunitinib	Best response by sunitinib	Thyroid autoantibody		At baseline			During sunitinib-Tx		
					<u>Thyroglobulin antibody (IU/ml)</u>	<u>TPO antibody (IU/ml)</u>	<u>Thyroid volume(ml)</u>	TSH (mLU/L)	Status	<u>Thyroid volume (ml)</u>	TSH (mLU/L)	Status
1	F/44	No	9	PR	<u><0.15</u>	<u><0.15</u>	<u>18.5</u>	5.06	Hypo	<u>8</u>	33.15	Hypo*
2	F/62	No	6	PR	<u><0.15</u>	<u><0.15</u>	<u>8.3</u>	1.6	Eu	<u>2.4</u>	117.53	Hypo*
3	M/65	No	23	CR	—	—	<u>17.3</u>		Unknown	<u>1.1</u>	137.13	Hypo*
4	M/64	No	11	SD	—	—	<u>10.6</u>	9.43	Hypo	<u>0.4</u>	230.89	Hypo*
5	M/69	Yes / 6	10	PR	<u><0.15</u>	<u><0.15</u>	<u>7.8</u>	3.62	Eu	<u>1.2</u>	27.23	Hypo
6	F/56	Yes / 3	20	PR	—	—	<u>11.6</u>	1.86	Eu	<u>1.7</u>	42.53	Hypo
7	F/59	No	18	PR	—	—	<u>18.2</u>	10.14	Hypo	<u>6.6</u>	19.8	Hypo
8	<u>F/66</u>	<u>No</u>	<u>16</u>	<u>PR</u>			<u>14.3</u>	<u>0.61</u>	<u>Eu</u>	<u>6.8</u>	<u>4.69</u>	<u>Hypo</u>
9	M/52	Yes / 6	6	PR	—	—	<u>21</u>	1.29	Eu	<u>22</u>	3.06	Eu
10	<u>F/23</u>	<u>No</u>	<u>2</u>	<u>PD</u>	<u><0.15</u>	<u><0.15</u>	<u>8.8</u>	<u>8.65</u>	<u>Hypo</u>	<u>7.9</u>	<u>12.72</u>	<u>Hypo</u>
11	M/65	Yes / 24	3	PR	<u><0.12</u>	<u><0.05</u>	<u>13.6</u>	1.66	Eu	<u>13</u>	3.71	Eu
12	M/55	Yes / 3	2	PD	—	—	<u>11.4</u>	0.84	Eu	<u>9.5</u>	3.91	Eu
13	M/64	No	2	PD	—	—	<u>12</u>	1.07	Eu	<u>10</u>	3.93	Eu
14	M/78	Yes / 6	2	SD	—	—	<u>20.2</u>	2.24	Eu	<u>19.2</u>	2.3	Eu
15	F/59	Yes / 6	1	PD	<u><0.12</u>	<u><0.05</u>	<u>5.8</u>	1.49	Eu	<u>2.8</u>	3.14	Eu
16	M/76	Yes / 20	4	SD	—	—	<u>15.6</u>	0.65	Eu	<u>14</u>	3.51	Eu
17	M/45	Yes / 2	1	PD	—	—	<u>18.9</u>	1.57	Eu	<u>20.9</u>	1.73	Eu

* Evidence of thyrotoxicosis before experiencing hypothyroidism, Tx: treatment, TPO: Thyroid peroxidase, TSH: Thyroid stimulating hormone

Eu: Euthyroid, Hypo: Hypothyroidism

Table 2 Patient characteristics upon stratification into two groups by the rate of reduction in thyroid volume

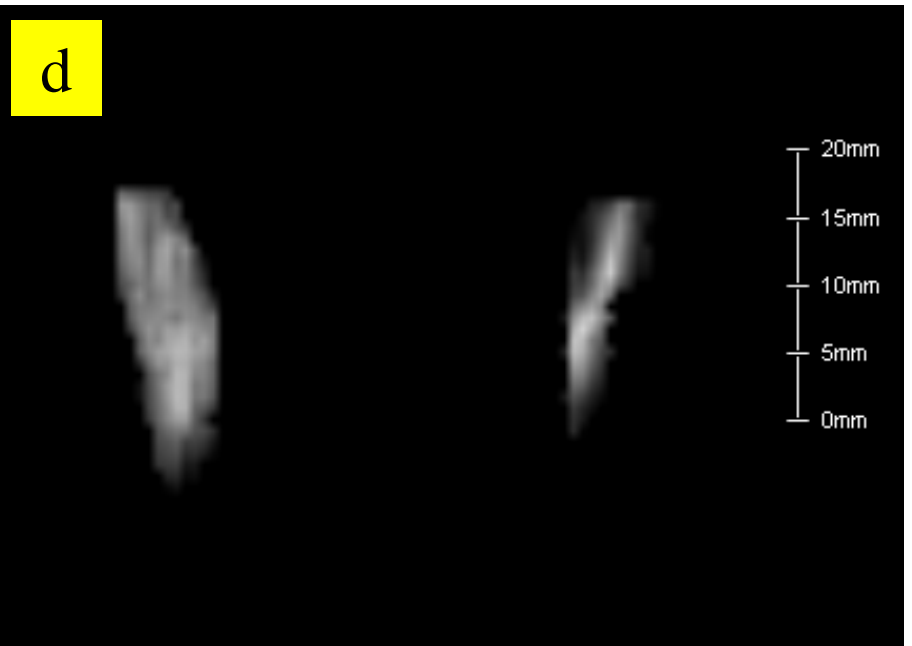
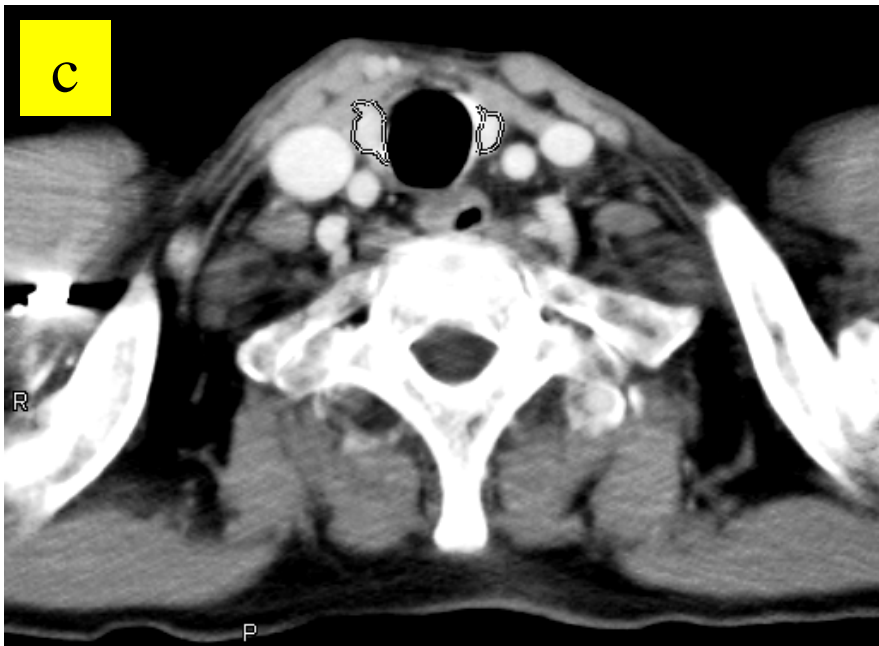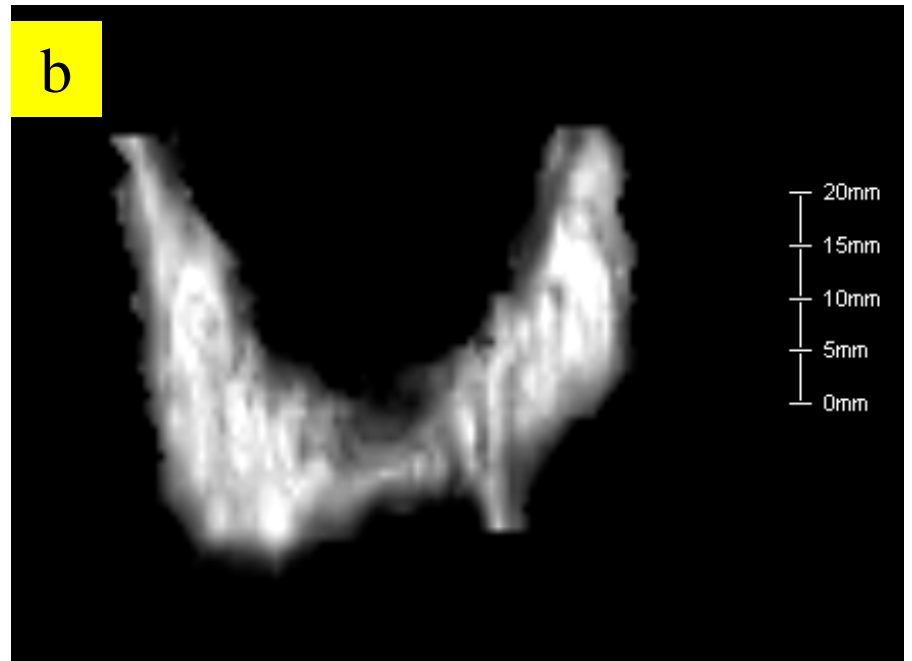
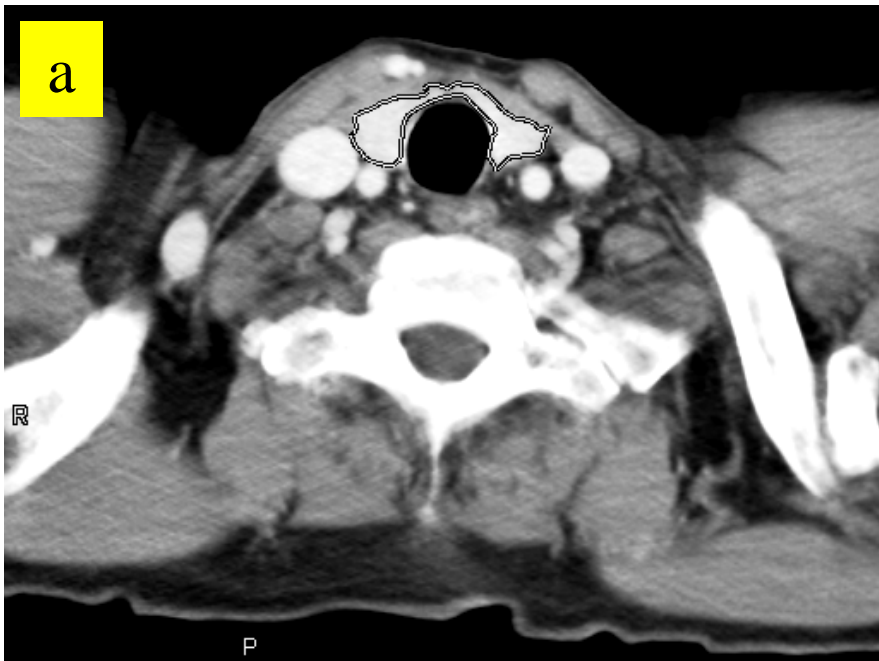		High reduction rate group	Low reduction rate group	p-value
Gender	female/male	5 / 3	2 / 7	0.234
Age, yrs	median (range)	63 (44-69)	59 (23-78)	0.797
Sunitinib Tx, cycles	median (range)	13.5 (6-23)	2 (1-6)	0.001
ORR	CR/PR	7	2	
	SD	1	2	
	PD	0	5	0.012
<u>50%PFS, months</u>		<u>Not reach(>14.9)</u>	<u>2.3</u>	<u>0.004</u>
Thyroid status at baseline				
	Hypothyroidism	3	1	
	Euthyroid	4	8	
	Unknown	1	0	0.243
TSH at baseline, mIU/L	median (range)	3.62 (0.61-10.14)	1.57 (0.52-8.65)	0.314
Thyroid volume at baseline, ml	median (range)	13.0 (7.8-18.5)	13.6 (5.8-21.0)	0.797
Thyroid status during sunitinib-Tx				
	<u>Hypothyroidism</u>	<u>8 *</u>	<u>1</u>	
	<u>Euthyroid</u>	<u>0</u>	<u>8</u>	<u>0.001</u>
Max. TSH during sunitinib-Tx, mIU/L	median (range)	37.84 (4.69-230.89)	3.51 (1.73-12.72)	0.001
Supplement of L-T4	During sunitinib-Tx	7	1	0.008

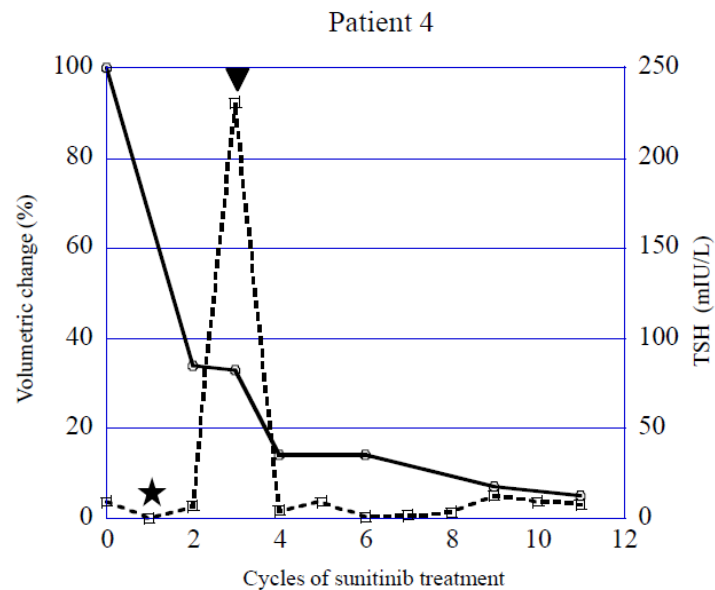
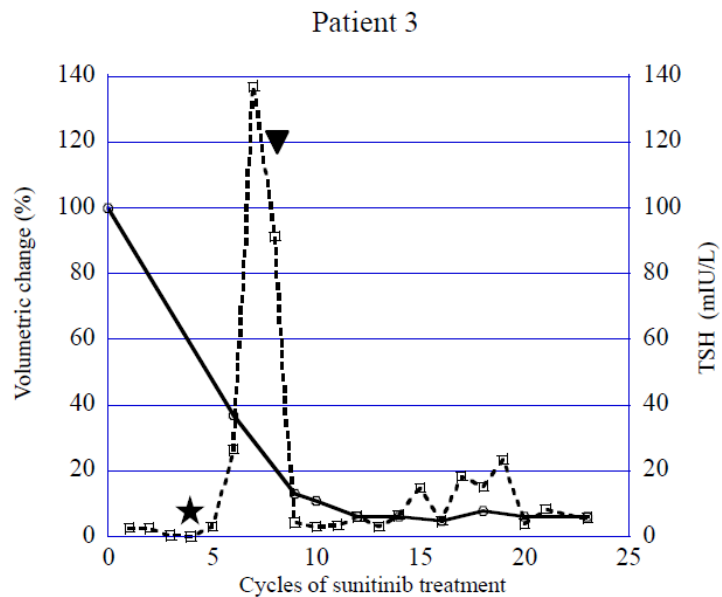
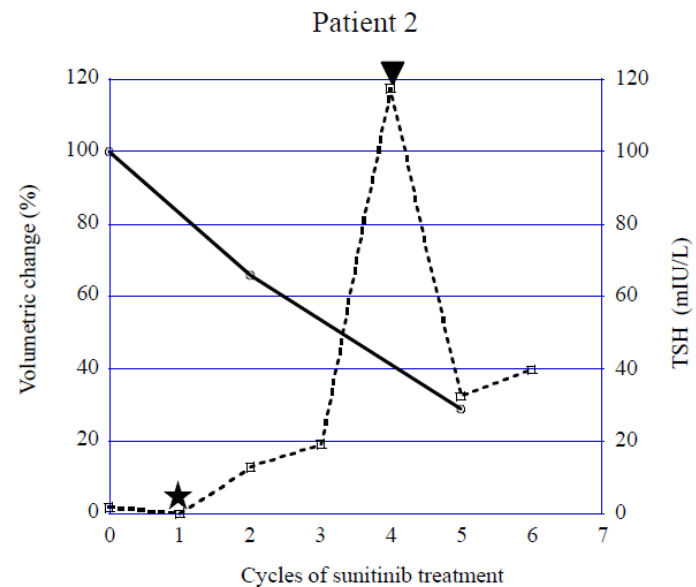
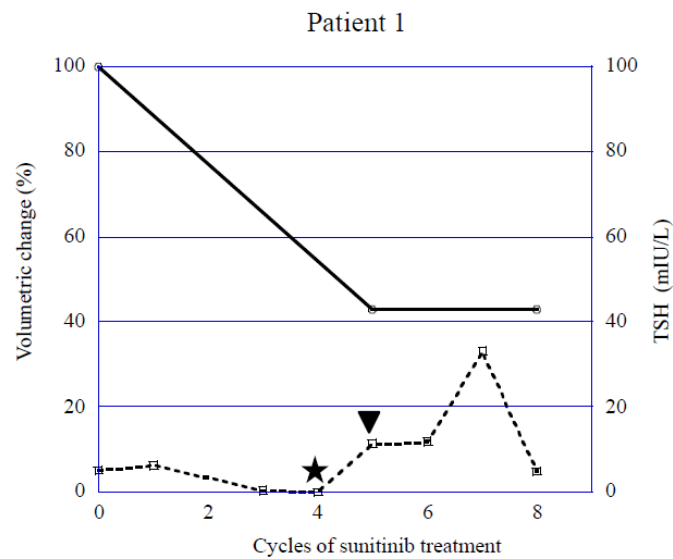
*Four patients experienced hyperthyroidism before hypothyroidism

Tx: Therapy, ORR: Objective response rate, CR: Complete response, PR: Partial response,

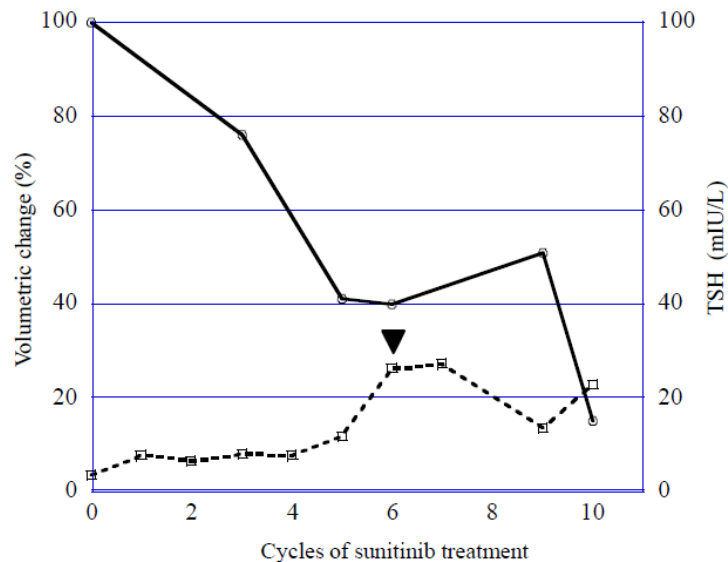
SD: Stable disease, PD: Progressive disease, PFS: Progression-free survival,

TSH: Thyroid stimulating hormone

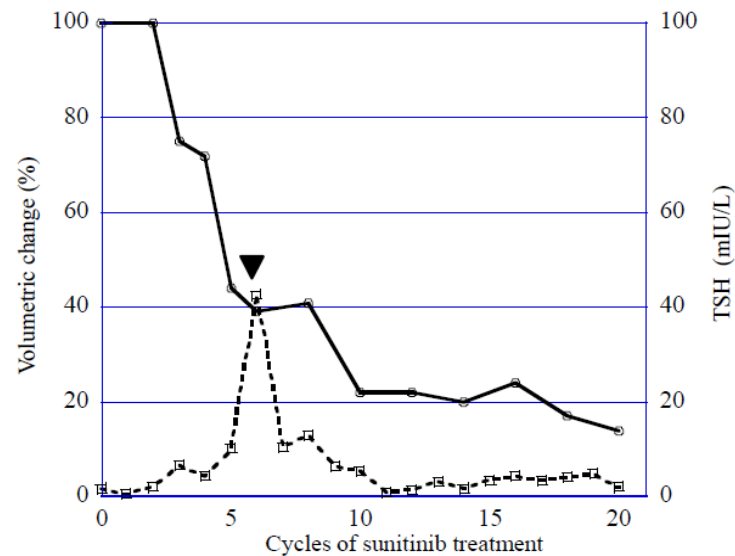




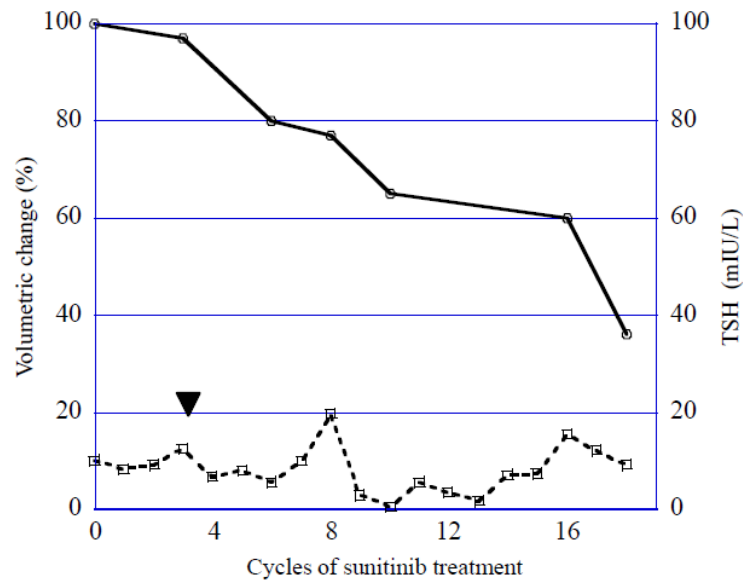
Patient 5



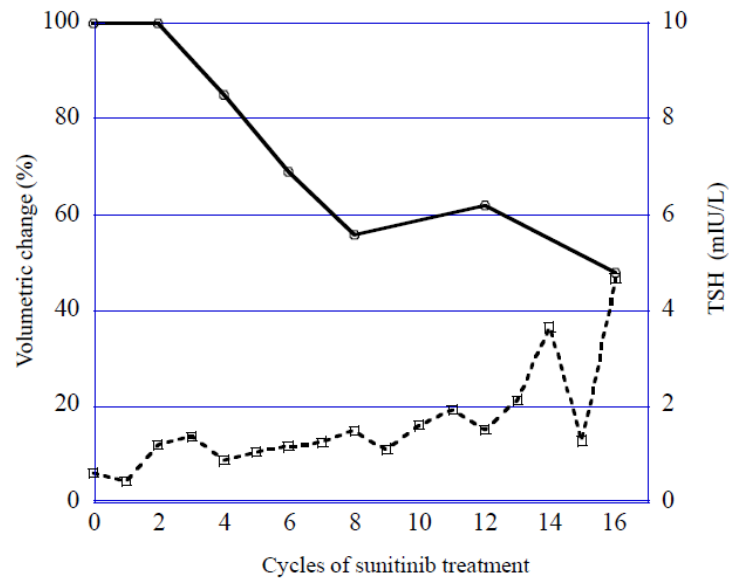
Patient 6

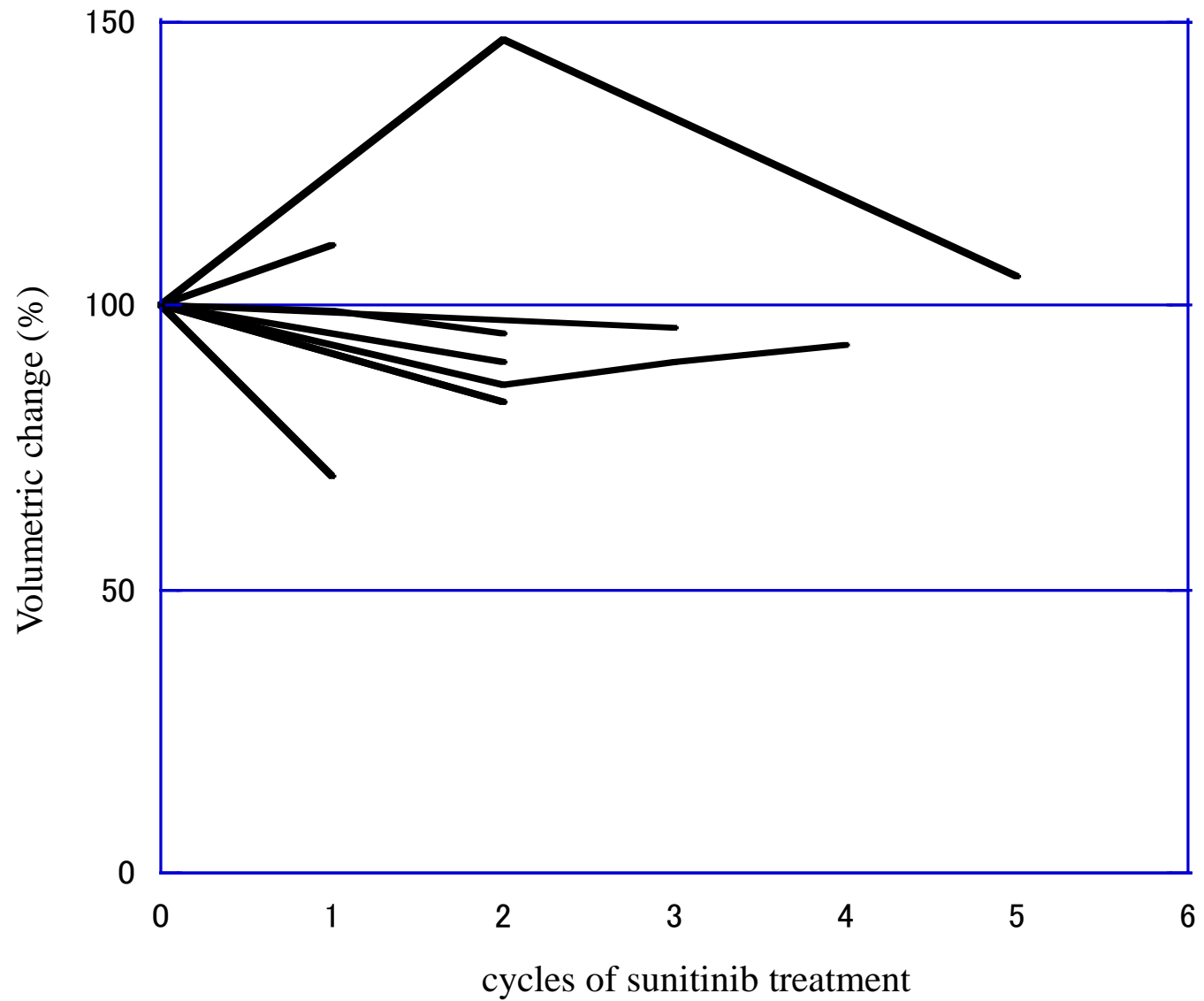


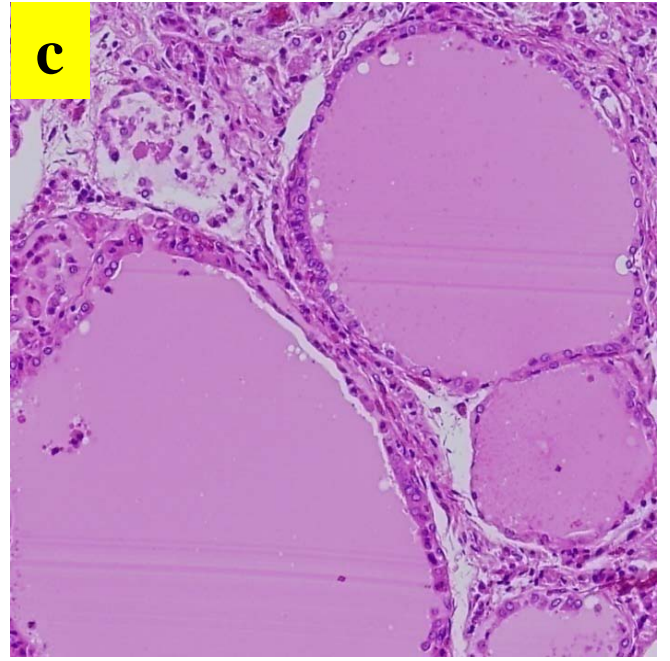
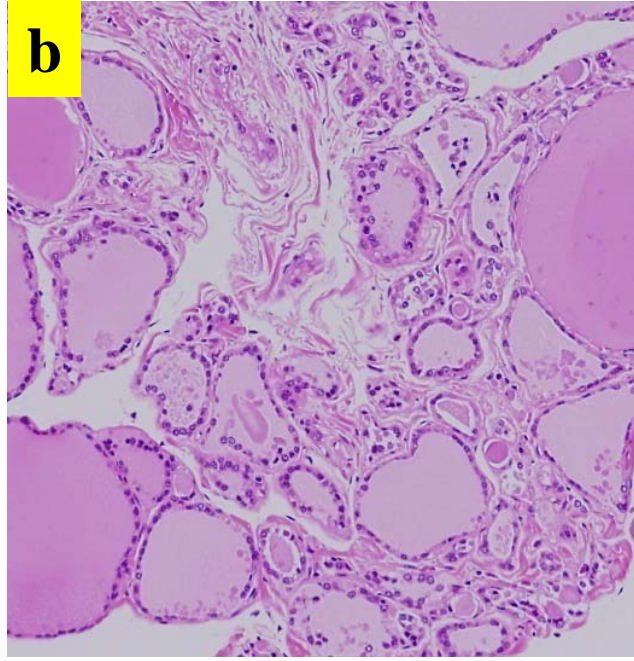
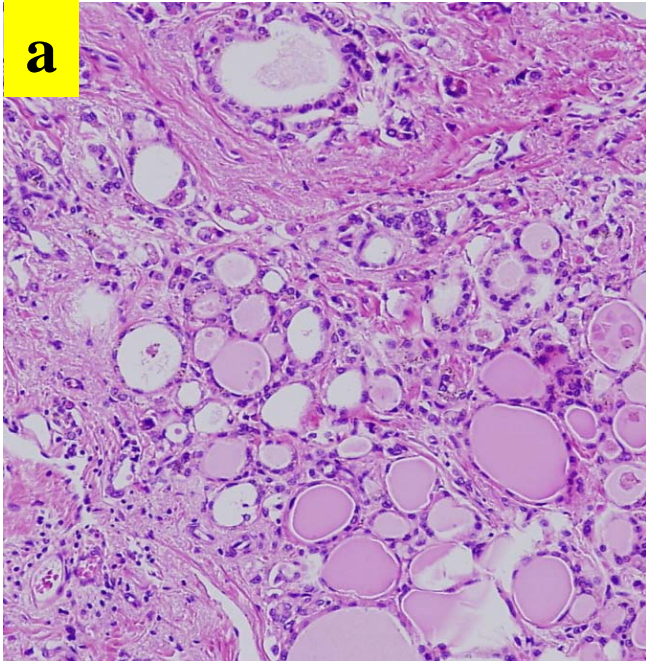
Patient 7



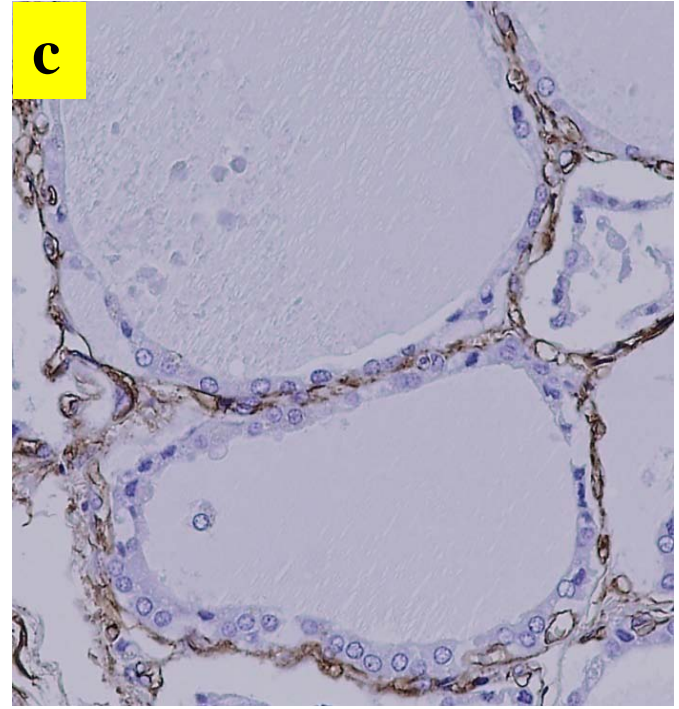
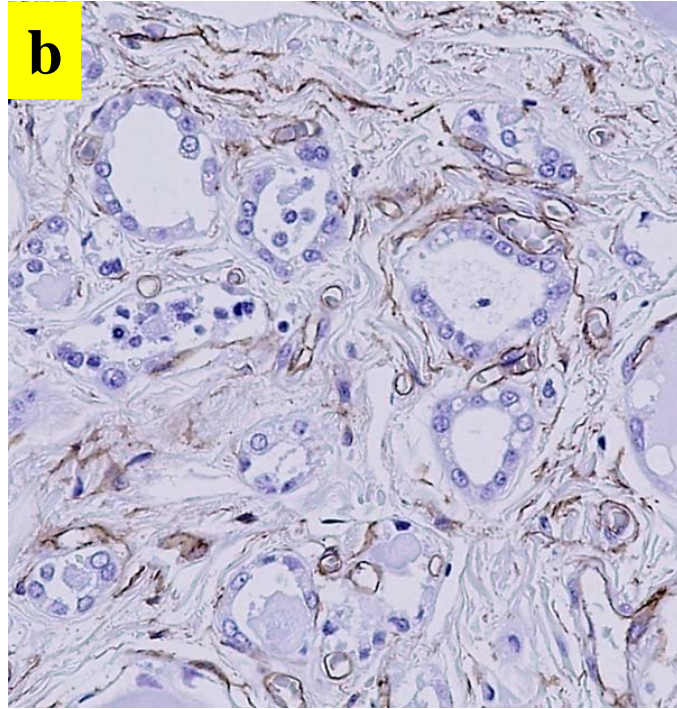
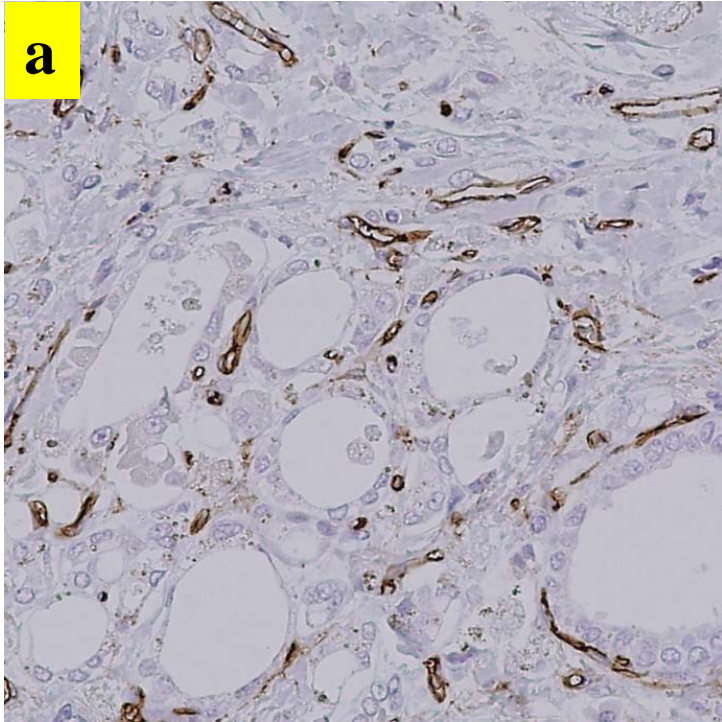
Patient 8







× 100



× 100